

Copyright is owned by the Author of the thesis. Permission is given for a copy to be downloaded by an individual for the purpose of research and private study only. The thesis may not be reproduced elsewhere without the permission of the Author.

**Comparison of transcutaneous ultrasound over  
the right flank with transrectal  
ultrasonography in the diagnosis of pregnancy  
in New Zealand dairy herds**

A thesis presented in partial fulfillment of the requirements  
for the degree of  
**Master of Veterinary Science**  
at Massey University

**Jaimie Catherine Glossop**  
2004



## **Abstract:**

Application of a 3.5 MHz sector transducer over the right flank allows the rapid and clear visualization of bovine pregnancy (ie: fetus, fetal membranes, fetal fluid and/or placentomes). A total of 1736 cows in ten commercial, pasture-based New Zealand dairy herds were examined for pregnancy by transcutaneous ultrasound across the right flank and transrectal ultrasound between 37 and 198 days of gestation. The gold standard was derived from calving records or examination at slaughter. The overall sensitivity of transrectal ultrasound (96.24%) was markedly higher than flank ultrasound (58.55%) and the overall probability of a correct diagnosis of pregnancy status was also significantly higher ( $p < 0.0001$ ). From 155 days of gestation, however, flank ultrasound represented a more accurate method of pregnancy diagnosis and the probability of a correct diagnosis was significantly higher ( $p < 0.0001$ ) after this gestational age.

The gestational age of 225 cows from four Spring-calving dairy herds was determined and ultrasound pregnancy test recorded, to determine possible fetal characteristics able to be visualized via transcutaneous ultrasound over the right flank in order to age pregnancy during mid to late gestation. Linear or quadratic equations and curves were formulated from 60 to 198 days of gestation. The fetal characteristics of thoracic diameter, abdominal diameter or umbilical diameter can be used to age pregnancy from 60 days of gestation. Placentome height and length were not significant in the determination of gestational age.



## **Acknowledgements:**

I would like to acknowledge the partial funding received for these studies from the New Zealand Large Herd Association (NZLHA) and Massey University who purchased the 3.5 MHz sector scanner for this study.

My sincere thanks go to my supervisors, Dr Tim Parkinson, Dr Scott McDougall and Nick Lopez-Villalobos who never failed to give me support, encouragement and a “gentle shove” when needed.

I cannot thank enough the Whangarei-based herdowners and managers who willingly participated in the study, providing complete access to their herds, records and time. My sincere thanks go to Rob and Jo Philip; John and Jenny Waterhouse; Grant and Gaylene Pram; Barrie Neeley; Darryl and Raewyn Barge; David and Erin Jones; Peter and Cath Noakes; Royce and Lorraine Kokich; Tom and Sue Wood; Dave and Sharon Hodgson; Archie and Gail Rika and their herd manager Birgit. I would also like to thank Andrew and Anne Fraser, Fraser McBeth and Brett Farrell who demonstrated enormous patience during the early trials of the project involving rotary dairies.

Thank you to all at Whangarei Veterinary Services, particularly Dr Angus Campbell, Dr Jules Wilson, Dr Vicki Payne, Sue Wood, Linda Elson, Jane Langford and Faye Moore who provided the ultrasound machine, transrectal transducer and never-ending support, patience and chocolate biscuits. A huge thankyou to Shelley McKenzie who was always a willing assistant despite hardships (ie: several long showers!). Thank you also to the Animal Health Centre, Whangarei for lending their ultrasound scanner.

Thank you also to all at South and Mid Canterbury Vet Services, in particular those at Ashbury Vet Centre, Timaru and Ashburton Veterinary Centre, Ashburton for their patience in my frequent absences in order to finish this Thesis.

My sincere thanks to Dr Kevin Bell, chief veterinary officer and staff at Dargaville Beefpackers and the head of the meat department and staff at Morewa Richmond for examination of all cull animals included in this study.

It takes more than a simple acknowledgement to express my thanks to my family, friends and, in particular, Johann for providing support and encouragement every step of the way – couldn't have and wouldn't have done it without you.

## **Table of contents:**

Acknowledgements

Table of contents

List of tables and figures

## **Chapter 1:**

### **LITERATURE REVIEW OF MID-GESTATION PREGNANCY TESTING IN CATTLE**

#### 1.1 The Anatomy of Bovine Pregnancy

##### 1.1.1 The non-pregnant cow

##### 1.1.2 The pregnant cow

###### 1.1.2.1 Early pregnancy (<3 months)

Fertilization and cleavage

Early embryonic development

Implantation and placentation

###### 1.1.2.2 Mid pregnancy (3-6 months)

###### 1.1.2.3 Late pregnancy (>6 months)

#### 1.2 Currently Available Mid-Gestation Pregnancy Testing Techniques

##### 1.2.1 Manual palpation *per rectum*

###### 1.2.1.1 Early (<3 months)

###### 1.2.1.2 Mid (3-6 months) and Late (>6 months)

###### 1.2.1.3 Fetal ageing using manual palpation *per rectum*

##### 1.2.2 Transrectal ultrasonography

###### 1.2.2.1 Early (<3 months)

###### 1.2.2.2 Mid (3-6 months) and Late (>6 months)

###### 1.2.2.3 Fetal ageing using transrectal ultrasonography

##### 1.2.3 The potential consequences of pregnancy diagnosis *per rectum*

###### 1.2.3.1 Stress and Pain

###### 1.2.3.2 Injury

##### 1.2.4 Oestrone sulphate

##### 1.2.5 Progesterone

##### 1.2.6 Oestrus detection

- 1.2.7 Abdominal enlargement and right abdominal wall
- 1.2.8 Post-oestrus bleeding
- 1.2.9 Changes in udder size
- 1.2.10 Doppler/fetal echocardiography
- 1.2.11 Electrocardiography
- 1.2.12 Early pregnancy factor (EPF)
- 1.2.13 Bovine pregnancy specific protein B (bPSP-B) and bovine pregnancy associated glycoprotein (bPAG)
- 1.2.14 Transcutaneous flank ultrasound
- 1.3 Pregnancy testing and the herdowner
  - 1.3.1 The Northland/New Zealand dairy farm
  - 1.3.2 Spring and Autumn calving
- 1.4 Mid-gestation pregnancy testing and the veterinarian
- 1.5 Conclusion

## **Chapter 2:**

### **DEVELOPMENT OF A TRANSCUTANEOUS ULTRASOUND METHOD OVER THE RIGHT FLANK TO DIAGNOSE PREGNANCY IN THE DAIRY COW**

- 2.1 Scanner placement: the right flank
- 2.2 Transducer type: sector scanner
- 2.3 Transducer frequency: 3.5 MHz
- 2.4 Preparation of the animal and right flank
- 2.5 Current New Zealand holding facilities
  - 2.5.1 Vet/AI race
  - 2.5.2 Crush
  - 2.5.3 Walk-through dairy
  - 2.5.4 Herringbone dairy
  - 2.5.5 Rotary herringbone
  - 2.5.6 Rotary Turnstyle
- 2.6 Preliminary images derived from transcutaneous scans over right flank
  - 2.6.1 The non-pregnant cow
  - 2.6.2 The pregnant cow
- 2.7 Conclusion

### **Chapter 3:**

## **COMPARISON OF TRANSCUTANEOUS FLANK ULTRASOUND WITH RECTAL ULTRASOUND FOR PREGNANCY DIAGNOSIS IN THE DAIRY COW**

### 3.1 Introduction

### 3.2 Materials and Methods

#### 3.2.1 Real-time B-mode transrectal ultrasonography

#### 3.2.2 Manual palpation *per rectum*

#### 3.2.3 Real-time transcutaneous flank ultrasonography

##### 3.2.3.1 Plank

##### 3.2.3.2 Pit

##### 3.2.3.3 Vet/AI race

#### 3.2.4 Gold standard

#### 3.2.5 Calculation of conception dates

#### 3.2.6 Comparison and statistics

### 3.3 Results

#### 3.3.1 Numbers examined and derivation of gold standard

#### 3.3.2 Sensitivity, specificity and positive and negative predictive values

##### 3.3.2.1 Overall results

#### 3.3.3 Results by:

##### 3.3.3.1 Gestational age at pregnancy diagnosis (days)

##### 3.3.3.2 Probability curves

##### 3.3.3.3 Herd

##### 3.3.3.4 Method of diagnosis (flank)

##### 3.3.3.5 Cow breeds

##### 3.3.3.6 Cow age

##### 3.3.3.7 Sire breed

##### 3.3.3.8 Calf sex

##### 3.3.3.9 Comparison of veterinarians

### 3.4 Discussion

### 3.5 Conclusion

## **Chapter 4:**

# **MEASUREMENT OF FETAL CHARACTERISTICS IN ORDER TO DETERMINE THE LENGTH OF GESTATION AT DATE OF PREGNANCY DIAGNOSIS BY TRANSCUTANEOUS ULTRASOUND OVER THE RIGHT FLANK**

## 4.1 Introduction

## 4.2 Materials and Methods

### 4.2.1 Pregnancy diagnosis

### 4.2.2 Estimation of fetal age

### 4.2.3 Statistical analysis

## 4.3 Results

### 4.3.1 Thoracic diameter

### 4.3.2 Abdominal diameter

### 4.3.3 Umbilical diameter

### 4.3.4 Placentome height

### 4.3.5 Placentome length

## 4.4 Discussion

## 4.5 Conclusion

## **REFERENCES**



## List of tables and figures:

Table 1.1	Approximate size and “rule of thumb” measurement using the average hand for amniotic size according to gestational age
Table 3.1	Herd size and the date of the start of artificial insemination and natural mating and end of natural mating relative to the date of pregnancy diagnosis
Table 3.2	Number of cows culled and retained on-farm with results of each herd
Table 3.3	Derivation of pregnant and non-pregnant cow gold standard
Table 3.4	Comparison of results for pregnant and non-pregnant cows
Table 3.5	Values for correct pregnant (a), incorrect pregnant (b), correct non-pregnant (c), incorrect non-pregnant (d), sensitivity, specificity, and positive (PPV) and negative (NPV) predictive values for the two methods
Table 3.6	Values for a, b, c, d, sensitivity, specificity, positive (PPV) and negative (NPV) predictive values for each gestational stage
Figure 1.1	Dorsal view of a cow’s uterus, partially dissected
Figure 1.2	Lateral view of the genitalia and udder of a cow
Figure 1.3	Early embryonic development within the bovine oviduct
Figure 1.4	Hatching of the blastocyst
Figure 1.5	Bovine fetus and placenta
Figure 1.6	Growth curve and development stages of the cow
Figure 1.7:	Right lateral view demonstrating the position of the gravid uterus: at 5 months the uterus is out of reach via manual palpation <i>per rectum</i>
Figure 1.8	Left lateral view demonstrating the position of the gravid uterus: Manual palpation <i>per rectum</i> of a “late” pregnancy
Figure 1.9	A transrectal ultrasound image of a fetus at 65 days of gestation showing the heart, rumen, ribs and a placentome
Figure 2.1	The surface anatomy of the bovine right flank. The transducer is placed underneath the right flank fold
Figure 2.2	Topography of the nerves to the flank
Figure 2.3	Scanner placement for the visualization of early and late pregnancies
Figure 2.4	Topography of the abdominal viscera in the non-pregnant cow
Figure 2.5	Ventral views of the abdominal viscera of a newborn calf, a non-pregnant cow and a heavily pregnant cow
Figure 2.6	Right lateral and transverse view of the gravid and non-gravid horn in mid to late pregnancy
Figure 2.7	Linear and sector transducers
Figure 2.8	Cows held in an AI/vet race allowing easy access to the right flank
Figure 2.9	A crush with head bale and side gate access
Figure 2.10	Movement of the bottom side gate allows access to the right flank in a crush
Figure 2.11	A simple high-line, swing-over Herringbone dairy

- Figure 2.12 Access to the right flank at pit level in the left side of a Herringbone shed
- Figure 2.13 Direction of cow movement and accessibility to the right flank of each animal in a Rotary Herringbone dairy
- Figure 2.14 Cow position on a Rotary Herringbone shed
- Figure 2.15 Rotary Turnstyle dairy
- Figure 2.16 Demonstrating the difficulty in gaining access to the right flank due to intervening pipework of the bail dummy and kick rail in the turnstyle rotary shed and the area available for cow movement within the bale
- Figure 2.17: Small intestinal loops filling the right caudoventral abdomen in a non-pregnant cow
- Figure 2.18 A lateral and craniocaudal view of a fetal abdomen and thorax with anechoic ruminal compartments, acoustic shadowing from the ribs, the hyperechoic reticulum and granular intestinal mass
- Figure 2.19 Fetal forelimbs and cranial thorax at 104 days of gestation
- Figure 2.20 Lateral view of fetal tail vertebrae at 111 days of gestation illustrating the relatively fine detail achievable by transcutaneous scanning.
- Figure 2.21 Two views of the fetal heart chambers, pericardium and ribs at 139 days and 95 days of gestation
- Figure 2.22 Placentomes and a placental anastomosis of a twin pregnancy at 106 days of gestation.
- Figure 2.23 Longitudinal and cross-sectional images of an umbilical cord and fetal membranes
- Figure 3.1 Application of the transcutaneous flank technique to diagnose pregnancy in the left side of a Herring-bone shed.
- Figure 3.2 Sensitivity of transrectal and flank ultrasound according to age at pregnancy diagnosis (days)
- Figure 3.3 Specificity of transrectal and flank ultrasound according to age at pregnancy diagnosis (days)
- Figure 3.4 Probability curve of a correct diagnosis using transcutaneous flank ultrasound (p) according to gestational age at pregnancy diagnosis (days)
- Figure 3.8 Probability of a correct diagnosis using rectal ultrasound (p) according to gestational age at pregnancy diagnosis (days)
- Figure 4.1 The number and frequency scanned by transcutaneous ultrasound for fetal ageing
- Figure 4.2 Principal fetal and placental measurements
- Figure 4.3 The number and relative accessibility of each measurement relative to the total number of animals available
- Figure 4.4 Thoracic diameter at 89 days of gestation and 107 days of gestation
- Figure 4.5 Thoracic diameter at 127 days of gestation and 153 days of gestation
- Figure 4.6 The significance of possible effects on fetal thoracic diameter

- Figure 4.7 Foetal age estimation curve: Thoracic diameter according to gestational age at pregnancy diagnosis (days)
- Figure 4.8 Abdominal diameter at 57 days and 118 days of gestation
- Figure 4.9 Abdominal diameter at 131 days and 151 days of gestation
- Figure 4.10 Abdominal diameter at 183 days of gestation
- Figure 4.11 The significance of possible effects on fetal abdominal diameter
- Figure 4.12 The significance of each cow and bull breed on fetal abdominal diameter
- Figure 4.13 Fetal age estimation curve: Abdominal diameter according to gestational age at pregnancy diagnosis (days)
- Figure 4.14 Umbilical diameter at 89 days of gestation and 118 days of gestation
- Figure 4.15 Umbilical diameter at 137 days of gestation and 146 days of gestation
- Figure 4.16 Umbilical diameter at 192 days of gestation
- Figure 4.17 The significance of possible effects on fetal umbilical diameter
- Figure 4.18 Fetal age estimation curve. Umbilical diameter according to gestational age at pregnancy diagnosis (days)
- Figure 4.19 Similar sized placentomes at 124 days of gestation and 89 days of gestation
- Figure 4.20 The significance of possible effects on placentome height
- Figure 4.21 Relative frequencies at which various parts of the fetal body were accessible for transrectal ultrasound in relation to month of gestation
- Figure 4.22 Regression of uterine and umbilical blood flows on day of gestation
- Figure 4.23 Mean diameter and thickness (mm) of placentomes surrounding in vivo embryos and fetuses from Day 37 to Day 93 of pregnancy





## **CHAPTER 1:**

### **LITERATURE REVIEW OF MID-GESTATION PREGNANCY TESTING IN CATTLE**

The accurate diagnosis of pregnancy is an essential factor in the assurance of economic success on the New Zealand dairy farm (Oltenacu *et al.*, 1990; Honey, 1998). Although transrectal ultrasound and manual palpation *per rectum* are the most common techniques currently used for pregnancy diagnosis, the accuracy of both is limited in mid to late gestation due to movement of the fetus over the cranial pelvic brim and towards the dam's ventral abdominal wall. Veterinarians are commonly asked to pregnancy test either individual or groups of cows in mid to late gestation and a technique which would allow accurate and efficient pregnancy detection and ageing at this stage of gestation would be an asset to both the veterinarian and herdowner. Although transcutaneous scanning over the ventral abdomen and right flank in order to diagnose pregnancy has been successfully completed in a number of species, including horses, deer and sheep, there has not been a comprehensive study of its potential use in cattle. The unusual uterine anatomy and abdominal shape and size of dairy and beef cattle, the possible advantages of accurate mid-gestation pregnancy diagnosis and the accuracy of currently available methods must be taken into consideration when assessing the potential of this technique.

#### **1.1 THE ANATOMY OF BOVINE PREGNANCY:**

##### **1.1.1 THE NON-PREGNANT COW:**

Although the structure and position of the bicornuate, non-pregnant bovine uterus is highly dependant on the stage of the reproductive cycle and the age, parity and condition score of the animal, in general the uterine body can be found lying within the pelvic cavity (Dyce *et al.*, 1996). The main support for the uterus arises from a fold of peritoneum known as the broad ligament which originates from the dorsolateral wall of the pelvic cavity (Sorenson, 1979). The cranial section of the broad ligament, or

mesovarium, attaches to and supports the ovary and is continuous with the mesosalpinx which supports the oviducts (see Figure 1.1). The proper ovarian ligament, which is a section of the mesovarium, directly anchors the ovary in place. The caudal broad ligament, or mesometrium, attaches to the lateral borders of the uterine horns and body. The round ligament is situated in the lateral fold of the mesometrium and plays an active role in maintaining the non-pregnant uterus within the pelvic cavity (Smallwood, 1992).

The vagina of the non-pregnant animal is 25-30 cms long with collapsed, muscular walls (Sorenson, 1979) (See Figure 1.1). The 8-10 cm long cervical canal is tortuous and, in the non-pregnant uterus, tightly closed and difficult to dilate (Getty, 1975). Although the uterine body, externally, appears to be up to 15 cms, it is, in reality, only 3-4 cms long, due to an intercornual ligament connecting the caudal sections of the two uterine horns (Hafez and Rajakoski, 1964). The myometrium or uterine body wall consists of an external longitudinal layer and two inner circular strata and is lined with longitudinal folds (Getty, 1975). During uterine development within the foetus, small, rounded prominences called caruncles develop on and in these longitudinal folds.

The uterine horns, which have an average length of 35-40 cms, are coiled into a spiral, similar to the horns of a ram, and taper at their junction with the uterine tubes or oviducts (Smallwood, 1992). The mucosa of the oviducts consists of a complex arrangement of primary, secondary and tertiary folds which almost fill the oviductal lumen (Hafez and Hafez, 2000). The ciliated cells of the oviductal mucosa have slender, motile cilia which extend into the lumen and beat towards the uterine body. The cranial end of the coiled oviducts form a large, funnel-shaped uterine orifice, or infundibulum, and the fringed border of the terminal membrane, or fimbriae, lie closely over the ovary allowing safe passage of the ovum following ovulation (Sorenson, 1979). In the non-pregnant cow, the ovaries lie in a

thin peritoneal fold of the mesosalpinx, or ovarian bursa, within the peritoneal cavity, near the middle of the lateral margin of the pelvic inlet (Hafez and Hafez, 2000). The size of the oval, flattened ovaries varies greatly with the stage of the reproductive cycle but they are measured at 4 cms in length and 2.5 cms in width in their anoestrus state (Getty, 1975; Sorenson, 1979).

The primary blood supply to the uterus is the uterine artery which arises as the first branch of the umbilical artery, which, in turn, is a branch of the internal iliac artery (see Figure 1.2). The uterine artery anastomoses cranially with the ovarian artery, a direct branch of the abdominal aorta, which becomes tortuous and forms a plexus with the ovarian vein near the ovary (Smallwood, 1992).

### **1.1.2 THE PREGNANT COW:**

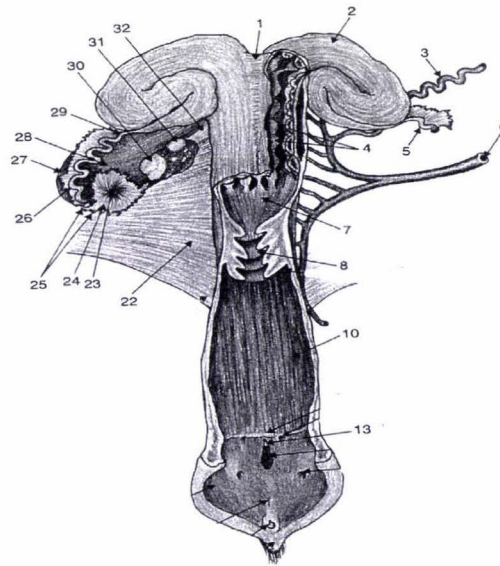
The accepted average gestation length of dairy cattle within New Zealand is currently 282 days, with a range of 272-293 days. Nonetheless there are a number of factors which have been repeatedly shown to influence the gestation length of cattle including season, region, breed of sire, calf sex and the presence of twins (Anderson and Plum, 1965; MacMillan and Curnow, 1976). Pregnancy can be divided into three time periods:

1. "Early" pregnancy (first trimester): less than 3 months
2. "Mid" pregnancy (second trimester): 3-6 months
3. "Late" pregnancy (third trimester): over 6 months

#### **1.1.2.1 EARLY pregnancy (< 3 months):**

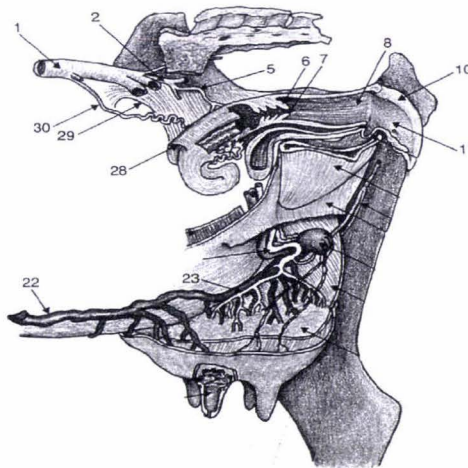
a. Fertilization and cleavage:

After ejaculation of semen into the cranial end of the vagina and cervix, large amounts of sperm are trapped in the complex mucosal folds of the cervical crypts (Hafez and Hafez, 2000). The sperm, which are released sequentially for a prolonged period, are transported to the uterine tubes via



- |   |                                  |
|---|----------------------------------|
| 1. Dorsal part of intercornual ligament | 22. Mesometrium                  |
| 2. Right uterine horn                   | 23. Abdominal opening of oviduct |
| 3. Right ovarian artery                 | 24. Infundibulum                 |
| 4. Caruncles in right uterine horn      | 25. Frimbriae                    |
| 5. Right uterine horn                   | 26. Ampulla of oviduct           |
| 6. Right uterine artery                 | 27. Mesosalpinx                  |
| 7. Uterine body                         | 28. Ovarian bursa                |
| 8. Cervical canal with circular folds   | 29. Isthmus of oviduct           |
| 10. Vagina                              | 31. Ovarian follicle             |
| 13. External urethral orifice           | 32. Proper ligament of ovary     |

**Figure 1.1:** Dorsal view of a cow's uterus, partially dissected (From Smallwood, 1992)



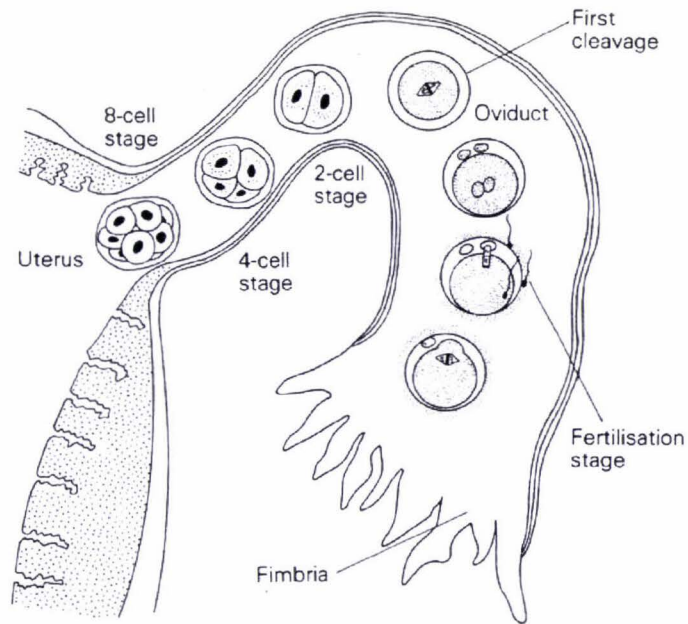
- |                                |   |
|--------------------------------|---|
| 1. Aorta                       | 22. Subcutaneous abdominal vein   |
| 2. Right internal iliac artery | 23. Cranial mammary artery  |
| 5. Right uterine artery        | 28. Intercornual ligament   |
| 7. External ostium of uterus   | 29. Lateral fold of right broad ligament, containing round ligament of the uterus |
| 8. Vagina                      | 30. Right ovarian artery  |
| 11. Vestibule                  |   |

**Figure 1.2:** Lateral view of the genitalia and udder of a cow (From Smallwood, 1992)

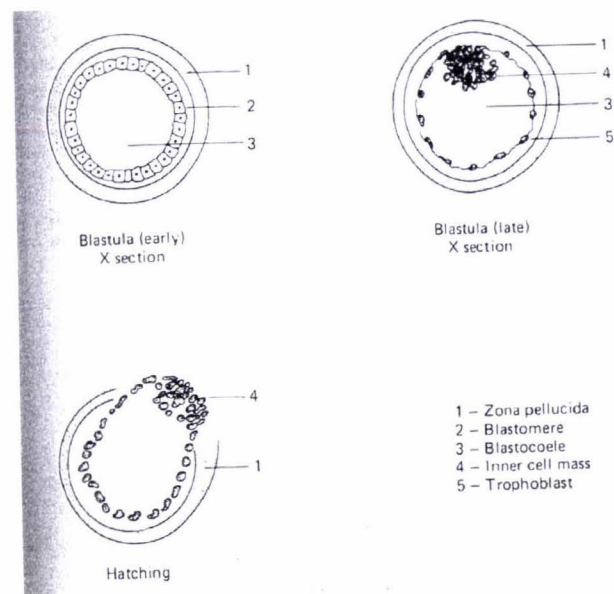


the contractile activity of the vagina and myometrium. Follicles, which produce and contain the growing ovum, appear as clear blisters bulging from the ovarian surface (Sorenson, 1979) (see Figure 1.1). The ovary, through the action of the proper ovarian ligament and the mesovarium, is propelled to the surface of the fimbriae into which the mature ovum is released on rupture of the follicle. The cilia of the mucosa of the uterine tubes convey the egg and sperm in opposite directions almost simultaneously, allowing fertilization within the infundibulum. In cattle, ovulation occurs most commonly from the right ovary and, as the embryo is typically confined unilaterally, 58-60% of bovine pregnancies occur in the right horn (Dyce *et al.*, 1996; Nation *et al.*, 2003). In the majority of twin pregnancies, one ovulation occurs in each ovary and one twin is present in each horn (Arthur *et al.*, 1982). Unicornual twins, where two foeti are found in the one horn, result from two ovulations from the one ovary, while 4-6% of all twin pregnancies are identical twins which result from a single ovulation.

The sperm undergo capacitation within the uterine tubes, which involves modification and removal of components on the sperm's surface, before it can become capable of penetrating the ovum (Hunter, 1982). Movement of the sperm through the zona pellucida and into the perivitelline space causes the ovum to become "activated". The ovum undergoes meiosis resulting in the two haploid groups of chromosomes becoming enclosed within pronuclei (Hafez and Hafez, 2000). These pronuclei meet in the centre of the ovum, undergo cytoplasm division and produce a 2-cell egg which undergoes several mitotic divisions. Spontaneous separation of the blastomeres (embryonic cells) at this stage can result in the development of identical twins (Latshaw, 1987). After remaining within the uterine tube for 3 days, the embryo is propelled towards the uterine body at the 8-16 cell stage (morula) via the peristaltic contractions and ciliary currents of the oviduct (Arthur *et al.*, 1982) (see Figure 1.3). The timing of uterine entry appears to be critical for future embryonic development and is delayed by



**Figure 1.3:** Early embryonic development within the bovine uterine tube (From Hunter, 1982).



**Figure 1.4:** Hatching of the blastocyst (From Sorenson, 1979)

the sphincter action of the isthmic region of the uterine tube (Dyce *et al.*, 2002). Although the embryo is released with a considerable cytoplasmic reserve of yolk, it soon becomes dependant on uterine fluid or “milk” (Hunter, 1982).

b. Early embryonic development:

The embryonic cells, on 7-9 days post-fertilization, secrete fluid into the intracellular spaces and form a central, fluid-filled space known as the blastocyst (Sorenson, 1979). The surrounding single layer of cells is called the trophoblast and contributes to the formation of extra-embryonic structures including the foetal membranes (Latshaw, 1987). At one pole of the blastocyst, there a small group of cells, known as the inner cell mass, which develop into the embryo proper. Expansion and contraction of the blastocyst causes tearing of the surrounding zona pellucida 9-11 days after fertilization, in a process called hatching (Arthur *et al.*, 1982) (see Figure 1.4). From 13-17 days of gestation, the blastocyst elongates rapidly, through hyperplasia of the trophoblast and rearrangement of the cell layers, from a sphere to a filamentous thread-like structure up to 25 cms in length (Hunter, 1982). There is relatively little embryonic migration within the uterus but by 18 days of gestation the blastocyst has extended into the contralateral horn and so caused extensive preimplantation exposure to the myometrium (Latshaw, 1987; Hafez and Hafez, 2000). Maternal recognition of pregnancy in cattle occurs between 15-17 days of gestation.

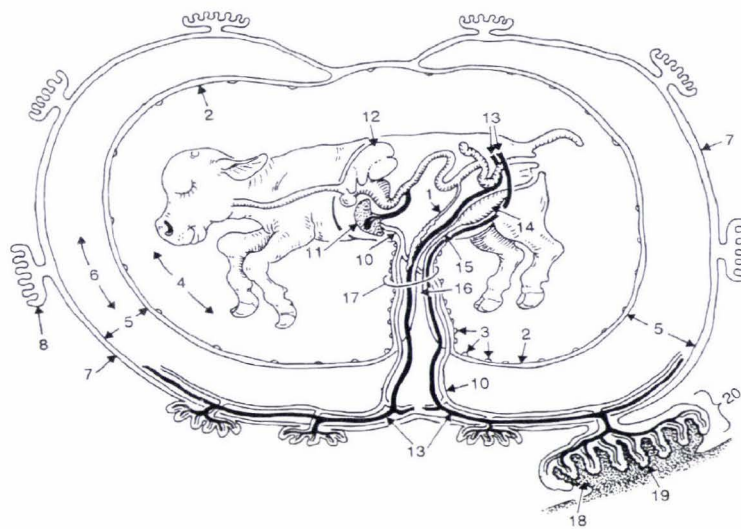
c. Implantation and placentation:

Embryonic and placental development in the cow requires the differentiation of four distinct extraembryonic membranes: yolk sac, amnion, allantois and chorion. The yolk sac, which is continuous with the embryonic gut, is initially large but regresses as the placenta develops. It functions to nourish the embryo during its early development and forms the first red blood cells and primordial germ cells (Latshaw, 1987). By 25 days post-fertilization, the yolk sac is reduced to a solid, cord-like structure within the umbilical cord.

The embryo is situated within the amniotic vesicle (see Figure 1.5.) The allantois, which is an outgrowth of the embryonic hindgut, fills with allantoic fluid and makes contact with the outer chorion to form the vascular allanto-chorionic membrane 40-60 days post-fertilization (Arthur *et al.*, 1982). The allantois also fuses inwardly with the amnion to form the allanto-amnion. In twin or triplet pregnancies, adjoining sacs coalesce to create allantoic vascular communication between the fetal membranes by Day 40 of gestation. Although the source of amniotic and allantoic fluid is not clear, it is likely to be a distillate of the blood within the allantoic vessels and urine collected through the urachus in the umbilical cord (Sorenson, 1979; Latshaw, 1987) (see Figure 1.6).

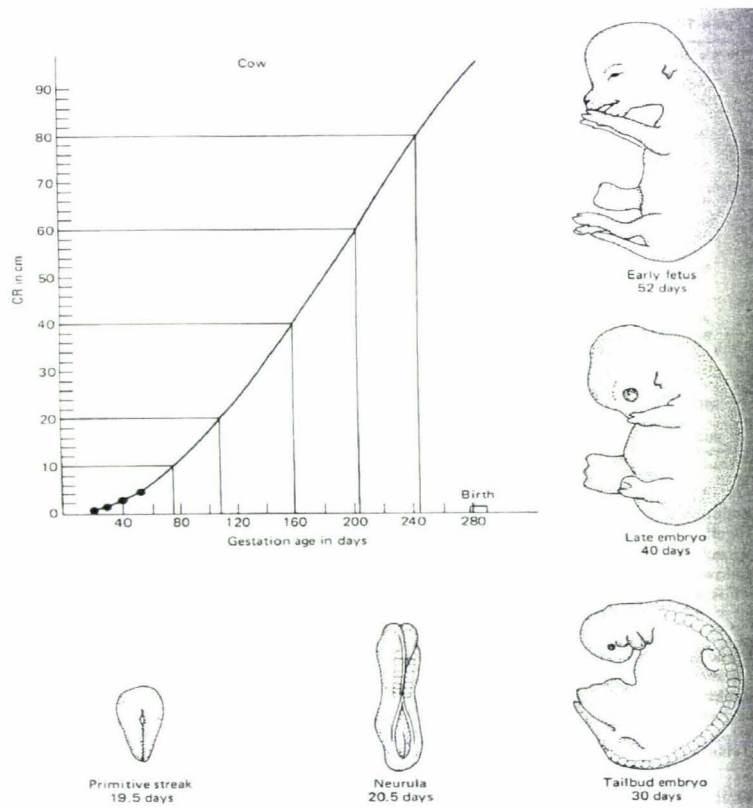
At 28 days of pregnancy the amniotic sac is spherical and approximately 2 cms in diameter but by 60 days of gestation the amnion is oval and relatively tense with a transverse diameter of 5 cms (Arthur *et al.*, 1982). The majority of fetal fluid in the first third of pregnancy is allantoic fluid that gravitates to the poles of the allantochorion lying in the dependant sections of the uterine horns (Arthur *et al.*, 1982). Fetal fluid provides a protective cushion for the developing fetus, prevents adherence of the embryo to the surrounding membranes and allows unrestricted movement of the fetus in the early stages of pregnancy. As there is no pronounced decidual reaction in cattle, it is difficult to determine when implantation takes place (Dyce *et al.*, 2002). The ruminant placenta is cotyledonary and histologically has been classified as epitheliochorial (Noakes, 1985). Within 22 days of fertilization, the chorioallantois attaches to caruncles on the uterine endometrium at specialized areas of attachment known as cotyledons (see Figure 1.5) (Hunter, 1982). The attachments take the form of interdigitating villous projections within the walls of the maternal crypts, which allow a surface area of contact between the dam and fetus of over 130 metres squared (Latshaw, 1987; Schlafer, 2000). The bovine placenta consists of 70-120 of these combinations of cotyledons and caruncles.





- |                        |                        |                      |
|------------------------|------------------------|----------------------|
| 1. Remnant of yolk sac | 7. Chorion             | 14. Urinary bladder  |
| 2. Amnion              | 8. Cotyledon           | 15. Urachus          |
| 3. Amnionic plaques    | 10. Umbilical vein     | 16. Allantoic stalk  |
| 4. Amnionic cavity     | 11. Liver              | 17. Umbilical cord   |
| 5. Allantois           | 12. Stomach            | 18. Caruncle         |
| 6. Allantoic cavity    | 13. Umbilical arteries | 19. Chorionic villus |
|                        |                        | 20. Placentome       |

**Figure 1.5:** Bovine fetus and placenta (From Smallwood, 1992)



**Figure 1.6:** Growth curve and development stages of the cow (From Evans and Sack, 1972)

collectively known as placentomes, which are arranged in four rows, two ventral and two dorsal, running lengthwise along both uterine horns (Roberts, 1986). The largest placentomes are situated around the fetus itself and at the attachment of the middle uterine artery and tend to decrease in size towards the horn's apex. There are also accessory placentomes at the intercaruncular areas (Latshaw, 1987). There is no relationship between either the placentome weight or length and the number of placentomes present which suggests the normal bovine placentome has a large reserve capacity available (Laven, 2001). Placentome development in the non-gravid horn remains unaffected by growth within the gravid horn and Laven *et al.* (2001) found 21% (10/47) of uteri, in fact, had no placental development within the non-gravid horn. The section of chorioallantois which occupies the uterine horn tip undergoes degeneration and coagulative necrosis and these necrotic placental tips can reach 3-5 cms in length (Schlafer *et al.*, 2000).

Organogenesis begins at or shortly after the time of implantation (Currie, 1995). The three cell layers of ectoderm, mesoderm and entoderm are formed through thickening of the trophoblast in a process known as gastrulation. The ectoderm (outer cell layer) forms the outer skin, epidermis, hooves, brain and nervous system. The mesoderm (middle cell layer) forms muscle, cartilage, ligaments, bones and circulation organs (eg: heart) while the entoderm (inner cell layer) forms the glands, liver and lining of the gastrointestinal tract (Sorenson, 1979). Initially amniotic and allantoic fluid production exceeds early foetal growth. Prior to 90 days of gestation the increase in embryonic weight is 85 times relative to crown-rump length, while the amniotic fluid volume increases 580 times in the same time period (see Figure 1.6) (Hafez and Rajakoski, 1964).

### **1.1.2.2 MID pregnancy (3-6 months):**

Uterine distension is marked by 90 days of gestation, with a gravid and non-gravid horn width of 9 cms and 4.5 cms respectively (Arthur *et al.*, 1982). There is a dramatic increase in the volume of amniotic fluid between 3 and 4 months of gestation and, although broad ligament hypertrophy initially prevents it, by 120 days of gestation the gravid horn has sunk below the cranial pelvic brim (Zemjanis, 1970). In some multigravid or obese animals, the uterus will lie in the abdomen before this time. The uterus typically enters the supraomental recess, between the right face of the rumen and the greater omentum, before descending to the dam's abdominal floor by 150 days of pregnancy. On occasion, the uterus may slip forward against the right or, less frequently, the left flank, displacing the intestines or rumen respectively from the abdominal wall (Dyce *et al.*, 1996). Allantoic fluid gravitates towards the extremities of the cornua between 4-5 months and concurrent elongation of the cervix and vagina is readily noticeable at this stage of gestation (Abusneina, 1969). During the early months of gestation, the fetus enjoys relative freedom of movement, and the incidences of anterior and posterior presentations are approximately equal. Longitudinal rotation is limited by the length of the umbilical cord and, by 5 to 6 months of gestation, transverse rotation is also limited as the fetal crown-rump length at 35-40 cms exceeds the width of the amnion (Arthur *et al.*, 1982).

### **1.1.2.3 LATE pregnancy (>6 months):**

Between approximately 6.5 and 7.5 months of gestation, there is a dramatic increase in the volume of allantoic fluid and at term this volume has reached 20 litres (Arthur *et al.*, 1982). Throughout gestation the allantoic fluid is watery, but, in the final third of gestation, the amniotic fluid becomes mucoid in nature which gives it a lubricant quality at parturition. Rapid foetal growth in the last trimester of pregnancy causes the tissues of the dam's abdominal wall to become stretched and hypertrophied. The fetus

becomes aligned in parallel to the long axis of the dam with its limbs flexed against its trunk (Roberts, 1986). As the hindquarters are of relatively higher density in comparison to the head, in over 95 percent of pregnancies the fetus adopts an anterior presentation at parturition with the head raised and presented towards the pelvis (Roberts, 1986; Dyce *et al.*, 1996). At birth, Holstein fetuses weigh 35 percent more than Jersey calves and 15% more than the average dairy calf (Holmes *et al.*, 2003). Although environmental factors such as parity and nutrition of the dam, litter size and climatic stress all play a role in fetal size at birth, maternal size is the most significant factor.

## **1.2 CURRENTLY AVAILABLE MID-GESTATION PREGNANCY TESTING TECHNIQUES:**

The first record of man's awareness of conception and pregnancy can be traced back over 35,000 years, to the art of Cro-Magnon man (Dunlop and Williams, 1996). The surprisingly complex artworks contain numerous images of phallic symbols and pregnant animals, suggesting the artist had some sense of both fertilization and its consequences. In 1993, Veena and Narendranath investigated the first written example of a test for pregnancy in cattle from a Kahun papyrus of ancient Egypt, dated 2100-2200 BC. They found the germination of barley seeds was inhibited due to the presence of plant growth regulators in the urine of pregnant cows. Visual examination of cow's urine was also undertaken through the 15<sup>th</sup> century in order to diagnose pregnancy (Keil, 1988). In 1607, England's Gervase Markham promoted one of the more barbaric attempts at pregnancy diagnosis in the cow by pouring water into the animal's ear (Fleming, 1896; Dunlop and Williams, 1996). The diagnosis was based on whether the animal shook her entire body (non-pregnant) or just her head (pregnant) to rid herself of the water.



Since that time, countless tests have been designed, developed and/or discarded in order to diagnose pregnancy in cattle more accurately, more easily and at an earlier gestational age. They include:

1. Manual palpation *per rectum*
2. Transrectal ultrasonography
3. Plasma and milk oestrone sulphate
4. Plasma and milk progesterone
5. Oestrus detection
6. Abdominal enlargement and right abdominal wall ballottement
7. Post-oestrus bleeding
8. Changes in udder size
9. Doppler/ fetal echocardiography
10. Electrocardiography
11. Early pregnancy factor (EPF)
12. Bovine pregnancy specific protein B (bPSP-B) and bovine pregnancy associated glycoprotein (bPAG)
13. Transcutaneous flank ultrasonography

### **1.2.1 MANUAL PALPATION PER RECTUM:**

Manual palpation of the uterus involves the insertion of a gloved, lubricated hand into the cow's rectum and downwards palpation through the ventral rectal wall (Zemjanis, 1970). The first known record of rectal examination in cattle was described in the Kahun papyrus, where a bull with severe necrotic gastroenteritis was treated by manual evacuation of infected tissue via the rectum (Schwabe, 1978; Dunlop and Williams, 1996). Columella and Vegetius of Rome, in the first and fourth centuries AD respectively, described rectal palpation of abdominal organs for the diagnosis of digestive disorders (Smithcors, 1957). Manual palpation of the uterus to diagnose pregnancy has been mentioned in various references from the early 1800s and was described in detail by Fleming in 1896. Burgess was responsible

for the introduction of manual palpation into the curriculum of Edinburgh's Royal Veterinary College in 1942 and the technique is now a fundamental part of veterinary practice throughout the world (Momont, 1990).

#### **1.2.1.1 Early (<3 months): manual palpation *per rectum*:**

Although manual palpation of bovine pregnancy can be successfully completed from 27 days post-conception, the earliest recommended stage is 36-42 days in heifers and 42-49 days in mature cows (Zemjanis, 1970; Roberts, 1986). The definitive diagnosis of pregnancy at this early stage is dependant on the detection of one or more of the four positive signs of pregnancy (Momont, 1990; Honey, 1998):

a. Fetal membrane slip: was first described by Abalein and involves slipping the chorioallantoic membrane, as a band over the greater curvature of the uterus, between the thumb and forefinger at 30 to 42 days of pregnancy (Zemjanis, 1970; Arthur *et al.*, 1982). Embryonic implantation and organogenesis also occur at this time and numerous investigations have been undertaken to ascertain whether fetal slip can cause iatrogenic, early embryonic death (Paisley *et al.*, 1978; Abbitt *et al.*, 1978; Vaillancourt *et al.*, 1979; Franco *et al.*, 1987; Thurmond and Picanso, 1993; Alexander *et al.*, 1995). Despite claims of up to 9 percent embryonic loss, research has proven difficult as, prior to the development of ultrasound and fetal heart visualization, it was impossible to unequivocally confirm the pregnancy status of the animal before and after manual palpation (Abbitt *et al.*, 1978; Thompson *et al.*, 1994). Confirmation was further complicated as fetal membranes can take up to three months to disperse after embryonic loss (Parmigiani *et al.*, 1978). Early studies also typically failed to take into account naturally occurring embryonic loss, which has been estimated to vary between 9-28 percent in cows with normal fertility and up to 60 percent in repeat breeder cows, from 31 to 55 days post-breeding (Forar *et al.*, 1995). Recent investigations have concluded the economic and

managerial risks of failing to pregnancy test makes any potential embryonic loss due to manual palpation relatively insignificant (Thompson *et al.*, 1994; Alexander *et al.*, 1995).

b. Palpation of the amniotic vesicle: was first described in 1923 by two German veterinarians, Pissl and Ruther, and involves placing gentle pressure over the chorioallantoic sac, from 30 days of gestation, to detect the round, turgid amniotic vesicle floating within the chorioallantoic fluid (Studer, 1969; Arthur *et al.*, 1982). Rowson *et al.* (1963) found amniotic vesicle palpation caused heart rupture in 2 out of 4 fetuses examined and Dawson (1974) reported intentional rupture of the amniotic vesicle *per rectum* resulted in abortion within 2-3 weeks. Development of the caudal intestine is completed between days 30-40 of gestation and Bellows *et al.* (1975) were the first to suggest amniotic vesicle palpation within this time period may result in rectal and/or colonic atresia, due to colonic vascular damage (Winters *et al.*, 1942; Von Schlegel *et al.*, 1986; Syed and Shanks, 1992a). It has been found, however, that there is a marked predisposition for atresia coli development in Holstein-Friesians, due to an autosomal recessive lethal factor, regardless of pregnancy examination technique (Constable *et al.*, 1997, Brenner and Orgad, 1999). Although vigorous palpation of the amniotic vesicle may increase the risk to the genetically predisposed fetus, some consider it a safer form of pregnancy diagnosis compared to the fetal slip technique (Abbitt *et al.*, 1978; Syed and Shanks, 1992b).

c. As the amnion becomes flaccid, the uterine wall thins and direct palpation of the fetus becomes possible at approximately 60 to 70 days of gestation (Benesch and Wright, 1950; Honey, 1998). From approximately 30 to 35 days of gestation, a pronounced asymmetric enlargement of the gravid horn, due to allantoic fluid accumulation within the chorioallantoic membrane, also gives strong evidence of the presence of pregnancy (Noakes, 1985; Sheldon and Noakes, 2002). The uterine wall is thinner relative to the non-

gravid horn, and feels fluctuant when palpated. The examiner should, however, be conscious of other possible causes of fluid accumulation within an empty uterus, particularly in older, multiparous cows, and the fact that bicornual twins will also create symmetrical fluid accumulation between the two uterine horns (Arthur *et al.*, 1982).

d. Placentomes, which consist of interdigitating tissue projections of the fetal cotyledon and maternal caruncle, are first detectable via manual palpation at 70 to 80 days of pregnancy as circumscribed, ovoid, thickened areas (Roberts, 1986; Schlafer *et al.*, 2000). During the last two trimesters of the gestation period, as the fetus “falls” to the abdominal floor, the placentomes are typically the most accessible, positive characteristic of pregnancy (Zemjanis, 1970).

The palpation of a mature corpus luteum, middle uterine artery hypertrophy and fremitus and/or a “heavy” cervix are considered signs suggestive of pregnancy (Honey, 1998). Repeated palpation of a mature corpus luteum, typically on the ovary ipsilateral to the pregnancy, has been shown to be 85-90 percent accurate as a pregnancy testing technique (Zemjanis, 1970; Sheldon and Noakes, 2002). From 3-4 months of gestation, the uterine arteries undergo hypertrophy and a characteristic change in their pulse wave (Arthur *et al.*, 1982). The tremor-like pulse (ie: fremitus) can be distinctly felt approximately 2 cms lateral to the anterior border of the iliac shaft. The artery supplying the pregnant horn becomes noticeably larger in diameter relative to the other uterine artery from approximately 100 days of gestation (Ginther and del Campo, 1974). Fremitus can also be felt, however, in cases of fetal maceration or mummification, and should not be used as the sole indicator of pregnancy.

The reported sensitivity, specificity and positive and negative predictive values for pregnancy diagnosis by manual palpation *per rectum* at less than 90 days of gestation are well summarized by Mueller (2001). Sensitivity,



positive and negative predictive values were consistently over 90 percent. Specificity values, however, were highly variable ranging from 49.2 percent in the study of White *et al* (1989) to 100 percent in a study of manual palpation *per rectum* in beef cows by Tierney (1983). This indicates that there is a wide variability in the ability of the operator to correctly diagnose a non- pregnant cow as such by manual palpation *per rectum*.

The ease of rectal palpation *per rectum* is highly dependant on the age, size, breed and condition score of the cow and the relative experience and strength of the palpator (Burgess, 1942; Honey, 1998). In the last 50 years, the average liveweight of the New Zealand dairy cow has increased from an estimated 375 to 440 kgs (Holmes *et al.*, 2002). Holstein-Friesians have also surpassed Jerseys as the dominant dairy breed in New Zealand and pregnant uteri within the relatively deep abdomen of this larger framed dairy breed can be extremely difficult to palpate, particularly in mid to late gestation (Roberts, 1986; Dairy Statistics, 2003). In pluriparous, older cows, where multiple pregnancies have caused the cervix and mesometrium to become stretched, the pregnant uterus can also commonly be found in the abdominal cavity from a relatively early stage of gestation (Roberts, 1986).

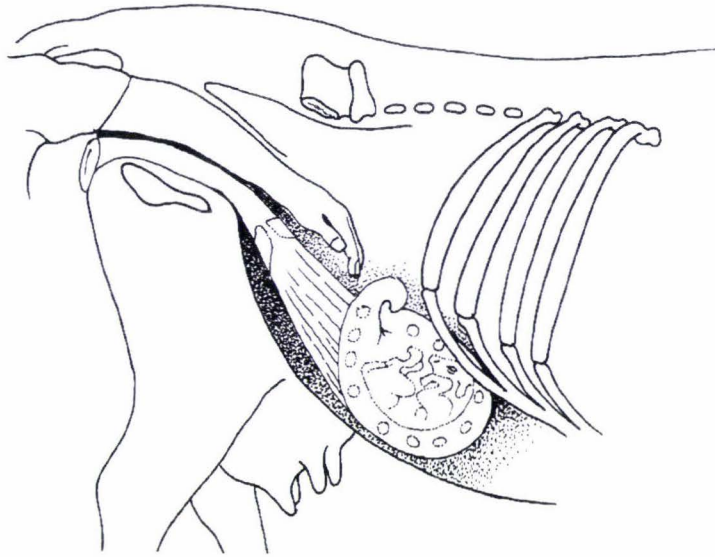
It is difficult to distinguish the landmarks of pregnancy via palpation *per rectum* in high condition score cows grazed for a season without lactating (ie: carry-overs), due to non-pregnancy in the previous year (Honey, 1998). The uterus of a non-pregnant, obese cow, pulled ventrally by increased mesometrial fat, can be easily misdiagnosed as pregnant as the only detectable characteristic of pregnancy may be fremitus. Autumn calvers also tend to be in relatively high body condition score (ie: 5+) at pregnancy testing in December/January as they undergo mid and late lactation during the spring and early summer pasture flush (Holmes *et al.*, 2002).

Although pregnancy diagnosis requires a thorough knowledge of bovine reproductive anatomy, embryology and physiology, only those experienced

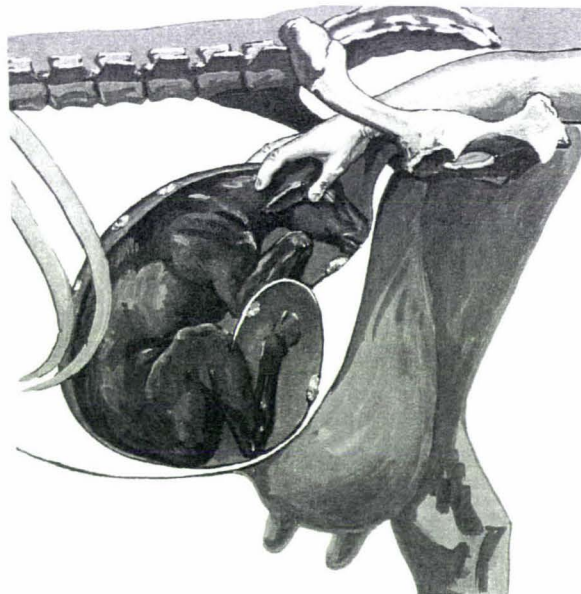
in palpating large numbers of cattle can claim to have mastered this particular skill. Inexperienced palpators and/or palpators with thick forearms, who are unaccustomed to palpating large numbers of cattle, fatigue easily and mistakes can occur, particularly in beef cows and heifers (Honey, 1998).

Enzootic Bovine Leucosis (EBL), a malignant, systemic neoplasia of the bovine reticuloendothelial system, is present in approximately 5 percent of cattle infected with bovine leukemia virus (BLV) (Hopkins *et al.*, 1991). BLV is spread via the horizontal transmission of contaminated biological materials and proven routes of inoculation include oral, intradermal, subcutaneous, intramuscular, intravenous, vaginal and intrauterine (Radostits, 1994). The transmission of EBL via the rectal mucosa, however, has remained somewhat contentious (Henry, 1987). Vigorous rectal palpation can result in superficial rectal mucosal hemorrhage which is visible as blood on the rectal glove. Despite contrary results in a previous study (Lassauzet *et al.*, 1989), Wentink *et al.* (1993) found BLV was transmitted after manual palpation *per rectum* using a glove covered in blood contaminated mucus. Hopkins *et al.* (1991) found BLV transmission via palpation *per rectum* was dependant on the degree of trauma induced by the palpator and generally this routine procedure does not play a major role in most commercial dairies.

Lang-Rec *et al.* (1994) found Bovine Viral Diarrhoea Virus (BVDV) from a persistently infected (PI) animal could be transmitted via a shared rectal glove. At less than four months of gestation, when manual palpation for pregnancy is typically completed, the calf is not immunologically competent to recognize the BVD virus and either foetal death or deformities may result (Radostits, 1994). Programs to control the potential spread of BLV and BVDV, therefore, currently include the use of a new glove for each rectal examination (Honey, 1998).



**Figure 1.7:** Right lateral view demonstrating the position of the gravid uterus: at 5 months the uterus is out of reach via manual palpation *per rectum* (From Dyce *et al.*, 2002)



**Figure 1.8:** Left lateral view demonstrating the position of the gravid uterus: Manual palpation *per rectum* of a late pregnancy (From Arthur *et al.*, 1982)

### **1.2.1.2 Mid (3-6 months) and Late (>6 months): manual palpation *per rectum*:**

From approximately 90 to 120 days of pregnancy, the uterus passes over the pelvic brim as a result of increasing fetal and fetal fluid weight. Direct palpation of either fetal membrane slip or amniotic vesicle palpation is not possible after this time period. Between 120 and 160 days of pregnancy, the fetus and/or placentomes can be palpated in only 50 percent of pregnancies and pregnancy diagnosis *per rectum* becomes progressively more difficult as the uterus slips further cranially within the abdomen (Arthur *et al.*, 1982). From 160 to 220 days of pregnancy, frequently the only palpable signs suggestive of pregnancy are a heavy cervix, which a palpating hand finds difficult to lift, and detectable fremitus of the uterine arteries (see Figure 1.7). From 220 days of pregnancy onwards the fetal head and/or legs may become detectable as the fetus ascends towards the pelvic cavity in preparation for parturition (see Figure 1.8). In deep-bellied, multiparous cows, however, the fetus and placentomes can be undetectable throughout pregnancy, even to term.

There is little information available on the average sensitivity, specificity, positive and negative predictive values for the diagnosis of pregnancy over 90 days of gestation through manual palpation *per rectum*. Meacham *et al.* (1976), in a study of over 1,800 beef cattle in 4 years, found pregnancy testing at an average of 127 days of gestation resulted in a sensitivity, specificity, positive and negative predictive value of 99.0 percent, 69.6 percent, 94.9 percent and 92.8 percent respectively. The effect of increasing gestational age on each of these values was not discussed, however.

### **1.2.1.3 Fetal ageing using manual palpation *per rectum*:**

Prior to the development of manual palpation *per rectum*, fetal age was primarily determined via measurement of crown-rump length and fetal fluid



volumes collected from aborted and postmortem fetuses (Winters, 1942; Maneely, 1952; Lyne, 1960; Gjesdal, 1969; Richardson, 1990). The accuracy of fetal ageing using manual palpation *per rectum* is greatest between 35 and 65 days of gestation and tends to decrease with increasing gestational age as the fetus passes out of reach (Honey, 1998). There is a general tendency to underestimate the age of the fetus in early gestation and overestimate fetal age within and after mid gestation. Up to a 7 week error in fetal age estimation can be expected as the calf nears parturition, a large part of which is due to the variation in normal gestation length between 272 and 293 days (MacMillan and Curnow, 1976).

Between 30 to 70 days of gestation, the size of the amniotic vesicle (see Table 1.1) and a volumetric measurement of the gravid uterine horn in relation to the non-gravid horn can be used to determine fetal age using manual palpation *per rectum* (Honey, 1998). The relative accuracy of uterine fluid volume is less versus amniotic vesicle size as fluid amounts vary between individual animals and from heifers to cows.

<b>Gestation age (days):</b>	<b>Amniotic vesicle length (cms):</b>	<b>Rule of thumb measurement:</b>
38 days	0.7 cms	½ finger
42 days	1.5 cms	1 finger
49 days	3.5 cms	2 fingers
58 days	7.5 cms	4 fingers
63 days	9.0 cms	hand less thumb
70 days	10.5 cms	hand plus thumb

**Table 1.1:** Approximate size and rule of thumb measurement using the average hand for amniotic size according to gestational age (From Honey, 1998)

By 70 days of gestation, the amniotic fluid volume decreases and the amnion becomes flaccid to the point where the fetus may be palpated. There is a linear relationship between fetal age and crown-rump length and a general equation of:

$$A = 65 + (2.3 \times CR)$$

where A is the foetal age in months and CR is the crown-rump length, allows the operator to age the pregnancy between 60 and 210 days of gestation (Richardson, 1990). The presence and strength of fremitus in one or both of the middle uterine arteries and their relative size also gives a good approximation of pregnancy duration after 5 months. Fetal hoof and head size are currently the only measurements available to estimate fetal age after 7 months of gestation using manual palpation *per rectum*.

Although detection of placentomes is a cardinal sign of pregnancy, the measurement of placentome size is one of the least accurate methods of determining fetal age (Honey, 1998). Placentomes can be palpated as circumscribed, firm nodules over the uterine surface at approximately 75 to 80 days of gestation (Roberts, 1986; Ferrell, 1991). There is great variation in placentome size within the gravid horn at all stages of gestation. Placentomes are larger, heavier and more numerous within the gravid horn relative to the non-gravid horn, particularly near the fetus and the attachment of the middle uterine artery which, after approximately 90 days of gestation, are out of reach of manual palpation (Echternkamp, 1992; Leiser *et al.*, 1997). Hypertrophy of placentomes within the gravid horn occurs in 10-20 percent of cattle in response to a failure in development of placentomes in the non-gravid horn (Roberts, 1986).

### **1.2.2 TRANSRECTAL ULTRASONOGRAPHY:**

Transrectal ultrasonography involves insertion of an ultrasound probe, either cupped in the operator's hand or taped to a rigid "extender", into the cow's rectum. The probe's scanning surface is positioned in direct contact with the ventral rectal wall to allow visualization of structures within, or cranial to, the pelvic cavity (Mueller, 2001).

Ultrasound imaging is based on the pulse-echo principle (Herring and

Bjornton, 1985). Piezoelectric crystals within the ultrasound probe emit low-intensity, high-frequency sound pulses into the patient (Peter *et al.*, 1992). When these ultrasound waves strike an interface between two tissues of different density or acoustic impedance (eg: soft tissue vs bone), a characteristic portion of the ultrasound beam is reflected back to the probe (Reeves *et al.*, 1984). The manner in which the echo's amplitude is displayed is subject to the mode chosen. A-mode indicates tissue interfaces via a series of vertical peaks on a horizontal axis (Haibel, 1990). In B-mode the relative brightness of dots on a screen represent the amplitude of the echo. The vertical position of the pixel on the monitor is dictated by the time it takes the echo to return to the transducer face, which in turn directly correlates to the reflector's depth in the tissue. Real-time B-mode involves a constantly updated image of tissues scanned and allows for observation of motion in addition to anatomy (Siems, 2000). White, hyperechoic images are created by tissues (eg: gas and bone) which cause the bulk of the ultrasound beam to be reflected, while black, anechoic images are created by tissues (eg: fluid) which allow the bulk of the beam to pass without attenuation (Herring and Bjornton, 1985; Siems, 2000).

In the first recorded use of ultrasound to diagnose pregnancy in a domestic animal, Lindahl (1966), using A-mode ultrasound in sheep, described an accuracy of approximately 95 percent. A-mode was rapidly replaced, however, with real-time B-mode ultrasound and when Chauffaux *et al.* (1982) described several anechoic structures within a cow's uterine lumen, it represented the first use of transrectal ultrasound to diagnose pregnancy in this species. Today, a 3.5 or 5.0 MHz, linear transducer is the most commonly used probe for transrectal ultrasound pregnancy diagnosis in cattle and ultrasound now rivals manual palpation *per rectum* as the primary pregnancy testing technique of cattle in many veterinary practices worldwide (Cranefield, 2004).

### **1.2.2.1 EARLY (<3 months): transrectal ultrasonography**

Although the spherical equine amniotic vesicle is relatively easy to detect via transrectal ultrasound as early as 8 to 9 days of gestation, the bovine vesicle is more difficult to visualize at this early stage due to its unusual anatomical shape in utero (Ginther, 1984; Hickey, 1990). The length of the bovine blastocyst increases dramatically from a sphere at 8 days of gestation to a filamentous structure at 14 days of gestation (Winters *et al.*, 1942).

The age at which the bovine amniotic vesicle can be first visualized by transrectal ultrasound is dependant on the frequency of transducer used. High frequency transducers, with relatively high resolution, allow visualization of structures with a diameter of only 2 mm. Boyd *et al.* (1988), using a high frequency 7.5 MHz transducer, reported the earliest identification of the bovine amniotic vesicle at 9 days of gestation. Curran *et al.* (1986a) reported 88 percent of amniotic vesicles could be visualized by 12 days of pregnancy using a 5 MHz linear transducer in the horn ipsilateral to the corpus luteum. The vesicle was typically located in the first major curve of the gravid horn proximal to the remaining, highly convoluted horn (Pierson and Ginther, 1984). The vesicle occupied the entirety of the gravid horn by 17 days and all of the contralateral horn by 19 days of gestation (Curran *et al.*, 1986a).

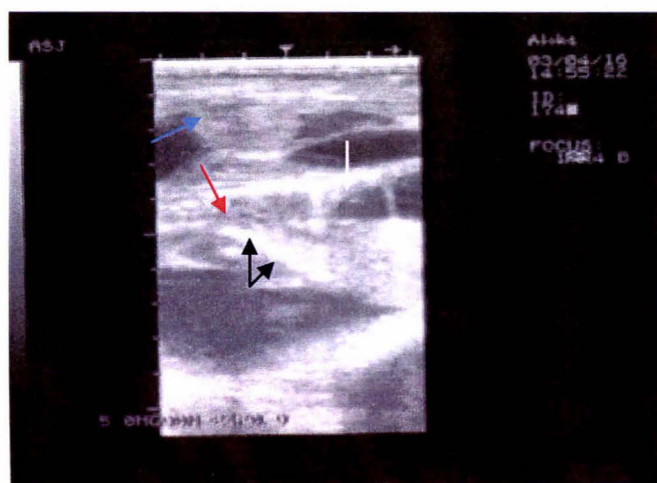
Despite this early success, it is generally accepted that 20 days of gestation is the resolution limit of most modern transrectal transducers for the detection of pregnancy and the majority of operators cannot regularly diagnose a pregnancy at less than 30 to 35 days of gestation in the mature cow (Curran *et al.*, 1986b, Rajamahendran *et al.*, 1994). The highly convoluted bovine uterine horn creates difficulties in obtaining a clear cross-sectional view of the small amount of fluid present at this early stage of pregnancy. The uterus can also contain similar amounts of fluid up to 3 to 4 days after the end of the oestrus cycle and with mucometras and early pyometras (Badtram *et al.*, 1991).



The numerous reported sensitivity, specificity, positive and negative predictive values for pregnancy diagnosis by transrectal ultrasound at less than 90 days of gestation are well summarized by Mueller (2001). With few exceptions, these values range above 90 percent if pregnancy is diagnosed from 30 days of gestation onwards, with increasing gestational age and transducer frequency resulting in improved accuracy (White *et al.*, 1985; Hanzen and Delsaux, 1987; Badtram *et al.*, 1991; Hanzen and Laurent, 1991; Szenci *et al.*, 1995; Chauffaux *et al.*, 1998; Pieterse *et al.*, 1990). Hughes and Davies (1989) found the accuracy of detection of pregnancy was also inversely proportional to the age of the cow with heifers able to be diagnosed earlier (ie: 22-28 days) and with higher accuracy than mature cows (ie: 30-35 days). Nation *et al.* (2003), using a 7.5 MHz transducer, found a sensitivity and specificity of 96 percent and 97 percent respectively between 28-35 days of gestation when using the simplified method of visualizing uterine fluid accumulation and embryonic membranes only as opposed to observation of the fetus. The authors concluded, however, that pregnancy diagnosis between 28-35 days of gestation was too early to reliably detect pregnancy due to the high degree of fetal loss (9%) found between the early test and a 13-week recheck (Nation *et al.*, 2003).

The most definite sign of a viable embryo using transrectal ultrasound is the observation of an echogenic area with rhythmic pulsations (ie: heartbeat) within the presumptive thorax at approximately 20 to 26 days of gestation (Pierson and Ginther, 1984) (see Figure 1.9). The embryo develops from a prominent C shape, due to the cephalic and caudal flexures and general curvature of the back, to an L-shape as a result of straightening of the neck and raising of the fetal head (Curran *et al.*, 1986b). The placentomes become visible at approximately 33 to 38 days of gestation as smooth, flattened, semicircular elevations on the surface of the uterine lumen. Movements of the fetal head and feet generally become detectable at 40 to 50 days of pregnancy and the bones of the braincase calcify into a distinctive, oval hyperechoic shape by 55 days of gestation.





**Figure 1.9:** A transrectal ultrasound image of a fetus at 65 days of gestation showing the heart (red arrow), rumen (white arrow), ribs (white arrows) and a placentome (blue arrow)

#### **1.2.2.2 MID (3-6 months) and LATE (>6 months): transrectal ultrasonography:**

At mid and late gestation, the fetus within the gravid horn generally passes over the pelvic brim and out of range of the ultrasound beam. Pregnancy at this age is typically visualized as uterine fluid cranial to the bladder and/or placentomes but commonly the gravid horn cannot be seen regardless of the transducer frequency used. Manual palpation *per rectum* must then be completed in an attempt to confirm pregnancy status. The vast majority of studies investigating the accuracy of pregnancy testing using transrectal ultrasound have focused on the time period of less than 90 days of gestation, endeavoring to develop a test which will diagnose pregnancy at the earliest date possible. Although White *et al.* (1985), using a 3.5 MHz transducer between 92 and 202 days after last service, found an overall accuracy of pregnancy diagnosis of 98.3 percent, it was not described whether this accuracy changed with increasing gestation length.

#### **1.2.2.3 Fetal ageing using transrectal ultrasonography:**

The efficiency and accuracy of fetal age determination by transrectal ultrasound depends on the length of gestation, transducer frequency and the

position and orientation of the fetus (Kahn, 1989). The most accurate assessment of fetal age is between 40 and 120 days of gestation (Wright *et al.*, 1988). White *et al.* (1985), in their definitive study of bovine fetal ageing, found the regression and correlation coefficients of fetal crown-rump length, trunk diameter, head diameter, head length and nose diameter to gestational age were all highly significant. Trunk diameter was most frequently and crown-rump length least frequently measured (White *et al.*, 1985). In a similar study, Wright *et al.* (1988) found the overall difference between actual and predicted calving dates was 0.9 days (standard deviation = 9.0 days), with 80.5 percent of cows calving within 10 days of the predicted date.

White *et al.* (1985) did find, however, that the fetus could not be regularly scanned, and therefore aged, beyond approximately 140 days of gestation. Kahn (1989) found fetal heads could be visualized in approximately 80 percent of pregnancies up to 10 months of gestation, but as only heifers were examined, it could be expected that this percentage would be lower in older, multiparous animals, where the fetus is located deeper in the abdomen at an early gestational age.

### **1.2.3 The potential consequences of pregnancy diagnosis *per rectum*:**

It is conceivable that insertion of an ultrasound probe through the anus of a cow and the application of pressure to the ventral rectum could result in stress, pain and/or injury to that animal.

#### **1.2.3.1 STRESS AND PAIN:**

The question of whether a dairy cow feels pain during pregnancy testing *per rectum* via ultrasound or manual palpation does not have a simple answer. Despite our natural tendency to interpret animal behaviour in terms of our own emotions (ie: anthropomorphism), from a strictly scientific point of view, it is not possible to objectively prove what another being is

subjectively experiencing (Martin and Bateson, 1993).

Blood and Studdert (1994) defined pain as "a feeling of distress, suffering or agony, caused by the stimulation of specialized nerve endings (nociceptors)". Although it cannot be proven, it is a common assumption that animals, such as cattle, which have a central nervous system containing analogous nociceptive systems to those of humans, could suffer pain in a similar manner (Zayan, 1986). Unlike other receptors, nociceptors do not show "fatigue" and continued stimulation can actually result in increased receptor sensitivity. In particular, it has been found the greater the stimulation and area involved, the greater the intensity of visceral pain (eg: due to intestinal distension) (Ettinger and Feldman, 2000). Although measurement of nociception is currently not possible, it is conceivable that the increased pressure applied to the ventral rectal wall, particular in ultrasonography, to diagnose the "deep" pregnancies of mid and late gestation could create increased nociceptor stimulation and therefore increased "pain" for the animal. There is a widespread belief that cattle are relatively insensitive to pain, due to their inherently stoical nature (O'Callaghan, 2002). This is likely, however, to be a survival strategy developed by prey species in the wild to divert attention away from a sick or injured animal, rather than a lack of pain sensitivity (Zimmerman, 1986).

The quantification of pain is acknowledged as a perilous undertaking in humans due to confounding psychological factors (Morton and Griffiths, 1985). Although it cannot be proven, from a strict animal welfare perspective, it must be assumed that conscious animals are capable of experiencing a potentially damaging sensory event and that that animal will subsequently modify its biochemistry, physiology and behavior to allow active avoidance of that event. An animal's acute response to a noxious experience involves a rapid-onset, but short-lived adrenaline response mediated by the sympathetic nervous system and a slow-onset, but relatively longer lasting, cortisol response mediated by the hypothalamic-pituitary-

adrenocortical system (Mellor *et al.*, 2002). These and other biochemical and physiological responses, plus any behavioural changes, have all been utilized to assess the pain status of domestic animals in order to produce adequate guidelines on animal welfare (O'Callaghan, 2002).

#### Behaviour:

Behavioural changes are possibly the most commonly used indicator of pain both in research and in routine animal husbandry procedures (O'Callaghan, 2002). How an animal alters its behaviour when experiencing pain, or presumed pain, is dependant on both the evolution of that species and the individualistic nature of the animal (Zimmerman, 1986). It could be assumed that those best suited to assess any behavioural responses to acute pain, including protective motor reflexes (eg: kicking), vocalization and defense reactions (eg: freezing), would be a stockmen or veterinarian accustomed to both the species and the animal (Molony and Kent, 1997). Although an observer's qualitative assessment of an animal's behaviour could be affected by their own individual bias, Wemelsfelder *et al.* (2000) found there was significant agreement between 18 naïve observers of spontaneous behaviour of 20 piglets.

Numerous studies have utilized both acute and long-term changes in behaviour as an indicator of pain in response to castration and mulesing in lambs and dehorning and castration in calves (Faulkner and Weary, 2000; Fisher *et al.*, 2001; Thornton and Waterman-Pearson, 2002). A 2000 study found calves administered a subcutaneous injection of an anti-inflammatory or local anaesthetic prior to dehorning exhibited significantly less head shaking and/or ear flicking (Faulkner and Weary, 2000). Fell *et al.* (1989) found that although lambs resumed normal behaviour in the paddock within 72 hours of undergoing a modified mulesing operation, they showed pronounced aversion to their human handler for up to 37 days post-surgery. The reliability of methods used for behavioural assessment of pain has



remained controversial, however, as there exists substantial individual animal, daily and seasonal variation in behaviours shown (Thornton and Waterman-Pearson, 2002).

#### Physiological:

Physiological signs of acute pain and stress, such as changes in blood pressure, an increased heart and breathing rate, changes in plasma noradrenaline and adrenaline and increased body temperature, are aspects of the sympathetic (flight or fight) nervous system (Sanford *et al.*, 1986). A 1998 study found the increase in heart rate seen in bulls subjected to transrectal palpation was lower in comparison to electroejaculation, but higher than if a lidocaine epidural or xylazine sedation was administered (Mosure *et al.*, 1998).

#### Biochemical:

Numerous studies have used the increased cortisol levels present in sheep and calves as an indicator of acute pain and stress in response to venipuncture, restraint, shearing, mulesing, tail amputation and/or dehorning (Bassett and Hinks, 1969; Fulkerson and Jamieson, 1982; Johnston and Buckland, 1986; Jephcott *et al.*, 1988; Lester *et al.*, 1991; Niezgodá *et al.*, 1993; Graf and Senn, 1999). Changes in expected liveweight gain has also been used as a potential physical measurement of chronic pain (Cohen *et al.*, 1985).

In 1986, Alam and Dobson found plasma cortisol concentrations remained elevated 1-1.5 hours after reproductive tract palpation *per rectum*, with more experienced animals showing a lower response in comparison to naïve animals. Interfering variables, such as individual variation, diurnal changes and a variety of alternate environmental stressors, however, can limit the use of cortisol as the sole indicator of pain. It is generally acknowledged, therefore, that a wide range of physiological, biochemical and behavioral variables should be used in an integrated approach to pain assessment in



domestic animals.

### **1.2.3.2 INJURY:**

Insertion of a gloved hand or ultrasound probe through the anus and into the rectum during pregnancy testing stimulates the defaecation reflex. This results in contractions of the colonic and intestinal musculature and voluntary contraction of the external anal sphincter (Dyce *et al.*, 1996; Ettinger and Feldman, 2000). If too much force is applied during the straining commonly encountered during transrectal palpation or scanning, the palpating hand or ultrasound probe can perforate the rectal or intestinal wall (Burgess, 1942; Boyd and Omran, 1991). If faeces are manually evacuated before palpation, negative pressure within the abdomen can cause aspiration of air into the rectum, resulting in an atonic and stretched rectal wall (Zemjanis, 1970; Roberts, 1986). This causes palpation to become extremely difficult and can also lead to trauma to the rectum and intestine. Rectal tissue, oedematous as a result of long-standing enteritis or diarrhea, can also be inadvertently traumatized by the action of rectal palpation (Zemjanis, 1970).

Even though superficial hemorrhage of the rectal mucosa is a relatively common and accepted occurrence during manual palpation, rectal perforation is generally considered to be a rare event (Burgess, 1942). An experienced palpator can detect the waves of peristaltic contractions and alter manual pressure accordingly (Momont, 1990). Rectal insertion of an ultrasound probe, attached to a long, rigid rod, however, does not have the dexterity of manual palpation and the possibility of rectal damage or perforation is increased (NZVA, 2002). This is particularly the case in pregnancies of 4-7 months where the fetus is positioned on the ventral abdominal wall and the “rod” must be inserted to its full length and pushed downwards to allow imaging of these “deeper” pregnancies.

In 1972, Hulet described a “rectal-abdominal” technique for the diagnosis of

pregnancy in sheep. A plastic rod, inserted approximately 30-35 centimetres into the rectum, was moved horizontally across the ventral abdominal wall until the pregnant uterus was located and elevated to within reach of the non-palpating hand. Although Hulet claimed 100 percent accuracy with this technique, blood was reported to be "frequently" present on removal of the rod and, in numerous studies completed between 1973 and 1979, up to 20 percent of ewes aborted and 3 percent died from intestinal perforation and/or peritonitis (Morcan, 1973; Plant, 1974; Turner and Hindson, 1975; Tyrell and Plant, 1979). Tyrell and Plant (1979) found almost half of all ewes pregnancy tested demonstrated bruising or abrasions of the rectal tissue, despite increasing operator experience. Similar abortion and death rates of 16 percent and 5 percent respectively, were also proven after use of the rectal-abdominal technique in does (Ott *et al.*, 1981). Although, this technique is consequently not recommended for pregnancy diagnosis in small ruminants, rectal ultrasonography with a fixed rod, which sometimes requires similar deep, forceful manipulation, particularly in advanced pregnancies, is a common form of pregnancy diagnosis in cattle.

Currently, there is no standard ultrasound fixed probe handle or rod manufactured for use by New Zealand veterinarians (Cranefield, 2004). As a result, veterinarians are forced to test and modify rods of their own design over a number of seasons, despite an obvious lack of experienced engineers in this profession. Despite some ingenious designs, it is not surprising, therefore, that in March 2004, Murray Gibb, as chairman of the Veterinary Veterinary Protection Insurance Society (VPIS) of New Zealand, stated "the increased use of ultrasound machines with fixed probes for *per rectal* pregnancy diagnosis has seen a significant increase in rectal perforations." Ultrasound examinations *per rectum*, by both claim number and dollar value, have become the most "risky" activity insured by the VPIS since 2002 (Gibb, 2004). If the incidence of rectal perforations does not decrease ultrasound examination *per rectum* may not be insurable in the future. Contributing factors include the time constraints placed on veterinarians

working in rotary sheds during milking and the VPIS encourages active communication with farmers on the inherent risks of this now popular method of pregnancy diagnosis.

The New Zealand Veterinary Association's (NZVA) policy on ultrasound transrectal pregnancy examination states rigid rectal probes should only be used by veterinary surgeons and in unskilled hands "there is a significant threat to the animal's welfare due to the potential for damage to vital structures" (NVZA, 2002). As the percentage of veterinarians and herdowners utilizing rectal ultrasonography increases, the number of "layscanners", who have little to no formal training in the anatomy and potential dangers of a rigid rectal probe, has also increased (Hollands, 1994). Although Yaniz *et al* (2002) found any peritoneal surface alterations present after manual palpation were insignificant, there have been no controlled studies completed on the potential incidence and severity of rectal and intestinal injury after routine manual palpation *per rectum* and transrectal ultrasonography. One study of 1115 cows, however, noted the death of one animal as a result of peritonitis caused by rectal perforation by a Doppler probe head during routine pregnancy examination (Cameron and Malmo, 1993).

Until such controlled studies are completed alternative techniques for the diagnosis of pregnancy in cattle 4-7 months in calf should be considered.

#### **1.2.4 OESTRONE SULPHATE:**

Oestrone sulphate is the primary oestrogen synthesized via sulpho-conjugation in placentomes and has been used in the assessment of fetal viability (Mueller, 2001). Although the concentration of oestrone sulphate increases gradually during gestation, it is virtually undetectable in the milk of non-pregnant animals (Noakes, 1995). Oestrone sulphate can be analysed from the plasma, serum, faeces and milk of pregnant cows and during the first half of gestation, there is a relatively close correlation between plasma

and milk levels (Heap and Hamon, 1979).

The development of oestrone sulphate as a potential pregnancy diagnosis technique began in the 1970s and a recently developed enzyme-immunoassay, based on oestrone sulphate competing with an added oestrone sulphate enzyme conjugate for antibody binding sites, uses a relatively minor colour change as the diagnostic indicator (Mueller, 2001). Henderson *et al.* (1994a) found milk oestrone sulphate concentrations of 0 to 1.3 nmol/l in non-pregnant cows and 1.1 nmol/l at 70 to 90 days of gestation and 3.2 nmol/l at 140 to 160 days of gestation in pregnant cows. The peak in median milk oestrone sulphate concentration occurs at 160-180 days of gestation at a level of 1 ng/ml (Henderson *et al.*, 1993). There is considerable individual variation, however, in oestrone sulphate concentrations between cows. Power *et al.* (1985) found the highest milk concentration in non-pregnant cows was 622 pg/ml and the lowest concentration in pregnant cows at 121 days of gestation was 127 pg/ml. Currently, a recommended cut-off level between pregnant and non-pregnant cows of 120 pg/ml is used in cows more than 100 to 120 days in calf.

The sensitivity, specificity, positive and negative predictive values for pregnancy diagnosis by oestrone sulphate are well summarized by Mueller (2001). Sensitivity values of less than 60 percent were seen in studies completed at less than 120 days of gestation and Mueller (2001) found that a milk oestrone sulphate enzyme-immunoassay only reached a sensitivity level comparable to transrectal ultrasound and manual palpation *per rectum* after 140 days of gestation (Hamon *et al.*, 1981; Henderson *et al.*, 1992; Henderson *et al.*, 1993; Henderson *et al.*, 1995). Although the specificity of oestrone sulphate appeared unaffected by the gestational age range, values of 98-100 percent found in previous studies could not be replicated in Mueller's study, resulting in non-pregnant cows incorrectly diagnosed as pregnant (Heap and Hamon, 1979; Henderson *et al.*, 1994a; Henderson *et al.*, 1994b).



Oestrone sulphate levels are unaffected by either calf sex, calf birthweight, cow condition score during gestation or any of the dairy management systems prevalent in New Zealand (Bloomfield *et al.*, 1982; Henderson *et al.*, 1994b). Echternkamp (1992) found higher oestrone sulphate levels in cows carrying twins, presumably as more placental tissue is present in these pregnancies, but this level was not significant and could not be used to predict twin pregnancies.

Although over 90 percent of the oestrone sulphate content in milk is confined to the whey portion due to its aqueous solubility, milk yield or composition does not influence the concentration (Heap and Hamon, 1979). Mastitis and/or oestrus can lead to a misdiagnosis of pregnancy using oestrone sulphate, however, and concentrations can also be slightly increased by freezing (McCaughey *et al.*, 1982).

#### **1.2.5 PROGESTERONE:**

The corpus luteum produces progesterone which remains elevated in the peripheral circulation of the cyclical, non-pregnant cow throughout the oestrus cycle (Noakes, 1985). Just prior to ovulation, however, the concentration of progesterone decreases and, with a simultaneous decrease in the concentration of oestrogen, causes the animal to show behavioral signs of oestrus. The concentration of progesterone in the first 14 days of gestation are similar to those of the dioestrus period, but by Day 18-21 in the pregnant cow, due to persistence of the corpus luteum, progesterone concentrations remain elevated, while in the non-pregnant cow concentrations decrease. The main purpose of measuring progesterone as a form of pregnancy diagnosis, therefore, is to identify cows that have either failed to conceive or have undergone early embryonic death before maternal recognition of pregnancy (Carriere *et al.*, 2000).

The diagnosis of pregnancy via measurement of plasma progesterone was first studied by Robertson and Sarda (1971) and found to be over 87 percent



accurate in dairy cattle. Although the concentration of milk progesterone remains relatively constant until just prior to calving, it does not generally exceed the levels found during the normal luteal phase of the oestrus cycle (McCaughey, 1981). Therefore, accurate knowledge of mating dates and correct sampling during the follicular phase of the next cycle post-mating, when progesterone levels are low in the non-pregnant cow, are essential. The normal bovine interoestrus interval is, on average, 18-24 days in length and, as Pennington *et al.* (1985) found no statistically significant difference in accuracy between the two dates, sampling is recommended between 21 to 24 days post-mating (Sheldon and Noakes, 2002).

Milk progesterone sampling 21-24 days post-mating has proven 65-85 percent and 94-100 percent accurate for pregnancy and non-pregnancy detection respectively (McCaughey, 1981; Roberts, 1986; Humblot *et al.*, 1988). An embryonic loss rate of up to 40 percent within 42 days of mating, which results in a return to cycling after 24 days post-mating, is a major reason for the relatively high incidence of false positives (Peters, 1996). A persistent corpus luteum (eg: due to chronic pyometra), luteal cysts, fetal mummification and unusually short or prolonged luteal function can also result in a false positive result (Paisley *et al.*, 1978; Sheldon and Noakes, 2002). Kourletaki-Belibasaki *et al.* (1995) estimated approximately 8 percent of cows presented with high serum progesterone at mating and so were inappropriately inseminated during dioestrus. This is a prominent cause of non-pregnancy and false positive diagnosis when measuring serum progesterone at 21-24 days post-mating. The high false positive results of milk progesterone therefore limits its value as a diagnostic test for pregnancy and confirmation at a later date via manual palpation *per rectum* or transrectal ultrasound is recommended. Accuracies of 95.2 percent and 94.7 percent, however, for positive and negative pregnancy diagnosis respectively have been demonstrated if milk is sampled on 38 and 46 days post-mating (ie: double sampling technique) (McCaughey, 1981).

Progesterone concentrations vary with the fat content of the milk and, as this changes with evening versus morning milking and bulk versus hand-drawn foremilk samples, the type of milk sample analyzed as well as the assay method used are important in determining the actual pregnancy status of the animal via the milk progesterone method (Carriere *et al.*, 2000). The choice of an appropriate cutoff level has also proved contentious.

Since 1975, the milk progesterone assay has been routinely available to dairy farmers and, despite the widespread availability of the rapid milk progesterone test (RPMA), which has allowed cow-side detection of progesterone levels, there has been minimal acceptance of this method of pregnancy diagnosis in the UK, with poor accuracy and cost cited as the main deterrents (Newton *et al.*, 1982; Hickey, 1990; Pitcher and Galligan, 1990; Kourletaki-Belibasaki *et al.*, 1995). By 1981, only 2 percent of herds with 100 or more cows in Northern Ireland and approximately 5 percent of cattle in the United Kingdom were undergoing pregnancy diagnosis via milk progesterone (Booth, 1979; Newton, 1982).

#### **1.2.6 OESTRUS DETECTION:**

The decreased progesterone level and simultaneous increased oestrogen level of the bovine pro-oestrus period results in the manifestation of intense and characteristic oestrus behaviour which lasts, on average, 9.5 to 14 hours (Nebel *et al.*, 1992). The cow will stand to be mounted, commonly by a herdmate, vocalize, become agitated and temporarily stand separate from the herd (Foote, 1974). Based on normal bovine reproductive physiology, the failure of a cow to return to oestrus and demonstrate oestrus behaviour 18-24 days after insemination may indicate pregnancy has been established (Sheldon and Noakes, 2002). Oestrus detection, therefore, appears to represent a relatively simple and inexpensive method of pregnancy detection, particularly in small, owner-run herds.

Accurate oestrus detection requires a thorough knowledge of the normal

signs of bovine oestrus, a conscientious, patient and experienced approach to animal husbandry and good record keeping. Although many cows will show a “silent heat” during their first ovulation at approximately 39 days post-calving, by 90 days postpartum up to 93 percent of cows should be demonstrating a standing heat (Foote, 1974). Donaldson (1968) found both morning and afternoon oestrus checks were essential as of the 67 percent of dairy cows showing signs of oestrus in the morning, up to 45 percent did not show behavioural oestrus in the afternoon (Appleyard and Cook, 1976).

The efficiency of oestrus detection by the average herdsmen, measured via serum progesterone or continuous observation, ranges from 51 to 77 percent (Williamson *et al.*, 1972; Esslemont, 1973; Senger, 1994). Up to 90 percent of cows submitted as anoestrus are due to a failure to observe oestrus correctly rather than a lack of normal cycling and between 5 and 30 percent of all inseminations occur in cows that are not in oestrus (Bozworth, 1972; Appleyard and Cook, 1976). The use of oestrus detection aids such as mounted heat-detectors and tail paint, however, have increased the accuracy and efficiency of heat detection (Senger, 1994). Despite an approximate 5-fold increase in the number of cows per farm in New Zealand since the 1930s, the number of workers on each farm has remained relatively constant and, unless actively encouraged, oestrus detection remains a low priority on many modern, busy New Zealand dairy farms (Holmes *et al.*, 2002).

Approximately 15-30 percent of inseminated cows which do not return to oestrus and are, therefore, assumed to be pregnant, are actually non-pregnant (Zemjanis, 1970). Uterine and/or ovarian pathology (eg: pyometra, ovarian cysts) can prevent luteolysis and the resumption of normal oestrus cycling and a certain percentage will undergo early embryonic death (Roberts, 1986). A 2001 study also found up to 18 percent are phantom cows which did not conceive at insemination, did not suffer any pathological reproductive conditions, but still failed to cycle for reasons unknown (Nation *et al.*, 2001).

Approximately 6-10 percent of pregnant cattle will exhibit behavioural signs of oestrus particularly between 4 and 8 months of gestation (Thomas and Dobson, 1989; Sheldon and Noakes, 2002). Oestrus behaviour is seen most commonly in pregnant cows in high condition score and those in their 4<sup>th</sup> or 5<sup>th</sup> lactation (Thomas and Dobson, 1989). Plasma progesterone and oestrogen levels do not change significantly in pregnant cows and the mechanism responsible for the oestrus behaviour in these animals is currently unknown. Artificial insemination of a pregnant cow based on the signs of oestrus, can result in abortion due to a breakdown of the integrity of the cervical seal and the introduction of infection.

Although highly variable, the accuracy of oestrus detection has been estimated at approximately 70 percent and a recent New Zealand-based abattoir study found an average 7 percent difference in the perceived and actual pregnancy status of cull cattle at slaughter (Esselmont, 1973; Lawton *et al.*, 2000). Of the cattle culled on the basis of oestrus detection, 10.3 percent recorded as pregnant were non-pregnant at slaughter and pregnancy was commonly more advanced in those cattle diagnosed via oestrus detection in comparison to those diagnosed by manual or ultrasound examination. Farmer observation of oestrus, therefore, commonly results in an overestimation of pregnancy rates.

### **1.2.7 ABDOMINAL ENLARGEMENT AND RIGHT ABDOMINAL WALL BALLOTTEMENT:**

From approximately 6 months of gestation, the right abdomen of the pregnant cow noticeably swells. This is not, however, a constant nor absolute sign of pregnancy (McCaughey, 1981). Some herdowners believe twin-bearing cattle are easily identified by their relatively bell-shaped right abdomen when viewed from behind (Lambert *et al.*, 1998). Direct ballottement of the fetus, by firmly pushing a closed fist into the right flank and feeling the rebound of the solid fetus, is easier in older dairy cows at this stage due to their relatively relaxed and flaccid abdominal walls

(Roberts, 1986; Honey, 1998). Sporadic, rapid foetal movement, which differentiates it from intestinal peristalsis, may also become visible at the right abdominal wall from approximately 7 months of gestation onwards (McCaughey, 1981).

#### **1.2.8 POST-OESTRUS BLEEDING:**

Although the presence of bleeding or “menstruation” from the cow’s vulva 24-48 hours post-insemination is taken by some to indicate a successful conception, studies have shown 50-60 percent of cows and 75-85 percent of heifers exhibit bleeding after oestrus regardless of pregnancy status (Roberts, 1986). Approximately one-third of heifers discharge blood-tinged mucus post-ovulation and it has now been proven that there is no relationship between vulval bleeding and pregnancy (Pierson and Ginther, 1984).

#### **1.2.9 CHANGES IN UDDER SIZE:**

At approximately 4 months of gestation, maiden pregnant heifers show noticeable udder development and teat enlargement (Arthur *et al.*, 1982; Roberts, 1986). Although the udder is initially primarily fat, mammary parenchyma gradually becomes the dominant tissue and herdowners will commonly consider uddering up in heifers as confirmation of pregnancy and impending parturition (Dyce *et al.*, 1996). Heifers which abort after 3 to 4 months of gestation, however, will still demonstrate udder enlargement and so can be falsely diagnosed as pregnant. In pluriparous cows, enlargement and oedema of the udder occurs only in the last month of gestation and so is not useful as confirmation of pregnancy.

#### **1.2.10 DOPPLER/ FETAL ECHOCARDIOGRAPHY:**

When ultrasound waves strike a moving object (eg: beating fetal heart or fetal blood vessel) they are reflected back to the source at a slightly altered frequency which can be amplified as an audible blowing or swishing sound (ie: fetal echocardiography or Doppler) (Mitchell, 1973; McDougall, 2003).



Mitchell (1973), in the first study of Doppler as a potential pregnancy testing technique in cattle, found “it was not possible to detect the fetus consistently at any stage of pregnancy”. The passage of the fetus over the pelvic brim during mid gestation and out of Doppler range was cited as the principle reason for this inconsistency. A 1985 study found the Doppler agreed with calving results on only 46 percent of occasions, disagreed on 31% and gave no clear indication on 23 percent of occasions (Ducker, 1985). Despite these results, a number of simplified ultrasonic Doppler rectal probes have been marketed to herdowners to allow on-farm pregnancy diagnosis without additional veterinary assistance. A comprehensive Australian study (Cameron and Malmo, 1995) of one such machine yielded a sensitivity of 92.8 percent and specificity of 75.8 percent which was found to be “insufficient to recommend the probe to be used by farmers for the diagnosis of pregnancy.”

#### **1.2.11 ELECTROCARDIOGRAPHY:**

Despite numerous studies dating back to the 1940s, the measurement of foetal heart rate through the use of an electrocardiograph to diagnose and age either bovine or equine pregnancy has proven highly inaccurate and is currently not recommended (Maneely, 1952; Too *et al.*, 1965; Pipers and Adams-Brendemuehl, 1984).

#### **1.2.12 EARLY PREGNANCY FACTOR (EPF):**

Early pregnancy factor (EPF), a pregnancy-associated glycoprotein with growth regulatory and immunomodulatory properties, is detectable in the serum and milk of pregnant cattle as early as 3 days post-conception (Cordoba *et al.*, 2001; Sheldon and Noakes, 2002). An ECF dipstick test, performed 11-15 days post-insemination, was found to have a sensitivity, specificity, PPV and NPV of 81 percent, 26 percent, 40 percent and 69 percent respectively, indicating there was no significant agreement between the test result and the actual pregnancy status of the cow (DesCouteaux *et al.*, 2000). Varying incubation times, individual variation in visual

assessment of the test strip and the source of light available for this assessment were possible factors responsible for the inaccuracy of the test (Hafez and Hafez, 2000). Investigations of a qualitative serum ECF assay, undertaken 1-3 and 7-9 days post-insemination, yielded similar results with the authors concluding "the current ECF test cannot accurately identify the non-pregnant cow with the precision needed by the dairy producer" (Cordoba *et al.*, 2001; Gandy *et al.*, 2001).

#### **1.2.13 BOVINE PREGNANCY SPECIFIC PROTEIN B (bPSP-B) and BOVINE PREGNANCY ASSOCIATED GLYCOPROTEIN (bPAG):**

Placental proteins, such as equine chorionic gonadotrophin (ECG), have been used to detect pregnancy in mares for many years (Cole and Hart, 1942; Sasser *et al.*, 1986). The pregnancy specific proteins bPSP-B and bPAG are produced by the trophoblastic ectoderm of the developing embryo (Hickey, 1990; Zoli *et al.*, 1992). As these proteins indicate the presence of a live embryo they have proven to be accurate indicators of pregnancy and, as the concentration of bPAG is raised with increasing gestational age, it can also be used to estimate the age of gestation (Zoli *et al.*, 1992; Sheldon and Noakes, 2000). Patel *et al.* (1997) also found bPAG can offer accurate prediction of fetal number in the bovine pregnancy. Breed of dam, fetal sex and twins, however, can affect the concentration of bPAG (Zoli *et al.*, 1992; Ectors *et al.*, 1996).

Although bPAG and bPSP-B are detectable in the serum of pregnant cows from 24 days post-conception, Humblot *et al.* (1988) found that the measurement of serum bPSP-B was only an efficient test from 30 days of gestation, due to early embryonic mortality (Szenci *et al.*, 1996). Szenci *et al.* (1996) found pregnant animals were diagnosed with a greater than 95 percent accuracy from Day 29-30 of gestation. The use of bPSP-B and bPAG can result in false positive pregnancy diagnosis, however, as each have long half-lives and are readily detectable up to 100 days after embryonic or fetal death and parturition (Ruder and Sasser, 1996; Sheldon

and Noakes, 2000). Although a serum bPSP-B assay is currently available for pregnancy detection at less than 33 days post-conception and at least 100 days post-partum, cost and convenience currently limit its use (Sheldon and Noakes, 2000).

#### **1.2.14 TRANSCUTANEOUS FLANK ULTRASOUND:**

In 1966, Lindahl, through A-mode ultrasonography, was the first to diagnose pregnancy in a domestic animal (sheep) through the use of ultrasound across the abdominal skin. While rapid advances were being made in rectal-based pregnancy diagnosis via ultrasound in the early 1980s, transcutaneous, flank, real-time B-mode ultrasonography was also actively developed in a number of domestic species including sheep, goats, horses, pigs, deer and camelids, as well as a variety of exotic species.

Transcutaneous, flank ultrasonography is currently the most common technique used to diagnose ovine and caprine pregnancy in New Zealand and Australia. In early studies the ewe was placed in dorsal recumbency in a cradle with the flank area shorn, but sheep are now scanned in the right inguinal area while standing, with vegetable oil as a contact agent, without prior clipping or shearing (White *et al.*, 1984; Bretzlaff *et al.*, 1993). Fowler (1984) found an accuracy of 99.4 percent to 100 percent from 46 days of gestation onwards using this technique. Experienced operators with good facilities (eg: a chute) can pregnancy test over 300 ewes per hour (Bretzlaff *et al.*, 1993). Differentiation of single and twin pregnancies via transcutaneous scanning resulted in an accuracy of 97 percent and was found to be most accurate “a month either side of mid-pregnancy.” (Fowler and Wilkins, 1980; Fowler, 1984). Logue *et al* (1987) found similar accuracy levels (95%) were achieved by inexperienced operators scanning for multiple pregnancies after only two days of instruction. The most accurate interval for the prediction of ovine and caprine gestational age is 40 to 80 days, with occipito-snout diameter (head length) and/or biparietal diameter (head width) providing the most accurate predictors (Haibel and

Perkins, 1989; Kelly and Newnham, 1989; Aiumlamai *et al.*, 1992).

Despite a previous claim to the contrary (Palmer and Driancourt, 1980), ultrasound across the flank to diagnose equine pregnancy was successfully completed for the first time in 1981 by O'Grady *et al.* in two mares at 175 and 225 days of gestation. Transcutaneous ultrasonography has since been utilized in the development of an equine fetal biophysical profile for high-risk pregnancies via indicators such as fetal movement, heart contractions and aortic diameter (Pipers and Adams-Brendemuehl, 1984; Reef, 1995; McGladdery, 1999). Direct foetal cardiac puncture with KCl via a transcutaneous ultrasound-guided needle can result in successful twin reduction in mares over 40 days of gestation (Rantanen and Kincaid, 1988). Although blood PMSG (pregnant mare serum gonadotrophin) and oestrone sulphate are currently the most common mid-gestation pregnancy testing techniques used, transcutaneous ultrasound measurement of the orbit, aortic root and intercostal spaces have been used to estimate equine foetal age after 70-80 days of gestation (Reef, 1998).

A 3.5 MHz linear scanner placed against the right abdominal wall caudal to the umbilicus of the standing sow is 99 percent and 100 percent accurate in the diagnosis of pregnancy and non-pregnancy, respectively, from 24 days post-service (Jackson, 1986). Transcutaneous scanning for pregnancy has been described as "a highly accurate, rapid on-farm method of confirming pregnancy in sows" and is less invasive and traumatic relative to transrectal ultrasound scanning (Cartee *et al.*, 1985; Cohen *et al.*, 1999).

Fallow deer are generally considered too small for rectal examination and Mulley *et al.* (1987) found transcutaneous scanning 100 percent accurate for both pregnancy and non-pregnancy from 50 days of gestation. Although rectal examinations are readily completed in red deer, trunk and head diameter have been measured to age foeti via transcutaneous scanning across the right flank from 50 to 170 days (White *et al.*, 1989). In camels,



new world camelids and llamas a 5 MHz linear probe against the right flank is used to determine fetal biparietal diameter in order to age pregnancy from 66 days of gestation (Haibel and Fung, 1991; Kahn, 1992). Successful transcutaneous scanning for pregnancy has also been reported in dolphins from 78 days to the end of gestation (Kahn, 1992).

Despite numerous studies in almost all other domestic species, there is a noticeable lack of detailed research into the possible use of transcutaneous flank ultrasound to diagnose pregnancy in either the dairy or beef cow. Yamaga *et al.* (1984), as part of a general ultrasonographic study of bovine abdominal structures across the lower right abdomen and flank, reported the visualization of fetal organs, fetal fluid, the placenta and umbilical cord, in pregnancies of 4 to 7 months. Fetal movements and heart contractions were also visible. Although mentioned in several texts, the transcutaneous technique in cattle is universally criticized for various reasons including the perceived need for special skin preparation and apparatus, assuming the cow will kick in response to scanning over the right flank skin and that the bovine abdomen is too large to allow detailed examination (Chauffaux *et al.*, 1986; Boyd and Omran, 1991; Boyd, 1995).

Braun and associates have completed numerous studies of the ultrasonographic appearance of various abdominal organs of the cow via the transcutaneous approach. Once the hair over the area of interest was clipped and remaining hair removed via depilatory cream, the abomasum, caecum, sections of the colon, small intestine and liver were all clearly visible using a 3.5 MHz linear transducer (Braun, 1990; Braun and Marmier, 1995; Braun *et al.*, 1997a; Braun and Amrein 2001). Abdominal disease conditions such as peritonitis, left displaced abomasum and caecal dilatation and/or torsion can also be visualized via this approach (Braun *et al.*, 1997b; Braun *et al.*, 2001; Braun *et al.*, 2002). Transcutaneous ultrasonography has been described as the “diagnostic imaging modality of choice” for the bovine



mammary gland and detailed echocardiograms have also been successfully completed in mature dairy cows (Trostle and O'Brien, 1998; Braun *et al.*, 2001).

### **1.3 PREGNANCY TESTING AND THE HERDOWNER:**

#### **1.3.1 The Northland/New Zealand dairy farm:**

In both beef and dairy herds, efficient reproductive management is pivotal to the economic success of the both types of farming operation. Knowledge of the herd's pregnancy status is fundamental to gaining control over the calving pattern, pasture availability, culling rates, production of replacement cattle and age structure of the herd (Boneschancher *et al.*, 1982; Oltenacu *et al.*, 1990; Honey, 1998).

The current New Zealand dairy herd stands at 3.3 million in over 14,000 herds, incorporating 1 percent of the world's total population of 230 million cows (Holmes *et al.*, 2002). Over 76 percent of dairy herds are located in the North Island and approximately 10 percent are found in Northland, the region north of Auckland (Dairy Statistics, 2003). The overall average herd size is 271 cows, but South Island farms tend to carry a higher number of cows with an average herd size of 394 cows. Since the 1930s there has been a five-fold increase in the New Zealand cow population, and, in 2001/2002, there was record production nationwide with almost 13 billion litres of milk processed (Dairy Statistics, 2003).

Over 65 percent of New Zealand farms are operated by the owner, 25 percent are operated by a 50 percent sharemilker and the remaining are contract milkers (Holmes *et al.*, 2003). Although the Jersey breed dominated until the late 1960s, by 1970 Holstein-Friesians were and continue to be the foremost dairy breed in New Zealand. Friesian/Jersey cross-breds and Ayrshires have also recently increased in popularity. Beef breeds utilized on New Zealand dairy farms include polled Hereford, Angus,

Belgian Blue, Charolais and Simmental (Holmes *et al.*, 2003). In the last 50 years, the percentage of herringbone and rotary dairies has increased from 0 percent to 90 percent of sheds, with the herringbone continuing to be the most popular design.

### **1.3.2 Spring vs Autumn calving:**

The typical New Zealand dairy farm is at least partially pasture-based and herdowners are highly dependant on good weather to promote fast pasture growth and allow synchronization of the herd's feed requirements (MacMillan, 2002). The main factors limiting pasture growth include temperature in winter and moisture in summer. In most temperate regions of New Zealand, pasture growth is most rapid in spring and, therefore, on over 90% of New Zealand farms, all cows will ideally calve in a highly concentrated pattern between July to September (MacMillan and Moller, 1977; Garcia and Holmes, 1999; Holmes *et al.*, 2003).

In certain regions of New Zealand (eg: Northland), however, hot, dry summers are the period of slowest pasture growth. Approximately 120,000 cows (<10% New Zealand total) calve in Autumn (ie: February to April) to allow drying off in the dry summer and winter milk production for which the herdowner receives a premium (Holmes *et al.*, 2003). This gives the herdowner some flexibility as valuable cows which do not conceive in the Spring can be carried over to the Autumn.

On average, 80-85 percent of a herd will be submitted for artificial insemination (AI) in a 36 day AI period with an average of 1.34 inseminations per cow (MacMillan and Moller, 1977; Dairy Statistics, 2003). Approximately 55-65 percent of cows will conceive to each insemination, whether artificial or natural, with 1.5 inseminations required per pregnancy (Holmes *et al.*, 2003). By the end of the sixth week of mating, approximately 80 percent of cows should be pregnant and after a mean mating period length of 14-15 weeks, only 5-7 percent of the herd

should be empty (MacMillan and Moller, 1977; Lawton *et al.*, 2000). The majority of New Zealand herds will use a Jersey, Friesian or Hereford herd sire during the last 3-5 weeks of their mating period.

Pregnancy diagnosis is ideally carried out less than 21 days after the last service to allow a cow which has not conceived to be presented for insemination at her next cycle. A reliable, accurate and convenient test is currently not available for this stage of gestation and practitioners now recommend pregnancy testing 42 days after the end of the AI period and a second test 42 days after the end of natural mating by either manual palpation *per rectum* or transrectal ultrasound. There is a need, however, for accurate pregnancy diagnosis during mid to late gestation on both a herd and individual cow level.

New Zealand herdowners have an average mating start date (MSD) of October 10<sup>th</sup> and a mating end date of January 30<sup>th</sup> (Holmes *et al.*, 2003). Pregnancy diagnosis is commonly carried out at a minimum of 42 days after the last service. The most advanced gestation length at the date of pregnancy diagnosis, based on the "average" mating period would, therefore, be 4-4½ months. If a herdowner pregnancy tests their autumn calving cows with their spring herd or tests later due to drought or a low payout, the pregnancies become more advanced and, therefore, more difficult to correctly diagnose using manual palpation *per rectum* or transrectal ultrasound.

Pregnancy testing in beef herds is commonly completed at weaning, 8-10 weeks after the end of mating after a mating period of 2-4 months, primarily allowing identification of non-pregnant cattle (Honey, 1998). The gestation length of beef cattle at the date of pregnancy diagnosis can therefore range from 2 to 6 months.

Veterinarians are routinely asked to pregnancy test individual or groups of

dairy cattle while in mid to late gestation, including “carry-overs”, cull cows, suspected aborted cows and cows sold in May/June with a guarantee of pregnancy. An accurate mid to late pregnancy diagnosis technique would reduce the number of cows culled while pregnant, reduce the number of non-pregnant cows on-farm and allow accurate planning of the calving period throughout the year. Manual palpation *per rectum* and transrectal ultrasound are both difficult to apply at mid to late gestation due to movement of the fetus within the gravid horn over the pelvic brim and into the abdominal cavity.

### Culling:

Up to half of cows culled from New Zealand dairy herds in the 1998/99 season were due to suspected infertility (Holmes *et al.*, 2003). Abattoir surveys have revealed that a significant source of reproductive wastage is the slaughter of pregnant cows, although the percentage varies considerably (Ladds *et al.*, 1975; Al-dahash and David, 1977; Singleton and Dobson, 1995; Singleton and Dobson, 1996; Esslemont and Kossaibati, 1997; Lawton *et al.*, 2000). Singleton and Dobson (1995) found 23.5 percent of cows slaughtered at a UK abattoir were pregnant, 49.1 percent of which were in their second trimester and 26.9% in their third trimester. In 50.9 percent of cases the farmer believed a pregnant cow was non-pregnant pre-slaughter, resulting in an estimated annual loss of 30.78 million pounds to the UK cattle industry (Singleton and Dobson, 1995; Esslemont and Kossaibati, 1997). A recent New Zealand abattoir study found 39 percent of slaughtered cows were pregnant and the mean fetal size in cows that were pregnancy tested pre-slaughter was significantly smaller than those that had pregnancy status based on oestrus detection alone (Lawton *et al.*, 2000).

Ladds *et al.*(1975), in a northern Australian study of extensively farmed beef cattle, found 62.9 percent of cows examined were pregnant at slaughter. Pregnancy testing completed in herds prior to disposal of cull cows resulted in the slaughter of 34 percent fewer cows than in undiagnosed

herds and the majority of pregnant cows were in early pregnancy. In undiagnosed herds, 41.8 percent of pregnant cull cattle were 3-6 months in calf.

#### Non-pregnant cows on-farm:

Pregnancy testing allows identification of non-pregnant cows early in the season (Lawton *et al.*, 2000). The proportion of cows culled for low fertility in New Zealand is only 3.4 percent even though the average empty rate is 5.4 percent which results in the retention of non-pregnant cows on-farm for an unproductive season (MacMillan and Moller, 1977).

#### Planned calving pattern:

The distribution of calving dates within the herd has a major effect on the herd's pattern of feed demand and its supply of milk throughout the year (Garcia and Holmes, 1999). The majority of New Zealand dairy farms have a natural mating period of 4-5 weeks which results in unknown service dates and difficulty in the accurate prediction of calving dates (White *et al.*, 1985). A cow which calves late in the season has a postpartum period which extends into the mating period, resulting in a relatively short lactation and subsequent late mating (Holmes *et al.*, 2003). Accurate knowledge of which cows will be late calvers allows an informed choice of which cows need to be culled or induced to calve earlier, taking into account the condition score and age of the animal (Welch, 1971; Singleton, 1996). The careful management of late calving cows is becoming of increasingly important as calving induction, which is currently used in over 80 percent of New Zealand herds, is now actively discouraged on animal welfare grounds (Stevens *et al.*, 2000; MacMillan, 2002).

During the last month of gestation, a large amount of the cow's energy intake is channeled towards fetal and mammary gland development and a dry period of at least 6 weeks is essential for future udder health and milk productivity (Gill and Allaire, 1976; Honey, 1998). Accurate knowledge of



a cow's pregnancy status and gestation length allows management of adequate feed distribution, vaccination programs (eg: Rotavirus vaccine) and milk quota as well as an ample dry period (Garcia and Holmes, 1999).

#### **1.4 MID-GESTATION PREGNANCY TESTING AND THE VETERINARIAN:**

In the United States, a survey of nonfatal occupational injuries found dairy farmers and veterinary services amongst the highest risk industries with 12.9 and 8.1 cases per hundred workers, respectively (Cattell, 2000). The repetitive nature of rectal examination can cause a traction type injury to the roots of the spinal nerves 5 to 7 at the cervical foramina, which results in "repetitive motion or cumulative trauma disorder" (CTD) (Ailsby, 1996; Cattell, 2000). The clinical symptoms indicate a chronic "neurological deficit in the median, ulnar and radial nerves with slight wasting of the shoulder musculature in the deltoid and upper arm" which can remain after a three month rest period (Ailsby, 1996). Symptoms occurring in the side contralateral to the palpating arm are believed due to the neck being bent away from the arm in use (Cattell, 2000). The percentage of female veterinarians, relative to men, has been progressively increasing over the last 20 years and there was some evidence that shorter veterinarians are at higher risk of injury to the shoulder due to upwards extension of the arm.

Rectal examination can place the operator in danger, particularly if they are dealing with poorly handled and/or aggressive cattle. Sudden lateral or ventral movements of the cow during rectal examinations can also result in serious injury, particularly of the elbow, if posts, rails or partitions are nearby (Zemjanis, 1970; Honey, 1998). The bovine hindlimb also has a wide range of motion and the operator, when working from behind the animal, is in danger of a strike if a kick rail is not in place (Honey, 1998).

Examination of a herd with an average gestation length of over 3-4 months

can be frustrating, tiring and time-consuming, as a veterinarian attempting to pregnancy test using transrectal ultrasound will need to repeatedly stop to confirm pregnancy status via manual palpation *per rectum*. Pregnancy diagnosis in obese carry-overs, large, deep-bellied, multiparous animals and beef cattle at all stages of gestation via either manual palpation *per rectum* or transrectal ultrasound can also be extremely difficult with the operator commonly dependant on fremitus as the sole indicator of pregnancy. Fetal ageing in these cattle is also subsequently close to impossible. Veterinarians are facing increasing competition from lay scanners who are commonly used by herdowners due to their generally lower cost despite a lack of formal training. Veterinarians, therefore, require constant updating and refinement of their pregnancy testing knowledge and skills. An efficient and accurate technique which can accurately diagnose pregnancy status at mid and late gestation may allow veterinarians to supply a valuable service which is superior to that available from lay-scanners.

### **1.5 Conclusion:**

The development of novel techniques in order to determine the pregnancy status of cattle have focused on the accurate and early diagnosis of pregnancy. Accuracies of over 90% from 25-30 days post insemination through the use of manual palpation *per rectum* and/or transrectal ultrasonography allow relatively early intervention for non-pregnant cows (White *et al.*, 1985; Pieterse *et al.*, 1990; Nation *et al.*, 2003). Both techniques are highly invasive, however, involving insertion of either a palpating hand or ultrasound transducer into the rectum and application of pressure to the ventral rectal and intestinal wall. The increasing incidence of rectal bruising and perforations during routine transrectal ultrasound pregnancy testing are of immediate concern and potentially threaten the future use of this technique in the dairy and beef industries (Gibb, 2004). The transmission of the Bovine Viral Diarrhoea Virus (BVD) and Enzootic Bovine Leucosis (EBL) via manual palpation *per rectum* is also still contentious. Less commonly used tests such as serum/milk progesterone,

oestrone sulphate, early pregnancy factor and bovine pregnancy specific proteins are also currently limited by cost, availability, reliability and/or accuracy and oestrus detection by the herdowner tends to lead to overestimation of pregnancy rates.

It is difficult for the bovine pregnancy to be either palpated or visualized during mid to late gestation via manual palpation *per rectum* or transrectal ultrasound, due to movement of the fetus over the dam's cranial pelvic brim. There is a need, therefore, by both herdowners and veterinarians for the development of a rapid, accurate and safe technique for both the animal and the operator to diagnose pregnancy in mid to late gestation. There is currently no proven technique that is able to accurately and consistently diagnose bovine pregnancy after 120 days of gestation. Transcutaneous ultrasound across the flank to diagnose pregnancy has been successfully completed in a variety of other species, including sheep, goats, deer and horses. Despite detailed knowledge of the characteristic anatomy, physiology and movement of the bovine fetus in mid to late gestation this technique has not been comprehensively investigated, however, in either dairy or beef cattle. This literature review has stimulated a desire to investigate the potential use of transcutaneous ultrasound across the right flank in order to determine the pregnancy status of the dairy cow.



## **CHAPTER 2:** **DEVELOPMENT OF A TRANCUTANEOUS** **ULTRASOUND METHOD OVER THE RIGHT FLANK** **TO DIAGNOSE PREGNANCY IN THE DAIRY COW**

To the author's knowledge, a comprehensive, detailed study of transcutaneous ultrasound over the right flank to diagnose pregnancy in the dairy or beef cow has not been previously completed. This project, therefore, involved the development of the flank ultrasound method including choice of transducer frequency, type and placement based on the anatomy of the pregnant and non-pregnant dairy cow. The possible practical application of this method, utilizing the currently available holding facilities in New Zealand, was also investigated.

### **2.1 SCANNER PLACEMENT: the right flank**

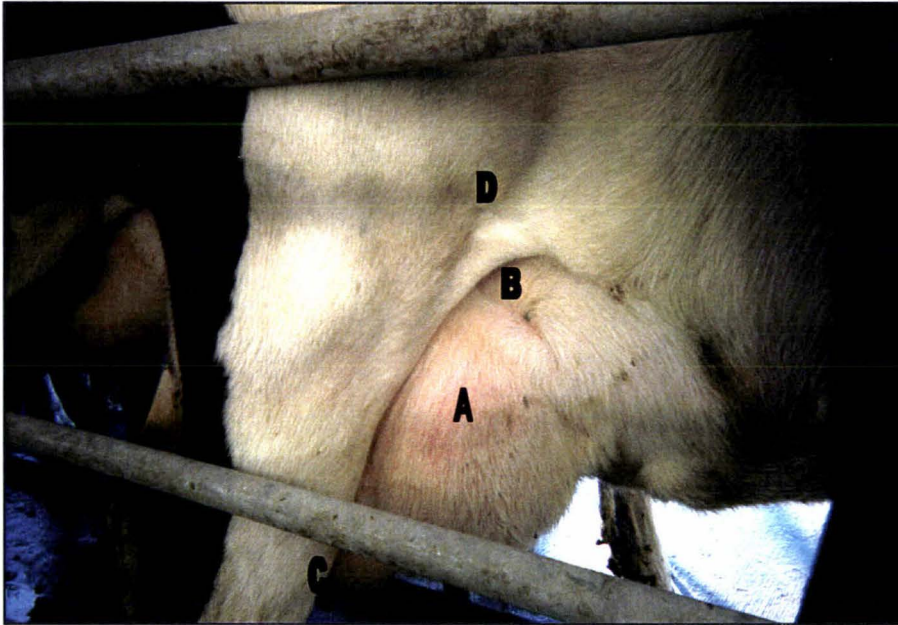In the non- and early pregnant dairy cow, the uterus and ovaries are typically held within the pelvic cavity. The uterus in some older, multiparous and/or obese animals may lie cranial to the pelvic brim and within the abdominal cavity in both the early pregnant and non-pregnant animal. Between 3 and 4 months of gestation there is a dramatic increase in the volume of amniotic fluid and, although broad ligament hypertrophy initially prevents it, by Day 120 of gestation the gravid horn has sunk below the cranial pelvic brim (Zemjanis, 1970). The uterus typically enters the supraomental recess, between the right face of the rumen and the greater omentum, before descending to the dam's abdominal floor by Day 150 of pregnancy (Dyce *et al.*, 1996). On occasion, the uterus may slip forward against the right or, less frequently, the left flank, displacing the intestines or rumen respectively from the abdominal wall (deLahunta and Haibel, 1986).

Although the caudoventral abdomen of the cow ascends steeply to the pubic brim, this is not immediately obvious as it is overlain ventrally by the udder and covered laterally by the flank fold, which passes between the flank and the stifle joint (Dyce *et al.*, 2002) (see Figure 2.1). The wall of the right



flank consists of a triple muscle layer covered externally by freely moveable skin with only a sparse cover of hair. The meeting of the udder skin with the caudal abdominal wall at the right flank is demarcated only by an indentation. In older, multiparous cows, the abdomen of the non-pregnant animal tends to be relatively deeper and wider with a consequent deepening of the flank fold. A thin layer of fascia covers the flank muscles within the abdominal cavity and supports the parietal peritoneum. The nervous supply to the right flank area consists of the last thoracic (T13) and 1<sup>st</sup> and 2<sup>nd</sup> lumbar nerves (See Figure 2.2).

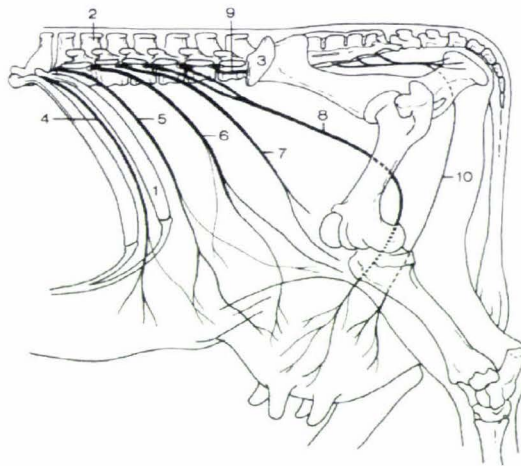
Direct ballottement of the fetus over the right flank, by firmly pushing a closed fist into the right caudoventral abdomen in order to feel the “rebound” of the solid fetus, is often used as a confirmatory form of pregnancy diagnosis. Yamaga and Too (1984), while completing a general transcutaneous, ultrasonographic study of the bovine abdomen, found the fetus, fetal organs, fetal fluid, placenta and umbilical cord could be visualized by scanning over the right flank. In a number of domestic species, including fallow deer, red deer and horses, the fetus can be visualized across the body surface over the right flank and ventral abdomen, in close proximity to the dorsal surface of the mammary gland (Mulley *et al.*, 1987; White *et al.*, 1989; Reef, 1998). Reef (1998) found that scanning the equine fetus in the sagittal plane initially was useful in determining fetal orientation, whilst multiple transverse and parasagittal scans across the ventral abdomen and right flank were used to determine fetal numbers. Pipers and Adams-Brendemuehl (1984) noted transcutaneous scanning of equine fetuses at 85-150 days of gestation was best accomplished with the probe positioned between the mammary and inguinal areas, while from Day 180 of gestation to term fetuses were typically found 20 cm cranial to the mammary gland on the right of the midline.



A: udder  
B: flank fold

C: hock joint  
D: stifle joint

**Figure 2.1:** The surface anatomy of the bovine right flank. The transducer is placed underneath the right flank fold (B).



4. 12<sup>th</sup> intercostals nerve (T12)  
5. costoabdominal nerve (T13)  
6. iliohypogastric nerve (L1)

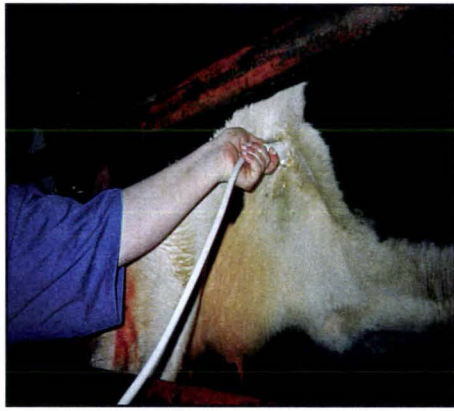7. ilioinguinal nerve (L2)  
8. genitofemoral nerve (L3, L4)  
10. ventral perineal nerve

**Figure 2.2:** Topography of the nerves to the flank (From Dyce *et al.*, 2002)

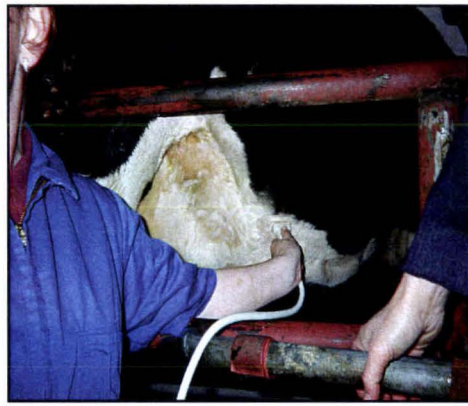Based upon previous transcutaneous studies in horse and deer, ultrasound visualization of early pregnancy in cattle could be best accomplished by positioning the probe in the most caudodorsal section of the flank fold, while later pregnancies could be visualized by scanning further cranially (see Figure 2.3).

In the non-pregnant cow, the right caudoventral abdomen may be filled by either the ileum, jejunum and/or rumen, while the ventral boundary of the abdomen is marked by the udder (deLahunta and Haibel, 1986) (see Figure 2.4). The small intestine and ascending colon lie almost entirely to the right of the midline and a common mesenteric support holds them in a complex coiled arrangement with all but the ascending duodenum separated from the abdominal wall by the greater omentum (deLahunta and Haibel, 1986; Dyce *et al.*, 2002).

The rumen is a large, muscular sac with a capacity measuring over 60 litres. It extends from the cardia to the pelvic inlet and almost entirely fills the left side of the abdominal cavity, but can pass caudally and ventrally to enter the lower right flank (Dyce *et al.*, 2002). The rumen is subdivided into sacs by muscular pillars which appear as grooves on its external surface with the dorsal sac comprising the largest compartment (Frandsen and Spurgeon, 1992). With increasing gestational age, the uterus begins to fill the right side of the abdomen, displacing the intestines and rumen cranially and to the left (see Figure 2.5). In late gestation, the cranial border of the uterus is located well within the right costal arch, placing pressure on the diaphragm and the great vessels (see Figure 2.6).

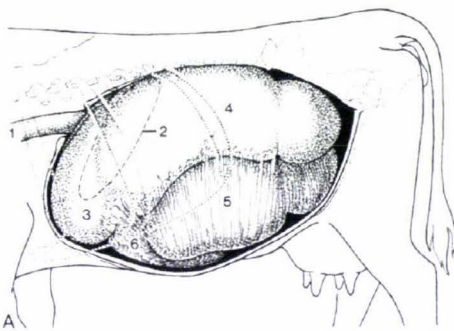


A

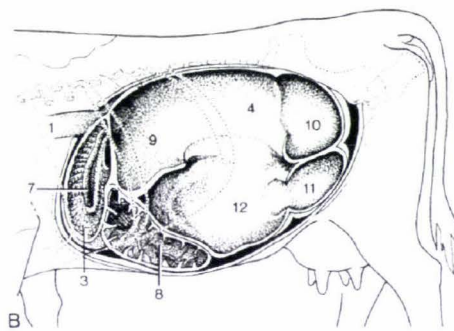


B

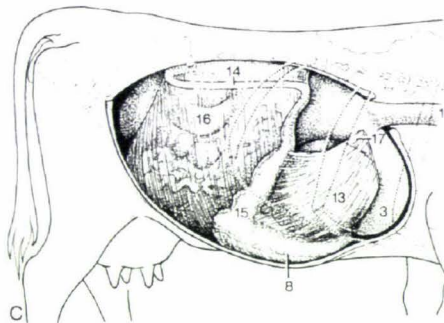
**Figure 2.3:** Scanner placement for the visualization of early (A) and late (B) pregnancies



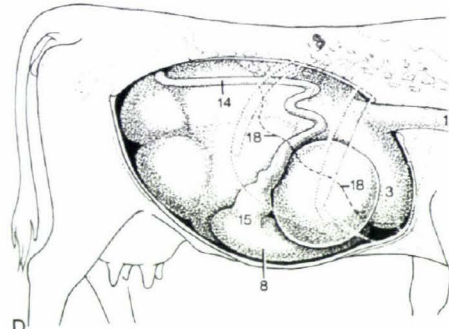
A



B



C

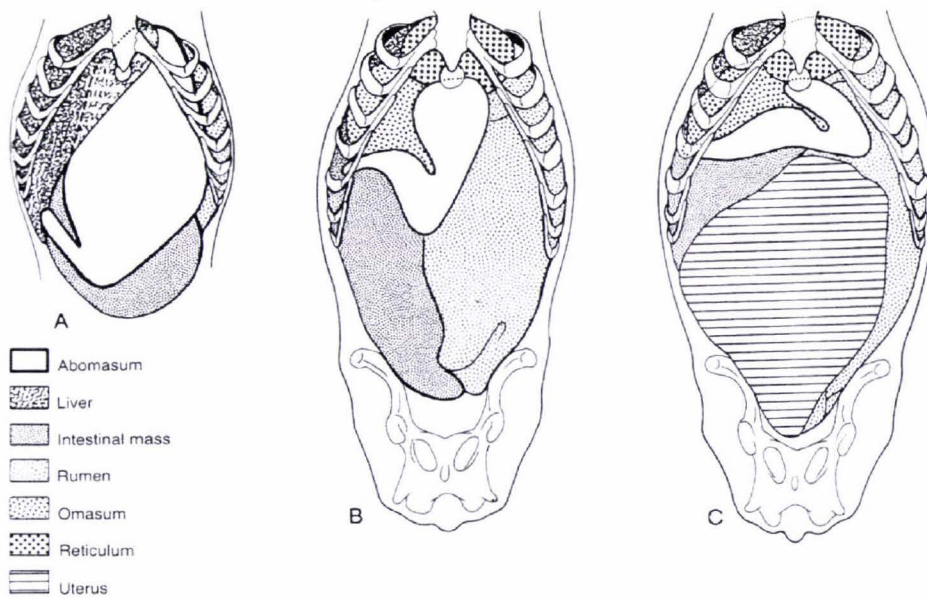


D

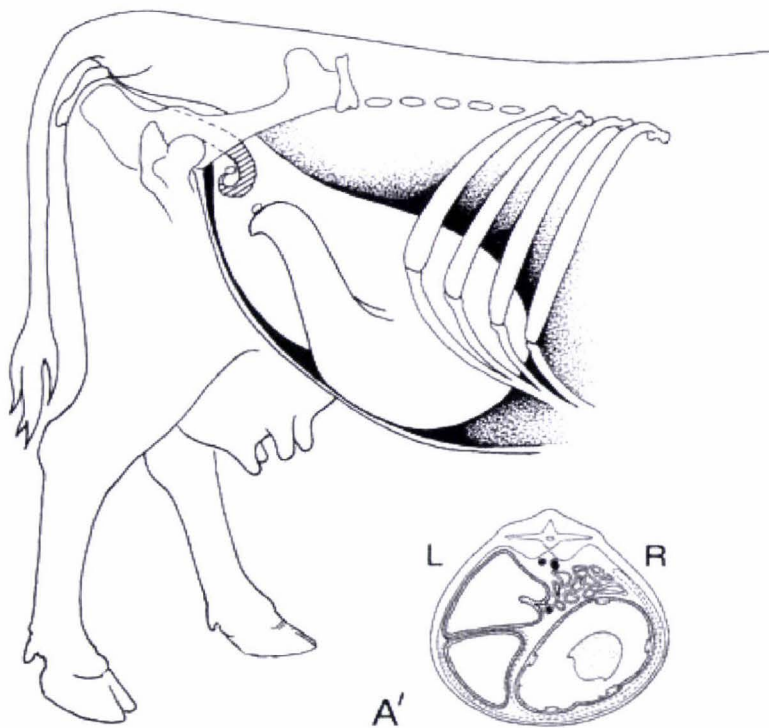
- 4. Dorsal sac of the rumen
- 5. Ventral sac of the rumen
- 12. Ventral sac of the rumen (opened)

- 11. Caudoventral blind sac of the rumen
- 16. Greater omentum covering the intestinal mass

**Figure 2.4:** Topography of the abdominal viscera in the non-pregnant cow. A: Relationship of abdominal viscera to the left abdominal wall; B: The interior of the rumen seen from the left; C: Relationship of the abdominal viscera to the right abdominal wall; D: position of the rumen when seen from the right (From Dyce *et al.*, 2002)



**Figure 2.5:** Ventral views of the abdominal viscera of a newborn calf (A), a non-pregnant cow (B) and a heavily pregnant cow (C). Note the uterus fills the right flank area, displacing the rumen and intestinal mass (From Dyce *et al.*, 2002)



**Figure 2.6:** Right lateral and transverse view of the gravid and non-gravid horn in mid to late pregnancy (From Dyce *et al.*, 2002).



The external appearance of the mammary gland varies greatly depending on the cow's maturity and stage of lactation as well as individual and breed characteristics (Dyce *et al.*, 2002). The fluid (milk/colostrum)-filled lactiferous ducts are easily identified via transcutaneous ultrasonography within the udder as anechoic, tubular areas contiguous with the gland sinus (Takeda, 1988). Blood vessels can be easily differentiated from the ducts as they have thin inner walls and a characteristically turbulent blood flow (Waldridge and Ward, 1999). The glandular parenchyma of the udder has a homogeneous, hyperechoic appearance on ultrasound (Cartee *et al.*, 1986).

During the early months of gestation, the bovine fetus enjoys relative freedom of movement, and the incidence of anterior and posterior presentations are approximately equal. In late gestation, the fetal hindquarters are of relatively higher density in comparison to the head and, in over 95% of pregnancies, the fetus adopts an anterior presentation with the head raised and presented towards the pelvis (Roberts, 1986; Dyce *et al.*, 1996).

## **2.2 TRANSDUCER TYPE: sector scanner**

Real-time ultrasound enables the operator to visualize a moving gray-scale image of cross-sectional anatomy. Two basic types of real-time B-mode transducer types are available: sector and linear-array (see Figure 2.7).

A linear-array transducer has a long series of piezo-electric crystals arranged in a row which are fired in a predetermined sequence and create a rectangular image on the screen (Rajamahendran *et al.*, 1994). Although linear scanners are commonly used for transrectal ultrasound pregnancy diagnosis, their main disadvantage for transcutaneous studies is their relatively large surface area which makes positioning across the skin difficult. A sector transducer has a few piezoelectric crystals which rotate around an axis to produce an arc-shaped segmental image with a typical sector angle of 90 degrees (Herring and Bjornton, 1985; Nyland and

Mattoon, 1985). A smaller surface area allows easier positioning against the skin but a disadvantage of this transducer type can be a lack of definition at both the edges and in the near field of the image (Goddard, 1995). Kahn (1990) found a sector transducer “more suitable for the study of the fetus than linear array scanners” and numerous studies of the pregnant mare over the right flank and ventral abdomen also promote the use of a sector scanner as the relatively smaller surface area allows a wider, more complete view of the fetus (Pipers and Adams-Brendemuehl, 1984; Rantanen and Kincaid, 1988; Reef *et al.*, 1995). Sector scanners are also used for transcutaneous pregnancy diagnosis in red deer, fallow deer and sheep (Mulley *et al.*, 1987; White *et al.*, 1989; Bretzlaff *et al.*, 1993).

### **2.3 TRANSDUCER FREQUENCY: 3.5 MHz**

The depth to which the ultrasound beam will penetrate into a soft tissue structure is directly related to the frequency of transducer used (Nyland and Mattoon, 1995). The frequency emitted by a particular transducer is dependant on the properties of the piezoelectric crystal within the scanhead. High frequency soundwaves are more attenuated within tissue relative to low frequency soundwaves and, therefore, a 3.5 MHz transducer will image deeper structures relative to a 7.5 MHz transducer. The resolution (ie: image quality) of an ultrasound image, however, is dependant on the wavelength and, as the wavelength is inversely proportional to frequency, the lower the frequency, the higher the wavelength.

The 3.5 MHz transducer, therefore, has a relatively decreased tissue resolution in comparison to the 7.5 MHz transducer (Herring and Bjornton, 1985; Nyland and Mattoon, 1995). As the reproductive tract in the early pregnant cow is in close proximity to the rectal wall, transrectal ultrasound pregnancy diagnosis utilizes high-frequency transducers which result in a detailed image. Although the pregnant uterus in mid to late pregnancy commonly lies directly against the right abdominal flank wall,

transcutaneous scanning would be facilitated by a low frequency (ie: 3.5 MHz) transducer to allow imaging of a large section of the fetus and/or placenta.

The majority of transcutaneous ultrasound studies to image the abdominal organs or specifically the pregnant uterus in cows, horses, deer and sheep have been completed using a low frequency transducer of 2.25 to 3.5 MHz (Fowler, 1984; Pipers and Adams-Brendemuehl, 1984; Braun and Marmier, 1995; Braun *et al.*, 2002).

## **2.4 PREPARATION OF THE ANIMAL AND RIGHT FLANK:**

Braun, in numerous transcutaneous ultrasonographic studies of organs within the bovine abdomen, found it necessary to clip and clear the skin of the animal prior to scanning (Braun *et al.*, 1997a; Braun and Amrein, 2001; Braun *et al.*, 2002). Aqueous gel was typically used as a coupling agent between the skin and the transducer surface. It is a common assumption that transcutaneous scanning over the bovine flank would require prior shaving of the body wall; a view supported by Kahn (1989). However, flank skin, which is overlain by the stifle fold, was typically only sparsely haired and early trials found time-consuming clipping of the flank hair is not necessary to obtain a high-quality ultrasound image.

Placing tactile pressure over the skin of the right flank of the dairy cow could conceivably present a real danger to the operator from a hindlimb strike. Dairy cows undergo manual manipulation of their teats and quarters on a twice daily basis, however, as the milker checks for the heat and swelling associated with mastitis. Vacuum pressures of approximately 45-50 kPa are applied to the udder and milkers commonly use a high-pressure hose to wash dirt and mud from the udder prior to milking. These actions combine to ensure the dairy cow is experienced to touch in the udder and

flank areas and early trials of the transcutaneous ultrasound technique found very few cows reacted negatively to application of the transducer head against the skin with most settling within 3-5 seconds.

Rantanen and Kincaid (1988) administered a combination of acepromazine, xylazine and butorphanol to a mare to cause uterine relaxation and forward fetal movement to allow easier visualization via transcutaneous scanning. This appears to be the only published study in which sedation was used on any species to allow transcutaneous ultrasound scanning for pregnancy diagnosis.

## **2.5 PRACTICAL CONSIDERATIONS:**

### **2.5.1 CURRENT NEW ZEALAND HOLDING FACILITIES:**


The primary practical limitations of the transcutaneous technique involves adequate access to the right flank and the availability of facilities able to hold the animal during scanning. The New Zealand dairy farm offers a variety of stock holding facilities including:

1. Vet/Artificial Insemination (AI) race
2. Crush
3. Walk-through dairy
4. Herringbone dairy
5. Rotary Herringbone dairy
6. Rotary Turnstyle dairy


#### **2.5.1 Vet/AI race:**

Cows can be either pushed individually or in groups into the race with heads directed away and rumps towards the operator to allow easy access to the right flank (see Figure 2.8). The ultrasound machine can be transported along the race on a moveable trolley. This method would be particularly useful for animals which are not trained to enter either a Herringbone or Rotary shed (eg: heifers, beef animals).





**A**



**B**

**Figure 2.7:** Linear (A) and sector (B) transducers (ALOKA). Note: the rectangular and arc-shaped scanning surface of the linear and sector transducers respectively.



**Figure 2.8:** Cows held in an AI/vet race allowing easy access to the right flank



### 2.5.2 Crush:

A crush with a head bale holds an individual animal relatively immobile (See Figure 2.9). A side gate can be opened to allow access to the right flank (See Figure 2.10). Flank scanning an animal held in a crush is a relatively safe method for both the operator and cow, especially for animals that have not been previously well handled (eg: beef animals).

### 2.5.3 Walk-through dairy:

Until the 1950s, the walk-through dairy was the most common shed type in New Zealand, particularly in herds of less than 100 cows (Holmes *et al.*, 2002). Cows were milked in individual stalls and one person could milk 30-40 cows per hour. Although now quite uncommon, this shed type would allow easy access to the right flank.

### 2.5.4 Herringbone dairy:

During the 1960s the Herringbone shed design became very popular on New Zealand dairy farms and, in 2001, there was an estimated 11,000 Herringbones present (Holmes *et al.*, 2002). This shed type allows 80-130 cows to be milked per person per hour (see Figure 2.11). Cattle positioned in the left hand race allow easy access to their right flanks either from the pit or planks which hold the operator at cow level (see Figure 2.12).

### 2.5.5 Rotary Herringbone:

In a Rotary Herringbone shed, the cow's head is directed to the outside of the shed while the milker stands in the centre to apply the cups (see Figure 2.13). If the shed has a left hand-side entry, the cows readily expose their right flanks to an operator (Figure 2.14).

### 2.5.6 Rotary Turnstyle:

Although rotary dairies have increased in popularity since the 1970s, they have been reserved mainly for the larger herds due to their high cost (see Figure 2.15). The larger, modern dairies can milk up to 200 cows per person per hour. Standard bail design specifications are a 200 mm wide bail dummy, a 660 mm wide entry to the bale and a 1640 mm bale length. These measurements allow a reasonable degree of animal movement and this, plus the fact that the operator cannot gain direct access to the side of the animal due to intervening pipework, makes transcutaneous scanning over the right flank very difficult in this type of dairy (see Figure 2.16).



**Figure 2.9:** A crush with head bale and side gate access

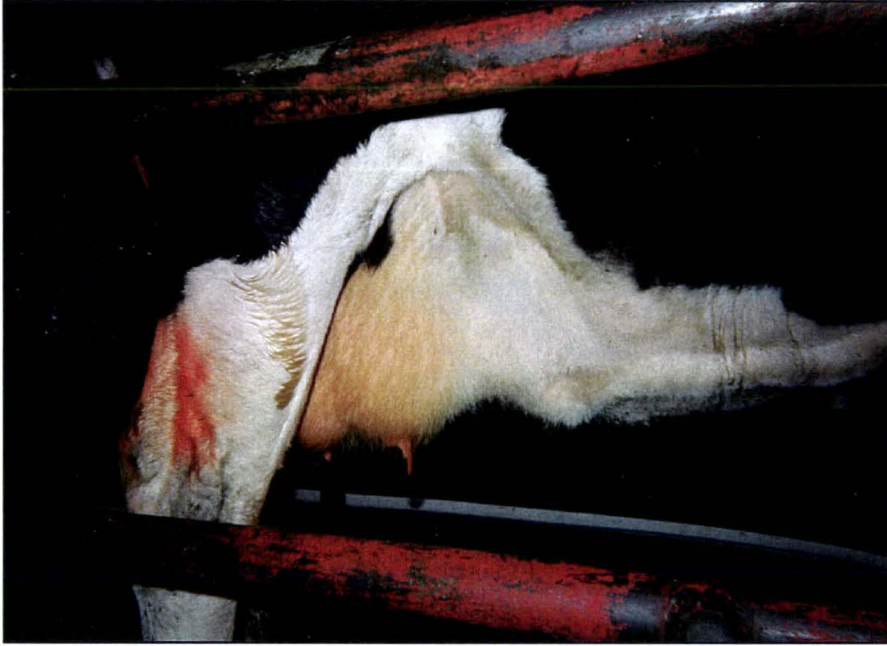



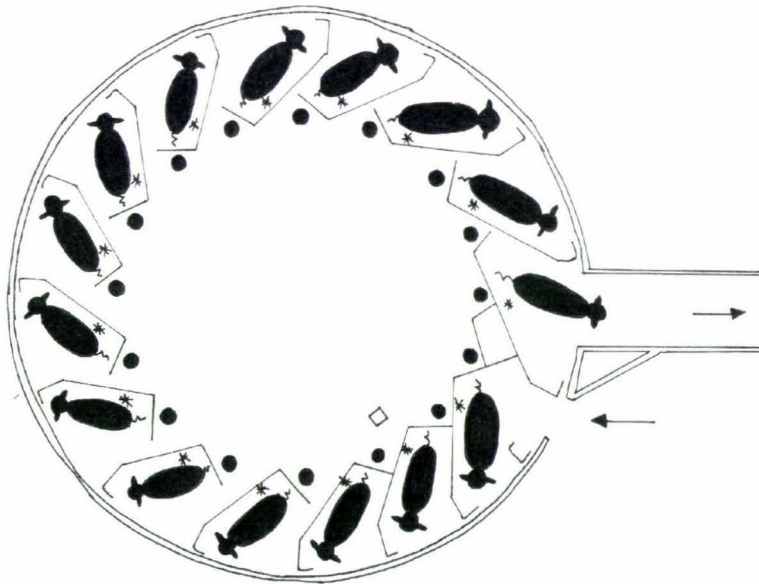
**Figure 2.10:** Movement of the bottom side gate allows access to the right flank in a crush



**Figure 2.11:** A simple high-line, swing-over Herringbone dairy

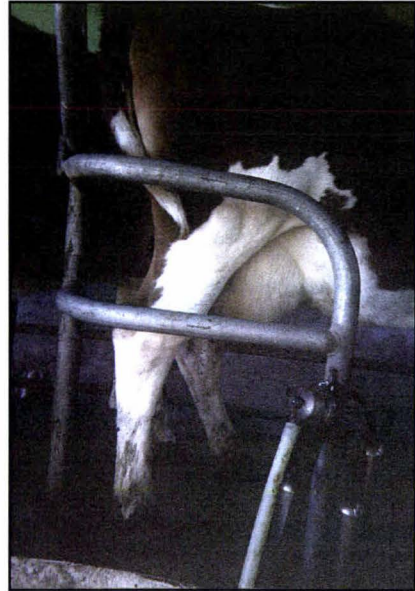
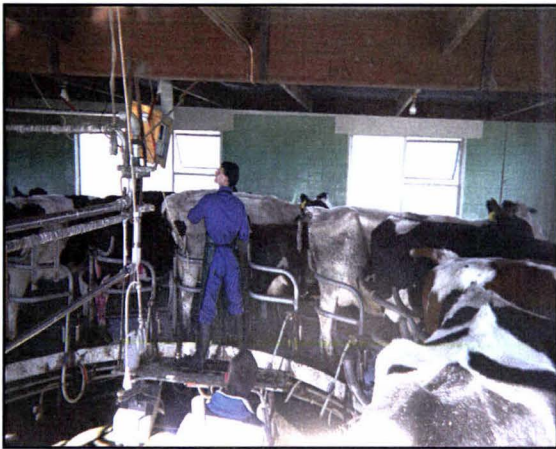
**Figure 2.12:** Access to the right flank at pit level in the left side of a Herringbone shed



**Figure 2.13:** Direction of cow movement and accessibility to the right flank of each animal in a Rotary Herringbone dairy (modified from Holmes *et al.*, 2002)



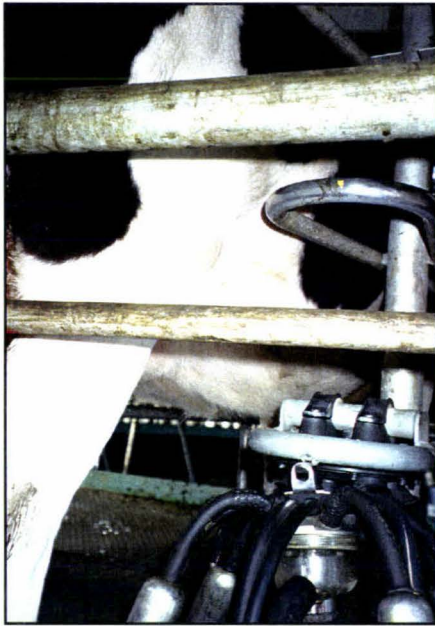

**Figure 2.14:** Cow position on a Rotary Herringbone shed. Note: allows easy access to the right flank




**Figure 2.15:** Rotary Turnstyle dairy





A



B

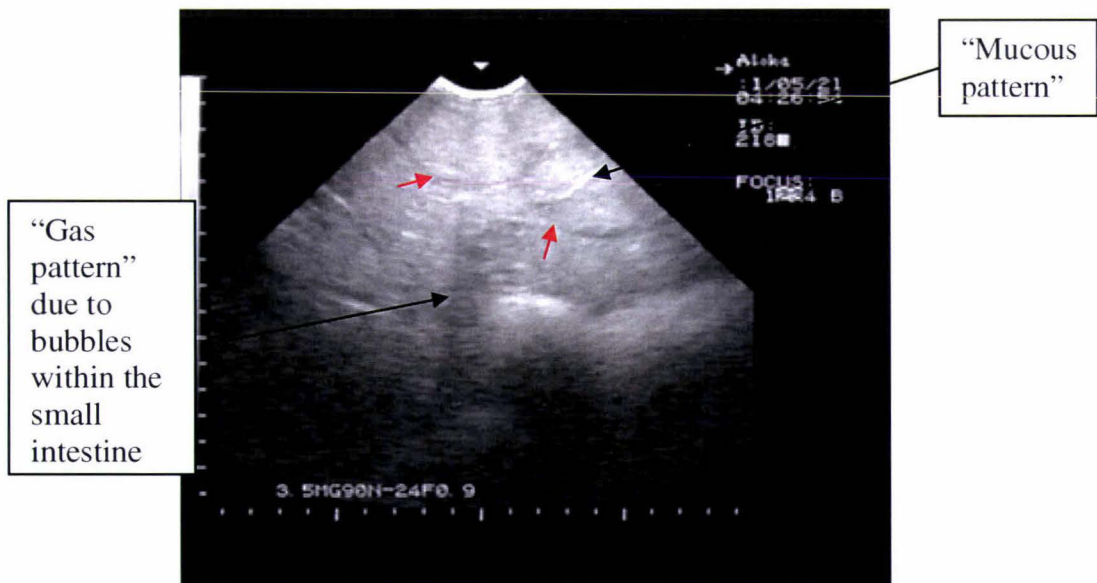
**Figure 2.16:** Demonstrating the difficulty in gaining access to the right flank due to intervening pipework of the bail dummy and kick rail in the turnstyle rotary shed (at pit level) (A) and the area available for cow movement within the bale (B).

## **2.6 PRELIMINARY IMAGES DERIVED FROM TRANSCUTANEOUS SCANS OVER THE RIGHT FLANK:**

### **2.6.1 THE NON-PREGNANT COW:**

The right caudoventral abdomen of the non-pregnant cow is principally occupied by the ileum and jejunum, although the rumen can enter the right flank if overfilled. Preliminary transcutaneous scans over the right flank of the non-pregnant dairy cow using a 3.5 MHz sector transducer found cross-sectional images of the small intestinal loops could be easily identified as echoic, irregular oval-shaped structures with visible peristaltic motion (see Figure 2.17). Braun *et al.* (1995) found more than 10 loops of small intestine could be visualized via transcutaneous ultrasonography over the right flank in over 94% of non-pregnant cows scanned.

The ileum and jejunum can be differentiated ultrasonographically from the large intestine on the basis of their contents. The small intestinal contents appear hypoechoic to echoic, whereas the contents of the large intestine are anechoic due to higher levels of intraluminal gas produced from carbohydrates remaining in the ingesta after passage through the forestomachs (Braun and Amrein, 2001). An ultrasonographic study in horses found the small intestine was identified more consistently when the animal was fed hay and concentrate relative to a grass-based diet (Freeman, 2002). The collapsed small intestine is characterized by echogenic mucous contents without acoustic shadowing (ie: a “mucous pattern”) (Nyland and Mattoon, 1995). As gas acts as an acoustic barrier to ultrasound and reflects most of the incident beam, a small intestine containing gas appears as a series of highly hyperechoic-reflective interfaces with acoustic shadowing (ie: a “gas pattern”).



**Figure 2.17:** Small intestinal loops (red arrows) filling the right caudoventral abdomen in a non-pregnant cow

The walls of the small intestine are in relative close proximity to the abdominal wall in comparison to the large intestine where intraluminal gas

prevents visualization of the wall furthest from the examiner. The ileum and jejunum can be differentiated from the duodenum due to constant motion as a result of peristaltic and oscillating movements (Braun and Marmier, 1995). The ileum and jejunum, however, cannot be differentiated individually ultrasonographically.

### **2.6.2 THE PREGNANT COW:**

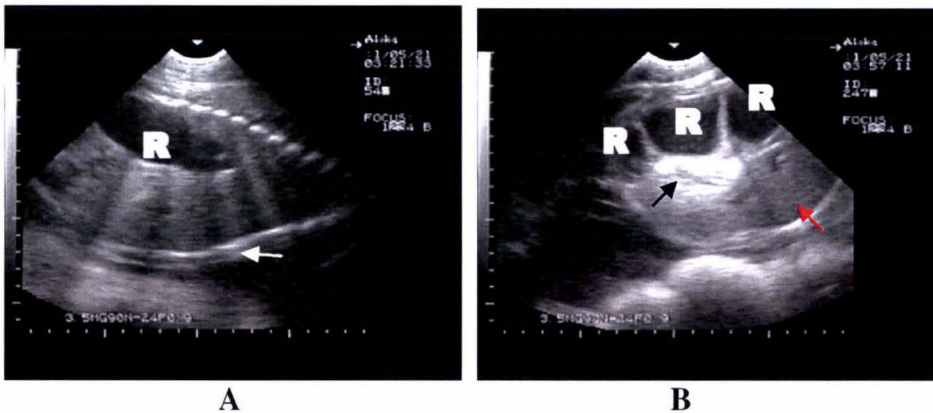
Preliminary transcutaneous scans of the pregnant dairy cow using a 3.5 MHz sector transducer found the fetus, placentomes, umbilical cord, fetal membranes and fetal fluids could be readily visualized. Yamaga and Too (1984) found similar results for basic transcutaneous scans over the right flank of 5 cows from 4-7 months of gestation. In this preliminary study, an image able to provide a definitive diagnosis of pregnancy could be achieved within 2-5 seconds of transducer application in the majority of animals.

Prior to 5 to 6 months of gestation, the fetus enjoys a limited degree of movement within the amnion and can be visualized in a variety of planes when scanned from the right flank (see Figure 2.18). Rotation around the longitudinal axis is limited by the length of the umbilical cord and no more than a three-quarter revolution is possible. Movement around the transverse axis is also limited once the fetal length exceeds the width of the amnion and a complete revolution is generally only seen in mummified calves (Arthur *et al.*, 1982).

Although the use of a low frequency transducer decreases the resolution of the ultrasound image, it was still possible to visualize the uterine structures in a relatively high degree of detail (see Figure 2.20). Calcification of the ribs becomes visible from 59 days of gestation and acoustic shadowing, or areas of low-amplitude echoes created by bony structures such as the vertebrae and ribs, are readily visible in transcutaneous scans (Curran *et al.*, 1986b). The largest anechoic area in the fetal abdomen was the developing fluid-filled rumen subdivided into compartments. Cranioventral to the

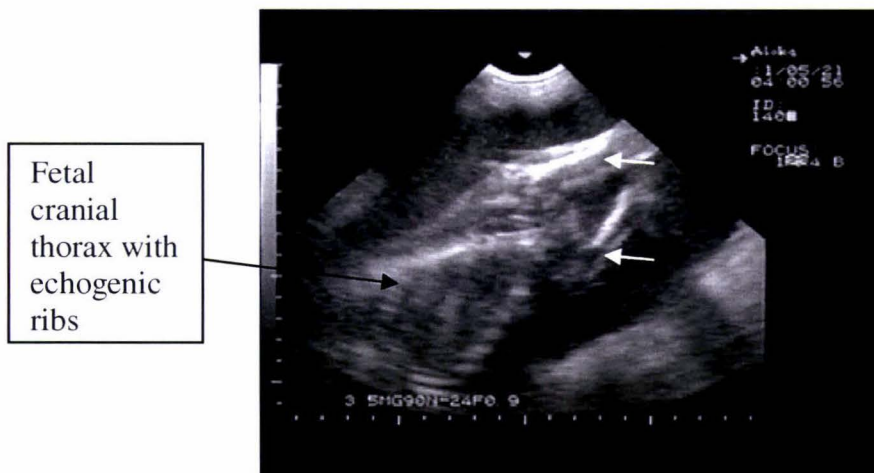


rumen was the echogenic reticulum and intestinal mass.

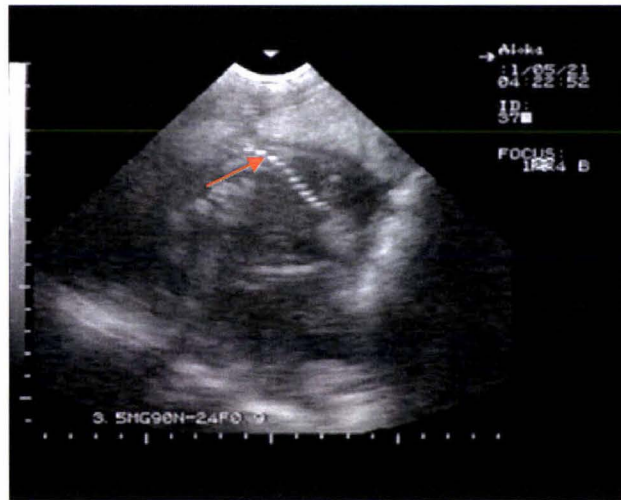

**Figure 2.18:** A lateral (A) and craniocaudal (B) view of a fetal abdomen and thorax with anechoic ruminal compartments (R), acoustic shadowing from the ribs (white arrow), the hyperechoic reticulum (black arrow) and granular intestinal mass (red arrow).

The bones of the fore- and hindlimbs, incorporating the humerus, femur, radius, tibia, ulna, fibula, metatarsus and metacarpus, are readily identifiable from 10-12 weeks of gestation using transcutaneous scanning (Kahn, 1989) (see Figure 2.19). By 12 weeks of gestation, the cartilage of the hooves can also be clearly seen.

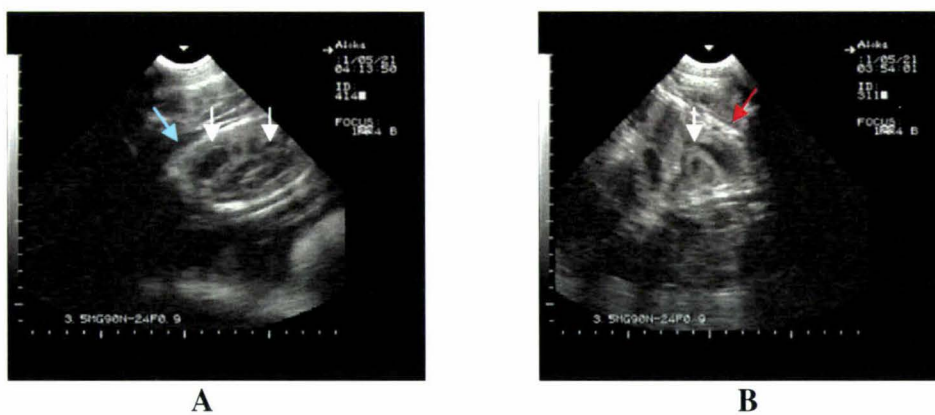


**Figure 2.19:** Fetal forelimbs (white arrows) and cranial thorax at 104 days of gestation



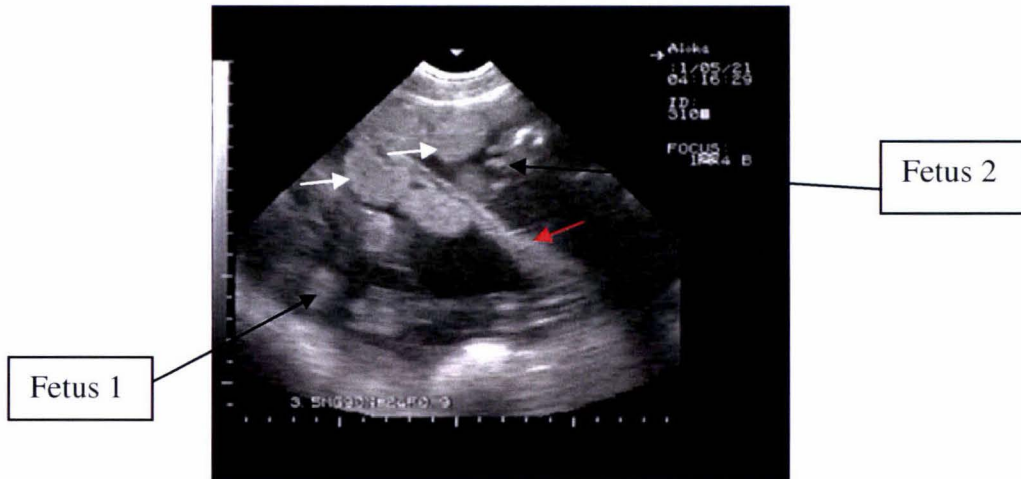**Figure 2.20:** Lateral view of fetal tail vertebrae (red arrow) at 111 days of gestation illustrating the relatively fine detail achievable by transcutaneous scanning.

Dynamic images such as fetal movements and beating of the fetal heart within the cranial, cone-shaped thorax could also be easily visualized (see Figure 2.21). By 35 days of gestation, placentomes are evident via transrectal ultrasound as discrete, raised, arcuate areas over the uterine lumen (see Figure 2.22) (Boyd and Omran, 1991; Boyd, 1995). There is great variation in placentome number, size and shape with the largest placentomes found surrounding the fetus (Roberts, 1986; Leiser *et al.*, 1997). Placental vessels anastomose in cases of twinning in cattle, which results in fetal chimerism, a characteristic obvious on transcutaneous scans (Schlafer *et al.*, 2000).



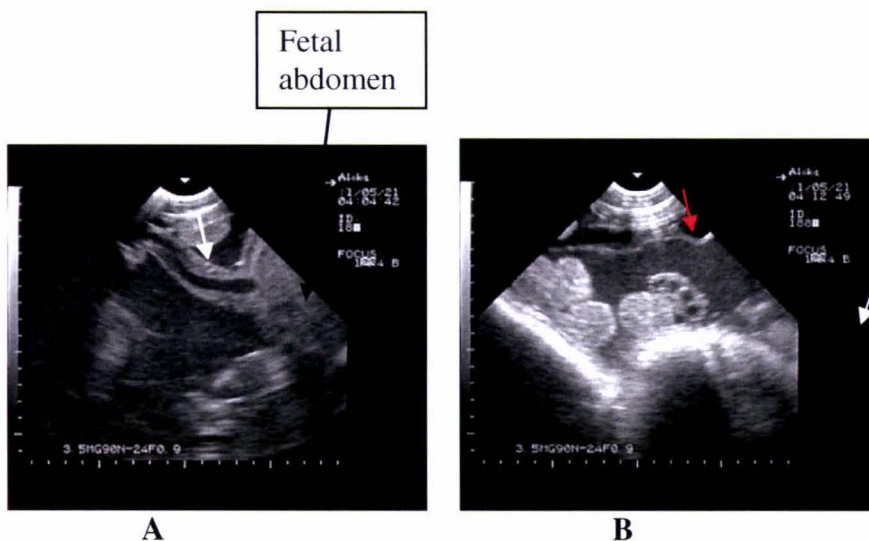
**Figure 2.21:** Two views of the fetal heart chambers (white arrows), pericardium (blue arrow) and ribs (red arrow) at 139 days (A) and 95 days of gestation (B)





**Figure 2.22:** Placentomes (white arrows) and a placental anastomosis (red arrow) of a twin pregnancy at 106 days of gestation.

In a transrectal ultrasonographic study, Kahn (1989) found the umbilical cord was detectable at a very early stage of fetal development and by 3 months of gestation, detailed anatomy such as the paired umbilical arteries and veins become visible within the cord. In cross-section, the four vessels can be visualized in a quadrilateral arrangement, whereas in the longitudinal view, only one to two vessels can be seen at one time (see Figure 2.23).



**Figure 2.23:** Longitudinal (A) and cross-sectional (B) images of an umbilical cord (white arrows) and fetal membranes (red arrow).

## **2.7 Conclusion:**

The use of transcutaneous ultrasound in order to diagnose pregnancy in the dairy or beef cow has not been previously studied in detail. Knowledge of the characteristic anatomy, development and movement of both the bovine uterus within the dam's abdomen and the bovine fetus, however, indicates the right flank is the most appropriate position for pregnancy diagnosis across the skin in this species.

Studies in red and fallow deer, horses, sheep, goats and pigs allow extrapolation of practical details such as transducer frequency and type. In preliminary studies of dairy cows, it was found the use of a 3.5 MHz sector transducer produced detailed images of the bovine fetus in utero, allowing easy and rapid diagnosis of pregnancy.

The commonly available New Zealand holding facilities of the Herringbone dairy, Rotary Herringbone dairy, Vet/AI race, crush and/or Walk-through dairy allow rapid access to the right flank of a dairy or beef animal and securely holds the animal to safely allow this access. Transcutaneous scanning of an animal held in a Rotary Turnstyle dairy, however, is impractical due to intervening pipework limiting access to the right flank and the relatively large area allowed for animal movement.

Transcutaneous ultrasound utilizing a 3.5 MHz sector transducer applied over the right flank allows rapid and detailed visualization of bovine pregnancy (ie: fetus, fetal fluids, placentomes and/or fetal membranes). Further investigation of the accuracy of this method over the entire gestation period and its possible use in ageing the bovine fetus is merited.



### **CHAPTER 3:** **COMPARISON OF TRANSCUTANEOUS ULTRASOUND OVER THE RIGHT FLANK WITH TRANSRECTAL ULTRASOUND FOR PREGNANCY DIAGNOSIS IN THE DAIRY COW**

#### **3.1 Introduction:**

Pregnancy diagnosis via either manual palpation *per rectum* and/or transrectal ultrasound is essential in the controlled and economic management of the modern New Zealand dairy farm (Williamson, 1994). Numerous, comprehensive studies have demonstrated high and acceptable accuracy levels (>90%) for both techniques between 30-90 days of gestation (White *et al.*, 1985; Pieterse *et al.*, 1990; Hanzen and Laurent, 1991; Szenci *et al.*, 1995; Nation *et al.*, 2003). After this time period, however, the bovine fetus passes over the dam's cranial pelvic brim and out of range of the ultrasound beam or palpating hand, and the accurate diagnosis of mid to late gestation using either technique becomes increasingly difficult (White *et al.*, 1985). Both manual palpation *per rectum* and transrectal ultrasound are also invasive, requiring insertion of a gloved, lubricated hand or transducer probe into the cow's rectum, risking rectal and/or intestinal bruising or perforation.

The development of alternative pregnancy testing techniques has focused on the first 30 days of gestation, allowing rapid and accurate intervention for non-pregnant cows. There is a requirement, however, for a rapid, safe and accurate technique for the diagnosis of pregnancy status in mid to late pregnancy. Preliminary trials of transcutaneous ultrasound over the right flank, both by Yamaga and Too (1984) and in this study have found a 3.5 MHz sector transducer over the skin allows rapid visualization of the fetus, fetal membranes, fetal fluids and placentomes within the uterus. Small intestinal loops, which occupy the right caudoventral flank in the absence of a pregnant uterus, were also readily visible.



The current study was aimed at assessing the accuracy of transcutaneous ultrasound over the right flank for pregnancy diagnosis over the entire gestational period and in early vs mid-late pregnancy in dairy cattle, while comparing it to transrectal ultrasound.

### **3.2 Materials and methods:**

The pregnancy status of ten commercial, spring and autumn-calving dairy herds in the Northland region of New Zealand was identified using a combination of real-time transrectal ultrasound, transcutaneous ultrasound over the right flank and manual palpation *per rectum*. Herds were chosen on the basis of:

- being long-standing clients of Whangarei Veterinary Services
- a history of annually presenting their entire herd for transrectal ultrasound pregnancy diagnosis
- availability of a herring-bone dairy or vet/AI race
- a history of herd testing on a regular basis
- accurately recording their farm data using the MindaLINK or MindaPRO systems monitored by the Livestock Improvement Corporation (LIC)

Herd size ranged from 73 to 422 cows. A total of 2325 cattle were used (see Table 2.1). All herds, with the exception of Herd 3, had an artificial insemination (AI) period of 4 to 5 weeks with a subsequent natural mating period of 4 to 9 weeks. Herd 3 was mated by natural service only, while Herd 8 had an extended AI period of 7 weeks. Pregnancy diagnosis was carried out between 127- 193 days after the start of mating. Table 2.1 shows the date of pregnancy diagnosis in relation to the start of artificial insemination, start of natural mating (ie: end of artificial insemination) and the end of mating for each herd. The range of possible gestation lengths at pregnancy diagnosis, based on the service periods, over all herds was 42 to 193 days.



**Table 3.1: Herd size and the date of the start of artificial insemination and natural mating and end of natural mating relative to the date of pregnancy diagnosis**

HERD	Herd size:	Start of artificial insemination (AI):	Start of natural mating:	End of natural mating:	Day of pregnancy diagnosis (PD):	Start of mating to PD:	End of mating to PD:
1	240	20/10/2002	12/11/2002	31/12/2002	25/02/2003	127 days	57 days
2	177	16/10/2002	UNK	9/01/2003	20/02/2003	128 days	42 days
3	73	N/A	1/10/2002	1/01/2003	14/02/2003	137 days	45 days
4	363	10/10/2002	14/11/2002	31/12/2002	28/02/2003	142 days	60 days
5	191	7/10/2002	7/11/2002	27/12/2002	27/02/2003	144 days	63 days
6	422	1/10/2002	8/11/2003	20/01/2003	3/03/2003	154 days	42 days
7	260	11/10/2002	12/11/2002	20/12/2002	11/03/2003	163 days	81 days
8	300	9/10/2002	3/12/2002	1/01/2003	8/04/2003	182 days	98 days
9	174	11/10/2002	23/11/2002	20/02/2003	16/05/2003	187 days	56 days
10	125	1/10/2002	5/11/2002	1/01/2003	11/05/2003	193 days	101 days
	<b>2325</b>				<b>RANGE:</b>	<b>127-193 days</b>	<b>42-101 days</b>

The cows were held in rows of six to eight in either a herring-bone dairy or vet/AI race. All examinations were completed before the next row was examined. One veterinarian (JCG) completed all examinations in all herds, with the exception of Herd 6. In Herd 6, one veterinarian completed the transrectal ultrasound and manual palpation *per rectum* (ASC) while another veterinarian (JCG) completed the flank ultrasound examinations. Due to the difference in the lead length of the linear transducer, used for transrectal ultrasound scans, and the sector transducer, used for flank ultrasound scans (approximately 295 cms and 200 cms respectively), of the 2325 animals scanned by the transrectal technique, only a random number in each row, totaling 1736 (74.7%) animals, were examined by the flank technique (see Table 3.2). Only animals scanned by the flank technique were included in the analysis. The individual ear tag number of each animal was used as the sole source of identification in all cases.

Adhering to practice policy, any cows diagnosed as “non-pregnant” on transrectal ultrasound were then examined via manual rectal palpation, regardless of the result of the flank ultrasound examination.

### **3.2.1 REAL-TIME B-MODE TRANSRECTAL ULTRASONOGRAPHY:**

An ALOKA SSD-500 ultrasound machine with a 7.5 MHz linear probe was used for all transrectal ultrasound examinations. The probe was taped to an “extender”, which consisted of a flattened, stainless steel rod (length: 35 cms ; width: 3 cms; depth: 0.5 cm), screwed to a wooden handle, for easier insertion of the probe head into the rectum. The probe was carefully introduced into the rectum of each cow lubricated with Veterinary Lubricant (active compound = Methylcellulose). The probe, while being directed into the rectum, had pressure applied ventrally and was rotated to the left and right to ensure a thorough examination of the pelvic area. A diagnosis of pregnant, non-pregnant or “re-examination at a later date needed” was made

and recorded by an assistant or the herdowner.

A diagnosis of pregnant was made when an anechoic, fluid-filled structure was visualized, cranial to the bladder, containing an entire fetus, fetal parts and/or placentomes. A diagnosis of non-pregnant was made when the above structure(s) could not be visualized in the area between the bladder and the caudal wall of the rumen. Re-examination at a later date was recommended when the above structures could not be visualized but the uterus, when palpated manually, contained fluid that resembled a 5 to 6 week pregnancy. Re-examinations were completed 3 to 4 weeks after the initial pregnancy diagnosis date. These animals were not included in the analysis.

### **3.2.2 MANUAL PALPATION *PER RECTUM*:**

The veterinarian who completed the transrectal ultrasound examination and diagnosed the animal as non-pregnant, manually checked the same animal within 2-3 minutes using a gloved, lubricated hand inserted into the rectum.

### **3.2.3 REAL-TIME TRANSCUTANEOUS FLANK ULTRASONOGRAPHY:**

An ALOKA SSD-500 ultrasound machine with a 3.5 MHz sector probe was used for all flank ultrasound examinations. The probe was taped to an extender similar to that used in the transrectal ultrasound examinations. In all cases, the sector probe was positioned against the skin of the right flank, dorsal to the udder and underneath the flank fold of the cow or heifer (see Figure 3.1). The probe was initially placed centrally under the flank fold and then directed caudally and cranially along the flank fold to identify earlier and more advanced pregnancies, respectively. Lubricant was used to facilitate contact between the probe and the skin. No hair removal or skin preparation was necessary or used. Diagnoses of “pregnant” or “no detectable pregnancy” (NDP) was recorded by an assistant. A diagnosis of



pregnant was made when a fluid-filled structure containing a fetus, fetal parts and/or placentomes were visualized on application of the probe to the flank skin. A diagnosis of no detectable pregnancy was made when the above structure(s) could not be visualized but a clear ultrasound image was produced of the small intestines.



**Figure 3.1:** Application of the transcutaneous flank technique to diagnose pregnancy in the left side of a Herring-bone shed.

#### **Method of pregnancy diagnosis using transcutaneous ultrasound over the right flank:**

Cows were scanned either at cow level from planks spanning the pit of a Herringbone shed or within a vet/AI race, or from pit level within a Herringbone shed.

##### **3.2.3.1 PLANK:**

Two specially designed stainless steel planks running parallel with the left side of a Herringbone dairy hung over two cross-bars spanning the pit and were used to elevate the operator to cow level. The cows were run into the left side of the shed and examined with the ultrasound machine suspended from the milk line. All herds, except Herds 2 and 3, were examined via



transrectal ultrasound in this way, and all herds except Herds 2, 3 and 6 were examined via flank ultrasound in this manner. No additional roping or holding devices were used.

#### 3.2.3.2 PIT:

The cows were run into the left side of a Herring-bone dairy with their right flanks exposed. The cows were flank scanned from the pit of the dairy with the ultrasound machine secured on a moveable, stainless steel trolley which was wheeled along the pit. Flank ultrasound examinations were completed in this way for Herd 6.

#### 3.2.3.3 VET/AI RACE:

The cows were run into a vet/AI race with their heads facing away and rumps facing towards the operator on the right side, allowing access to the right flank. Transrectal and flank ultrasound examinations were completed in this manner in Herds 2 and 3.

In Herd 6, due to time constraints, rectal ultrasound and manual palpation *per rectum* were completed by veterinarian B on the planks while flank ultrasound was performed simultaneously by veterinarian A from the pit. To ensure the two veterinarians were compatible in terms of their relative sensitivity and specificity in rectal ultrasound diagnosis, the pregnancy status of a separate herd of 139 mixed age, mixed breed dairy cattle was identified. The age of the pregnancies ranged from 52-172 days, which was in a comparable range to Herd 6. The veterinarians completed their herd pregnancy tests two days apart and were not aware of the results diagnosed by the other veterinarian.

### **3.2.4 GOLD STANDARD OF PREGNANCY STATUS:**

#### Cows remaining on-farm:

The applied gold standard (ie: confirmation of pregnancy status at

pregnancy diagnosis) for each animal which remained on-farm until the end of the calving period (ie: 31<sup>st</sup> October 2003) was a specific calving date. A non-pregnant animal was confirmed as such by a lack of known calving date by the end of the calving period. The calving dates were collected from the herdowner, where necessary, and from the farm data set via the MindaPRO (Livestock Improvement Corporation, 2003) system. Further information was sought from farmers where there was significant discrepancy between the test result and the recorded calving outcome.

Herdowners were also asked to record any abortions, premature calvings and all animals which received induction shots and their subsequent calving dates.

#### Cull cows:

The senior veterinarian or the head of the meat department at the two local abattoirs were asked to check the pregnancy status of any animals culled from the enrolled herds up to the 31<sup>st</sup> October 2003. The abattoir was made aware of the tag and slaughter line numbers of the cattle and their date of transport to enable slaughterline examination. The results of the cull cow examinations were pregnant/non-pregnant only and specific ageing measurements (eg: crown-rump length) of the fetuses were not completed. The author was made aware of the cull cow examinations via phone and fax.

#### Sold cows:

In Herds 2 and 7, cull cows were sold either privately or through saleyards. In all cases, the subsequent buyers did not remove the original ear tags and so could state whether the animals calved before October 31<sup>st</sup> 2003. If possible the calving date of any pregnant cows was noted but the focus was on establishing a gold standard for the sold, non-pregnant cows.

### 3.2.5 CALCULATION OF CONCEPTION DATES:

The age of gestation at the time of pregnancy diagnosis was determined using the definitions formulated by Mueller (2001).

#### Cows with full term pregnancies:

The conception date for cows which remained in the herd and calved at full-term was defined as the calving date minus 282 days. The calculated conception date was compared to recorded artificial insemination and natural service dates and where the discrepancy between recorded service date and calculated conception date was:

\* *12 days or less*, the recorded service date was taken as the actual conception date

\* *13 days or more* and the calculated conception date fell into the natural mating period for that farm, this calculated date was used as actual conception date

\* *13 to 21 days* and the calculated conception date fell into the artificial insemination period for that farm, the recorded service date was used as actual conception date.

For cows for which there was irreconcilable disagreement between the dates of recorded service and calculated conception dates, the calculated conception date was used.

#### Cows with induced parturitions:

The conception date was initially calculated as the induced calving date minus 282 days. The last recorded service was then used as the actual conception date where this was later than the calculated conception date. If the last recorded service date fell before the calculated conception date, multiples of 21 days were added to the last service date, until the new service date was later than the calculated conception date. Where the



difference between calculated conception date and last recorded service date was seven days or less, the calculated conception date was used as actual conception date.

Cows with abortions and premature calvings:

The last recorded service date was used as the actual conception date for cows with a recorded abortion or premature calving.

**3.2.6 COMPARISON AND STATISTICS:**

Results were grouped into (a) correct diagnosis pregnant; (b) incorrect diagnosis non-pregnant; (c) incorrect diagnosis pregnant; and (d) correct diagnosis non-pregnant.

		<b>PREGNANCY STATUS:</b>	
		PREGNANT    NON-PREGNANT	
<b>TEST:</b>	PREGNANT	a (TP)	b (FP)
	NON-PREGNANT	c (FN)	d (TN)

TP = True pregnant  
FN= False negative

FP = False positive  
TN = True negative

Sensitivity was calculated as

$$[a/(a+c)] \times 100$$

Specificity was calculated as:

$$[d/(b+d)] \times 100$$

Positive predictive value was calculated as:

$$[a/(a+b)] \times 100$$

Negative predictive value was calculated as:

$$[d/(c+d)] \times 100$$

Sensitivity, specificity, negative and positive predictive value analysis of flank and transrectal ultrasound overall and with cows grouped into 14-day periods was carried out. For each flank and transrectal ultrasound



pregnancy test a new variable of “correct diagnosis” was created combining the results of sensitivity and specificity. True positive and true negative diagnoses were given a score of 1 and false positive and false negative diagnoses were given a score of 0. Using the “proc freq” command of SAS (2001), the differences in the probability of a correct diagnosis between flank and transrectal ultrasound were compared using the chi-square test. Factors affecting the probability of a correct diagnosis were evaluated using logistic regression (SAS, 2001). The models considered the effects of herd, cow age, cow breed, bull breed, calf sex and method of diagnosis. A threshold value of gestational age at pregnancy diagnosis was determined as the value where there existed an odds ratio of 1.

### **3.3 Results:**

#### **3.3.1 NUMBERS EXAMINED AND DERIVATION OF GOLD STANDARD:**

As shown in Table 3.2, of the 1736 cows examined for pregnancy by both flank and transrectal ultrasonography, 11.3% were culled and 88.7% were retained to calve on-farm. While 98.8% of retained cows had their pregnancy status confirmed by gold standard, only 24.8% of culled cows had a gold standard result.

Although cow deaths (15 cases; 7.8%) and incomplete record keeping (5 cases; 3%) accounted for the loss of retained cows on-farm, the majority of cows lost to the study were due to culling without confirmation of pregnancy status (148 cases; 89.2%). In total, 1570 (90.4%) had their pregnancy status confirmed by gold standard.

Overall, 91.7% of cows scanned via flank ultrasound were pregnant, all of which were confirmed by calving records (See Table 3.3). Of the cows retained on-farm, 94.9% (1440/1517) were pregnant while 5.1% were non-pregnant (81/1517). Non-pregnant cows (130/1570; 8.3%) had their

pregnancy status confirmed either by a lack of calving date on-farm (81/130; 62.3%); abattoir examination of the reproductive tract (37/130; 28.4%) or lack of calving date via vendor (12/130; 9.2%). Only non-pregnant cull cows were included in this study.

### **3.3.2 SENSITIVITY, SPECIFICITY, POSITIVE AND NEGATIVE PREDICTIVE VALUES:**

#### **3.3.2.1 Overall results:**

Table 3.4 illustrates the number of cows that had their pregnancy status correctly or incorrectly diagnosed for each herd in the study. Significantly ( $p < 0.001$ ) more pregnant cows were incorrectly diagnosed as not detectably pregnant (NDP) by flank ultrasound (594) relative to transrectal ultrasound (54) while marginally more non-pregnant animals were incorrectly diagnosed as pregnant by transrectal ultrasound (3 vs 1).

The overall sensitivity, specificity and positive and negative predictive values for all cows flank scanned with gold standard in the ten herds is shown in Table 3.5. The sensitivity of flank ultrasound overall was relatively much lower than transrectal ultrasound at 58.55% and 96.24% respectively while the specificity of flank ultrasound (99.20%) was marginally higher than transrectal ultrasound (97.70%) (see Table 3.5). The overall negative predictive value of flank ultrasound was relatively low in comparison to transrectal ultrasound at 17.84%. The positive predictive value of the two methods was almost identical, however, at 99.85% for transrectal ultrasound and 99.80% for flank ultrasound. The probability of making a correct diagnosis of pregnancy status was significantly ( $p < 0.0001$ ) higher when using transrectal ultrasound in comparison to flank ultrasound over the entire gestational age range of 42-193 days.

### 3.3.3 RESULTS BY:

#### 3.3.3.1 Gestational Age at Pregnancy Diagnosis (days):

The effect of gestational age at date of pregnancy diagnosis upon the specificity and sensitivity of pregnancy diagnosis was highly significant for both flank and transrectal ultrasound ( $p < 0.0001$ ). Sensitivity, specificity and positive and negative predictive values of flank and transrectal ultrasound were calculated with cows grouped according to their gestational age at date of pregnancy diagnosis (see Table 3.6).

The sensitivity of flank ultrasound increased in a linear fashion with advancing stage of gestation, reaching a plateau at approximately 155 days of gestation (see Figure 3.2). For cows at least 155 days in calf, the sensitivity of flank ultrasound improved significantly by 49.75% (49.2% to 98.95%) and after this date the sensitivity of flank ultrasound was marginally higher than the sensitivity of transrectal ultrasound (98.5% vs 91.85%). The sensitivity of rectal ultrasound remained relatively constant to 168 days of gestation, after which it decreased to less than 86%. Although the positive predictive values remained relatively constant for the flank ultrasound method, they were quite variable for transrectal ultrasound particularly between 70 and 170 days of gestation (see Table 3.6).

The specificity of both transrectal and flank ultrasound remained relatively constant from 31 to 196 days of gestation (see Table 3.6 and Figure 3.3). The negative predictive values of flank ultrasound improved significantly ( $P < 0.001$ ) from 8.7% at less than 155 days of gestation to 83.35% after 155 days of gestation and was greater for flank ultrasound than transrectal ultrasound during this time period (83.35% vs 53.20%) (see Table 3.6).

The probability of making a correct diagnosis of the pregnancy status was significantly ( $p > 0.0001$ ) higher for flank ultrasound after 155 days of gestation in comparison to transrectal ultrasound.

**Table 3.2: Number of cows culled and retained on-farm with results for each herd**

HERD:	Herd size:	Cows with flank scan result:		Flank scanned cows with full set of results*:		Total number of flank scanned cows culled from herd:		Cows with full set of results of cull cows:		Total number of flank scanned cows retained in the herd		Cows with full set of results of retained cows:	
		Number:	%:	Number:	%:	Number:	%:	Number:	%:	Number:	%:	Number:	%:
1	240	164	68.3	153	93.2	19	12.4	9	47.3	145	88.4	144	99.3
2	177	166	93.7	148	89.1	24	14.4	8	33.3	142	85.5	141	98.6
3	73	73	100	71	97.2	3	4.1	3	100	71	95.9	67	94.4
4	363	216	59.5	196	90.7	23	10.6	5	21.7	193	89.4	193	100
5	191	183	95.8	166	90.7	11	6	0	0	172	93.9	167	97.1
6	422	334	79.1	298	89.2	36	10.7	0	0	298	89.2	298	100
7	260	203	78	159	78.3	48	23.6	7	14.5	155	76.3	149	96.1
8	300	196	65.3	184	93.8	27	13.7	16	59.2	169	86.2	169	100
9	174	101	58	96	95	5	4.9	0	0	96	95	95	98.9
10	125	99	79.2	99	100	1	1	1	100	98	98.9	98	100
<b>TOTAL:</b>	<b>2325</b>	<b>1736</b>	<b>74.7</b>	<b>1570</b>	<b>90.4</b>	<b>197</b>	<b>11.3</b>	<b>49</b>	<b>24.8</b>	<b>1539</b>	<b>88.7</b>	<b>1521</b>	<b>98.8</b>



Herd:	Flank scanned cows with full set of results	<u>Pregnant cows:</u>				<u>Non-pregnant cows</u>											
		Flank scanned cows		Pregnant cows with gold standard derived from calving records:		Flank scanned cows non-pregnant on gold standard:		Non-pregnant cows with gold standard derived from calving records:		Non-pregnant cows with gold standard derived from abattoir:		Non-pregnant cows with gold standard derived from vendor:					
		No:	%:	No:	%:	No:	%:	No:	%:	No:	%:	No:	%:				
1	153	144	94.1	144	100	9	5.8										
2	148	133	89.9	133	100	15	10	0	0	9	100	0	0	0	0	0	0
3	71	66	92.9	66	100	5	7.1	7	46.6	0	0	8	53.3	0	0	0	0
4	196	171	87.2	171	100	25	13	2	40	3	60	0	0	0	0	0	0
5	166	163	98.1	163	100	3	1.8	20	80	5	25	0	0	0	0	0	0
6	298	298	100	298	100	0	0	3	100	0	0	0	0	0	0	0	0
7	159	151	94.9	151	100	8	5	0	0	0	0	0	0	0	0	0	0
8	184	165	89.7	165	100	19	10	1	12.5	3	37.5	4	50	0	0	0	0
9	96	54	56.3	54	100	42	44	3	15.7	16	84.2	0	0	0	0	0	0
10	99	95	95.9	95	100	4	4	42	100	0	0	0	0	0	0	0	0
<b>TOTAL:</b>	<b>1570</b>	<b>1440</b>	<b>91.7</b>	<b>1440</b>	<b>100</b>	<b>130</b>	<b>8.3</b>	<b>3</b>	<b>75</b>	<b>1</b>	<b>25</b>	<b>0</b>	<b>0</b>	<b>0</b>	<b>0</b>	<b>0</b>	<b>0</b>

**Table 3.4: Comparison of results for pregnant and non-pregnant cows:**

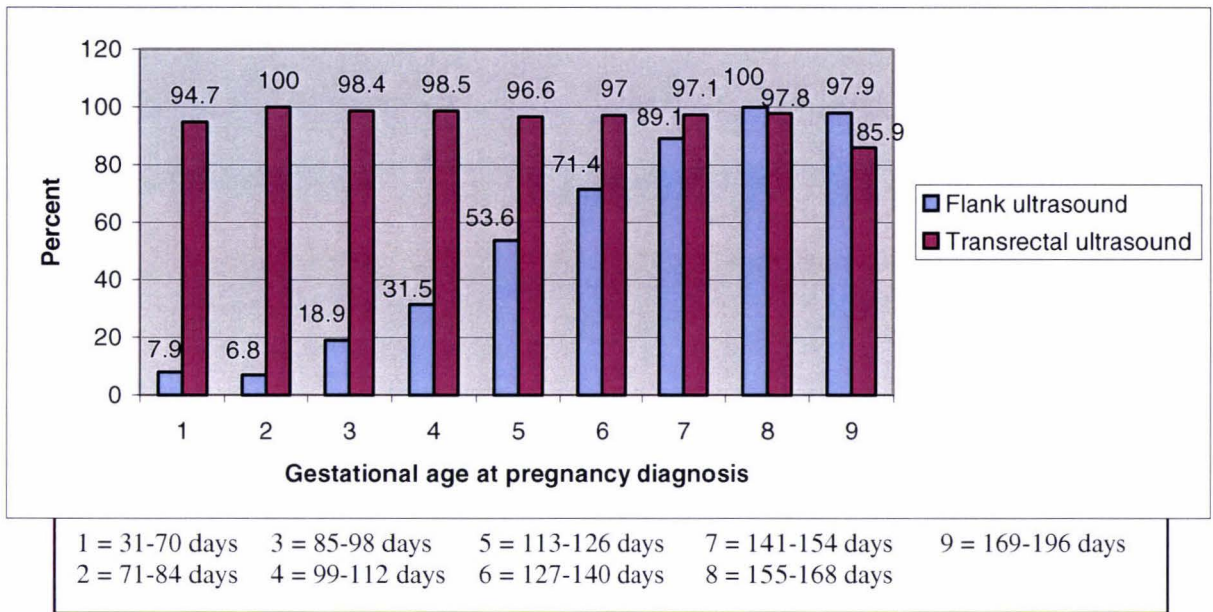
	Number of cows:	Flank ultrasound:	Rectal ultrasound:	HERD:									
				1	2	3	4	5	6	7	8	9	10
<b>Pregnant cows:</b>	791	Pregnant	Pregnant	26	45	48	52	75	219	83	129	35	79
	48	Pregnant	NDP	2	8	5	3	0	3	1	13	3	10
	588	NDP	Pregnant	116	77	12	115	88	76	66	23	16	6
	6	NDP	NDP	0	3	1	1	0	0	1	0	0	0
<b>Non-pregnant cows:</b>	1	Pregnant	Pregnant	0	0	0	0	0	0	0	1	0	0
	0	Pregnant	NDP	0	0	0	0	0	0	0	0	0	0
	2	NDP	Pregnant	0	0	0	1	0	0	1	0	0	0
	127	NDP	NDP	9	15	5	24	3	0	7	18	42	4

**Table 3.5: Values for correct pregnant (a), incorrect pregnant (b), correct non-pregnant (c), incorrect non-pregnant (d), sensitivity, specificity, and positive (PPV) and negative (NPV) predictive values for the two methods:**

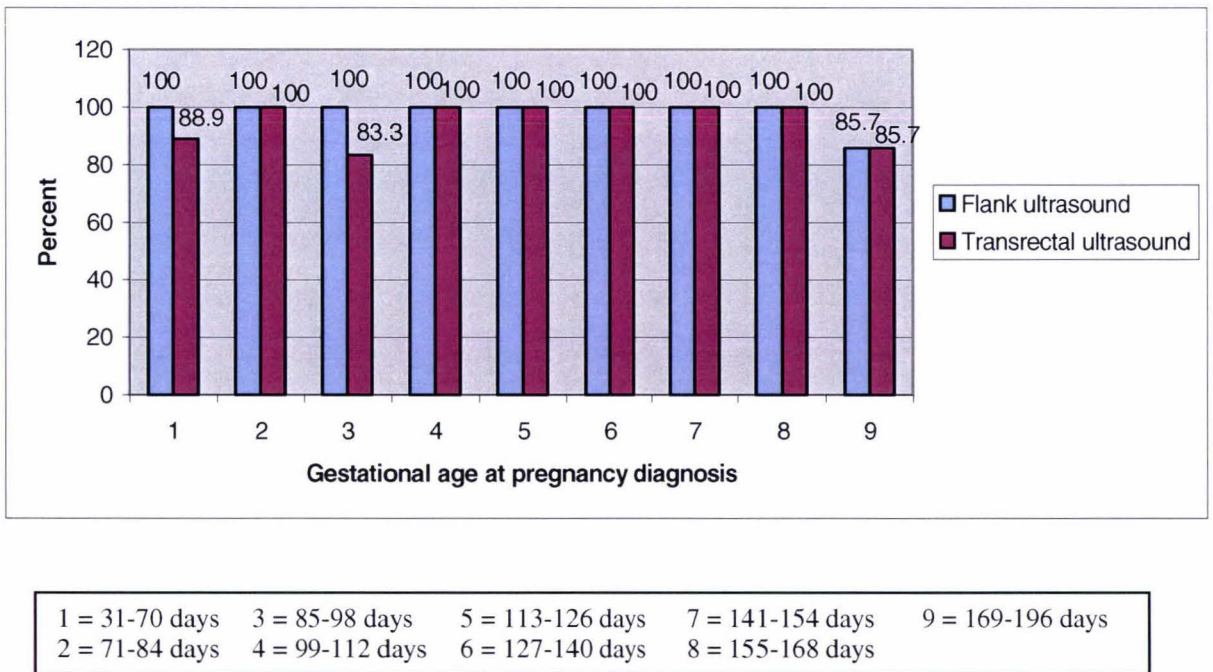
<b>Method:</b>	<b>a</b>	<b>b</b>	<b>c</b>	<b>d</b>	<b>Sensitivity:</b>	<b>Specificity:</b>	<b>PPV:</b>	<b>NPV:</b>
Rectal ultrasound:	1379	3	54	127	96.24	97.70	99.85	70.16
Flank ultrasound:	839	1	594	129	58.55	99.20	99.80	17.84

**Table 3.6: Values for a, b, c, d, sensitivity, specificity, positive (PPV) and negative (NPV) predictive values for each gestational stage**

<b>Gestational Stage (days):</b>	<b>Method:</b>	<b>a</b>	<b>b</b>	<b>c</b>	<b>d</b>	<b>Sensitivity:</b>	<b>Specificity:</b>	<b>PPV:</b>	<b>NPV:</b>
<b>37-70</b>	47 cows: 39 pregnant, 9 non-pregnant								
	<b>Rectal ultrasound</b>	36	1	8	2	94.7%	88.9%	97.3%	80.0%
	<b>Flank ultrasound</b>	3	0	9	35	7.9%	100.0%	100.0%	20.5%
<b>71-84</b>	65 cows: 59 pregnant, 6 non-pregnant								
	<b>Rectal ultrasound</b>	59	0	6	0	100.0%	100.0%	100.0%	100.0%
	<b>Flank ultrasound</b>	4	0	6	55	6.8%	100.0%	100.0%	9.8%
<b>85-98</b>	128 cows: 121 pregnant, 7 non-pregnant								
	<b>Rectal ultrasound</b>	120	1	5	2	98.4%	83.3%	99.2%	71.4%
	<b>Flank ultrasound</b>	23	0	6	99	18.9%	100.0%	100.0	5.7%
<b>99-112</b>	211 cows: 200 pregnant, 11 non-pregnant								
	<b>Rectal ultrasound</b>	197	0	11	3	98.5%	100.0%	100.0%	78.6%
	<b>Flank ultrasound</b>	63	0	11	137	31.5%	100.0%	100.0%	7.4%
<b>113-126</b>	331 cows: 323 pregnant, 8 non-pregnant								
	<b>Rectal ultrasound</b>	312	0	8	11	96.6%	100.0%	100.0%	42.1%
	<b>Flank ultrasound</b>	173	0	8	150	53.6%	100.0%	100.0%	5.1%
<b>127-140</b>	340 cows: 332 pregnant, 8 non-pregnant								
	<b>Rectal ultrasound</b>	322	0	8	10	97.0%	100.0%	100.0%	44.4%
	<b>Flank ultrasound</b>	237	0	8	95	71.4%	100.0%	100.0%	7.6%
<b>141-154</b>	176 cows: 175 pregnant, 1 non-pregnant								
	<b>Rectal ultrasound</b>	170	0	1	5	97.1%	100.0%	100.0%	20%
	<b>Flank ultrasound</b>	156	0	1	19	89.1%	100.0%	100.0%	5%
<b>155-168</b>	50 cows: 45 pregnant, 5 non-pregnant								
	<b>Rectal ultrasound</b>	44	0	5	1	97.8%	100.0%	100.0%	83.3%
	<b>Flank ultrasound</b>	45	0	5	0	100.0%	100.0%	100.0%	100.0%
<b>169-196</b>	149 cows: 142 pregnant, 7 non-pregnant								
	<b>Rectal ultrasound</b>	122	1	6	20	85.9%	85.7%	99.2%	23.1%
	<b>Flank ultrasound</b>	139	1	6	3	97.9%	85.7%	99.3%	66.7%



**Figure 3.2:** Sensitivity of transrectal and flank ultrasound according to age at pregnancy diagnosis (days)

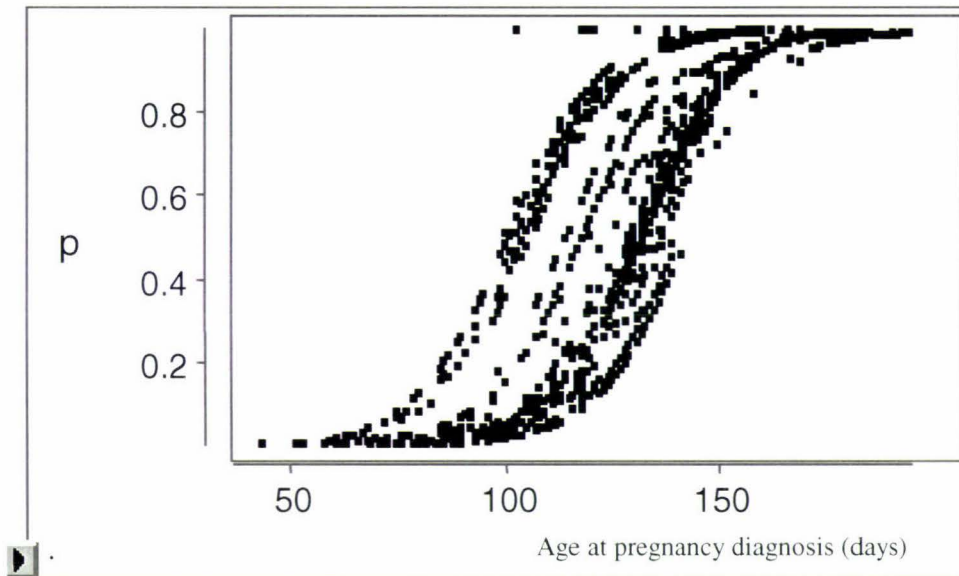


**Figure 3.3:** Specificity of transrectal and flank ultrasound according to age at pregnancy diagnosis (days)

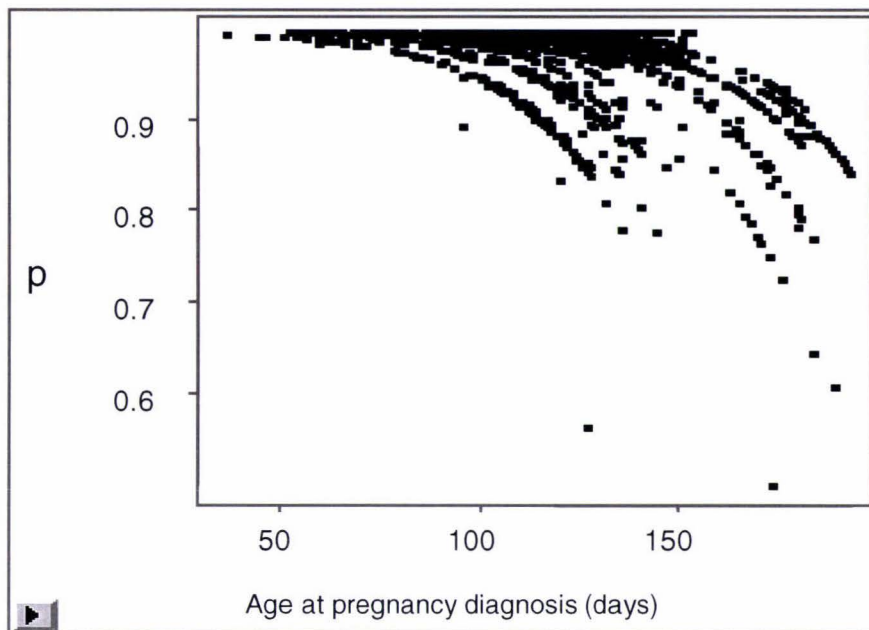


### 3.3.3.2 Probability curves:

Figure 3.4 and 3.5 illustrates the probability of a correct diagnosis of an animal's pregnancy status by flank or transrectal ultrasound respectively. There is a significantly high probability of making a correct diagnosis ( $p < 0.0001$ ) from 155 days of gestation onwards. An odds ratio of 1 for the flank ultrasound probability curve occurs at 114 days indicating that after this gestational age there is a greater than 50% probability of making a correct diagnosis. The probability of making a correct diagnosis using transrectal ultrasound is relatively high to 130 days of gestation but progressively falls with increasing gestational age.



**Figure 3.4:** The probability of a correct diagnosis of pregnancy status ( $p$ ) using transcutaneous flank ultrasound according to gestational age at pregnancy diagnosis (days)



**Figure 3.5:** The probability of a correct diagnosis of pregnancy status ( $p$ ) by transrectal ultrasound according to gestational age at date of pregnancy diagnosis (days)

### 3.3.3.3 Herd

Ten herds were involved in this study and were pregnancy tested over three months between the 14<sup>th</sup> March 2003 and 16<sup>th</sup> May 2003. The effect of herd was significant in the determination of a correct diagnosis of pregnancy status by flank ultrasound ( $p < 0.0001$ ), but was not significant for transrectal ultrasound ( $p > 0.6$ ).

### 3.3.3.4 Method of flank ultrasound diagnosis:

The method of flank ultrasound pregnancy diagnosis using flank ultrasound was known for 1498 cows. 1109 cows, or 67.3% of the total, were pregnancy tested while the operator stood on a set of planks in a Herringbone shed, 296 (19.8%) cows were pregnancy tested from the pit of a Herringbone shed and 193 (12.9%) were pregnancy tested from the right

side of a vet or artificial insemination (AI) race. The effect of method of pregnancy diagnosis approached significance ( $p = 0.1328$ ) in determining the probability of a correct diagnosis of pregnancy status.

#### **3.3.3.5 Comparison of cow breeds:**

The breed was known for a total of 1420 cows. Over one-third were pure Friesians (588, 41.4%) or Friesian/Jersey crossbreds (504, 35.4%). Pure Jerseys and Ayrshire or Ayrshire crosses accounted for 19.6% (279) and 3.4% (49) respectively. The breed of the remaining 79 cows was unknown and was not included in this section of the analysis. Breed had no significant effect on the probability of a correct diagnosis of pregnancy status by either the transrectal or flank ultrasound method ( $p > 0.3$ ) and there was no significant difference between pure Friesians or Friesian/Jersey crosses and pure Jerseys ( $p > 0.3$ ).

#### **3.3.3.6 Comparison of cow age:**

The age was known for a total of 1468 cows and ranged from first-calving 2 year old heifers to 14 year olds. Approximately 10% were heifers but comparison between heifers and mature cows (ie: greater than 3 years of age) was not significant in the determination of a correct diagnosis of pregnancy status by either the transrectal or flank ultrasound methods ( $p > 0.3$ ).

#### **3.3.3.7 Comparison of sire breed:**

The sire breed was known for a total of 1329 pregnancies. Over one-third consisted of either pure-bred Friesians (592, 44.5%) or pure-bred Jerseys (498; 37.5%). The remaining bulls were beef breeds (ie: Hereford, Hereford crossbred or Angus) (239; 18.0%) and 170 sires were of unknown breed. Sire breed was not significant in the determination of a correct diagnosis of pregnancy status by flank ultrasound but was significant when pregnancy



was diagnosed by transrectal ultrasound ( $p = 0.0252$ ) (pure-bred Friesian = 0.0087; pure-bred Jersey = 0.0502; Beef breeds = 0.4324). The effect of bull breed became insignificant, however, when the herd effect was removed from the analysis.

### **3.3.3.8 Comparison of calf sex:**

The sex of the calf at birth was known for 1361 pregnancies and 138 were unknown. Over half of the calves were male (755; 55.5%) and just under half were female (606; 44.5%). The sex of the calf was not significant in the probability of a correct diagnosis of pregnancy status by either transrectal or flank ultrasound ( $p > 0.3$ ).

### **3.3.3.9 Comparison of veterinarians:**

In Herd 6, due to time constraints, rectal ultrasound and manual palpation *per rectum* were completed by veterinarian B on the planks while flank ultrasound was performed simultaneously by veterinarian A from the pit. The sensitivity and specificity values were 100% for both veterinarians with complete agreement in the pregnancy status of every animal in the herd, whether pregnant or non-pregnant. The rectal ultrasound results from Herd 6 as completed by veterinarian B were therefore included in the analysis as comparable to veterinarian A.

## **3.4 Discussion:**

The incorrect diagnosis of a pregnant cow as non-pregnant will result in a significant economic waste due to pregnant cows being sent for slaughter. Pregnant cows will also be sent to grazing without the necessary management through the dry period, resulting in a relatively high number of dystocias and metabolic diseases. On average, 13.6% of the New Zealand dairy herd is culled each year with the predominant reason for cull selection being perceived infertility (Holmes *et al.*, 2003). In a 1995 abattoir study in the UK, of the 23.5% of cattle that were pregnant at slaughter, the herdowner believed over half (50.9%) were not pregnant (Singleton and



Dobson, 1995). A 1975 study of the culling policy of extensive Australian beef herds found 62.9% of cows examined were pregnant at slaughter and, in herds not undertaking pregnancy diagnosis, this rate increased to 71.6% of slaughtered cows (Ladds *et al.*, 1975). Although herds which had undergone pregnancy diagnosis had significantly lower levels (16.6% to 41.8%), a sizeable number of pregnant cows were 3 to 6 months in calf, indicating the sensitivity of the pregnancy test at this stage of gestation was, in some instances, not sufficiently accurate (Ladds *et al.*, 1975).

The incorrect diagnosis of a non-pregnant cow as pregnant is also of concern to the herdowner as these animals are retained on-farm, utilizing pasture and resources with little to no gain.

#### **Transcutaneous flank ultrasound pregnancy diagnosis:**

To the author's knowledge, there have been no comprehensive studies of the accuracy of transcutaneous ultrasound over the right flank in dairy or beef cattle. Sensitivity values of 100% using the flank ultrasound technique in red deer has been demonstrated in numerous studies, with the fetus able to be clearly visualized from 40-50 days of gestation (Mulley *et al.*, 1987; White *et al.*, 1989). White *et al.* (1984) found pregnancy diagnosis by transcutaneous ultrasound in sheep was 99% accurate between 50-100 days of gestation. There was also a significant association ( $p < 0.005$ ) between the number of lambs born and the number of fetuses observed in utero by this method with a 100% sensitivity in ewes carrying a single fetus and 97.3% in ewes carrying twins (White *et al.*, 1984; Gearhart *et al.*, 1988). Lower sensitivity values were found for transcutaneous ultrasound in does with 82% in does carrying a single fetus and 100% for does carrying triplets, but a lower frequency 5 MHz transducer was used. A 3.5 MHz linear transducer applied to the flank and ventral abdomen of the sow also resulted in a sensitivity of 99% (Jackson, 1986).

The probability of a correct diagnosis of pregnancy status using flank ultrasound for all cows over the gestational period of 37-198 days in this study was significantly lower ( $p < 0.0001$ ) than that of transrectal ultrasound. The sensitivity value of flank ultrasound increased in a linear fashion with increasing gestational age, however, reaching a plateau at 155 days of gestation. Between 155-198 days of gestation, flank ultrasound was more accurate in the correct diagnosis of pregnancy status in comparison to transrectal ultrasound which had a sensitivity of only 85.9% after 168 days of gestation. Although the negative predictive value of flank ultrasound was extremely low prior to 155 days, averaging 8.7%, it also increased markedly after this gestational age (83.4%).

The specificity of the flank ultrasound method was extremely accurate throughout the gestational range of 37-198 days as only one animal was falsely diagnosed as pregnant while non-pregnant. The structures visible via ultrasound over the right flank in the non-pregnant animal (ie: small intestinal loops) cannot be easily misdiagnosed as a pregnancy, in comparison to transrectal ultrasound where the bladder, uterine vessels and ovaries can resemble a pregnancy to the unexperienced operator.

The gravid horn will generally remain within the pelvic cavity prior to 90 days of gestation. After approximately 120-150 days of gestation, however, increasing fetal weight and fetal fluid volume cause the pregnant uterus to pass over the cranial pelvic brim and towards the dam's ventral abdominal wall (Arthur *et al.*, 1982). The uterus can either pass through the supraomental recess, between the right face of the rumen and the greater omentum, against the right flank directly or less frequently against the left flank, displacing the intestines or rumen respectively from the abdominal wall (Dyce *et al.*, 1996). As the depth of a 3.5 MHz sector transducer is generally limited to 15 cms, early bovine pregnancies cannot be visualized by transcutaneous ultrasound over the right flank. During mid gestation, however, the uterus passes to within range of the transducer and pregnancy



is more likely to be visualized. Although only a minority of pregnancies lie against the dam's left flank, it could be assumed they would be impossible to visualize throughout pregnancy when scanning from the right flank, due to the intervening intestines and rumen.

Herd was a significant effect in the determination of a correct diagnosis of pregnancy status by flank ultrasound. Although there was a significant association between herd and gestational age at pregnancy diagnosis (days), this result also represents the effect of increasing operator experience. Fowler (1984) found the accuracy of inexperienced operators using the flank ultrasound method in sheep improved significantly after only one session with an experienced operator.

The method of flank ultrasound pregnancy diagnosis approached significance in the determination of a correct diagnosis of pregnancy status. Increased pressure can be applied upwards against the flank skin when the operator is scanning from the pit of a Herringbone shed, allowing the visualization of pregnancies located within the caudodorsal abdomen. An operator located at cow level, such as on the planks or beside the vet/AI race, needs to bend from the waist before applying the transducer to the flank making visualization of these earlier pregnancies more difficult.

In a 1984 study of the accuracy of transcutaneous pregnancy diagnosis in sheep, Fowler found Merino ewes were diagnosed less accurately than twin-bearing Dorset-Merino cross ewes and more accurately than Border Leicester-Merino cross ewes. Although these apparent breed effects were without obvious explanation, anatomical features of the differing breeds such as wool follicle density and structure, thickness and nature of the skin and associated tissue layers of the abdomen were believed to have affected the accuracy of the technique (Fowler, 1984). In older, obese and/or multigravid animals, where the non-pregnant uterus can be found lying cranial to the pelvic brim, it could be assumed that the pregnant uterus

would be visualized at an earlier gestational age via flank ultrasound. There was no statistically significant association, however, between maternal age or breed and the probability of making a correct diagnosis of pregnancy status. Similarly, there was no significant association between bull breed or calf sex and a correct diagnosis of pregnancy status when using transcutaneous ultrasound across the right flank.

### **Transrectal ultrasound diagnosis:**

This study confirms the value of pregnancy diagnosis via transrectal ultrasound in cattle. The overall sensitivity of transrectal ultrasound in this study (96.2%) was comparable to previous studies, particularly between 70-168 days of gestation (Chauffaux *et al.*, 1988 Pieterse *et al.*, 1990; Szenci *et al.*, 1995, Nation *et al.*, 2003). The sensitivity of transrectal ultrasound in the earliest gestational age period of 37-70 days (94.7%) was low in comparison to the results of previous studies completed within 70 days post-insemination, in particular Szenci *et al.* (1996) and Hanzen and Laurent (1991) who achieved 100% and 97% respectively. The sensitivity of transrectal ultrasound when undertaken less than 33 days post-insemination in previous studies tends to be, on average, lower, ranging from 38.1% to 97.7% (Pieterse *et al.*, 1990; Szenci *et al.*, 1996). Possible explanations given for the low sensitivity values found during early pregnancy have included a difficulty in visualizing the filamentous bovine amniotic vesicle, the caudal intrapelvic uterine position in early pregnancy and the frequency of the transducer used (Szenci *et al.*, 1996; Pieterse *et al.*, 1990; Szenci *et al.*, 1995; Hanzen and Laurent, 1991; Hanzen and Delsaux, 1987; Badtram *et al.*, 1991; Willemse and Taverne, 1989). The low sensitivity seen at 37-70 days of gestation in this study should not, however, have been as dependant on these factors particularly as a high frequency, 7.5 MHz transducer was used. Operator experience may have contributed to this lower sensitivity value as this study was completed in the operator's second year of pregnancy testing by transrectal ultrasound.



The lowest sensitivity of transrectal ultrasound in this study was found from 168-198 days of gestation (85.9%). Movement of the bovine fetus towards the dam's ventral abdominal wall and therefore out of range of the ultrasound beam would have contributed to this relatively low value. Kahn (1989), using a 3.5 MHz sector transducer, however, found a fetal head, thorax or abdomen was accessible for 80% of pregnancies, with the only exceptions confined to Months 8 to 10 of pregnancy. This study was completed on heifers, however, which generally have increased uterine tone relative to older, multiparous animals. Kahn's (1989) result could not be replicated in one of the few studies which have investigated the sensitivity of transrectal ultrasound in cattle over 70 days of gestation. White *et al.* (1985), using a 3.5 MHz transducer, found an overall sensitivity of 98.8% when pregnancy testing cattle between 92-202 days of gestation. Although the effect of increasing gestational age on this sensitivity value was not discussed, the author found the fetus could not be imaged beyond 120 days of gestation.

The specificity of 97.7% for transrectal ultrasound found in this study was comparable to previous studies (Hanzen and Delsaux, 1987; Szenci *et al.*, 1995; Szenci *et al.*, 1996). Although the overall specificity value for transrectal ultrasound was lower in comparison to flank ultrasound, only 3 animals were falsely diagnosed as pregnant when non-pregnant. Conditions which cause abnormal fluid accumulation, such as pyometra, mucometra and hydrometra can resemble an early pregnancy via transrectal ultrasound (Bretzlaff, 1993). Naturally occurring early embryonic loss, which has been estimated to vary between 9-28% in cows with normal fertility and up to 60% in repeat breeder cows, may have also contributed to this relatively lower specificity value (Forar *et al.*, 1995).

The possible effect of cow breed, calf sex and bull breed were not statistically significant in the determination of a correct diagnosis of pregnancy status by transrectal ultrasound.

Mulley *et al.*, (1987) found a transcutaneous scan in order to diagnose pregnancy could be completed in red deer within 60 seconds of restraint. Haibel (1988) found pregnant does could be differentiated from open does within 5-30 seconds using transcutaneous ultrasound and some operators can pregnancy test up to 300 sheep per hour in a specially designed chute for transabdominal scanning (Buckrell, 1988). Although the average time taken to complete each transcutaneous study was not calculated in this study, the author found a bovine pregnancy could generally be visualized as fetal parts, fetal fluids, fetal membranes and/or placentomes within seconds of placement of the transducer against the abdominal skin.

Due to time constraints, this study did not complete flank and transrectal ultrasound diagnosis of pregnancy after 198 days of gestation. Haibel and Fung (1991) found visualization of the llama fetus became particularly difficult in the last trimester of gestation due to the posture of the fetus and the limited penetration of the 5 MHz transducer. Although the 3.5 MHz transducer used in this study allows greater penetration into the abdomen, visualization of recognisable fetal parts may also be difficult in the cow in late gestation. Diagnosis of pregnancy, however, should not be difficult at this gestational stage as the bovine uterus generally maintains contact with the right abdominal wall throughout late gestation until parturition.

The twinning rate of dairy cattle increases from an average of 1% in first calving heifers to approximately 8% for all subsequent calvings, particularly in cows over 7 years of age (Ryan and Boland, 1991). McMillan *et al.* (1994) found transrectal ultrasound imaging to Day 60 of gestation was not an accurate technique for determining the twin pregnancy status in cattle, with an accuracy ranging from 20%-52%. Lambert *et al.* (1998), however, found an accuracy of 74-94% with no difference between cows carrying single calves or twins. As only four sets of twins were born to this study's animals, a statistical analysis of the accuracy of twin pregnancy diagnosis

by flank ultrasound was not possible. The placental anastomoses characteristic of bovine twin pregnancy, however, was readily visible via flank ultrasound.

### **3.5 Conclusion:**

This study found a higher overall probability of a correct diagnosis of pregnancy status in cattle when using transrectal ultrasound in comparison to transcutaneous ultrasound over the right flank. Flank ultrasound could not be recommended as an accurate method for early pregnancy diagnosis. At less than 155 days, flank ultrasound has a lower sensitivity and probability of a correct diagnosis of pregnancy status in comparison to transrectal ultrasound. After 155 days of gestation, however, flank ultrasound is the more accurate technique and represents an accurate method of pregnancy diagnosis for cows in mid to late gestation, such as possible cull cows, beef cows, and obese and/or multigravid cattle.

Flank ultrasound is an easy and rapid technique to learn and utilize. One possible limitation, however, is the cost of ultrasound equipment. The majority of New Zealand veterinary practices which service a reasonable number of dairy farms have purchased and are actively using an ultrasound scanner, however, for transrectal ultrasound pregnancy diagnosis. Although flank ultrasound would not be recommended for whole herd diagnosis, unless the average gestational age is known to be 150-155 days, the use of this technique in individual animal or small mob pregnancy testing while the animals were in mid to late gestation would be worthwhile.





**CHAPTER 4:**  
**MEASUREMENT OF FETAL CHARACTERISTICS IN  
ORDER TO DETERMINE THE LENGTH OF  
GESTATION AT DATE OF PREGNANCY DIAGNOSIS  
BY TRANSCUTANEOUS ULTRASOUND OVER THE  
RIGHT FLANK**

**4.1 Introduction:**

The accurate detection of pregnancy in both beef and dairy herds is essential for the maintenance of high levels of reproductive efficiency and accurate ageing of these pregnancies allows for management decisions such as the early induction of cows calving late in the season (White *et al.*, 1985). The measurement of bovine fetal anatomical characteristics in order to estimate the age of pregnancy has previously only been reported for aborted and post mortem fetuses (Maneely, 1942; Winters, 1942; Rexroad *et al.*, 1973; Thomsen, 1974, Eley *et al.*, 1977). This process has recently been refined, however, by the development of manual palpation *per rectum* and transrectal ultrasound.

Manual palpation *per rectum* is most accurate between 35 and 65 days of gestation and fetal age estimation curves developed by White *et al.*(1985), based on the transrectal ultrasound measurement of such fetal characteristics as crown-rump length, head diameter and trunk diameter, are of limited accuracy after approximately 120 days (Honey, 1998). During mid-gestation, the fetus passes over the cranial pelvic brim and towards the dam's ventral abdominal wall, and out of range of either the palpating hand or a transrectal ultrasound beam (White *et al.*, 1985; Kahn, 1989). The operator must often base a diagnosis of pregnancy at this stage on either the detection of fremitus or the visualization of uterine fluid and/or placentomes, neither of which can be used to accurately determine gestational age.

An accurate and relatively convenient method to age pregnancy after this stage of gestation would be useful for both the veterinarian in both routine herd and individual animal pregnancy diagnosis, and would allow the herdowner greater knowledge when deciding the future of cows at this stage of pregnancy.

## **4.2 Materials and Methods:**

### **4.2.1 Pregnancy diagnosis:**

The pregnancy status of 225 spring calving cows from three herds in the Whangarei area was established using methods as outlined in Chapter 3. These herds were chosen on the basis of:

- being long-standing clients of Whangarei Veterinary Services
- a history of annually presenting their entire herd for transrectal ultrasound pregnancy diagnosis
- availability of a herring-bone dairy or vet/AI race
- a history of herd testing on a regular basis
- accurately recording their farm data using the MindaLINK or MindaPRO systems, as provided by the Livestock Improvement Corporation (LIC).

Pregnancy diagnosis by transcutaneous ultrasound over the right flank was carried out between 57 to 195 days of gestation using an ALOKA® SSD-500 machine. A 3.5 MHz sector transducer was positioned against the skin of the right flank, dorsal to the udder and underneath the flank fold of the cow or heifer, either held in the operator's hand or taped to a stainless steel "extender". The penetration depth of the transducer was approximately 15 cms. The probe was initially placed centrally under the flank fold and then directed caudally and cranially along the dorsal udder line to identify earlier and more advanced pregnancies, respectively. Lubricant was used to facilitate contact between the probe and the skin. No hair removal, skin preparation, roping or additional holding devices were used.

Cow age varied between 2 to 14 years (see Figure 4.1). Almost half of the cows were Holstein-Friesians (44.2%), with the remaining cows were either pure Jersey (27.6%), Jersey/Friesian cross (24.1%) or a beef breed (4.9%). Bull breeds included pure Friesians (91; 40.2%); pure Jersey (77; 34.0%) and Hereford/Angus (58; 25.8%), while over half of the calves were male (127; 55.9%), 38.3% were female and the sex of the remaining calves was unknown (13; 5.7%).

<b>Cow age:</b>	<b>Number and frequency:</b>
2	15 (6.6%)
3	28 (12.3%)
4	22 (9.7%)
5	37 (16.3%)
6	20 (8.8%)
7	33 (14.5%)
8	20 (8.8%)
9	22 (9.7%)
10	8 (3.5%)
11	4 (1.7%)
12	8 (3.5%)
13	5 (2.2%)
14	1 (0.4%)
unknown	4 (1.7%)

**Figure 4.1:** The number and frequency scanned by transcutaneous ultrasound for fetal ageing

The determination of a gold standard result for cows remaining on-farm, cull cows and sold cows and the determination of conception dates for cows with full-term pregnancies, induced or premature calvings was undertaken using the same materials and methods as described in Chapter 3.

#### **4.2.2 Estimation of fetal age:**

Each scan was recorded in real-time directly onto video tape on a Panasonic VHS video player. All animals were identified by an ear tag number which was typed on screen previous to each scan to allow future identification. All scans were individually loaded onto a PC using the AverCap Version 2.3 program (AverMedia Technologies Inc., Copyright 2000) and then onto



compact disc. Each scan was examined on an individual basis to establish possible characteristics to be used for fetal ageing and to measure each characteristic based on a set scale present on the ALOKA ultrasound machine.

#### 4.2.3 Statistical analysis:

The principal measurements made were (see Figure 4.2):

1. **thoracic diameter:** greatest diameter between the lateral extremities of the rib cage (ie: between the vertebrae and sternum) where the heart is clearly visible.
2. **abdominal diameter:** greatest diameter between the lateral extremities of the abdomen where the anechoic rumen was clearly visible.
3. **umbilical diameter:** the greatest diameter of either a cross-sectional or longitudinal view of the umbilical cord within the amnion
4. **placentome height:** The greatest distance from the base of the placentome at the placenta to the placentome pole
5. **placentome length:** The greatest distance from one lateral pole of the placentome to the opposite lateral pole

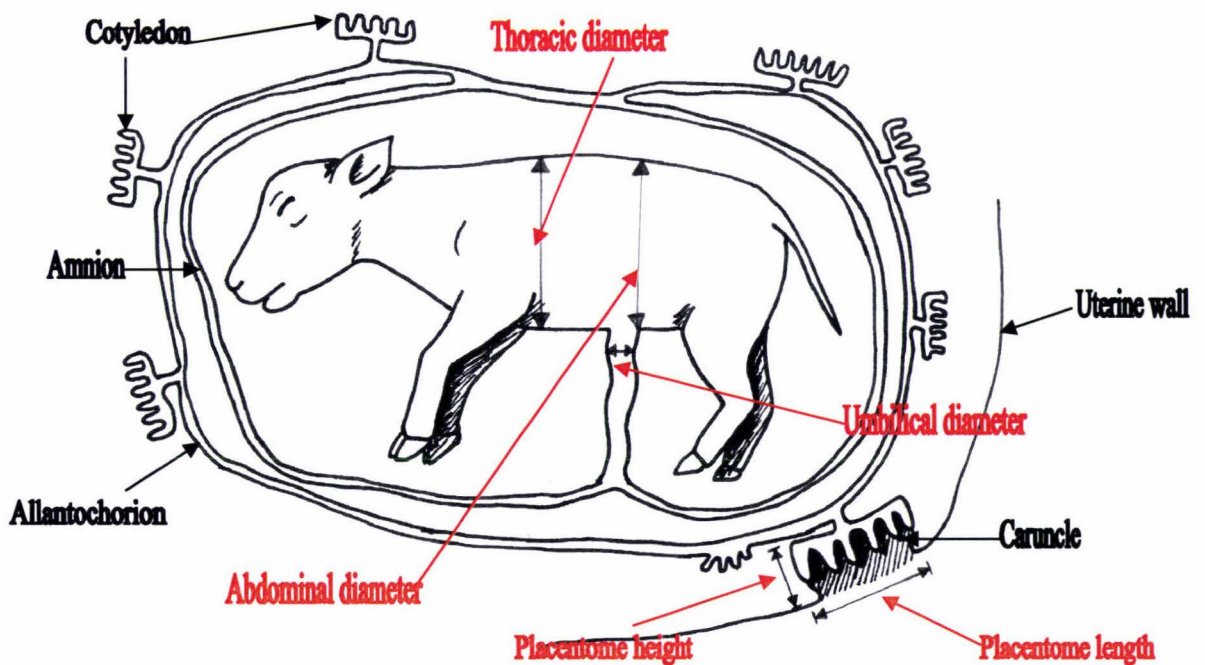


Figure 4.2: Principal fetal and placentome measurements



Relationships between gestational age and the measurements recorded were derived using regression analysis with respect to fetal thoracic diameter, umbilical diameter, abdominal diameter, placentome height and placentome length (SAS, 2000).

### 4.3 Results:

Figure 4.3 illustrates the number of observations made of each measurement, and the relative accessibility of each measurement to the total number of animals available. Placentome height and length were visualized most frequently (64.4%) and umbilical diameter least frequently (20.8%).

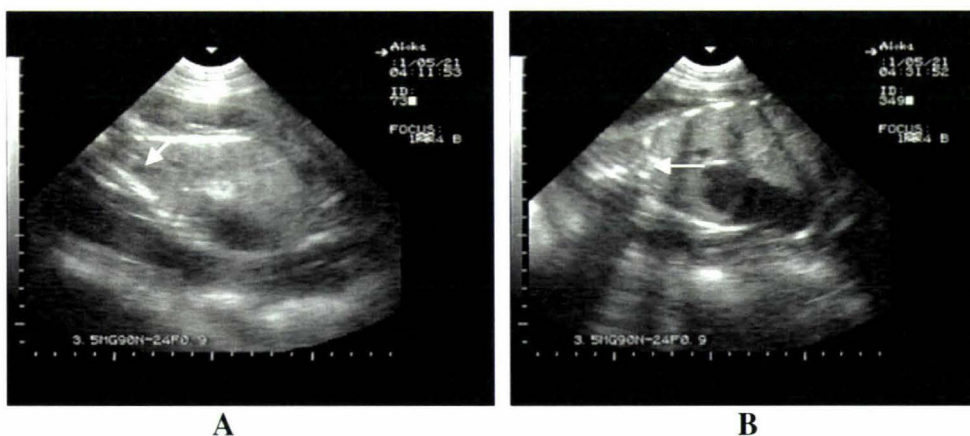
Measurement:	Number:	Percent of total:
Thoracic diameter:	49	21.7%
Abdominal diameter:	107	47.5%
Umbilical diameter:	47	20.8%
Placentome height:	145	64.4%
Placentome length:	145	64.4%

**Figure 4.3:** The number and relative accessibility of each measurement relative to the total number of animals available

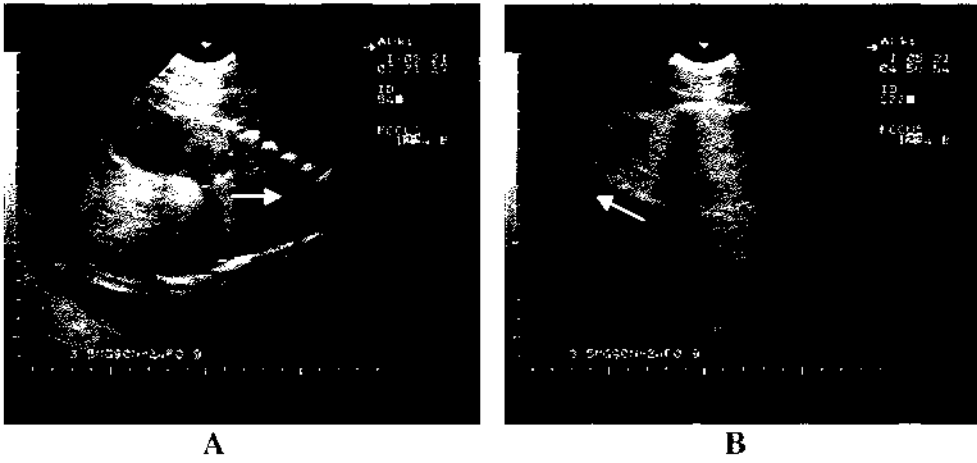
#### 4.3.1 THORACIC DIAMETER:

##### Images of thoracic diameter with increasing gestational age:

Transcutaneous scans of increasing thoracic diameter with gestational age are illustrated in figures 4.4 and 4.5.



**Figure 4.4:** Thoracic diameter at 89 days of gestation (A) and 107 days of gestation (B). Heart shown (white arrows)



**Figure 4.5:** Thoracic diameter at 127 days of gestation (**A**) and 153 days of gestation (**B**). Heart shown (white arrows)

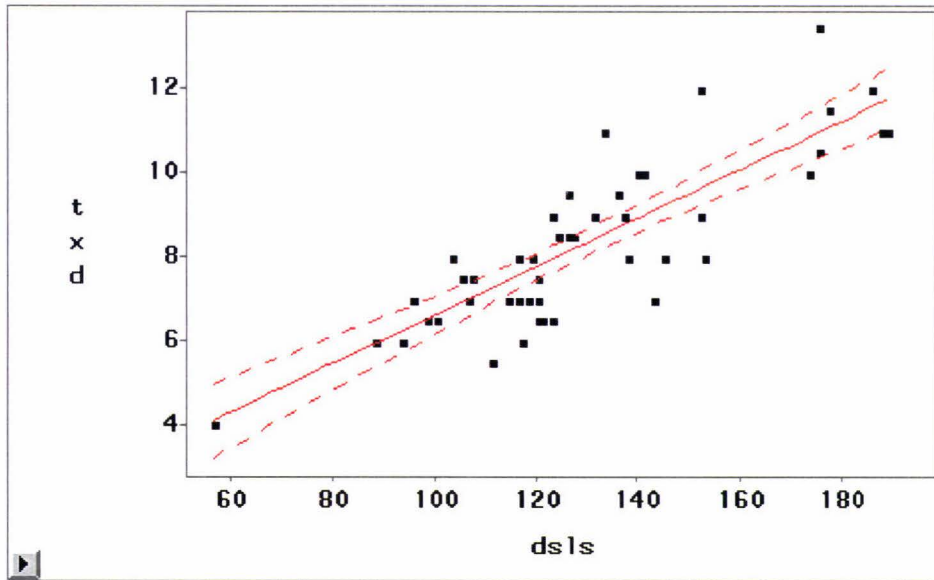
Effect:	F-value:	p-value:
N = 49		
Cow age:	0.79	0.3808
Cow breed:	1.76	0.1709
Bull breed:	0.82	0.4460
Calf sex:	0.10	0.9028
Age at PD:	19.12	<0.0001

**Figure 4.6:** The significance of possible effects on fetal thoracic diameter

Thoracic diameter was measured in 49 animals between 57 and 190 days of gestation. The regression of thoracic diameter (td) of the fetus on gestational age (d) was described by the following equation:

$$td \text{ (cm)} = 0.0577d (+/- 0.0056)$$

as determined by linear regression. Only gestational age at pregnancy diagnosis was significant ( $p < 0.001$ ) in relation to fetal thoracic diameter, as shown in figure 4.6. Figure 4.7 illustrates the fetal estimation curve of thoracic diameter according to age at pregnancy diagnosis.

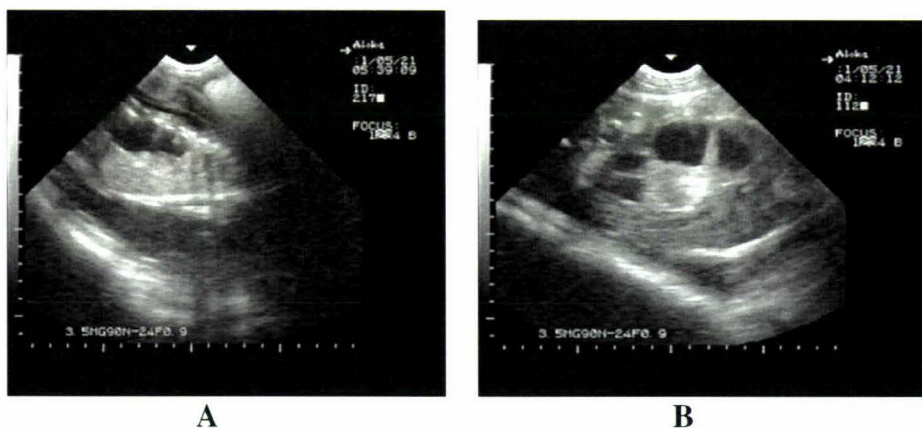


**Figure 4.7:** Foetal age estimation curve: Thoracic diameter according to gestational age at pregnancy diagnosis (days)

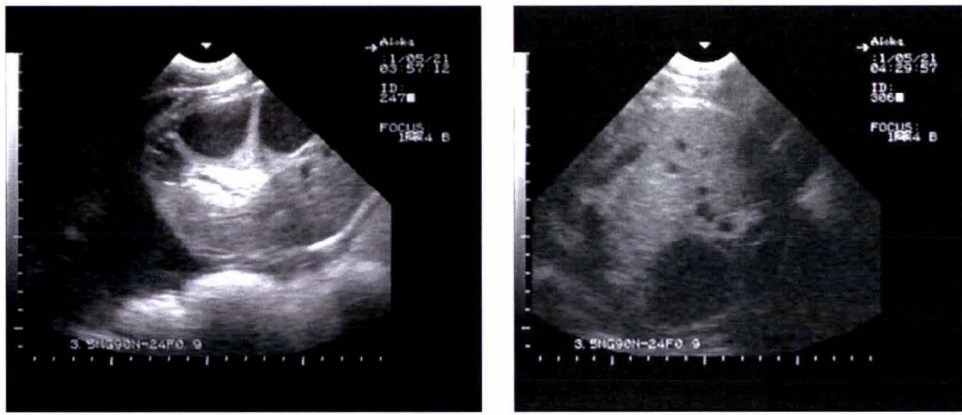
#### 4.3.2 ABDOMINAL DIAMETER:

Images of abdominal diameter with increasing gestational age:

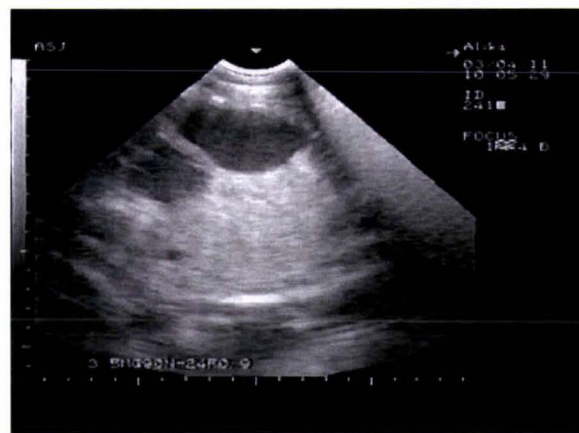Transcutaneous scans of increasing abdominal diameter with gestational age are illustrated in figures 4.8, 4.9 and 4.10.



**Figure 4.8:** Abdominal diameter at 57 days (A) and 118 days of gestation (B)



**Figure 4.9:** Abdominal diameter at 131 days (A) and 151 days of gestation (B)



**Figure 4.10:** Abdominal diameter at 183 days of gestation

Abdominal diameter was measured in 107 animals between 57 and 195 days of gestation. The regression of abdominal diameter (abd) of the fetus on gestational age (d) was described by the following equation:

$$\text{abd (cms)} = 0.0586 d^2 (+/- 0.0034)$$

as determined by quadratic regression. Gestational age at pregnancy diagnosis, cow breed and bull breed were all significant in the measurement of fetal abdominal diameter (see Figure 4.11). Figure 4.12 shows that Friesian cows and Jersey bulls had the main effect on fetal abdominal diameter.

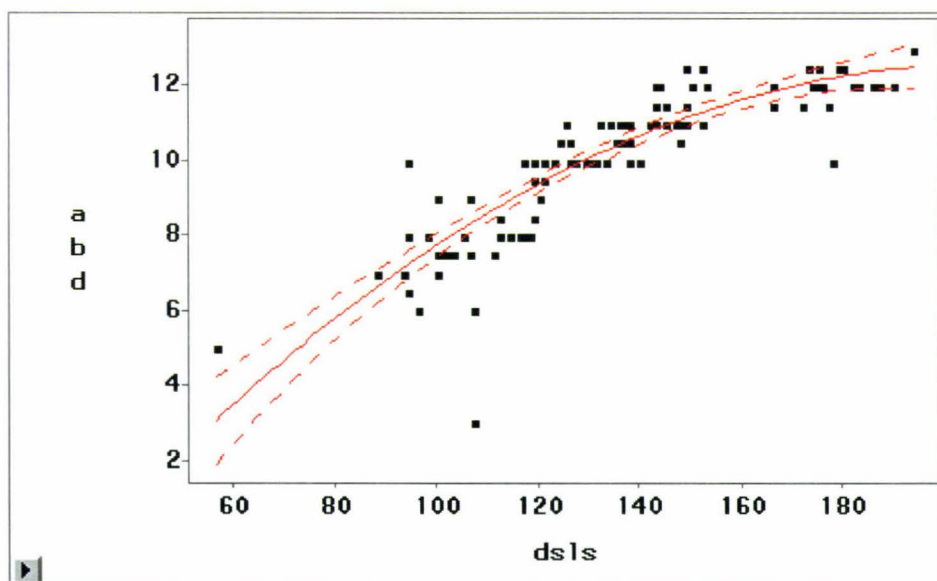


N = 107		
<b>Effect:</b>	<b>F-value:</b>	<b>p-value:</b>
Cow age:	0.98	0.3249
Cow breed:	3.15	0.0284*
Bull breed:	4.32	0.016*
Calf sex:	1.17	0.3136
Age at PD:	13.37	0.0004***

**Figure 4.11:** The significance of possible effects on fetal abdominal diameter

<b>Effect:</b>	<b>p-value:</b>
<u>Cow breed:</u>	
Friesian:	0.0037***
Jersey:	0.0639**
Jersey cross:	0.0245**
<u>Bull breed:</u>	
Friesian:	0.0115**
Jersey:	0.0045***

**Figure 4.12:** The significance of each cow and bull breed on fetal abdominal diameter

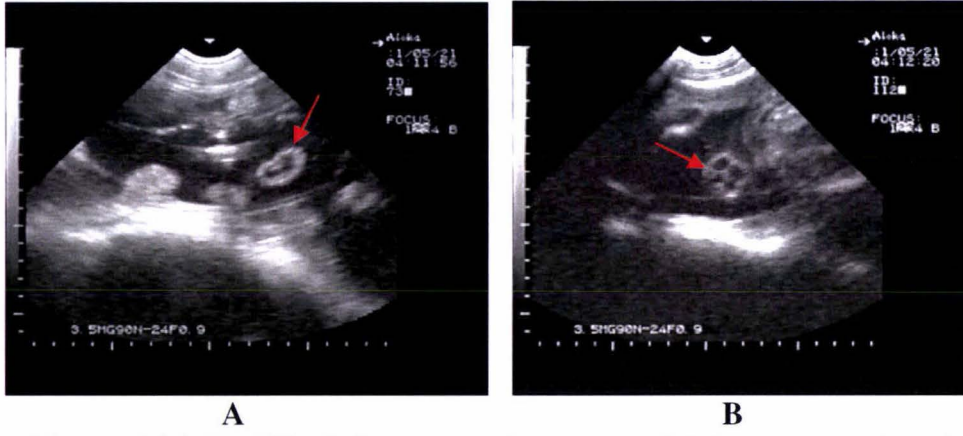


**Figure 4.13:** Fetal age estimation curve: Abdominal diameter according to gestational age at pregnancy diagnosis (days)

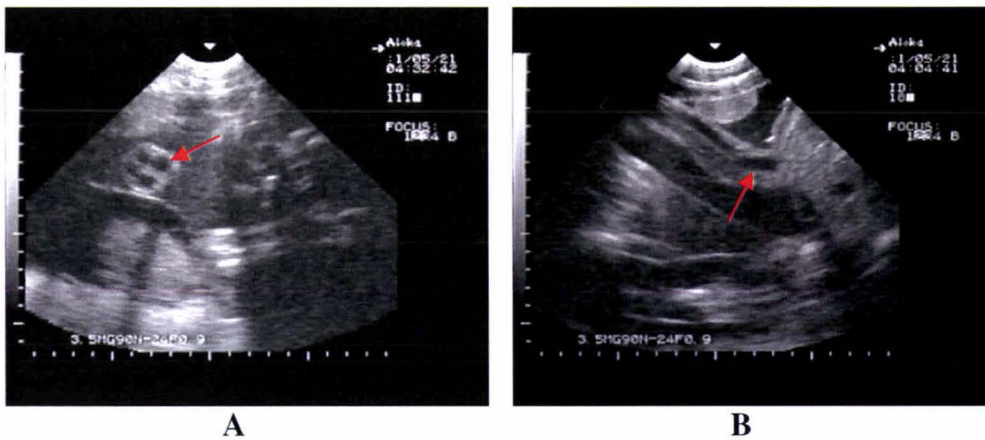
## UMBILICAL DIAMETER:

### Images of umbilical diameter with increasing gestational age:

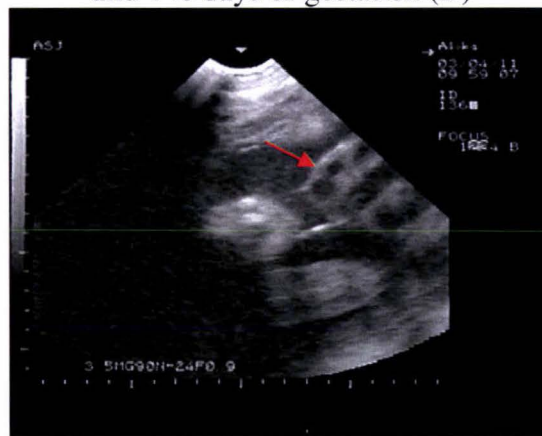Transcutaneous scans of increasing umbilical diameter with gestational age are illustrated in figures 4.14, 4.15 and 4.16.



**Figure 4.14:** Umbilical diameter (red arrows) at 89 days of gestation (A) and 118 days of gestation (B)



**Figure 4.15:** Umbilical diameter (red arrows) at 137 days of gestation (A) and 146 days of gestation (B)



**Figure 4.16:** Umbilical diameter (red arrow) at 192 days of gestation

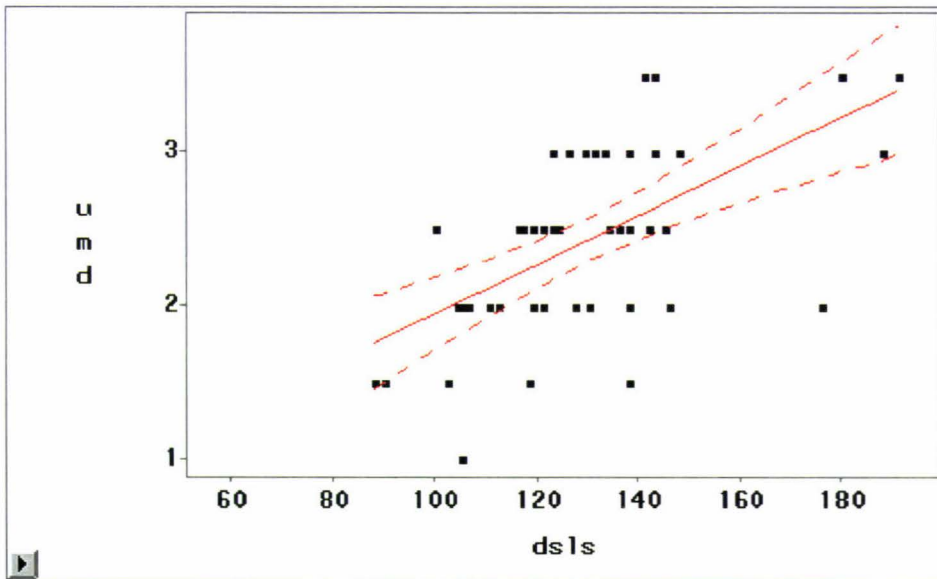
Umbilical diameter was measured in 47 animals between 89 and 192 days of gestation. The regression of umbilical diameter (umd) of the fetus on gestational age (d) was described by the following equation:

$$\text{Umd (cms)} = 0.0160 d (+/- 0.0224)$$

as determined by linear regression. Only gestational age at pregnancy diagnosis was significant in the measurement of fetal umbilical diameter (see Figure 4.17). Figure 4.18 illustrates the fetal estimation curve of umbilical diameter according to age at pregnancy diagnosis

N = 47		
<b>Effect:</b>	<b>F-value:</b>	<b>p-value:</b>
Cow age:	1.58	0.2161
Cow breed:	0.59	0.6226
Bull breed:	1.31	0.2824
Calf sex:	0.43	0.6521
Age at PD:	7.40	0.0099***

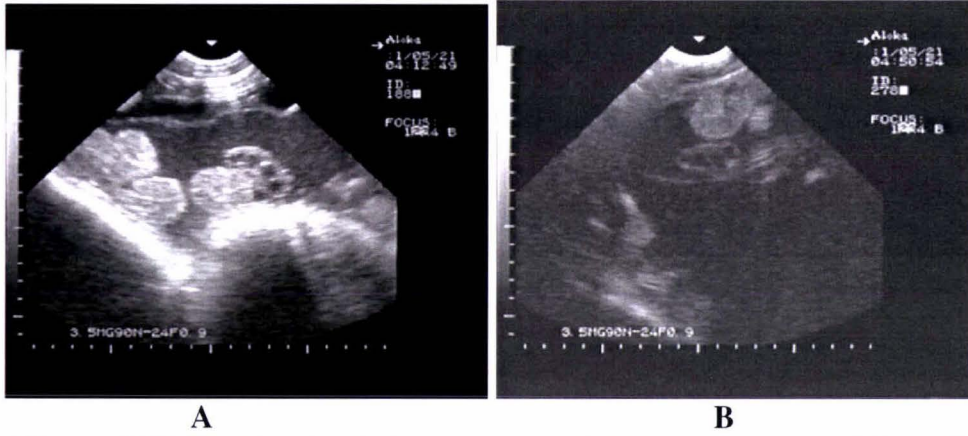
**Figure 4.17:** The significance of possible effects on fetal umbilical diameter



**Figure 4.18:** Fetal age estimation curve. Umbilical diameter according to gestational age at pregnancy diagnosis (days)

**4.3.4 PLACENTOME HEIGHT and  
4.3.5 PLACENTOME LENGTH:**

**Images of placentomes using transcutaneous ultrasound:**



**Figure 4.19:** Similar sized placentomes at 124 days of gestation (A) and 89 days of gestation (B)

Gestational age at pregnancy diagnosis was not a significant factor when measuring either placentome height or length (see Figure 4.20). Both Friesian and Hereford bull breeds were significant in the measurement of placentome height and length. The effect of bull breed became insignificant, however, once the herd effect was also removed from the analysis.

Effect:	F-value:		p-value:	
	<u>Length:</u>	<u>Height:</u>	<u>Length:</u>	<u>Height:</u>
Cow age:	0.05	0.8	0.8154	0.3733
Cow breed:	0.35	1.55	0.7914	0.2044
Bull breed:	3.04	5.33	0.0511***	0.0059***
Calf sex:	1.79	2.32	0.1712	0.1025
Age at PD:	0.04	0.64	0.8343	0.4255

Effect	p-value:	
<u>Bull breed:</u>	<u>Length:</u>	<u>Height:</u>
Friesian:	0.0478***	0.0017***
Hereford:	0.0168***	0.0098***

**Figure 4.20:** The significance of possible effects on placentome height



#### 4.4 Discussion:

Prior to the development of transrectal ultrasound, bovine fetal age was determined principally via the measurement of bodyweight and crown-rump length from postmortem and aborted fetuses (Maneely, 1942; Winters *et al.*, 1942; Nichols, 1944; Gjesdal, 1969; Rexroad *et al.*, 1973; Thomsen, 1974; Eley *et al.*, 1977). Bodyweight is highly dependant, however, on breed and breed strain making the estimation of fetal age based on this characteristic relatively inaccurate across all cattle breeds (Richardson *et al.*, 1990; Rajamahendran, 1994). Fetal age estimation curves, based on ultrasonographic fetometry, are currently available for horses, sheep, goats, deer, swine, dogs and cats as well as cattle via transrectal ultrasound (Kahn, 1992).

Studies by White *et al.* (1985), Wright *et al.* (1988) and Kahn (1989) have formed the basis of tables used by veterinarians to age bovine fetuses to approximately 120 days of gestation. Although the mean difference between the actual and predicted calving date, based on the fetal ageing equations of White *et al.* (1985), was only 0.9 days (standard deviation = 9.0 days) the authors found “it was not possible to make measurements of fetal dimensions beyond about 140 days of gestation” (Wright *et al.*, 1988). Wilson and Bingham (1990) found the mean error of prediction of red deer fetal age by transrectal ultrasound increased with increasing gestational age and, although the number of dimensions measured per scan increased, there was a tendency to underestimate the age of older fetuses. The fetus became too large to image via transrectal ultrasound from 100 days of gestation, but was readily visible from Day 50 to 170 of gestation via transcutaneous ultrasound over the right flank (White *et al.*, 1989; Bingham *et al.*, 1990).

The probability of a correct diagnosis of pregnancy status can only be used with confidence from approximately 114 days of gestation using transcutaneous ultrasound over the right flank. Fetal age, however, may be

estimated with relative confidence from approximately 60 to 190 days of gestation. The relationship of fetal thoracic diameter, abdominal diameter and umbilical diameter according to gestational age at pregnancy diagnosis were all highly significant ( $p < 0.0005$ ).

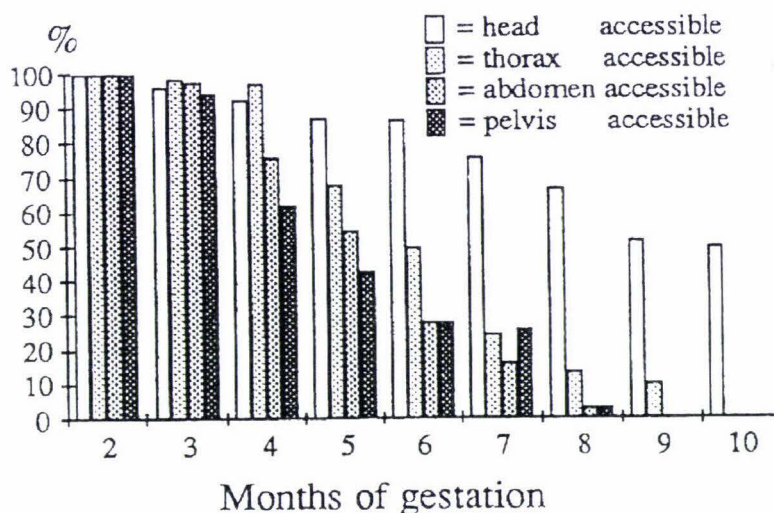
Fetal thoracic diameter:

Kahn (1990) found longitudinal sonographic images of the bovine fetal thorax were characterized by parallel rows of acoustic echoes from the ribs overshadowing the thoracic contents. During late gestation, these echoes became more pronounced requiring a 90 degree turn of the transducer to allow visualization of the heart and lungs. The measurement of thoracic diameter in this study was based on the definition used in transcutaneous ultrasound studies of sheep and red deer as the maximum distance between the echogenic thoracic vertebrae and the sternum with a detectable heartbeat (Bingham *et al.*, 1990; Sergeev *et al.*, 1990). The heart is readily visible as echogenic muscle tissue surrounding a hypoechoic lumen which, in cattle, demonstrates pronounced pulsation after Day 30 of gestation (Kahn, 1990). The surrounding lung tissue appears as a granular echo pattern which was relatively less dense than the liver.

Over the entire gestational period, Kahn (1989) found the bovine fetal thorax was accessible for 69% of cases, but, during mid gestation, as the fetus passed over the pelvic brim, visualization of the thorax declined significantly (see Figure 4.21). Fetal thoracic diameter has been recommended in previous studies as one of the most precise measurements of bovine fetal age up to 120 days of gestation, as measured via transrectal ultrasound (White *et al.*, 1985; Wright *et al.*, 1988). The results of this transcutaneous ultrasound study were similar to those of previous studies until 4 months of gestation, after which fetal thoracic diameter was lower than that found in the transrectal studies. Fetal thoracic diameter has been successfully used to estimate fetal age in red deer throughout gestation by transcutaneous ultrasound and between 61 and 80 days of gestation using



transrectal ultrasound (White *et al.*, 1989; Bingham *et al.*, 1990; Wilson and Bingham, 1990; Revol and Wilson, 1991). Sergeev *et al.* (1990) found a linear relationship between thoracic depth and gestational age was also an acceptable measurement for the estimation of fetal age in sheep.



**Figure 4.21:** Relative frequencies at which various parts of the fetal body were accessible for transrectal ultrasound in relation to month of gestation (From Kahn, 1990).

#### Fetal abdominal diameter:

Although Kahn (1989) found abdominal diameter was visualized less frequently than thoracic diameter when scanning by transrectal ultrasound, the opposite was found when transcutaneous ultrasound was used (see Figure 4.21). Previous measurements of bovine fetal abdominal diameter as measured via transrectal ultrasound were generally lower than those found via transcutaneous ultrasound (White *et al.*, 1989). As fetal length exceeds amniotic vesicle width and limits movement of the fetus around the transverse axis from mid gestation, the fetus is found in either an anterior or posterior presentation with the head or rump, respectively, directed towards the cervix (Arthur *et al.*, 1982; Kahn, 1990). When using transrectal ultrasound, therefore, the view and diameter of the fetal abdomen would be significantly different from the view using transcutaneous ultrasound which consistently images the lateral fetus.

Although bull and cow breed were both significant in the measurement of fetal abdominal diameter, further analysis found these effects were not significant once the effect of herd was removed from the analysis.

The anechoic, fluid-filled rumen subdivided into compartments can be visualized from 40 days of gestation using transrectal ultrasound (Kahn, 1990). By 5 months of gestation, the ruminal contents display echogenic patterns and occasional turbulence. Kahn (1989), using a 3.5 linear transrectal transducer, found a linear relationship between the largest intraluminal diameter of the fetal rumen and age of gestation and, although it was not investigated, this measurement could conceivably form a measurable characteristic via transcutaneous flank ultrasound as the rumen is visible on most fetal abdominal scans.

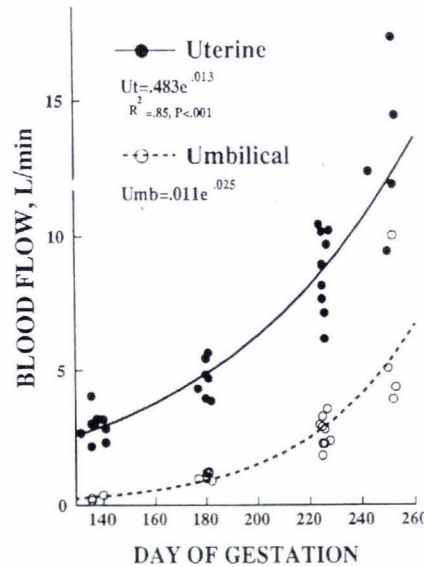
#### Fetal umbilical diameter:

Kahn (1990) found the paired umbilical arteries and veins within the umbilical cord become visible from approximately 90 days of gestation in cattle. As the umbilicus takes a winding course through the placental fluids, cross-sectional views are relatively straightforward to locate until approximately 7 months of gestation. Although umbilical blood flow increases throughout pregnancy, averaging 0.18 L/min/kg, there is a significant ( $p < 0.001$ ) increase in umbilical and uterine blood flow in mid-late gestation in response to the escalating uptake of oxygen, glucose, lactate and nitrogen by the fetus and gravid uterine horn (see Figure 4.22) (Reynolds and Redmer, 1995).

Of the three fetal measurements found to be significant in relation to gestational age, umbilical diameter demonstrated the largest variation around the mean, particularly after 150 days of gestation. Similarly, Revol and Wilson (1991), in a transrectal ultrasound study of fetal ageing in red deer, found that although umbilical diameter was the most frequently visualized measurement and was valid from 33-192 days of gestation, it



provided the largest standard error of all measurements at over 11 days.



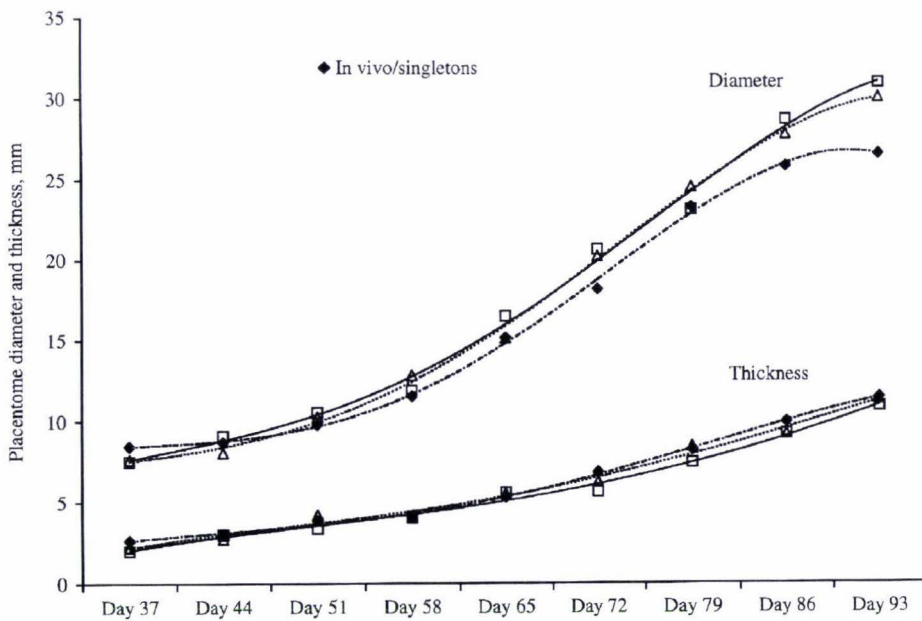
**Figure 4.22:** Regression of uterine and umbilical blood flows on day of gestation (From Reynolds and Redmer, 1995)

Placentome height and length:

Placentomes are first visible by transrectal ultrasound on Day 35 of gestation as flattened, semicircular elevations on the surface of the uterine lumen (Curran *et al.*, 1986; Boyd and Omran, 1991). In the cow, unlike other ruminants, the placentome weight and surface area continually increase throughout gestation (Laven and Peters, 1991; Perry *et al.*, 1999). Numerous references have found the significant variation in placentome size and number between gravid and non-gravid horn and proximal to distal fetus precludes their use as a measurement for fetal ageing via transrectal ultrasound or manual palpation *per rectum* (Honey, 1998; Schlafer *et al.*, 2000). Laven and Peters (2001) found, however, that there was no correlation between the number and mean length of placentomes in the cow. The same study found there was a significant linear increase in the average placentome length with increasing gestational age, although there were four separable homogeneous subsets of 71-130 days, 131-160 days, 161-190 days and 191+ days. A linear relationship was also found between placentome diameter and thickness to 93 days of gestation by Bertolini *et al.* (2002) for *in vivo* singleton pregnancies (see Figure 4.23). The rate of

increase of placentome length decreased significantly after 190 days of gestation and the estimation of fetal age based on this measurement was considered not possible after this time period (Laven and Peters, 2001). Although there is great variation in the number, size and shape of bovine placentomes, there appears, therefore, to be consistent changes overlaying this individual variation.

Placentome height and length were not significant in relation to gestational age when measured via transcutaneous ultrasound across the right flank. As the majority of placentomes measured were those directly surrounding the fetus, the effect of the inherent variation in placentome size within the horn should be lessened. The placentome is not two-dimensional, however, and placentome length and height may not be significantly related to gestational age due to the lack of obvious landmarks to standardize measurements via ultrasound and because of the dependence of the placentome image on its position and orientation within the uterus.



**Figure 4.23:** Mean diameter and thickness (mm) of placentomes surrounding in vivo embryos and fetuses from Day 37 to Day 93 of pregnancy (From Bertolini *et al.*, 2002)

In sheep, foetal requirements, maternal nutrition and season have significant effects on placental development, particularly placentome weight and shape (Laven and Peters, 1991; Doize *et al.*, 1997). Although the placental tissue can demonstrate a high degree of plasticity to adapt to adverse nutritional and environmental conditions, there is no indication in cattle that fetal growth is mediated by restriction or enhancement of placental development (Prior and Laster, 1979; Perry *et al.*, 1999; Bertolini *et al.*, 2002). Bull breed was significant in the measurement of placentome height and length by transcutaneous ultrasound. Although not replicated in this study Ferrell (1991) also found placentome development to be dependant on maternal breed, with greater placentome weights in Charolais in comparison to Brahman cows.

Additional dimensions, such as head diameter and limb length and width, were visible via transcutaneous ultrasound but in insufficient numbers to allow a thorough investigation of their potential use as measurable characteristics of fetal age. White *et al.* (1985), using transrectal ultrasound in cattle, showed a highly significant relationship between gestational age and head diameter, crown-rump length, head length, nose diameter and uterine diameter. Richardson *et al.* (1990), however, in an abattoir study of Jersey calves, found the prediction equation for crown-rump length developed by White *et al.* (1985) underestimated fetal age by more than 30 days once the fetus reached a length of greater than 11 cms. The long bones of the fore- and hindlimbs are readily visible via transrectal ultrasound from 120 days of gestation (Kahn, 1989). Richardson *et al.* (1990) found long bone length, in particular the tibia and radius which have long, straight diaphyses measurable on a lateral radiograph, was the most useful single measurement for predicting bovine fetal age to 250 days of gestation. Fetal head length and width (biparietal diameter) are the most accurate predictors of fetal age in sheep and goats respectively using transcutaneous ultrasound (Kelly and Newnham, 1984; Haibel and Perkins, 1989; Riechle and Haibel, 1991; Aiumlamai *et al.*, 1992).



Galland *et al.* (1994) found it took, on average, 11.3 seconds per animal to determine the fetal age of beef heifers by rectal palpation and 16.1 seconds per animal by transrectal ultrasound. This time was relatively less in heifers 40 to 108 days pregnant, as the fetus was quickly visualized at this later stage of gestation, but was unaffected by breed or heifer body condition score at pregnancy diagnosis. The average length of time necessary to confirm fetal age via transcutaneous flank ultrasound was not investigated in this study, but, as fetal visualization was possible within 2-5 seconds of transducer application to the skin, the author predicts visualization of a measurable fetal characteristic would not extend this time beyond that found for transrectal ultrasound.

A measurement's variability at a given gestational age is influenced by the dam and sire's breed, by the nutrient intake of the fetus and by fetal exposure to agents capable of producing stress (Richardson *et al.*, 1990). There is also considerable inherent variation in the gestation length of cattle and thus it is impossible to reduce the standard deviation of the difference between the actual and predicted calving date based on the measurement of a fetal characteristic in utero to below 5.0 days (Wright *et al.*, 1988). The length of gestation and calf birth weight are also decreased as the number of calves born increases from single to twins to triplets (Echternkamp, 1992).

### **Conclusion:**

Transcutaneous ultrasound over the right flank in dairy cattle thus appears to be an accurate and reliable means of ageing pregnancy in the cow from 60 days of gestation. The choice of measurement used will depend, however, on the position and orientation of the fetus in relation to the transducer. Abdominal diameter was the most frequently seen measurable characteristic, while thoracic diameter was the least. An apparent limitation of this technique is that, overall, a measurable characteristic was able to be visualized in only 67.2% (151/225) of cases. The study was completed,



however, during routine herd pregnancy diagnosis which did not allow sufficient time to adequately explore each visible pregnancy. It is possible that thoracic diameter, abdominal diameter and/or umbilical diameter may be visible in more cases than were seen in this study.

It is considered that the technique of transcutaneous ultrasound over the right flank is a potentially valuable aid to the management of both beef and dairy herds. Fetal ageing of cows in mid and late gestation will allow grazing management based on a known calving pattern and correct culling and management of cattle due for induction and vaccination based on the expected date of calving (Galland *et al.*, 1994).



## References:

- Abbitt, B., Ball, L., Kitto, G.P., Sitzman, C.G., Wilgenburg, B., Raim, L.W., and Seidel, G.E. (1978) Effect of three methods of palpation for pregnancy diagnosis per rectum on embryonic and fetal attrition in cows. *Journal of the American Veterinary Medical Association*, 173(8), 973-977.
- Abusineina, M.E. (1969) Effect of parity and pregnancy on the dimensions and weight of the cervix uteri of cattle. *British Veterinary Journal*, 125,12-24
- Adam, C.L., McDonald, I., Moir, C.E., and Pennie, K. (1988) Foetal development in red deer (*Cervus elaphus*) 1.Growth of the foetus and associated tissues. *Animal Production* 46, 131-138
- Adams-Brendemuehl, C., and Pipers, F.S. (1987) Antepartum evaluations of the equine fetus. *Journal of Reproduction and Fertility (Supplement)* 35, 565-573
- Ailsby, R.L. (1996) Occupational arm, shoulder and neck syndrome affecting large animal practitioners. *Canadian Veterinary Journal* 37, 411
- Aiumlamai, S., Fredriksson, G., and Nilsfors, L. (1992) Real-time ultrasonography for determining the gestational age of ewes. *The Veterinary Record* 131, 560-562
- Alam, M.G.S., and Dobson, H. (1977) Effect of various veterinary procedures on plasma concentrations of cortisol, luteinising hormone and prostaglandin F2-alpha metabolite in the cow. *Veterinary Record* 118, 7-10
- Al-dahash, S.Y.A., and David, J.S.E. (1977) The incidence of ovarian activity, pregnancy and bovine genital abnormalities shown by an abattoir survey. *The Veterinary Record* 101, 296-299
- Allaire, F.R., Sterwerf, H.E., and Ludwick, T.M. (1977) Variations in removal reasons and culling rates with age for dairy females. *Journal of Dairy Science* 60, 254-267
- Anderson, H., and Plum, M. (1965) Gestation length and birth weight in cattle and buffaloes: a review. *Journal of Dairy Science* 48, 1224-1235
- Appleyard, W.T., and Cook, B. (1976) The detection of oestrus in dairy cattle. *The Veterinary Record* 99, 253-256

- Archibong, J.E., and Diehl, J.R. (1982) Evaluation of an ultrasonic amplitude depth analysis technique for pregnancy diagnosis in the cow. *American Journal of Veterinary Research* 43(4), 711-713
- Arthur, G.H., Noakes, D.E., and Pearson, H. (1982) *Veterinary Reproduction and Obstetrics* (5<sup>th</sup> edn) Bailliere Tindall, London
- Badtram, G.A., Gaines, J.D., Thomas, C.B., and Bosu, W.T.K. (1991) Factors influencing the accuracy of early pregnancy detection in cattle by real-time ultrasound scanning of the uterus. *Theriogenology* 35(6), 1153-1166
- Ball, P.J.H. (1978) The relationship of age and stage of gestation to the incidence of embryo death in dairy cattle. *Research in Veterinary Science* 25, 120-122
- Ball, P.J.H., and Logue, D.D.N. (1994) Ultrasound diagnosis of pregnancy in cattle. *Veterinary Record* 134, 532
- Barrett, G.R., Casida, L.E., and Lloyd, C.A. (1948) Measuring breeding efficiency by pregnancy examinations and by non-returns. *Journal of Dairy Science* 31, 682-683
- Bassett, J.M., and Hinks, N.T. (1969) Micro-determination of corticosteroids in ovine peripheral plasma: effects of venepuncture, corticotrophin, insulin and glucose *Journal of Endocrinology* 44, 387-403
- Bateson, P. (1991) Assessment of pain in animals. *Animal Behaviour* 42, 827-839
- Baxter, S.J., and Ward, W.R. (1997) Incidence of fetal loss in dairy cattle after pregnancy diagnosis using an ultrasound scanner. *Veterinary Record* 140, 287-288
- Bellows, R.A., Rumsey, T.S., Kasson, C.W., Bond, J., Warwick, E.J., and Pahnish, O.F. (1975) Effects of organic phosphate systemic insecticides on bovine embryonic survival and developments. *American Journal of Veterinary Research* 36, 1133-1140
- Benesch, F., and Wright, J.G. (1950) *Veterinary Obstetrics* Bailliere Tindall and Cox, London
- Bertolini, M., Mason, J.B., Beam, S.W., Carneiro, G.F., Sween, M.L., Kominek, D.J., Moyer, A.L., Famula, T.R., Sainz, R.D., and Anderson, G.B. (2002) Morphology and morphometry of in-vivo and in-vitro produced bovine concepti from early pregnancy to term and association with high birth weights. *Theriogenology* 58, 973-994



- Bingham, C.M., Wilson, P.R., and Davies, A.S. (1990) Real-time ultrasonography for pregnancy diagnosis and estimation of fetal age in farmed red deer. *The Veterinary Record* 126,102-106
- Blood, D.C., and Studdert, V.P. (1994) *Bailliere's Comprehensive Veterinary Dictionary*. (4<sup>th</sup> edn.) Bailliere Tindall (W.B. Saunders) London
- Booth, J.M. (1979) Milk progesterone testing: application to herd management. *Journal of Dairy Science* 62, 1829-1834
- Booth, J.M. (1987) Pregnancy testing today. *British Veterinary Journal* 143, 385-386
- Booth, J.M., Davies, J., and Holsworth, R.J. (1979) Use of the milk progesterone test for pregnancy determination. *British Veterinary Journal* 135, 478-488
- Boyd, J.S. (1995) Real-time Diagnostic Ultrasound in Bovine Reproduction. P 233 In: *Veterinary Ultrasonography*. Eds: Goddard PJ CAB International. Oxon, UK
- Boyd, J.S., Omran, S.N., and Ayliffe, T.R. (1988) Use of a high frequency transducer with real-time B-mode ultrasound scanning to identify early pregnancy in cows. *Veterinary Record* 123, 8-11
- Boyd, J.S., Omran, S.N., and Ayliffe, T.R. (1990) Evaluation of real time B-mode ultrasound scanning for detecting early pregnancy in cows. *The Veterinary Record* 127, 350-352
- Boyd, J.S., and Omran, S.N. (1991) Diagnostic ultrasonography of the bovine female reproductive tract. *In Practice* 109-118
- Bozworth, R.W., Ward, G., Call, E.P., and Bonewitz, E.R. (1972) Analysis of factors affecting calving intervals of dairy cows. *Journal of Dairy Science* 55, 334-338
- Braun, U. (1990) Ultrasonographic examination of the liver in cows. *American Journal of Veterinary Research* 51(10), 1522-1526
- Braun, U., and Amrein, E. (2001) Ultrasonographic examination of the caecum and the proximal and spiral ansa of the colon of cattle. *The Veterinary Record* 149, 45-48

- Braun, U., Amrein, E., Koller, U., and Lischer, C. (2002) Ultrasonographic findings in cows with dilatation, torsion and retroflexion of the caecum. *The Veterinary Record* 150, 75-79
- Braun, U., and Marmier, O. (1995) Ultrasonographic examination of the small intestine of cows. *Veterinary Record* 136, 239-244
- Braun, U., Pusterla, N., and Anliker, H. (1998) Ultrasonographic findings in three cows with peritonitis in the left flank region. *Veterinary Record* 142, 338-340
- Braun, U., Pusterla, N., and Schonmann, M. (1997b) Ultrasonographic findings in cows with left displacement of the abomasum. *Veterinary Record* 141, 331-335
- Braun, U., Schweizer, T., and Pusterla, N. (2001) Echocardiography of the normal bovine heart: technique and ultrasonographic appearance. *The Veterinary Record* 148(2), 47-51
- Braun, U., Wild, K., and Guscetti, F. (1997a) Ultrasonographic examination of the abomasums of 50 cows. *The Veterinary Record* 140, 93-98
- Brenner, J., and Orgad, U. (1999) An outbreak of intestinal atresia in dairy cattle. *Israel Journal of Veterinary Medicine* 54(3), 93
- Bretzlaff, K., Edwards, J., Forrest, D., and Nuti, L. (1993) Ultrasonographic determination of pregnancy in small ruminants. *Veterinary Medicine* 88, 12-24
- Buckrell, B.C. (1988) Applications of ultrasonography in reproduction in sheep and goats. *Theriogenology* 29(1), 71-84
- Buckrell, B.C., Bonnett, B.N., and Johnson, W.H. (1986) The use of real-time ultrasound rectally for early pregnancy diagnosis in sheep. *Theriogenology* 25(5), 665-673
- Burgess, J.W. (1942) The clinical diagnosis of pregnancy in bovines. *The Veterinary Record* 54(7), 79-81
- Butler, J.E., Hamilton, W.C., Sasser, R.G., Ruder, C.A., Hass, G.M., and Williams, R.J. (1982) Detection and partial characterization of two bovine pregnancy-specific proteins. *Biology of Reproduction* 26, 925-933

- Cameron, A.R., and Malmo, J. (1993) Evaluation of an ultrasonic Doppler probe for pregnancy diagnosis in cattle. *Australian Veterinary Journal* 70(3), 109-111
- Carpenter, D. (1980) *Animals and Ethics*. Watkins, London
- Carriere, P.D., DesCouteaux, L., and Bigras-Poulin, M. (2000) Choosing the right cutoff level of milk progesterone to determine pregnancy status of dairy cows on day 21 post-breeding. *The Bovine Practitioner* 34(2), 81-86
- Cartee, R.E., Powe, T.A., and Ayer, R.L. (1985) Ultrasonographic detection of pregnancy in sows. *Modern Veterinary Practice* 23-26
- Cartee, R.E., and Rowles, T. (1984) Preliminary study of the ultrasonographic diagnosis of pregnancy and fetal development in the dog. *American Journal of Veterinary Research* 45(7), 1259-1265
- Cartee, R.E., Selcer, B.A., Hudson, J.A., Finn-Bodner, S.T., Mahaffey, M.B., Johnson, P.L., and Maria, K.W. (1995) *Practical Veterinary Ultrasound* Williams and Wilkins, Philadelphia
- Cattell, M.B. (2000) Rectal palpation associated cumulative trauma disorders and acute traumatic injury affecting bovine practitioners. *Bovine Practitioner* 34(1), 1-5
- Cavestany, D., and Foote, R.H. (1985) The use of milk progesterone and electronic vaginal probes as aids in large dairy herd reproductive management. *Cornell Veterinarian* 75(3), 441-453
- Chaffaux, S., Reddy, G.N.S., Valon, F., and Thibier, M. (1986) Transrectal real-time ultrasound scanning for diagnosing pregnancy and for monitoring embryonic mortality in dairy cattle. *Animal Reproduction Science* 10, 1295-1302
- Chaffaux, S., Valon, F., and Martinez, J. (1982) Evolution de l'image echographique u produit de conception chez la vache. *Bulletin Academie Veterinaire France* 55, 213-221
- Chang, M.C. (1952) Development of bovine blastocyst with a note on implantation. *Anatomical Record* 113, 143-161

- Cohen, R.D.H., Janzen, E.D., and Hunter, P.R. (1985) A comparison of chemical and surgical castration of beef calves at two different ages with or without Ralgro implants. *Journal of Animal Science* 61 (Suppl), 422 (abstract)
- Constable P.D., Shanks, R.D., Huhn, J., and Morin, D.E. (1997) Evaluation of breed as a risk factor for atresia coli in cattle. *Theriogenology* 48: 775-790
- Cordoba, M.C., Sartori, R., and Fricke, P.M. (2001) Assessment of a commercially available early conception factor (ECF) test for determining pregnancy status of dairy cattle. *Journal of Dairy Science* 84, 1884-1889
- Cottrell, D.F., and Molony, V. (1995) Afferent activity in the superior spermatic nerve of lambs – the effects of application of rubber castration rings. *Veterinary Research Communications* 19, 503-515
- Cranefield, S. (March, 2004) Safe scanning techniques In: *VetScript* New Zealand Veterinary Association (NZVA), New Zealand
- Curran, S., Pierson, R.A., and Ginther, O.J. (1986a) Ultrasonographic appearance of the bovine conceptus from days 20 through 60. *Journal of the American Veterinary Medical Association* 189 (10), 1295-1302
- Curran, S., Pierson, R.A., and Ginther, O.J. (1986b) Ultrasonographic appearance of the bovine conceptus from days 10 through 20. *Journal of the American Veterinary Medical Association* 189(10), 1289-1294
- Currie, W.B. (1995) *Structure and function of domestic animals*. Butterworth Publishers, USA
- Dairy Statistics 2001-2002. Livestock Improvement Corporation Ltd (2003) ([www.lic.co.nz](http://www.lic.co.nz)).
- Davis, M.E., and Haibel, G.K. (1993) Use of real-time ultrasound to identify multiple fetuses in beef cattle. *Theriogenology* 40, 373-382
- Dawson, F.L.M. (1959) The normal bovine uterus: physiology, histology and bacteriology. *Veterinary Reviews and Annotations* 5, 73-81
- Dawson, F.L.M. (1974) Methods for early termination of pregnancy in the cow. *The Veterinary Record* 94, 542-548



- Dawson, L.J., Sahlu, T., Detweiler, G., Gipson, T.A., The, T.H., Henry, G.A., and Bahr, R.J. (1994) Determination of fetal numbers in Alpine does by real-time ultrasonography. *Small Ruminant Research* 14, 225-231
- Day, J.D., Weaver, L.D., and Franti, C.E. (1995) Twin pregnancy diagnosis in Holstein cows: discriminatory powers and accuracy of diagnosis by transrectal palpation and outcome of twin pregnancies. *Canadian Veterinary Journal* 36(2), 93-97
- Deas, D.W. (1977) Pregnancy diagnosis in the ewe by an ultrasonic rectal probe. *The Veterinary Record* 101,113-115
- deLaHunta, A., and Haibel, R.E. (1986) *Applied Veterinary Anatomy* WB Saunders Co., Philadelphia, USA
- DesCouteaux L, Carriere PD and Bigras-Poulin M (2000) "Evaluation of the early conception factor (ECF) dip stick test in dairy cows between days 11 and 15 post-breeding." *The Bovine Practitioner* 34(2):87-91: Ref 342
- Dobson, H., and Fitzpatrick, R.J. (1976) Clinical application of the Progesterone in-milk test. *British Veterinary Journal* 132, 538-542
- Dobson, H., Rowan, T.G., Kippax, I.S., and Humblot, P. (1993) Assessment of fetal number and fetal and placental viability throughout pregnancy in cattle. *Theriogenology* 40, 411-425
- Doize, F., Vaillancourt, D., Carabin, H., and Belanger, D. (1997) Determination of gestational age in sheep and goats using transrectal ultrasonographic measurement of placentomes. *Theriogenology* 48, 449-460
- Donaldson, L.E. (1968) The efficiency of several methods for detecting oestrus in cattle. *Australian Veterinary Journal* 44, 496
- DuBoulay, G.H., and Wilson, O.L. (1988) Diagnosis of pregnancy and disease by ultrasound in exotic species. In: Smith GR and Hearn JP *Reproduction and disease in captive and wild animals*" Zoological society of London symposia 60 – Oxford science Publications 135-150

- Ducker, M.J., Haggett, R.A., Fairlie, F.J., Rowe, G.J., Yarrow, N.H., and Jackson, N.W. (1985) Evaluation of an ultrasonic pregnancy detector. *British Veterinary Journal* 141, 515-518
- Dunlop, R.H., and Williams, D.J. (1996) *Veterinary medicine: an illustrated history* Mosby-Year Book, USA
- Dyce, K.M., Sack, W.O., and Wensing, C.J.G. (1996) *Textbook of Veterinary Anatomy* (2<sup>nd</sup> edn) WB Saunders Co, Philadelphia
- Dyce, K.M., Sack, W.O., and Wensing, C.J.G. (2002) *Textbook of Veterinary Anatomy* (3<sup>rd</sup> edn) WB Saunders Co, Philadelphia
- Echternkamp, S.E., and Gregory, K.E. (1991) Identification of twin pregnancies in cattle by ultrasonography. *Journal of Animal Science* 69(Suppl), 220 (Abst)
- Eley, R.M., Thatcher, W.W., Bazer, F.W., Wilcox, C.J., Becker, R.B., Head, H.H., and Adkinson, R.W. (1978) Development of the conceptus in the bovine. *Journal of Dairy Science* 61, 467-473
- Esselmont, R.J. (1973) Oestrus behaviour in dairy cows. *The Veterinary Record* 93, 252-253
- Esslemont, R.J., and Kossaibati, M.A. (1996) An estimation of the costs of wastage in dairy herds. *XIX World Buiatrics Congress*, Edinburgh 8-12 July, British Cattle Veterinary Association
- Esslemont, R.J., and Kossaibati, M.A. (1997) Culling in 50 dairy herds in England. *Theriogenology* 140, 36-39
- Ettinger, S.J., and Feldman, E.C. (2000) *Textbook of Veterinary Internal Medicine*. (5<sup>th</sup> edn) W.B. Saunders Co
- Evans, H.E., and Sack, W.O. (1973) Prenatal development of domestic and laboratory mammals: growth curves, external features and selected references. *Anat Histol Embryol* 2, 11-45
- Farin, P.W., Stockburger, E.M., Rodriguez, K.F., Crosier, A.E., Blondin, P., Alexander, J.E., and Farin, C.E. (2000) Placental morphology following transfer of bovine embryos produced in vivo or in vitro. *Theriogenology* 53: 474

- Faulkner, P.M., and Weary, D.M. (2000) Reducing pain after dehorning in dairy calves. *Journal of Dairy Science* 83, 2037-2041
- Fell, L.R., Wells, R., and Shutt, D.A. (1986) Stress in calves castrated surgically or by the application of rubber rings. *Australian Veterinary Journal* 63, 16-18
- Fell, L.R., and Shutt, D.A. (1989) Behavioural and hormonal responses to acute surgical stress in sheep. *Applied Animal Behaviour Science* 22: 283-294
- Ferrell, C.L. (1991) Maternal and fetal influences on uterine and conceptus development in the cow: 1. Growth of tissues of the gravid uterus. *Journal of Animal Science* 69, 1945-1953
- Fisher, A.D., Knight, T.W., Cosgrove, G.P., Death, A.F., Anderson, C.B., Duganzich, D.M., and Matthews, L.R. (2001) Effects of surgical or banding castration on stress responses and behaviour of bulls. *Australian Veterinary Journal* 79(4), 279-284
- Fissore, R.A., Edmondson, A.J., Pashen, R.L., and Bondurant, R.H. (1986) The use of ultrasonography for the study of the bovine reproductive tract II: non-pregnant, pregnant and pathological conditions of the uterus. *Animal Reproduction Science* 12, 167-177
- Fleming, G. (1896) *A textbook of veterinary obstetrics* (2<sup>nd</sup> edn) Bailliere Tindall and Cox, New York
- Foote, R.H. (1974) Estrus detection and estrus detection aids. *Journal of Dairy Science* 58(2) 248-254
- Forar, A.L., Gay, J.M., Hancock, D.D., and Gay, C.C. (1995) Foetal loss frequency in 10 Holstein dairy herds. *Theriogenology* 45(8), 1505-1513
- Fowler, D.G. (1984) Diagnosis of pregnancy and number of fetuses in sheep by real-time ultrasonic imaging. I: effects of number of fetuses, stage of gestation, operator and breed of ewe on accuracy of diagnosis. *Livestock Production Science* 11, 437-450
- Fowler, D.G., and Wilkins, J.F. (1980) The identification of single and multiple bearing ewes by ultrasonic imaging. *Proceedings of the Australian Society of Animal Production* 13, 492

- Fox, M.W. (1984) *Farm animals: husbandry, behaviour and veterinary practice*. University Park Press, Baltimore
- Franco, O.J., Drost, M., Thatcher, M-J., Shille, V.M., and Thatcher, W.W. (1987) Fetal survival in the cow after pregnancy diagnosis by palpation per rectum. *Theriogenology* 27(4), 631-642
- Frandsen, R.D., and Spurgeon, T.L. (1992) *Anatomy and Physiology of Farm Animals* (5<sup>th</sup> edn) Lea & Febiger, USA
- Fraser, D., Ritchie, J.S.D., and Fraser, A.F. (1975) The term "stress" in a veterinary context. *British Veterinary Journal* 131, 63-66
- Freeman, S. (2002) Ultrasonography of the equine abdomen: techniques and normal findings. *In Practice* 24(4), 204-211
- Fricke, P.M. (2002) Scanning the futures – ultrasonography as a reproductive management tool for dairy cattle. *Journal of Dairy Science* 85, 1918-1926
- Fulkerson, W.J., and Jamieson, P.A. (1982) Pattern of cortisol release in sheep following administration of synthetic ACTH or imposition of various stressor agents. *Australian Journal of Biological Science* 35, 215-222
- Galland, J.C., Offenbach, L.A., and Spire, M.F. (1994) Measuring the time needed to confirm fetal age in beef heifers using ultrasonographic examination. *Food-Animal Practice* 89, 795-804
- Gandy, B., Tucker, W., Ryan, P., Williams, A., Tucker, A., Moore, A., Godfrey, R., and Willard, S. (2001) Evaluation of the early conception factor (ECF) test for the detection of nonpregnancy in dairy cattle. *Theriogenology* 56, 637-647
- Garcia, S.C., and Holmes, C.W. (1999) Effects of time of calving on the productivity of pasture-based dairy systems: A review. *New Zealand Journal of Agricultural Research* 42(3), 347-362
- Gearhart, M.A., Wingfield, W.E., Knight, A.P., Smith, J.A., Dargatz, D.A., Boon, J.A., and Stokes, C.A. (1988) Real-time ultrasonography for determining pregnancy status and viable fetal number in ewes. *Theriogenology* 30(2), 323-337



- Getty, R. (1975) *Sisson and Grossman's The Anatomy of Domestic Animals* (5<sup>th</sup> edn) W.B. Saunders and Co London
- Gibb, M. (2004) Postscript In: *VetScript* New Zealand Veterinary Association (NZVA), New Zealand
- Gill, G.S., and Allaire, F.R. (1976) Relationship of age at first calving, days open, days dry and herd life to a profit function for dairy cattle. *Journal of Dairy Science* 59(6), 1131-1139
- Ginther, O.J. (1984) Ultrasonic evaluation of the reproductive tract of the mare: the single embryo. *Journal of Equine Veterinary Science* 4(2), 75-81
- Ginther, O.J. (1986) *Ultrasonic imaging and reproductive events in the mare*. Equiservices, Cross Plains WI, 1986 pp 1
- Ginther, O.J., and Del Campo, C.H. (1974) Vascular anatomy of the uterus and ovaries and the unilateral lueolytic effect of the uterus: cattle. *American Journal of Veterinary Research* 35(2), 193-203
- Gjesdal, F. (1969) Age determination of Bovine Fetuses *Acta Vet Scand* 10:197-218
- Goddard, P.J. (1995) General Principles. p 1-12 In: *Veterinary Ultrasonography* Eds: Goddard PJ CAB International Oxon, UK
- Gowan, E.W., Etches, R.J., Bryden, C., and King, G.J. (1982) Factors affecting accuracy of pregnancy diagnosis in cattle." *Journal of Dairy Science* 65, 1294-1302
- Graf, B., and Senn, M. (1999) Behavioural and physiological responses of calves to dehorning by heat cauterization with or without local anaesthesia. *Applied Animal Behaviour Science* 62, 153-171
- Green, M. (1994) BVD virus and pregnancy diagnosis in cattle. *The Veterinary Record* 462-463
- Gregory, K.E., Echternkamp, S.E., Dickerson, G.E., Cundiff, L.V., Koch, R.M., and van Vleck, L.D. (1990) Twinning in cattle III: effects of twinning on dystocia, reproductive traits, calf survival, calf growth and cow productivity. *Journal of Animal Science* 68, 3133-3144

- Griffin, P.G., and Ginther, O.J. (1992) Research applications of ultrasonic imaging in reproductive biology. *Journal of Animal Science* 70, 953-972
- Hafez, E.S.E., and Hafez, B. (2000) *Reproduction in Farm Animals* (7<sup>th</sup> edn) Lippincott, Williams and Williams USA
- Hafez, E.S.E., and Rajakoski, E. (1964) Placental and fetal development during multiple bovine pregnancy: anatomical and physiological studies. *Anatomical Record* 150, 303-316
- Haibel, G.K. (1988) Real-time ultrasonic fetal head measurement and gestational age in dairy goats. *Theriogenology* 30(6), 1053-1057
- Haibel, G.K., and Perkins, N.R. (1989) Real-time ultrasonic biparietal diameter of second trimester Suffolk and finn sheep fetuses and prediction of gestational age. *Theriogenology* 32(5), 863-868
- Haibel, G.K., and Fung, E.D. (1991) Real-time ultrasonic biparietal diameter measurement for the prediction of gestational age in llamas. *Theriogenology* 35(4), 683-687
- Haibel, G.K., Perkins, N.R., and Lidl, G.M. (1989) Breed differences in biparietal diameters of second trimester toggenburg, nubian and angora goat fetuses. *Theriogenology* 32(5), 827-834
- Haibel, G.K. (1990) Use of ultrasonography in reproductive management in sheep and goat herds." *Advances in sheep and goat medicine. Veterinary Clinics of North America: Food Animal Practice* 6(3), 597-613
- Hancock, J.I. (1962) The Clinical features of the reproductive organs of pregnant and non-pregnant cattle. *The Veterinary Record* 74(23), 646-652
- Hanzen, C., and Delsaux, B. (1987) Use of transrectal B-mode ultrasound imaging in bovine pregnancy diagnosis. *The Veterinary Record* 121, 200-202
- Hanzen, C., and Laurent, Y. (1991) Application de l'échographie bidimensionnelle au diagnostic de gestation et a l'évaluation de l'incidence de la mortalite embryonnaire dans l'espece bovine. *Annales de Medicine Veterinaire* 135, 481-487

- Hatzidakis, G., Stefanakis, A., and Krambovitis, E. (1993) Comparison of different antibody-conjugate derivatives for the development of a sensitive and specific progesterone assay. *Journal of Reproduction and Fertility* 97, 557-561
- Hawk, H.W., Tyler, W.J., and Casida, L.E. (1955) Effect of sire and system of mating on estimated embryonic loss. *Journal of Dairy Science* 38, 420-427
- Hay, M., Vulin, A., Genin, S., Sales, P., and Prunier, A. (2003) Assessment of pain induced by castration in piglets: behavioural and physiological responses over the subsequent 5 days. *Applied Animal Behaviour Science* 82, 201-218
- Heap, R.B., and Hamon, M. (1979) Oestrone sulphate in milk as an indicator of a viable conceptus in cows. *British Veterinary Journal* 135, 355-363
- Heap, R.B., Holdsworth, R.J., Gadsby, J.E., Laing, J.A., and Walters, D.E. (1976) Pregnancy diagnosis in the cow from milk progesterone concentration. *British Veterinary Journal* 132, 445-464
- Henry, H.T., Levine, J.F., and Coggins, L. (1987) Rectal transmission of bovine leukemia virus in cattle and sheep. *American Journal of Veterinary Research* 48(4), 634-635
- Herring, D.S., and Bjornton, G. (1985) Physics, facts and artifacts of diagnostic ultrasound. *Veterinary Clinics of North America: Small Animal Practice* 15(6), 1107-1122
- Hickey, G.J. (1990) Pregnancy diagnosis in dairy cattle: present status and future prospects. *Cornell Veterinarian* 80(4), 299-302
- Hill, J., Westhusin, M., and Varner, D.D. (1998) Advances in large-animal reproduction: the expanding role of ultrasonography. *Veterinary Medicine* 93(5), 480-484
- Hollands, C. (1994) Use of lay personnel. *The Veterinary Record* 134, 428
- Holmes, C.W., Brookes, I.M., Garrick, D.J., MacKenzie, D.D.S., Parkinson, T.J., and Wilson, G.F. (2002) *Milk production from pasture: principles and practices*. Massey University
- Honey, P.G. (ed) (1998) *Pregnancy testing in cattle*. Australian Association of Cattle Veterinarians

- Hopkins, S.G., DiGiacomo, R.F., Evermann, J.F., Christensen, J.D., Deitelhoff, D.P. and Mickelsen, W.D. (1991) Rectal palpation and transmission of bovine leukemia virus in dairy cattle. *Journal of the American Veterinary Medical Association* 199(8), 1035-1038
- Hubbert, W.T., Stalheim, H.V., and Booth, G.D. (1972) Changes in organ weights and fluid volumes during growth of the bovine fetus. *Growth* 36, 217-233
- Hughes, E.A., and Davies, D.A.R. (1989) Practical uses of ultrasound in early pregnancy in cattle. *The Veterinary Record* 124, 456-458
- Hulet, C.V. (1972) A rectal-abdominal palpation technique for diagnosing pregnancy in the ewe. *Journal of Animal Science* 35(4), 814-819
- Humblot, P., Camous, S., Martal, J., Charlery, J., Jeanguyot, N., Thibier, M., and Sasser, G. (1988) Diagnosis of pregnancy by radioimmunoassay of a pregnancy-specific protein in the plasma of dairy cows. *Theriogenology* 30, 257-267
- Hunter, R.H.F. (1982) *Reproduction of Farm Animals*. Longman Handbooks in Agriculture, USA
- Jackson, G.H. (1986) Pregnancy diagnosis in the sow using real-time ultrasonic scanning. *Veterinary Record* 119, 90-91
- Jephcott, E.H., McMillen, I.C., Congdon, P., and Thorburn, G.D. (1988) Electroimmobilisation and ovine plasma cortisol concentrations: effect of current intensity, current duration and diazepam. *Research in Veterinary Science* 44, 21-24
- Johnston, J.D., and Buckland, R.B. (1976) Response of male Holstein calves from seven sires to four management stresses as measured by plasma corticoid levels. *Canadian Journal of Animal Science* 56, 727-732
- Jonker, F.H., van Oord, H.A., van Geijn, H.P., van der Weijden, G.C. and Taverne, M.A.M. (1994) Feasibility of continuous recording of fetal heart rate in the near term bovine fetus by means of transabdominal Doppler. *Veterinary Quarterly* 16(3), 165-168
- Kahn, W. (1985) Sonographic Imaging of the Bovine Fetus. *Theriogenology* 33(2), 385-395
- Kahn, W. (1992) Ultrasonography as a diagnostic tool in female animal production. *Animal Reproduction Science* 28, 1-10



- Kahn, W. (1989) Sonographic fetometry in the bovine. *Theriogenology* 31(5), 1105-1121
- Kastelic, J.P., Bergfelt, M. and Ginther, O.J. (1991) Ultrasonic detection of the conceptus and characterization of intrauterine fluid on days 10 to 22 in heifers. *Theriogenology* 35(3), 569-581
- Kastelic, J.P., Curran, S., Pierson, R.A., and Ginther, O.J. (1988) Ultrasonic evaluation of the bovine conceptus. *Theriogeneology* 29(1), 39-54
- Keil, G. (1988) A bovine urine prognostication for pregnancy diagnosis from the 15<sup>th</sup> century. *Deutsche Tierärztliche Wochenschrift* 95 (10), 433-434
- Kelly, R.W., Newnham, J.P., Johnson, T., and Speijers, E.J. (1987) An Ultrasound Technique to Measure Placental Growth in Ewes. *Australian Journal of Agricultural Research* 38, 757-764
- Kelly, R.W., and Newnham, J.P. (1989) Estimation of gestational age in Merino ewes by ultrasound measurement of fetal head size. *Australian Journal of Agricultural Research* 40, 1293-1299
- Kleeman, D.O., Smith, D.H., Walker, S.K., and Seamark, R.F. (1987) A study of real-time ultrasonography predicting ovine fetal growth under field conditions. *Australian Veterinary Journal* 64(11), 352-353
- Kent, J.E., and Molony, V. (1993) Changes in plasma cortisol concentration in lambs of three ages after three methods of castration and tail docking. *Research in Veterinary Science* 55, 246-251
- Koch, E., Morton, H., and Ellendorff, F. (1983) Early pregnancy factor: biology and practical application. *British Veterinary Journal* 139, 52-58
- Kourletaki-Belibasaki, S., Stefanakis, A., Vafiadis, D., Hatzidakis, G., and Krambovitis, E. (1995) Reproduction management in dairy cattle: a prospective study using progesterone and oestrone sulphate for monitoring pregnancy. *Animal Science* 60, 177-183
- Labernia, J., Lopez-Gatius, F., Santolaria, P., Lopez-Bejar, M., and Rutilant, J. (1995) Influence of management factors on pregnancy attrition in dairy cattle. *Theriogenology* 45(6), 1247-1253

- Ladds, P.W., Summers, P.M., and Humphrey, J.D. (1975) Pregnancy in slaughtered cows in north-eastern Australia: Incidence and relationship to pregnancy diagnosis, season, age and carcass weight. *Australian Veterinary Journal* 51, 472-477
- Laing, J.A., and Heap, R.B. (1971) The concentration of progesterone in the milk of cows during the reproductive cycle. *British Veterinary Journal* 127, 19-22
- Lambert, M.G., Perkins, N.R., Devantier, B.P., Knight, T.W., and Betteridge, K. (1998) Pregnancy diagnosis of twinning beef cows. *Proceedings of the New Zealand Society of Animal Production* 58, 259-261
- Lang-Ree, J.R., Vatn, T., Kommisrud, E., and Loken, T. (1994) Transmission of bovine viral diarrhea virus by rectal examination. *The Veterinary Record* 135, 412-413
- Lassauzet, M-L.G., Thurmond, M.C., and Walton, R.W. (1989) Lack of evidence of transmission of bovine leukemia virus by rectal palpation of dairy cows. *Journal of the American Veterinary Medical Association* 195(12), 1732-1733
- Laster, D.B. (1977) A pregnancy-specific protein in the bovine uterus. *Biology of Reproduction* 16, 682-690
- Latshaw, W.K. (1987) *Veterinary Developmental Anatomy: a clinically oriented approach*. BC Decker, USA
- Laven, R.A., and Peters, A.R. (2001) Gross morphometry of the bovine placentome during gestation. *Reproduction in domestic animals* 36, 289-296
- Lawton, D.E.B., Mead, F.M., and Baldwin, R.R. (2000) Farmer record of pregnancy status pre-slaughter compared with actual pregnancy status post-slaughter and prevalence of gross genital tract abnormalities in New Zealand dairy cows. *New Zealand Veterinary Journal* 48, 160-165
- Leiser, R., Krebs, C., Klisch, K., Ebert, B., Dantzer, V., Schuler, G., and Hoffman, B. (1997) Fetal villosity and microvasculature of the bovine placentome in the second half of gestation. *Journal of Anatomy* 191, 517-527

- Lemire, G.E., Stalheim, P.S., Lemire, M.R., Tiemann, M., and Verdon, L. (1993) Monitoring pregnancy losses in small dairy herds. *Canadian Veterinary Journal* 34, 33-35
- Lester, S.J., Mellor, D.J., and Ward, R.N. (1991) Effects of repeated handling on the cortisol responses of young lambs castrated and tailed surgically. *New Zealand Veterinary Journal* 39, 147-149
- Lindahl, I.L. (1966) Detection of pregnancy in sheep by means of ultrasound. *Nature* 212, 642-643
- Lindahl, I.L., and Brobeck, L. (1972) Ewe pregnancy diagnosis by ultrasonic scanning. *Journal of Animal Science* 34, 354-355
- Livingston, A. (1986) Assessing pain by physiological means In: Eds: Duncan IJH and Molony V *Assessing pain in animals*. Commission of the European Communities, Luxembourg
- Logue, D.N., Hall, J.T., McRoberts, A., and Waterhouse, A. (1987) Real-time ultrasonic scanning in sheep: the results of the first year of its application on farms in south-west Scotland. *The Veterinary Record* 121, 146-149
- MacCaulay, A.S., Friend, T.H., and LaBore, J.M. (1986) Behavioural and physiological responses of dairy calves to different methods of castration. *Journal of Animal Science* 63 (Suppl 1), 166 (Abstract 14)
- MacMillan, K.L. (1979) Factors influencing conception rates to artificial breeding in New Zealand dairy herds: a review. *Proceedings of the New Zealand Society of Animal Production* 39, 129-137
- Macmillan, K.L., and Curnow, R.J. (1976) Aspects of reproduction in New Zealand dairy herds 1. Gestation length. *New Zealand Veterinary Journal* 24(11), 243-252
- MacMillan, K.L., Henry, R.I., Taufa, V.K., and Phillips, P. (1990) Calving patterns in seasonal dairy herds. *New Zealand Veterinary Journal* 38, 151-155
- MacMillan, K.L., and Moller, K. (1977) Aspects of reproduction in New Zealand dairy herds. *New Zealand Veterinary Journal* 25, 220-224

- MacMillan, K.L. (2002) Advances in bovine theriogenology in New Zealand. 1. Pregnancy, parturition and the postpartum period. *New Zealand Veterinary Journal* 50(3) Supplement, 67-73
- Maneely, R.B. (1952) Note on the ageing of bovine embryos. *The Veterinary Record* 64(35), 509-511
- Martin, P., and Bateson, P. (1993) *Measuring behaviour: an introductory guide*. (2<sup>nd</sup> edn) Cambridge University
- McCaughey, W.J. (1981) *Pregnancy diagnosis in cattle*. 54<sup>th</sup> Annual Report – Agricultural research Institute of Northern Ireland. pp 24-33
- McCaughey, W.J., and Gilmore, J.G. (1990) A note on pregnancy diagnosis in suckler cows using a Doppler ultrasonic detector. *Irish Veterinary Journal* 43, 83-85
- McDougall, S. (2002) *Reproductive Ultrasonography in Cattle Practice*. Available from author.
- McGladdery, A.J. (1999) Ultrasonography diagnosis and management of fetal abnormality in the mare in late pregnancy. *Pferdeheilkunde* 15(6), 618-621
- McMillan, W.H., Oakley, A.P., and Hall, D.R.H. (1994) Determining the number of calves in early pregnancy using real-time ultrasound imaging in beef cows induced to twin. *Proceedings of the New Zealand Society of Animal Production* 54, 353-355
- Meacham, T.N., Bovard, K.P., and Bond, J. (1976) Accuracy of pregnancy diagnosis in beef cows. *Journal of Animal Science* 42(1), 274
- Mee, J.F., Ryan, D.P., and Condon, D. (1994) Ultrasound diagnosis of pregnancy in cattle. *The Veterinary Record* 134, 532
- Mellor, D., and Stafford, K. (1994) Assessing and minimizing the distress caused by painful husbandry procedures in ruminants. *In Practice* 21, 436-446
- Mellor, D.J. (1987) Nutritional effects on the fetus and mammary gland during pregnancy. *Proceedings of the Nutrition Society* 46, 249-257



- Mellor, D.J., Stafford, K.J., Todd, S.E., Lowe, T.E., Gregory, N.G., Bruce, R.A., and Ward, R.N. (2002) A comparison of catecholamine and cortisol responses of young lambs and calves to painful husbandry procedures. *Australian Veterinary Journal* 80(4), 228-233
- Mialon, M.M., Renand, G., Camous, S., Martal, J., and Menissier, F. (1994) Detection of pregnancy by radioimmunoassay of a pregnancy serum protein (PSP60) in cattle. *Reproduction Nutrition Development* 34, 65-72
- Mitchell, D. (1973) Detection of foetal Circulation in the mare and cow by Doppler ultrasound. *The Veterinary Record* 93, 365-368
- Miyagi, M. (1966) Changes in the arteria uterine media of cows caused by pregnancy. *Japanese Journal of Veterinary Research* 13, 137-138
- Mohammed, H.O., Loeffler, S., and Shearer, J. (1990) Financial comparison of three testing strategies for detection of oestrus in dairy cattle. *Journal of the American Veterinary Medical Association* 196(6), 865-869
- Molony, V., Kent, J.E., and McKendrick, I.J. (2002) Validation for a method for assessment of an acute pain in lambs. *Applied Animal Behaviour Science* 76, 215-238
- Molony, V., Kent, J.E., and Robertson, I.S. (1995) Assessment of acute and chronic pain after different methods of castration of calves. *Applied Animal Behaviour Science* 46, 33-48
- Molony, V., and Kent, J.E. (1997) Assessment of acute pain in farm animals using behavioral and physiological measurements. *Journal of Animal Science* 75, 266-272
- Momont, H. (1990) Rectal palpation: safety issues. *The Bovine Practitioner* 25, 122-123
- Morcan, L. (1973) Pregnancy detection in ewes – a new technique. *New Zealand Journal of Agriculture* 126, 15-17
- Morton, D.B., and Griffiths, P.H.M. (1985) Guidelines on the recognition of pain, distress and discomfort in experimental animals and an hypothesis for assessment. *The Veterinary Record* 116, 431-436
- Mostl, E., Maggs, J.L., Schrotter, G., Besenfelder, U., and Palme, R. (2002) Measurement of cortisol metabolites in faeces of ruminants. *Veterinary Research Communications* 26, 127-139

- Mosure, W.L., Meyer, R.A., Gudmundson, J., and Barth, A.D. (1998) Evaluation of possible methods to reduce pain associated with electroejaculation in bulls. *Canadian Veterinary Journal* 39, 504-506
- Mueller, K. (2001) *Comparison of enzyme-immunoassay of oestrone sulphate in milk with rectal palpation, ultrasonography and farmer's observations for pregnancy diagnosis in seasonal dairy herds in New Zealand*. Masters Thesis. Massey University, New Zealand
- Mulley, R.C., English, A.W., Rawlinson, R.J., and Chapple, R.S. (1987) Pregnancy diagnosis of fallow deer by ultrasonography. *Australian Veterinary Journal* 64(8), 257-258
- Nancarrow, C.D., Wallace, A.L.C., and Grewal, A.S. (1981) The early pregnancy factor of sheep and cattle. *Journal of Reproduction and Fertility* 30 (Suppl),191-199
- Nation, D.P., Malmo, J., Davis, G.M., and MacMillan, K.L. (2003) Accuracy of bovine pregnancy detection using transrectal ultrasonography at 28 to 35 days after insemination. *Australian Veterinary Journal* 81, 63-65
- Nation, D.P., Morton, J., Cavalieri, J., and MacMillan, K.L. (2001) Factors associated with the incidence of "phantom cows" in Australian dairy herds. *Proceedings of the New Zealand Society of Animal Production* 61, 180-183
- Nebel, R.L., Whittier, W.D., Cassell, B.G., and Britt, J.H. (1987) Comparison of On-farm and Laboratory Milk Progesterone Assays for identifying errors in detection of oestrus and diagnosis of pregnancy. *Journal of Dairy Science* 70, 1471-1476
- New Zealand Veterinary Association Inc (2002) *Members Manual*. NZVA, Wellington, New Zealand
- Newton, J.M., and Shaw, R.C. (1982) Pregnancy diagnosis in dairy herds in England and Wales. *Veterinary Record* 110(6), 123-125
- Nichols, C.W. (1944) The embryology of the calf: fetal growth weights, relative age and certain body measurements. *American Journal of Veterinary Research* 5, 135-141
- Niezgoda, J., Bobek, S., Wronskafortuna, D., and Wierzchos, E. (1993) Response of sympho-adrenal axis and adrenal cortex to short-term restraint stress in sheep. *Journal of Veterinary Medicine Series A* 40, 631-638

- Noakes, D. (1985) Pregnancy diagnosis in cattle. *In Practice* 7, 46-51
- Noonan, G.J., Rand, J.S., Priest, J., Ainscow, J., and Blackshaw, J.K. (1994) Behavioural observations of piglets undergoing tail docking, teeth clipping and ear notching. *Applied Animal Behaviour Science* 39, 203-213
- Nyland, T.G., and Mattoon, J.S. (1995) *Veterinary Diagnostic Ultrasound*. WB Saunders Co, London
- O'Callaghan, K. (2002) Lameness and associated pain in cattle – challenging traditional perceptions. *In Practice* 24(4), 212-219
- O'Connor (1994) Alternative methods for determining pregnancy status. *Proceedings of the National Reproduction Symposium*, September 22-23, 1994, Pittsburgh, American Association of Bovine Practitioners p 23-32
- O'Grady, J.P., Yeager, C.H., Findleton, L., Brown, J., and Esra, G. (1985) In Utero visualization of the fetal horse by ultrasonic scanning. *Equine Practice* 3(5), 45-49
- Oltenucu, P.A., Ferguson, J.D., and Lednor, A.J. (1990) Economic evaluation of pregnancy diagnosis in dairy cattle: a decision analysis approach. *Journal of Dairy Science* 73, 2826-2831
- Ott, R.S., Braun, W.F., Lock, T.F., Memon, M.A., and Stowater, J.L. (1981) A comparison of intrarectal Doppler and rectal abdominal palpation for pregnancy testing in goats. *Journal of the American Veterinary Medical Association* 178(7), 730-731
- Paisley, L.G., Mickelsen, W.D., and Frost, O.L. (1978) A survey of the incidence of prenatal mortality in cattle following pregnancy diagnosis by rectal palpation. *Theriogenology* 9(6), 481-489
- Palmer, E., and Driancourt, M.A. (1980) Use of ultrasonic echography in equine gynecology. *Theriogenology* 13(3), 203-216
- Park, R.D., Nyland, T.G., Lattimer, J.C., Miller, C.W., and Lebel, J.L. (1981) B-mode gray-scale ultrasound: imaging artifacts and interpretation principles. *Veterinary Radiology* 22(5), 204-210

- Parmigiani, E., Ball, L., Lefever, D., Rupp, G., and Seidel, Jr G. (1978) Elective termination of pregnancy in cattle by manual abortion. *Theriogenology* 10(4), 283-290
- Patel, O.V., Domeki, I., Sasaki, N., Takahashi, T., Hirako, M., Sasser, R.G., and Humblot, P. (1995) Effect of fetal mass, number and stage of gestation on pregnancy-specific protein B concentrations in the bovine. *Theriogenology* 44, 827-833
- Patel, O.V., Sulon, J., Beckers, J.F., Takahashi, T., Hirako, M., Sasaki, N., and Domeki, I. (1997) Plasma bovine pregnancy-associated glycoprotein concentrations throughout gestation in relationship to fetal number in the cow. *European Journal of Endocrinology* 137, 423-428
- Pennington, J.A., Schultz, L.H., and Hoffman, W.F. (1985) Comparison of pregnancy diagnosis by milk progesterone on Day 21 and Day 24 postbreeding: field study in dairy cattle. *Journal of Dairy Science* 68, 2740-2745
- Perry, V.E.A., Norman, S.T., Owen, J.A., Daniel, R.C.W., and Phillips, N. (1999) Low dietary protein during early pregnancy alters bovine placental development. *Animal Reproduction Science* 55, 13-21
- Peter, A.T., Pierson, R.A., and Jakovljevic, S. (1992) Use of real-time ultrasonography in bovine and equine reproduction. *Compendium on Continuing Education for the Practicing Veterinarian* 14, 1116-1124
- Pierson, R.A., and Ginther, O.J. (1984) Ultrasonography for detection of pregnancy and study of embryonic development in heifers. *Theriogenology* 22(2), 225-233
- Pieterse, M.C., Szenci, O., Willemsse, A.H., Bajcsy, C.S.A., Dieleman, S.J., and Taverne, M.A.M. (1990) Early pregnancy diagnosis in cattle by means of linear-array real-time ultrasound scanning of the uterus and a qualitative and quantitative milk progesterone test. *Theriogenology* 33(3), 697-707
- Pipers, F.S. (1982) Applications of diagnostic ultrasound in veterinary medicine. *Equine Veterinary Journal* 14(4), 341-344
- Pipers, F.S., and Adams-Brendemuehl, C.S. (1984) Techniques and applications of transabdominal ultrasonography in the pregnant mare. *Journal of the American Veterinary Medical Association* 185(7), 766-771



- Pitcher, P.M., and Galligan, D.T. (1990) Decision analysis and economic evaluation of the use of the rapid milk progesterone assay for early detection of pregnancy status of cows. *Journal of the American Veterinary Medical Association* 197(12), 1586-1591
- Plant, J.W. (1974) Evaluation of a rectal-abdominal palpation technique for pregnancy diagnosis in sheep. *Australian Veterinary Journal* 50, 178-179
- Pope, G.S., and Hodgson-Jones, L.S. (1975) Use of plasma progesterone levels in an assessment of embryonic loss in dairy cattle. *The Veterinary Record* 96, 154
- Prior, R.L., and Laster, D.B. (1979) Development of the bovine fetus. *Journal of Animal Science* 48 (6), 1546-1553
- Radostits, O.M., Blood, D.C., and Gay, C.C. (1994) *Veterinary Medicine: A textbook of the diseases of cattle, sheep, pigs, goats and horses*. (8<sup>th</sup> edn) Bailliere Tindall, London
- Rajamahendran, R., Ambrose, D.J., and Burton, B. (1994) Clinical and research applications of real-time ultrasonography in bovine reproduction: A review. *Canadian Veterinary Journal* 35, 563-572
- Rantanen, N.M., and Kincaid, B. (1988) Ultrasound guided fetal cardiac puncture: a method of twin reduction in the mare. *Proceedings of the 34<sup>th</sup> Annual American Association of Equine Practitioners* 173, 173-179
- Reef, V.B., Vaala, W.E., Worth, L.T., Spencer, P.A., and Hammett, B. (1995) Ultrasonographic evaluation of the fetus and intrauterine environment in healthy mares during late gestation. *Veterinary Radiology and Ultrasound* 36(6), 533-541
- Reef, V.B. (1998) *Equine Diagnostic Ultrasound*. WB Saunders London
- Reeves, J.J., Rantanen, N.W., and Hauser, M. (1984) Transrectal real-time ultrasound scanning. *Theriogenology* 21(3), 485-494
- Renaudin, C.D., Troedsson, M.H.T., Gillis, C.L., King, V.L., and Bodena, A. (1997) Ultrasonographic evaluation of the equine placenta by transrectal and transabdominal approach in the normal pregnant mare. *Theriogenology* 47, 559-573
- Reynolds, L.P., and Redmer, D.A. (1995) Utero-placental vascular development and placental function. *Journal of Animal Science* 73, 1839-1851

- Reynolds, L.P., and Ferrell, C.L. (1987) Transplacental clearance and blood flows of bovine gravid uterus at several stages of gestation. *American Journal of Physiology* 253, R735-R739
- Reynolds, L.P., Ferrell, C.L., and Nienaber, J.A. (1985) Effects of chronic environmental heat stress on blood flow and nutrient uptake of the gravid bovine uterus and foetus. *Journal of the Agricultural Sci Cambridge* 104, 289-297
- Revol, B., and Wilson, P. (1990) *Rectal ultrasonographic pregnancy diagnosis and foetal ageing of red deer*. Massey University, New Zealand
- Revol, B., and Wilson, P.R. (1991) Ultrasonography of the reproductive tract and early pregnancy in red deer. *The Veterinary Record* 128, 229-233
- Revol, B., and Wilson, P.R. (1991) Foetal ageing in farmed red deer using real-time ultrasonography. *Animal Reproduction Science* 25, 241-253
- Rexroad, C.E., Casida, L.E., and Tyler, W.J. (1973) Crown-rump length of fetuses in Purebred Holstein-Friesian Cows. *Journal of Dairy Science* 57(3), 346-347
- Reynolds, L.P., Millaway, D.S., Kirsch, J.D., Infeld, J.E., and Redmer, D.A. (1990) Growth and in-vitro metabolism of placental tissues of cows from Day 100 to Day 250 of gestation. *Journal of Reproduction and Fertility* 89, 213-222
- Richardson, C., Jones, P.C., Barnard, V., Herbert, C.N., Terlecki, S., and Wijeratne, W.V.S. (1990) Estimation of the developmental age of the bovine fetus and newborn calf. *Veterinary Record* 126, 279-284
- Roberts, S.J. (1986) *Veterinary Obstetrics and Genital Diseases*. (Theriogenology) published by The Author (3<sup>rd</sup> edn).
- Robertson, H.A., and Sarda, I.R. (1971) A very early pregnancy test for mammals: its application to the cow, ewe and sow. *Journal of Endocrinology* 49, 407-419
- Robertson, I.S., Kent, J.E., and Molony, V. (1994) Effect of different methods of castration on behaviour and plasma cortisol in calves of three ages. *Research in Veterinary Science* 56, 8-17

- Rowson, L.E.A., and Dott, H.M. (1963) A hazard of pregnancy diagnosis in cattle: early foetal size. *The Veterinary Record* 75(34), 865-869
- Ruder, C.A., and Sasser, R.G. (1986) Source of bovine pregnancy-specific protein B (bPSPB) during the postpartum period and estimation of half-life of bPSPB. *Journal of Animal Science* 63 (Suppl), 335
- Ruppanner, R., Behymer, D.E., Paul, S., Miller, J.M., and Theilen, G.H. (1983) A strategy for control of bovine leukemia virus infection: test and corrective management. *Canadian Veterinary Journal* 24, 192-195
- Sanford, J., Ewbank, R., Molony, V., Tavernor, W.D., and Uvariv, O. (1986) Guidelines for the recognition and assessment of pain in animals. *The Veterinary Record* 118, 334-338
- Sasser, R.G., Alexander, B.M., and Ruder, C.A. (1991) Pregnancy detection in postpartum cows by measurement of pregnancy-specific protein B (PSPB). *Journal of Animal Science* 69 (Suppl), 466
- Sasser, R.G., Ruder, C.A., Ivani, K.A., Butler, J.E., and Hamilton, W.C. (1986) Detection of pregnancy by radioimmunoassay of a novel pregnancy-specific protein in serum of cows and a profile of serum concentrations during pregnancy. *Biology of Reproduction* 35, 936-942
- Scanlon, P.F. (1974) Orientation of cattle fetuses in utero in relation to stage of pregnancy. *Journal of Dairy Science* 58(4), 571-573
- Scheerboom, J.E.M., and Taverne, M.A.M. (1985) A study of the pregnant uterus of the ewe and the goat using real-time ultrasound scanning and electromyography. *Veterinary Research Communications* 9, 45-56
- Schlafer, D.H., Fisher, P.J., and Davies, C.J. (2000) The bovine placenta before and after birth: placental development and function in health and disease. *Animal Reproduction Science* 60-61, 145-160
- Schwabe, C.W.(1978) *Cattle, priests and progress in medicine*. The Wesley W Spink Lectures in Comparative Medicine (Vol 4)

- Sergeev, L., Kleeman, D.O., Walker, S.K., Smith, D.H., Grosser, T.I., Mann, T., and Seamark, R.F. (1990) Real-time ultrasound imaging for predicting ovine fetal age. *Theriogenology* 34(3), 593-601
- Shaw, F.D., and Morton, H. (1980) The immunological approach to pregnancy diagnosis: a review. *The Veterinary Record* 106, 268-269
- Sheldon, M., and Noakes, D. (2002) Pregnancy diagnosis in cattle. *In Practice* 24(6), 310-317
- Siems, J. (2000) Diagnostic Ultrasound. In: Han, C.M., and Hurd, C.D. *Practical Diagnostic Imaging for the Veterinary Technician*. (2<sup>nd</sup> edn) Mosby, USA
- Singleton, G.H. (1996) A Survey to establish why pregnant cows are culled. *XIX World Buiatrics Congress*, Edinburgh 8-12 July 1996, British Cattle Veterinary Association Proceedings: Volume 1
- Singleton, G.H., and Dobson, H. (1995) A survey of the reasons for culling pregnant cows. *Veterinary Record* 136, 162-165
- Singleton, G.H., and Dobson, H. (1996) A survey to establish why pregnant cows are culled. *XIX World Buiatrics Congress*, Edinburgh 8-12 July, British Cattle Veterinary Association
- Smallwood, J.E. (1992) *A Guided Tour of Veterinary Anatomy*. WB Saunders CO., USA
- Smithcors, J.F. (1957) *Evolution of the veterinary art*. Veterinary Medicine Publishing, USA
- Sorenson Jnr, A.M. (1979) *Animal reproduction: principles and practices*. McGraw- Hill Book Co., New York
- Sreenan, J.M., and Diskin, M.G. (1986) *Embryonic mortality in farm animals*. Martinus Nijhoff Publishers
- Sreenan, J.M., and Diskin, M.G. (1983) Early embryonic mortality in the cow: its relationship with progesterone concentration. *The Veterinary Record* 112, 517-521



- Stafford K (1994) Training animal welfare professionals – animal-based scientists and veterinarians. In: *Animal welfare in the 21<sup>st</sup> century: ethical, educational and scientific challenges* – Proceedings of the ANZCCART conference (April 1994) Christchurch
- Stevenson, J.S., and Britt, J.H. (1977) Detection of estrus by three methods. *Journal of Dairy Science* 60, 1994-1998
- Stroud, B.K. (1994) Clinical applications of bovine reproductive ultrasonography. *Compendium on Continuing Education for the Practising Veterinarian*. 16(8), 1085-1097
- Stroud, B.K. (1996) Using ultrasonography to determine bovine fetal sex. *Food Animal Practice* 663-672
- Studer, E. (1969) Early pregnancy diagnosis and fetal death. *Veterinary medicine and small animal clinician* 64, 613-617
- Swett, W.W., Matthews, C.A., and Plowman, R.D. (1965) Associations between internal anatomy and milk production in Holstein and Jersey cows slaughtered at Beltsville. *Journal of Dairy Science* 48 (Abst), 812
- Syed, M., and Shanks, R.D. (1992) Atresia coli inherited in Holstein cattle. *Journal of Dairy Science* 75, 1105-1111
- Syed, M., and Shanks, R.D. (1992) Incidence of atresia coli and relationships among the affected calves in one herd of Holstein cattle. *Journal of Dairy Science* 75, 1357-1364
- Szenci, O., Gyulai, Gy., Nagy, P., Kovacs, L., Vara, J., and Taverne, M.A.M. (1995) Effect of the uterus position relative to the pelvic inlet on the accuracy of early bovine pregnancy diagnosis by means of ultrasonography. *The Veterinary Quarterly* 17(1), 37-39
- Szenci, O., Beckers, J.F., Humblot, P., Sulon, J., Sasser, R.G., Taverne, M.A.M., Varga, J., Baltusen, R., and Schekk, Gy. (1996) Comparison of ultrasonography, bPSPB and bPAG 1 test for pregnancy in dairy cows. *XIX World Buiatrics Congress*, Edinburgh 8-12 July, British Cattle Veterinary Association
- Szenci, O., Varga, J., and Bajcsy, A.C.S. (1999) Role of early pregnancy diagnosis by means of ultrasonography in improving reproductive efficiency in a dairy herd: a retrospective study. *The Bovine Practitioner* 33(1), 67-69

- Takeda, T. (1988) Diagnostic ultrasonography of the bovine udder. *Japanese Journal of Veterinary Research* 37, 133
- Taverne, M.A.M. (1991) Applications of 2-dimensional ultrasound in animal reproduction. *Wiener Tierärztliche Monatsschrift* 78(10), 341-345
- Taverne, M.A.M., and Willemse, A.H. (1989) Diagnostic ultrasound and animal reproduction. *Current Topics in Veterinary Medicine and Animal Science* (Vol 51) Kluwer Academic Publishers.
- Thomas, I., and Dobson, H. (1989) Oestrus during pregnancy in the cow. *The Veterinary Record* 124: 387-390
- Thompson, J.A., Marsh, W.E., Etherington, W.G., Momont, H.W., and Kinsel, M.L. (1995) Evaluation of the benefits of the timing of pregnancy testing by transrectal palpation in dairy cattle. *Journal of the American Veterinary Medical Association* 207(11), 1462-1465
- Thompson, J.A., Marsh, W.E., Calvin, J.A., Etherington, W.G., Momont, H.W., and Kinsel, M.L. (1994) Pregnancy attrition associated with pregnancy testing by rectal palpation. *Journal of Dairy Science* 77, 3382-3387
- Thomsen, J.L. (1974) Body length, head circumference and weight of bovine fetuses: prediction of gestational age. *Journal of Dairy Science* 58(9), 1370-1373
- Thornton, P.D., and Waterman-Pearson, A.E. (2002) Behavioural responses to castration in lambs. *Animal Welfare* 11, 203-212
- Thurmond, M.C., and Picanso, J.P. (1993) Fetal loss associated with palpation per rectum to diagnose pregnancy in cows. *Journal of the American Veterinary Medical Association* 203(3), 432-435
- Thurmond, M.C., Picanso, J.P., and Jameson, C.M. (1990) Considerations for use of descriptive epidemiology to investigate fetal loss in dairy cows. *Journal of the American Veterinary Medical Association* 197(10), 1305-1313
- Tierney, T.J. (1982) The accuracy of ultrasound techniques in diagnosing pregnancy in beef cattle. *Australian Veterinary Journal* 60(8), 250-251

- Too, K., Kanagawa, H., and Kawata, K. (1965) Fetal electrocardiogram in dairy cattle. *Japanese Journal of Veterinary Research* 13(3), 71-83
- Trostle, S.S., and O'Brien, R.T. (1998) Ultrasonography of the Bovine Mammary Gland. *Compendium on Continuing Education for the Practising Veterinarian* 20(2), S64-S71
- Turner, C.B., and Hindson, J.C. (1975) An assessment of a method of manual pregnancy diagnosis in the ewe. *The Veterinary Record* 96, 56-58
- Tyrrell, R.N., and Plant, J.W. (1979) Rectal damage in ewes following pregnancy diagnosis by rectal-abdominal palpation. *Journal of Animal Science* 48(2):348-350
- Vaillancourt, D., Bierschwal, C.J., Ogwu, D., Elmore, R.G., Martin, C.E., Sharp, A.J., and Youngquist, R.S. (1979) Correlation between pregnancy diagnosis by membrane slip and embryonic mortality. *Journal of the American Veterinary Medical Association* 175(5), 466-468
- van de Wiel, D.F.M., and Koops, W. (1986) Development and validation of an enzyme immunoassay for progesterone in bovine milk or blood plasma. *Animal Reproduction Science* 10, 201-213
- Veena, T., and Narendranath, R. (1993) An ancient Egyptian pregnancy test extended to cattle. *Current Science* 65(12), 989-990
- Verkerk, G.A., and MacMillan, K.L. (1998) Milk progesterone concentrations at selected times following oestrus and insemination in relation to the success of pregnancy establishment. *Proceedings of the New Zealand Society of Animal Production* 58, 95-97
- Von Schlegel, F., Muller, W., Willer, S., and Busch, W. (1986) Die rektale Fruhtrachtigkeitsuntersuchung als auslosender Faktor der partiellen Kolonaplasie beim Rind. ("Rectal Early Pregnancy Examination of Cattle – A Triggering Factor for Partial Colonic Aplasia.") *Monatshifte fur Veterinarmedizin* 41, 377-382
- Waldridge, B.M., and Ward, T.A. (1999) Ultrasound examination of the equine mammary gland. *Equine Practice* 21(7), 10-13
- Ward, A.H., and Castle, O.M. (1947) Average length of gestation period in dairy cattle in New Zealand. *The New Zealand Journal of Science and Technology* 29(4), 171-173

- Warnick, L.D., Mohammed, H.O., White, M.E., and Erb, H.N. (1995) The relationship of the interval from breeding to uterine palpation for pregnancy diagnosis with calving outcomes in Holstein cows. *Theriogenology* 44, 811-825
- Wemelsfelder, F., Hunter, E.A., Mendl, M.T., and Lawrence, A.B. (2000) The spontaneous qualitative assessment of behavioural expressions in pugs: first explorations of a novel methodology for integrative animal welfare measurement. *Applied Animal Behaviour Science* 67, 193-215
- Wentink, G.H., van Oirschot, J.T., Pelgrim, W., Wensing, Th., and Gruys, E. (1993) Experimental transmission of bovine leukemia virus by rectal palpation. *The Veterinary Record* 132, 135-136
- White, M.E., LaFauce, N., and Mohammed, H.O. (1989) Calving outcomes for cows diagnosed pregnant or nonpregnant by per rectum examination at various intervals after insemination. *Canadian Veterinary Journal* 30, 867-870
- White, I.R., McKelvey, W.A.C., Busby, S., Sneddon, A., and Hamilton, W.J. (1989) Diagnosis of pregnancy and prediction of fetal age in red deer by real-time ultrasonic scanning. *The Veterinary Record* 124, 395-397
- White, I.R., Russel, A.J.F., Wright, I.A., and Whyte, T.K. (1985) Real-time ultrasonic scanning in the diagnosis of pregnancy and the estimation of gestational age in cattle. *The Veterinary Record* 117, 5-8
- White, I.R., Russel, A.J.F., and Fowler, D.G. (1984) Real-time ultrasonic scanning in the diagnosis of pregnancy and the determination of fetal numbers in sheep. *The Veterinary Record* 115, 140-143
- White, M.E., LaFauce, N., and Mohammed, H.O. (1989) Calving outcomes for cows diagnosed pregnant or nonpregnant by rectum examination at various intervals after insemination. *Canadian Veterinary Journal* 30, 867-870
- Williamson, N.B., Morris, R.S., Blood, D.C., and Cannon, C.M. (1972) A study of oestrus behaviour and oestrus detection methods in a large commercial dairy herd. *The Veterinary Record* 91, 50-58



- Wilkins, J.F., and Fowler, D.G. (1982) Real time ultrasound for diagnosing litter number in naturally mated flocks. *Proceedings of the Australian Society of Animal Production* 14, 638
- Wilson, P.R., and Bingham, C.M. (1990) Accuracy of pregnancy diagnosis and prediction of calving date in red deer using real-time ultrasound scanning. *The Veterinary Record* 126, 133-135
- Winters, L.M., Green, W.W., and Comstock, R.E. (1942) Prenatal development of the bovine. *Minnesota Technical Bulletin 151 – Agricultural Experiment Station, University of Minnesota* p 1-43
- Wright, I.A., White, I.R., Russel, A.J.F., Whyte, T.K., and Bean, A.J. (1988) Prediction of calving date in beef cows by real-time ultrasonic scanning. *The Veterinary Record* 123, 228-229
- Yamaga, Y. and Too, K. (1984) Diagnostic ultrasound imaging in domestic animals: fundamental studies on abdominal organs and fetuses. *Japanese Journal of Veterinary Science* 46(2), 203-212
- Yang, C.J., Wu, L.S., Tseng, C.M., Chao, M.J., Chen, P.C. and Lin, J.H. (2003) Urinary estrone sulfate for monitoring pregnancy of dairy cows. *Asian-Australian Journal of Animal Science* 16(9), 1254-1260
- Yaniz, J., Santolaria, P., and Lopez-Gatius, F. (2002) Surface alterations in the bovine pelvic peritoneum following rectal examination of reproductive organs: A scanning electron microscopy study. *Anatomia Histologia Embryologia-Journal of Veterinary Medicine Series C* 31(6), 372-374
- Young, G.B., Lee, G.J., Waddington, D., Sales, D.I., Bradley, J.S., and Spooner, R.L. (1983) Culling and wastage in dairy cows in East Anglia. *The Veterinary Record* 113, 107-111
- Zayan, R. (1984) Assessment of pain in animals. In: *Assessing pain in farm animals*. Agriculture Report- Commission of the European communities Eds: Duncan IJH and Moloney V – Proceedings of a workshop held in Roslin, Scotland
- Zayan, R. (1986) Assessment of pain in animals: epistemological comments. In: Eds: Duncan IJH and Molony V (1986) *Assessing pain in animals* Commission of the European Communities, Luxembourg

- Zemjanis, R. (1970) *Diagnostic and therapeutic techniques in animal reproduction*. (2<sup>nd</sup> edn)  
The Williams and Wilkins Co, Baltimore
- Zemjanis, R., Fahning, M.L., and Schultz, R.H. (1969) Anoestrus: the practitioners dilemma.  
*Vet Scope* 14, 15
- Zimmerman, M. (1986) Behavioural investigations of pain in animals. In: Eds: Duncan IJH  
and Molony V *Assessing pain in animals* Commission of the European Communities,  
Luxembourg
- Zoli, A.P., Guilbault, L.A., Delahunt, P., Ortiz, W.B., and Beckers, J-F. (1992)  
Radioimmunoassay of a bovine pregnancy-associated glycoprotein in serum: its  
application for pregnancy diagnosis. *Biology of Reproduction* 46, 83-92