

Copyright is owned by the Author of the thesis. Permission is given for a copy to be downloaded by an individual for the purpose of research and private study only. The thesis may not be reproduced elsewhere without the permission of the Author.

A HISTOCHEMICAL STUDY OF BOVINE SALIVARY GLAND
SECRETORY PRODUCTS AND AN INVESTIGATION OF
INTRAEPITHELIAL GRANULAR DUCT CELLS
OF THE PAROTID GLAND

A thesis presented in partial fulfillment
of the requirements for the degree
of Master of Philosophy in
Physiology and Anatomy at
Massey University.

Chandan Jayaraj Gurusinghe

1983

*"The co-existence of the most wonderful success
with the most profound ignorance is one of
the characteristic features of present day biology."*

A. SZENT-GYÖRGYI.

ABSTRACT

Paraffin wax embedded histological tissue samples of bovine salivary glands were examined by staining, histochemical and immunohistochemical methods. The characteristically tubular secretory endpieces were composed of either proteoserous cells or mucous cells and demilunes.

Parotid glands and the histologically identical ventral buccal glands were composed entirely of proteoserous cells which occasionally contained diastase resistant PAS positive neutral glycoproteins, additionally confirmed by acetylation and saponification. Immunohistochemical studies established that most proteoserous cells also contained either protein band 4 or band 10. An examination of sheep and cattle parotid glands revealed that basal striations were absent from intralobular ducts of cattle but were abundant in those of sheep. Some duct cells contained diastase labile and diastase resistant PAS positive material and apical blebs. A granulated intraepithelial cell type, which was ultrastructurally examined and found to be similar to a globule leucocyte, was specific to intralobular duct walls of the parotid glands; their precise function was not established. The main excretory duct of the parotid gland contained several goblet cells.

The mandibular gland mucous cells contained acidic and neutral mucosubstances. The presence of acidic groups was confirmed by methylation, saponification and neuraminidase digestion. The conspicuous demilunes contained acidic and neutral mucosubstances and acidophil granules which contained protein band 8. Intralobular ducts with tall columnar cells were basally striated. Goblet cells were not identified in the main excretory duct.

The sublingual gland mucous cells contained neutral and acidic mucosubstances; the latter were not neuraminidase labile. Unlike the mandibular glands, the sublingual mucous

cells stained for sulphate groups, attributed to sulphated or sialo-sulphated glycoproteins, since hyaluronidase digestion did not eliminate basophilia at low pH. The demilune cells were mostly proteoserous and contained protein band 9. The "striated" intralobular ducts were identical to those of the mandibular gland.

Intermediate buccal, dorsal buccal, palatine, posterior tongue and pharyngeal glands mucous cell histochemical composition was similar to those of the sublingual glands. The demilune contents of the minor glands were mainly proteoserous; however those of the pharyngeal and posterior tongue occasionally contained acidic and neutral mucosubstances.

Two unusual features of the minor glands were the presence of goblet cells in intralobular ducts of the pharyngeal glands and the appearance of an atypical secretory mechanism in dorsal buccal, intermediate buccal and palatine glands, the secretions of which frequently contained cellular debris mixed with mucus.

Humoral immunity in bovine salivary glands was mediated by sublingual, mandibular and pharyngeal glands, three glands which contained abundant subepithelial plasma cells. The parotid and ventral buccal glands noticeably lacked plasma cells but contained intraepithelial granular duct cells. It was proposed that these cells may provide cell-mediated immunoprotection against bloat since increased numbers of these cells have been reported in animals with low bloat scores.

Salivary protein band 4 from parotid saliva has been correlated with bloat susceptibility in cattle, but was equally distributed in parotid tissues of both low and high bloat susceptible animals, suggesting that band 4 is synthesised but not secreted by low bloat strains.

Acknowledgements

I wish to extend my sincere thanks to Mr. M.J. Birtles who supervised the preparation of this thesis and provided invaluable advice and guidance throughout the course.

My thanks are also due to Professor R.E. Munford who made available departmental facilities for this study, and critically assessed the draft copy of the text.

I am also grateful to Dr. W.T. Jones, (Applied Biochemistry Division, D.S.I.R., Palmerston North) without whose skilful assistance and stimulating discussion the immunohistochemical studies with salivary proteins would not have been possible.

I am very much indebted to Mr. Roy Sparksman who was responsible for taking the excellent photomicrographs presented in the thesis, and to the staff of the Electron Microscopy Laboratory, D.S.I.R., Palmerston North, for instructions on use of the electron microscope and for processing the electron micrographs.

I would also wish to thank Professor John Bienenstock, Dept. of Pathology, McMaster University, Ontario, Canada, for his numerous illuminating communications pertaining to immunological functions of mucosal cell types.

Sincere thanks are also due to Mrs. Pam Slack and Mr. Roy Sparksman, for their expert technical advice and assistance at various times throughout the course.

Finally, I would wish to thank Mrs. E. Baxter for her services in typing the draft and final copy of this thesis.

CONTENTS

| | Page |
|--|------|
| Abstract | iii |
| Acknowledgements | v |
| CHAPTER 1 <u>Introduction</u> | 1 |
| 1.1 <u>Gross Anatomy of the Salivary Glands</u> | 5 |
| 1.1.1 Parotid Gland | 7 |
| 1.1.2 Mandibular Gland | 7 |
| 1.1.3 Sublingual Glands | 8 |
| 1.1.4 Buccal Glands | 9 |
| 1.1.5 Labial Glands | 10 |
| 1.1.6 Lingual Glands | 10 |
| 1.1.7 Palatine Glands | 10 |
| 1.1.8 Pharyngeal Glands | 10 |
| 1.2 <u>Histology and Cytology of Salivary Glands</u> | 12 |
| 1.2.1 Proteoserous Cells | 14 |
| 1.2.2 Mucous Cells | 16 |
| 1.2.3 Demilune Cells | 17 |
| 1.2.4 Myoepithelial Cells | 17 |
| 1.2.5 The Ductal System | 18 |
| 1.2.6 Intercalated Ducts | 18 |
| 1.2.7 Intralobular Ducts | 19 |
| 1.2.8 Excretory Ducts | 21 |
| 1.3 <u>Bovine Salivary Composition</u> | 23 |
| 1.3.1 Secretion of water and electrolytes | 23 |
| 1.3.2 Primary saliva | 24 |
| 1.3.3 Final saliva | 26 |

| | Page |
|---|------|
| 1.3.4 Organic secretory products | 30 |
| 1.3.5 Synthesis and secretion of proteins and muco- substances | 31 |
| 1.3.6 Composition of Bovine salivary mucosubstances | 34 |
| 1.4 <u>Control of Salivary Secretion</u> | 38 |
| 1.5 <u>Mucosal Immunity</u> | 42 |
| 1.6 <u>Salivary Secretions and Bloat Susceptibility</u> | 47 |
| CHAPTER 2 <u>Bovine Salivary Gland Histology and Histochemistry</u> | 49 |
| 2.1 <u>Introduction</u> | 49 |
| 2.2 <u>Materials and Methods</u> | 53 |
| 2.2.1 Tissue sampling and fixation procedures | 53 |
| 2.2.2 Paraffin wax processing and microtomy | 54 |
| 2.2.3 Staining and histochemical methods | 54 |
| 2.2.4 Immunohistochemistry | 55 |
| 2.2.5 Photomicrography | 57 |
| 2.3 <u>Results</u> | 58 |
| 2.3.1 Parotid Gland | 58 |
| 2.3.2 Mandibular Gland | 59 |
| 2.3.3 Sublingual Gland | 61 |
| 2.3.4 Buccal Glands | 62 |

| | Page |
|--|------|
| 2.3.5 Palatine Glands | 63 |
| 2.3.6 Posterior Tongue Glands | 64 |
| 2.3.7 Pharyngeal Glands | 64 |
| 2.3.8 Immunohistochemistry | 65 |
| 2.4 <u>Discussion</u> | 67 |
| CHAPTER 3 <u>Parotid Gland Intraepithelial Duct Cells</u> | 76 |
| 3.1 <u>Introduction</u> | 76 |
| 3.2 <u>Materials and Methods</u> | 78 |
| 3.3 <u>Results</u> | 81 |
| 3.3.1 Histology | 81 |
| 3.3.2 Histochemistry | 82 |
| 3.3.3 Ultrastructure | 83 |
| 3.4 <u>Discussion</u> | 84 |
| CHAPTER 4 <u>General Discussion</u> | 91 |
| CHAPTER 5 <u>Conclusion</u> | 109 |
| Appendix I The principles of histochemical methods used for the detection of mucosubstances. | 114 |
| Appendix II Staining and histochemical techniques | 116 |
| Bibliography | 128 |

LIST OF TABLES

| | Following Page |
|--|----------------|
| 1.1 Bovine Salivary Proteins I | 30 |
| 1.2 Bovine Salivary Proteins II | 36 |
| 1.3 Immunoglobulin Composition of Adult Ruminant Saliva | 44 |
| 2.1 Histochemical Results of Bovine Major and Minor Salivary Glands | 58 |
| 3.1 Histochemical Results of IEG Duct Cells and Mast Cells | 82 |
| 5.1 Histochemical Classification of Bovine Salivary Glands | 109 |

LIST OF FIGURES

| Figure | Following Page |
|--|----------------|
| 2.1 Parotid and Ventral Buccal Glands | 66 |
| 2.2 Parotid and Ventral Buccal Gland Intralobular Ducts | 66 |
| 2.3 Immunohistochemistry: Distribution of Parotid and Ventral Buccal Gland Salivary Protein Bands 4 and 10 | 66 |
| 2.4 Mandibular Gland | 66 |
| 2.5 Sublingual Gland | 66 |
| 2.6 Intermediate Buccal Gland | 66 |
| 2.7 Dorsal (Upper) Buccal Gland | 66 |
| 2.8 Palatine Glands | 66 |
| 2.9 Posterior Tongue Glands | 66 |
| 2.10 Pharyngeal Glands | 66 |
| 2.11 Hyaluronidase Activity | 66 |
| 3.1 Morphology and Distribution of Intra-epithelial Granular (IEG) Duct Cells of the Parotid and Ventral Buccal Glands | 83 |
| 3.2 Morphology and Distribution of Mast Cells in Bovine Salivary Glands | 83 |

| Figure | Following Page |
|--|----------------|
| 3.3 Histological and Histochemical Features of Cytoplasmic Granules in IEG duct cells | 83 |
| 3.4 Ultrastructural Features of IEG Duct Cells | 83 |

CHAPTER 1 : INTRODUCTION

Saliva is produced by specialised glands associated with the oral cavity. In mammals the three major paired salivary glands are the parotid, mandibular and sublingual. Additionally there are several minor salivary glands embedded in the subepithelial tissues of the mouth and oropharynx.

Mammalian saliva generally consists of water, electrolytes and proteinacious material. The volume and composition of secretion from individual glands varies within species and between different species.

In many animals, including man, saliva contains significant amounts of enzymes such as salivary amylase, lipase, maltase, peroxidase and lysozyme (Young and van Lennep, 1978). Recently several biologically active peptides, with wide ranging functions, have been isolated from salivary gland tissue (Barka, 1980). This may be suggestive of a yet poorly understood endocrine role for salivary glands in addition to their well established exocrine function.

Functionally, salivary secretion provides protection for the oral mucosa against abrasion and dessication, facilitates mastication, taste, swallowing and effective sucking and suckling. Saliva also exhibits antibacterial properties and also maintains the calcium ion equilibrium necessary for the maintenance of teeth.

Salivary secretions are usually divided into two categories, serous and mucous. Serous secretion is thin and watery and consists of water, inorganic ions and some proteinacious material, while mucous secretion is more viscous and contains a higher concentration of organic proteinacious matter including neutral and acidic glyco-

proteins (Schneyer and Schneyer, 1967). In general, the parotid gland produces a serous secretion while the mandibular and sublingual glands produce a mixed serous and mucous secretion.

Ruminants, such as sheep and cattle, in contrast to monogastric species secrete large quantities of saliva owing to the generally coarse nature of their diet and the necessity to maintain fluid in a capacious non-secretory forestomach. Salivary secretions in the reticulorumen function as a nutrient medium for fermentative microorganisms which produce enzymes required for breakdown of plant material (Church, 1976).

Bovine saliva is composed of inorganic and organic components. The former consists of electrolytes such as Na^+ , K^+ , Ca^{++} , Mg^{++} , PO_4^{--} , HCO_3^- , and Cl^- . The inorganic anions function primarily as salivary buffers while the cations particularly Na^+ and K^+ , are responsible for establishing a concentration gradient for passive transport of water. The organic components, which are chiefly mucosubstances, provide physical protection for the oral and forestomach mucosa and are also a source of nutrients for rumen bacteria. Salivary immunoglobulins such as secretory IgA, probably provide immunoprotection for the entire ruminant forestomach, since plasma cells are usually not found in the mucosa of these regions. In addition, to sufficiently moisten dry feed, a copious amount of water is secreted during feeding and rumination (Kay, 1960; Church, 1976).

The parotid glands of cattle secrete large quantities of saliva with or without nervous stimulation compared to the mandibular glands which secrete little except during feeding periods (Kay, 1960). The sublingual glands, although continuously secreting, contribute negligible quantities of saliva compared to both the mandibular and the parotid (Kay, 1960). The volume of saliva supplied by the minor glands described by Kay (1960) as the residual saliva, is approximately equal to that secreted from both

the parotid glands. Bailey and Balch (1961) estimated the total volume of saliva secreted by cattle to be as high as 98-190 litres per day.

The rumen fluid volume and composition is affected by the balance between inflow of ions from saliva and food and the net outflow by absorption or passage to the omasum (Kay, 1966). The tonicity between rumen contents and the blood is therefore maintained at an equilibrium which limits the movement of water across the ruminal epithelium. For fermentative digestion to function optimally the maintenance of the rumen fluid level is essential (Bailey, 1961).

The microbial population of the reticulorumen is heavily dependent on the constituents of saliva for their growth, particularly nitrogen and minerals (Church, 1976). Urea present in ruminant saliva provides about 75-85% of the nitrogen requirements (Philipson and Magnan, 1959), while the salivary buffers, bicarbonate and phosphate ions, maintain the pH at an optimum for fermentative digestion (Kay, 1966). The rumen pH is also influenced by the nature and dryness of the feed, which in turn modifies salivary secretion (Church, 1976).

Secretions from the parotid, ventral buccal, palatine, pharyngeal and buccal glands are strongly buffered with bicarbonate and phosphate ions compared with the mandibular and sublingual gland secretions which are weakly buffered. (Kay, 1960). Although present in large quantities, bicarbonate and phosphate ions are capable of neutralizing only a fraction of the volatile fatty acids produced during microbial fermentation because acidity of rumen contents frequently exceeds the buffering capacity of the ions (Bailey, 1961). Salivary buffers therefore, mainly provide a first line of defence against sharp declines in ruminal pH by counteracting peaks of volatile fatty acid production soon after feeding. Fatty acids not neutralized by salivary buffers are absorbed through the ruminal epithelium and neutralized by buffers of the blood (Kay, 1966; Bartley,

1976).

Ruminant saliva, particularly of cattle, has also been implicated with susceptibility to bloat, a disease of considerable economic importance. Saliva and its association with bloat will be discussed in section 1.6.

1.1 Gross Anatomy of the Salivary Glands.

The following outline is descriptive of salivary gland architecture (source reference: Young and van Lennep, 1978).

The major salivary glands are large distinct structures located in the head and neck region. Saliva formed by these glands is delivered to the oral cavity by relatively long excretory ducts. Each gland is enclosed by a fibrous tissue capsule and the secretory tissue is subdivided into lobes and smaller lobules by connective tissue septa from the capsule. The gland parenchyma consists of closely packed secretory acini (or endpieces) and drainage ducts. The stroma is composed of loose areolar connective tissue, blood vessels, nerve bundles and excretory ducts. The hilus of the gland contains arteries, veins, nerves, lymphatics and the main excretory duct (or ducts). Additional to the vascular supply entering the hilus small arteries enter through the capsule at several points. While the mandibular and sublingual glands display the above features, the parotid has no true hilus since the arterial supply and venous drainage are randomly scattered over the gland surface.

The distribution of blood vessels within salivary glands usually parallels that of the branching duct system. Arteries accompany the ducts within lobules and terminate in extensive capillary plexuses around endpieces and intra-lobular ducts. The venous drainage follows a similar pattern although some veins drain directly to the gland periphery. The presence of arteriovenous anastomoses in some glands provides a regulatory mechanism which influences the rate of salivary secretion.

The nervous supply to the three major salivary glands is provided by both parasympathetic and sympathetic division of the autonomic nervous system. Preganglionic parasympathetic fibres originate in the rostral and caudal salivary nuclei in the lateral reticular formation of the lower

brain stem, medial to the spinal tegmental tract. Post-ganglionic parasympathetic fibres to individual glands are located in VII and IX cranial nerves. After entering the stroma of the gland they form small branches that penetrate the basal lamina of the secretory endpieces and terminate in small budlike thickenings on the basal surfaces of secretory cells. Preganglionic sympathetic fibres originate in the first two thoracic segments of the spinal cord and ascent in the vagosympathetic trunk to synapse in the cranial cervical ganglion. Terminations of postganglionic sympathetic fibres that reach the gland are distributed in the walls of blood vessels and the basal plasmalemma of secretory cells. Parasympathetic and sympathetic branches of nerves to secretory cells also supply the salivary gland duct cells.

In contrast to the major salivary glands which are distinct organs, the minor glands are basically lobules of glandular tissue embedded in the submucosal connective tissues of the mouth and oropharynx. The minor glands are not surrounded by a distinct connective tissue capsule but are arranged in groups of lobules, which are mostly diffuse. Secretions from these glands are delivered into the oral cavity via short ducts that open through the epithelial surface.

In cattle, the paired minor salivary glands are the ventral buccal, intermediate buccal, dorsal buccal, labial and pharyngeal glands. The two non-paired minor salivary glands are the palatine and lingual glands (Birtles, 1981). Kay (1960), stated that the combined total weight of the minor glands in cattle is half that of the three major glands. The minor glands therefore undoubtedly constitute an important mass of salivary gland tissue in ruminants.

The Bovine Salivary Glands.

The following descriptions have been based on accounts presented in texts of Veterinary Anatomy by Habel (1970),

Getty (1975) and Nickel, Schummer, Seiferle and Saek (1973).

1.1.1 Parotid Gland

The parotid gland is pinkish brown in colour with an average weight of 115 grams. It is long, narrow and triangular in shape with a wide thick dorsal end that reaches the region of the temporomandibular joint. The gland lies along the caudal border of the masseter muscle and extends from the zygomatic arch to the ramus of the mandible. The ventral aspect follows the caudal border of the mandible and is related deeply to the mandibular gland. The deep surface is related to the angle of the stylohyoid bone and the occipitohyoideus and diaphragmatic muscles.

The parotid duct leaves the gland ventrally with the facial artery and vein and ascends on the lateral surface of the masseter muscle to open near the posterior upper molar teeth in the buccal cavity.

The highly vascular parotid gland receives its blood supply from all the underlying arteries particularly the external carotid; the venous drainage is by the maxillary and external jugular veins.

The parotid glands are innervated by the secretomotor parotid nerve which is a branch of the buccal nerve from the trigeminal nerve. The parotid nerve is located dorsal to the parotid duct and accompanies it to the gland. Sympathetic fibres reach the gland in the vascular plexuses and synapse with α and β receptors on secretory cells.

1.1.2 Mandibular Gland

The mandibular gland is larger than the parotid and weighs about 140 grams. It is pale yellow in colour, distinctly lobulated and extends in a curve medial to the angle of the mandible from the atlantal fossa to the

basihyoid muscle. Caudally the gland is partly covered by the parotid gland.

The mandibular duct leaves the gland from the middle of its rostral border and extends laterally along the digastric muscle, then passes forward on the deep surface of the mylohyoid and opens lateral to the sublingual caruncle.

The vascular supply to the mandibular gland is from branches of the facial and lingual arteries; venous drainage reaches the linguofacial and facial veins. Preganglionic parasympathetic fibres from the rostral salivary nucleus leave in the facial nerve in nerve trunks known as chorda tympani, to join the lingual nerve. Synaptic junctions are usually found within ganglia located in the hilus of the gland and postganglionic fibres pass into lobules of the gland by following the branching drainage duct system.

1.1.3 Sublingual Glands

The sublingual glands are divided into two parts, the more ventral monostomatic and the dorsal polystomatic portion. The polystomatic part is composed of a chain of lobules about 15-18 cm in length, pale yellow in colour and lying under the floor of the mouth. This group extends from the incisive area of the mandible to the palato-glossal arch and is drained by many small ducts which open along rows of long papillae found in the lateral sublingual recess of the mouth.

The monostomatic gland is 10-12 cm in length and 2-3 cm in width and extends from the incisive area of the mandible to the midline of the polystomatic gland which lies dorsally. A single excretory duct passes forward medial to the gland and accompanies the mandibular duct to the sublingual caruncle located on the floor of the mouth behind the incisor teeth.

Collectively, the sublingual glands are related on their lateral aspects to the mylohyoid muscle and the sublingual nerve, medially to the hyoglossus, styloglossus and genioglossus muscles and ventrally to the geniohyoid muscle.

The blood supply and venous drainage are via the sublingual artery and vein respectively. The nerve supply is similar to the mandibular gland in that secretomotor fibres from the chorda tympani join the lingual nerve to supply the gland.

1.1.4 Buccal Glands

These glands are well developed and arranged into three groups: dorsal, intermediate and ventral buccal glands.

The dorsal group are yellow in colour, distinctly lobulated and extend from the angle of the mouth to the maxillary tuberosity. Thin superficial layers of the buccinator and masseter muscles envelope the dorsal buccal glands. Short ducts drain the gland through the papillated area of the epithelium to the buccal cavity.

The ventral buccal gland is a compact, brown-coloured mass weighing about 15 grams. The gland lies adjacent to the lower molar teeth and extends from the angle of the mandible to the rostral border of the masseter muscle. The gland is drained via short ducts to the buccal cavity. The ventral buccal gland is similar in consistency and function to the parotid gland.

The intermediate buccal glands are diffuse loosely-arranged lobules yellow in colour, and extend along the dorsal border of the ventral buccal gland. Lobules of glandular tissue are scattered within connective tissues, adipose tissue and portions of the buccinator muscle. The gland is drained via short ducts that open into the buccal

vestibule.

Collectively, the three buccal glands are innervated by the buccal nerve, a branch of the mandibular nerve.

1.1.5 Labial Glands

These glands are composed of small scattered yellow-coloured lobules of secretory tissue found near the labial commissure of the upper lip embedded between bundles of labial muscles. Short ducts open at the summits of tiny papillae located on the internal surface of the lip.

1.1.6 Lingual Glands

The lingual glands are composed of small yellow-coloured lobules scattered between skeletal muscles and connective tissues of the posterior third of the tongue and also extend rostrally along the margins of the tongue. The glands are drained by several small ducts which open onto the lingual surface through rows of papillae. The group of glands associated with the vallate papillae are called gustatory or von Ebner's glands.

1.1.7 Palatine Glands

This is a large mass of yellow-coloured, lobulated glandular tissue embedded in the subepithelial connective tissues of the soft palate and distal portion of the hard palate. The glands are drained by several small ducts which open onto the oral cavity.

1.1.8 Pharyngeal Glands

This group are yellow in colour and distributed in the submucosal connective tissues of the oral and laryngeal regions of the pharynx. The glands are drained via small ducts that open onto the epithelium of the pharynx. Glandular tissue found in the root and lateral margins of the

tongue, in the area between tongue and epiglottis are also included in the pharyngeal group.

1.2 Histology and Cytology of Salivary Glands

Histologically salivary glands are classified as exocrine glands, where products of secretory cells are discharged to an external surface via a system of ducts.

Four factors distinguish exocrine glands:-

1. The number of cells (unicellular or multicellular).
2. The secretory endpiece (tubular, acinar or tubular-acinar) and the duct system (simple or compound).
3. Mode of secretion (apocrine, merocrine or holocrine).
4. The nature of secretion (mucous or serous).

Salivary glands are multicellular and arise as tubular invaginations of an epithelial sheet that extends into the underlying connective tissue. The secretory cells are confined to the terminal portions of the tubular invaginations (Young and van Lennep, 1978). The terminal secretory endpieces were classically referred to as acini owing to the belief that secretory endpieces were spherical terminal expansions. However this may be an oversimplification as secretory endpiece morphology varies considerably depending on the gland and the species. The morphology of mammalian salivary glands, with particular reference to species variation, has been extensively reviewed by Young and van Lennep (1978) and Pinkstaff (1980).

Salivary glands are compound exocrine glands with a branched system of ducts since simple exocrine glands with unbranched ducts have not been reported for salivary glands.

The mode of secretion of salivary glands can be described as merocrine since the secretory product elaborated by endpiece cells is released through the apical cell membrane leaving the cell intact.

An entire secretory endpiece, regardless of its morphology, is composed of a collection of secretory cells. The

precise identification of all the cell types in an end-piece is however, still controversial. Traditionally four cell types; serous, mucous, seromucous and special serous have been implicated in the formation of saliva (Shackleford and Wilborn, 1968). The morphology and secretory products of typical serous and mucous cells are well documented (Young and van Lennep, 1978). However, the precise nature of secretory cells with characteristics common to both serous and mucous cells, is open to debate.

In general, serous cells secrete water, electrolytes and proteinacious material that may be either basic proteins or neutral glycoproteins or both. Mucous cells synthesise and secrete mucosubstances while the seromucous cells synthesise and secrete significant amounts of mucosubstance in addition to water and electrolytes (Munger, 1964; Shackleford and Wilborn, 1968). The "special serous" cell described by Shackleford and Wilborn (1968) had ultrastructural features found in serous cells but the secretory granules, although similar to mucous granules, differed histochemically. Tandler and Poulsen (1977) reported an identical cell type but called it seromucous. A solution to the classification problem suggested by Young and van Lennep (1978) was to adopt the terms serous, mucous and seromucous (special serous was not mentioned) to describe morphological features of secretory cells without alluding to the histochemical definition of the secretory product. Within this classification serous cells have small electron dense homogeneous granules while mucous granules are large and closely packed with a homogeneous electron lucent matrix. Secretory granules of seromucous cells have characteristics common to both serous and mucous granules.

The fundamental question of whether cells that secrete significant amounts of proteinacious material with water and electrolytes, could be called "serous" remains unanswered, the term "serous" denoting a watery secretion with ions but not proteins or glycoproteins. Pinkstaff (1980) referred to all three cell types, serous, seromucous and special serous,

as "serous" cells and reported that all "serous" cells are generally involved in the synthesis of proteinacious material, to "one degree or another". Recently, the term "proteoserous" has been suggested for "serous" cells (Birtles, 1981). This may be the most appropriate term after a careful appraisal of the existing literature. In the present study, the term proteoserous has been adopted for future discussion.

In general, the secretory cells of an endpiece are either proteoserous or mucous, but mixed endpieces with proteoserous and mucous cells are present in some glands. The demilune cells of salivary glands located distal to an endpiece, produce mainly a proteoserous secretion. Contractile myoepithelial cells which lie between the basal lamina and secretory cells have also been reported (Garrett and Emmelin, 1979).

1.2.1 Proteoserous Cells

Proteoserous cells involved in secretion of water, electrolytes and proteinacious material are observed in two basic forms in salivary glands. Firstly, a pyramidal-shaped cell in an acinar endpiece and secondly a cuboidal cell in a tubular endpiece (Young and van Lennep, 1978). The latter form is usually descriptive of the bovine parotid and ventral buccal glands.

A pyramidal endpiece cell, with a broad base and a narrow apex is generally specialised for synthesis of basic proteins and secretion of some water and electrolytes. The broad basal cytoplasm contains considerable amounts of rough endoplasmic reticulum (RER) and the narrow apex houses small, dense secretory granules.

Secretory cells which are predominantly specialised for water and electrolyte transport, however, require a greater surface area to volume ratio (Young and van Lennep, 1978). In the ruminant this characteristic is clearly demonstrated

by the presence of extensive basolateral infoldings of the plasma membrane, an apical area with several secretory canaliculi and well developed microvilli. These cell surface modifications generally facilitate water equilibration (van Lennep, Kennerson and Compton, 1977).

The presence of tight junctions (zonula occludens) between the lateral intercellular canaliculi and the apical secretory canaliculi (Young and van Lennep, 1978) may additionally contribute to the establishment of an ionic gradient. Thus it is tempting to postulate that overall, cuboidal cells with lateral surface modifications are more advantageous for water and electrolyte transport in addition to synthesizing and secreting some proteins and glycoproteins.

Above findings are particularly valid for parotid gland proteoserosus cells of sheep (van Lennep et al., 1977) and cattle (Shackleford and Wilborn, 1969) although in the latter species evidence has accumulated in favour of a significantly high protein and glycoprotein content in parotid saliva (Table 1.2).

Apart from structural modifications of the cytoplasmic membrane proteoserosus cells of ruminants do not possess unusual features. The position of the spherical nucleus, for example, is governed by the numbers of secretory granules present; when the cell is replete with granules the nucleus occupies the basal third of the cell, following their discharge the nucleus becomes more centrally placed (van Lennep et al., 1977). In accordance with a low level of protein secretion generally little RER has been described in proteoserosus cells (Shackleford and Wilborn, 1969). RER appears as flattened cisternae stacked on top of one another, parallel with the base of the cell and filling the perinuclear cytoplasm. The Golgi complex is located in the supranuclear position which is typical of cells engaged in protein synthesis. A system of vesicles, lamellae, vacuoles and saccules are present in addition to curved stacks of

three to five smooth membrane cisternal elements of Golgi-ER-lysosome (GERL) system (Novikoff, Novikoff, Quintana and Hauw, 1971). Mitochondria are usually elongated and particularly abundant in proteoserous cells of the sheep parotid (van Lennep et al., 1977). Their distribution, although random shows a preference for the lateral cytoplasmic membranes (Young and van Lennep, 1978).

The secretory granules of proteoserous cells consist of a trilaminar membrane enclosing a matrix with one or more electron dense inclusions (Young and van Lennep, 1978); the size and shape of the granules and the electron microscopic appearance of their matrix may vary depending on the fixation procedure. In sheep two granule types have been observed by van Lennep et al., (1977). The majority of granules classified as type I were described as small and electron dense while type II granules were larger with a less electron dense matrix and had a tendency to fuse with one another, a feature typical of mucous secretory granules. This latter characteristic was responsible for the ruminant proteoserous cells being previously labelled as "special serous" by Shackleford and Wilborn, (1969).

1.2.2 Mucous Cells

Tubular endpieces with cuboidal secretory cells specialised for synthesis of mucous granules do not display the complex lateral surface modifications of proteoserous cells (Young and van Lennep, 1978). The apical plasma membrane is usually devoid of microvilli and secretory canaliculi are rarely present. Basal and lateral plasma membranes are smooth or slightly plicated with some interdigitation between adjacent cells.

The nucleus is displaced towards the base of the cell owing to the large volume occupied by the secretory granules. The RER consists of closely packed cisternae in the basal region but its precise distribution and concentration varies with the secretory cycle (Pinkstaff, 1980). Golgi complexes

are large with several dilated cisternae on their concave side. Mitochondria are located predominantly in the basal part of the cell.

The mucous secretory granules are larger than proteoserous secretory granules and consist of an electron lucent matrix. The granules often appear fused with adjacent granules which produce the characteristic "foamy" appearance of the cytoplasm (Young and van Lennep, 1978). Pinkstaff (1980) had extensively reviewed the fine structure of mucous granules with reference to species variation and fixation artifacts.

1.2.3 Demilune Cells

In salivary glands of most species the mucous tubules are often "capped" by crescent-shaped secretory cells referred to as demilunes. The morphology and secretions of demilunes vary among species and in different glands of the one species but generally the secretory products are proteoserous. Purely mucous demilunes are rare and have been reported in only a few species (Pinkstaff, 1980).

The arrangement of a demilune distal to an endpiece has resulted in much speculation as to the mode of release of their secretory material to the lumen of a tubule. Shackelford and Wilborn, (1970) have reported the presence of a system of intercellular canaliculi in demilunes of bovine mandibular glands. These may interconnect to communicate with a demilune that has direct access to the lumen of its associated tubule (Pinkstaff, 1980).

Functionally, proteoserous secretions of the demilune cells may provide a "flushing" effect for the viscous material secreted by the endpiece mucous cells.

1.2.4 The Myoepithelial Cells

Myoepithelial cells are frequently found between the

endpiece secretory cells and the basal lamina. They are slender, spindle-shaped cells with long branching cytoplasmic processes which encircle cells of the secretory endpieces and intercalated ducts.

Myoepithelial cells have been associated with a contractile role. Pressure exerted during contraction may expel secreted material from the endpiece lumens into the intercalated ducts and also prevent backflow of saliva into the endpiece lumen. Pinkstaff (1980) has suggested that myoepithelial cells may additionally support the secretory endpiece and intercalated ducts during secretion.

1.2.5 The Ductal System

In contrast to secretory endpieces, classification of the salivary gland duct system is less controversial. The basic pattern of the drainage ducts within a salivary gland begins with an intercalated duct which connects a secretory endpiece to an intralobular duct. These empty into a confluence of drainage vessels termed interlobular and interlobar ducts, depending upon their position. The latter anastomose to form a main excretory duct or in some glands into multiple excretory ducts. The main excretory duct (or ducts) terminates at the oral mucosa.

1.2.6 Intercalated Ducts

Intercalated ducts vary in length, diameter and cell height; generally the duct walls are composed of cuboidal epithelial cells but may range from squamous to low columnar (Pinkstaff, 1980). In bovine parotid glands the intercalated duct epithelium near the secretory endpiece has been described as low cuboidal changing to low columnar near the junction with intralobular ducts (Shackleford and Wilborn, 1969).

In cattle, intercalated duct cells have short apical microvilli and minimal lateral and plasmalemmal modifications

(Shackleford and Wilborn, 1969). The intracytoplasmic components do not possess unusual features. A large spherical centrally-placed nucleus occupies a large area of the cytoplasm which contains a few mitochondria in addition to a Golgi complex and scattered RER cisternae.

Previously, intercalated ducts were considered as passive conduits for transfer of secretory products from end-pieces into intralobular ducts; however according to Young and van Lennep (1978) and Pinkstaff (1980) this is an oversimplification. Histochemical and ultrastructural studies have demonstrated a possible secretory role for these ducts in some species. Secretory granules have been reported in epithelial cells of intercalated ducts of sheep parotid (van Lennep et al., 1977) and bovine mandibular glands (Shackleford and Wilborn, 1970; Bloom and Carlsoo, 1974).

1.2.7 Intralobular Ducts

Intercalated ducts are continuous with intralobular ducts which often exhibit distinct eosinophilic basal striations. This cytoplasmic feature is responsible for intralobular ducts being frequently referred to as "striated" ducts. However, the term intralobular duct seems more appropriate as basal striations are not evident in intralobular duct cells of all salivary glands. In addition the "granular" ducts of rodents interposed between intercalated and striated ducts are also part of the intralobular duct system.

Ham and Cormack (1979) have described the principal cell type lining intralobular ducts to be tall columnar with basal striations; however, cuboidal cells with poorly developed basal striations have been found in some species (Young and van Lennep, 1978). In ruminants the duct cells are further specialised into three types, "light cells", "dark cells" and basal cells (Shackleford and Wilborn, 1969; 1970; Bloom and Carlsoo, 1974). Basal cells are rarely seen but when present are close to the basal lamina and do not

extend towards the duct lumen. Their cytoplasm contains scattered RER, few mitochondria and some intracellular fibrils. The dark cells are characterised by an electron dense cytoplasmic ground substance, an irregular nucleus and closely packed cytoplasmic organelles. The more common light cell has a spherical, centrally-placed nucleus and extensive basal membrane foldings housing abundant mitochondria oriented parallel to the plasmalemmal foldings. The basal striations are due to infoldings of the basal cell membrane. Lateral plasmalemmal foldings are observed towards the base of the cell.

In general, striated ducts are well developed in proteoserous glands but poorly developed or absent in mucous glands and minor salivary glands, with the exception of the ventral buccal glands of ruminants. Although the above pattern has been observed in salivary glands of sheep (van Lennep et al., 1977), the parotid glands of cattle are an exception in that the intralobular ducts show a marked lack of basal striations (Shackleford and Wilborn, 1969; Pal, Chandra and Bharadwaj, 1972; Pinkstaff, 1980; Vignoli and Nogueira, 1981). However striated ducts are well developed in bovine mandibular and sublingual glands.

It is generally accepted that striated ducts of sheep enable the animal to secrete a hypotonic saliva (depending on its sodium status) by reabsorption of sodium ions (Young and van Lennep, 1979). The abundant basal mitochondria suggest a possible active transport mechanism for striated ducts while the lack of mitochondria or basal striations may indicate secretion of an isotonic saliva with little reabsorption of ions.

Apart from basal plasmalemmal infoldings the striated duct cells show apical modifications of two varieties; microvilli and "apical blebs", (Pinkstaff, 1980). "Apical blebs" have been variously described as fixation artifacts or stages of an apocrine secretion process (see Young and van Lennep, 1978). The cytoplasm of intralobular duct cells

contains a few scattered RER cisternae and a Golgi complex situated apical to the nucleus.

Intralobular ducts are additionally engaged in the synthesis of secretory material (Young and van Lennep, 1978; Pinkstaff, 1980). Enzymes such as kallikrein, peroxidase, lysozyme and the secretory component of IgA have been identified in striated duct cells (Young and van Lennep, 1978).

In sheep and cattle, an additional intraepithelial duct cell has been described in the walls of intralobular ducts. In cattle, these cells have been called "intrastriated" duct cells by Shackelford and Klapper (1962) and Birtles (1981) while in sheep, van Lennep et al. (1977) described them as "globule leucocytes". One of the aims of the present study is to investigate these "intrastriated" duct cells more closely.

1.2.8 Excretory Ducts

The excretory ducts are usually interposed between intralobular ducts and the main excretory duct. More than one type of excretory duct may be present; an interlobular duct located in the interlobar connective tissue septa between lobules and an interlobar duct in connective tissue septa between lobes.

The epithelium of excretory ducts can vary considerably ranging from simple columnar to stratified cuboidal or stratified columnar. Typically the main excretory duct is lined by stratified columnar or in some glands, with pseudostratified columnar epithelium with goblet cells.

Histochemical studies have shown that excretory ducts possess considerable secretory activity: Kallikreins and succinate dehydrogenase are among the many enzymes isolated (see Pinkstaff, 1980 for review of excretory duct secretory products). Young and van Lennep (1979) have indicated that excretory ducts may be involved in further modification of

the saliva from the secretory endpieces and striated ducts.

The excretory duct lining changes to stratified squamous epithelium a short distance before it becomes continuous with the oral cavity.

1.3 Bovine Salivary Composition

The composition of bovine saliva can be divided into an inorganic component composed of electrolytes and water, and an organic component of mucosubstances, proteins and urea.

On the basis of numerous micropuncture studies on the major salivary glands of various species, it is now generally accepted that salivary gland endpieces secrete an isotonic primary fluid having an electrolyte composition similar to plasma (Schneyer, Young and Schneyer, 1972). The secondary or final saliva that emerges into the oral cavity is primary saliva which has undergone ductal modification.

Although the composition of electrolytes elaborated by an endpiece are secondarily modified by the duct system, there is no evidence to suggest that the mucosubstances secreted simultaneously by the endpiece cells also undergo further modification. It is generally assumed that water secreted along with electrolytes dissolves and flushes out the more viscous mucosubstances (Young and van Lennep, 1979).

1.3.1 Secretion of Water and Electrolytes

As early as the last century, Ludwig (1851), observed that saliva could be secreted at pressures in excess of blood pressure. Investigations by Heidenhain (1878) further established that saliva was produced as a result of a secretory process rather than an ultrafiltrate of plasma, by observing changes in intensity and duration of nervous stimulation which caused salivary flow rates to vary widely with subsequent changes in salivary electrolyte composition. Thaysen, Thorn and Schwartz (1954) extended Heidenhain's (1878) findings and formulated a two stage hypothesis of salivary secretion to account for the variation in electrolyte composition with salivary flow rate. In the first stage it was postulated that a precursor (primary) saliva

was produced in the endpiece region with an electrolyte concentration similar to plasma. In the second stage, it was proposed that primary fluids delivered to the duct system underwent changes in electrolyte composition by a ductal mechanism with a limited maximum transport capacity.

1.3.2 Primary Saliva

It has been established that primary saliva produced by secretory endpieces is due to an active transport process initiated by neural stimulation. This secretory process may involve the transfer of sodium and other inorganic ions derived from plasma across the distal segment of the secretory endpiece into its lumen (Schneyer and Emmelin, 1974). Water is transferred passively since no evidence exists that active transport of water occurs (Schneyer et al., 1972).

As yet, there is no widely accepted theory or model to account for water and electrolyte transport in salivary glands. Evidence pertaining to this process in secretory endpieces is usually by analogy with available data on ionic transport across intestinal epithelia and proximal tubules of the kidney. Despite the paucity of data available on epithelial membrane potentials in secretory endpieces, it has been postulated that endpiece epithelium is of the "leaky" type (Schneyer et al., 1972), with potentiality to transport large volumes of fluid isototically. It is widely held (Petersen, 1980) although not proved, that transported ions and water pass via paracellular channels across intercellular junctional complexes and that an active transcellular flux of at least one ion is likely to occur.

One model for ionic transport proposed by Frizzell, Field and Schultz (1979) involved a tightly coupled electro-neutral Na^+Cl^- co-transport protein located in the basal plasma membrane of the secretory cell. Most secretory epithelia maintain Na^+ and K^+ ions at electrochemical potentials widely displaced from equilibrium. It has been postulated that the diffusion of Na^+ into the cytoplasm concentrates

Cl^- in the cytoplasm against an electrochemical gradient established by Na^+ , K^+ -ATPase located in the basolateral plasma membrane. Under this proposed model Cl^- would then move passively into the endpiece lumen across the apical cell membrane by an undefined mechanism. This ion flow is thought to initiate a secretion process (electrostatically and osmotically) in which most of the secreted ions and water enter the lumen by a paracellular route, composed of intercellular spaces and secretory canaliculi. Such a mechanism is known to be thermodynamically sound (Cook and Young, 1981) but an explanation remains to be found to demonstrate how junctional complexes can be adequately permeable to ions and water and yet maintain a high reflexion coefficient to the secretion ion (Hill, 1980).

Diamond and Bossert (1967) proposed a model which emphasised the geometrical features of epithelia specialised for ionic transport. The lateral intercellular channels identified universally in electrolyte transporting epithelia may establish standing osmotic gradients that could facilitate the production of an isotonic secretion even though secretory rates may be changed by up to three orders of magnitude.

Well developed lateral intercellular channels and secretory canaliculi have been described in parotid gland proteoserous cells of the bovidae (Young and van Lennep, 1978).

The inorganic composition of the primary secretion in ruminant salivary glands has received little attention until recently when Compton, Nelson, Wright and Young (1980) investigated parotid saliva of sheep in relation to the sodium status of the animal.

The primary saliva sodium concentration of sodium replete sheep was found to be isotonic and independent of salivary flow rate. However, in sodium depleted sheep primary saliva sodium concentration was very low and the plasma-like

osmolality of the primary fluid was composed of an unidentified solute. According to Compton et al. (1980) this solute may be a low molecular weight organic compound which is reabsorbed and utilized by the duct cells since it was absent from final saliva. This unidentified organic compound would also have to be non-ionized or poorly ionized as the summed sodium and potassium concentration in primary saliva corresponds closely to the summed chloride, phosphate and estimated bicarbonate concentrations.

In contrast with the sodium concentration of primary saliva, potassium concentration did not differ significantly between sodium replete and sodium depleted sheep. On the basis of available micropuncture data, Young and van Lennep (1979) concluded that potassium is concentrated in the cytoplasm of endpiece cells by basally located Na^+ , K^+ ATPase and that the ion enters saliva across the apical membrane by a passive process.

Compton et al. (1980) in their investigations of the anion content of primary saliva concluded that the sodium status of the animal had little effect on the concentrations and excretory patterns of salivary anions. On average the concentrations of bicarbonate, chloride and phosphate ions did not differ significantly between sodium replete and sodium depleted sheep. In addition all phosphate ions appearing in final saliva were found to have been secreted during the formation of primary saliva, while bicarbonate ions appeared to be secondarily secreted by the duct system. Chloride ions entering primary saliva across the secretory endpiece epithelium could be reabsorbed during secondary modification of saliva by the duct system.

1.3.3 Final Saliva

The second step of saliva formation originates distally in the striated and excretory ducts of the salivary glands. The ducts reabsorb sodium and chloride ions and secrete potassium and bicarbonate ions. Reabsorption by the duct

epithelium occurs at a faster rate than secretion and ductal permeability to water is low, hence, final saliva is mainly hypotonic (Schneyer and Schneyer, 1960). However, the magnitude of the ionic changes in final saliva often depends on the species, the gland and the nature and intensity of the stimulation of secretory cells (Schneyer and Emmelin, 1974). For example, in ruminants the final saliva produced by the parotid gland may be either hypotonic or isotonic depending on the sodium status of the animal (Compton et al., 1980) whereas saliva formed by the mandibular and sublingual glands has been shown by Kay (1960) to be hypotonic.

Ultrastructurally, striated and excretory duct cells show morphological features characteristic of secretory and absorptive epithelia (Schneyer et al., 1972). The presence of luminal clefts between adjacent cells and basal infoldings provides fluid columns oriented in lateral and basal aspects of cells. Tight junctions located at the basal extremities of the clefts prevent direct continuity with lateral intercellular spaces. The presence of luminal clefts creates a double standing gradient in series which ensures luminal hypotonicity. The first gradient could be formed in the lateral intercellular space between tight junctions and basal border of the epithelial layer by active transport of sodium out of the cell into the intercellular space. The second gradient could be created in the luminal cleft from the apical cell borders to the tight junction and established by passive sodium transport from luminal fluid into the cell. Since the permeability of duct epithelia to water is generally low, both standing gradients contribute to luminal hypotonicity. Other standing gradients formed luminally between microvilli and basally between plasmalemmal plications or infoldings also contribute to the development of luminal hypotonicity.

The final saliva osmolality of the sheep parotid is additionally dependent on the sodium status of the animal (Compton et al., 1980). The duct systems of the sheep parotid glands were unique in possessing the capacity

to cease all net sodium and potassium transport activity in sodium replete animals. The final saliva produced was therefore isotonic and failed to exhibit flow dependency while sodium depleted animals produced hypotonic saliva particularly at low flow rates with maximum ductal sodium reabsorption.

Reported levels of potassium in parotid saliva of sodium depleted animals may be indicative of a higher rate of ductal secretion than that which occurs during the formation of primary saliva. In sodium replete animals, the final salivary potassium concentration was lower than in primary saliva indicating that potassium was mostly reabsorbed by the duct epithelium.

The bicarbonate content in final parotid saliva of the sheep was considerably greater than in primary saliva indicating that ductal secretion of the ion has occurred either directly or indirectly, (by absorbing hydrogen ions). Furthermore, salivary bicarbonate concentration was not dependent on the sodium status of the animal.

Phosphate and chloride levels also appeared to be uninfluenced by the animal's sodium status. Both phosphate and chloride ions in final saliva were reported to be totally derived from the primary fluid with no ductal secretion but some chloride appeared to be reabsorbed during secondary modification by the duct system.

It is uncertain, without further investigation, whether the findings of Compton et al. (1980) could equally apply to bovine parotid glands, although existing reports indicate that parotid secretions of cattle are likely to be purely isotonic (Pinkstaff, 1980).

In addition to Compton et al. (1980), the inorganic composition of final saliva in ruminants has been studied by Philipson and Mangan (1959); Kay (1960); Bailey and Balch (1961) and reviewed by Church (1976) and Bartley (1976).

Kay (1960) investigated the electrolyte composition of parotid, mandibular and sublingual gland secretions as well as the "residual" saliva from the minor salivary glands of sheep and cattle.

The parotid glands were found by Kay to continuously secrete large quantities of well-buffered isotonic saliva while the mandibular and sublingual glands secreted relatively small quantities of weakly buffered hypotonic saliva with a high mucous content. Kay (1960) failed to observe the relationship between sodium status and osmolality of parotid saliva reported by Compton et al. (1980), but reported a negative correlation between Na^+ and K^+ and HCO_3^- and HPO_4^{--} while the K^+ and Cl^- levels were similar to those of parotid saliva. Mandibular salivary secretion in particular, was found to be influenced by the rate of secretion and the $\text{Na}^+ : \text{K}^+$ ratio was depressed by sodium depletion.

Of the minor salivary glands investigated by Kay (1960) the ventral buccal was found to be identical to the parotid with respect to composition of the secretion, histology and rate of secretion per gram of secretory tissue. The palatine, intermediate and dorsal buccal and pharyngeal glands were predominantly mucous secreting with a similar ionic composition to parotid saliva, although the Na^+ levels differed with little or no reduction in concentration with sodium depletion. The minor salivary glands were also found to produce isotonic secretions and their combined volume of saliva was approximately equal to that secreted by the parotid glands.

Salivary nitrogen is an inorganic element of considerable metabolic importance to rumen microorganisms. The nitrogen content of bovine saliva is mainly in the form of urea and salivary proteins. Parotid saliva contributes approximately 75-85% of the total nitrogen as urea and the protein secreted by the mandibular gland provides the remaining 15-25%, particularly during feeding when much higher concentrations

of nitrogen are utilized (Phillipson and Mangan, 1959).

The stimulus for the secretion of saliva and control of electrolyte composition of saliva is mainly provided by parasympathetic and sympathetic nerves. The control of salivary secretion will be discussed in Section 1.4.

1.3.4 Organic Secretory Products

Like inorganic constituents, the organic composition of saliva varies considerably between species and between different glands of the same species. The nature of the secretory stimulus is an additional factor which may cause variations in composition of saliva.

Generally, the organic content of saliva is provided by the mandibular, sublingual and minor salivary glands (Leeson, 1967), but the parotid glands are known to synthesise and secrete some proteinaceous material, the composition of which varies depending on species (Young and van Lennep, 1978). For example, significant quantities of organic material have been isolated from ruminant parotid saliva (Table 1.1) (Patterson, Brightling and Titchen, 1982).

Organic components of salivary secretion can be divided into two broad categories, dependent on whether the secretory product is derived directly from plasma or synthesised and secreted by the glandular epithelium (Young and van Lennep, 1979). Extrinsic proteins are derived from plasma and secreted without modification via the glandular epithelium into the saliva. Organic compounds such as albumin, orosomucoid, caeruloplasmin, B₂-lipoprotein, transferrin, B₂-macroglobulin, urea and immunoglobulins are some extrinsic proteins identified in saliva. Of the salivary immunoglobulins, IgG and IgM appear to be extrinsic, while IgA is probably intrinsic, being synthesised in glandular plasma cells and subsequently modified by conjunction to secretory component synthesised by striated duct cells

Table 1.1

BOVINE SALIVARY PROTEINS I(Low Molecular Weight Fraction)

| Protein Band | Parotid Gland | Mandibular Gland | Sublingual Gland | Int. Buccal Gland | PAS Reaction | Apparent Molecular Weight \pm S.D. | Number of Bands observed upon isoelectric focussing |
|--------------|---------------|------------------|------------------|-------------------|--------------|--------------------------------------|---|
| 1 | + 1(a) (b) | + 1(c) | - | + | ++ | ? | 2 |
| 2 | ? | ? | ? | ? | + | ? | 5 |
| 3 | + 3(a) | + 3(b) | - | + | ++ | ? | 6 |
| 4 | +++ | - | - | traces | - | 140000 \pm 8000 | 3 |
| 5 | ++ | - | - | traces | ++ | 36000 \pm 2000 | 4 |
| 6 | + | - | - | traces | + | 36000 \pm 2000 | 4 |
| 7 | + | - | - | + | - | 53000 \pm 2000 | 1 |
| 8 | - | +++ | - | + | - | 50000 \pm 2500 | 5 |
| 9 | - | - | +++ | + | - | 43000 \pm 2000 | 3 |
| 10 | ++++ | - | - | + | - | 32000 \pm 2000 | 5 |
| 10s | ++++ | - | - | + | - | 32000 \pm 2500 | 6 |
| 10d | ++++ | - | - | + | - | 25000 \pm 2000 | 3 |

(Source: Dr. W.T. Jones, D.S.I.R., Palmerston North, New Zealand.)

(Young and van Lennep, 1978).

Mucous cells and to a lesser extent proteoserous cells are responsible for producing most of the intrinsic proteins of saliva, namely glycoproteins or mucosubstances, polypeptides and enzymes. Glycoproteins and polypeptides produced by the secretory endpieces constitute the predominant intrinsic organic components, since, in ruminants, it has been reported that the enzyme content of saliva is negligible (Church, 1976).

Salivary gland duct cells have also been implicated in the production of intrinsic proteins (Young and van Lennep, 1978). Glycoproteins and peptides of ductal origin include the secretory component of IgA, enzymes such as kallikrein and carbonic anhydrase and numerous growth factors manifesting various functions (Barka, 1980). A nerve growth factor, and an epithelial growth factor known as "Parotin" have been isolated from bovine parotid gland duct cells by Hoffman, McAuslan, Robertson and Burnett (1976).

In the present study an attempt has been made to examine histochemically the composition of the intrinsic proteins produced by bovine salivary glands.

1.3.5 Synthesis and Secretion of Proteins and Mucosubstances

The synthesis of exportable proteins from secretory cells is primarily controlled by genetic information stored in the DNA molecule segregated in the cell nucleus (Ham and Cormack, 1979). One double-stranded DNA molecule consists of four nucleotide bases, adenine, thymine, guanine and cytosine. The sequence of the bases on the DNA strands determines the order in which amino acids required for protein synthesis appear on a peptide chain or protein molecule. The genetic information on DNA strands are next translated with a complementary base sequence into a single-stranded messenger RNA (mRNA) molecule which migrates from

the nucleus to the cytoplasm to initiate protein synthesis. The mRNA molecules are in turn attached to ribosomes present in RER; multiple ribosomes aligned on a mRNA molecule are referred to as polysomes.

The amino acids required for protein synthesis are extracted from the extracellular amino acid pool into the cell by active transport (van Venrooij, Kuijper-Lenstra and Kramer, 1973). After uptake, the amino acids are attached to transfer RNA (tRNA) molecules, and then transferred to ribosomes bound to mRNA. The recognition of mRNA sites with complementary bases on tRNA releases amino acids from tRNA molecules to react with a terminal amino acid in an elongating polypeptide chain found in polysomes. The secretory polypeptide molecule then enters the lumen of the RER cisternae through membrane pores and is sequestered from the cytoplasm (Palade, 1975).

The secretory polypeptide molecules from RER are transferred by transitional vesicles to the Golgi complex, condensing vacuoles and finally to secretory granules. The function of the Golgi complex is mainly to accept the transitional vesicles, modify their contents and distribute the secretory products via condensing vacuoles towards the cell apex in preparation for export extracellularly.

Carbohydrate molecules required for incorporation into the polypeptide backbone of a glycoprotein molecule appear to be synthesised in the Golgi complex (Palade, 1975). N-acetylglucosamine and N-acetylgalactosamine are added to the polypeptide chain with sialic acid and fucose as terminal residues; the membranes of the Golgi complex contain the necessary glycosyltransferase enzymes required for transfer of residues. Sulphation of glycoproteins is also probably completed in the Golgi complex.

In the next stage of the synthetic process, the secretory products from the Golgi complex are transported in Golgi vesicles to condensing vacuoles, where the secretory product

is concentrated by a withdrawal of water (Palade, 1975). Condensing vacuoles develop first into immature and then mature secretory granules by a further process of condensation. In a proteoserous cell this results in the formation of discrete homogeneous electron dense granules. In contrast, since very little condensation occurs in mucous cells, the granules of these cells are larger and electron lucent. The secretory granules thus formed are stored in the apical cytoplasm and either discharged into the lumen or if no stimulation occurs, degraded by lysosomal enzymes (Young and van Lennep, 1978).

Discharge of serous and seromucous granules occurs by exocytosis (Palade, 1975) where the membrane of the secretory granule fuses with the apical plasma membrane bordering the central lumen or an intercellular secretory canaliculus of an endpiece. The fusion of the two membranes is followed by perforation which allows the granule contents to escape into the lumen without disruption of the integrity of the plasma membrane or loss of cytoplasm. In salivary glands cells chain exocytosis is a common feature. This involves fusion of membranes of a whole row of granules each acting as an extension of the lumen (Young and van Lennep, 1978). After exocytosis surface membrane is recovered and returned to the Golgi cisternae, presumably to be reutilized for newly synthesised secretory products (Palade, 1975). However, the precise pathways taken by surface membrane to reach the Golgi complex remains to be established. The available evidence (Herzog, 1981) indicates a likelihood that both a direct route from surface membrane to Golgi complex and an indirect route involving lysosomes, may be present in different cell types for cell membrane turnover.

The mechanism of discharge of typical mucous granules appears to differ from that of proteoserous granules (Young and van Lennep, 1978). Although existing evidence is far from conclusive, Kim, Nasjleti and Han (1972) have suggested that apical mucous granules upon stimulation fuse to form a large mucous droplet, which when discharged

through a wide gap in the apical plasma membrane leaves an open space within the cell. The mucous droplet was found to carry portions of plasma membrane with it, including its own outer membrane. This loss of integrity of the cell membrane during exocytosis is in sharp contrast to proteoserosous cells which are believed to recycle the membranes of secretory granules. Mucous cells are thus probably capable of regenerating a new cell membrane with the aid of numerous cytoplasmic vesicles around the intracellular space. However, Tandler and Poulsen (1976) have indicated that mucous granules are normally discharged by a process of exocytosis similar to that observed in proteoserosous cells. It is therefore unclear whether the observed difference reflects variations in the mechanism of exocytosis or whether earlier observations were due to fixation artifacts.

The above description of synthesis and secretion of proteins and glycoproteins has mainly concentrated on proteoserosous and mucous cells. The synthetic and secretory mechanisms for other types of cells appear to vary (Palade, 1975). In plasma cells, for example, the concentration step has not been identified, intracellular storage is reduced in duration or eliminated and discharge of secretory material seems to occur continuously. Additionally the equivalent of a secretory granule has not yet been identified (see Palade, 1975).

1.3.6 Composition of Bovine Salivary Mucosubstances

Salivary gland mucosubstances are biochemically and histochemically similar to those derived from gastrointestinal, respiratory and reproductive tract epithelia.

In this section, the biochemical aspects of mucus will be reviewed with particular reference to bovine salivary gland mucous secretions. Histochemical aspects will be examined in Chapter 2.

Epithelial mucous secretions consist mainly of glyco-

proteins, compounds with a polypeptide backbone and attached carbohydrate residues which may be either acidic or neutral (Shreeve, 1974). Of the amino acids identified in the protein core, serine and threonine represent more than 50% of the total amino acid composition, other amino acids that occur in appreciable amounts include alanine, glycine and proline (Herp, Wu and Maschera, 1979). Herp and his associates have also reported that the predominant carbohydrate groups that occur in glycoproteins are sialic acid and N-acetylgalactosamine, with fucose, galactose and mannose occasionally present in variable proportions. The carbohydrate side chains are joined by O-glycosidic bonds to hydroxyl residues of threonine and serine, via an intermediary compound, N-acetylgalactosamine, while their terminal non-reducing positions are always occupied by sialic acid and fucose residues. Sialic acid in particular imparts considerable viscosity to saliva because the mutual repulsion of carboxyl groups stiffens the random coil of the glycoprotein molecule (Shreeve, 1974). Glycoproteins are also thought to be sulphated (Pamer, Jerzy Glas and Horowitz, 1968); such sulphated glycoproteins have a high valine content in the protein core but the exact nature of the sulphate residue or its chemical combination with the protein core is poorly understood.

According to Shreeve (1974) other properties of glycoproteins are:-

- (i) frequent branching of side chains
- (ii) there are few or no repeating units present
- (iii) the monosaccharide residues number about 25 or less.

Apart from glycoproteins some acid mucopolysaccharides may also be present in epithelial mucosubstances. However, acid mucopolysaccharides are predominantly localised in connective tissue elements and consist mainly of chondroitin sulphates and hyaluronic acid residues on a polypeptide backbone. In contrast to glycoproteins, acid mucopolysaccharides contain a smaller polypeptide component and the

side chains are linear with little or no branching (Shreeve, 1974). However, it is not unlikely that epithelial mucosubstances may consist of a protein core which could carry a mixture of carbohydrate residues of glycoproteins and acid mucopolysaccharides. Therefore, in general, use of the term mucosubstance when referring to epithelial secretions indicates the presence of both glycoproteins as well as some acid mucopolysaccharides. The preference for the term "mucosubstance" instead of glycoproteins or mucopolysaccharides will be discussed in Chapter 2.

In bovine salivary secretions the mucosubstances and proteins identified have been classified into three groups: (i) bovine salivary mucoprotein (BSM), (ii) oesophageal mucoprotein (OSM), and (iii) low molecular weight protein (LMP) (Jones, Gurnsey, Birtles and Reid, 1977). The high molecular weight, BSM and OSM fractions (Table 1.2) are glycoproteins with protein contents of 60% w/w and 30% w/w respectively, of which 69% and 75% of the protein consists of valine, threonine, serine, alanine, glycine and proline. OSM has an unusually high valine content (21%). The major carbohydrate components identified were sialic acid and amino sugars. Herp et al. (1979) further identified eight different derivatives of sialic acid in bovine salivary mucoprotein with N-acetylneuraminic acid, N-glycolylneuraminic acid and N-acetyl, 9-o-acetylneuraminic acid as the predominant types. OSM is secreted by the sublingual, intermediate and dorsal buccals, palatine and pharyngeal glands, while BSM is secreted by the mandibular glands.

The low molecular weight protein fraction (Table 1.1) has been separated into twelve components or bands (Jones, Broadhurst and Gurnsey, 1982). The twelve proteins have been numbered in order of their electrophoretic mobility. Of the twelve proteins the majority were present in secretions produced by the parotid, ventral and intermediate buccal glands, with bands 4 and 10 predominant in parotid and ventral buccal saliva. Band 3 and band 8 have been identified in mandibular saliva while band 9 was found to be

Table 1.2

BOVINE SALIVARY PROTEINS II
(High Molecular Weight Fraction)

| Amino Acid | BSM Fraction | | OSM Fraction | |
|---------------|--|---------|--|---------|
| | comp. % | mole. % | comp. % | mole. % |
| Glycine | 18.2 | 23 | 6.7 | 8 |
| Valine | 8.4 | 10 | 21.0 | 26 |
| Serine | 15.5 | 20 | 10.28 | 13 |
| Threonine | 6.0 | 7 | 18.3 | 28 |
| Alanine | 13.3 | 6 | 10.9 | 14 |
| Proline | 8.53 | 11 | 8.54 | 11 |
| Lysine | 1.6 | 2 | 1.23 | 1 |
| Histidine | 0.85 | 1 | 0.86 | 1 |
| Isoleucine | 2.9 | 4 | 1.35 | 2 |
| Tyrosine | 1.0 | 1 | 1.13 | 2 |
| Phenylalanine | 1.3 | 2 | 1.13 | 2 |
| Arginine | 4.5 | 6 | 4.5 | 6 |
| Aspartic | 4.5 | 6 | 3.68 | 4 |
| Glutamic | 7.4 | 8 | 6.7 | 8 |
| | Secreted by the mandibular glands, with 60% w/w protein and 20% w/w sialic acid. | | Secreted by the sublingual and minor glands, with 30% w/w protein and 20% w/w sialic acid. | |

(Source: Dr. W.T. Jones, D.S.I.R., Palmerston North, New Zealand.)

present in sublingual saliva. Bands 2 and 7 were further classified as extrinsic proteins because they cross reacted with antibodies raised against bovine serum. Bovine salivary bands 1, 2, 3, 5 and 6 were found to be glycoproteins while the remainder were classified as peptides.

1.4 Control of Salivary Secretion

Saliva is usually secreted in response to stimulation from autonomic innervation of the glands or by pharmacological agents mimicking the action of autonomic neurotransmitters (Emmelin, 1967). Salivary gland endpieces and ducts are innervated by parasympathetic and sympathetic secretomotor fibres but the parotid glands of sheep and cattle exhibit a spontaneous secretion (Kay, 1960) that persists in the absence of neuronal and humoral stimuli (Babkin, 1950).

In the production and flow of saliva parasympathetic and sympathetic nerves generally cooperate, although, particularly in sympathetic innervation, variations between the different salivary glands are considerable. The secretomotor nerves in general initiate the formation of primary saliva in endpieces and effect the absorption and secretion of certain ions by the ducts. In addition they stimulate exocytosis of granules containing macromolecules such as glycoproteins from the endpieces as well as kallikrein from the ducts (Emmelin, 1967).

The composition of saliva is also influenced by the nature of the secretory nerves. Parasympathetically evoked saliva exhibits considerable species variation in the excretory patterns of the major electrolytes, Na^+ , K^+ , Cl^- , HCO_3^- and PO_4^{--} ions (Young and van Lennep, 1979). The duration and intensity of parasympathetic stimulation also affects the inorganic composition of saliva (Schneyer et al., 1972). The inorganic composition immediately after stimulation differs from that during steady state secretion owing to alterations in cellular permeability. An increase in intensity of the stimulus changes salivary flow rate with a consequent change in electrolyte concentrations. The steady state secretory levels reached by most ions are also highly variable both among species and individual glands (Young and van Lennep, 1979).

Sympathetically evoked saliva has received comparatively little attention, however, α -sympathetic receptors when stimulated produce a response similar to parasympathetic saliva while the β -sympathetic response elicits only a sparse quantity of viscous saliva rich in organic material (Young and van Lennep, 1979).

The secretory and absorptive processes of the ducts have long been suspected to be controlled by autonomic nerves (Schneyer and Emmelin, 1974). It appears that sympathetic stimulation usually modifies parasympathetic effects in controlling ductal electrolyte transport activity with little effect on ductal water permeability (Young and van Lennep, 1979).

Myoepithelial cells which serve to accelerate the salivary flow upon contraction are innervated mainly by sympathetic motor fibres that exert their effect via α -receptors (Garrett and Emmelin, 1979). However, both parasympathetic and sympathetic motor nerves appear to act in cooperation to produce maximal contraction of the myoepithelial cells (Garrett and Emmelin, 1979).

In contrast to secretory endpiece, duct and myoepithelial cells, the classical antagonism between parasympathetic and sympathetic effects is found in the innervation of the vasculature to the salivary glands. The blood vessels of salivary glands receive sympathetic vasoconstrictor nerves (acting on α -receptors) and parasympathetic vasodilator nerves (Emmelin, 1967), both of which contribute to the adaptation of the blood flow to the requirements of the glandular tissue. Blood vessels to the glands are additionally controlled by vasodilator polypeptides such as physalaemin and eledoisin (Emmelin, 1971) and substance P from bovine hypothalamus (Leeman and Hammerschlag, 1967). These substances induce secretion which cannot be inhibited by specific parasympathetic and sympathetic blockers (Emmelin, 1971). Recently, additional polypeptide neurotransmitters have been shown to possess vasodilatory activity. These

vasoactive intestinal polypeptide (VIP) containing nerve fibres have been identified in close contact with secretory endpieces, ducts and blood vessels (Polak and Bloom, 1980). As a result of sympathetic stimulation, salivary gland duct cells are reported to release kallikrein, which could further modify salivary flow rate by constriction of arterioles, dilation of venules, increase in capillary permeability and release of prostaglandins and cyclic GMP (Ørstavik and Gautvik, 1977). Duct cells are additionally known to be under endocrine control, particularly from mineralocorticoid hormones such as aldosterone. In ruminant salivary glands aldosterone action on duct cells could increase sodium reabsorption in sodium depleted sheep (Blair-West, Coghlan, Denton, Nelson, Wright and Yamauchi, 1969).

Neural control of salivary secretion in ruminant species has been investigated with reference to the sheep parotid (Coats, Denton, Goding and Wright, 1956; Kay, 1958; Patterson and Titchen, 1979) and mandibular (Ariyakulkal, 1981) glands. Preliminary findings of parasympathetic and sympathetic effects on bovine parotid and mandibular glands have been reported by Phillipson and Mangan, (1959).

The innervation of parasympathetic secretomotor nerves to the sheep parotid gland, produces saliva rich in inorganic ions, water and some protein (Young and van Lennep, 1979). The sympathetic response of the sheep parotid has been previously investigated with reference to an α -sympathetic motor effect causing a mechanical expulsion of saliva from the parotid gland (Coats et al., 1956). However, more recently an additional β -sympathetic secretory component has been reported for the sheep parotid by Patterson and Titchen (1979). This was shown to cause a net increase in the amount of fluid formed accompanied by a significant elevation in the protein content of parotid saliva. Patterson et al. (1982) extended the above findings and concluded that protein concentrations of parotid saliva were increased mainly upon feeding and waned rapidly after feeding. However it was not established whether para-

sympathetic as well as sympathetic influences contribute to the increase in protein secretion observed on commencement of feeding. Patterson et al. (1982) additionally reported on an increase in K^+ , Cl^- and Mg^{++} ions during sympathetic innervation of the parotid glands, with an unexplained positive correlation between magnesium and protein concentrations in parotid saliva.

Neural control of the sheep mandibular gland has been recently investigated by Ariyakulkaln (1981). The mandibular gland mucous cells were demonstrated to be predominantly under parasympathetic control while the demilunes were under sympathetic control. Furthermore, the mandibular salivary protein secretion appeared to be primarily mediated via a β -adrenergic mechanism and the secretion of water, electrolytes and mucus appeared to be under parasympathetic innervation.

In addition to parasympathetic and sympathetic effects, it is well established that salivary secretion in ruminants is influenced by reflex control (Coats et al., 1956; Kay, 1958; Ash and Kay, 1959; Kay and Phillipson, 1959). The receptors responsible for reflex control are found in the oral cavity, oesophagus, rumen and reticulum. These receptors stimulate or inhibit salivary secretion during feeding and rumination and are effective especially for fibrous diets (Kay, 1966). The various examples cited above serve to illustrate the possibilities that may exist which could vary the flow rate and composition of saliva at the neuro-effector level.

1.5 Mucosal Immunity

Within the last two decades considerable attention has been focussed on immune mechanisms of mucosal surfaces since these are intimately associated with potentially pathogenic organisms and continuously exposed to antigenic stimulation from environmental and dietary antigens. The mucosa of the oral cavity in particular is associated with such stimuli.

The surfaces of all mucous membranes are primarily protected by a layer of mucus which is effective against attack from microorganisms. Mucous secretions may contain attachment sites for pathogenic bacteria that physically entrap and immobilise the organism and prevent infection or penetration of underlying epithelial cells (Lindley, 1980). The protective role of mucus is additionally augmented by the presence of antibacterial proteins such as lysozyme and lactoferrin. Lysozyme, for example, interacts with sialic acid residues of the mucus layer and against neuraminic acid containing bacterial cell walls (Creeth, Bridge and Horton, 1979). Lactoferrin complexes iron (an essential mineral for microorganisms) present in secretions, thereby denying it to the organism (Emery, 1980). Ruminant saliva is particularly rich in mucus (Jones et al., 1977), and its protective functions may extend beyond the oral cavity to the ruminant forestomach which lacks mucus producing cells and immunoglobulin synthesising plasma cells as mentioned in Section 1.

Humoral immunity at mucosal surfaces is mediated primarily by immunoglobulins such as secretory IgA, IgG, IgG₂, IgM and IgE (Tomasi, 1976). The major immunoglobulin in bovine saliva is SIgA (Mach and Pahud, 1971) which is composed of two monomers (7S) joined by a polypeptide (J chain) to produce dimeric (11S) IgA; the latter molecule is bound to a glycoprotein called secretory component (SC), synthesised by epithelial cells (Tomasi, 1976). Plasma cells of salivary gland stroma produce the dimeric IgA and the J

chain, while the endpiece duct cells are thought to produce the secretory component (Young and van Lennep, 1978). It is likely that the binding of the SC with dimeric (11S) IgA is essential for transcellular transport of sIgA from sub-epithelial sites to the duct lumen.

The presence of plasma cells differentiated to produce sIgA from salivary glands, without evidence of any precursor cells suggests that blast cells destined for synthesis of dimeric IgA are primed elsewhere then migrate to salivary gland tissues and differentiate into plasma cells (Tomasi, Larson, Challacombe and McNabb, 1980). The site or sites of origins of blast cells programmed to reach salivary gland tissue and the antigen recognition sites in salivary glands are unknown. However, it appears that a common mucosal associated lymphoid tissue system (MALT) which includes the gut, lung, mammary glands, salivary and lacrimal glands could be involved in the transport of precursor cells of sIgA among each of the secretory sites (Tomasi et al., 1980). This may enhance proliferation and retention of precursor cells locally in sites such as the salivary glands (Bienenstock, Befus and McDermott, 1981).

The effector functions of sIgA are varied depending on the nature of the antigen (Dobbins, 1982). In general, the close association between sIgA and mucus (Clamp, 1981) can interfere with the adhesion of organisms to epithelial surfaces and prevent their penetration into underlying tissue.

In ruminants, a distinction has been made between sIgA levels isolated from parotid and non-parotid saliva (Watson and Lascelles, 1971; 1973). It seems that in sheep the mandibular glands secrete very high concentrations of sIgA compared with the parotids (Cripps and Lascelles, 1976). Histological studies have shown a relative absence of plasma cells from parotid tissue when compared with the mandibular. Watson and Lascelles (1973) have further indicated that parotid saliva owing to its greater total salivary volume

could probably act as a diluent of IgA secreted by the mandibular and possibly the sublingual glands. The continuous flow of large quantities of parotid saliva could ensure that the gland receives relatively little local antigenic stimulation (Watson and Lascelles, 1973).

In the present study, a histological examination was conducted to identify those salivary glands of cattle which represent the major contributors of salivary sIgA.

In addition to sIgA, IgG, IgG₂, and IgM have been identified in significant concentrations in ruminant saliva (Table 1.3) (Watson and Lascelles, 1973). The levels of IgG, IgG₂ and IgM were 3.5 - 5.0 times higher in non-parotid saliva. IgG was reported as being selectively transferred across the glandular epithelium with some local synthesis while most of the IgG₂ and IgM were derived from plasma with minimal local synthesis. The secretion of IgM appears to be facilitated by complexing with J-chain containing polymers and membrane bound secretory component as a prerequisite for epithelial transfer; the mechanism is analogous to transport of sIgA (Tomasi et al., 1980). IgE, although described in external secretions (Tomasi, 1976) has not been quantitatively assayed in ruminant saliva (Butler, 1981). The absolute concentration of IgE in saliva is very small, however the ratio of salivary to serum IgE is high (Tomasi, 1976). The role of IgE in immediate hypersensitivity reactions is well documented (Strober, 1982), thus it is tempting to postulate that salivary IgE may be involved in poorly-understood mucosal allergic reactions. A possible transport mechanism (if any) for secretory IgE at mucosal surfaces has not been investigated, although Mayrhofer, Bazin and Gowans (1976) have suggested that in the rat, secretion of IgE may involve intraepithelial mast cells (or "globule leucocytes") which were found to contain intracytoplasmic IgE.

Studies on mucosal immunity thus far have largely focussed on humoral immune responses initiated by B-lympho-

Table 1.3 IMMUNOGLOBULIN COMPOSITION OF ADULT

RUMINANT SALIVA (mg/100 ml)

| Species | IgA | IgG | IgG ₁ | IgG ₂ | IgM | IgE |
|---------|-----|-----|------------------|------------------|-------|-----|
| Cattle | 56 | ? | 3 | 1 | 1 | ? |
| Sheep | 20 | 10 | ? | ? | trace | ? |
| Goat | 20 | 10 | ? | ? | trace | ? |

from Butler (1981).

cyte activated cell-mediated immunity at mucosal sites.

Whilst the factors controlling migration and localisation of T-blast cells in mucosal tissues are unknown, it has been reported by Guy-Grand, Griscelli and Vassali (1978) that they are derived from lymph nodes and subsequently migrate to the mucosa where most can later be identified as intraepithelial lymphocytes. Subpopulations of these cells are known to contain cytoplasmic granules with staining characteristics similar to mast cells (Rudzik and Bienenstock, 1974; Mayrhofer, 1980). Existing evidence reviewed by Mowat and Fergusson (1981) suggests that mucosal cell-mediated immunity involves primarily T-suppressor and T-cytotoxic cells in the epithelium. The suppressor cells may protect the epithelium from immune mediated damage caused by continuous antigen-antibody and antigen-cell interactions while the cytotoxic cells could provide a first line of cell-mediated defence when a group of epithelial cells are destroyed by a pathogen. The T-helper cells located mainly at subepithelial sites may be responsible for producing lymphokines, after interaction with antigens.

Investigations pertaining to the role of subepithelial or mucosal mast cells in immunoregulation at mucosal surfaces are only at a preliminary stage, however existing evidence suggests that these cells are probably derived from a lymphocyte subpopulation and are functionally implicated in inflammatory responses of the gut (Castro, 1982 ; Haig, Mckee, Jarrett, Woodbury and Miller, 1982).

Cell-mediated immunity in salivary gland tissue seems to have been totally unexplored. However, the findings described above regarding intestinal CMI may apply to other mucosal sites. In ruminants, the lack of B or T cells or their precursors in the forestomachs, highlights the probable importance of the protective functions of salivary gland lymphoid cells and secretions in these areas. In the present study an intraepithelial cell of unknown identity was

located in the ducts of the parotid and ventral buccal glands. One possibility is that this cell line may be involved in poorly understood mucosal immune reactions.

1.6 Salivary Secretions and Bloat Susceptibility

Bloat is a disorder of ruminants caused by a failure to successfully eructate gases produced in the reticulorumen during fermentative digestion. The retention of gas together with the formations of a stable foam, mechanically interferes with respiration and can be fatal within an hour of commencement of feeding (Clarke and Reid, 1974).

Evidence to date, reviewed by Clarke and Reid (1974) suggests that bloat is likely to be a complex multivariate disorder with interactions of environmental, plant, animal and microbial factors. However, recent investigations have focussed attention mainly on saliva and its association with bloat susceptibility in cattle (Reid, Gurnsey, Waghorn and Jones, 1975; Gurnsey, Jones and Reid, 1976; Jones et al., 1977).

Animals that are genetically predisposed to bloat and manifest a high susceptibility (H.S.) produce significantly less saliva than animals of low bloat susceptibility (L.S.) (McIntosh, 1975). Studies on the weights of individual salivary glands indicate that L.S. animals have a higher weight of secretory tissue, thereby contributing to an increased flow rate (Gurnsey, Reid, Jones and Birtles, 1977).

Biochemical analysis of saliva secreted by H.S. and L.S. cattle have demonstrated that the low molecular weight protein, band 4, isolated from parotid saliva, has been correlated with bloat susceptibility (McIntosh and Cockrem, 1977). Band 4 content in the reticulorumen of H.S. animals was found to be significantly greater than in L.S. animals. It is possible that salivary proteins and mucosubstances could act as surfactants to promote the formation of a stable foam that could retain the gases produced during fermentation. In the present study, parotid gland tissue from H.S. and L.S. cattle were examined immunohistochemically to observe the distribution of secretory cells responsible for producing band 4.

Bartley (1976) has suggested a possible involvement of salivary immunoglobulins to bloat, but at present any association between immunity and bloat in the absence of a preliminary investigation would remain hypothetical.

From histological studies of parotid and ventral buccal glands of cattle, preliminary observations have revealed an association between the occurrence of intrastriated duct cells and bloat susceptibility (Birtles, 1981). In L.S. animals the numbers of intrastriated duct cells observed were greater than in H.S. animals. In the present investigation the above findings were extended to examine the intrastriated duct cells in greater detail and postulate a possible relationship of these cells to bloat susceptibility.

CHAPTER 2. BOVINE SALIVARY GLAND HISTOLOGY AND HISTOCHEMISTRY

2.1 Introduction

Investigations by Shackelford and Klapper (1962); Quintarelli (1963a); Shackelford (1963); Shackelford and Wilborn (1968) and Birtles (1981) have demonstrated in considerable detail the histology and histochemistry of the major and minor salivary glands of cattle. The histological features of bovine salivary gland endpieces and ducts have been described in detail elsewhere (Section 1.2).

The purpose of the present study has been to re-examine and extend previous findings where necessary and determine the histochemical characteristics of bovine salivary gland secretory products with the aid of histological stains and enzyme blocking methods. However, since the classification of epithelial mucosubstances remains controversial (Reid and Clamp, 1978) owing to confusion between the usage of biochemical and histochemical terminology, a suitable classification system will be introduced with consideration to both disciplines.

Epithelial secretory products, generally referred to as mucus, have been traditionally designated as either glycoproteins or acid mucopolysaccharides. However, mucus of epithelial origin, consists predominantly of acidic and neutral glycoproteins with an insignificant mucopolysaccharide content (Young and van Lennep, 1978; Reid and Clamp, 1978).

The biochemistry of glycoproteins has been previously described in Section 1.3.6. Essentially the acidic nature of this compound is due to its high sialic acid content, carboxyl groups of non-sialic acid origin and sulphate groups. An acid glycoprotein therefore has an excess of negative charges while a neutral glycoprotein has

predominantly positive charges from free amino groups (Shreeve, 1974).

In contrast to glycoproteins, acid mucopolysaccharides consist of a polypeptide core and considerable amounts of repeating polysaccharide units with little or no branching of side chains, the monosaccharide content being considerably higher (50 units or more for a given molecule) than that of glycoproteins (Reid and Clamp, 1978). The monosaccharides usually identified are hyaluronic acids and derivatives of chondroitin sulphate. These two groups are mainly responsible for the highly acidic nature of mucopolysaccharides. Unlike glycoproteins which are mainly found in body fluids and epithelial secretions, the acid mucopolysaccharides are predominantly distributed in bone, cartilage and connective tissue ground substances (Ham and Cormack, 1979). In general, mucus, connective tissue ground substance and skeletal structures can be composed of a mixture of both glycoproteins and mucopolysaccharides with the latter mainly found in connective tissue elements, conjugated to small quantities of glycoproteins (Ham and Cormack, 1979) whereas the former as identified in mucus, is likely to contain very small quantities of mucopolysaccharides such as uronic acid (Young and van Lennep, 1978).

The difference of opinion between biochemical and histochemical classification of epithelial mucosubstances primarily stem from an inability to demonstrate histochemically that carbohydrate and protein constituents of molecules such as glycoproteins and mucopolysaccharides, belong to the same or different molecules. The histochemical findings are generally attributed to reactive groups present in side chains of monosaccharide or oligosaccharide units, for example glycol groups, carboxylic and sulphate groups. Histochemists commonly use a variety of basic dyes that react with acid radicles and chemical reactions specific for neutral groups to distinguish between the two side chains as they occur in glycoproteins and mucopolysaccharides. Additional information can be derived from enzyme hydrolysis or

blocking methods which remove specific reactive groups (Culling, 1974). Histochemical results are thus classified according to whether an acidic or neutral group has been stained.

However, it is inappropriate for histochemists to continue to use the terms glycoproteins and mucopolysaccharides somewhat arbitrarily when describing the nature of a side group, as these two compounds are biochemically different. A more appropriate form of terminology would be to adopt the terms "acid glycoprotein" and "neutral glycoprotein" when describing mucosubstances of an epithelial origin, as suggested by Young and van Lennep (1978). Ideally, the terms acid and neutral mucosubstances would be even more appropriate, since these would include any acid mucopolysaccharides present (albeit in small amounts) in epithelial mucous secretions and side groups which cannot be detected by existing stains and histochemical methods.

From salivary glands therefore, proteoserous secretion consists mostly of inorganic ions, water and some neutral glycoproteins with little evidence of acid glycoproteins, whereas mucous secretions are composed predominantly of both acidic and neutral glycoproteins (or mucosubstances).

It is hoped that the above suggestions may alleviate some of the confusion associated with classification of epithelial secretory products and contribute towards a clearer understanding of the distinction between biochemical and histochemical terminology.

The histochemical procedures used for this study have been selected to distinguish between neutral and acidic side groups of mucosubstances and to identify separately carboxyl and sulphate acid radicles. Two enzymes, hyaluronidase and neuraminidase were additionally used to confirm the presence or absence of acid mucopolysaccharides and sialic acids respectively, in bovine salivary gland tissue.

The present study will also report on preliminary findings to histologically establish the major source of immunoglobulins in bovine saliva, from an assessment of plasma cell numbers in the connective tissue stroma of both major and minor salivary glands. It has been previously reported by Watson and Lascelles (1973) that non parotid saliva of sheep contains 3.5 - 5.0 times more immunoglobulins than parotid saliva with the mandibular gland being the major contributor (Cripps and Lascelles, 1976). However, in cattle the salivary gland or glands responsible for secretion of immunoglobulins have so far not been identified, although estimated values for IgA, IgG, IgG₂ and IgM in bovine saliva have been reported by Mach and Pahud (1971).

Antibodies produced against each of the bovine salivary protein bands 4, 8, 9 and 10 were reacted with appropriate salivary gland tissue to identify immunohistochemically the distribution of cells specialised for synthesis of bands 4, 8, 9 and 10 respectively. Parotid gland tissues of both low and high bloat susceptible cattle were examined for distribution of band 4, the salivary protein predominantly implicated with bloat susceptibility in cattle (Section 1.6).

A few paraffin wax embedded sections from sheep parotid tissues were also studied to observe any morphological changes attributable to species differences between sheep and cattle parotid glands.

2.2 Materials and Methods

2.2.1 Tissue sampling and fixation procedure

The histological sections used for most of the staining and histochemical methods were prepared from previously embedded paraffin wax blocks supplied by Mr. M.J. Birtles, Department of Physiology and Anatomy, Massey University, Palmerston North, and contained tissue specimens fixed in formol saline and Bouins fluid (Culling, 1974). All blocks have been prepared with tissue samples removed from both right and left, major and minor salivary glands of cattle (*Bos taurus*). Most tissue samples examined were from a mature animal with a low bloat score.

For the latter part of the study further samples for histological examination were gathered from two animals with known bloat susceptibility (one L.S. and the other H.S.). Both animals were stunned with a captive bolt and killed by exsanguination. At dissection, the head was separated at the level of the fourth or fifth cervical vertebrae with the upper oesophagus and epiglottis intact. The salivary glands from both the right and left sides of the head were dissected in the following order:- mandibular, parotid, sublingual, dorsal buccal, intermediate buccal and ventral buccal. The head was re-oriented for samples to be taken from the posterior tongue, epiglottis and soft palate. Samples removed from each gland were separately placed in the following fixatives:- Bouins fluid, 10% neutral formol saline and Zenker-formol (Culling, 1974). Further samples were processed for electron microscopy and utilized for a study of intraepithelial granulated duct cells in the parotid and ventral buccal glands (see Chapter 3).

Tissues in formol saline were left for 2-3 days while those in Bouins fluid were left for 24 hours before being transferred into 70% alcohol. Tissues in Zenker-formol were fixed for 12-15 hours and then washed in running tap-water for 6-8 hours.

2.2.2 Paraffin wax processing and microtomy

Following fixation the tissues were loaded into a Shandon Elliot automatic tissue processor (Watson, Victor Ltd.) for overnight dehydration, clearing and paraffin wax impregnation. The preliminary dehydration step included changes of an hour's duration each in increasing concentrations of ethyl alcohol (70%, 95%, 100%, 100%, 100%). The clearing step utilized chloroform (1 hour) and two changes of xylene (1 hour each). Impregnation was carried out at 56°C with two changes of paraffin wax (2 hours each).

Tissue blocks were then removed from the processor and embedded in 56°C M.P. paraffin wax. Sections were prepared from wax blocks with samples cut at 5-6 μ m thickness using a Reichart sliding microtome (Selby-Wilton Ltd.). Individual sections were floated on warm water at about 46-48°C and then attached onto sparsely albumenised glass slides (3" x 1") and left at room temperature for about 30 minutes before being air dried at 60°C overnight.

2.2.3 Staining and histochemical methods

Before staining the sections were dewaxed in two changes of xylene, rinsed in absolute alcohol and 70% alcohol respectively and washed in running tap water.

The following stains and histochemical methods were applied to sections from all the major and minor salivary glands:-

1. Haematoxylin and eosin (H&E)
2. Alcian blue pH 1.0 and pH 2.5 / H&E
3. Alcian blue pH 2.5 / phosphotungstic acid haematoxylin (PTAH)
4. Periodic acid Schiff (PAS)
5. Alcian blue (pH 2.5) and PAS
6. Phenylhydrazine - periodic acid Schiff (PAPS)
7. Toluidine blue

8. Azure A at pH 1, 2, 3 and 4
9. Alcian yellow
10. Hales Colloidal Iron
11. BIAL reagent
12. Diastase followed by PAS
13. Acetylation and PAS
14. Acetylation, saponification and PAS
15. Methylation and Alcian blue at pH 1.0 and 2.5
16. Methylation, saponification and Alcian blue at pH 1.0 and 2.5
17. Neuraminidase followed by Alcian blue at pH 2.5
18. Hyaluronidase followed by Alcian blue at pH 1.0
19. Methyl-Green pyronin

The staining procedures used and the reaction mechanisms where applicable are listed in Appendices I and II.

After staining, sections were dehydrated in 70% alcohol and absolute alcohol respectively, cleared in xylene and mounted in D.P.X. medium (B.D.H. chemicals).

Prepared slides were examined with an Olympus microscope at four different magnifications, namely x40, x100, x400 and x1000.

Bouins fixed tissue samples of sheep parotid gland were also cut and stained with H&E and Alcian blue & PTAH.

2.2.4 Immunohistochemistry

Antibodies to bovine salivary protein bands 4, 8, 9 and 10 were each separately raised in rabbits and prepared by Dr. W.T. Jones, Applied Biochemistry Division, D.S.I.R., Palmerston North. An antibody specific to a bovine salivary protein was then reacted with the respective tissue antigen; band 4 and 10 (Parotid gland), band 8 (Mandibular gland) and band 9 (Sublingual gland).

The immunohistochemical method used was the indirect

enzyme labelled antibody technique (Sternberger, 1974). Rabbit antibovine salivary protein was used as primary antiserum. The secondary antiserum was goat antirabbit IgG conjugated with horseradish peroxidase. Sites of antibody to antigen attachment were detected by using either 3,3'-diaminobenzidine (DAB) or 3-amino-9-ethylcarbazole, both complexed with hydrogen peroxide.

Procedure for indirect enzyme labelled antibody method

Paraffin wax sections from parotid, mandibular and sublingual glands, previously fixed in Bouins fluid, were prepared as described in Section 2.2.2.

Parotid tissue samples from both L.S. and H.S. cattle, intermediate buccal gland and the sheep parotid were additionally examined for the distribution of protein band 4.

1. Dewax sections and bring to water.
2. Treat sections with 2% bovine serum albumen (BSA) in phosphate buffered saline (PBS) for 5 minutes to reduce non-specific binding. Shake off excess BSA.
3. Treat with rabbit antibovine salivary protein diluted 1:1000 in 2% BSA in PBS for 30 minutes in moist chamber.
4. Wash with PBS, minimum of three changes, 15 minutes each with constant stirring.
5. Treat with 2% BSA in PBS for 10 minutes.
6. React with peroxidase-labelled goat antirabbit immunoglobulin (diluted 1:60) for 30 minutes in moist chamber.
7. Wash with 2% BSA in PBS (optional).
8. Wash in PBS three changes 5 minutes each with constant stirring.
9. Incubate with solution of DAB (75 mg) in 0.001% hydrogen peroxide in 0.15 M trischloride buffer pH 7.6 for 10 - 30 minutes.

10. Wash briefly in trischloride buffer.
11. Rinse in distilled water.
12. Counterstain with 1% aqueous light green solution for about 5 - 10 seconds.
13. Dehydrate, clear and mount in D.P.X.

Control sections were similarly treated except that preimmune rabbit IgG was substituted for the primary antiserum to detect non-immunological binding of γ -globulins. Endogeneous peroxidase activity was not suppressed since previous findings have indicated that such activity is minimal in bovine salivary gland tissue (W.T. Jones, personal communication).

The distribution of IgA synthesising plasma cells in parotid, mandibular and sublingual glands was examined by substituting goat antihuman IgA (1:10) as primary antiserum in step 2 and rabbit antig goat immunoglobulin in step 6.

2.2.5 Photomicrography

Photomicrographs of areas representative of most of the salivary glands examined from histochemical methods, were taken using a Leica 35 mm reflex camera mounted on a Leitz Ortholux microscope (Medical Supplies (N.Z.) Ltd.). Exposure times were calculated with a microsix L exposure meter. Agfachrome 50L and Kodachrome 50 negative films were used. Colour prints used in this thesis were processed by Kodak (N.Z.) Ltd. from 35 mm transparencies.

2.3 Results

Histological findings from the major and minor salivary glands are described below and the results from histochemical reactions have been summarized in Table 2.1.

2.3.1 Parotid Gland

The bovine parotid gland was composed of tubular secretory endpieces with cuboidal cells surrounding a narrow lumen. The secretory endpiece cells showed no evidence of cytoplasmic basophilia and had a generally vacuolated appearance. The centrally-placed spherical nuclei were large and contained one or two nucleoli. With respect to the histochemical reactions used, the cytoplasm of secretory cells showed little evidence of reactivity with basic stains, although in one animal a cluster of cells positive to Alcian blue at pH 2.5 was found (Figure 2.1.2). However, the occasional secretory cell of most animals examined was distinctly PAS positive (Figure 2.1.1), distribution of (diastase-resistant) PAS positive material was supranuclear and sometimes close to the apical border.

Intercalated ducts leading from the secretory endpieces were long and branched and lined by epithelial cells which were initially flattened but became cuboidal near the intralobular ducts. The cytoplasm was moderately basophilic (with H&E). The nuclei of duct cells close to the endpieces were flat and dense while those near the intralobular ducts were ovoid.

The intralobular ducts had a convoluted appearance with moderately large diameter lumina. The epithelium was cuboidal or low columnar with centrally placed nuclei. The cytoplasm of some intralobular duct cells was notably PAS positive while the apical cell membranes of some were frequently modified with cytoplasmic protrusions of "apical blebs" which contained PAS positive material (Figure 2.2.1). There was little or no evidence for the presence of basal

HISTOCHEMICAL RESULTS OF BOVINE MAJOR AND MINOR SALIVARY GLANDS

[illegible]

| Salivary Glands | | Method | |
|----------------------|--------|------------------|--------|
| | | (M) + (S) + (AB) | pH 1.0 |
| Neuraminidase + (AB) | pH 2.5 | - | - |
| | | - | - |
| | | - | - |
| | | - | - |
| Hyaluronidase + (AB) | pH 1.0 | - | - |
| | | - | - |
| | | - | - |
| | | - | - |
| Alcian Yellow | pH 2.5 | - | - |
| | | - | - |
| | | - | - |
| | | - | - |
| Hales Colloidal Iron | | (+) | - |
| | | +++ | - |
| | | ++ | - |
| | | + | - |
| Toluidine Blue | | - | - |
| | | - | - |
| | | - | - |
| | | - | - |
| Azure A | pH 1 | - | - |
| | pH 2 | - | - |
| | pH 3 | - | - |
| | pH 4 | - | - |

striations in intralobular ducts (Figure 2.2.3). A frequent occurrence, particularly in the ductal epithelium of low bloat susceptible cattle, was a granulated cell lying adjacent to the basal lamina (Figure 2.2.2). This cell has been the subject of a separate investigation (see Chapter 3).

Walls of the larger interlobular and interlobar ducts were lined by stratified cuboidal epithelium and frequently surrounded by irregularly arranged fibrous connective tissue containing mast cells, nerves, blood vessels and lymphatics. Plasma cells were infrequently observed in all parotid tissue samples. Interlobular and interlobar ducts showed no evidence of apical cytoplasmic protrusions or basal striations but granulated cells identical to those found in the epithelium of intralobular ducts were occasionally present. The main excretory duct was lined by stratified columnar epithelium with goblet cells (Figures 2.1.3 and 2.1.4). The cytoplasmic contents of the goblet cells reacted with PAS and all the cationic dyes used (eg. Alcian blue, pH 1.0 and 2.5, Alcian yellow, Toluidine blue, Azure A and colloidal iron).

A brief investigation of the sheep parotid gland did not reveal histological features dissimilar to the bovine parotid, except that the intralobular duct epithelial cells were tall columnar with acidophilic basal striations (Figure 2.2.4). These ducts were frequently observed in clusters, located centrally within a lobule.

2.3.2 Mandibular Gland

The elongated tubular endpieces of this gland were composed of two cell types, the secretory cells which surrounded a narrow lumen and a demilune cell which occupied a position at the blind end of an endpiece (Figure 2.4). The secretory cells generally were cuboidal in appearance with a flattened basal nucleus and a characteristically "foamy" cytoplasm, while the demilune cells were large and

rounded with a spherical basally-placed nucleus.

The cytoplasmic contents of secretory (mucous) cells reacted positively with PAS, PAPS, Alcian blue (AB) pH 1.0 (weak), pH 2.5, Alcian yellow (AY), Toluidine blue, Azure A pH 4 and Hales colloidal iron (Figure 2.4). Methylation at 60°C for four hours eliminated basophilia at both pH 1.0 and pH 2.5. Subsequent saponification failed to restore AB staining at either pH 1.0 or pH 2.5. Acetylation, with a mixture of acetic anhydride and pyridine eliminated PAS staining which was subsequently restored by saponification. Basophilia at pH 2.5 was markedly reduced by neuraminidase activity (Figure 2.4.10), whereas hyaluronidase activity was negative with no reduction in degree of basophilia at either pH 1.0 or pH 2.5. In contrast to the secretory end-piece cells, the demilunes had distinct eosinophilic granules (Figure 2.4.6) within a moderately or weakly basophilic cytoplasm. The demilune cells were weakly positive to PAS (Figure 2.4.5), AB pH 1.0 and pH 2.5, AY and colloidal iron but reacted strongly with the BIAL reagent (Figure 2.4.7). The granules reacted strongly with acid stains such as eosin, phloxine and phosphotungstic acid haematoxylin (Figure 2.4.6). Although saponification after methylation produced no evidence of AB positive (pH 2.5) staining in mucous cells, the demilunes did not display this feature as there was evidence of weak AB positive (pH 2.5) staining restored by saponification.

The secretory endpieces terminated abruptly at intercalated ducts which were lined by simple cuboidal epithelium. The nuclei of intercalated duct cells were highly irregular in shape and the cytoplasm often invaginated the nuclei to about three-quarters of the latter's diameter. The walls of the intralobular ducts were lined by tall columnar cells with well-developed basal striations (Figure 2.4.5). The cell nuclei were large and spherical and were located midway between the base and apex of the cell. Overall, the striated duct cells did not appear to constitute an entirely homogeneous cell population, since variations were observed in

staining characteristics of their nuclei and cytoplasm. The cytoplasm and apical borders of some striated duct cells were also intensely PAS positive. The irregular fibrous connective tissue surrounding striated ducts and the larger interlobular ducts contained several plasma cells reactive to anti IgA antibody (Figure 2.4.11), mast cells, blood vessels, nerves and lymphatics. Interlobular ducts were composed of cuboidal or low columnar epithelium and did not show well-developed basal striations although there was some evidence of PAS positive material in their apical borders.

The main duct of the mandibular gland was composed of stratified columnar epithelium without goblet cells (Figure 2.4.12).

2.3.3 Sublingual Gland

The secretory endpieces were long and tubular with flattened demilune cells. The secretory cells were positive to PAS, AB pH 1.0 and 2.5, AY, Toluidine blue, Azure pH 4, PAPS and Hales colloidal iron (Figure 2.5). After methylation and saponification AB staining was restored at pH 2.5. Neuraminidase activity did not eliminate basophilia completely since considerable AB staining at pH 2.5 was observed after enzymic digestion. Similarly hyaluronidase treatment did not eliminate basophilia at either pH 1.0 or 2.5 (Figure 2.11).

The demilune cells of the sublingual gland differed morphologically and histochemically from those of the mandibular gland. The demilunes were slender in outline and not easily identified. They did not appear to react with basic stains but weak PAS positive material was identified in some demilunes.

Intralobular ducts were well developed and lined by tall columnar cells with basal striations (Figure 2.5.5). These striated ducts were morphologically similar to those of the

mandibular gland, although PAS positive material in duct cells was not a common feature of the sublingual gland. The interlobular and interlobar ducts were composed of stratified cuboidal epithelium without goblet cells.

An unusual feature of most sublingual gland tissues examined was the large number of plasma cells distributed in clumps between the secretory endpieces and striated ducts (Figures 2.5.7 and 2.5.8). Plasma cells were not observed in such high proportions in any of the other major or minor salivary glands. Another unusual characteristic observed in some tissue samples examined, was an apparent histological difference between certain areas of the gland (Figures 2.5.3 and 2.5.4). Some areas of the sublingual gland lacked plasma cells and striated ducts; instead the endpieces were closely packed and intralobular ducts were composed of low cuboidal cells without basal striations. Plasma cells were occasionally seen but never in groups or clumps between endpieces and ducts.

2.3.4 Buccal Glands

These glands are distributed in the subepithelial tissues of the dorsal, intermediate and ventral aspects of the buccal cavity. The histology and histochemistry of the ventral buccal glands were identical to that of the parotid glands (see Section 2.3.1).

The secretory endpieces of the dorsal and intermediate buccal glands were mainly tubular with flattened demilune cells toward their distal ends. Secretory cells reacted positively to PAS, AB pH 1.0 and 2.5, AY, Toluidine blue, Azure A pH 4, Hales colloidal iron and PAPS (Figures 2.6 and 2.7). Neuraminidase and hyaluronidase reactivity was similar to that of the sublingual gland. The demilunes, which were difficult to identify, did not appear to react with PAS or basic stains.

The intralobular ducts consisted of cuboidal epithelium;

no basal striations were observed but the granulated intraepithelial cell type found in the ductal epithelium of the parotid gland was infrequently observed in the ducts of both dorsal and intermediate glands (Figure 2.6.3). An unusual feature of both glands was the presence of cellular debris mixed with secretory material in the lumen contents of some secretory endpieces and intralobular ducts (Figure 2.7.4). Interlobular and interlobar ducts were lined by columnar epithelium with goblet cells while the main duct was lined by stratified columnar epithelium with goblet cells. The contents of goblet cells reacted with PAS and basic stains. The connective tissue stroma encircling the large ducts and the parenchyma frequently contained mast cells and plasma cells.

Both the dorsal and intermediate buccal glands frequently consisted of small islets of secretory cells similar in morphology and staining properties to parotid gland secretory cells (Figure 2.7.3). These islets contained their own intralobular and interlobular ductal systems.

2.3.5 Palatine Glands

The glandular tissue beneath the soft palate was composed of large elongated tubular endpieces with associated demilune cells. The secretory cells were positive to PAS, AB pH 1.0 and 2.5, AY, Toluidine blue, Azure A pH 4, PAPS and Hales colloidal iron (Figure 2.8). The demilune cells were relatively more conspicuous (Figure 2.8.4) than those of the dorsal and intermediate buccal glands and reacted weakly with PAS. The intralobular ducts were similar to the dorsal and intermediate buccal glands. The granulated intraepithelial cell type was infrequently observed in the ducts of the palatine glands (Figure 2.8.3).

The interlobar and interlobular ducts were lined by columnar epithelium with occasional scattered goblet cells. The connective tissue stroma surrounding the secretory tissues and the ducts frequently contained mast cells and plasma

cells.

Additional features in common with the dorsal and intermediate buccal glands were the frequent occurrence of small islets of secretory cells identical in morphology and staining properties to those of the parotid gland (Figure 2.8.1) and the presence of an atypical secretory mechanism (Figure 2.8.2).

2.3.6 Posterior Tongue

Glandular tissue found beneath the epithelium of the dorsal surface of the tongue was composed of large diameter tubular endpieces with flattened demilune cells on their blind ends (Figure 2.9). The secretory cells were positive to PAS, AB pH 1.0 and 2.5, AY, Toluidine blue, Azure A pH 4, PAPS and Hales colloidal iron. The demilunes were PAS and AB positive at pH 1.0 and 2.5 (Figures 2.9.3 and 2.9.4).

The intralobular ducts consisted of cuboidal epithelium with no evidence of basal striations or granulated intra-epithelial cells observed in the intralobular ducts of the parotid gland, the buccal glands and the palatine glands.

The intralobular ducts were linked to interlobular ducts which communicated with the exterior surface of the tongue via large subepithelial extralobular ducts lined by stratified cuboidal epithelium (Figure 2.9.1).

Plasma cells and mast cells were commonly observed in the subepithelial connective tissues and between secretory endpieces and ducts.

2.3.7 Pharyngeal Glands

Glands located within the subepithelial connective tissue of the lingual surface of the epiglottis were composed of short tubular endpieces with large rounded demilune cells on their blind ends (Figure 2.10). The secretory cells

were positive to PAS, AB pH 1.0 and 2.5, AY, PAPS, Toluidine blue, Azure A pH 4 and Hales colloidal iron. The demilunes contained abundant eosinophilic cytoplasmic granules that were BIAL positive, PAS positive (Figure 2.10.2) and weakly reactive with AB pH 1.0 and 2.5 and Toluidine blue.

The intralobular ducts were lined by columnar epithelial cells which were frequently modified as secretory cells, the contents of which reacted with PAS and basic stains. Morphologically, some of the modified epithelial secretory cells were typical goblet cells (Figure 2.10.3), while others had the appearance of secretory endpieces which seemed to communicate directly with intralobular ducts (Figures 2.10.3 and 2.10.4). The intralobular ducts communicated with the surface via interlobular ducts and short subepithelial excretory ducts.

The connective tissue stroma surrounding secretory endpieces and ducts contained plasma cells and mast cells; plasma cell numbers were usually higher than in other minor glands (Figure 2.10.2).

2.3.8 Immunohistochemistry

Antibodies to low molecular weight protein bands 4 and 10 reacted with parotid and ventral buccal gland tissues. Whilst only some secretory cells reacted with anti band 4 antibody, anti band 10 antibody positive cells were widespread (Figure 2.3). Parotid tissue samples of both low (L.S.) and high (H.S.) bloat susceptible cattle examined had equal quantities of secretory cells that reacted with anti band 4 antibody. Band 4 was additionally identified in the demilunes of the intermediate buccal gland (Figure 2.6.4). Antiovine band 4 antibody failed to cross react with band 4 or equivalent secretory protein present in sheep parotid tissues.

Band 8 was found to be localised in the demilunes of the mandibular gland (Figure 2.4.8) and band 9 in the

demilunes of the sublingual gland (Figure 2.5.6).

Antibody to IgA reacted with subepithelial plasma cells of the mandibular and sublingual glands (Figure 2.4.11).

Positive staining in all tissues which contained the antigen (salivary protein) was recognised by deposits of dark brown to black reaction product generally distributed throughout the cytoplasm of specific secretory cells with varying degrees of intensity.

FIGURE 2.1

PAROTID AND VENTRAL BUCCAL GLANDS

- 2.1.1 Diastase-resistant PAS positive material distributed in supranuclear sites of secretory cells.
(PAS/Tartrazine). Magnification: x 650

- 2.1.2 A rare observation of a group of secretory end-piece cells which have stained for carboxylated acid mucosubstances.
(Alcian Blue pH 2.5 /H and E). Magnification: x 100

- 2.1.3 Main excretory duct lined by stratified columnar epithelium with goblet cells.
(Hales colloidal iron/Neutral Red).
Magnification: x 100

- 2.1.4 Main excretory duct lined by stratified columnar epithelium with goblet cells containing sulphated acid mucosubstances.
(Alcian Blue pH 1.0/PTAH). Magnification: x 260

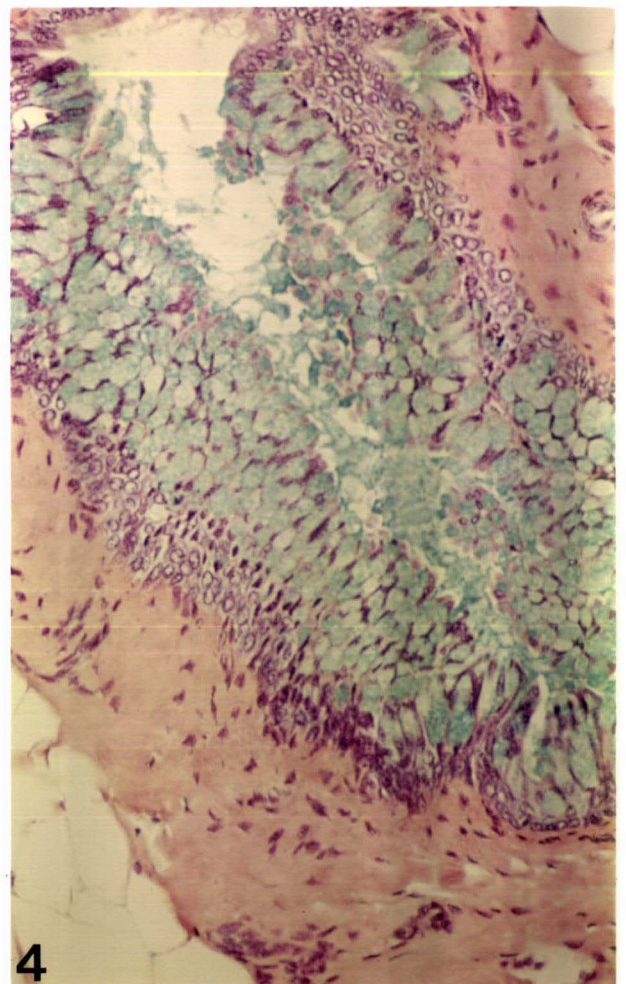
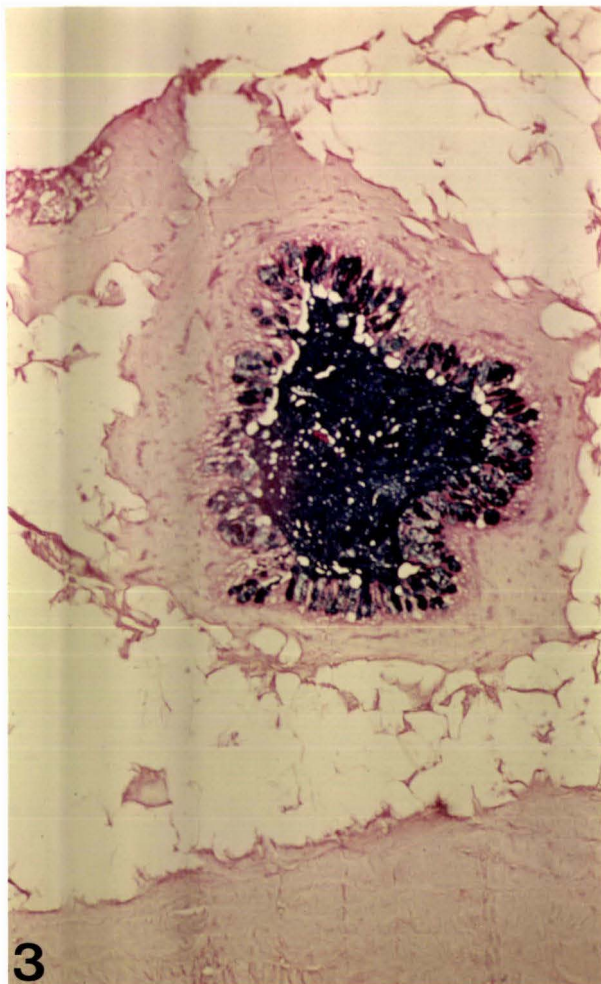
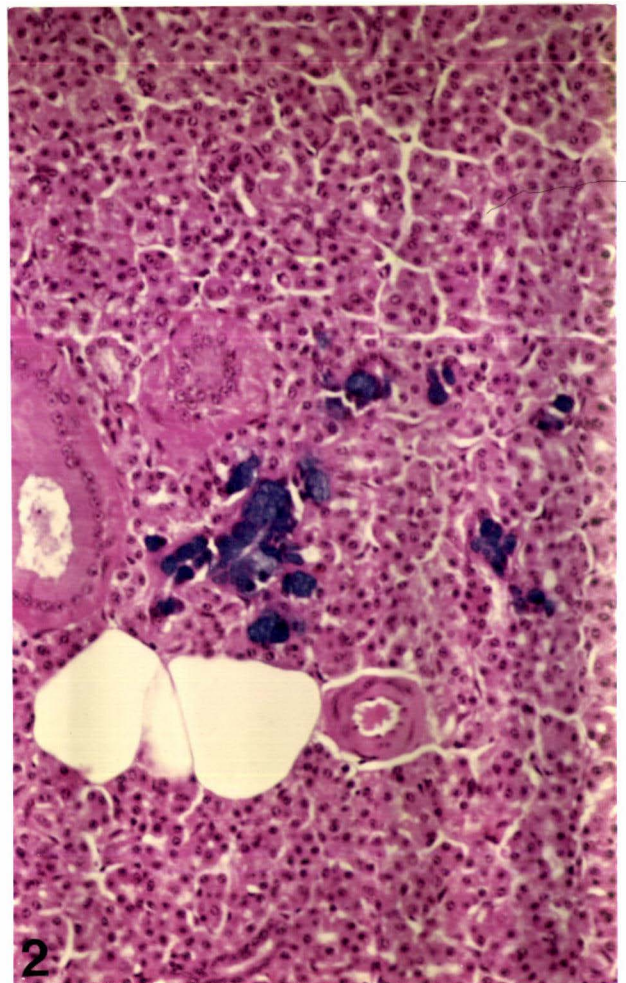
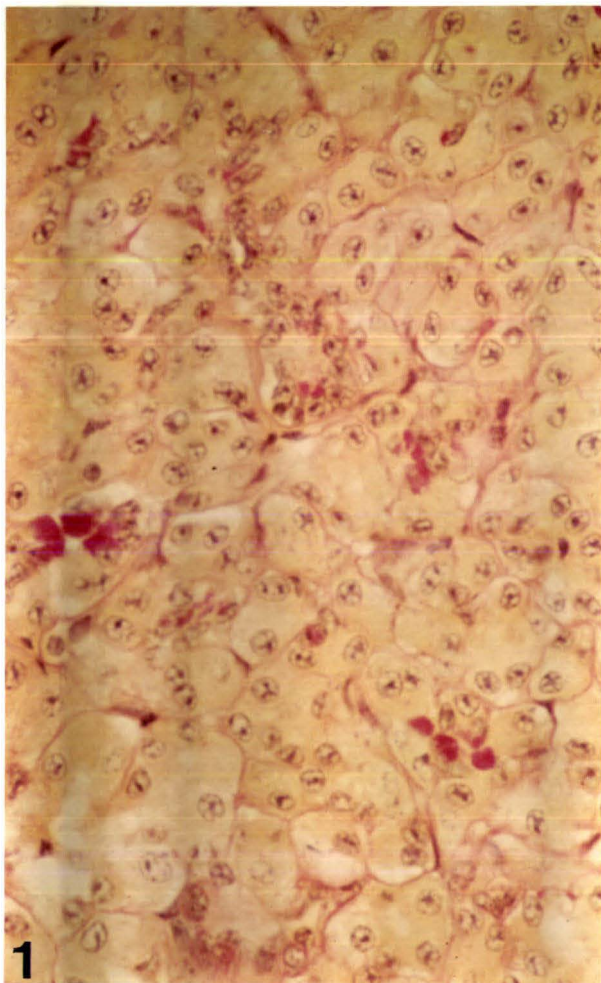


FIGURE 2.2

PAROTID AND VENTRAL BUCCAL GLAND INTRALOBULAR DUCTS

- 2.2.1 Diastase-resistant PAS positive intralobular duct cells with "apical blebs".
(PAS/Tartrazine). Magnification: x 650

- 2.2.2 Distribution of intraepithelial granular duct cells within the wall of an intralobular duct. Granular duct cells varied considerably in morphology but contained nuclei similar to those of plasma cells.
(Bismarck Brown/Haematoxylin).
Magnification: x 650

- 2.2.3 Intralobular duct cells lined by high cuboidal epithelium without basal striations.
(PTAH). Magnification: x 650

- 2.2.4 Sheep parotid gland intralobular ducts lined by tall columnar epithelium with acidophilic basal striations.
(PTAH). Magnification: x 650

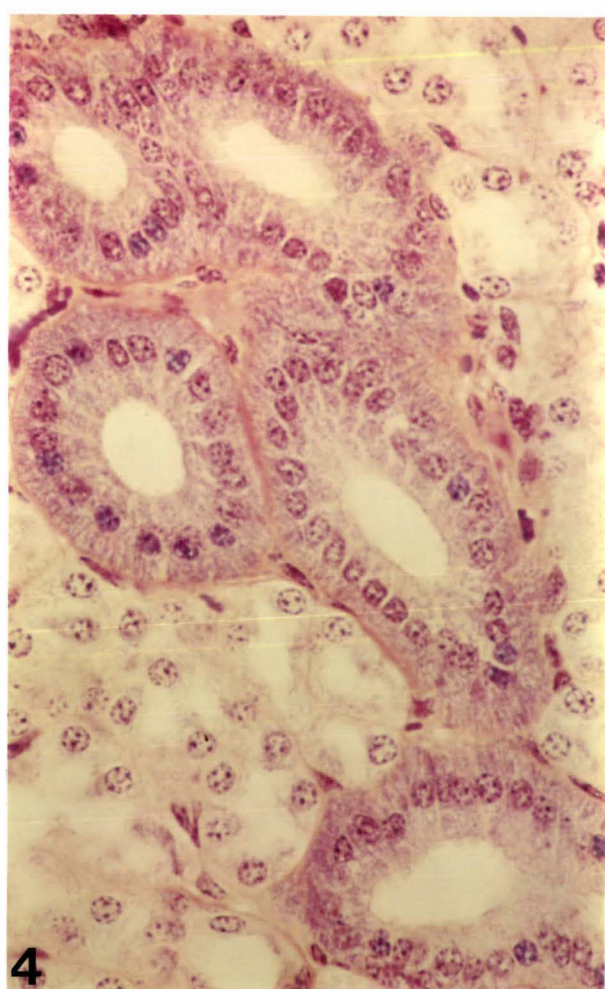
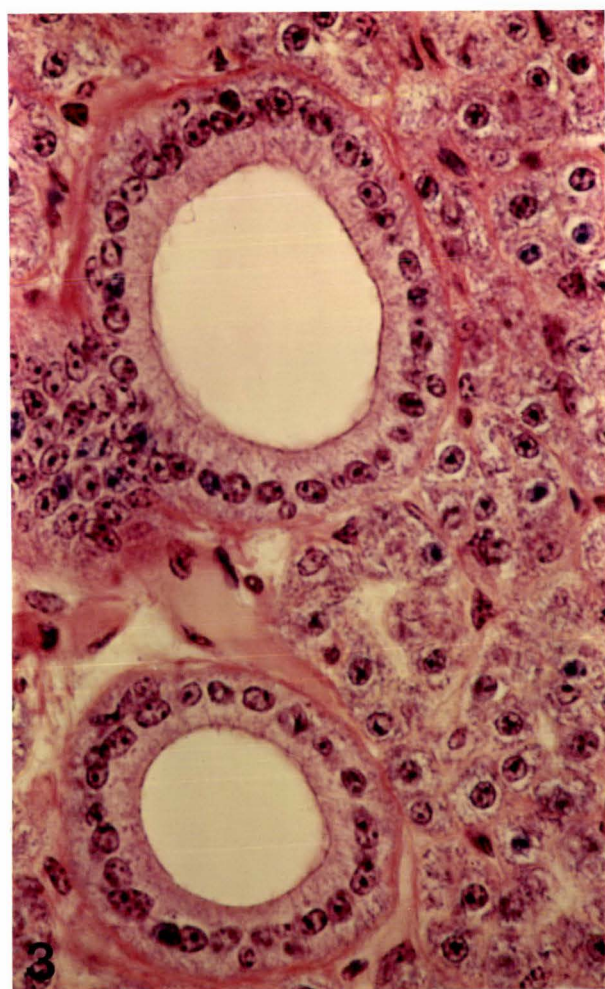
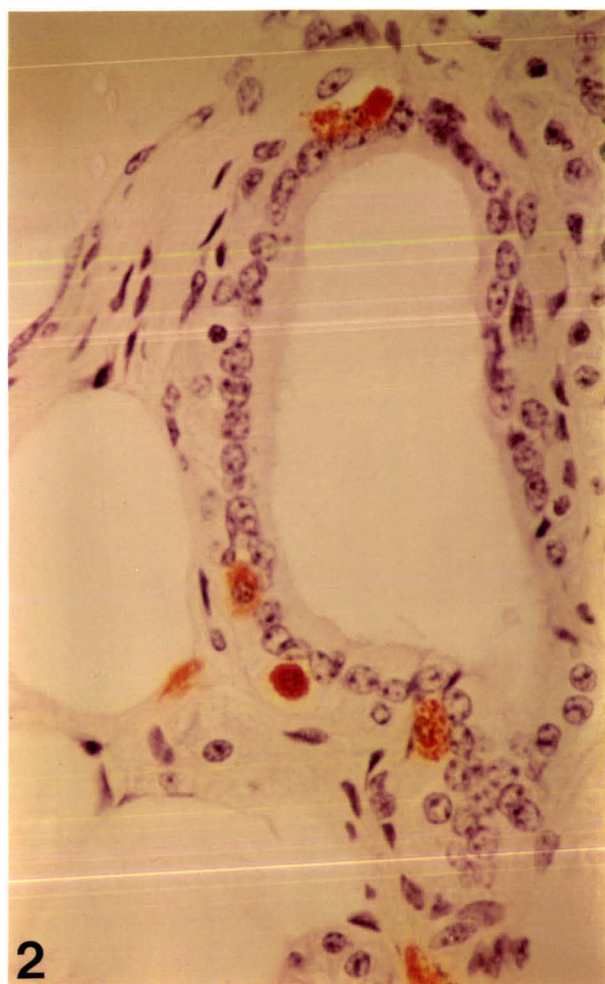
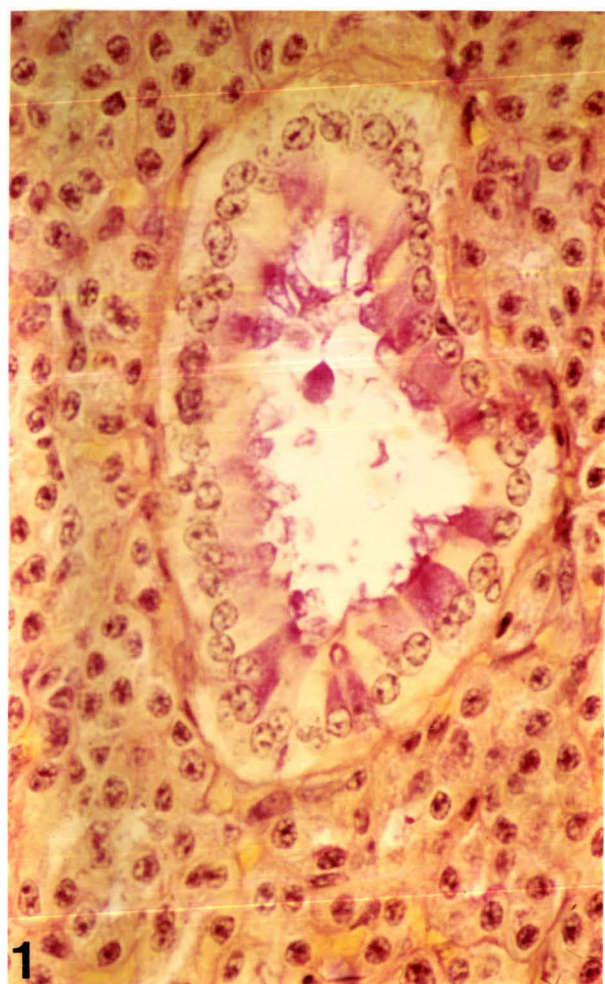


FIGURE 2.3

IMMUNOHISTOCHEMISTRY: DISTRIBUTION OF PAROTID AND
VENTRAL BUCCAL GLAND SALIVARY PROTEIN BANDS 4 AND 10

- 2.3.1 Control section without antibody to salivary protein.
(Light Green counterstain).
Magnification: x 100
- 2.3.2 Distribution of anti band 4 positive proteoserous cells.
(Dark brown precipitate with DAB substrate).
Magnification: x 60
- 2.3.3 Widespread distribution of anti band 10 positive proteoserous cells.
(Black precipitate with carbazole substrate).
Magnification: x 100
- 2.3.4 Distribution of both anti band 4 (brown precipitate) and anti band 10 (black precipitate) positive proteoserous cells.
Magnification: x 650

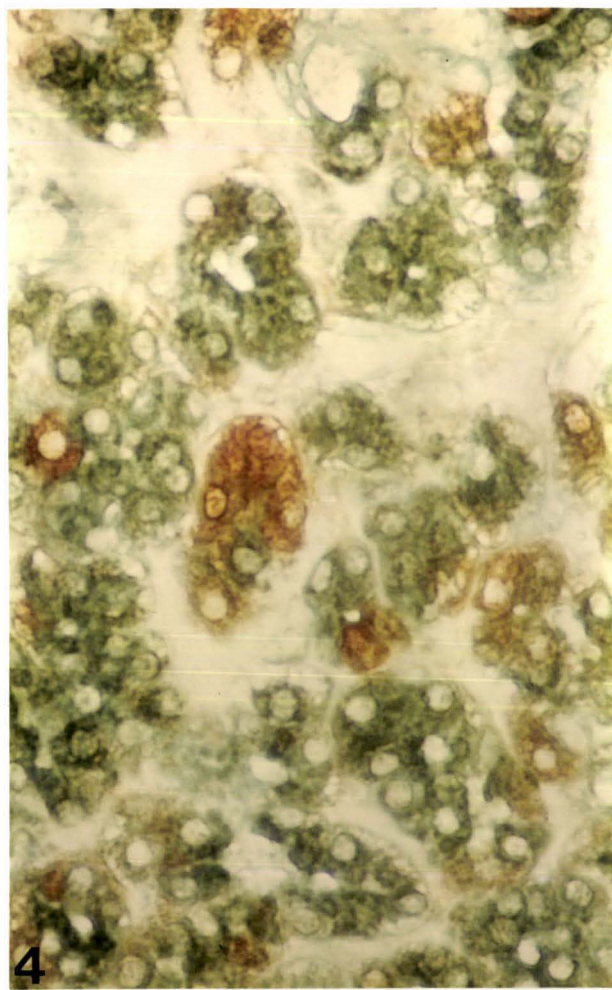
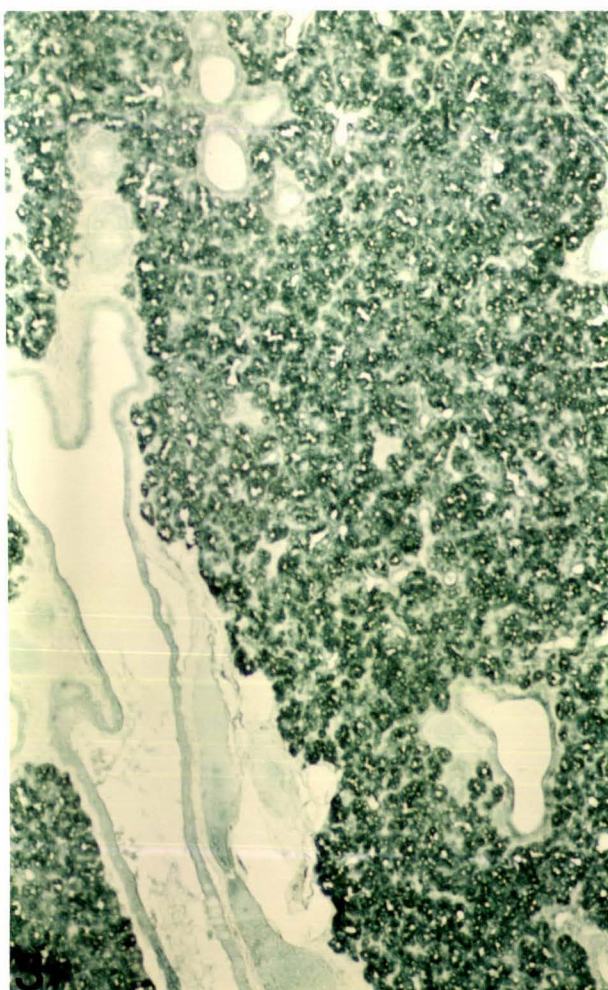
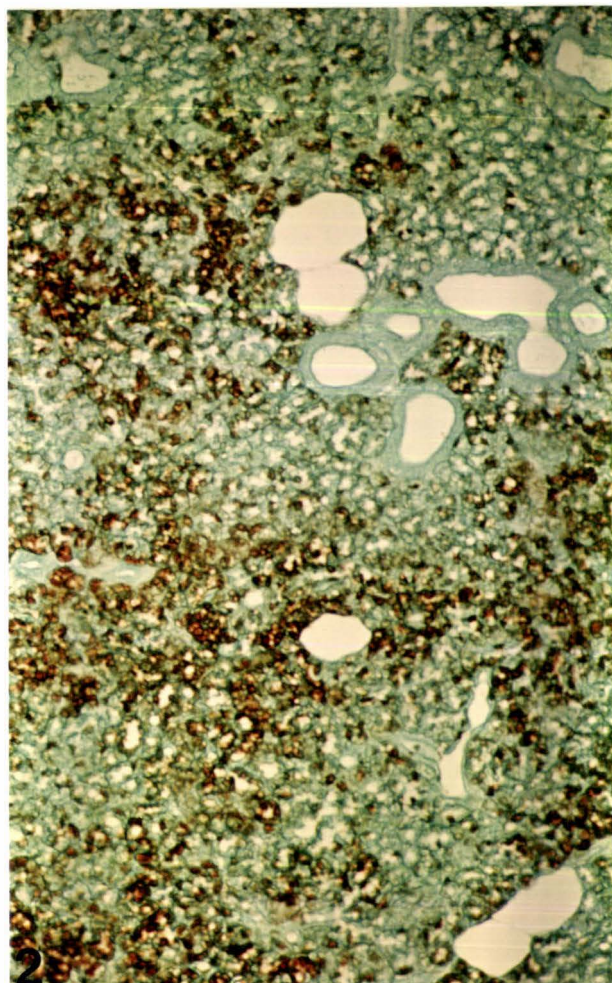
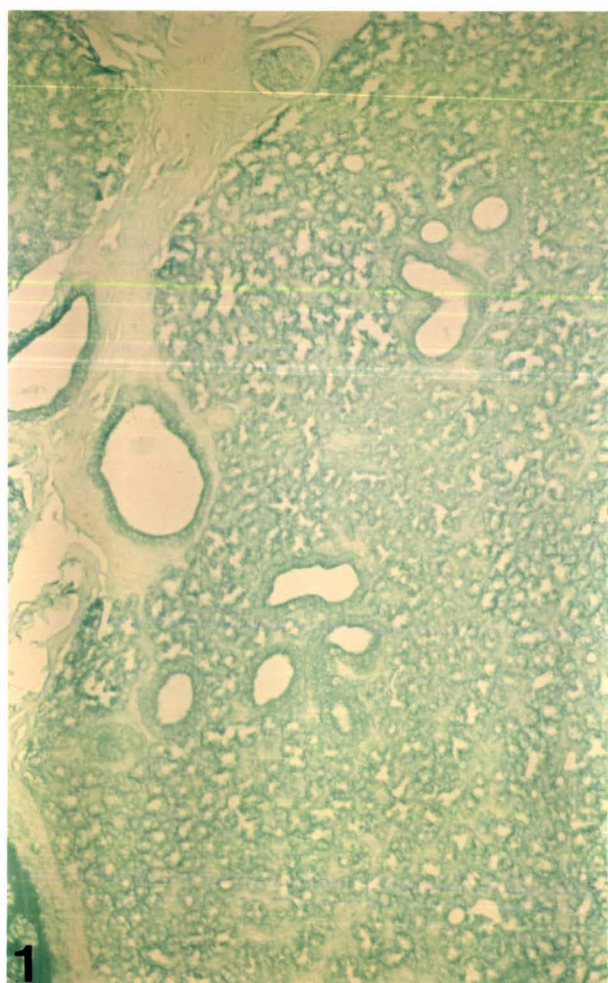


FIGURE 2.4

MANDIBULAR GLAND

- 2.4.1 Characteristic appearance of tubular endpieces with demilunes.
(Gomori Aldehyde Fuchsin).
Magnification: x 100

- 2.4.2 Distribution of carboxylated acid mucosubstances in mucous cells.
(Alcian Yellow/H and E).
Magnification: x 260

- 2.4.3 Toluidine blue metachromasia of mucous cells.
Note tall columnar striated duct cells.
Magnification: x 260

- 2.4.4 Acid mucosubstances of mucous cells demonstrated with Hales colloidal iron. Note weak colloidal iron staining in demilunes.
(Hales colloidal iron/Neutral Red).
Magnification: x 260

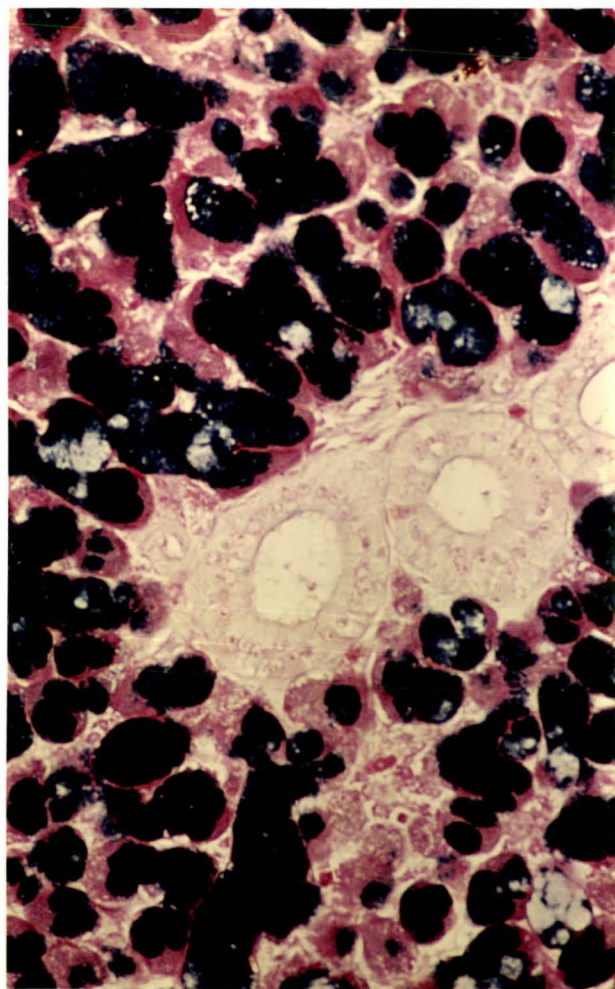
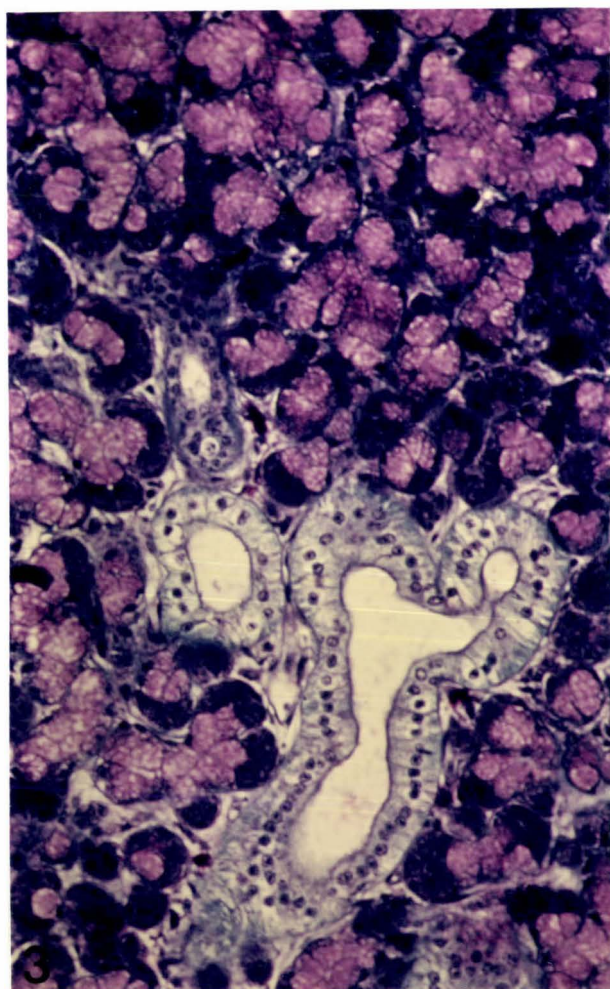
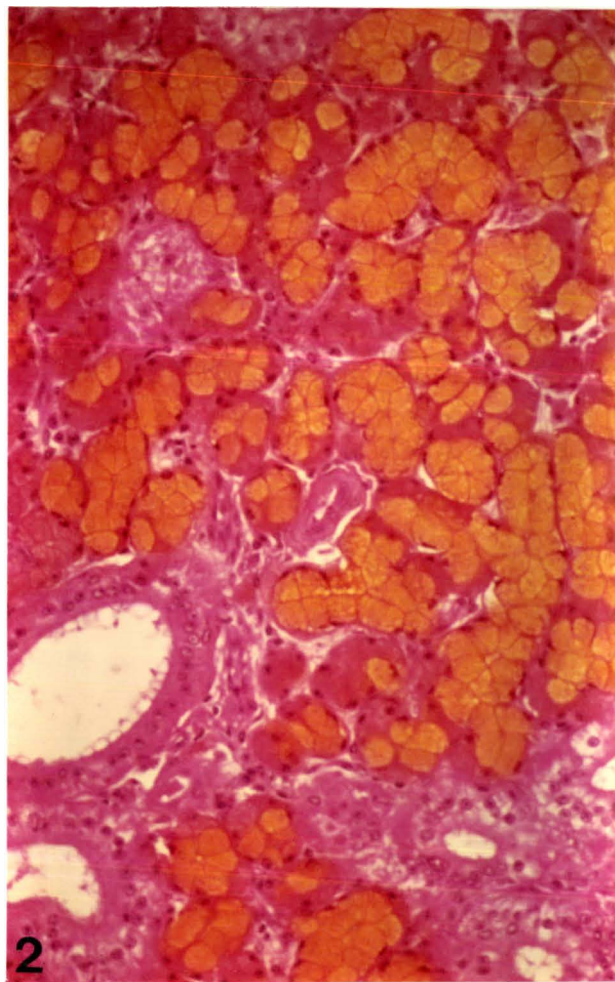
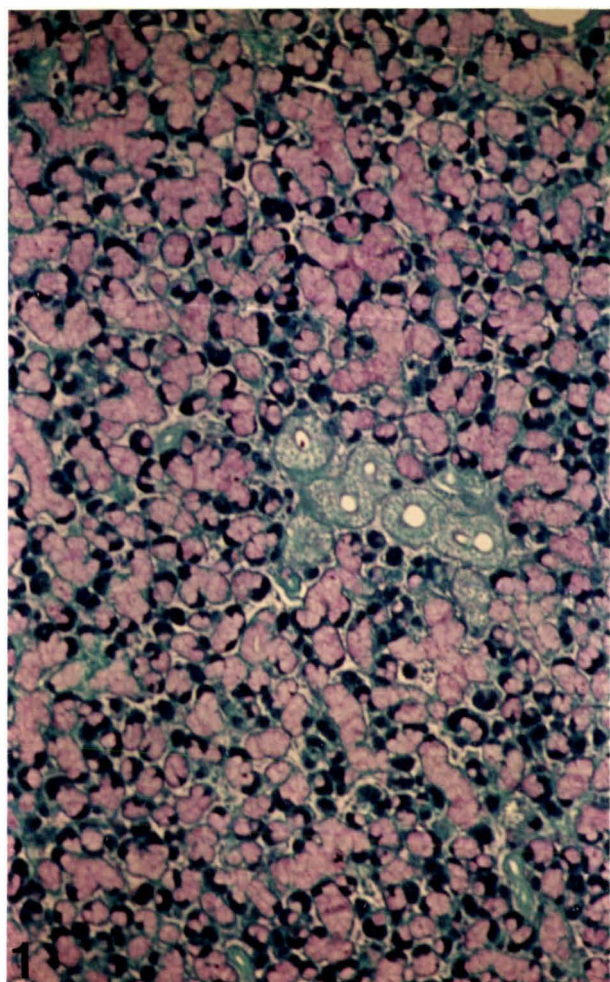


FIGURE 2.4 (Continued)

2.4.5 Distribution of PAS positive mucosubstances in demilunes and a mixture of acidic and neutral mucosubstances in mucous cells. (PAS/Alcian Blue pH 2.5/H and E).
Magnification: x 650

2.4.6 Alcian Blue positive mucous cells and demilunes with acidophil (dark blue) granules. Note distinct acidophilic basal striations of intralobular ducts and sub-epithelial plasma cells scattered between endpieces and ducts. (PTAH/Alcian Blue pH 2.5).
Magnification: x 650

2.4.7 BIAL positive sialic acid residues in demilune cells.
Magnification: x 650

2.4.8 Demilune cells positive for salivary protein band 8. (Light Green counterstain).
Magnification: x 260

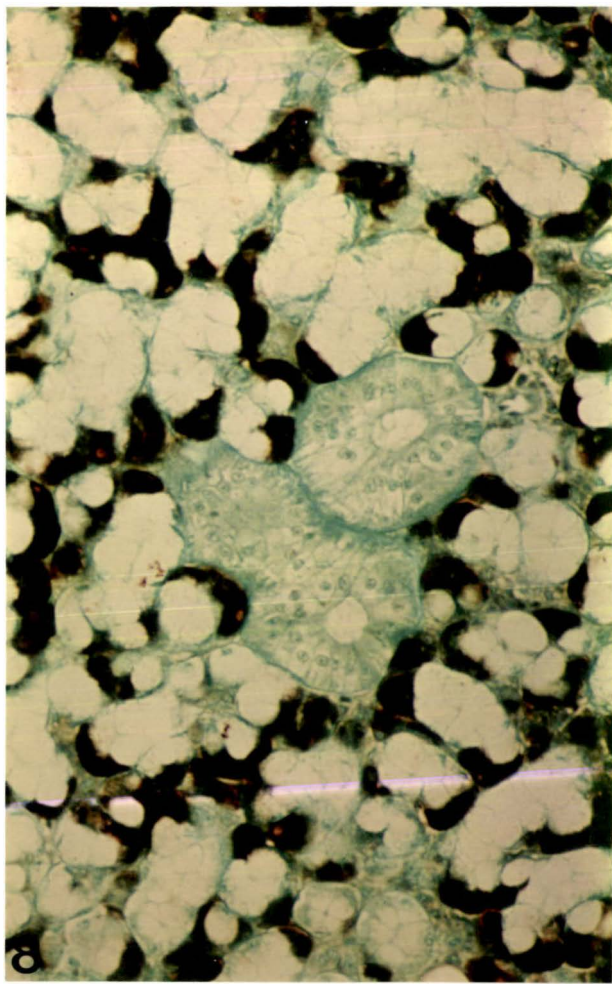
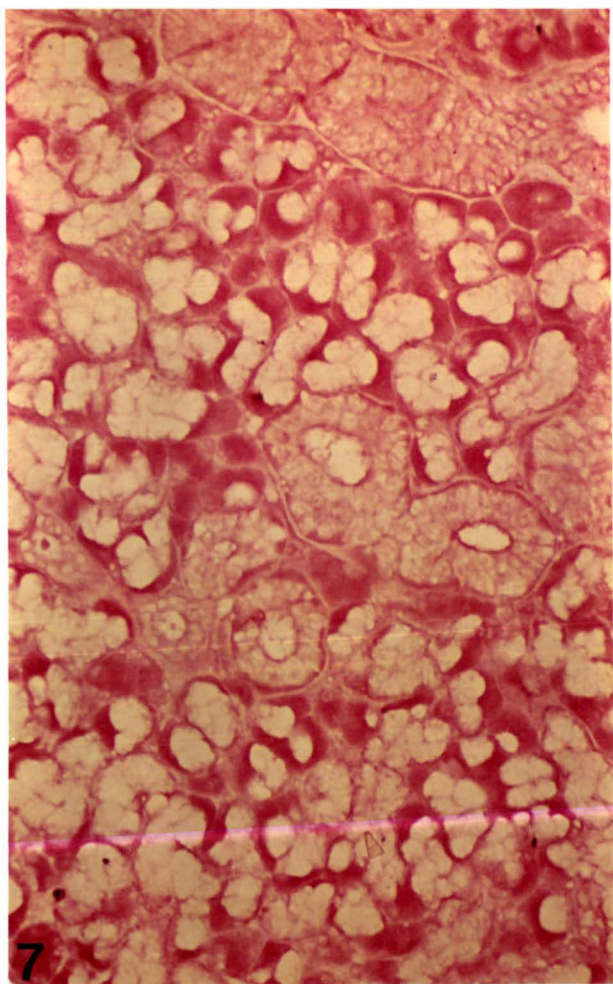
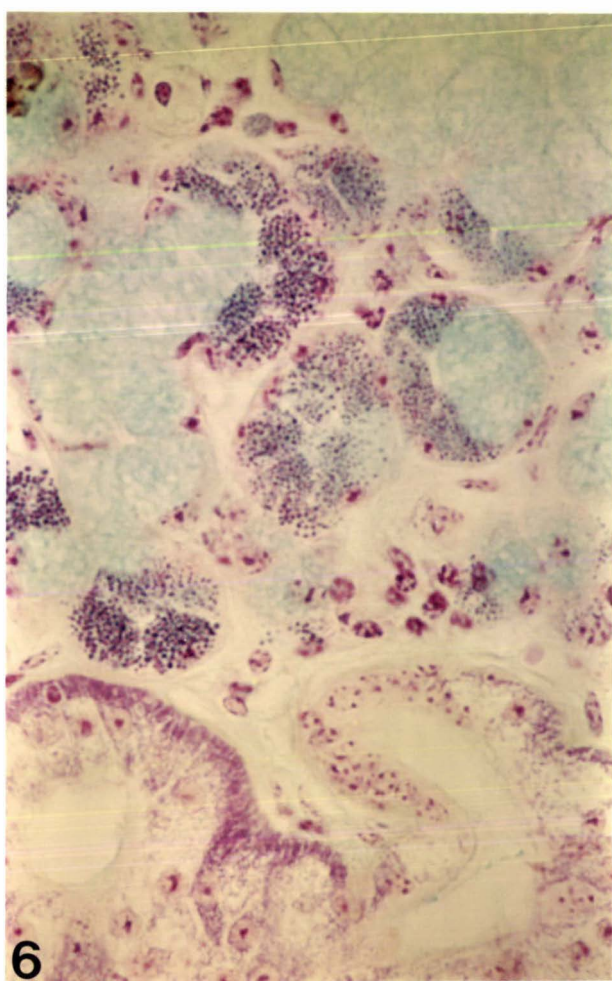
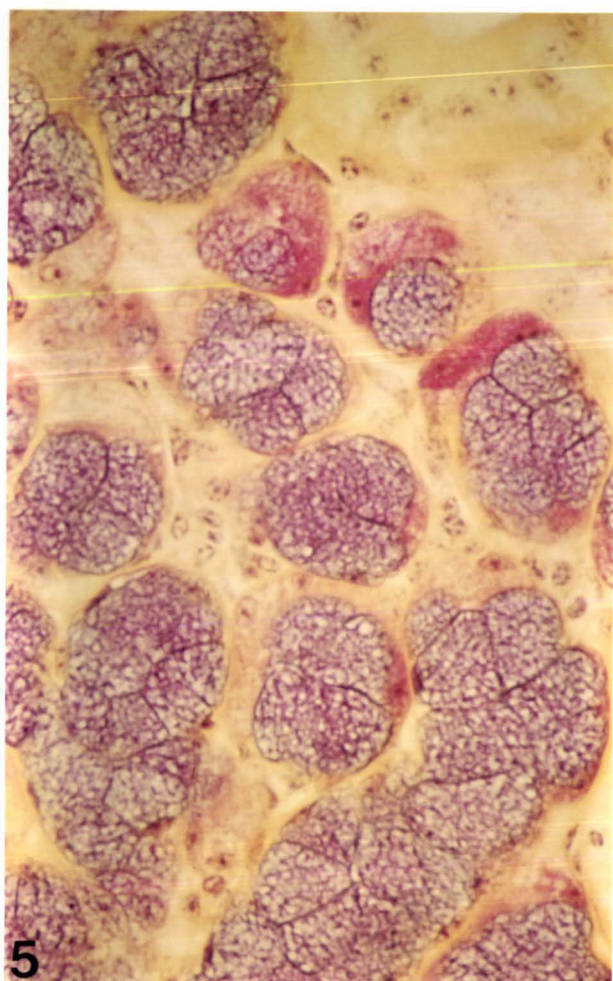


FIGURE 2.4 (Continued)

- 2.4.9 Mucous cells stained for carboxylated acid mucosubstances. Note acidophilic content of demilunes.
(Alcian Blue pH 2.5/H and E).
Magnification: x 260
- 2.4.10 Neuraminidase activity, shown by loss of Alcian Blue staining of mucous cells; carboxylated acid mucosubstances can therefore be attributed to sialic acid residues. Note weak Alcian Blue staining of mast cells at pH 2.5.
(Neuraminidase/Alcian Blue pH 2.5/H and E).
Magnification: x 260
- 2.4.11 An immunohistochemical demonstration of plasma cells which have reacted with anti IgA.
(Light Green counterstain).
Magnification: x 650
- 2.4.12 Main excretory duct: stratified columnar epithelium without goblet cells.
(PTAH/Alcian Blue pH 2.5).
Magnification: x 650

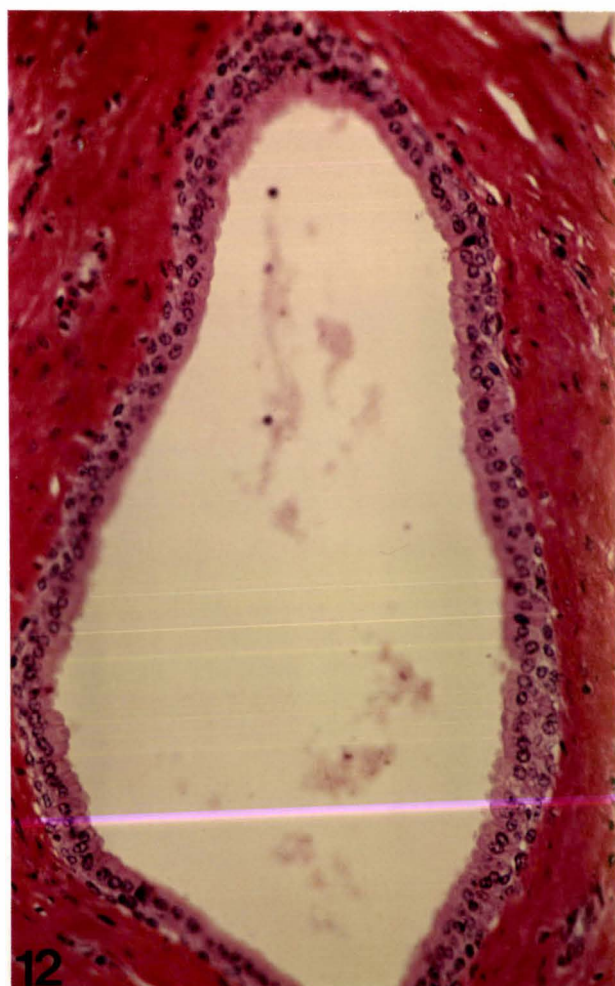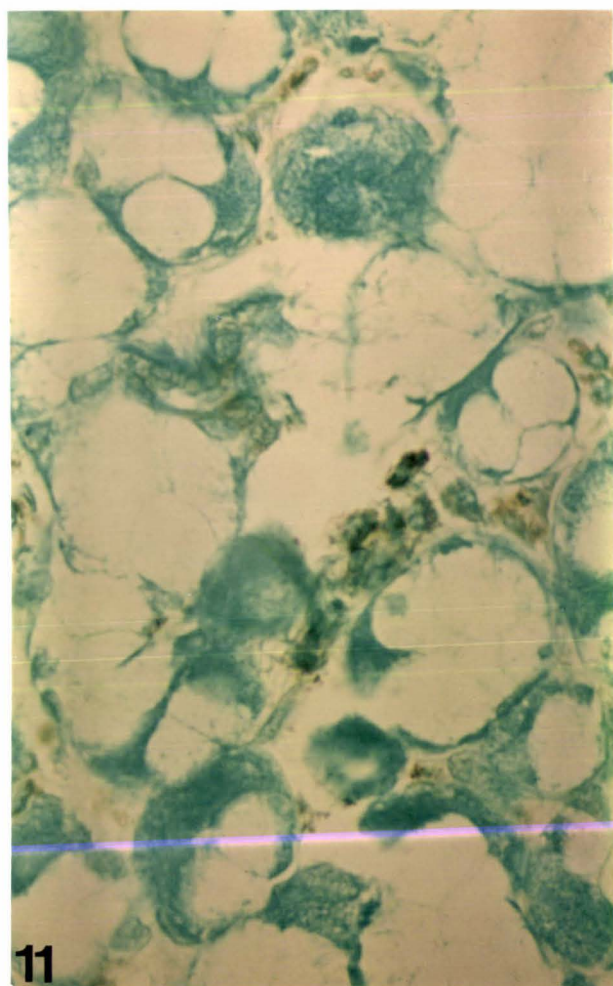
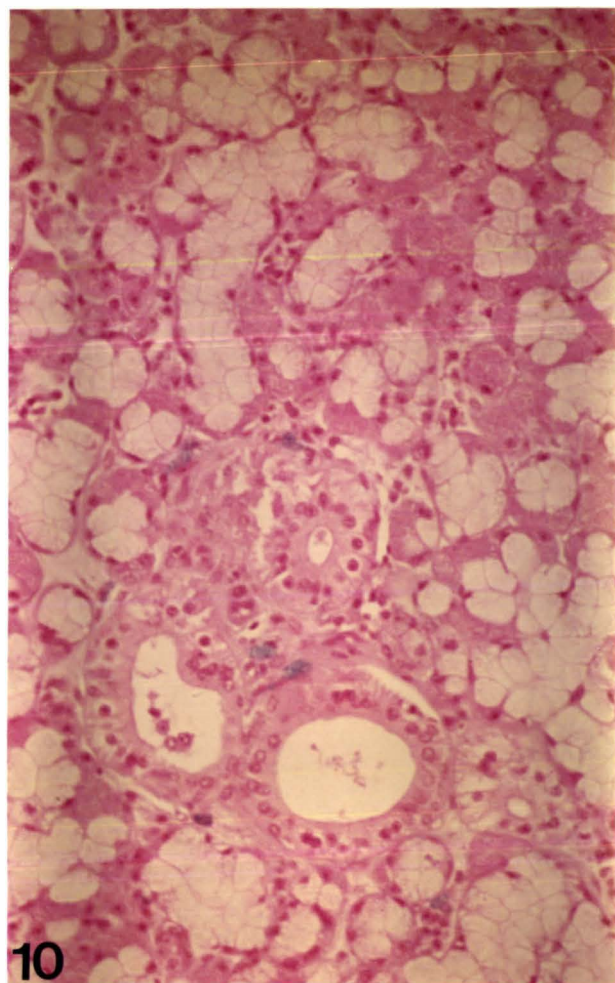
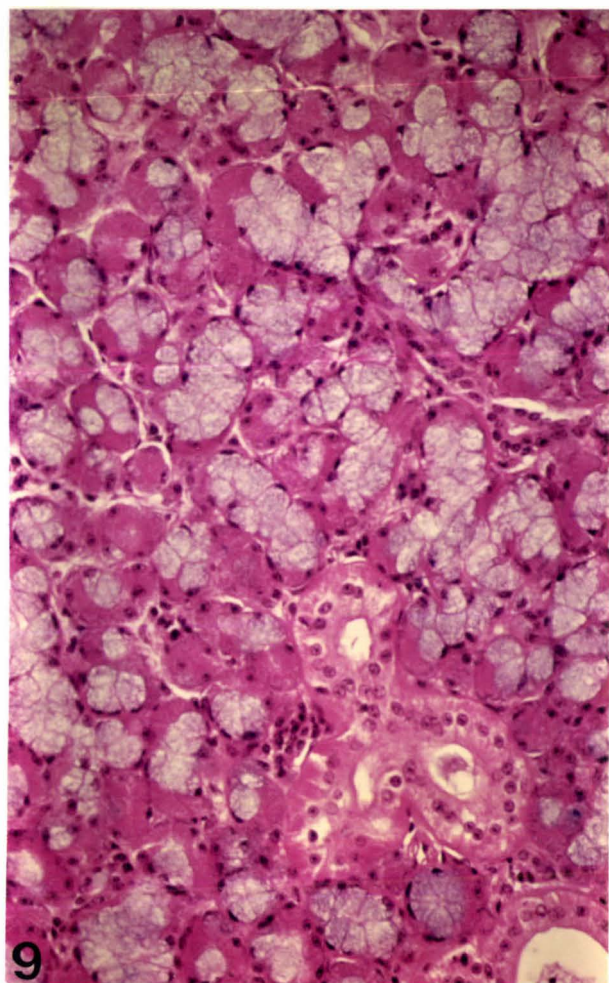


FIGURE 2.5

SUBLINGUAL GLAND

- 2.5.1 Secretory endpiece cells composed of mucous cells containing a mixture of acidic and neutral mucosubstances. Note predominantly proteoserous demilunes.
(PAS/Alcian Blue pH 2.5).
Magnification: x 650
- 2.5.2 Distribution of sulphated mucosubstances in mucous cells.
(Alcian Blue pH 1.0/H and E).
Magnification: x 260
- 2.5.3 The characteristic histological appearance of the sublingual glands, with numerous plasma cells and striated ducts.
(Alcian Yellow/H and E).
Magnification: x 260
- 2.5.4 Areas of sublingual gland tissue which differed from those shown in Fig. 2.5.3. Note lack of plasma cells and striated ducts.
(Alcian Yellow/H and E).
Magnification: x 260

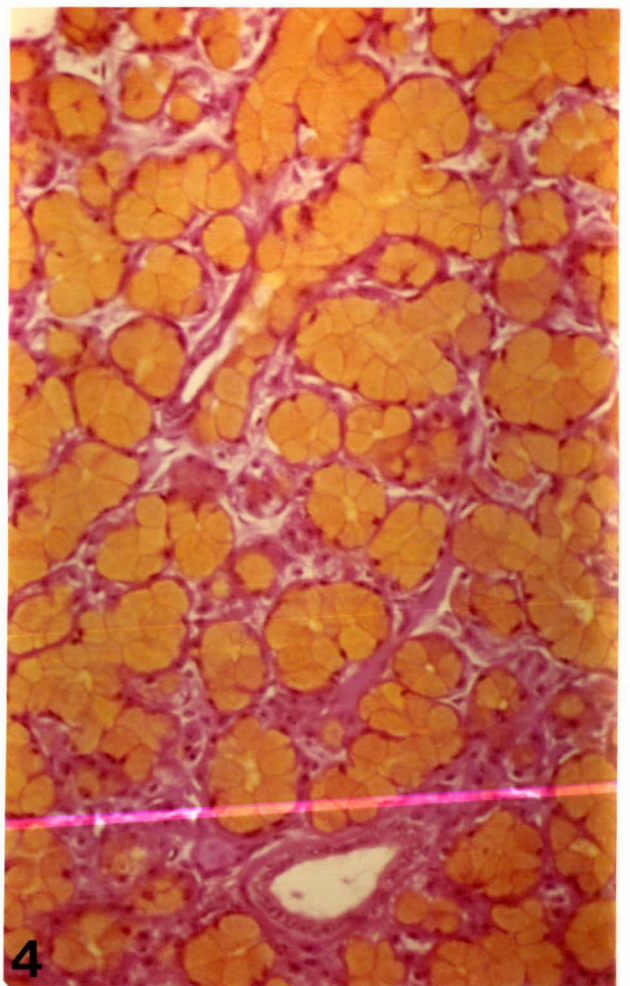
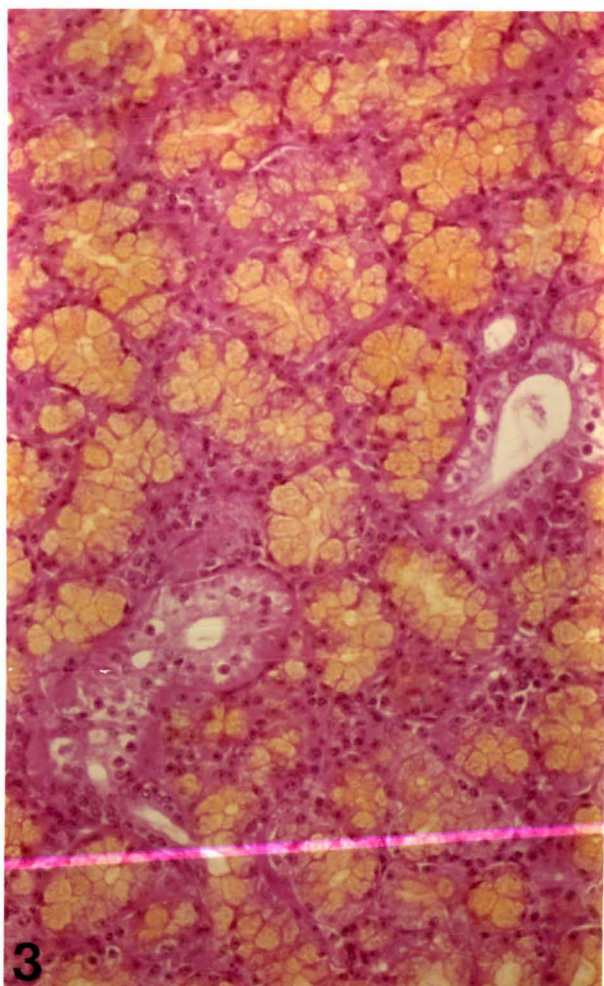
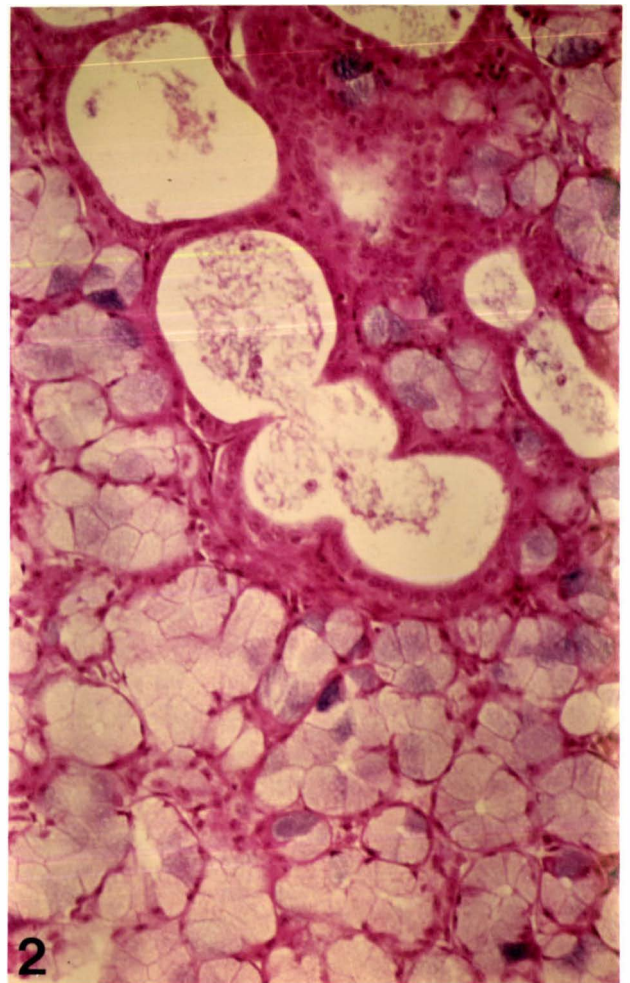
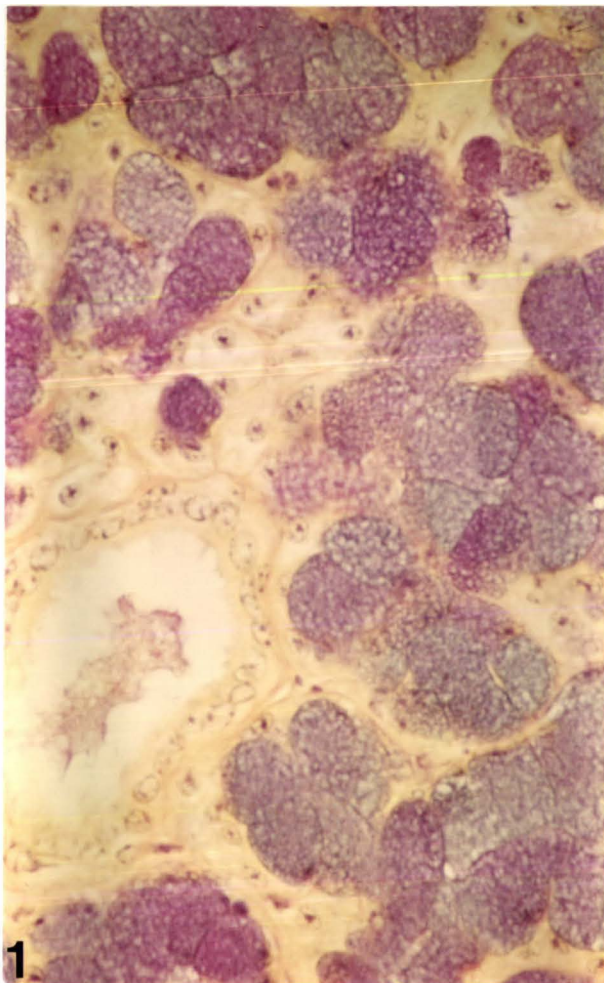


FIGURE 2.5 (Continued)

- 2.5.5 Intralobular ducts with tall columnar cells and distinct acidophilic basal striations. (PTAH). Magnification: x 650

- 2.5.6 Distribution of protein band 9 in demilune cells. Note numerous subepithelial plasma cells. (Light Green counterstain). Magnification: x 650

- 2.5.7 A large group of plasma cells distributed between secretory endpieces and ducts. (H and E). Magnification: x 260

- 2.5.8 Plasma cells stained with Methyl Green-Pyronin. Note pyroninophilia of plasma cell cytoplasmic RNA. Magnification: x 650

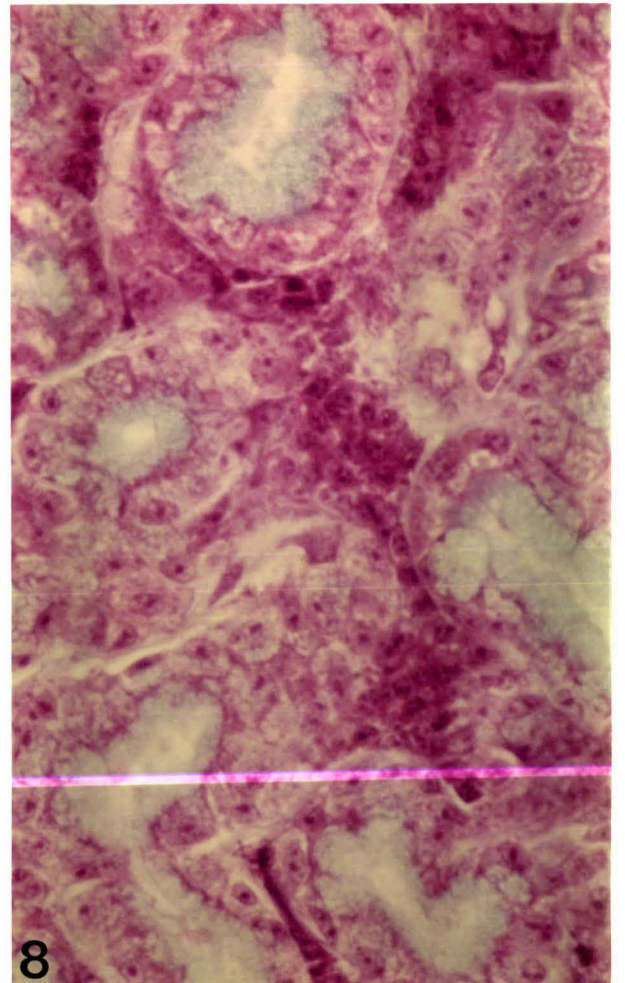
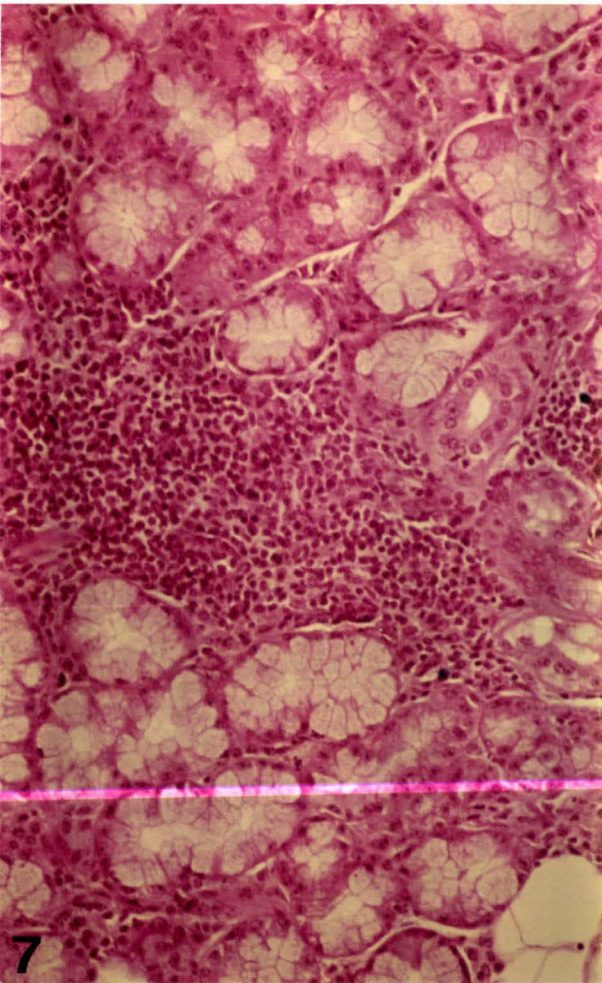
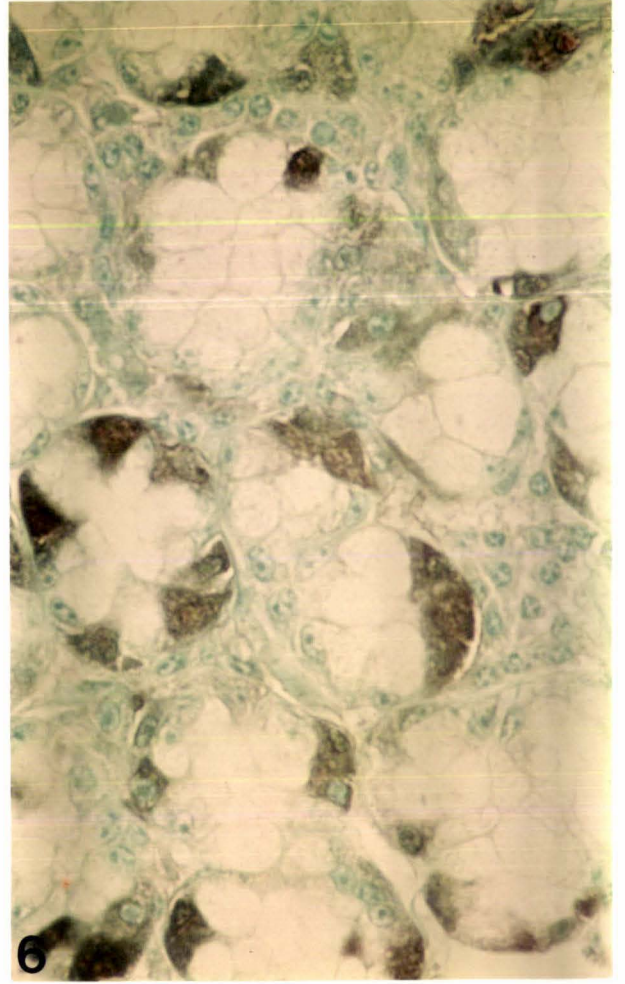
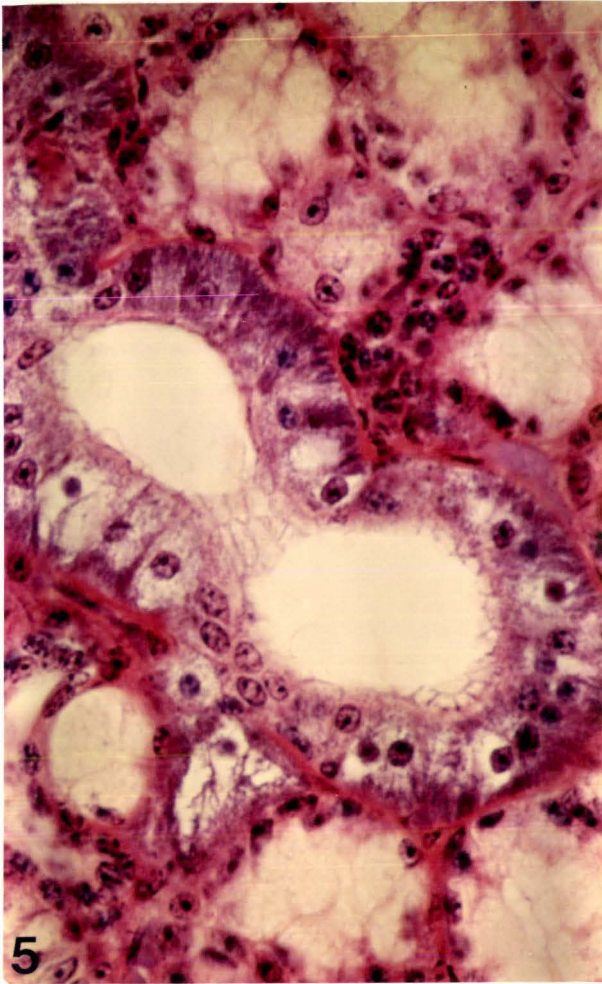


FIGURE 2.6

INTERMEDIATE BUCCAL GLAND

- 2.6.1 Mucous cells containing a mixture of neutral and acidic mucosubstances. Note intralobular ducts lined by cuboidal epithelium.
(PAS/Alcian Blue/H and E).
Magnification: x 260
- 2.6.2 Mucous cells containing PAS positive mucosubstances.
(PAS/Tartrazine).
Magnification: x 100
- 2.6.3 An intralobular duct with three intraepithelial granular duct cells similar to those of the parotid and ventral buccal glands.
(Alcian Blue pH 2.5/H and E).
Magnification: x 650
- 2.6.4 Proteoserous demilunes containing salivary protein band 4.
(Light Green counterstain).
Magnification: x 260

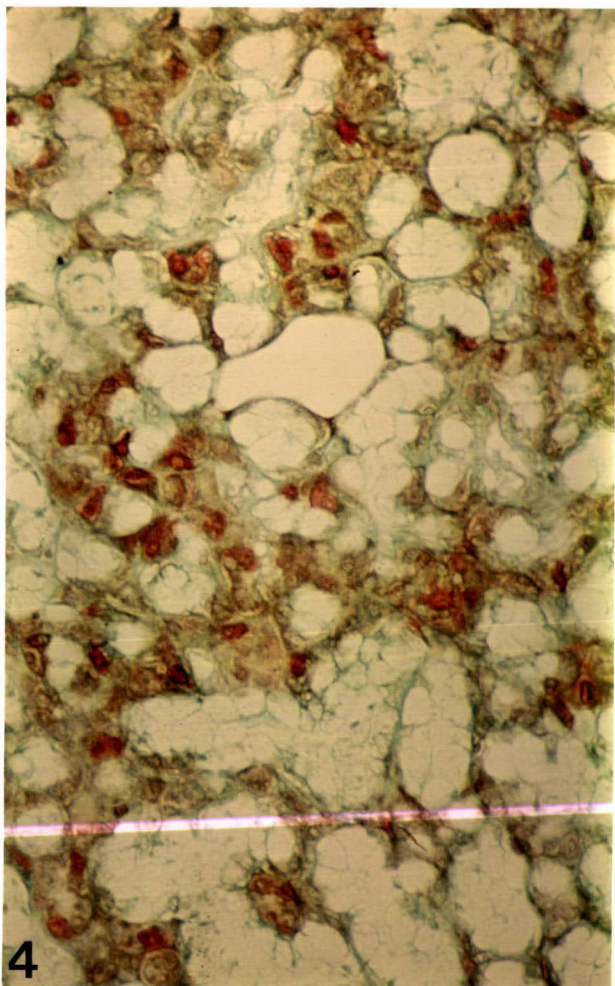
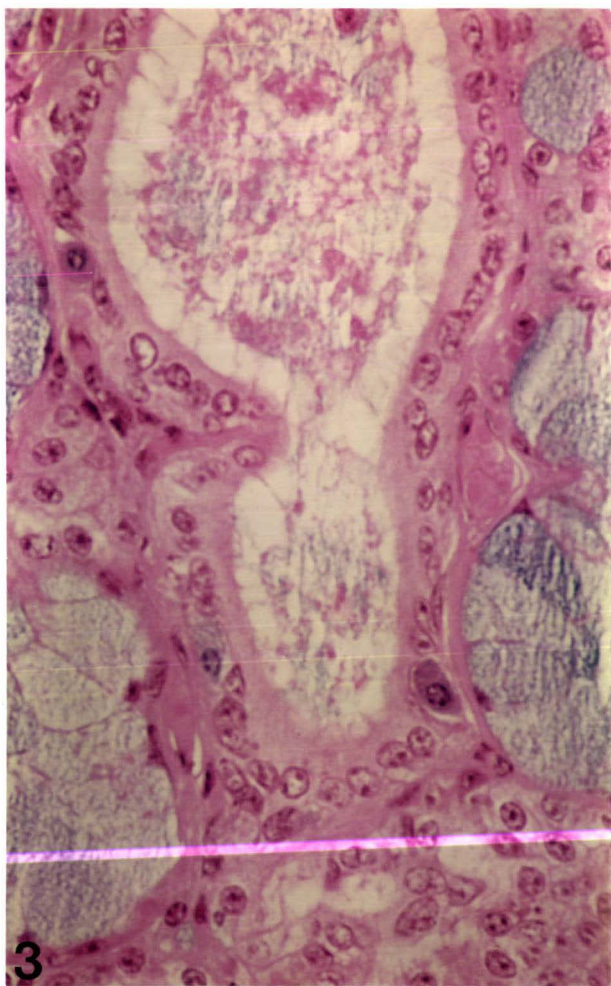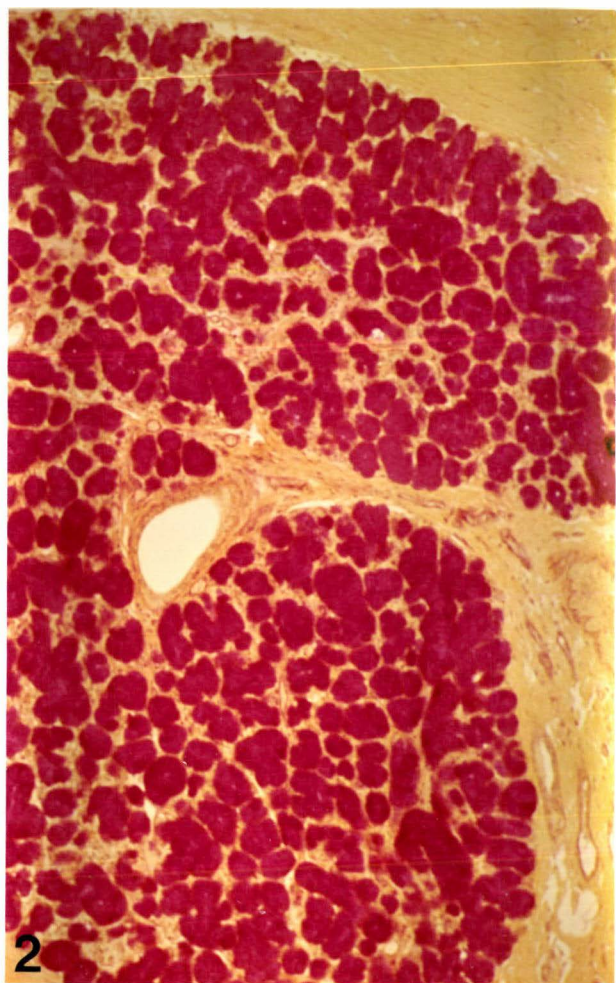
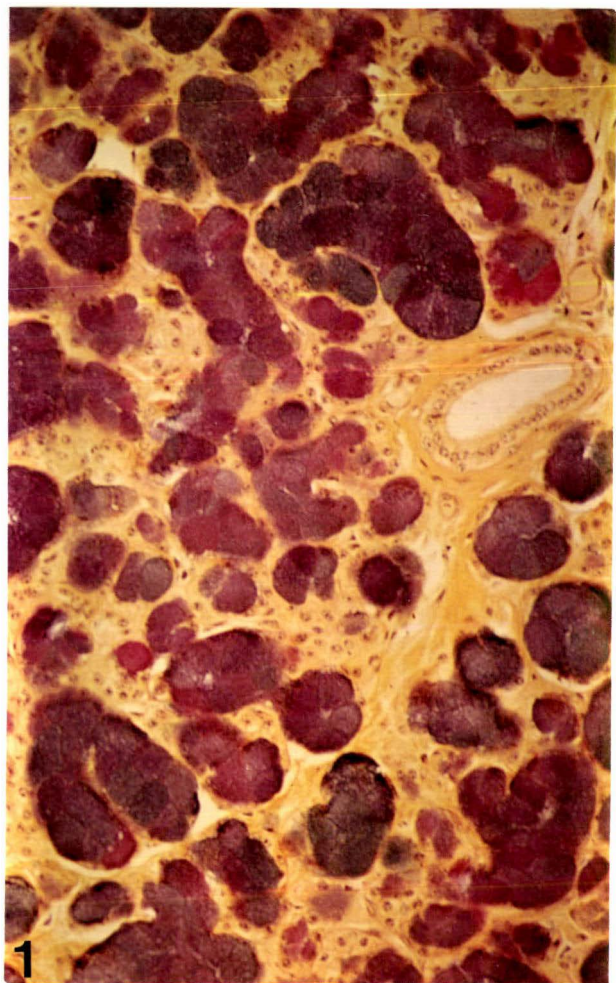


FIGURE 2.7

DORSAL (UPPER) BUCCAL GLAND

- 2.7.1 Toluidine blue metachromasia of mucous cells. Note numerous interlobular and intralobular ducts.
Magnification: x 260
- 2.7.2 The distribution of sulphate groups in some mucous cells. Note intense Alcian Blue staining of mast cells at low pH. (Alcian Blue pH 1.0/H and E).
Magnification: x 260
- 2.7.3 A group of proteoserous cells scattered among mucous endpieces. Note separate ductal system within proteoserous islet. (Alcian Blue pH 2.5/H and E).
Magnification: x 650
- 2.7.4 A possible holocrine secretory mechanism. Note cellular matter mixed with secretory products. (Alcian Blue pH 2.5/PTAH).
Magnification: x 650

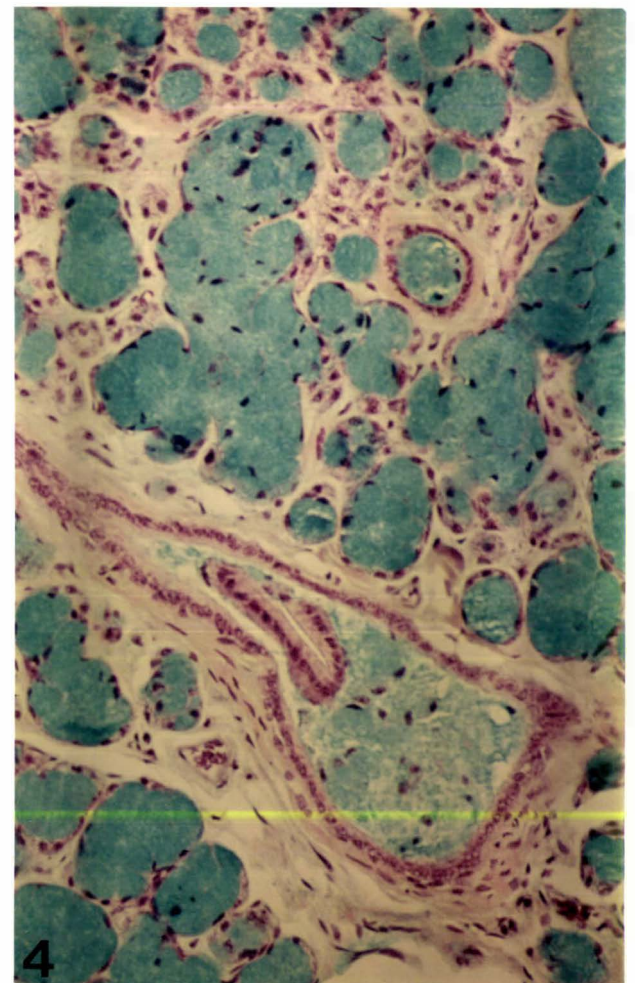
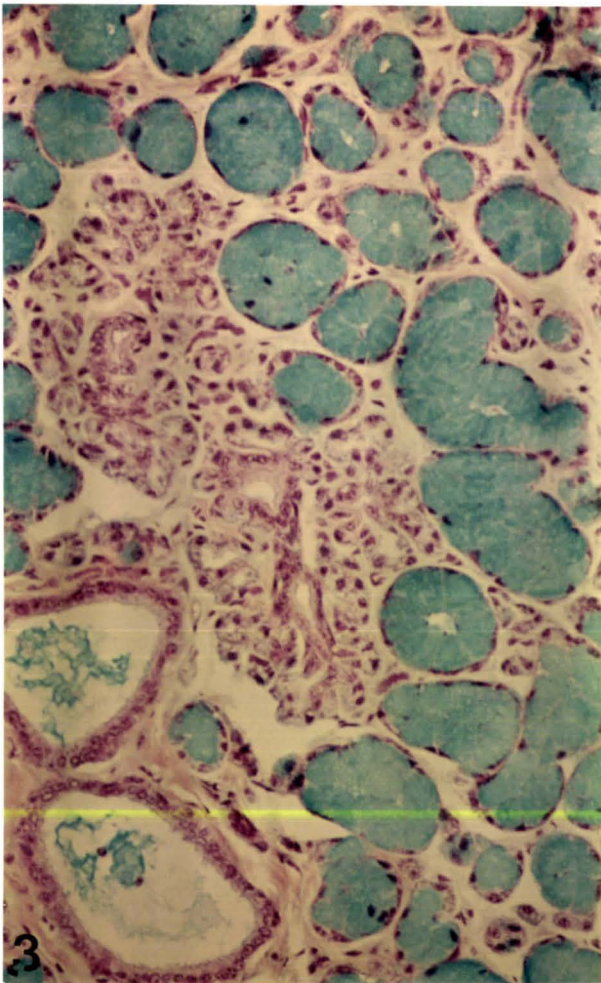
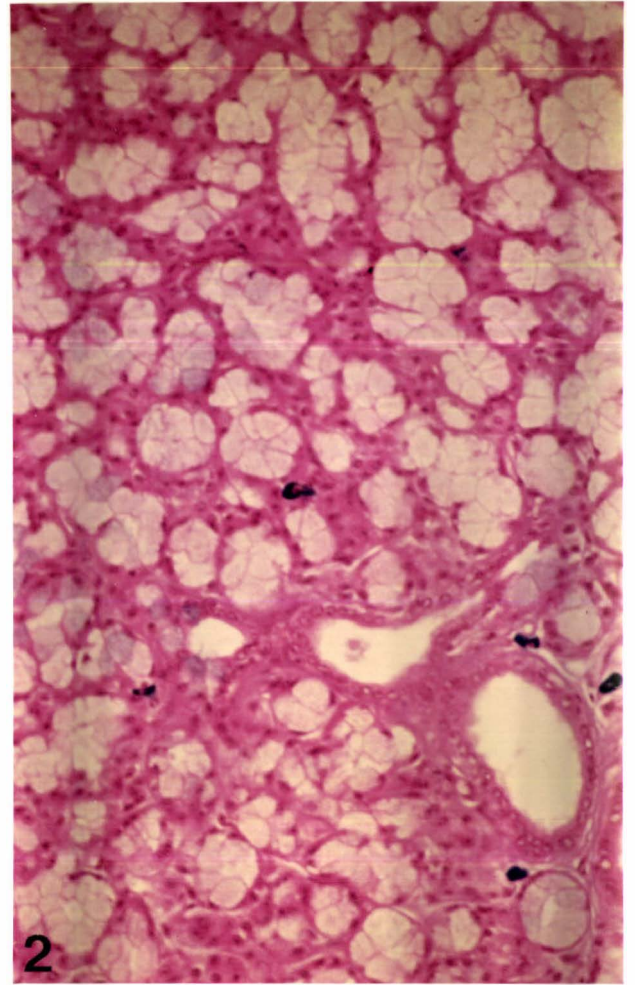
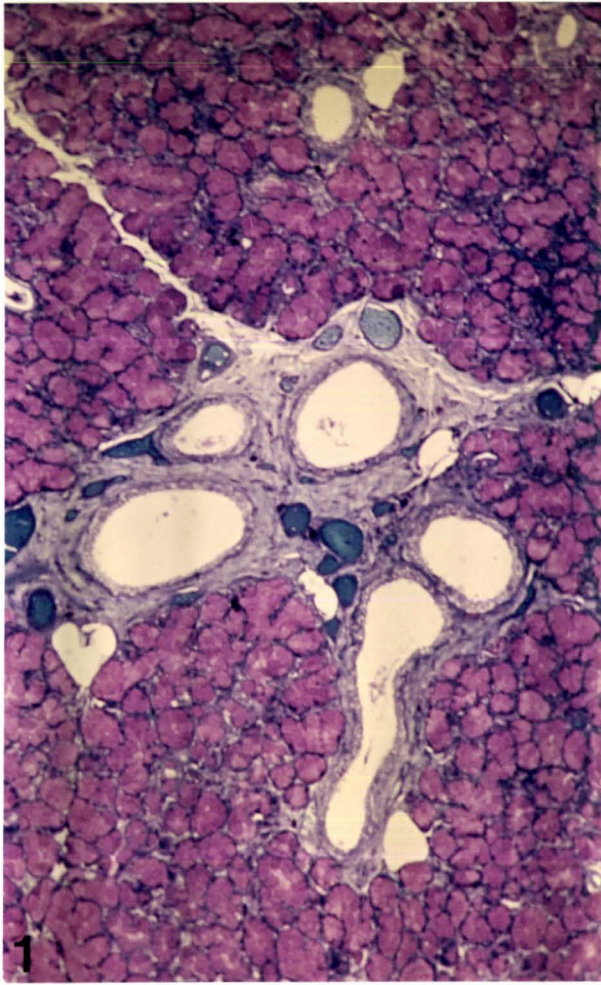


FIGURE 2.8

PALATINE GLANDS

- 2.8.1 Distribution of PAS positive mucosubstances in mucous cells. Note numerous proteoserous cells scattered among mucous cells. (PAS/Tartrazine). Magnification: x 260
- 2.8.2 A possible holocrine secretory mechanism within some secretory endpieces. Note cellular matter mixed with mucus and presence of sulphated mucosubstances in mucous cells. (Alcian Blue pH 1.0/H and E). Magnification: x 260
- 2.8.3 An intraepithelial granular duct cell located within the wall of an intralobular duct. (Alcian Blue pH 2.5/PTAH). Magnification: x 650
- 2.8.4 A typical secretory endpiece with carboxylated acid mucosubstances in mucous cells and predominantly proteoserous demilunes. (Alcian Blue pH 2.5/PTAH). Magnification: x 650

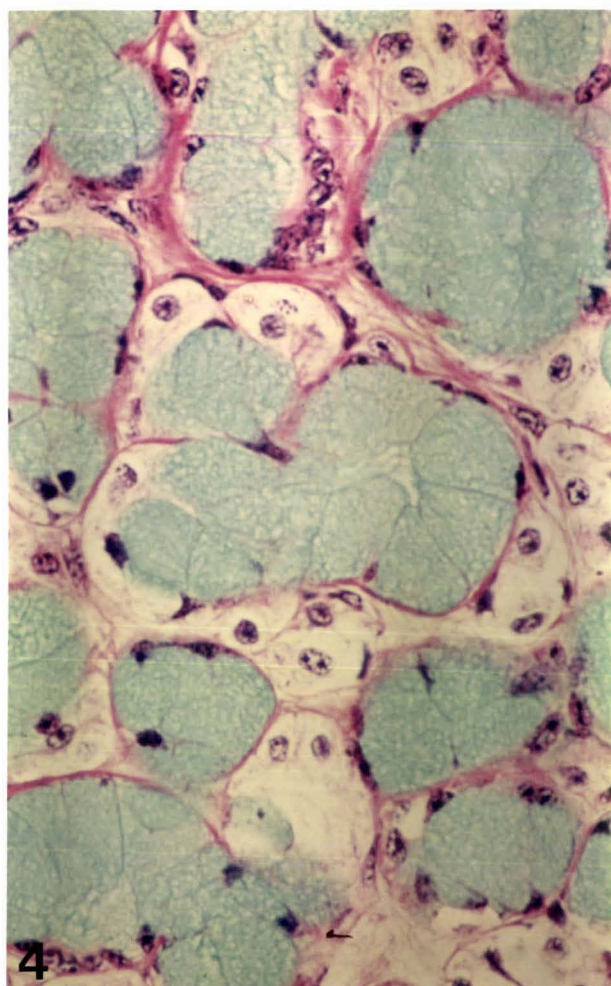
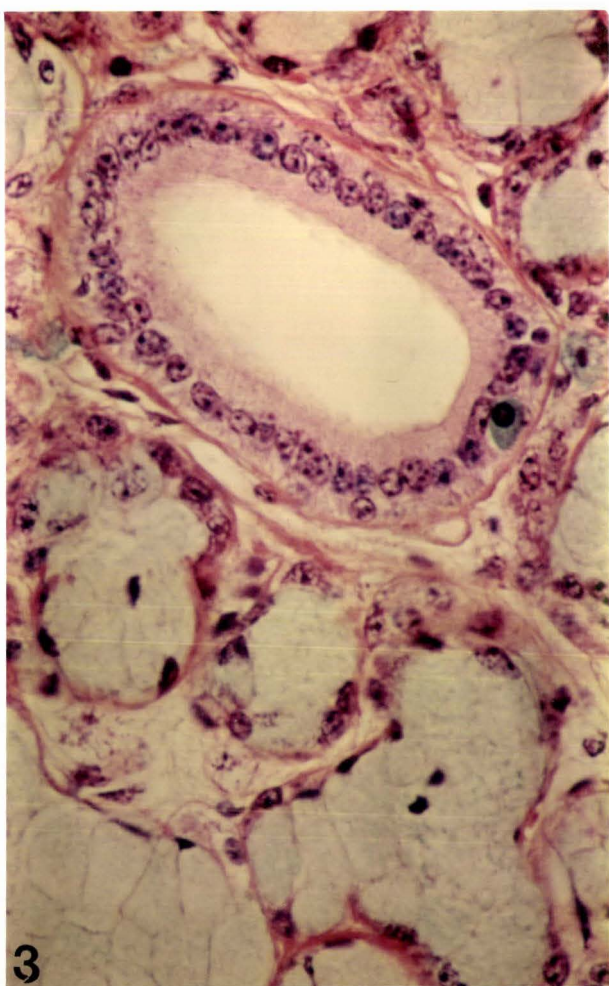
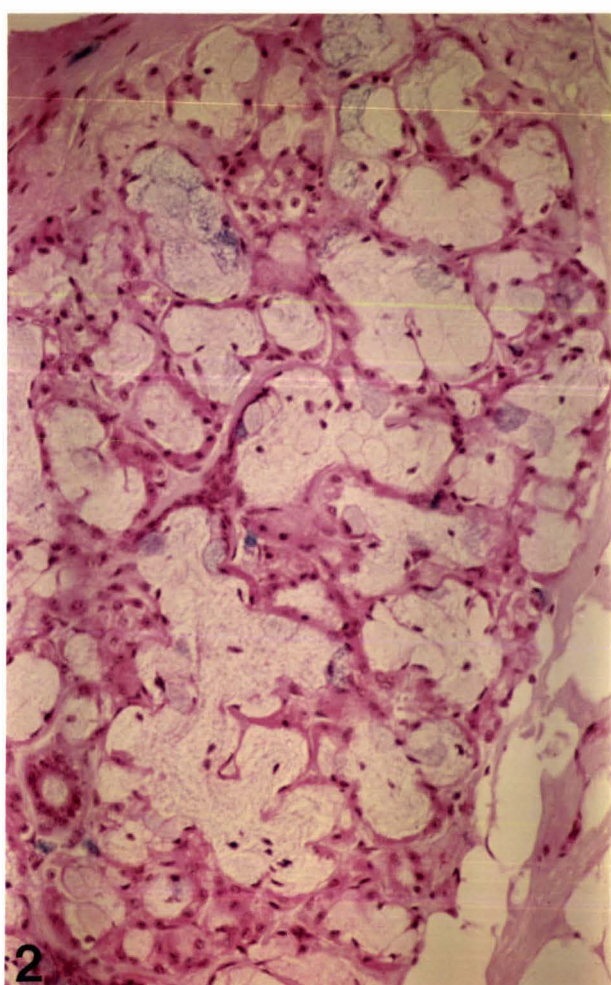
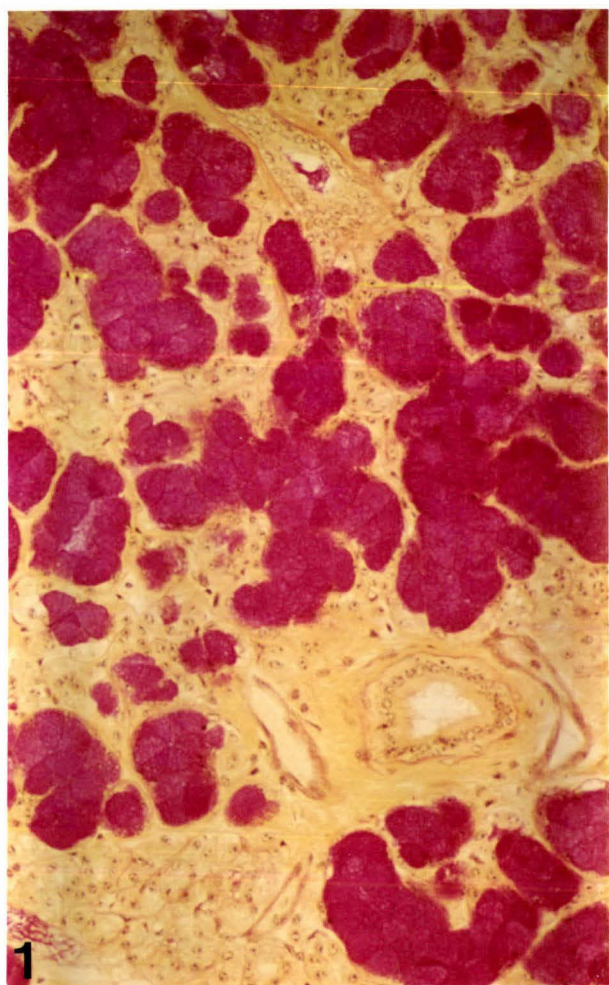


FIGURE 2.9

POSTERIOR TONGUE GLANDS

- 2.9.1 Subepithelial excretory ducts located between mucous endpieces and dorsal surface of tongue. (Alcian Yellow/H and E).
Magnification: x 260
- 2.9.2 Secretory endpieces containing mucous cells stained with colloidal iron. Note large interlobular ducts. (Hales colloidal iron).
Magnification: x 260
- 2.9.3 Distribution of Alcian Blue positive sulphate groups in demilunes. (Alcian Blue pH 1.0/H and E).
Magnification: x 650
- 2.9.4 Distribution of PAS positive mucosubstances in demilunes. Mucous cells have stained for both acidic and neutral mucosubstances. (Alcian Blue pH 2.5/PAS).
Magnification: x 650

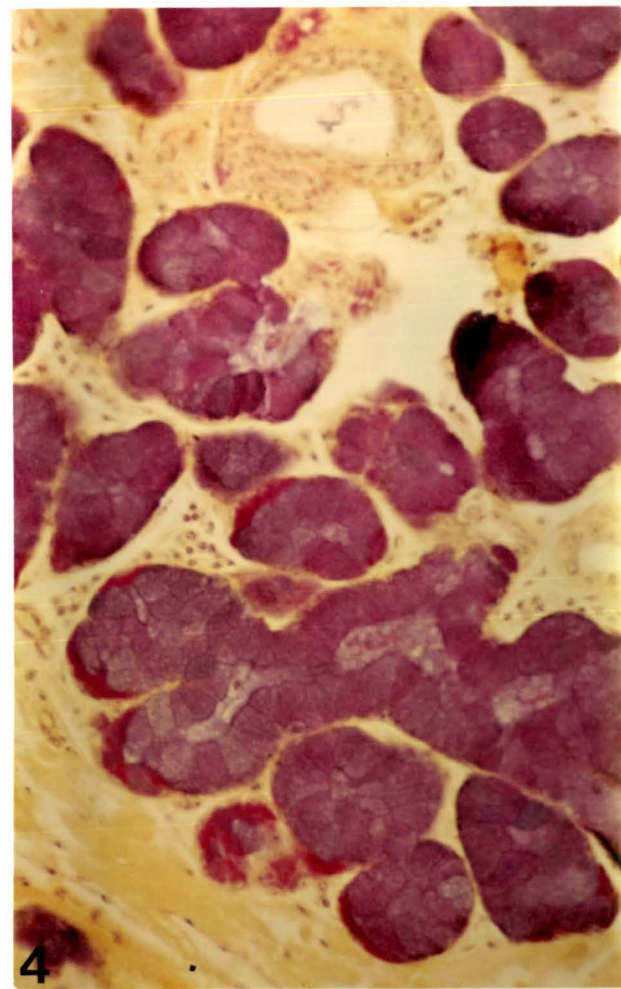
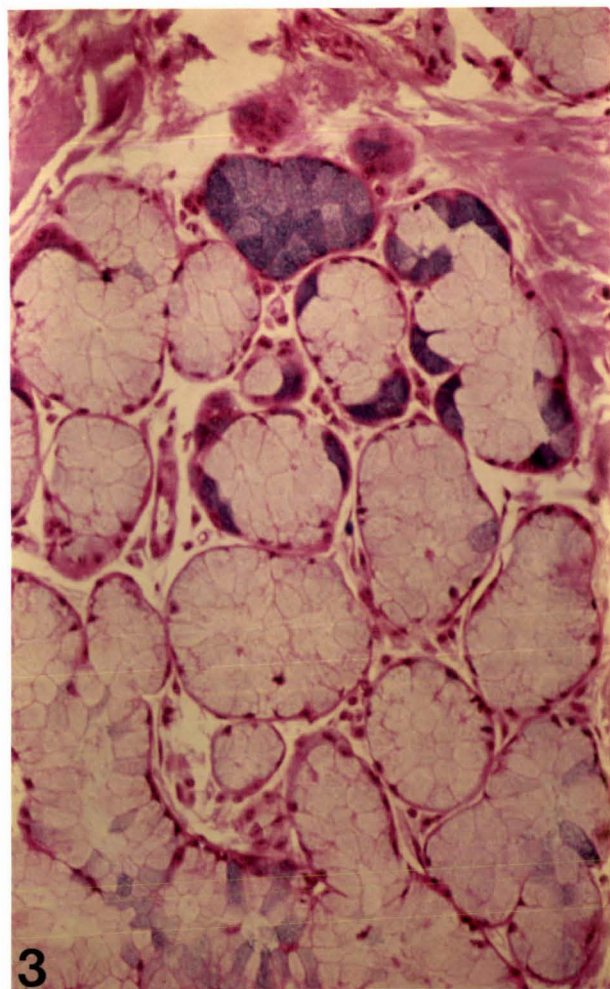
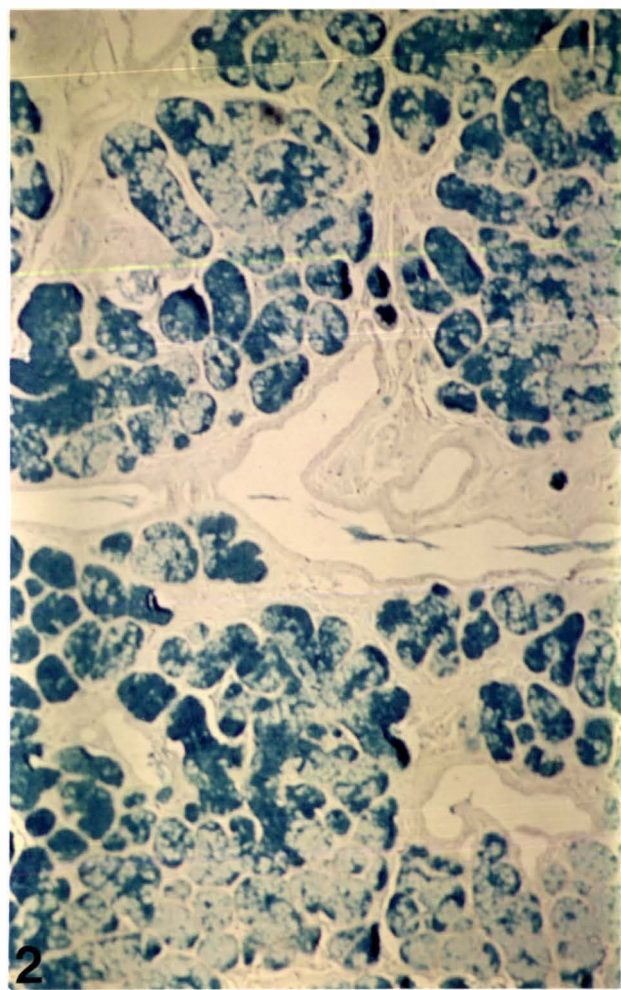
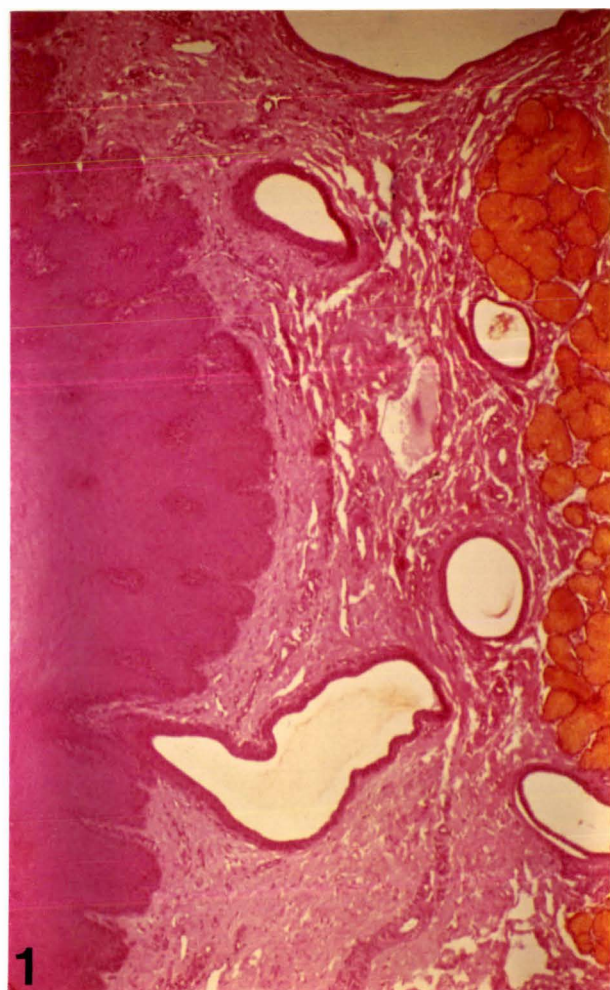


FIGURE 2.10

PHARYNGEAL GLANDS

- 2.10.1 Distribution of glandular tissue in the epiglottis. Note elastic cartilage.
(Alcian Blue pH 2.5/PAS).
Magnification: x 100
- 2.10.2 Mucous cells containing a mixture of both neutral and acidic mucosubstances. Demilunes contain PAS positive neutral mucosubstances. Note numerous plasma cells between secretory endpieces.
(Alcian Blue pH 2.5/PAS).
Magnification: x 650
- 2.10.3 Intralobular duct epithelia lined with goblet cells.
(Hales colloidal iron/Neutral Red).
Magnification: x 650
- 2.10.4 Secretory endpieces which communicate directly with intralobular ducts.
(Alcian Blue pH 2.5/PTAH).
Magnification: x 650

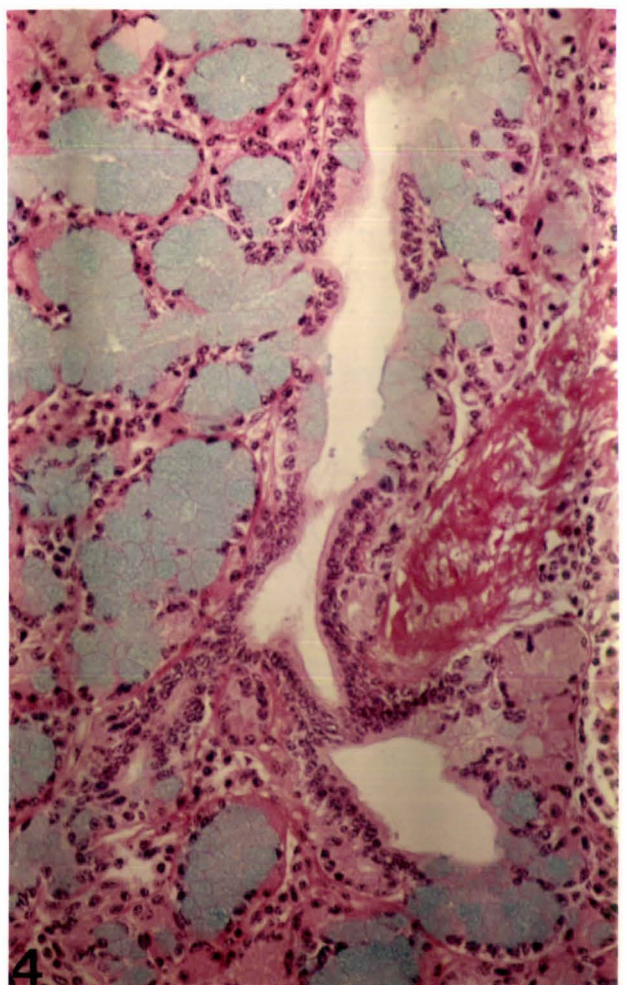
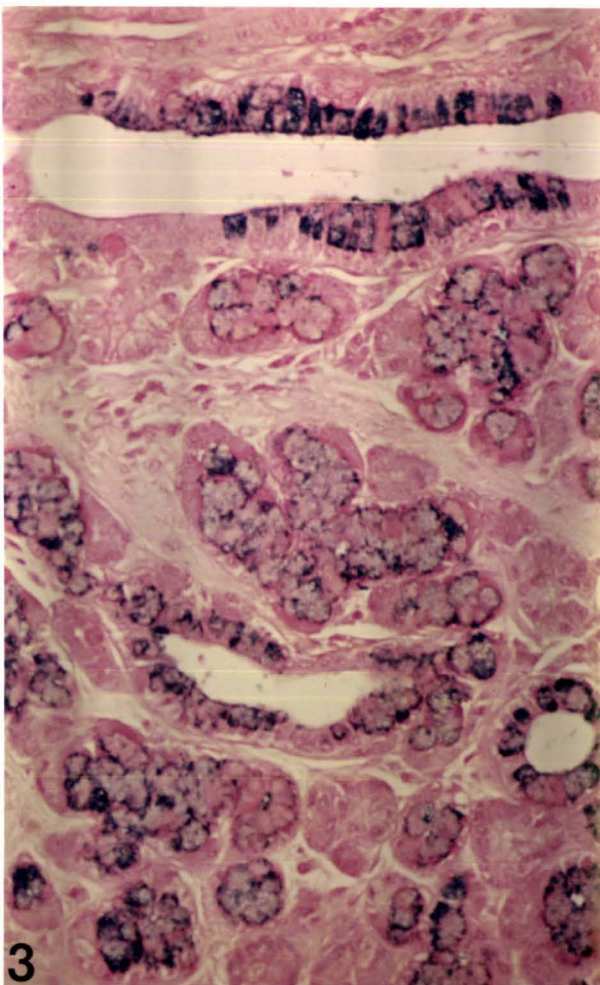
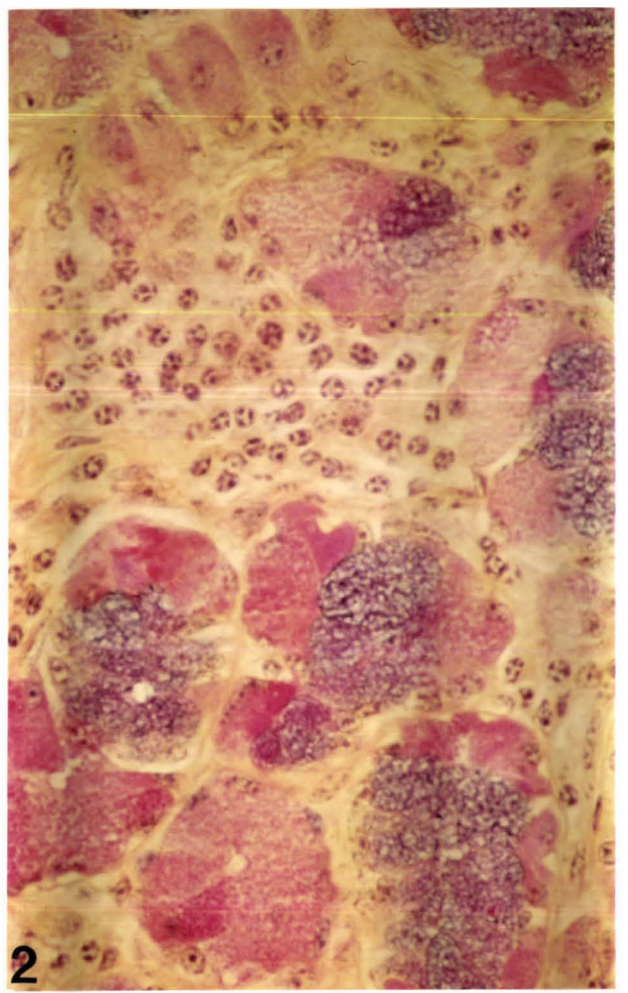
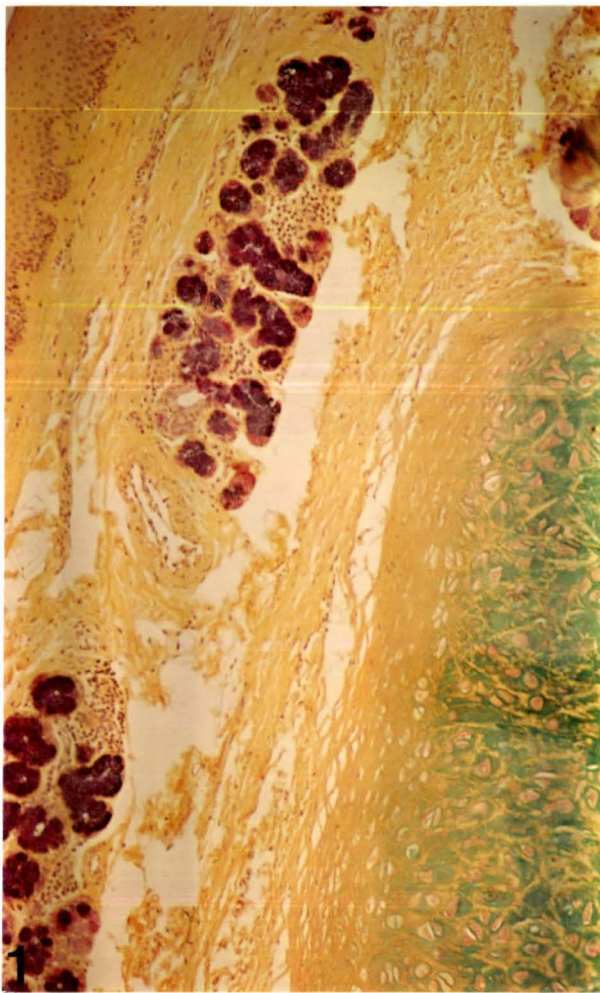


FIGURE 2.11

HYALURONIDASE ACTIVITY

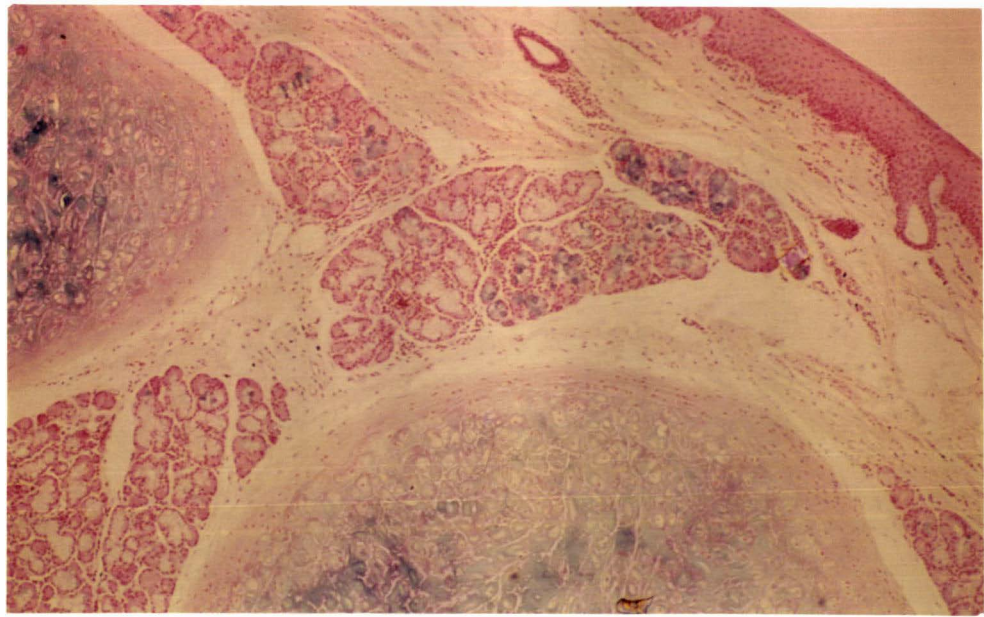
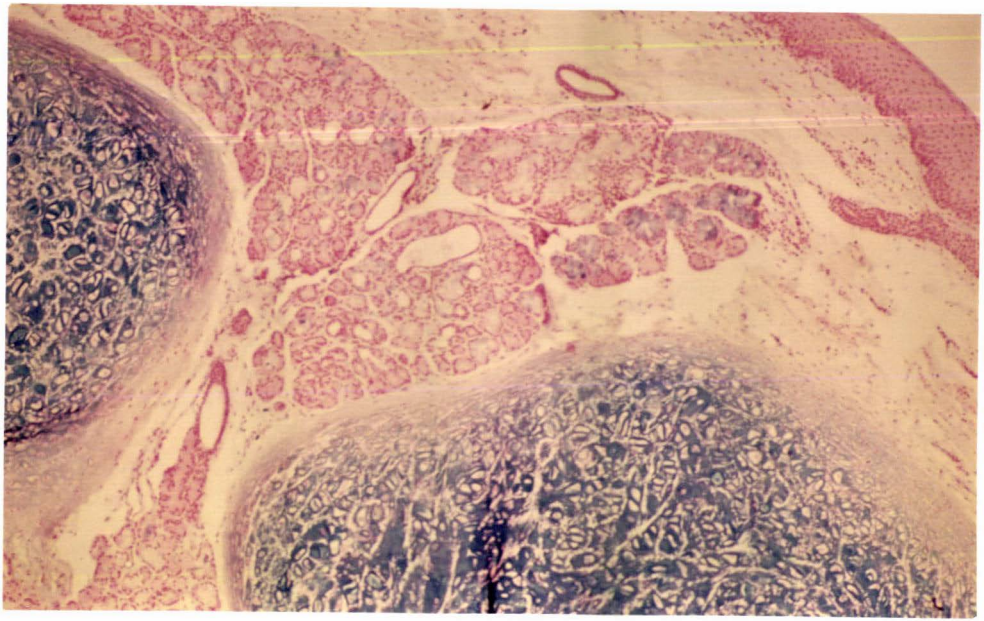
2.11.1 Demonstration of sulphate groups in pharyngeal gland mucous cells and matrix of cartilage, shown by Alcian Blue staining at low pH. (Alcian Blue pH 1.0/H and E).

Magnification: x 260

2.11.2 Hyaluronidase activity has noticeably reduced staining intensity of sulphate groups found in the cartilage matrix. Staining intensity of sulphate groups distributed in mucous cells remains unaltered. Similar results were obtained from mucous cells of the mandibular, sublingual and the minor glands (with the exception of the ventral buccal); a result which suggests that mucous cells probably contain a sulphated glycoprotein (or a sialo-sulphated glycoprotein) whereas the cartilage matrix is likely to contain acid mucopolysaccharides such as chondroitin sulphates.

(Hyaluronidase/Alcian Blue pH 1.0/H and E).

Magnification: x 260



2.4 Discussion

The major and minor salivary gland endpieces of cattle consisted of tubular endpieces composed of secretory cells specialised for synthesis and secretion of mucosubstances; the composition of these was demonstrated by a range of histochemical methods.

In general, the histochemical findings successfully established the classification of secretory cells into two divisions: proteoserous and mucous. The secretory cells that contained only scattered PAS positive material, synthesised some neutral glycoproteins (see Appendices I and II) and were classified as proteoserous cells. These cells are, however, primarily specialised for the secretion of water and electrolytes. The secretory cells, which contained mucosubstances that reacted strongly with PAS and basic stains such as Alcian blue, Alcian yellow, Toluidine blue, Azure A and colloidal iron consisted of a mixture of both neutral and acidic glycoproteins (see Appendices I and II), such cells were classified as mucous cells. These cells may additionally have a secondary role in the secretion of some water and electrolytes.

The parotid gland secretory portion was composed predominantly of proteoserous cells which occasionally contained diastase resistant PAS positive material (Figure 2.1.1). This suggests that in cattle the parotid gland could be responsible for the synthesis and secretion of some neutral glycoproteins in addition to secreting large quantities of water and electrolytes. Several glycoprotein components from bovine saliva have recently been isolated by Jones et al., (1982); glycoprotein bands 1, 3, 5 and 6 in particular, are secreted by the parotid glands (Table 1.1). In addition, there was some evidence to indicate that the parotid glands may also be secreting small quantities of sialic acid (Figure 2.1.2) since in a few tissue samples examined, isolated secretory cells had reacted with AB (pH 2.5), AY and colloidal iron, all basic stains specific for carboxyl

radicles. AB (pH 2.5) and Toluidine blue positive material was also occasionally identified in the lumens of intralobular and interlobular ducts, further demonstrating that acidic glycoproteins such as sialic acid may be secreted by the bovine parotid glands, albeit in small quantities.

Histological observations of parotid gland ducts revealed an unusual absence of basal striations in the intralobular ducts (Figure 2.2.3) where considerable water and electrolyte transport activity is expected to occur (Young and van Lennep, 1979). Basal striations, which house numerous mitochondria (van Lennep et al., 1977) are usually found in ducts specialised for ionic transport. The above finding pertaining to bovine parotid intralobular ducts conflicted with observations made on sheep parotid gland tissues (Figure 2.2.4) where "striated" (intralobular) ducts were abundant. In general, striated ducts of most mammalian species are prominent in the parotid gland, next the mandibular and lastly the sublingual (Leeson, 1967). However, the bovine parotid gland clearly departs from this general rule, because of relatively poorly developed intralobular ducts.

Although basal striations were absent from parotid gland intralobular ducts, there was some evidence to suggest that these may possibly be involved in synthesis of proteinaceous material, since diastase-resistant PAS positive granules were sometimes observed in the cytoplasm of some duct cells (Figure 2.2.1). At present a satisfactory explanation cannot be offered for the implication of this PAS staining, apart from attributing it to a neutral glycoprotein present in some duct cells. Another feature of intralobular duct cells was the presence of PAS positive apical cytoplasmic protrusions or "apical blebs"; although such "apical blebs" have been previously attributed to stages of an apocrine secretory mechanism, their real significance is still debated by most authors (see Young and van Lennep, 1978).

Goblet cells, which stained intensely for both neutral

and acidic mucosubstances, were present in the main excretory duct of the bovine parotid glands (Figures 2.1.3 and 2.1.4). Overall, some mucus could therefore still be secreted by the parotid glands, in addition to its voluminous watery secretion.

In contrast to the parotid gland, the mandibular gland secretory cells contained mucus, composed of acidic and neutral glycoproteins. The PAS method, together with acetylation and subsequent saponification (see Appendix I) established the presence of glycol groups in mucosubstances. Biochemically, these belong to galactose, mannose, acetylglucosamine, acetylgalactosamine, fucose and sialic acids, (Culling, 1974). The acidic side groups of mucosubstances, investigated by use of basic stains and blocking methods (see Appendix I) were identified as carboxyl groups and sulphate groups which, in epithelial secretions, belong to derivatives of sialic acids and sulphated glycoproteins (Reid and Clamp, 1978).

The enzyme hyaluronidase utilized to determine the origin of sulphate groups in mucous secretions, did not reduce or eliminate AB staining at pH 1.0 (Figure 2.11). This rules out the possibility that significant quantities of acid mucopolysaccharides such as chondroitin sulphates and hyaluronic acids, could be present in bovine salivary gland mucosubstances. AB (pH 1.0) staining observed after hyaluronidase treatment could therefore be attributed to sulphated glycoproteins. The bovine mandibular gland, however, did not appear to be a major source of sulphated glycoproteins owing to very weak AB (pH 1.0) staining observed in only a few mucous cells.

The sialic acid content of the mandibular gland was histochemically analysed by neuraminidase digestion (Figures 2.4.9 and 2.4.10). The use of this enzyme as well as methylation (see Appendix I) successfully abolished basophilia at pH 2.5. In particular methylation, followed by saponification, failed to restore AB staining at pH 2.5; this

suggests that sialic acid residues present were removed by neuraminidase as well as acid hydrolysis. Although the presence of sialic acid residues were established by neuraminidase activity, the BIAL reagent (specific for sialic acid) failed to react with sialic acid residues of mucous cells (Figure 2.4.7). This anomalous result may have been caused by the hydrolytic action of concentrated HCl acid heated to 70°C for the BIAL reaction and the presence of heat labile sialic acid residues.

The metachromatic purple reaction from Toluidine blue and Azure A methods, was further proof that mandibular gland mucous cells contained considerable amounts of acidic mucosubstances. The blue orthochromatic colour of Toluidine blue is generally indicative of non-acidic material while acidity as a result of carboxyl and sulphate groups shows a purple or purple-red reaction (Culling, 1974). Sialic acids in particular impart a weak purple colour (Figure 2.4.3) while acid mucopolysaccharides such as chondroitin sulphates and hyaluronic acids produce an intense purple-red colour.

Azure A metachromasia at pH 4.0 further established that mucous cells are likely to contain predominantly carboxylated mucosubstances, since purple metachromasia was not observed at low pH. On the other hand, strongly acidic mucopolysaccharides found in the elastic cartilage of the epiglottis for example, were strongly metachromatic at low pH (pH 1.0, 2.0 and 3.0).

In marked contrast to endpiece mucous cells, the demilunes of the bovine mandibular gland contained strongly acidophilic granules (Figure 2.4.6). This acidophilia could be attributed to the presence of histochemically detectable basic proteins. Antibody to bovine salivary protein band 8, for example, reacted intensely with the contents of the demilune cells (Figure 2.4.8). Band 8 is therefore likely to be derived from mandibular gland demilunes and may also be responsible for some or all of the acidophilia.

The demilunes were also weakly positive to PAS and AB at pH 1.0 and 2.5; the demilune secretions could therefore contain some sialic acid and sulphated glycoproteins. Sialic acid, in particular, was positively identified by the BIAL reagent (Figure 2.4.7); this suggests that unlike in mucous cells, carboxyl groups of sialic acid derivatives in demilunes are probably masked by basic proteins and remain mostly unreactive to basic stains such as Alcian blue (Figure 2.4.9). Methylation, followed by saponification restored some AB staining (pH 2.5) in demilunes but failed to restore AB staining of mucous cells. Unlike the mucous cells, the demilunes are thus likely to possess mostly bound sialic acid derivatives not susceptible to hydrolysis. Neuraminidase, followed by AB staining (pH 2.5) failed to restore basophilic staining of demilunes, a result which paralleled neuraminidase reactivity of mucous cells. This suggests that sialic acid of demilunes, although not heat labile is likely to be susceptible to neuraminidase activity.

The intralobular ducts of the bovine mandibular gland, in contrast to those of the parotid gland, were well developed with distinct acidophilic basal striations (Figure 2.4.6). By implication the mandibular gland striated duct cells could be of considerable importance for water and electrolyte transport (Young and van Lennep, 1978).

The mucous cells of the sublingual glands were PAS and AB positive at pH 1.0 and 2.5 (Figure 2.5). The secretory products are thus probably composed of neutral glycoproteins, sialic acids and sulphated glycoproteins. The sialic acid synthesised by sublingual gland mucous cells did not appear to be neuraminidase labile, a result by comparison with that of mandibular gland mucous cells, suggests that sialic acid is probably found in more than one form in bovine saliva. Methylation, for example, failed to remove most of the sialic acid residues; consequently AB staining (pH 2.5) was restored after saponification, a probable indication that sublingual gland sialic acid residues were not removed by hydrolytic action. In contrast the sialic acid

content of mandibular gland mucous cells was both neuraminidase and heat labile and after methylation AB staining (pH 2.5) was not restored by saponification.

Hyaluronidase activity was negative in sublingual gland mucous cells; this suggests that AB staining at pH 1.0 was probably due to the presence of sulphated glycoproteins (Figures 2.5.2 and 2.11).

The demilunes of the sublingual gland were weakly positive to PAS and reacted immunohistochemically with antibody to protein band 9 (Figure 2.5.6); therefore, the secretory products are mostly proteoserous.

The intralobular "striated" ducts of the sublingual gland by comparison with the mandibular gland, were equally well developed (Figure 2.5.5) and likely to be involved in water and electrolyte transport to the same extent as in the mandibular glands. Thus in cattle well developed striated ducts were found only in the mandibular and sublingual glands while those of the parotid were poorly developed.

The mucous cells of the minor glands, in general, contained histochemically similar mucosubstances to those of sublingual glands, but positive staining for sulphate groups was consistently greater than for both sublingual and mandibular glands.

Of the buccal glands, the ventral buccal was structurally and histochemically identical to the parotid. It appears likely that ventral buccal glands may act to supplement the parotid salivary secretion. The dorsal and intermediate buccal and the palatine glands were predominantly specialised for the synthesis and secretion of acidic and neutral mucosubstances (Figures 2.6, 2.7 and 2.8). although a minor proteoserous component was frequently observed. Lobules of proteoserous cells were often scattered amidst the mucous endpieces; their secretions could

contribute significantly to the volume of saliva secreted by the minor glands. The dorsal, intermediate buccal and palatine glands were also unusual in possessing what appeared to be a holocrine secretory mechanism since epithelial cells and necrotic nuclei were often found in duct lumens mixed with mucosubstances from the endpiece cells (Figures 2.7.4 and 2.8.2). The functional significance of such a secretory mechanism present only in some salivary glands is difficult to ascertain without perhaps a preliminary investigation utilising serial sections of tissues from the respective glands.

The posterior tongue had histochemically similar mucosubstances to those of the sublingual, intermediate and dorsal buccal and palatine glands. Neither lobules of proteoserous cells nor evidence of an atypical secretory mechanism was present (Figure 2.9). The demilunes of the posterior tongue glands often contained acidic and neutral mucosubstances (Figures 2.9.3 and 2.9.4) in contrast to demilunes of dorsal, intermediate buccal and palatine glands which appeared to elaborate a proteoserous secretion.

The pharyngeal group of glands histologically differed from the other minor glands. They appeared to possess shorter tubular endpieces and large round demilune cells which contained numerous acidophilic granules (Figure 2.10), in addition to PAS, AB (pH 2.5) and BIAL positive material. The demilune secretions are thus likely to contain some sialic acid and neutral mucosubstances. The composition of mucous cell secretions were however histochemically similar to those of the other minor glands.

The intralobular duct epithelium of the pharyngeal glands frequently contained goblet cells and secretory endpieces which seemed to communicate directly with the duct epithelia (Figures 2.10.3 and 2.10.4). Similar modifications of intralobular duct epithelia were not observed in the other salivary glands examined. Functionally, however, a duct epithelium with secretory cells could provide an

additional supply of mucosubstances to supplement those secreted by mucous and demilune cells.

An investigation of plasma cell numbers in both major and minor salivary glands of cattle revealed that most were distributed in the connective tissue stroma and subepithelial sites of the sublingual glands (Figure 2.5.7) and secondarily, in similar locations of the pharyngeal glands (Figure 2.10.2). The sublingual glands in particular appeared to be the major source of immunoglobulins found in bovine saliva. Some plasma cells were also frequently observed in the connective tissue stroma of the mandibular glands usually between secretory endpieces and striated ducts, while only a few such cells were present in subepithelial sites of intermediate and dorsal buccal, palatine and posterior tongue glands. On the other hand, the parotid and ventral buccal glands contained negligible numbers of plasma cells and are therefore unlikely to be major contributors of immunoglobulins to bovine saliva.

Secretory IgA, the major immunoglobulin found in bovine saliva (Watson and Lascelles, 1973), is probably synthesised and secreted by the majority of plasma cells in bovine salivary glands. The presence of sIgA in plasma cells was immunohistochemically demonstrated (Figure 2.4.11). Immunohistochemical studies also demonstrated the distribution of bovine salivary protein bands 4, 8, 10 and 9 in salivary gland tissues (Figures 2.3, 2.4.8, 2.5.6 and 2.6.4). Most proteoserous cells of the parotid and ventral buccal glands reacted with anti band 4 and anti band 10 antibody. Proteoserous cells positive for anti band 10 antibody were generally more widespread than those positive for anti band 4 antibody (Figure 2.3). Biochemical studies have also established a greater proportion of protein band 10 in parotid saliva than band 4 (W.T. Jones, personal communication). Band 4 from parotid saliva has been correlated with bloat susceptibility in cattle (McIntosh and Cockrem, 1974) but biochemical tests have shown that parotid glands of both L.S. and H.L. animals contained approximately equal

quantities of protein band 4 (W.T. Jones, personal communication). Immunohistochemical investigations of parotid tissue samples also revealed that both strains had equal proportions of anti band 4 positive proteoserous cells. However, only H.S. animals are known to secrete band 4 in significant quantities, a result which suggests that poorly understood cellular regulatory mechanisms in parotid proteoserous cells of L.S. and H.S. animals may be responsible for the synthesis and secretion of band 4.

Band 4 was additionally found in the demilunes of the intermediate buccal glands (Figure 2.6.4); this latter group of glands was also unusual in secreting traces of all the salivary proteins isolated from bovine saliva (Table 1.1). Embryologically, the intermediate buccal glands may have retained the genetic material required for the synthesis of all the salivary proteins throughout the animal's lifetime.

CHAPTER 3. PAROTID GLAND INTRAEPITHELIAL DUCT CELLS

3.1 Introduction

Previous histological studies of ruminant parotid glands have always revealed the presence of a granular cell type, presumably non-epithelial in origin and of doubtful identity, distributed within the epithelium of intralobular ducts. Shackleford and Klapper (1962) and Birtles (1981) designated these cells in the bovine parotid gland as "intrastriated duct cells" which closely resembled both mast cells and plasma cells. Van Lennep et al. (1977), from a study of the sheep parotid gland, observed two granular cell types located within the epithelium of striated ducts. The most common type was an intraepithelial mast cell, found also in the connective tissue stroma surrounding the striated ducts. The other type, referred to as a "globule leucocyte", was characterised by the possession of large intracytoplasmic eosinophilic granules. Recently, Vignoli and Nogueira (1981), from a histological and histochemical study of the parotid gland of a bovidae species, *Bos indicus*, reported the presence of "intraepithelial mastocytes" abundantly distributed within the intralobular duct epithelium. Pal et al. (1972), who examined the parotid glands of the Indian buffalo (*Bubalus bubalis*) have also reported an "intraepithelial cyst" with staining characteristics similar to that of a mast cell, frequently present within the epithelium of the excretory duct. It is unclear whether the reference was to an unknown cell type.

The parotid and the histologically identical ventral buccal gland examined in the present study, contained several intraepithelial granular cells within the walls of intralobular ducts and infrequently in the walls of larger interlobular ducts. Similar cells were also rarely observed within intralobular duct epithelia of the dorsal and intermediate buccal glands and palatine glands.

Intraepithelial granular duct cells, in general, resembled mast cells in morphology and staining characteristics, but possessed nuclear configurations similar to those of plasma cells.

For further discussion, the term intraepithelial granular (IEG) duct cell has been adopted instead of intrastriated duct cell because basal striations are not a feature of intralobular ducts of the bovine parotid gland (Section 2.3.1) and IEG duct cells were also occasionally present within the interlobular duct epithelium.

The precise nature of the IEG duct cells were examined by histological, histochemical and ultrastructural methods. Since IEG duct cells of the parotid gland have also been implicated with bloat susceptibility in cattle (Section 1.6) the present study has extended this finding to comment on the possible function of these cells in relation to bloat.

As far as it is known, there have been no reports yet of detailed investigations pertaining to unknown or poorly defined cell types located in salivary gland ducts.

3.2 Materials and Methods

Histological sections of parotid and ventral buccal gland tissues prepared earlier for histochemical examination (Section 2.2) were additionally used for a light microscopic evaluation of IEG duct cells. The cytoplasmic contents of these cells were also closely investigated with the aid of the following additional methods:-

1. Phloxine-Tartrazine
2. Bismarck brown
3. Neutral red
4. Fast red 2B
5. Fluorescein conjugated anti IgA
6. Silver impregnation

(see Appendix II for staining procedures).

Histological sections from the sheep parotid gland and abomasum, previously fixed in Bouins fluid and stained with AB at pH 1.0 and 2.5 and PTAH, were also examined for the presence of identical or closely related cell types to the IEG duct cells of cattle.

From the dissection of two animals (Section 2.2), samples of parotid tissue were separately taken for an electron microscopic examination of the IEG duct cells.

Preparation of tissues for electron microscopy

Tissues were initially placed in petri dishes which contained a small quantity of modified Karnovsky's fixative. Tissue blocks 1-2 mm² were cut with a scalpel and allowed to fix for at least two hours.

Modified Karnovsky's Fixative

Prepare 20 mls of 10% solution of paraformaldehyde by dissolving 2 grams of paraformaldehyde powder in 20 mls of distilled water and heating to 60°C in a fume cupboard. Add a few drops of 1N NaOH until the solution clears. Allow to

cool before use. Prepare fixative with:

0.2M Sodium cacodylate buffer 50 mls
 10% paraformaldehyde in water 20 mls
 25% glutaraldehyde in water 10 mls
 add distilled water to 100 mls.

- A. Fixed tissues were washed in three changes of 0.2M Sodium cacodylate buffer (pH 7.2) for approximately 2 hours.
- B. Postfixation was carried out in 1% OsO_4 for 1 hour with sufficient OsO_4 to cover the tissues. Samples were then washed for 30 minutes with sodium cacodylate buffer.
- C. Fixed tissues were dehydrated in a graded alcohol series at room temperature. 25%, 50%, 70%, 95% and 2 x 100% concentrations were used, 20 minutes each on stirrer with tops on sample bottle. Some tissue samples were left overnight in 1% uranyl acetate in 70% alcohol at 4°C to intensify staining.
- D. The tissues were infiltrated with 2 x 20 minute changes of propylene oxide using a mechanical stirrer in a fume cupboard.
- E. Embedding medium was prepared using a mixture of 25% resin and 75% propylene oxide. The embedding medium (Durcupan ACM Fluka) consisted of an epoxy resin, hardener, accelerator and plasticizer. For 10 mls of resin the above components were mixed in the following proportions:-

| | | |
|-------------|-----|------------|
| Epoxy resin | (A) | 5.47 grams |
| hardener | (B) | 4.79 grams |
| accelerator | (C) | 0.2 ml |
| plasticizer | (D) | 0.1 ml |

Components A and B were weighed and incubated at 60°C for about 10 minutes to ensure a good mix. Components

C and D were next added carefully from a 1 ml syringe. The components were mixed thoroughly until the solution cleared.

- F. Propylene oxide was removed after infiltration and the embedding medium of 25% resin and 75% propylene oxide was added and left overnight on a stirrer. The following morning contents were replaced by fresh 100% resin, left for 6-8 hours, then embedded in fresh 100% resin in gelatine capsules and hardened for 48-72 hours at 60°C.
- G. Approximately 2 μm thick sections were cut with a glass knife on an LKB ultratome, stained with Toluidine blue and examined with a light microscope to note tissue contents. Thin sections (600 Å) of intralobular duct epithelium were cut and floated onto copper grids.
- H. Sections were stained with uranyl acetate (5 minutes), washed with 50% alcohol and distilled water. Grids were dried on filter paper and stained in lead acetate (5 minutes), followed by rinsing in distilled water.
- I. Sections were examined and photographed using a Philips EM 200 electron microscope.

3.3 Results

3.3.1 Histology

IEG duct cells were frequently located within the walls of intralobular ducts of the parotid and ventral buccal glands, adjacent to the basement lamina of the duct epithelium. Usually, two to seven IEG duct cells were observed in most intralobular duct cross sections (Figure 3.1). Very rarely, some cells appeared to have been shed into the duct lumen (Figure 3.1.6) and others were found at subepithelial sites close to a duct (Figure 3.1.5). The range of shapes exhibited varied widely, most had irregular outlines while some were round or oval shaped with eccentrically-located nuclei.

The cytoplasm of IEG duct cells was often vacuolated in appearance and remained refractory to most histological stains but contained numerous round granules or globules that showed considerable variation in size and quantity per cell (Figure 3.3). Nuclei of IEG duct cells were characteristically round or oval in shape and often occupied an eccentric position. The distribution of chromatin around the periphery of the nucleus appeared similar to the "cart-wheel" pattern observed in nuclei of plasma cells. Signs of cell division or evidence of pyknosis in nuclei were not observed.

Some difficulty was encountered in an attempt to make a distinction between mature and immature IEG duct cells, although a common observation was that the majority of cells seemed to develop within the duct epithelium. The granular contents were probably released at a particular stage of the cell cycle or possibly on receipt of a stimulus to "degranulate". The cytoplasm of some cells was completely devoid of granules (Figure 3.3.6) while others were replete with granules of various sizes (Figure 3.3).

A potential precursor cell was not identified in the

vicinity of intralobular ducts nor was there any evidence to suggest that IEG duct cells had previously migrated from the subepithelial connective tissue via the basement lamina into the duct epithelium.

IEG duct cells noted in the epithelium of intralobular ducts of the three minor glands, dorsal, intermediate buccal and palatine glands were similar to those of the parotid glands (Figures 2.6.3 and 2.8.3).

Mature subepithelial or mucosal mast cells occasionally observed close to the intralobular ducts or between secretory tubules of the parotid and ventral buccal glands were polymorphic in appearance (Figure 3.2). Some mucosal mast cells were relatively flattened or elongated and consisted of spherical nuclei with scattered chromatin, while others were rounded or oval-shaped with nuclei similar to those of plasma cells (Figure 3.2.4). Mucosal mast cells of all other glands were similar to those of parotid and ventral buccal glands but had a tendency to be distributed near plasma cells; in such instances the close resemblance between nuclei of both mucosal mast cells and plasma cells was strikingly evident. Mast cells observed in loose areolar connective tissue of all glands were elongated with long tapering ends. Their nuclei were often similar to those of mucosal mast cells but at times were densely staining without peripheral chromatin.

3.3.2 Histochemistry

Histochemical reactions of IEG duct cells have been separately summarized in Table 3.1 together with reactions observed for mast cells.

The cytoplasm of IEG duct cells, although refractory to most histological stains, was markedly positive to AB at both pH 1.0 and 2.5 (Figures 3.1.1 and 3.1.2). The contents of the granules showed moderate reactivity to PAS (Figure 3.1.3), Phloxine (Figure 3.3.2), Eosin, PTAH, Fast Red 2B

Table 3.1

HISTOCHEMICAL RESULTS OF
IEG DUCT CELLS AND MAST CELLS

| Histochemical Method | IEG duct cells | | Mast cells |
|-----------------------------------|----------------|--|------------|
| | Result | Comments | |
| H & E | + | weak eosinophilia | + |
| Alcian Blue pH 1.0 | ++++ | strong cytoplasmic basophilia | ++++ |
| Alcian Blue pH 2.5 | +++ | cytoplasmic basophilia | +++ |
| PAS | ++ | moderate reactivity | - |
| Alcian Blue/PAS | +++ | cytoplasmic basophilia | ++ |
| Alcian Yellow | ++ | moderate basophilia | + |
| Neutral Red | +++ | yellow-red granules (metachromatic?) | +++ |
| Bismarck Brown | +++ | basophilic granules | +++ |
| Colloidal Iron | +++ | cytoplasm - blue granules - dark brown | + |
| Phloxine | ++ | acidophilic granules | - |
| Phloxine/AB | +++ | cytoplasm - basophilic granules - acidophilic | +++ |
| Toluidine Blue | ++++ | metachromatic granules (purple) | ++++ |
| Azure A pH 1-3 | - | | - |
| Azure A pH 4 | ++++ | metachromatic granules (purple) | ++++ |
| Fast Red 2B | ++ | orange-brown granules | + |
| Methyl Green-Pyronin | ++ | cytoplasm - pink/purple granules - orange/brown | + |
| PTAH/AB | +++ | cytoplasm - blue granules - dark purple | - |
| Silver Impregnation | ++ | cytoplasm - negative globules - +ve (brown) | ++ |
| Anti-IgA | - | | - |
| Formalin-induced autofluorescence | +++ | yellow-green fluorescence | +++ |

(Figure 3.3.8) and silver impregnation (Figure 3.3.5). In addition they were strongly metachromatic to Toluidine blue (Figure 3.3.1) and Azure A at pH 4. When both Alcian blue (a basic stain) and Phloxine (an acid stain) were used together, some IEG duct cells contained only phloxine positive granules while others had an Alcian blue positive cytoplasm which contained Phloxine positive granules (Figure 3.3.7).

IEG duct cells did not appear to react with fluorescein conjugated anti IgA antibody but instead showed formalin-induced autofluorescence (see Appendix II).

Staining reactions of subepithelial or mucosal mast cells of parotid and ventral buccal glands closely paralleled those of IEG duct cells, although mast cells were PAS negative. Mucosal mast cells of all other glands were histochemically similar to IEG duct cells of the parotid and ventral buccal glands but were also PAS negative.

Granular "intrastriated" duct cells of the sheep parotid gland contained large eosinophilic globules and an AB positive (pH 1.0 and pH 2.5) cytoplasm (Figure 3.1.8). Similar cells examined in the sheep abomasum also had large eosinophilic granules but their cytoplasms were refractory to Alcian blue staining. A comparison between sheep and cattle parotid gland intraepithelial duct cells revealed considerable variation in granule sizes in cattle, while those of sheep were relatively uniform. Eosinophilic granules or globules were also more obvious in sheep than in cattle.

3.3.3 Ultrastructure

Ultrastructurally, IEG duct cells showed considerable morphological variation and were located between adjacent epithelial duct cells; intercellular attachments such as desmosomes were not present (Figure 3.4). There was however some evidence of cytoplasmic finger-like processes extending from surfaces of IEG cells into intercellular

FIGURE 3.1

MORPHOLOGY AND DISTRIBUTION OF INTRAEPITHELIAL GRANULAR (IEG) DUCT CELLS OF THE PAROTID AND VENTRAL BUCCAL GLANDS

- 3.1.1 Characteristic appearance of IEG duct cells located adjacent to the basal lamina of intralobular ducts.
(Alcian Blue pH 2.5/H and E).
Magnification: x 650

- 3.1.2 IEG duct cell with strongly sulphated cytoplasmic contents and small acidophilic granules. Note rare binucleated IEG duct cell and chromatin pattern of nuclei.
(Alcian Blue pH 1.0/H and E).
Magnification: x 1650

- 3.1.3 Moderate PAS reactivity of IEG duct cells.
(PAS/Tartrazine). Magnification: x 650

- 3.1.4 Neutral red positive (Metachromatic?) intracytoplasmic granules of various sizes distributed within IEG duct cells. One cell (bottom right) is without intracytoplasmic granules but shows an intact nucleus.
(Neutral Red). Magnification: x 1650

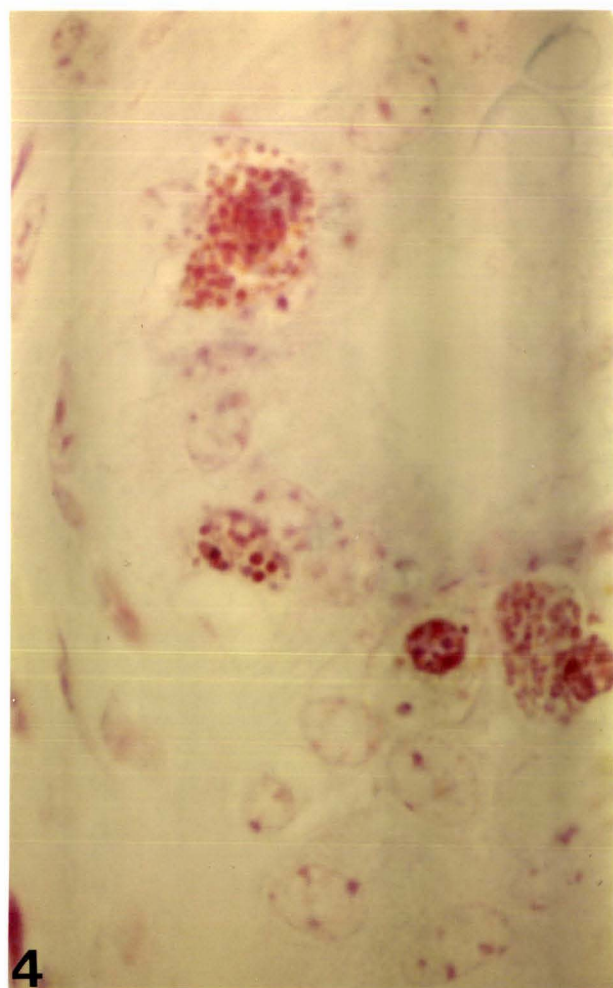
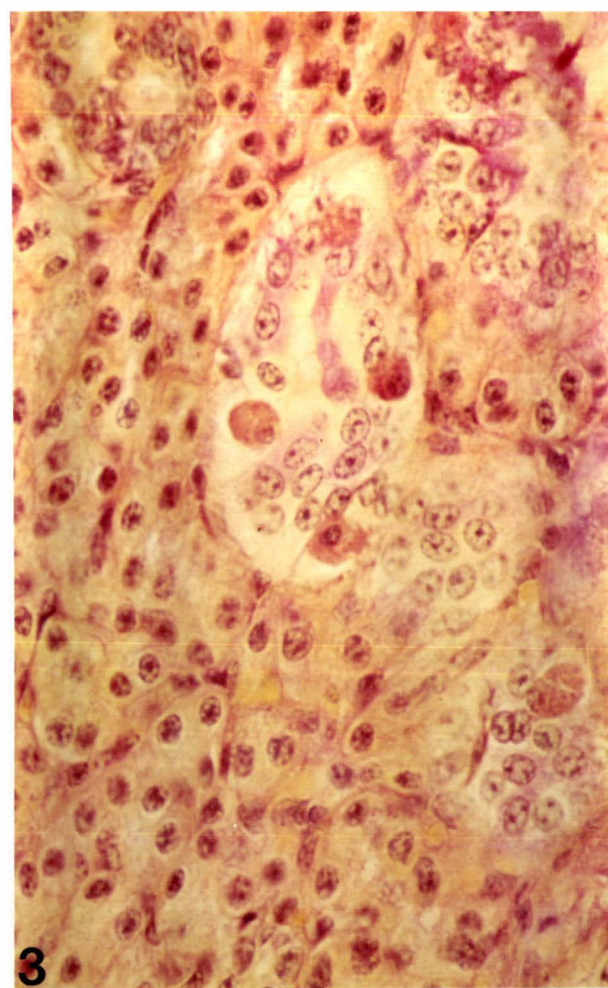
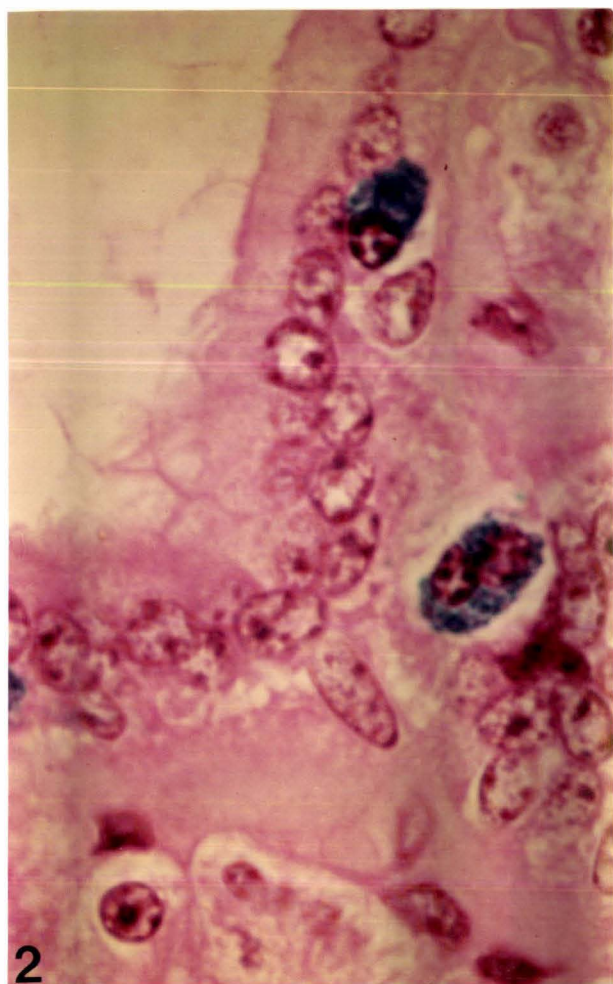
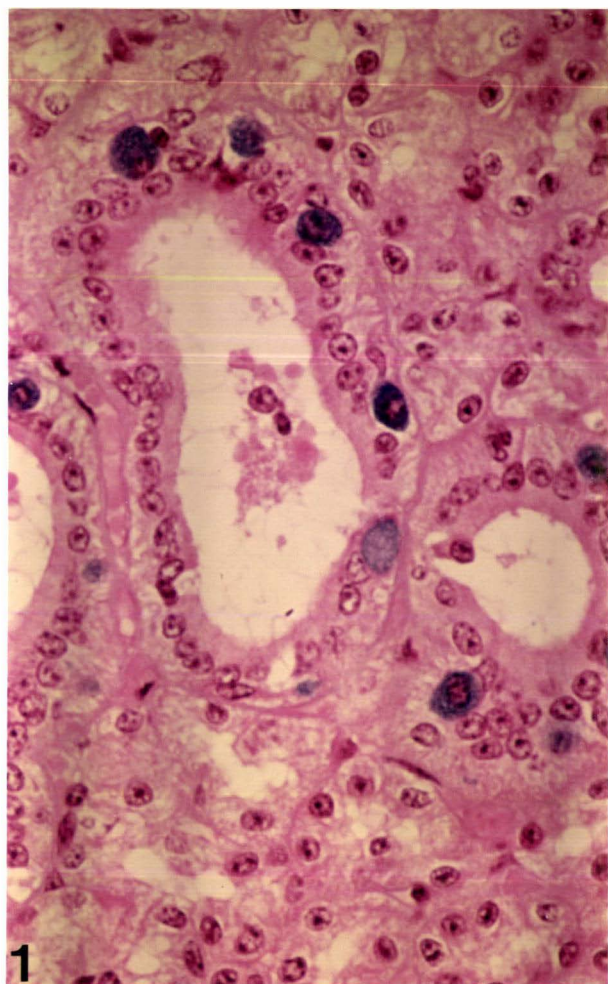


FIGURE 3.1 (Continued)

- 3.1.5 A rare subepithelial IEG duct cell. Note heterogeneous appearance of granules and eccentric nucleus.
(Alcian Blue pH 1.0/Tartrazine).
Magnification: x 1650
- 3.1.6 A group of IEG duct cells lying within the lumen of a duct.
(Alcian Blue pH 1.0/H and E).
Magnification: x 650
- 3.1.7 A semi-thin (2 μ m) section of parotid tissue fixed in Karnovsky's fixative. Note irregular appearance of IEG duct cells and their nuclei.
(Epon embedded/Toluidine Blue).
Magnification: x 650
- 3.1.8 Sheep parotid gland "intrastriated" duct cell with large acidophilic globules and basophilic (pH 1.0) cytoplasm. Similar cells in the sheep abomasum contained large acidophilic globules but did not show cytoplasmic basophilia. Note peripheral distribution of chromatin within the nucleus which is similar to that of a plasma cell.
(Alcian Blue pH 1.0/H and E).
Magnification: x 1650

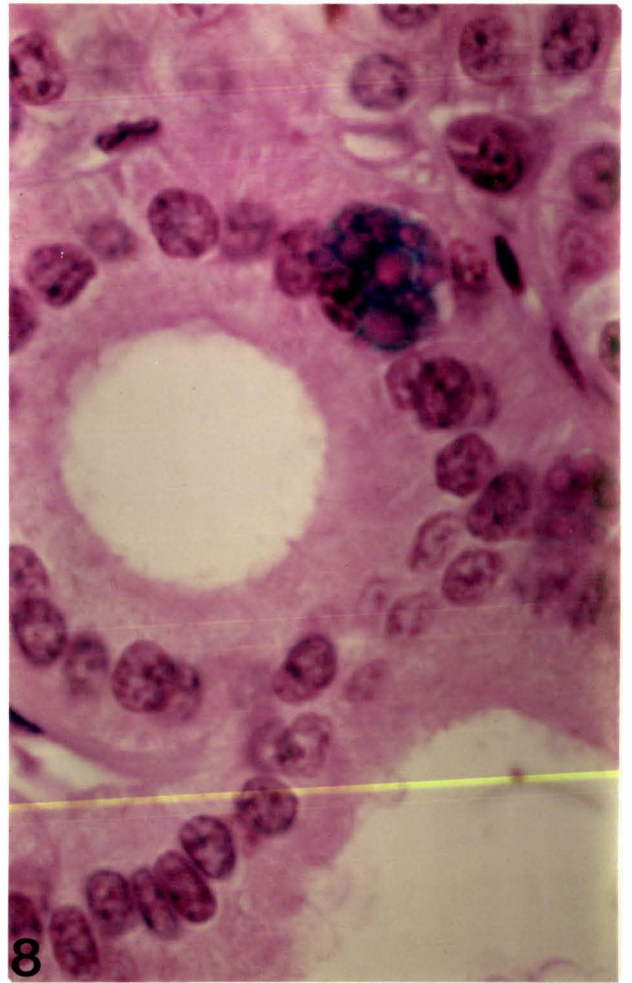
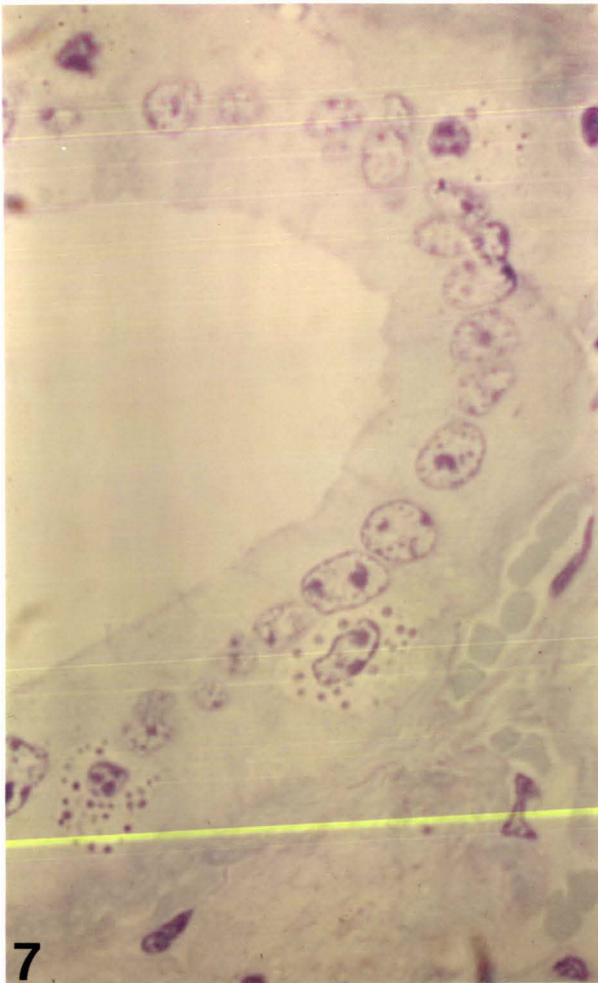
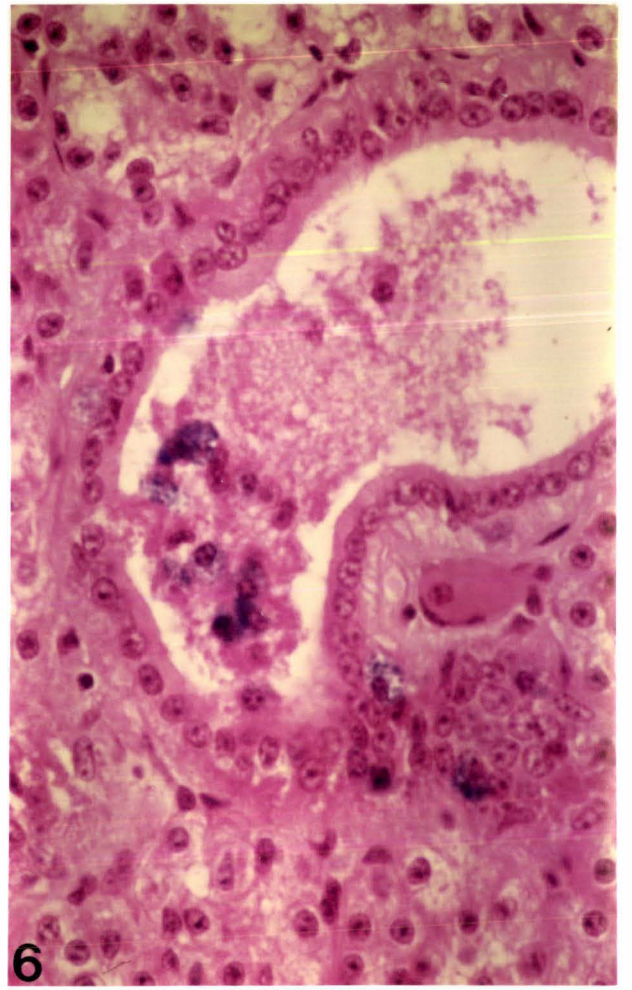
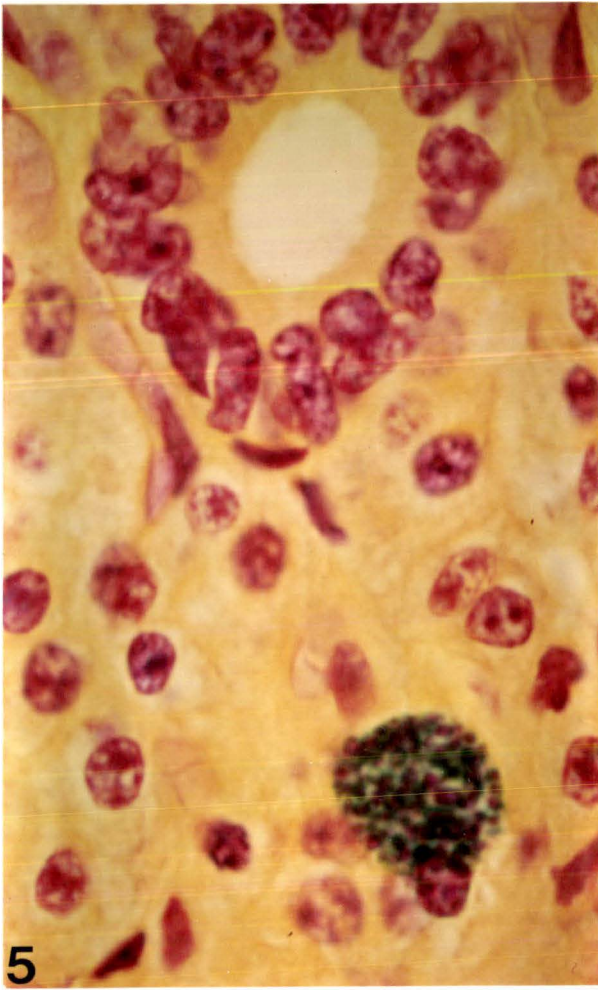

FIGURE 3.2

MORPHOLOGY AND DISTRIBUTION OF MAST CELLS IN BOVINE SALIVARY GLANDS

- 3.2.1 Subepithelial (mucosal) mast cells of the parotid and ventral buccal glands, located adjacent to an intralobular duct. Such cells were polymorphic in appearance and contained small basophilic granules.
(Hales colloidal iron/Neutral Red).
Magnification: x 650
- 3.2.2 Parotid gland mucosal mast cell (a similar cell to those in Fig. 3.2.1).
(Bismarck Brown/Haematoxylin).
Magnification: x 1650
- 3.2.3 Mucosal mast cell of the mandibular gland. Such cells were distributed close to plasma cells and contained a nucleus with peripherally distributed chromatin.
(Toluidine Blue). Magnification: x 1650
- 3.2.4 A few plasma cells and a mast cell, scattered within connective tissues of the pharyngeal glands. Note morphological similarities between the two cell types, in particular, the chromatin distribution pattern of nuclei.
(Alcian Blue pH 1.0/H and E). Magnification: x 1650

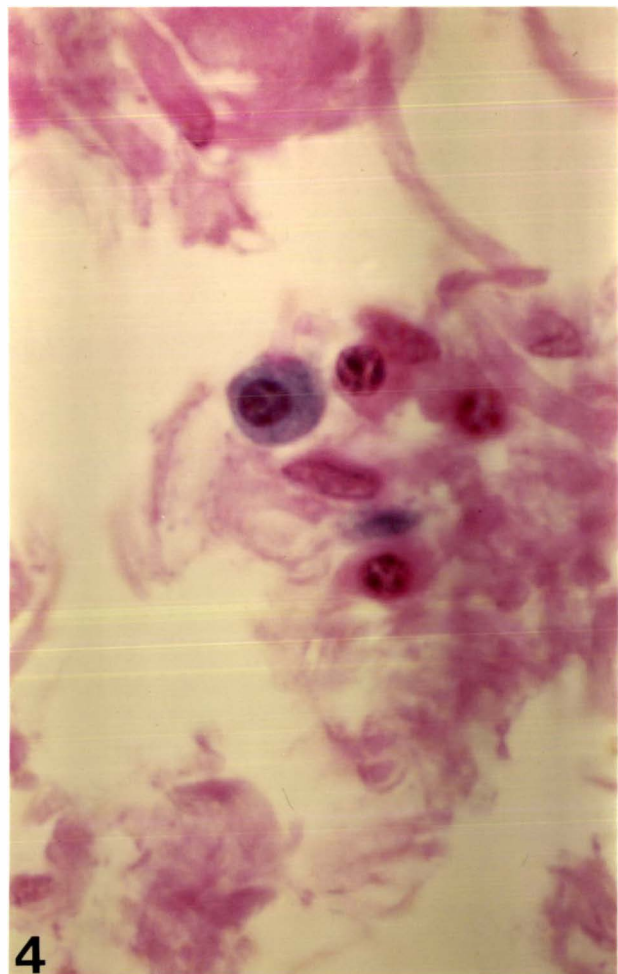
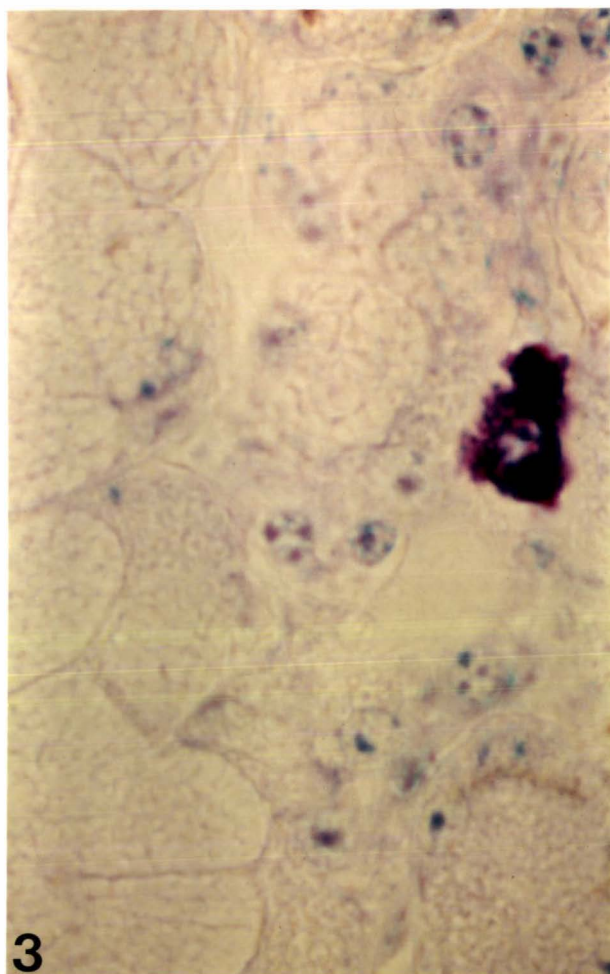
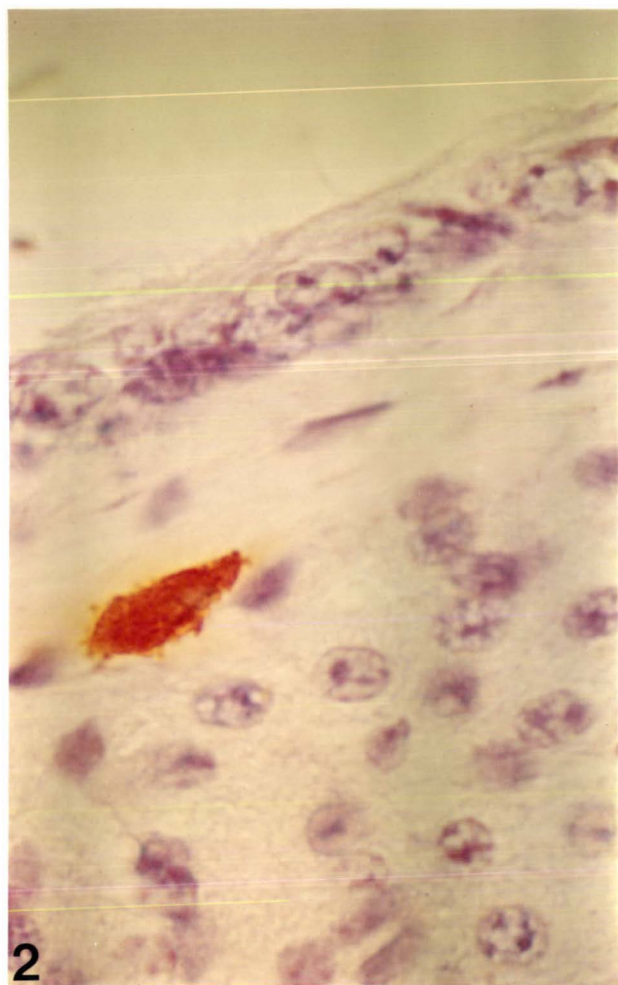
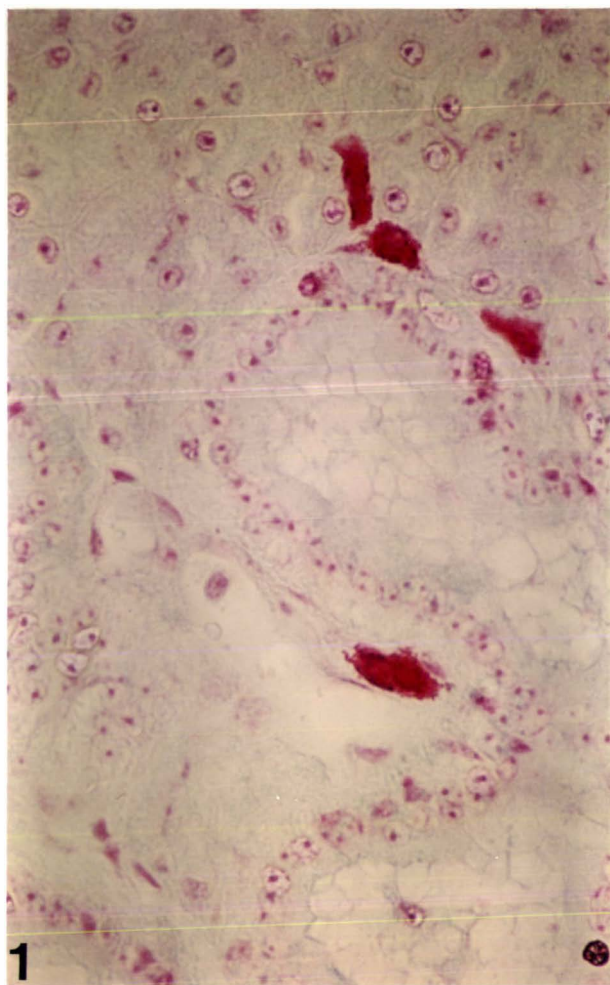


FIGURE 3.3

HISTOLOGICAL AND HISTOCHEMICAL FEATURES OF CYTOPLASMIC GRANULES IN IEG DUCT CELLS

- 3.3.1 IEG duct cells with intracytoplasmic metachromatic granules of various sizes: cell cytoplasm is refractory to staining and the nuclei are not visible. (Toluidine Blue). Magnification: x 1650
- 3.3.2 Acidophilic nature of IEG duct cell granules, demonstrated by staining with Phloxine (an acid dye). Note eccentric nucleus with peripherally distributed chromatin. (Phloxine/Tartrazine). Magnification: x 650
- 3.3.3 The heterogeneous nature of IEG duct cell granules. (Alcian Blue pH 1.0/Tartrazine). Magnification: x 1650
- 3.3.4 A similar cell to those shown in Figs 3.3.1 and 3.3.3, stained with Neutral Red. The yellow colour found in some granules suggests that Neutral Red may have metachromatic properties. Magnification: x 1650

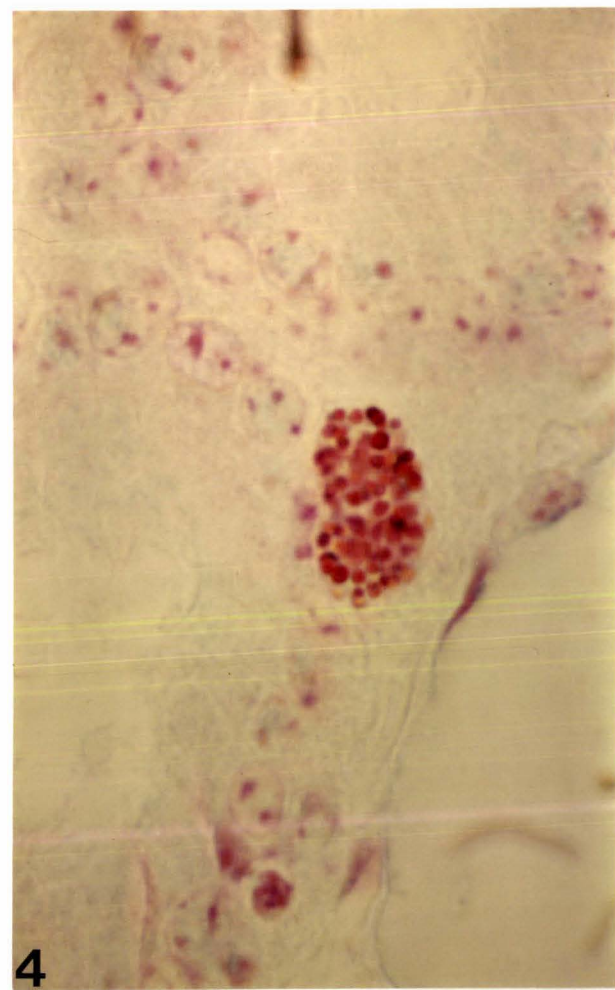
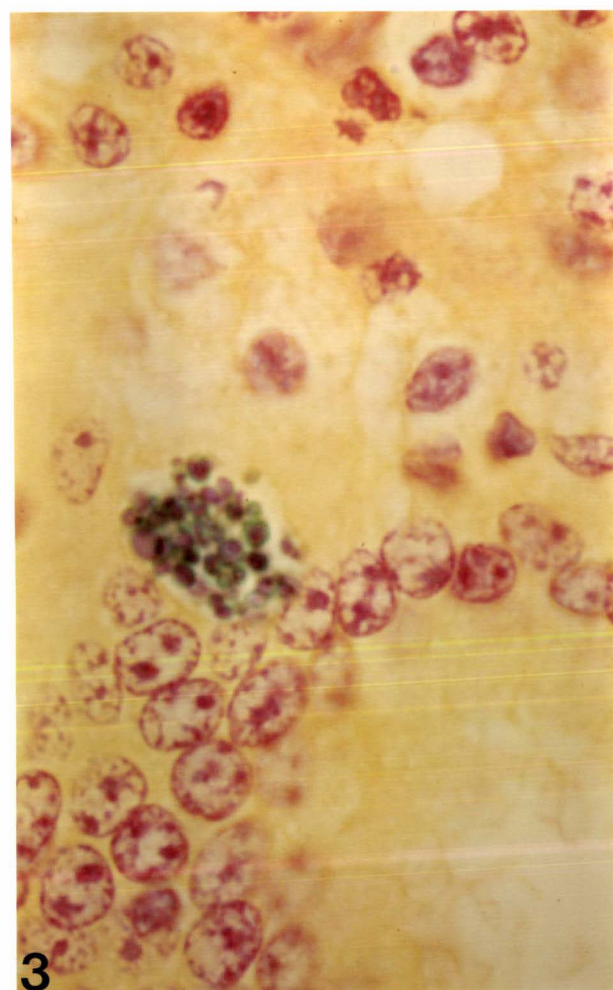
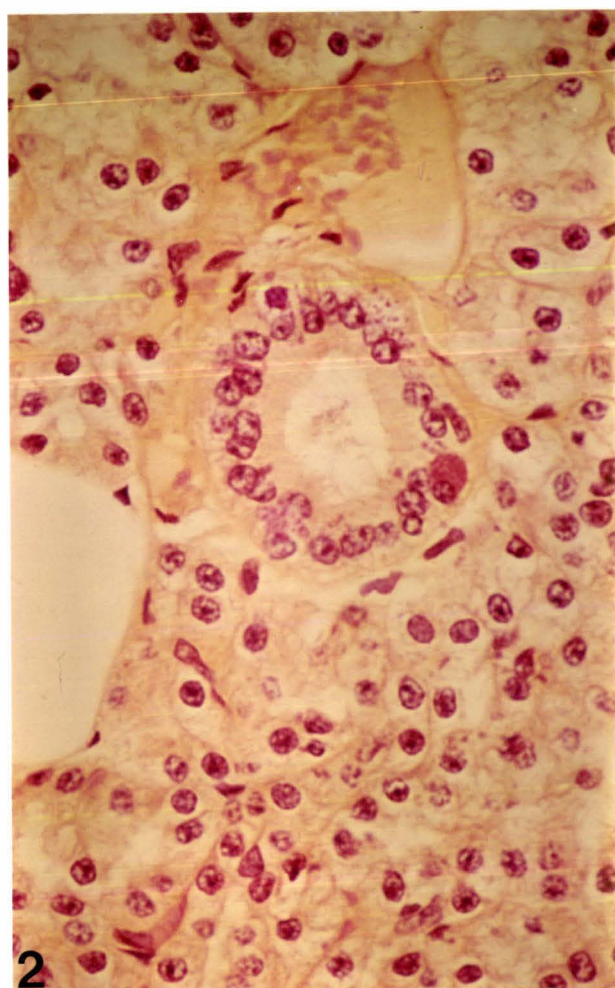
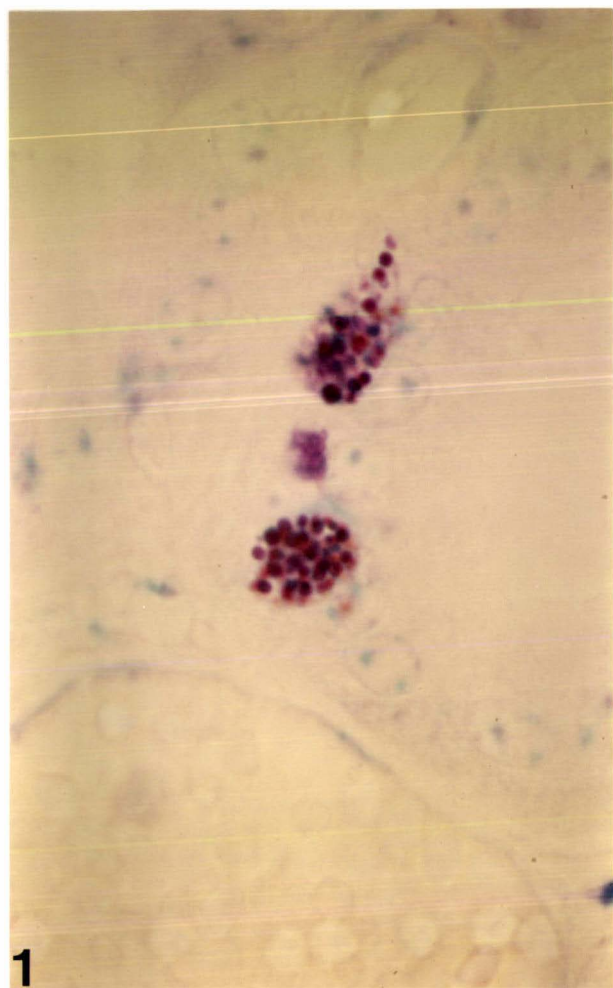


FIGURE 3.3 (Continued)

- 3.3.5 Two IEG duct cells demonstrated by silver impregnation. Argyrophilic staining of granules suggests the likely presence of a biogenic amine. Note partially "degranulated" cell. (Silver impregnation/Light Green).
Magnification: x/650
- 3.3.6 A "degranulated" IEG duct cell. Note appearance of nucleus with "cartwheel" distribution pattern of chromatin. (Silver impregnation/Light Green).
Magnification: x/650
- 3.3.7 Two histochemically different IEG duct cells. The cell on the left contains acidophilic material while the cell on the right contains a mixture of basophilic and acidophilic material. (Alcian Blue pH 1.0/Phloxine/Tartrazine).
Magnification: x 650
- 3.3.8 IEG duct cells with Fast Red 2B positive intracytoplasmic granules, suggesting that a biogenic amine (eg. 5-HT) is probably stored and/or synthesised by the granules. (Fast Red 2B/Haematoxylin).
Magnification: x 1650

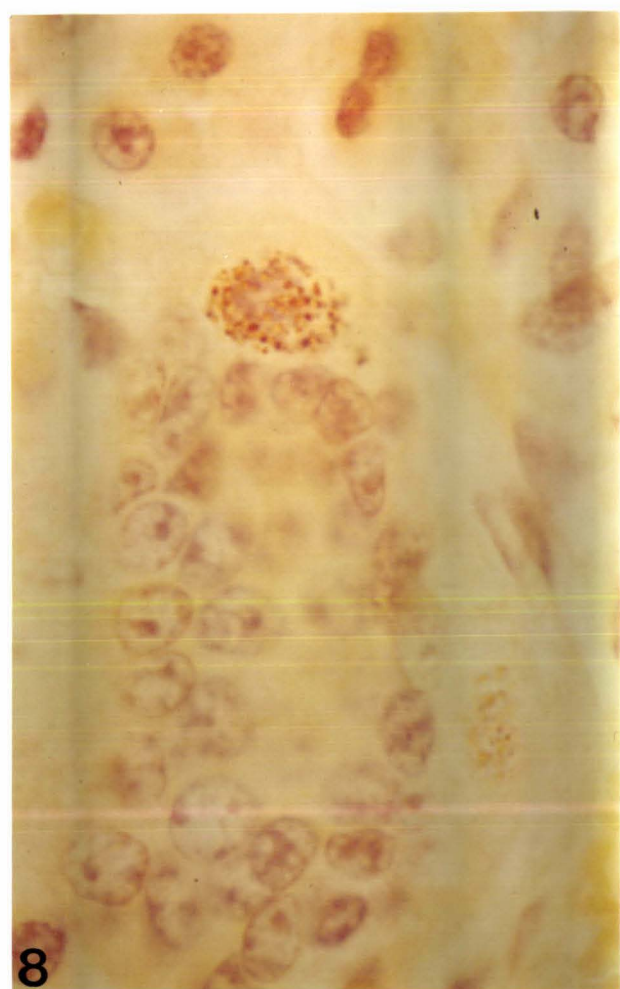
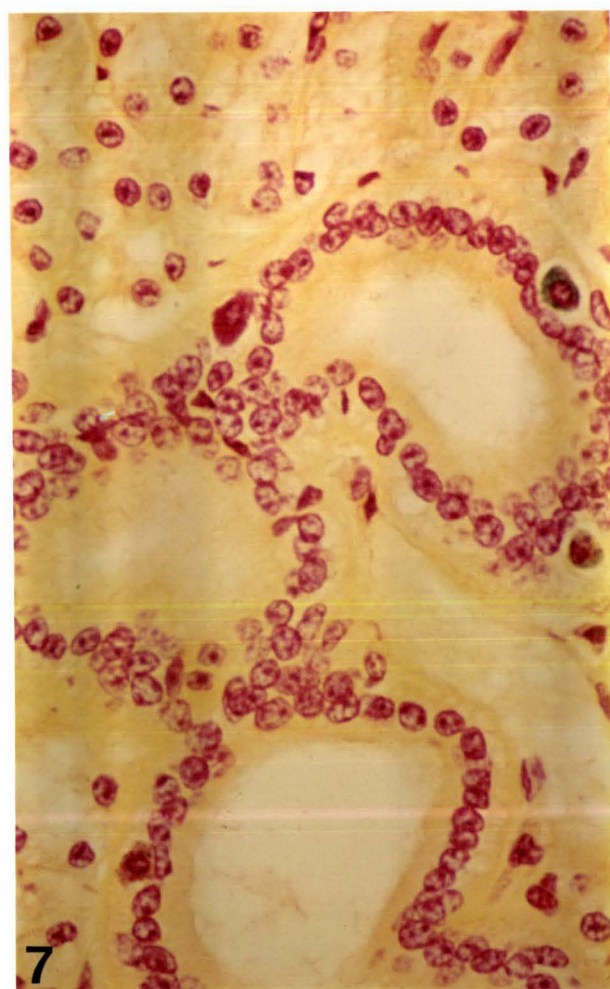
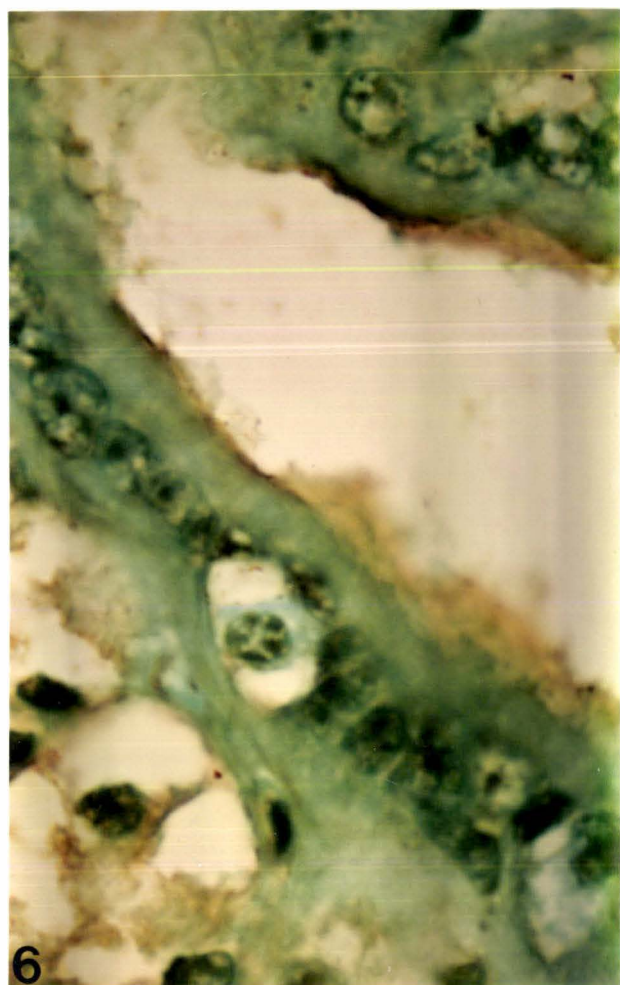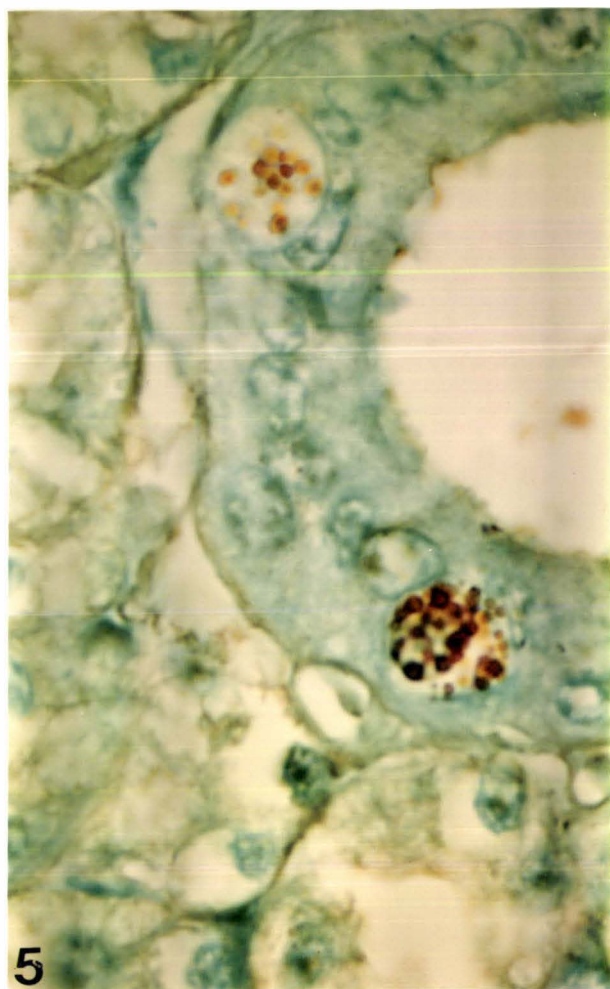


FIGURE 3.4

ULTRASTRUCTURAL FEATURES OF IEG DUCT CELLS

- 3.4.1 Typical electron microscopic appearance of an IEG duct cell located between intralobular duct epithelial cells. Four basic granule types are commonly found (see text). Note vacuolated appearance of cytoplasm and proteinacious crystalline material (arrows) located in some granules. The nucleus is not visible. A desmosome (D) is present between two intralobular duct cells but intercellular attachments are not present between IEG duct cells and epithelial cells.
Magnification: x 10500
- 3.4.2 An IEG duct cell similar to that shown in Fig. 3.4.1. Note variation in granule structure and the presence of crystalline material in some granules. The nucleus is not visible.
Magnification: x 6300

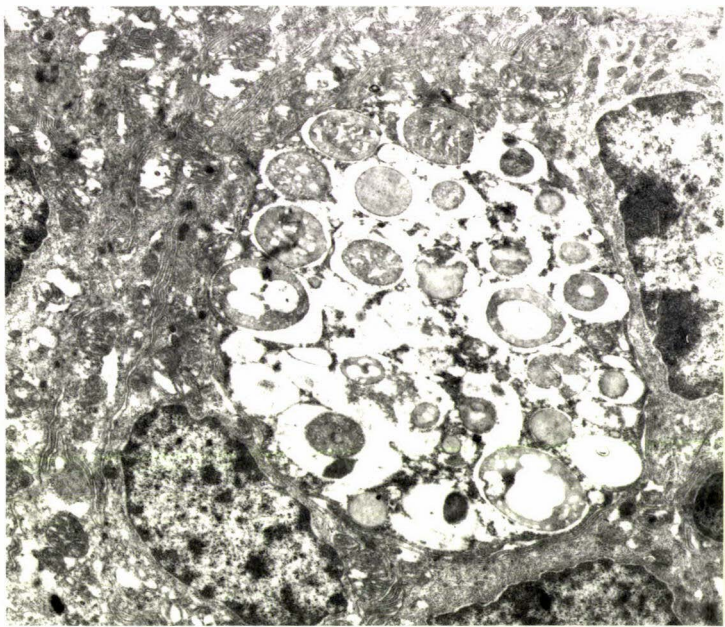
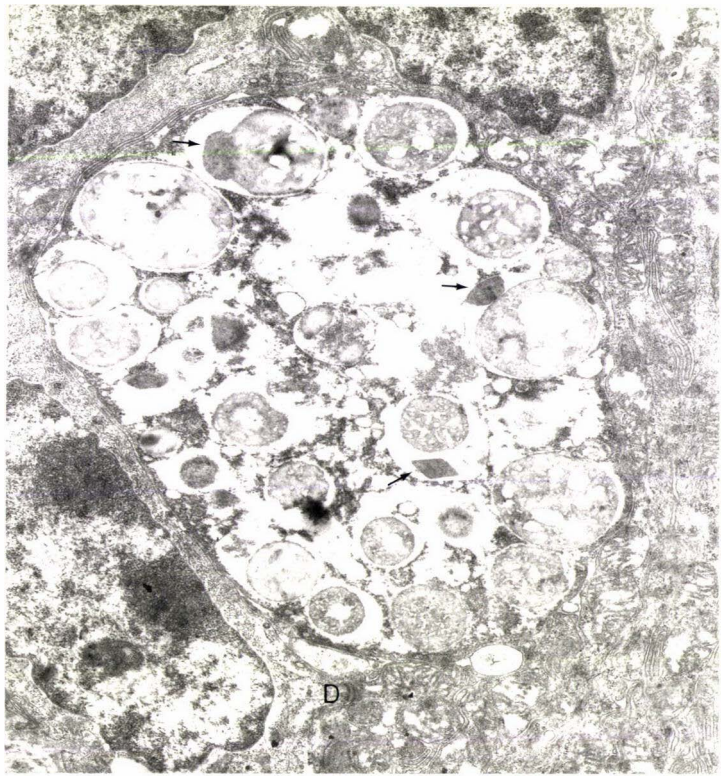
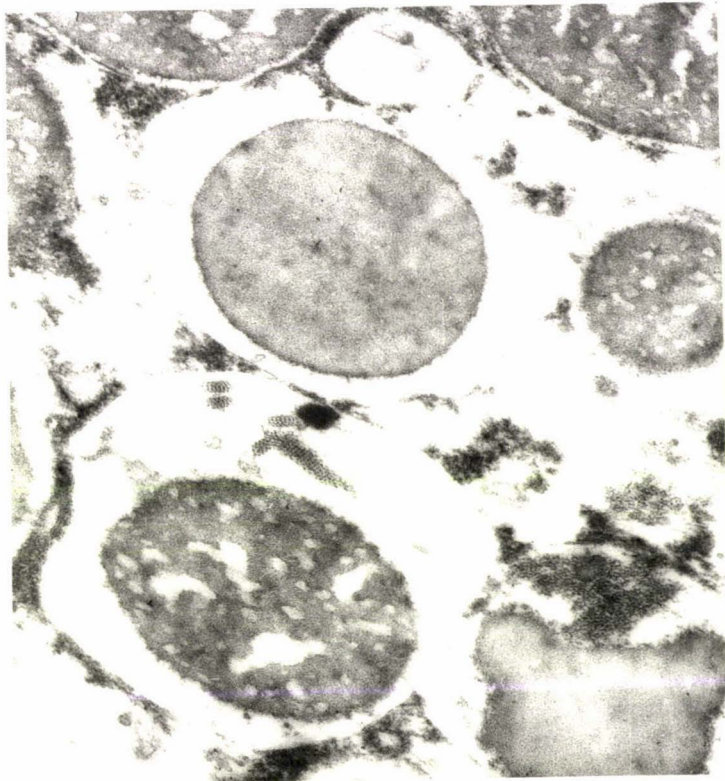
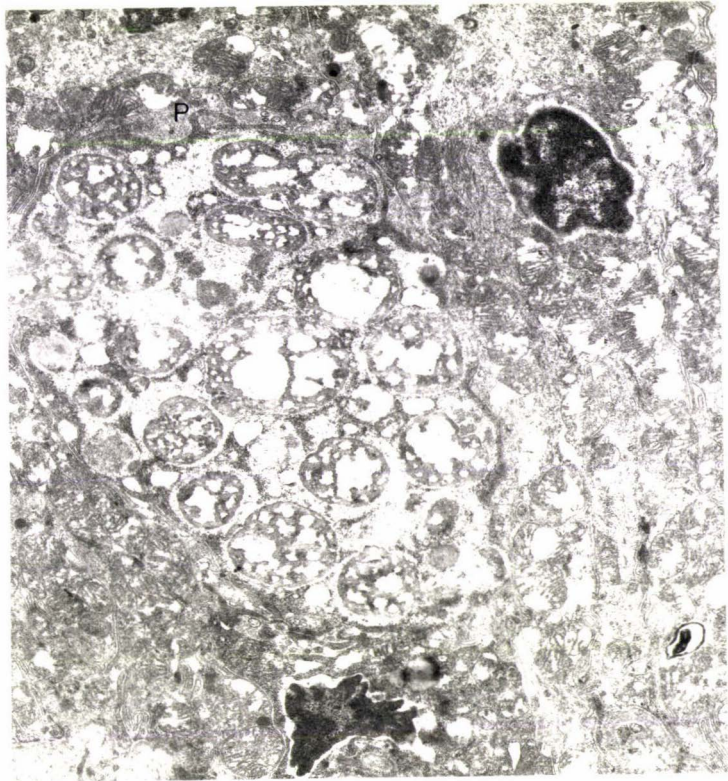


FIGURE 3.4 (Continued)

3.4.3 IEG duct cell with mostly type IV granules and cytoplasmic "finger" like process (P) on cell surface.
Magnification: x 10500

3.4.4 Two granules (types II and IV) are shown at a higher magnification. The type IV granule contains some crystalline material.
Magnification: x 47400



spaces (Figure 3.4.3).

The intracytoplasmic granules were surrounded by smooth-surfaced unit membranes and measured from 0.6 to 5.0 μm in diameter. Despite considerable variation in their morphology, four basic granule types were recognized:-

- Type I: small round homogeneously electron dense granules;
- Type II: large round or oval homogeneously electron dense granules;
- Type III: large round or oval granules with an electron dense outer core surrounding a less electron dense inner core;
- Type IV: large round or oval electron dense granules which had a reticular appearance produced by pockets of unevenly scattered electron lucent material.

Transitional granule types were also present with shrunken matrices and globular crystalline inclusions.

The cytoplasm of an entire IEG duct cell usually had a vacuolated appearance and organelles such as RER and Golgi complex were not visible because of the granular contents. The nucleus, when observed, had chromatin peripherally distributed as pyramidal-shaped projections extending towards the centre of the nucleus.

3.4 Discussion

The parotid and ventral buccal gland IEG duct cells were frequently found in the basal aspect of the intralobular duct epithelium. Their general orientation with respect to the duct epithelium did not suggest that these were migratory cells, although a few were occasionally observed in the duct lumen and at subepithelial sites.

The present investigation has successfully established

the morphology and histochemistry of IEG duct cells located within the intralobular duct epithelium of the parotid and ventral buccal glands.

In general IEG duct cells were similar to subepithelial or mucosal mast cells but had nuclei similar to those of plasma cells. Subepithelial mast cells were polymorphic in appearance with numerous uniformly small basophilic granules. The chromatin distribution pattern of their nuclei varied considerably and at times showed the "cartwheel" distribution pattern of plasma cell nuclei. There was no evidence to suggest that such mast cells migrated into the duct epithelium to become IEG duct cells. Migratory epithelial mast cells have however recently been described in gallbladder epithelium of sheep and cattle (Morales, Pereyra, Toledo and Montes, 1980) which were histologically and ultra-structurally similar to subepithelial mast cells (C.R. Morales, personal communication). A comparison between subepithelial mast cells and IEG duct cells of the parotid and ventral buccal glands revealed that although both were polymorphic in appearance, IEG duct cells showed a variety of granule sizes and their nuclei in particular, often closely resembled those of plasma cells, a feature only occasionally observed in subepithelial mast cells.

On the other hand a specific association, if any, between IEG duct cells and plasma cells is obscure. For example, there is no evidence yet to suggest that plasma cells have been observed at intraepithelial sites. In particular plasma cells specialised for synthesis and secretion of immunoglobulins at mucosal surfaces have been mostly observed at subepithelial sites (Tomasi et al., 1980). In bovine salivary glands numerous plasma cells were present subepithelially in the sublingual and mandibular glands but seldom in parotid or ventral buccal glands (Section 2.4). It is therefore unlikely that IEG duct cells are typical plasma cells. Furthermore, the majority of histochemical findings with the exception of the PAS reaction, were not characteristic of plasma cells. Morphologically, however, IEG duct

cells may at times appear similar to plasma cells with Russell bodies. Such cells are common in pathological conditions (Azar, 1979) and have probably reached the final stages of their secretory cycle (Walter and Israel, 1979). Although experimental evidence is lacking, Russell bodies are likely to contain immunoglobulins complexed with basic proteins. This could account for the intense PAS and acidophilic staining usually reported in Russell body cells (White, 1954). On the other hand, granules of IEG duct cells were frequently basophilic with only moderate PAS reactivity and acidophilia.

Ultrastructural evidence (Figure 3.4) showed that granules of IEG duct cells were not typical of either mast cells (Azar, 1979) or Russell bodies of plasma cells (Azar, 1979). Mast cell granules are uniformly small round and electron dense while Russell bodies of plasma cells are uniformly large with matrices of moderate electron density invested by a double membrane of RER. IEG duct cells were not uniform in appearance with heterogenous matrices surrounded by unit membranes, and their nuclei when observed were intact and suggestive of functional or living cells.

Histochemical studies demonstrated the strong cytoplasmic basophilia of IEG duct cells while a mixture of both acidophilic and basophilic material was identified in the granules (Figure 3.3.7). The cytoplasmic contents are probably composed of sulphated and carboxylated products which were demonstrated by staining with Alcian blue at pH 1.0 and 2.5 respectively. Histochemical methods such as Fast Red 2B (Figure 3.3.8), silver impregnation (Figure 3.3.5) and formalin-induced autofluorescence indicated that the granules are likely to contain a biogenic amine. Presence of neutral and acidic side groups in granules were indicated by the PAS reaction and Toluidine blue metachromasia, respectively. Crystalline inclusions identified within some granules (Figures 3.4.1 and 3.4.2) could probably be attributed to the presence of a globular protein (A.S. Craig, personal communication). There was, however, insufficient evidence

to conclude that the granules may be elaborating a secretory product. The possibility also exists that the granules may be involved in either transport or storage of secretory material, or both.

The rare observation of IEG duct cells in dorsal and intermediate buccal and palatine glands is difficult to explain, except to speculate that their appearance may in some way be associated with the presence of proteoserous islets in all three glands (Section 3.3) identical to those of the parotid and ventral buccal.

The preferential localisation of IEG duct cells in intra-lobular ducts of the parotid and ventral buccal glands strongly suggests that in cattle, the IEG duct cells are primarily associated only with a function specific to these two glands. This hypothesis can be further extended to state that IEG duct cells are probably an independent cell line, poorly understood functionally and specific only to certain tissue sites and organs. For example, the parotid and ventral buccal glands of low bloat susceptible cattle contain a higher proportion of IEG duct cells than high bloat susceptible cattle (Birtles, 1981). It is tempting to suggest that IEG duct cells in conjunction with a function specific to the parotid gland, afford considerable protection to cattle against bloat. This protective role may involve the mucosal immune system or an unknown secretory product elaborated by the IEG duct cells.

Although the exact function of IEG duct cells remains unknown, a likely origin or identity could be elucidated from an assessment of two possible theories based on all the available evidence pertaining to their morphology and histochemistry.

- (1) Parotid and ventral buccal gland IEG duct cells are identical to subepithelial or mucosal mast cells present in all major and minor salivary glands but located intraepithelially only in

parotid and ventral buccal gland intralobular ducts. The characteristic morphological appearance of their granules could thus be attributed to anatomical reasons since they are located intraepithelially rather than in connective tissue.

- (2) The IEG duct cells are an independent cell line closely related to both mucosal mast cells and plasma cells; all three cell types probably share a common stem cell but IEG duct cells or their precursors are specific to intraepithelial sites and in cattle, functionally associated only with the parotid and ventral buccal glands.

Drawbacks of the first theory are that, although mucosal mast cells shared numerous features in common with IEG duct cells, such as a nucleus similar to that of a plasma cell and intense basophilic staining, ultrastructurally the two cell types did not appear to be identical. Furthermore, as previously reported by Morales et al. (1980), intraepithelial mast cells of ruminants did not differ from subepithelial mast cells and degranulating mucosal mast cells observed subepithelially in the present study consistently contained uniformly small round granules, dissimilar to those found in IEG duct cells which showed a variety of granule sizes. In addition it has been reported by Collan (1972) that immigrant cells commonly observed intraepithelially such as lymphocytes and eosinophils, do not differ in morphology to similar cells located subepithelially. Another possibility, that IEG duct cells may be derived from mucosal mast cells which have previously migrated into the duct epithelium, is unlikely since mucosal mast cells of all glands appeared to be non-migratory whereas IEG duct cells seemed to differentiate only within the epithelium of parotid and ventral buccal gland intralobular ducts, adjacent to the basal lamina.

The second theory appears more plausible because of the characteristic features unique to the IEG duct cell such

as variation in granule size and structure, and the presence of a combination of features common to both mucosal mast cells and plasma cells, for example small electron dense granules, basophilia at low pH, metachromasia, presence of a biogenic amine, PAS reactivity and nuclear chromatin pattern.

It is well established that plasma cells are derived from lymphocytes (Ham and Cormack, 1979). Experimental evidence to date, in support of a lymphocyte origin for mucosal mast cells in rat and man, have been reviewed by Miller (1980) and Bienenstock, Befus, Pearce, Denburg and Goodacre (unpublished). It is probable that a lymphocyte subpopulation specific to intraepithelial sites could be implicated in the derivation of IEG duct cells of parotid and ventral buccal glands of cattle. This lymphocyte subpopulation may or may not be closely related to the precursor cells of the mucosal mast cell. It is also tempting to speculate on the significance of mucosal mast cells observed in the present study that seemed to differentiate in the vicinity of plasma cells (Figures 3.2.3 and 3.2.4); this could suggest a lymphocyte origin for the mucosal mast cells of cattle as well.

A preliminary histological and histochemical examination of sheep parotid gland striated ducts established an apparent species difference between intraepithelial duct cells of sheep and cattle. In sheep, typical mast cells with uniformly small cytoplasmic granules and densely-staining nuclei were occasionally observed intraepithelially. In addition a granular cell type was also noticed, essentially similar to IEG duct cell of cattle, with a nucleus similar to that of a plasma cell; however the granules were uniformly large, round and considerably more eosinophilic and were surrounded by Alcian blue positive basophilic material (pH 1.0 and 2.5), (Figure 3.1.8). Van Lennep et al. (1977) who examined this cell ultrastructurally during an investigation of the sheep parotid gland, reported the granule matrices to be homogeneous. This finding contradicts

observations made in the present study where the granules of IEG duct cells in cattle appeared heterogenous. The granular cells observed in the epithelium of the sheep abomasum were morphologically similar to those of the sheep parotid gland striated ducts but histochemically there was little evidence of cytoplasmic basophilia, although the granules were distinctly acidophilic. Such cells in the sheep abomasum have been variously described as either globule leucocytes (Kent, 1952; Murray, Miller and Jarrett, 1968) or plasma cells with Russell bodies (Dobson, 1966).

These preliminary findings seemed to indicate that variation of the epithelial granular cell type may be present, depending on species and anatomical location.

CHAPTER 4. GENERAL DISCUSSION

Over two decades ago, Kay (1960) investigated ruminant salivary secretions in considerable detail and reported briefly on the histology of the major and minor salivary glands of sheep and cattle. The parotid glands of both species were composed of PAS negative cuboidal-shaped secretory cells mainly specialised for secretion of water and electrolytes, but subsequent histological and histochemical investigations by Pal et al. (1972), Birtles (1981) and Vignoli and Nogueira (1981) have established that in bovine parotid glands in particular, the secretory cells occasionally consisted of diastase resistant PAS positive material. In the present study these findings were confirmed (Figure 2.1) and in addition some secretory cells were found to consist of weak Alcian blue (AB) (pH 2.5) and colloidal iron positive material, a feature also demonstrated by Pal et al. (1972) and Vignoli and Nogueira (1981). Immunohistochemical investigations with antibodies to bovine salivary protein bands 4 and 10 isolated by Jones et al. (1982), confirmed that most bovine parotid gland secretory cells additionally contained proteinacious material which was not detected by histological stains (Figure 2.3). This further strengthens the validity of naming serous cells as proteoserous cells (Birtles, 1981).

From an assessment of existing histochemical and biochemical data, it may be concluded that secretions of the bovine parotid glands are predominantly composed of water, electrolytes and proteins with small amounts of neutral and acidic glycoproteins. The PAS positive material can be attributed to protein band 5, a glycoprotein which contains numerous sialic acid subunits (W.T. Jones, personal communication). The Alcian blue and colloidal iron positive material rarely found in some tissue sections examined, may be due to small quantities of histochemically detectable sialic acid residues. According to Vignoli and Noguiera (1981), the occurrence of PAS and AB positive material in bovine parotid

glands, can be associated with the age of the animal; calves aged between 5 and 13 months had considerably higher levels of glycoproteins than more mature animals. This phenomenon was not explored in the present study. Salivary protein band 4 secreted by the parotid glands has been correlated with bloat susceptibility in cattle (McIntosh and Cockram, 1977) and was, in the present investigation, equally distributed in parotid tissue samples of both L.S. and H.S. animals. This unusual finding is likely to involve poorly understood cellular regulatory mechanisms associated with protein secretion. Recently, Patterson et al. (1982) have reported that protein secretion from the sheep parotid glands involved a β -adrenergic (sympathetic) component prominent upon commencement of feeding. If a similar secretory component exists in cattle, a valuable contribution to present understanding could be made by examining the effects of β -sympathetic stimulation on protein secretion from L.S. and H.S. animals, especially in relation to secretion of protein band 4. Although the sympathetic effects on ruminant parotid salivary secretion has been carefully explored, it is likely that owing to synergistic influences, (Babkin, 1950) both sympathetic and parasympathetic innervation may be implicated in protein secretion from parotid glands. Patterson et al. (1982) additionally correlated protein secretion with magnesium ion concentration of parotid saliva. A possible explanation for this association could be the influence of either an intracellular or a cellular membrane protein transport mechanism which utilises magnesium ions.

A histological survey of the parotid gland ductal system showed that basal striations which house mitochondria (Pinkstaff, 1980) were not a feature of the bovine parotid gland intralobular ducts (Figure 2.2.3). A similar conclusion was reached by Shackleford and Wilborn (1969), Pal et al. (1972), Pinkstaff (1980) and Vignoli and Nogueira (1981). In the present study, however, numerous basal striations were identified in sheep parotid gland striated ducts (Figure 2.2.4), a finding ultrastructurally confirmed by

van Lennep et al. (1977). Kay (1960) was not aware of the significance of basal striations in parotid gland ducts of either sheep or cattle and concluded that the ruminant parotid glands produced an isotonic secretion and were unlike the glands of most mammalian species which produced a hypotonic secretion. However, Compton et al. (1980) reported from micropuncture investigations that the sheep parotid gland ductal system was capable of water and electrolyte transport and secretion of hypotonic saliva. The lack of basal striations in intralobular ducts of bovine species suggests that these ducts, unlike those of the sheep parotid glands, are not actively engaged in water and electrolyte transport and thus secrete an isotonic saliva. The functional significance of an isotonic secretion can be attributed to a considerable saving of osmotic energy made from reduced ductal transport of ions, thereby enabling the animal to achieve a higher rate of secretion. According to Shackelford, (1969) ionic transportation in the bovine parotid glands is primarily conducted by lateral surface modifications of the proteoserous secretory cells while intralobular ducts may have a secondary role.

Another significant feature of bovine parotid gland intralobular ducts was the presence of PAS positive material and apical blebs in some duct cells (Figure 2.2.1). Although some of the PAS positive material was diastase labile, there was a significant amount of diastase resistant material which could be attributed to neutral glycoproteins. A similar conclusion was reached by Shackelford (1963), Pal et al. (1972), Birtles (1981) and Vignoli and Nogueira (1981). The PAS positive material may be released to the duct lumen via an apocrine secretory mechanism which could account for the presence of apical blebs.

The excretory duct of the bovine parotid gland was characterised by numerous goblet cells (Figures 2.1.3 and 2.1.4) which contained acidic and neutral mucosubstances; these findings paralleled observations by Shackelford and Klapper (1962), Pal et al. (1972), Birtles (1981) and

Vignoli and Nogueira (1981). The acidic mucosubstances of the goblet cells were found to contain both carboxylic and sulphate groups. The total secretion elaborated by the bovine parotid glands could therefore consist of water, electrolytes, proteins, neutral mucosubstances and acidic mucosubstances composed of sialic acids and sulphated glycoproteins, the latter secreted by goblet cells.

It is doubtful whether the parotid glands of cattle contribute significantly to the maintenance of the mucosal immune system since plasma cells were infrequently observed in parotid tissues. One explanation could be the high continuous salivary flow rate providing enhanced protection against antigenic stimulation (Watson and Lascelles, 1973). Another possibility is that IEG duct cells rather than plasma cells may primarily mediate mucosal immunity, although the exact mechanisms involved are at present unclear. This hypothesis is supported by the observation that of all three major salivary glands examined, IEG duct cells were located only in the ductal epithelium of the parotid glands. Both the mandibular and sublingual glands contained substantial numbers of plasma cells, but not IEG duct cells.

Bovine mandibular glands, unlike the parotid glands, were predominantly specialised for the secretion of mucosubstances. Long tubular endpieces of the mandibular glands were composed of mucous cells and demilune cells, their histological and ultrastructural features have been described by Shackleford and Klapper (1962), Shackleford and Wilborn (1970), Bloom and Carlsoo (1974) and Birtles (1981).

Mucous cells of the bovine mandibular gland were found to contain neutral and carboxylated acid mucosubstances, a conclusion also reached by Shackleford and Klapper (1962) and Birtles (1981). The composition of mucosubstances was primarily demonstrated with PAS, AB and Toluidine blue staining techniques, although Quintarelli (1963a), from histochemical investigations of mammalian salivary glands, found the bovine mandibular gland mucosubstances to be Toluidine

blue negative and non-metachromatic, a result disputed in the present study (Figure 2.4.3). Although the theory of metachromatic reactions is still in some doubt (Culling, 1974), it is likely that all acidic groups induce either purple or purple-red metachromasia depending on their molecular weight and polymeric nature. For example strongly acidic groups found in connective tissue mucopolysaccharides reveal a deep purple to red metachromatic colour not evident in epithelial mucous secretions. In the present study, bovine salivary gland mucosubstances exhibited purple metachromasia, demonstrating the presence of moderately strong acid radicles such as those of carboxyl groups. The purple metachromatic colour of the mandibular gland mucous cells is mainly due to the carboxyl groups of sialic acid residues, a result confirmed by neuraminidase digestion followed by AB staining (Figures 2.4.9 and 2.4.10), and also from histochemical (Quintarelli et al., 1960) and biochemical (Jones et al., 1977) studies. The major sialic acid residues in bovine mandibular gland secretions have been identified as N-acetylneuraminic acid (37%), N-acetyl-9-O-acetylneuraminic acid (33%) and N-glycolylneuraminic acid (17%), (Herp et al., 1979).

Whilst the sialic acid derivatives of the bovine salivary gland secretions have been well characterised, the presence of sulphate groups in the mandibular gland or in bovine salivary mucosubstances, in general, have received little attention. In the present investigation a few mucous cells of the mandibular glands contained very weak AB stain-int at pH 1.0. This could be attributed to the presence of small amounts of sulphated glycoproteins or sialo-sulphated glycoproteins (Reid and Clamp, 1978), rather than to derivatives of chondroitin sulphates, since AB staining at low pH was retained after hyaluronidase digestion. AB staining at pH 1.0 ascribed to "sulphomucins" has been demonstrated by Pal and Chandra (1979) in the mandibular gland of the water buffalo, a closely related bovidae species. Their histochemical findings appeared similar to those observed in cattle in the present study, except that the authors have

broadly attributed AB staining at pH 2.5 to "sialomucins and hyaluronic acid", neither of which were confirmed by enzymic digestion.

In contrast to mucous cells, the histochemistry of the bovine mandibular gland demilunes has received little attention. The demilunes were large conspicuous cells weakly PAS and AB (pH 2.5) positive demonstrating the presence of neutral and carboxylated acidic mucosubstances. Similar results were also reported by Shackelford and Klapper (1962) and Birtles (1981). The prominent acidophil granules of the demilunes (Figure 2.4.6) could contain some endogenous peroxidase (Bloom and Carlsoo, 1974) and bovine salivary protein band 8 which was located immunohistochemically in the demilunes (Figure 2.4.8).

An unusual property of the demilune acidophil granules, not previously investigated, could be in their ability to "mask" residues of any sialic acid present in the demilunes, so that such residues would remain inaccessible to histological stains. Quintarelli (1963b) investigated this masking effect of sialic acid residues by basic proteins and recommended the use of a proteolytic enzyme to unmask the residues. According to Quintarelli, sialic acid may be present in two different forms, a bound form detected after proteolytic action, and an unbound form easily detected and susceptible to mild acid hydrolysis. In the present investigation a proteolytic enzyme was not used but the BIAL reaction (Culling, 1974) specific for sialic acid, yielded a positive result only in the demilune cells. It is possible that the mild hydrolytic action of heating HCl acid to 70°C during the BIAL test would have removed sialic acid residues from the mucous cells while unmasking those of the demilunes. The red-brown reaction product, specific for sialic acid, was therefore located only in the demilunes (Figure 2.4.7). This "unmasking" action of the BIAL reaction is however not clear, although it is possible that the BIAL test would have produced different results if, as recommended by Culling (1974), formalin vapour-fixed sections were used for

the test instead of formalin-fixed paraffin sections, used in the present investigation. The latter fixative was also found to enhance AB staining of mandibular gland demilunes, (see Birtles, 1981). The reasons for this fixative-dependent staining effect of mandibular gland demilunes were not investigated, although it is likely that formalin may substantially reduce the masking effect of basic proteins.

The contents of some demilunes were also weakly reactive to AB at pH 1.0, indicative of negligible amounts of sulphated or sialo-sulphated glycoproteins. A similar result was reported by Pal and Chandra (1979) in the mandibular glands of the water buffalo, but it is unclear whether the reference was specifically to a demilune cell or an alternative cell type the authors have described as a "seromucous endpiece cell" which was also referred to as a "serous demilune".

The intralobular ducts of the mandibular glands were composed of tall columnar cells with distinct basal striations (Figures 2.4.3 and 2.4.6). These striated (intralobular) ducts would be capable of producing a hypotonic saliva (Kay, 1960) by conducting ductal water and electrolyte transport of ions (Young and van Lennep, 1979). On the other hand the parotid gland intralobular ducts lack basal striations (Figure 2.2) and produce an isotonic saliva (Kay, 1960). However, two features identified in some parotid gland intralobular duct cells, the presence of PAS positive material and apical blebs, (Figure 2.2.1) were also noticed in the mandibular gland striated ducts. The main excretory duct of the mandibular gland, unlike that of the parotid, did not contain goblet cells (Figure 2.4.12), a finding also reported by Birtles (1981). However, goblet cells have been identified in the main excretory duct of the sheep mandibular gland (AriyakulkaIn, 1981).

The morphology of the bovine sublingual gland secretory endpieces differed from those of the mandibular gland. The endpieces, although tubular, contained flattened, inconspic-

uous demilune cells which contrasted sharply in morphology with those of the mandibular glands. The secretory products of the mucous cells were mostly neutral and acidic mucosubstances; these findings paralleled observations by Shackelford and Klapper (1962) and Birtles (1981). The acidic mucosubstances were AB (pH 2.5), colloidal iron and Toluidine blue positive, but neuraminidase digestion failed to eliminate AB staining at pH 2.5; this demonstrates that most sialic acid residues of sublingual gland mucous cells were not neuraminidase labile and could be structurally different from those of the mandibular glands. Biochemical studies have additionally established a difference in composition between the mucous fractions of the two glands (Table 1.2).

Histochemical demonstration of sulphate groups in bovine sublingual glands established that mucous cells were reactive to AB at pH 1.0 (Figure 2.5.2) indicating the presence of a sulphated or sialo-sulphated glycoprotein. In contrast to the mandibular gland, proportionately more sublingual gland mucous cells were AB positive at low pH.

Most demilunes of the sublingual glands reacted immunohistochemically with anti bovine salivary protein band 9 antibody (Figure 2.5.6) and a few stained weakly with PAS. The secretory products of the demilunes unlike those of the mandibular gland demilunes were mainly proteoserous with little evidence of either acidic or neutral mucosubstances.

Striated ducts of the bovine sublingual glands were identical to those of the mandibular glands, with tall columnar cells and distinct basal striations (Figure 2.5.5). In contrast to most species, including sheep, the parotid glands consist of well developed striated ducts while those of the mandibular and sublingual glands are poorly developed (Leeson, 1967). The present investigation has histologically established that in cattle, striated ducts are distributed only in the mandibular and sublingual glands, findings which have not been previously reported. Physiologically,

well developed striated ducts are usually associated with a hypotonic final saliva (Young and van Lennep, 1979). Kay (1960) did not report the presence of striated ducts in either mandibular or sublingual glands but found their secretions to be hypotonic.

An unusual feature of the bovine sublingual glands was the apparent histological variation from one region to another (Figures 2.5.3 and 2.5.4). Some areas of sublingual gland tissue samples examined were composed of densely packed secretory endpieces and poorly developed intralobular ducts without basal striations. Plasma cells, a common feature of bovine sublingual glands, were not evident in such regions. However, most areas of the sublingual glands consisted of secretory endpieces distributed among irregularly-arranged connective tissue bundles which contained several plasma cells and well developed striated ducts. Shackleford (1963) remarked briefly on the histological variation of bovine sublingual glands with reference to "a pronounced difference in the relative numbers of mucous and non-mucous elements from one area to another", but there was no mention of plasma cells or striated ducts. The significance of this histological variation is unknown; tissues of other bovine salivary glands examined in the present study did not exhibit regional variation.

Histological and histochemical studies of the minor salivary glands of cattle have been well documented by Birtles (1981). Of the buccal glands, the ventral buccal was histologically identical to the parotid. Ruminant ventral buccal glands investigated to date, have been reported as generally similar to their parotid glands (Young and van Lennep, 1978) and could functionally supplement the parotid salivary secretion.

The mucous cells of the intermediate buccal glands contained acidic and neutral mucosubstances which were histochemically similar to sublingual gland mucosubstances, while the demilunes were proteoserous and immunohistochemically

found to contain salivary protein band 4 (Figure 2.6). Biochemical investigations have shown the intermediate buccal glands to be unusual in possessing traces of all bovine low molecular weight salivary proteins (Table 1.1). The significance of this finding, relative to all other bovine salivary glands and particularly in relation to future investigations is not clear, although it appears that genetic material required for synthesis of bovine salivary proteins has been retained by only the intermediate buccal glands, in addition to an ability to differentiate IEG duct cells observed in the parotid glands.

The dorsal buccal and palatine gland mucous cells contained histochemically similar secretory products to those of the intermediate buccal and sublingual glands: the demilunes were usually refractory to all stains used although immunohistochemical studies were not conducted to investigate the possible distribution of salivary proteins.

Areas of proteoserous lobules were frequently observed in dorsal and intermediate buccal glands and the palatine glands. It is therefore likely that these three minor glands along with the ventral buccal, contribute significantly to the volume of the total secretion from the bovine salivary glands. Kay (1960) previously concluded that the total volume of saliva secreted by the minor glands, approximately equalled the volume secreted by the parotid glands.

Birtles (1981) presented evidence in favour of a possible holocrine secretory mechanism found in dorsal and intermediate buccal glands and palatine glands, findings which were confirmed in the present study (Figures 2.7.4 and 2.8.4). The significance of this secretory mechanism observed only in some bovine salivary glands is speculative. Atypical secretory mechanisms have not been reported from investigations on salivary glands of other mammalian species.

Mucous cells of salivary gland tissues in the posterior tongue were histochemically similar to those of the

sublingual glands, dorsal and intermediate buccal and palatine glands. The demilunes, however, often contained carboxylated and sulphated mucosubstances and PAS positive neutral mucosubstances (Figure 2.9), features not observed in demilunes of either the sublingual glands or the three previously described minor glands. Additionally proteoserous lobules were not present.

The pharyngeal glands usually displayed morphological features not evident in the other minor glands. The secretory endpieces were short and tubular with conspicuous demilunes that contained acidophilic granules, neutral and carboxylated mucosubstances. In general the histochemical composition of the demilunes were similar to those of the mandibular glands but the pharyngeal gland demilunes stained more intensely for mucosubstances. The secretory products of the mucous cells were similar to those from mucous cells of posterior tongue, palatine, dorsal and intermediate buccal and sublingual glands.

The intralobular ducts of the pharyngeal glands were usually lined with goblet cells and the secretory endpieces often appeared to drain directly into intralobular ducts (Figures 2.10 and 2.10.4); this drainage pattern has been reported for salivary glands of other species (Young and van Lennep, 1978). However, both the above features and particularly goblet cells, were not observed in the intralobular ducts of other bovine major and minor salivary glands.

The pharyngeal glands shared in common with both sublingual and the mandibular glands, the presence of numerous subepithelial plasma cells, distributed between endpieces and close to intralobular ducts (Figure 2.10.2). This significant preliminary finding established that humoral mucosal immunity mediated via the bovine salivary glands is mainly provided by immunoglobulins synthesised and secreted by plasma cells of these three glands. The sublingual glands in particular contained the majority of plasma cells, most

of which reacted immunohistochemically with antibody to secretory IgA, the major immunoglobulin of ruminant saliva (Mach and Pahud, 1971). On the other hand there was little evidence to suggest that parotid and ventral buccal glands contribute significantly to humoral immunity since plasma cells were rarely found in these glands. Nevertheless, immunological studies by Watson and Lascelles (1971) previously established that in ruminants, immunoglobulins such as sIgA were low in parotid saliva compared with levels in non-parotid saliva. It is, however, alternatively proposed here, although not proved, that parotid and ventral buccal glands may contribute predominantly to cellular mucosal immune reactions, mediated via IEG duct cells which were specific to these two glands (Figure 3.1).

Immunologists who have recently focussed attention on the diverse mucosal cell types are generally of the opinion that, in addition to T-cell subpopulations, mucosal mast cells, globule leucocytes and intraepithelial lymphocytes are also involved in poorly understood mucosal cell-mediated immune reactions (Bienenstock and Befus, 1980; Tomasi et al., 1980). Tomasi et al. (1980) stated that "there may be several subclasses of T-lymphocytes, some granulated with mast cell-like functional properties, others more typically lymphoid with helper and suppressor functions. Intraepithelial lymphocytes in particular contain cytoplasmic granules and are morphologically similar to mast cells, with reported alterations in their proportions during gastrointestinal diseases." Additionally, Bienenstock (1979) stated that intraepithelial lymphocytes "may represent a closed cell population, whatever their derivation they have a resemblance to both lymphocytes and mast cells and may act as specific passively-sensitised sentinel cells at the mucosal surface." Some intraepithelial granular cell types with mast-like staining characteristics are known to possess natural killer activity (J. Bienenstock, personal communication). The relationship of intraepithelial lymphocytes, if any, with mucosal mast cells and globule leucocytes, has not been established.

In the present study, the IEG duct cells of parotid and ventral buccal glands examined had features common to both lymphocytes and mucosal mast cells. It should, however, be stressed that the nature of the relationships, if any, of IEG duct cells with intraepithelial lymphocytes, mucosal mast cells and globule leucocytes, are at best hypothetical, although from an overall assessment of the above data, a possible role for IEG duct cells in cell-mediated immunity cannot be ignored; additionally the established association between IEG duct cells and bloat susceptibility (Birtles, 1981) suggests that the appearance of these cells could be associated with a protective role.

In cattle, therefore, it seems that humoral immunity to the entire oral cavity, oesophagus and the reticulorumen, regions which lack lymphoid tissue, is provided by immunoglobulins secreted from the sublingual, mandibular and pharyngeal glands, whereas cellular immunity to the same regions is probably mediated via the IEG duct cells of the parotid and ventral buccal glands.

To postulate the identity of IEG duct cells, a critical evaluation was made of reports describing such cell types in epithelial locations. The cell type which appeared very similar to the IEG duct cell in morphology was the globule leucocyte, a poorly defined cell type, first described by Weill (1920)*, but as yet it has not been precisely identified (see Gregory, 1979). It is, however, established that the globule leucocyte is not widely distributed, but restricted mainly to epithelia in regions such as the respiratory tract (Kent, 1966; Vandenberghe and Baert, 1981), glandular stomach (Whur, 1966), small intestine (Kent, 1966; Whur and Johnstone, 1967; Murray et al., 1968; Takeuchi, Jarvis and Sprinz, 1969), colon (Takeuchi et al., 1969), bile duct (Rahko, 1972), uterine epithelium (Kellas, 1961) and urinary tract (Cantin and Veilleux, 1972).

* see Gregory (1979).

A "typical" globule leucocyte described in the above reports usually consisted of an eccentrically-placed nucleus with peripherally-distributed chromatin and a cytoplasm containing small metachromatic acidophilic granules or large acidophilic globules. A critical analysis of most reports, however, showed that there are species as well as histochemical differences described by most authors, a finding originally made by Weill (1920) who "not only emphasised the interspecific differences in the globules but in the degree of basophilia of the cytoplasm."* For example, in the rat the globule leucocytes were very similar to the mucosal mast cell (Kent, 1966; Murray et al., 1968; Cantin and Veilleux, 1972; Collan, 1972; Mayrhofer et al., 1976; Ham and Cormack, 1979; Vandenberghe and Baert, 1981) but their granule structure differed from mucosal mast cells and were more acidophilic; features which tempted Murray et al. (1968) to postulate that globule leucocytes are derived from mucosal mast cells. However this view has not received widespread support (Collan, 1972; Cantin and Veilleux, 1972; Ruitenbergh and Elgersma, 1979; Vandenberghe and Baert, 1981) since transitional cell types and mast cells which migrated into the epithelium to become globule leucocytes were not identified. In the rat, the current trend therefore is to emphasise the similarities between the mucosal mast cell and the globule leucocyte (Ham and Cormack, 1979) such as: morphology and Toluidine blue metachromasia (Collan, 1972), AB staining at low pH and presence of basic proteins (Cantin and Veilleux, 1972), cytoplasmic IgE (Mayrhofer et al., 1976) and a possible lymphocyte origin (Miller, 1980).

In ruminants, and particularly in the sheep abomasum, the globule leucocyte has been characterised by large acidophilic globules, a cytoplasm usually refractory to staining and a nucleus similar to that of a plasma cell (Kent, 1952; Dobson, 1966; Murray et al., 1968; Rhako, 1972). But even though histochemical similarities such as AB staining at low pH and Toluidine blue metachromasia have been reported

* see Gregory (1979).

(Murray et al., 1968), the mast cell association in ruminants was less clear since there was no correlation between appearance of mast cell numbers and globule leucocytes (Kent, 1952; Lawrence, 1972; Gregg, Dineen, Rothwell and Kelly, 1978). Dobson (1966) was of the opinion that in sheep, globule leucocytes were plasma cells with Russell bodies; however Kent (1952) previously established that the two cell types in sheep were, at times, morphologically similar but histochemically different, for example, globule leucocytes were strongly reactive to PTAH (phosphotungstic acid haematoxylin) and metachromatic with Toluidine blue while Russell bodies of plasma cells were negative to both stains. These two cell types were also studied by Murray et al. (1968) who demonstrated ultrastructural differences between globule leucocytes and Russell bodies of plasma cells and emphasised the ultrastructural and histochemical similarities between globule leucocytes and mucosal mast cells. Rhako (1972), from an investigation of globule leucocytes in the gall bladder epithelium of sheep, cattle and goats concluded that the globule leucocyte in all three species exhibited morphological as well as histochemical differences; for example sulphate groups were demonstrated only in cattle. In sheep uterine epithelium, an intraepithelial granular cell type tentatively identified by Kellas (1961) as a globule leucocyte, differed in morphology and histochemistry with globule leucocytes of the abomasum.

Globule leucocytes have also been studied in the cat, (Takeuchi et al., 1969), fowl (Toner, 1965) and mice (Ruitenbergh and Elgersma, 1979). Takeuchi et al. (1969) in particular reported histochemical differences between globule leucocytes of the small and large intestine.

Two cell types, the mast cell and the lymphocyte, have been commonly proposed as precursors of globule leucocytes. Murray et al. (1968) were of the opinion that globule leucocytes in ruminants are derived from mucosal mast cells whereas Kent (1952) has proposed the lymphocyte as the likely precursor of the globule leucocyte in sheep. The

origin of the globule leucocyte in the cat is unknown, (Finn and Schwartz, 1972) however in fowl (Kitagawa, Ogata, Sugimura, Hashimoto and Kudo, 1979) and in mice (Ruitenbergh and Elgersma, 1979) thymus-dependent lymphocytes have been demonstrated as likely precursors. Rudzik and Bienenstock (1974) associated the globule leucocyte with a granular lymphocyte specifically found in the gut mucosal epithelia but rare in lymphoid tissue and peripheral lymph nodes.

The function of the globule leucocyte is equally obscure. It is however established that in most species globule leucocytes are commonly present during parasitic infections (see Gregory, 1979), but the nature of the relationship is unknown. Previously Dobson (1966) and Whur and Johnstone (1967) suggested that the globule leucocyte in the sheep abomasum and rat ileum respectively, contained immunoglobulins, but their findings were later shown to be in error (Whur and White, 1970; Rudzik and Bienenstock, 1974). Murray et al. (1968) proposed that the transformation of mucosal mast cells to globule leucocytes may be associated with the secretion of immunoglobulin from plasma cells. Mayrhofer et al. (1976) demonstrated cytoplasmic IgE in globule leucocytes in the rat ileum and were of the opinion that globule leucocytes may be involved in transportation of secretory IgE during parasitic infections. Recently, H.R.P. Miller (personal communication) has isolated large amounts of dopamine and some chymotrypsin and trypsin from globule leucocytes but their significance was not examined. Bienenstock and Befus (1980) have suggested that globule leucocytes of the gastrointestinal tract may be implicated in cell-mediated immune reactions at mucosal surfaces. If this were so, an investigation of their role in salivary glands has yet to reach the preliminary stage. Overall there is, however, a consensus of opinion among authors that the globule leucocyte in association with the mucosal mast cell is in some way implicated in immunological reactions at epithelial surfaces (see Gregory, 1979 and Castro, 1982).

The IEG duct cells of parotid and ventral buccal glands

of cattle were found to be morphologically and histochemically similar to globule leucocytes of most species, especially the appearance of the nucleus, variation in granule structure and histochemical characteristics, such as acidophilic, metachromatic granules and cytoplasmic basophilia (Figure 3.1 and 3.3). Despite similarities, IEG duct cells did not appear to be identical to globule leucocytes reported in ruminants by Kent (1952), Kellas (1961), Murray et al. (1968) and Rhako (1972). In particular ultrastructural variations in granule morphology were noted between globule leucocytes of the bovine abomasum (Murray et al., 1968) and IEG duct cells. Globules of the abomasal globular leucocytes were acidophilic and sometimes rimmed by Alcian blue staining material giving rise to a "halo-effect". This suggests that morphological and histochemical variations of the globule leucocyte reported in other species (Kellas, 1961; Takeuchi et al., 1969; Rhako, 1972) may also be present in cattle. Moreover, the present study has been the first to investigate a possible globule leucocyte in salivary glands, and their function, like that of globule leucocytes in other species and organs remains undetermined. Previously, van Lennep et al. (1977) reported presumptive globule leucocytes in striated ducts of the sheep parotid glands; these cells were, however, not described in detail but could well be identical to those observed in the present study (Figure 3.1.8).

A comparison between intracytoplasmic contents of globule leucocytes and IEG duct cells revealed that both probably contain a biogenic amine. H.R.P. Miller (personal communication) has isolated dopamine from globule leucocytes while 5-hydroxytryptamine or a related biogenic amine was identified in IEG duct cells (Figure 3.3.8). The present investigation also established that sIgA is unlikely to be concentrated in the granule contents, but the presence of other immunoglobulins, especially IgE cannot be ruled out because of its association, in the rat, with globule leucocytes and parasitic infections (Mayrhofer et al., 1976). It is not clear whether similar conditions are present in cattle,

although globule leucocytes have been correlated with parasitic infections in this species (Lawrence, 1977).

If IEG duct cells are globule leucocytes their association with susceptibility to bloat still remains unresolved. Although it is tempting to postulate that since IEG duct cells are more numerous in L.S. animals, they may reduce bloat susceptibility by elaborating a secretory product or by mediating cellular immune reactions. The effects of such a secretory product or immune reactions controlled from ruminant parotid glands are likely to extend into the reticulorumen and omasum, areas which show a paucity of intraepithelial cells. In contrast, the presence of IEG duct cells or similar intraepithelial cell populations has not been reported in salivary glands of monogastric species which, not unexpectedly, have an abundance of intraepithelial cells, such as globule leucocytes, within the gastric mucosa, particularly during inflammatory disorders and infections of the GI tract.

The present study failed to establish that IEG duct cells (or presumptive globule leucocytes) as they appear in bovine salivary glands are derived from mucosal mast cells (Murray et al., 1968) although close similarities between the two cell types were noted. Rather, the writer favours a granular lymphocyte specific to epithelial sites as a likely precursor cell which may be related to the mucosal mast cell or its stem cell.

CHAPTER 5. CONCLUSION

Bovine salivary secretions are elaborated by three major salivary glands, the parotid, mandibular and sublingual and numerous minor salivary glands embedded among subepithelial connective tissues and muscles. The salivary glands consisted of tubular secretory endpieces composed of proteoserous, mucous and demilune cells, specialised for synthesis and secretion of water, electrolytes, proteins and mucosubstances. The ductal system, while functioning as conduits for transport of secretory products from endpieces, additionally possessed epithelia well developed for transport of water and electrolytes and synthesis of glycoproteins.

The histochemical composition of salivary glands examined are summarized in Table 5.1.

The parotid glands were composed of proteoserous cells specialised for secretion of water and electrolytes with small amounts of PAS positive neutral mucosubstances and salivary protein bands 1, 3, 4, 5, 6, 7, 10, 10s and 10d. Of these, bands 4 and 10 were traced immunohistochemically to individual proteoserous cells of the gland. The bovine parotid glands were unusual in not possessing "striated" intralobular ducts; although this may be significant in the secretion of an isotonic saliva, intralobular ducts of the sheep parotid glands were noticeably "striated". This singular difference may highlight the dangers of broadly applying the "ruminant model" arbitrarily without consideration to species variation. The intralobular duct cells of the bovine parotid glands occasionally consisted of PAS positive material and "apical blebs". Another unusual feature of the parotid gland intralobular ducts, was the presence of a granulated intraepithelial cell located adjacent to the basal lamina of the duct wall. Such cells were polymorphic in appearance with nuclei similar to those of plasma cells and basophilic cytoplasms which contained acidophil

Table 5.1

HISTOCHEMICAL CLASSIFICATION
OF BOVINE SALIVARY GLANDS

| PAROTID AND VENTRAL BUCCAL GLANDS | |
|-----------------------------------|---|
| Proteoserous cells. | Immunohistochemically detectable intrinsic proteins eg. band 4 and band 10, and PAS positive band 5. |
| MANDIBULAR GLANDS | |
| Mucous cells | Neutral glycoproteins and carboxylated acid mucosubstances. |
| Demilunes | Neutral glycoproteins, carboxylated acid mucosubstances and acidophilic basic proteins, including protein band 8. |
| SUBLINGUAL GLANDS | |
| Mucous cells | Neutral glycoproteins, carboxylated and sulphated acid mucosubstances. |
| Demilunes | Proteoserous, including protein band 9. Negligible amounts of acid mucosubstances and PAS positive glycoproteins. |
| INTERMEDIATE BUCCAL GLANDS | |
| Mucous cells | Neutral glycoproteins, carboxylated and sulphated acid mucosubstances. |
| Demilunes | Proteoserous, including protein band 4. Negligible amounts of acid mucosubstances and PAS positive glycoproteins. |
| UPPER BUCCAL GLANDS | |
| Mucous cells | Neutral glycoproteins, carboxylated and sulphated acid mucosubstances. |
| Demilunes | Proteoserous, negligible amounts of acid mucosubstances and PAS positive glycoproteins. |

Table 5.1 (cont.)

| PALATINE GLANDS | |
|-------------------------|---|
| Mucous cells | Neutral glycoproteins, carboxylated and sulphated acid mucosubstances. |
| Demilunes | Proteoserous, negligible amounts of acid mucosubstances and PAS positive glycoproteins. |
| POSTERIOR TONGUE GLANDS | |
| Mucous cells | Neutral glycoproteins, carboxylated and sulphated acid mucosubstances. |
| Demilunes | Neutral glycoproteins, carboxylated and sulphated acid mucosubstances. |
| PHARYNGEAL GLANDS | |
| Mucous cells | Neutral glycoproteins, carboxylated and sulphated acid mucosubstances. |
| Demilunes | Neutral glycoproteins, carboxylated and sulphated acid mucosubstances and acidophilic basic proteins. |

metachromatic granules of various sizes. It was proposed that granulated intraepithelial cells are derived from a granular lymphocyte subpopulation and are probably similar to the poorly defined globule leucocyte cell type described by most workers, (see Gregory , 1979). The excretory ducts of the parotid glands contained numerous goblet cells which could supplement the parotid secretion with acidic mucosubstances.

Tubular endpieces of the mandibular glands were composed of mucous cells and prominent demilune cells. The mucous cells contained neutral and acidic mucosubstances, the latter were mostly neuraminidase labile carboxyl groups of sialic acid. The demilunes contained acidophil granules the contents of which included protein band 8; in addition the demilunes appeared to synthesise neutral and acidic mucosubstances most of which were "masked" by the acidophil granules. The intralobular ducts of the mandibular glands, unlike those of the parotid gland, were composed of tall columnar cells with basal striations. Goblet cells, a feature of the parotid gland excretory ducts, were not found in the mandibular gland.

The mucous cells of the sublingual glands were positive for neutral and acidic mucosubstances. The acid glycoproteins in particular were not neuraminidase labile and appeared to differ histochemically to those of the mandibular gland. A histochemical evaluation for the presence of sulphate groups included hyaluronidase digestion followed by Alcian blue staining at low pH. Subsequent positive staining showed that connective tissue mucopolysaccharides are unlikely to be found in epithelial mucous secretions. Alcian blue staining was therefore attributed to sulphated glycoproteins or sialo-sulphated glycoproteins. Such residues were mainly present in the sublingual glands and all minor glands, except the ventral buccal; the sulphate content of the mandibular was found to be negligible. The secretions of the sublingual gland demilunes were predominantly proetoserous and contained protein band 9. There was very little evidence

of neutral or acidic glycoproteins. The sublingual gland "striated" intralobular ducts by comparison with those of the mandibular gland, were equally well developed.

The minor glands, with the exception of the ventral buccal, which was identical to the parotid, were specialised for the secretion of acidic and neutral mucosubstances. In general, the histochemical features of the minor gland mucous cells were similar to those of the sublingual gland. The pharyngeal glands however contained large demilune cells which were similar in morphology and histochemistry to those of the mandibular gland, although the demilunes of the former were noticeably more acidic. The demilunes of the posterior tongue glands occasionally contained sulphated mucosubstances, a feature also observed in demilunes of the pharyngeal glands. Demilunes of the intermediate buccal glands were found to contain protein band 4; it is not unlikely that demilunes of other minor glands may similarly contain proteinacious material which is not detected by histological stains, such as PAS and Alcian blue. It would be safe to assume that secretions from these cells are mainly proteoserous rather than purely serous.

Abundant goblet cells in the intralobular ducts were noticed only in the pharyngeal group of glands. There was also an indication that in this group, the secretory end-pieces communicated directly with the intralobular ducts.

Two unusual features observed in three other minor glands, the intermediate bucca, dorsal buccal and palatine, were (1) a possible atypical secretory mechanism which involved cellular debris mixed with mucous secretions, and (2) scattered islets of proteoserous lobules identical to those of the parotid and ventral buccal glands.

The humoral mucosal immune system of the bovine salivary glands is likely to be maintained by immunoglobulins, such as sIgA, synthesised and secreted from plasma cells distributed mostly in three salivary glands, the sublingual,

mandibular and pharyngeal glands. It was proposed that the parotid and ventral buccal glands may be specialised for maintenance of cell-mediated immunity at a mucosal level, mediated probably by granulated intraepithelial duct cells, which were tentatively identified as globule leucocytes.

Histological studies pertaining to bloat susceptibility in cattle, demonstrated that protein band 4 of parotid saliva, which has been correlated with susceptibility to bloat, was equally distributed in parotid tissue samples of both L.S. and H.S. animals. Explanations proposed for this anomalous result were: a possible difference in parasympathetic and sympathetic innervation patterns in L.S. and H.S. animals involving parotid protein secretion, and the presence of a poorly understood intracellular regulatory mechanism for secretion of protein band 4.

The questions that arose during the present study, which could provide guidance for further investigations are:-

- (1) The physiological significance for the lack of basal striations in the intralobular ducts of the parotid glands.
- (2) To identify the precursor cell of the intraepithelial granular duct cell, preferably from epon-embedded semi-thin serial sections and to conduct a comparative, ultrastructural and cytochemical study of both the intraepithelial granular duct cell and the mucosal mast cell.
- (3) A detailed examination of the apparent atypical secretory mechanism observed in three minor glands and its possible significance.
- (4) An ultrastructural investigation of parotid proteo-serous cells in both L.S. and H.S. animals to examine in detail the intracellular distribution pattern of band 4.

- (5) The stimulus for the appearance of intraepithelial granular duct cells in parotid glands of L.S. animals - a challenging problem which cannot be completely resolved from histological studies alone.

Since secretory tissues are not found in the ruminant forestomachs, it is the writer's opinion that the biochemical components of bovine saliva such as low molecular weight salivary proteins, high molecular weight mucosubstances, water and electrolytes, could each have a specific function within the reticulorumen and omasum. The histological structure and histochemical composition of the salivary glands show tissues specialised for either synthesis or secretion or both.

Investigations into the function of low molecular weight protein fractions are yet at a preliminary stage although band 4 has been implicated with bloat susceptibility. High molecular weight mucosubstances, such as acidic and neutral glycoproteins could provide a protective layer of mucus to the ruminant forestomachs to prevent abrasion and dessication of the lining epithelia and resist bacterial adherence in addition to supplying a valuable source of nitrogen for maintenance and proliferation of ruminal microorganisms. Additionally, since lymphoid tissues are scarce in the mucosa of ruminant forestomachs, immunoglobulins such as sIgA, synthesised and secreted by plasma cells of salivary glands can enhance immunoprotection to the oral cavity, oesophagus, reticulorumen and omasum, against harmful antigenic matter.

APPENDIX I

The principles of histochemical methods used for the detection of mucosubstances.

Epithelial mucosubstances consist predominantly of glycoproteins which are peptide chains bearing numerous covalently linked oligosaccharide units. These carbohydrate units are six-membered pyranose rings which contain histochemically detectable residues such as 1,2 glycol groups, 1,2 amino hydroxyl groups, carboxyl acid groups and sulphate esters. Epithelial secretory glycoproteins that contain these residues are mainly neutral sugars, sialic acids and sialosulphated glycoproteins and sulphated glycoproteins.

To establish the identity of the above groups histological stains can be used, as well as histochemical techniques such as acetylation, saponification, methylation and enzymic digestion.

A. Demonstration of neutral side groups

The periodic acid-schiff (PAS) method utilises periodic acid to oxidise hydroxyl groups of adjacent carbon atoms to aldehydes; these are then rendered visible by reaction with Schiff's reagent, with which the aldehydes form a stable product, pink or dark red in colour. Acetylation, by use of acetic anhydride in dry pyridine, blocks hydroxyl groups by converting them to acetyl esters thus preventing reactivity with the Schiff's reagent. A PAS positive substance after acetylation would be PAS negative, thus indicating that the original reaction was due to a 1,2 glycol group.

A distinction between PAS reactivity due to neutral side groups of glycogen molecules and neutral glycoproteins can be made using diastase digestion which specifically removes glycogen. PAS reactivity after diastase digestion could therefore be attributed to neutral glycoproteins other than glycogen.

B. Demonstration of acidic side groups

With contrast to neutral side groups there are a multiplicity of methods available for the demonstration of acid groups, the majority being cationic dyes specific for carboxyl and sulphate groups. For example, Alcian blue, Alcian yellow, colloidal iron, periodic acid-phenylhydrazine Schiff (PAPS), Toluidine blue and Azure A. In addition the use of a basic stain such as Alcian blue together with PAS, can be used to distinguish between neutral and acidic groups at the same site.

The most commonly used cationic dye is Alcian blue which can be used at either pH 1.0 or 2.5 to identify sulphated and carboxyl groups respectively. At low pH sulphate groups are sufficiently ionized to react with the dye whereas at pH 2.5 the reactive groups ionized are mostly carboxyl groups.

Methylation performed at 60°C for 4 hours by use of 1% HCl in methyl alcohol eliminates basophilia due to acidic groups: carboxyl groups are converted to methyl esters while sulphate groups are removed from glycoprotein molecules. Methylation could also remove carboxyl groups of some sialic acid residues without converting them to methyl esters.

The effects of methylation can be reversed by saponification with 0.5% solution of KOH in 70% ethanol. This procedure restores basophilia of carboxyl groups esterified by methylation but does not restore basophilia due to sulphate groups or carboxyl groups which have been removed during methylation. Saponification could also be used to restore PAS reactivity blocked by acetylation.

Carboxyl groups of sialic acid origin can be specifically identified by removal of sialic acid units by use of the enzyme sialidase (or neuraminidase) and staining subsequently with Alcian blue at pH 2.5. Any basophilia

after neuraminidase digestion is probably due to sialic acid residues not labile to neuraminidase and additionally to small amounts of uronic acid, although the latter has not been identified in bovine salivary gland mucosubstances.

The nature of the sulphate groups can be investigated by use of the enzyme testicular hyaluronidase which extracts mucopolysaccharide residues usually found in connective tissues. Subsequent Alcian blue staining at low pH could therefore be attributed to sulphate groups attached to glycoprotein molecules, such as sulphated glycoproteins or sialo-sulphated glycoproteins rather than chondroitin sulphates.

The acidic nature of the mucosubstances can be further established by use of periodic acid-phenylhydrazine Schiff reaction which uses phenylhydrazine to block periodate-induced aldehyde groups from neutral glycoproteins leaving aldehyde groups of sialo-glycoproteins or sialo-sulphated glycoproteins to react with the Schiffs reagent.

The phenomenon of metachromasia in the presence of thiazin dyes such as Toluidine blue and Azure A is due to the ability of the dye to impart a colour that differs from the original colour of the dye. This change in colour, due to a shift to shorter wavelengths (a hypsochromic shift) in the absorption spectrum of the dye, is characteristically induced by high molecular weight tissue substrates which have anionic radicles close together. High molecular weight connective tissue mucopolysaccharides such as chondroitin sulphates and hyaluronic acids impart an intense violet-red metachromatic colour with thiazine dyes and epithelial mucosubstances of lower molecular weight, such as sialic acids, impart a weaker purple metachromatic colour.

APPENDIX II

Staining and Histochemical Techniques

(1) Haematoxylin and Eosin (H&E)

Method:-

1. Dewax and bring sections to water.
2. Stain in Mayers Haemalum for 10 minutes.
3. Rinse in tapwater.
4. Blue in Scotts tapwater for 2 minutes.
5. Rinse in tapwater.
6. Stain in 1% aqueous Eosin Y for 2 minutes.
7. Rinse rapidly in tapwater.
8. Dehydrate, clear in xylene and mount in D.P.X.

(2) Alcian Blue (AB) pH 1.0 and pH 2.5

Method:-

1. Dewax and bring sections to water.
2. Stain in 1% Alcian blue 8GX in 3% acetic acid (pH 2.5) or 1% Alcian blue 8GX in 0.1N HCl (pH 1.0) for 10 minutes.
3. Rinse in tapwater.
4. Counterstain with H&E, dehydrate clear and mount.

Results:-

Carboxylated mucosubstances stain blue at pH 2.5,
Sulphated mucosubstances stain blue at pH 1.0.

(3) Periodic Acid Schiff (PAS)

Method:-

1. Dewax and bring sections to water.
2. Oxidise in 1% periodic acid for 8 minutes.
3. Wash in running tap water for 5 minutes.
4. Wash in three changes of distilled water.
5. React with Schiffs reagent for 10 minutes.
6. Wash in running tapwater for 10 minutes.
7. Stain in Mayers Haemalum for 5 minutes.
8. Rinse in tapwater.
9. Blue in Scotts tapwater for 2 minutes.
10. Rinse in tapwater.

11. Rinse in 70% and 95% alcohol.
12. Counterstain in saturated solution of Tartrazine in cellusolve (ethylene glycol monoethyl ether) for 2 minutes.
13. Differentiate and dehydrate in 2 changes of absolute alcohol.
14. Clear in xylene and mount in D.P.X.

Results:-

Neutral glycoproteins stain pink to dark red.

Preparation of Schiffs Reagent:-

To 400 ml of distilled water warmed to 37°C add 2 grams of pararosaniline and agitate until dissolved. Add 7.6 grams of sodium metabisulphite and 2 ml of concentrated Hydrochloric acid. Shake well for 10 minutes. Store in dark cupboard at room temperature overnight until solution becomes straw-coloured. Add 2 grams of activated charcoal. Shake well and filter before use. Store in refrigerator.

(4) Alcian blue and Periodic acid Schiff

Method:-

1. Follow AB method Steps 1 - 3.
2. Stain with PAS method Steps 1 - 14.

Results:-

Neutral glycoproteins stain red.

Acid glycoproteins stain blue.

Mixed groups stain purple.

(5) Phenylhydrazine-Periodic Acid Schiff (PAPS)

Method:-

1. Dewax and bring sections to water.
2. Oxidise in 1% periodic acid for 8 minutes.
3. Wash in running tapwater for 5 minutes.
4. Block periodate-induced aldehydes with 0.5% aqueous phenylhydrazine hydrochloride in coplin jar for 30 minutes.
5. Wash in running tapwater.

6. Stain with Schiff's reagent for 10 minutes.
7. Wash in running tapwater for 10 minutes.
8. Counterstain with tartrazine.
9. Dehydrate, clear and mount.

Results:-

Sialo glycoproteins and sialo-sulphated glycoproteins stain red.

(6) Acetylation and PAS

Method:-

1. Dewax and bring to water.
2. Treat with mixture of acetic anhydride (13 ml) and pyridine (20 ml) for 1 hour.
3. Wash in water.
4. Stain with PAS technique Steps 2 - 14.

Results:-

Acetylation blocks hydroxyl groups, which are then PAS negative.

(7) Acetylation, Saponification and PAS

Method:-

1. Dewax and bring to water.
2. Treat with mixture of acetic anhydride (13 ml) and pyridine (20 ml) for 1 hour.
3. Wash in water.
4. Treat with 0.1N KOH for 45 minutes in coplin jar.
5. Wash in water.
6. Stain with PAS technique Steps 2 - 14.

Results:-

Saponification restores PAS staining of hydroxyl groups blocked by acetylation.

(8) Diastase and PAS

Method:-

1. Dewax and bring to water.
2. Digest with diastase (1:1000 in distilled water)

or treat with saliva for 30 minutes at 37°C.

3. Wash in water.
4. Stain with PAS technique Steps 2 - 14.

Results:-

Diastase removes glycogen, PAS reactivity is therefore specific for neutral glycoproteins.

(9) Methylation and Alcian blue at pH 1.0 and pH 2.5

Method:-

1. Dewax and bring sections to 70% alcohol.
2. Place in preheated 1% HCl in methyl alcohol for 4 hours at 60°C.
3. Rinse in alcohol.
4. Stain with Alcian blue method Steps 2 - 4.

Results:-

Acid mucosubstances are AB negative at both pH 1.0 and pH 2.5, as active methylation eliminates basophilia.

(10) Methylation, Saponification and AB at pH 1.0 and pH 2.5

Method:-

1. Dewax and bring sections to 70% alcohol.
2. Place in preheated 1% HCl in methyl alcohol for 4 hours at 60°C.
3. Rinse in alcohol.
4. Saponify in 0.5% KOH in 70% alcohol for 30 minutes at Room Temperature.
5. Wash in water.
6. Stain with Alcian blue method Steps 2 - 4.

Results:-

Negative AB staining at pH 1.0 as sulphate groups are hydrolysed. Saponification restores methylated carboxyl groups to stain at AB pH 2.5.

(11) Neuraminidase and Alcian blue at pH 2.5

Method:-

1. Dewax and bring to water.
2. Incubate sections in solution of neuraminidase (Cl. Perfringens) (P.L. Biochemicals Inc.); prepared by:

| | |
|----------------------------|--------|
| 0.1M acetate buffer pH 5.5 | 1.0 ml |
| Calcium chloride | 10 mg |
| Neuraminidase | 10 mg |

 Incubate overnight at 37°C with control sections in buffer alone.
3. Wash in tap water.
4. Stain with AB method at pH 2.5, Steps 2 - 4.

Results:-

Neuraminidase eliminates AB staining attributed to carboxyl groups of neuraminidase labile sialic acids.

(12) Hyaluronidase and Alcian blue at pH 1.0

Method:-

1. Dewax and bring to water.
2. Incubate sections in solution of hyaluronidase (Bovine testes) (15,000 units) (P.L. Biochemicals Inc.); prepared by:

| | |
|-------------------------|------|
| hyaluronidase | 5 mg |
| Phosphate buffer pH 6.7 | 5 ml |

 Incubate overnight at 37°C with control section of elastic cartilage (epiglottis) in buffer alone.
3. Wash in tap water.
4. Stain with AB method at pH 1.0 Steps 2 - 4.

Results:-

Hyaluronidase removes chondroitin sulphate and hyaluronic acid; subsequent AB staining at pH 1.0 is due to sulphated glycoproteins.

(13) Alcian Yellow pH 2.5

Method:-

1. Dewax and bring to water.
2. Stain in 0.5% Alcian Yellow GX in 3% acetic acid (pH 2.5) for 10 minutes.
3. Wash in tap water.
4. Counterstain with H&E.
5. Dehydrate, clear and mount.

Results:-

Carboxylated mucosubstances stain yellow.

(14) Toluidine Blue

Method:-

1. Dewax and bring to water.
2. Stain in 1% aq. Toluidine blue for 1 minute.
3. Rinse in tap water.
4. Dehydrate rapidly, clear and mount.

Results:-

Acid mucosubstances stain purple.

(15) Azure A pH 1, 2, 3 and 4

Method:-

1. Dewax and bring to water.
2. Stain at required pH solution for 5 minutes;
Prepare Azure A 1:5000 at pH 1, 2, 3 and 4 with phosphate-citrate buffer.
3. Rinse in tap water.
4. Dehydrate, clear and mount.

Results:-

Strongly acidic mucosubstances stain at pH 2 and above while sialo-glycoproteins stain at pH 4.

(16) Hales Colloidal Iron

Method:-

1. Dewax and bring to water.
2. Flood with solution of dialysed iron 1 volume

and 2M acetic acid 1 volume (mixed just before use) for 10 minutes.

3. Wash with distilled water.
4. Flood with acid-ferrocyanide solution of 2% potassium ferrocyanide 1 volume and 2% HCl 1 volume for 10 minutes.
5. Wash with distilled water.
6. Counterstain in Mayers Haemalum for 5 minutes.
7. Rinse in tap water.
8. Dehydrate, clear and mount.

Results:-

Acid mucosubstances stain bright blue.

Preparation of dialysed iron stock solution:-

dissolve 75 grams of FeCl_3 in 250 ml distilled water.

Add 100 ml of glycerol, with constant stirring add 55 ml of 25% ammonia solution. Dialyse resulting solution against distilled water for 3 days.

(17) BIAL reaction for sialic acid

Method:-

1. Dewax and bring to water.
2. Spray sections with BIAL reagent by use of Shandon spray gun.
3. Place sections, face down, on a glass frame in a preheated contained, which has on the bottom a thin layer of concentrated HCl at 70°C , for 5-10 minutes.
4. Dry sections in air.
5. Clear in xylene and mount.

Results:-

Areas of high concentrations of sialic acids stain reddish brown.

Preparation of BIAL reagent:-

| | |
|------------------------|---------|
| orcinol | 200 mg |
| conc. HCl | 80 ml |
| 0.1M CuSO ₄ | 0.25 ml |

Dissolve the orcinol in HCl, add CuSO₄ solution and make up to 100 ml with distilled water. Allow to stand for 4 hours.

(18) Bismarck Brown

Method:-

1. Dewax and bring to water.
2. Stain in Bismarck Brown solution for 30 minutes.
3. Rinse in 70% alcohol.
4. Counterstain in Carazzi'shaematoxylin for 1-2 minutes.
5. Wash in running tap water for 5 minutes.
6. Dehydrate, clear and mount.

Results:-

Sulphated mucosubstances and mast cell granules stain yellow-brown.

Preparation of Bismarck Brown solution:-

| | |
|------------------|-------|
| Bismarck Brown | 0.5 g |
| Absolute alcohol | 80 ml |
| 1% HCl | 10 ml |

(19) Neutral Red

Method:-

1. Dewax and bring to water.
2. Stain in 1% aqueous solution of Neutral red for 5 minutes.
3. Dehydrate, clear and mount.

Results:-

Neutral red, a cationic dye, stains mast cell granules dark red.

(20) Phloxine-Tartrazine

Method:-

1. Dewax and bring to water.
2. Stain in Carazzi's haematoxylin for 2 minutes.
3. Stain with 0.5% phloxine in 0.5% calcium chloride for 30 minutes.
4. Rinse in water and 70% alcohol.
5. Counterstain in Tartrazine in cellosolve for 2 minutes.
6. Rinse in absolute alcohol.
7. Dehydrate, clear and mount.

Results:-

Phloxine, an acid dye, stains basic proteins pink to red.

(21) Fast Red 2B

Method:-

1. Dewax and bring to water.
2. Stain in 0.1% Fast Red 2B in 0.1M veronal acetate buffer at pH 9.2 for 2 minutes.
3. Wash in running tap water.
4. Counterstain in Carazzi's haematoxylin for 2 minutes.
5. Rinse in tap water.
6. Dehydrate, clear and mount.

Results:-

Biogenic amines stain dark orange to red.

(22) Methyl Green-Pyronin

Method:-

1. Dewax and bring to water.
2. Flood with staining solution of:

| | | |
|-------------------------|------|----|
| 5% aqueous pyronin Y | 17.5 | ml |
| 2% aqueous methyl green | 10 | ml |
| distilled water | 250 | ml |

 and leave for 15 minutes.
3. Rinse rapidly in distilled water and blot

dry with filter paper.

4. Flood with acetone, leave for a few seconds.
5. Flood with equal parts of acetone and xylene.
6. Clear in fresh xylene and mount in D.P.X.

Results:-

Stains RNA bright pink-red, particularly useful for identification of plasma cells.

(23) Fluorescent antibody method

Method:-

1. Dewax and bring to water.
2. Flood with 2% bovine serum albumen (BSA) for 5 minutes.
3. Treat with fluoresceine conjugated antibody (goat anti-human IgA) (Miles-Yeda Ltd., Indiana), diluted 1/10 with phosphate buffered saline (PBS) pH 7.1.
Place sections in petri-dishes with moist filter paper on bottom of dish. Incubate for 1 hour.
Control sections are incubated with PBS only.
4. Rinse in PBS.
5. Wash in glass jar with use of a magnetic stirrer, in 3 changes of PBS, 15 minutes each wash.
6. Rinse in distilled water.
7. Mount in glycerol jelly and examine with fluorescent microscope.

Results:-

A positive reaction, for example plasma cells synthesising IgA, is demonstrated by apple-green or yellow fluorescence; however if control sections show similar fluorescent colours, this indicates formalin-induced autofluorescence produced by a biogenic amine such as 5-Hydroxytryptamine.

(24) Silver impregnation method

Method:-

1. Bring sections to water.
2. Stain in freshly prepared 0.05% aqueous silver nitrate for 3 hours at 60°C.
3. Without rinsing reduce in a freshly prepared solution of 1% hydroquinone and sulphite for 1 minute at 45°C.
4. Rinse in distilled water.
5. Fix in 5% sodium thiosulphate for 2 1/2 minutes.
6. Rinse in distilled water.
7. Dehydrate, clear and mount.

Results:-

Argyrophilic substances such as mast cell granules stain dark brown to black.

Preparation of silver solution:

Mix 50 mg silver nitrate, 10 ml of pH 5.6 acetic acid-sodium acetate buffer in 90 ml of distilled water.

(25) Mallory's Phosphotungstic Acid Haematoxylin (PTAH)

Method:-

1. Dewax and bring to water.
2. Treat with Lugol's iodine and sodium thiosulphate, 2 minutes each.
3. Place in 0.25% aqueous potassium permanganate for 5 minutes.
4. Rinse in distilled water.
5. Place in 5% oxalic acid for 10 minutes.
6. Rinse in distilled water.
7. Wash in tap water for 5 minutes, rinse with distilled water.
8. Stain in PTAH 12-24 hours.
9. Dehydrate rapidly, clear and mount.

Results:-

Eosinophilic substances stain dark purple or black,

nuclei and cross striations of muscle fibres stain blue, collagen and ground substance of bone, yellow to brick red.

Preparation of PTAH solution:

| | |
|----------------------|---------|
| Haematein | 1 g |
| Phosphotungstic acid | 20 g |
| Distilled water | 1000 ml |

Dissolve haematein and phosphotungstic acid separately in distilled water, using gentle heat. When cool, combine solutions and make up to 1 litre. Ripen solution immediately by adding 0.177 grams of potassium permanganate or expose to light and warmth for 5-6 weeks.

BIBLIOGRAPHY

- Ariyakulkaln, P. (1981) A study of morphological and physiological changes in the mandibular gland of the sheep associated with eating and direct stimulation. Ph.D. thesis, Massey University, Palmerston North, New Zealand.
- Ash, R.W. & Kay, R.N.B. (1959) Stimulation and inhibition of reticulum contractions, rumination and parotid secretion from the forestomach of conscious sheep. Journal of Physiology 149, 43-57.
- Azar, H.A. (1979) The hematopoietic system. In: Diagnostic Electron Microscopy Vol.2. ed. Trump, B.F. & Jones, R.T. John Wiley & Sons.
- Babkin, B.P. (1950) "Secretory mechanism of the Digestive Glands." New York: Hoeber.
- Bailey, C.B. (1961) Saliva secretion and its relation to feeding in cattle. 4. The relationship between the concentrations of sodium, potassium, chloride and inorganic phosphate in mixed saliva and rumen fluid. British Journal of Nutrition 15, 489-498.
- Bailey, C.B. & Balch, C.C. (1961) Saliva secretion and its relation to feeding in cattle. 2. The composition and rate of secretion of mixed saliva in the cow during rest. British Journal of Nutrition 15, 383-402.
- Barka, T. (1980) Biologically active polypeptides in submandibular glands. The Journal of Histochemistry and Cytochemistry Vol. 28, No. 8, 836-859.
- Bartley, E.E. (1976) Bovine saliva: production and function. In: Buffers in Ruminant Physiology and Metabolism. ed. Weinberg, M.S. and Sheffner, A.L.

Church Dwight Co. Inc., New York.

Bienenstock, J. (1979) The physiology of the local immune response. In: Immunology of the Gastrointestinal Tract. ed. Asquith, P. Churchill, London.

Bienenstock, J. & Befus, A.D. (1980). Mucosal immunology. Immunology 41, 249-270.

Bienenstock, J., Befus, A.D. & McDermott, M. (1981) Mucosal Immunity. In: The Mucosal Immune System. Current Topics in Veterinary Medicine and Animal Science Vol. 12. Martinus Nijhoff (publishers)

Bienenstock, J., Befus, A.D., Pearce, F., Denburg, J. & Goodacre, R. Mast cell heterogeneity: Derivation and function with emphasis on the intestine. The Journal of Allergy & Clinical Immunology (in press).

Birtles, M.J. (1981) Histochemical studies of the secretory processes in bovine salivary glands. M.Sc. thesis, Massey University, Palmerston North, New Zealand.

Blair-West, J.R., Coghlan, J.P., Denton, D.A., Nelson, J., Wright, R.D. & Yamauchi, A. (1969) Ionic histological and vascular factors in the reaction of the sheep parotid to high and low mineralocorticoid status. Journal of Physiology 205, 563-579.

Bloom, G.D. & Carlsoo, B. (1974) Fine structure and peroxidase activity of the bovine mandibular gland cells. Zentralblatt fur veterinarmedizin C, 308-323.

Butler, J.E. (1981) The Ruminant Immune System. In: Advances in Experimental Medicine and Biology Vol. 137. Plenum Press, New York.

- Cantin, M. & Veilleux, R. (1972) Globule leukocytes and mast cells of the urinary tract in magnesium deficient rats. A cytochemical and electron microscopic study. Laboratory Investigation Vol. 27, 495-507.
- Castro, G.A. (1982) Immunological regulation of epithelial function. American Journal of Physiology Vol. 243, No. 5, G321-G329.
- Church, D.C. (1976) "Digestive Physiology and Nutrition of Ruminants". Vol. 1, 2nd Ed. Church (publishers)
- Clamp, J.R. (1981) The role of mucous secretions in the protection of the gastrointestinal mucosa. In: The Mucosal Immune System. Current topics in Veterinary Medicine and Animal Science Vol. 12. Martinus Nijhoff (publishers).
- Clarke, R.T.J. & Reid, C.S.W. (1974) Foamy Bloat of Cattle. A Review. Journal of Dairy Science 57, part 2, 753-785.
- Coats, D.A., Denton, D.A., Goding, J.R. and Wright, R.D. (1956) Secretion by the parotid gland of the sheep. Journal of Physiology 131, 13-31.
- Collan, Y. (1972) Characteristics of nonepithelial cells in the epithelium of normal rat ileum: a light and electron microscopic study. Scandinavian Journal of Gastroenterology 7, supplement 18, 1-66.
- Compton, J.S., Nelson, J., Wright, R.D. & Young, J.A. (1980) A micropuncture investigation of electrolyte transport in the parotid glands of sodium-replete and sodium-depleted sheep. Journal of Physiology 309, 429-446.
- Cook, D.I. & Young, J.A. (1981) Solution of epithelial cell models for secretion and absorption using

- optimization routines. In: Saliva and salivation.
ed. Zellas, T. 73-78. Pergamon, Oxford.
- Creeth, J.M., Bridge, J.L. & Horton, J.R. (1979) An interaction between lysozyme and mucus glycoproteins. Biochemical Journal 181, 717-724.
- Cripps, A.W. & Lascelles, A.K. (1976) The origin of immunoglobulins in salivary secretion of sheep. Australian Journal of Experimental Biology and Medical Science 54, 191-195.
- Culling, C.F.A. (1974) "Handbook of Histopathological and Histochemical Techniques." 3rd Ed. Butterworths.
- Diamond, J.M. & Bossert, W.H. (1967) Standing-gradient osmotic flow. A mechanism for coupling of water and solute transport in epithelia. Journal of General Physiology 50, 2061-2083.
- Dobbins, W.O. (1982) Gut immunophysiology: a gastroenterologist's view with emphasis on pathophysiology. American Journal of Physiology Vol. 242, No.1, G1-G8.
- Dobson, C. (1966) Studies on the immunity of sheep to *Oesophagostomum columbianum*: the nature and fate of the globule leucocyte. Australian Journal of Agricultural Research 17, 955-966.
- Emery, T. (1980) Iron deprivation as a biological defence mechanism. Nature 287, 776-777.
- Emmelin, N. (1967) Nervous control of salivary glands. In: Handbook of Physiology. Section 6, Vol. 2 595-632. American Physiological Society.
- Emmelin, N. (1971) Control of salivary glands. In: Oral Physiology. ed. Emmelin, N. & Zotterman, Y.

Pergamon Press.

- Finn, J.P. & Schwartz, L.W. (1972) A neoplasm of globule leucocytes in the intestine of a cat. Journal of Comparative Pathology 82, 323-326.
- Frizzell, R.A., Field, M. & Schultz, S.G. (1979) Sodium-coupled chloride transport by epithelial tissues. American Journal of Physiology 236, F1-F8.
- Garrett, J.R. & Emmelin, N. (1979) Activities of salivary myoepithelial cells: a review. Medical Biology 57, 1-28.
- Getty, R. (1975) "The Anatomy of the Domestic Animals." Vol. 1, 5th Ed. W.B. Saunders Co., Philadelphia.
- Gregg, P., Dineen, J.K., Rothwell, T.L.W. & Kelly, J.D. (1978) The effect of age on the response of sheep to vaccination with irradiated *Trichostrongylus colubriformis* larvae. Veterinary Parasitology 4, 35-48.
- Gregory, M.W. (1979) The globule leukocyte and parasitic infection - a brief history. The Veterinary Bulletin 49, No. 11, 821-827.
- Gurnsey, M.P., Jones, W.T. & Reid, C.S.W. (1976) Saliva responses to mechanical and drug stimuli in cattle of contrasting susceptibility to bloat. New Zealand Medical Journal 84, 202-206. (Abstract).
- Gurnsey, M.P., Reid, C.S.W., Jones, W.T. & Birtles, M.J. (1977) Salivary glands, total salivary flow rate and susceptibility to bloat. New Zealand Medical Journal 86, 449. (Abstract).
- Guy-Grand, D., Griscelli, C. & Vassali, P. (1978) The mouse gut T lymphocyte, a novel type of T cell:

nature, origin and traffic in mice in normal and graft-versus-host conditions. Journal of Experimental Medicine 148, 1661-1677.

Habel, R.E. (1975) "Guide to the dissection of domestic ruminants." 3rd Ed. Published by R.E. Habel, Ithaca, New York, 14850.

Haig, D.M., McKee, T.A., Jarrett, E.E.E., Woodbury, R. & Miller, H.R.P. (1982) Generation of mucosal mast cells is stimulated *in vitro* by factors derived from T cells of helminth-infected rats. Nature 300, No. 5888, 188-190.

Ham, A.W. & Cormack, D.H. (1979) "Histology" 8th Ed. J.B. Lippincott Co.

Herp, A., Wu, A.M. & Moschera, J. (1979) Current concepts of the structure and nature of mammalian salivary mucous glycoproteins. Molecular and Cellular Biochemistry, Vol. 23, No. 1, 27-44.

Heidenhain, R. (1878). Ueber secretorische und trophische Drüsennerven. Cited in "The Morphology of Salivary Glands." by Young, J.A. and van Lennep, E.W. Academic Press.

Herzog, V. (1981) Endocytosis in Secretory cells. Philosophical Transactions of the Royal Society, London. B296, 67-72.

Hill, A. (1980) Salt-water coupling in leaky epithelia. Journal of Membrane Biology 56, 177-182.

Hoffman, H., McAuslan, B., Robertson, D. & Burnett, E. (1976) An endothelial growth-stimulating factor from salivary glands. Experimental Cell Research 102, 269-275.

- Jones, W.T., Gurnsey, M.P., Birtles, M.J. & Reid, C.S.W. (1977) Salivary proteins of Cattle. Proceedings of the N.Z. Physiology Society, Abstract, N.Z. Medical Journal, 450.
- Jones, W.T., Broadhurst, R.B., Gurnsey, M.P. (1982) Partial characterisation of bovine salivary proteins by electrophoretic methods. Biochimica et Biophysica Acta, 701, 382-388.
- Kay, R.N.B. (1958) Continuous and reflex secretion by the parotid gland in ruminants. Journal of Physiology, 144, 463-475.
- Kay, R.N.B. (1960) The rate of flow and composition of various salivary secretions in sheep and calves. Journal of Physiology 150, 515-537.
- Kay, R.N.B. (1966) The influence of saliva on digestion in ruminants. World Review of Nutrition and Dietetics, Vol. 6, 292-235.
- Kay, R.N.B. & Phillipson, A.T. (1959) Responses of the salivary glands to distension of the oesophagus and rumen. Journal of Physiology 148, 507-523.
- Kellas, L.M. (1961) An intraepithelial granular cell in the uterine epithelium of some ruminant species during the pregnancy cycle. Acta Anatomica 44, 109-130.
- Kent, J.F. (1952) The origin, fate and cytochemistry of the globule leucocyte of sheep. Anatomical Record 112, 91-115.
- Kent, J.F. (1966) Distribution and fine structure of globule leucocytes in respiratory and digestive tracts of the laboratory rat. Anatomical Record, 156, 439-454.

- Kim, S.K., Nasjleti, C.E. & Han, S.S. (1972) The secretion processes in mucous and serous secretory cells of the rat sublingual gland. Journal of Ultrastructural Research 38, 371-389.
- Kitagawa, H., Ogata, K., Sugimura, M., Hashimoto, Y. & Kudo, N. (1979) Thymus origin of globule leucocytes in chicken. Japanese Journal of Veterinary Research 27, 16-18.
- Lawrence, J.A. (1977) The globule leucocyte in bovine schistosomiasis. Research in Veterinary Science 23, 239-240.
- Leeman, S.E. & Hammerschlag, R. (1967) Stimulation of salivary secretion by a factor extracted from hypothalamic tissue. Endocrinology 81, 803-810.
- Leeson, C.R. (1967) Structure of salivary glands. In: Handbook of Physiology Section 6, Volume 2. American Physiological Society.
- Lindley, M. (1980) Adhesion of pathogenic microorganisms. Nature 286, 556-557.
- Ludwig, G. (1851) Neue versuche uber die beihilfe der nerven zur speichelabsonderung. Cited in: Handbook of Physiology Chapter 35, Section 6, Volume 2. American Physiological Society.
- Mach, J.P. and Pahud, J.J. (1971) Secretory IgA, a major immunoglobulin in most bovine external secretions. Journal of Immunology 106, 552-563.
- Mayrhofer, G., Bazin, H. and Gowans, J.L. (1976). Nature of cells binding anti-IgE in rats immunized with *Nippostrongylus brasiliensis*. IgE synthesis in regional nodes and concentration in mucosal mast cells. European Journal of Immunology 6, 537-545.

- Mayrhofer, G. (1980) Fixation and staining of granules in mucosal mast cells and intraepithelial lymphocytes in the rat jejunum, with special reference to the relationship between the acid glycosaminoglycans in the two cell types. Histochemical Journal 12, 513-526.
- McIntosh, J.T. (1975) The components of bovine saliva in relation to bloat. Proceedings of the N.Z. Society of Animal Production Vol. 35, 29-34.
- McIntosh, J.T. & Cockrem, F.R.M. (1977) Preliminary results from saliva samples from cows of high and low bloat susceptibility. N.Z. Journal of Agricultural Research 20, 263-268.
- Miller, H.R.P. (1980) The structure, origin and function of mucosal mast cells, a brief review. Biologie Cellulaire 39, 229-232.
- Morales, C.R., Pereyra, L.A., Toledo, O.M.S & Montes, G.S. (1980) Histochemical and morphological characterisation of migrating mast cells in the bovine gall-bladder epithelium. Histochemistry 68, 159-168.
- Mowat, A.M. & Fergusson, A. (1981) Induction and expression of cell mediated Immunity. In: The Mucosal Immune System. Current topics in Veterinary Medicine and Animal Science Vol. 12. Martinus Nijhoff (Publisher)
- Munger, B.L. (1964) Histochemical studies on seromucous and mucous secreting cells of human salivary glands. American Journal of Anatomy 115, 411-429.
- Murray, M., Miller, H.R.P. and Jarrett, W.F.H. (1968) The globule leucocyte and its derivation from the sub-epithelial mast cell. Laboratory Investigation 19, 222-234.

- Nickel, R., Schummer, A., Seiferle, E. & Saek, W.O. (1973) "The Viscera of the Domestic Mammals." Verlag Paul Parey, Berlin, Hamburg.
- Novikoff, P.M., Novikoff, A.B., Quintana, N. & Hauw, J.J. (1971) Golgi apparatus, GERL and lysosomes of neurons in rat dorsal root ganglia studied by thick section and thin section cytochemistry. Journal of Cell Biology 50, 859-886.
- Ørstavik, T.B. & Gautvik, K.M. (1977) Regulation of salivary kallikrein secretion in the rat submandibular gland. Acta Physiologica Scandinavia 100, 34-44.
- Pal, C., Chandra, G. & Bharadwaj, M.B. (1972) Histological and certain histochemical observations on the parotid salivary gland of buffalo (*Bubalus bubalis*). Indian Journal of Animal Science 42(5), 420-426.
- Pal, C. & Chandra, G. (1979) Histochemistry of mucins in the submaxillary salivary gland of buffalo (*Bubalus bubalis*). Acta Anatomica 103, 336-343.
- Palade, G.E. (1975) Intracellular aspects of the process of protein synthesis. (Nobel Prize Lecture, Stockholm, 1974). Science (Washington D.C.) Vol. 189, 347-358.
- Pamer, T., Jerzy Glass, G.B. & Horowitz, M.I. (1968). Purification and characterisation of sulfated glycoproteins and hyaluronidase resistant mucopolysaccharides from dog gastric mucosa. Biochemistry Vol. 7, No. 11, 3821-3829.
- Patterson, J. & Titchen, D.A. (1979) Sympathetic and β -adrenergic stimulation of parotid salivary secretion in sheep. Quarterly Journal of Experimental Physiology 64, 175-184.

- Patterson, J., Brightling, P. & Titchen, D.A. (1982) β -adrenergic effects on composition of parotid salivary secretion of sheep on feeding. Quarterly Journal of Experimental Physiology 67, 57-67.
- Petersen, O.H. (1980) "Electrophysiology of Gland Cells." Academic Press, London.
- Phillipson, A.T. & Mangan, J.L. (1959) Bloat in cattle. 16. Bovine saliva: the chemical composition of the parotid, submaxillary and residual secretions. N.Z. Journal of Agricultural Research 2, 990-1001.
- Pinkstaff, C.A. (1980) The cytology of salivary glands. International Review of Cytology 63, 141-261.
- Polak, J.M. & Bloom, S.R. (1980) Neuropeptides in salivary glands. The Journal of Histochemistry and Cytochemistry 28, No. 8, 871-873.
- Quintarelli, G. (1963a) Histochemical identification of salivary mucins. Annals of the New York Academy of Science 106, 339-363.
- Quintarelli, G. (1963b) Masking action of basic proteins on sialic acid carboxyls in epithelial mucins. Experientia 19, 230-231.
- Quintarelli, G., Tsuiki, S., Hashimoto, Y. & Pigman, W. (1960) Histochemical studies of bovine salivary gland mucins. Biochemical and Biophysical Research Communications Vol. 2 No. 6, 423-426.
- Reid, C.S.W., Gurnsey, M.P., Waghorn, G.C. & Jones, W.T. (1975) Progress in identifying sources of animal variation in susceptibility to bloat. Proceedings of the N.Z. Society of Animal Production 35, 13-19.

- Reid, L. & Clamp, J.R. (1978) The biochemical and histochemical nomenclature of mucus. British Medical Bulletin 34, No.1, 5-8.
- Rhako, T. (1972) Studies on the pathology of dicrocoeliasis and fascioliasis in the goat. III. The histochemistry of mast cells and globule leucocytes. Acta Veterinaria Scandinavia 13, 575-584.
- Rudzik, O. & Bienenstock, J. (1974) Isolation and characteristics of gut mucosal lymphocytes. Laboratory Investigation 30, 260-266.
- Ruitenbergh, E.J. & Elgersma, A. (1979) Response of intestinal globule leucocytes in the mouse during a *Trichinella spiralis* infection and its independence of intestinal mast cells. British Journal of Experimental Pathology 60, 246-251.
- Schneyer, C.A. & Schneyer, L.H. (1960) Electrolyte levels of rat salivary secretions in relation to fluid flow rate. American Journal of Physiology 199, 55-58.
- Schneyer, L.H. & Schneyer, C.A. (1967) Inorganic composition of saliva. In: Handbook of Physiology Section 6 Vol. 2. American Physiological Society.
- Schneyer, L.H., Young, J.A. & Schneyer, C.A. (1972) Salivary secretion of electrolytes. Physiological Reviews 52, No. 3, 720-777.
- Schneyer, L.H. & Emmelin, N. (1974) Salivary secretion. In: Gastro-intestinal Physiology. M.T.P. International Review of Science Vol. 4, 183-226. Butterworths, London.
- Shackleford, J.M. (1963) Histochemical comparison of mucous secretions in rodent, carnivore, ungulate

and primate major salivary glands. Annals of New York Academy of Science 106, 572-582.

Shackelford, J.M. (1969) Ultrastructural evidence for the water transport mechanism in bovine parotid glands. Journal of Ultrastructural Research 29, 578.

Shackelford, J.M. & Klapper, C.E. (1962) Structure and carbohydrate histochemistry of mammalian salivary glands. American Journal of Anatomy 111, 25-48.

Shackelford, J.M. & Wilborn, W.H. (1968) Structural and histochemical diversity in mammalian salivary glands. Alabama Journal of Medical Science 5, 181-203.

Shackelford, J.M. & Wilborn, W.H. (1969) Ultrastructure of bovine parotid glands. Journal of Morphology 127, 453-474.

Shackelford, J.M. & Wilborn, W.H. (1970) Ultrastructural aspects of calf submandibular glands. American Journal of Anatomy 127, 259-280.

Shreeve, W.W. (1974) "Physiological chemistry of carbohydrates in mammals." W.B. Saunders Co., Philadelphia.

Sternberger, L.A. (1974) "Immunocytochemistry." Prentice-Hall, New York.

Strober, W. (1982) The regulation of mucosal immune system. The Journal of Allergy and Clinical Immunology Vol. 70 No. 4, 225-230.

Takeuchi, A., Jervis, H.R. & Sprinz, H. (1969) The globule leucocyte in the intestinal mucosa of the cat: a histochemical, light and electron microscopic study. Anatomical Record 164, 79-99.

- Tandler, B. & Poulsen, J.H. (1976) Fusion of the envelope of mucous droplets with the luminal plasma membrane in acinar cells of the cat submandibular gland. Journal of Cell Biology 68, 775-781.
- Tandler, B. & Poulsen, J.H. (1977) Ultrastructure of the cat sublingual gland. Anatomical Record 187, 153-159.
- Thaysen, J.H., Thorn, N.A. & Schwartz, I.L. (1954) Excretion of sodium, potassium, chloride and carbon dioxide in human parotid saliva. American Journal of Physiology 178, 155-159.
- Tomasi, T.B. (1976) "The Immune System of Secretions." Foundations of Immunology series. Prentice-Hall, Inc.
- Tomasi, T.B., Larson, L., Challacombe, S. & McNabb, P. (1980) Mucosal Immunity: The origin and migration patterns of cells in the secretory system. The Journal of Allergy and Clinical Immunology Vol. 65, No. 1, 12-19.
- Toner, P.G. (1965) The fine structure of the globule leucocyte in the fowl intestine. Acta Anatomica 61, 321-330.
- van Lennep, E.W., Kennerson, A.R. & Compton, J. (1977) The ultrastructure of the sheep parotid gland. Cell Tissue Research 179, 377-392.
- van Venrooij, W.J., Kuijper-Lenstra, A.H. & Kramer, M.F. (1973) Interrelationship between amino acid pools and protein synthesis in the rat submandibular gland. Biochimica et Biophysica Acta 312, 392-398.
- Vandenbergh, M.P. & Baert, J. (1981) Globule leucocytes in the tracheal epithelium of rats. Acta Anatomica 111, 268-276.

- Vignoli, V.V. & Nogueira, J.C. (1981) Histology and mucosubstance histochemistry of the parotid gland in suckling, prepuberal and puberal Zebus (*Bos indicus*). Zentralblatt fur veterinarmedizin C, 10, 147-158.
- Walter, J.B. & Israel, M.S. (1979) "General Pathology", 5th Ed. Churchill Livingstone, London.
- Watson, D.L. & Lascelles, A.K. (1971) IgA in the body fluids of sheep and cattle. Research in Veterinary Science 12, 503-507.
- Watson, D.L. & Lascelles, A.K. (1973) Comparisons of immunoglobulin secretion in the salivary and mammary secretions of ewes. Australian Journal of Experimental Biology and Medical Science 51, 255-258.
- White, R.G. (1954) Observations on the formation and nature of Russell bodies. British Journal of Experimental Pathology 35, 365-376.
- Whur, P. (1966) Relationship of globule leucocytes to gastrointestinal nematodes in the sheep and *Nippostrongylus brasiliensis* and *Hymenolepis nana* infections in rats. Journal of Comparative Pathology 76, 57-65.
- Whur, P. & Johnston, H.S. (1967) Ultrastructure of globule leucocytes in immune rats infected with *Nippostrongylus brasiliensis* and their possible relationship to the Russell body cell. Journal of Pathology and Bacteriology 93, 81-85.
- Whur, P. & White, R.G. (1970) Fluorescence microscopy of the small intestines of rats and sheep, with reference to the presence of immunoglobulin in globule leucocytes. International Archives of Allergy and Applied Immunology 38, 185-195.

Young, J.A. & van Lennep, E.W. (1978) "The Morphology of Salivary Glands." Academic Press, London.

Young, J.A. & van Lennep, E.W. (1979) "Transport in salivary and salt glands." In: Membrane Transport in Biology, Volume 4B. 563-674. Springer, Berlin, Heidelberg, New York.