

Copyright is owned by the Author of the thesis. Permission is given for a copy to be downloaded by an individual for the purpose of research and private study only. The thesis may not be reproduced elsewhere without the permission of the Author.

SOLE ASPECTS OF  
THE VAGAL INNERVATION OF THE CANINE ESOPHAGUS  
AN ANATOMICAL STUDY

by

Alastair Gordon Watson  
B.Agr.Sc. (Cantuar)

A thesis presented in partial fulfilment of the requirements for  
the Degree of Master of Agricultural Science in Animal Science  
at Massey University.

1974

## ABSTRACT

The anatomical disposition of the branches from the vagus nerves to the entire canine esophagus were investigated and the effects of various nerve transections on esophageal function were observed radiographically.

Twenty one adult mongrel dogs were carefully dissected; fourteen were dissected as fresh specimens and seven were formalin embalmed and dissected later. Ten of these dogs had previously undergone various surgical nerve transections: bilateral pharyngoesophageal neurectomy, bilateral cranial thoracic vagotomy, transection of recurrent laryngeal nerves at their origins, double bilateral cranial thoracic vagotomy, and caudal thoracic vagotomies. The surgical approaches for transection of these esophageal nerves have been investigated and the various techniques are described.

Esophageal function before and after nerve transection was studied radiographically, especially by cineradiography; all radiographs were made on conscious dogs, trained to stand in a normal position freely eating barium impregnated meal from a bowl placed immediately in front of their forepaws. Radiographic observations on esophageal motility were made on fifteen additional apparently normal dogs.

Contrary to standard texts, it was found in the present study that each parent recurrent laryngeal nerve was always divided into two trunks: the recurrent laryngeal nerve proper which coursed directly to and terminated in the ipsilateral intrinsic laryngeal muscles (excluding cricothyroideus), and a more dorsally lying pararecurrent laryngeal nerve which coursed parallel to the

recurrent proper but freely supplied many branches to the esophagus and trachea. These esophageal branches were especially numerous on the left side, as the left pararecurrent nerve richly supplied the cranial thoracic esophagus as well as the cervical portion. However, the right pararecurrent nerve supplied the cervical esophagus only. Each pararecurrent nerve then terminated in the anastomotic ramus from the internal branch of the ipsilateral cranial laryngeal nerve.

From the experimental studies it was concluded that the recurrent laryngeal nerves were functionally involved with the cranial thoracic esophagus, since this region was completely paralysed following bilateral recurrent laryngeal neurectomy. Some dysfunction was also seen in the cervical esophagus after this operation.

The cervical esophagus was primarily innervated and functionally controlled by the pair of pharyngoesophageal nerves which arose solely from the pharyngeal branch of each vagus nerve.

Caudal to the origins of the recurrent nerves, the thoracic and abdominal vagi supplied and controlled the caudal thoracic and abdominal portions of the esophagus.

The vagus nerves innervate and are involved in the normal function of the gastroesophageal junction, since bilateral cranial thoracic vagotomy considerably altered the activity of this region. However, double caudal thoracic vagotomy appeared only slightly to affect the function of the gastroesophageal junction.

In addition, the course and the histological structure of the canine esophagus has been observed and described.

During this study, radiographic observations were repeatedly made, on apparently normal dogs, that put in question the validity of the currently held concepts of esophageal physiology. Propulsive esophageal contraction waves did not necessarily directly follow each oropharyngeal deglutition sequence. Swallowed boluses were frequently delayed in the cranial cervical, thoracic inlet, and cranial thoracic regions of the esophagus. Twenty two of the twenty five apparently normal dogs examined, exhibited significant reflux of material from the stomach into the caudal thoracic esophagus. More detailed radiographic studies of the normal canine esophagus under truly physiological conditions are required.

## ACKNOWLEDGEMENTS

The opportunity for this study arose through the encouragement of Mr.D.A.Dowd and Dr.B.E.Goulden, and the generous provision of facilities by the Departments of Physiology and Anatomy, and Veterinary Clinical Sciences at Massey University. I am greatly indebted to my two supervisors for their guidance and constant interest.

I would like to extend my sincere gratitude to Mr.J.C.Newhook for his helpful advice in the production of this thesis and for his constructive criticism during the course of this study. Thanks are due to Mr.J.D.Lundy for his great help during the early stages by correcting the draft copy. I am also grateful to Mr.L.S.Wyburn and Mrs.L.R.Hofe for their assistance in operating the radiographic equipment and interpreting the radiographs, to Mr.H.J.Birtles for preparing the histological material, to Mr.B.P.O'Sullivan and Mr.M.Ratunaitavuki for cubalming the dogs, to Mr.J.D.Austin and Mr.T.G.Law for the preparation of photographs, to Dr.D.E.Dowd for drawing Figures 19b and 23b, to Mrs.H.McComish for labelling the diagrams, and to Dr.H.E.Batten for his comments on Appendix II. Thanks are also due to the Massey University library staff, especially Miss E.K.Green for obtaining many of the references.

My sincere thanks are due to Miss Sue Shirriffs for her patience and careful typing of the thesis.

I am particularly indebted to Maung Sha Ban for his friendship, great interest and valuable encouragement throughout this study, and to my wife Jenny, for her willingness to accompany me on this long, often trying, but always interesting, road.

# TABLE OF CONTENTS

Page

ABSTRACT

ACKNOWLEDGEMENTS

TABLE OF CONTENTS

LIST OF FIGURES

<u>INTRODUCTION</u> .....	1
<u>MATERIALS AND METHODS</u> .....	3
Experimental Method .....	3
Experimental Animals .....	3
Dissection Techniques .....	4
Embalming and Specimen Preparation .....	5
Experimental Groups .....	7
Surgical Techniques .....	8
Radiographic Techniques .....	10
Photographic Techniques .....	12
Nutrition .....	13
Post Mortem Technique .....	13
Histological Techniques .....	14
<u>RESULTS</u> .....	16
Anatomical Observations .....	16
Pharyngoesophageal nerves .....	16
Recurrent laryngeal nerves .....	20
right .....	21
left .....	24
Thoracic vagus nerves .....	27
right .....	27
left .....	28
Dorsal and ventral vagal trunks .....	30

	Page
Radiographic Observations .....	32
Normal dogs .....	32
After bilateral pharyngoesophageal neurectomy .....	32
After bilateral cranial thoracic vagotomy .....	33
After recurrent laryngeal neurectomies .....	35
After double bilateral cranial thoracic vagotomy ....	38
After caudal thoracic vagotomies .....	40
Clinical Observations .....	41
Laryngeal function .....	41
Eating behaviour .....	41
Post Mortem Observations .....	44
Neurectomy site .....	44
Esophageal dilatation .....	44
Nerve degeneration histology .....	45
<u>DISCUSSION</u> .....	46
Structural Considerations .....	47
Cervical esophagus .....	47
Cranial thoracic esophagus .....	51
Pararecurrent laryngeal nerves .....	52
Caudal thoracic and abdominal esophagus .....	54
Embryonic development .....	55
Functional Considerations .....	60
Methods of study .....	60
Cervical esophagus .....	62
Cranial thoracic esophagus .....	65
Thoracic and abdominal esophagus .....	67
Normal esophageal motility .....	70
<u>SUMMARY</u> .....	72
 <u>APPENDIX I</u>	
Course of the Canine Esophagus .....	74

## APPENDIX II

Structure of the Canine Esophagus .....	78
---	----

## APPENDIX III

Surgical Techniques for Experimental Neurectomies .....	87
---	----

## APPENDIX IV

Schedule of Postoperative Examination Days .....	93
--	----

## APPENDIX V

Histological Staining Techniques .....	94
--	----

FIGURES .....	95
---------------	----

REFERENCES .....	128
------------------	-----

## PUBLISHED WORK

Watson, A.G. (1973). Structure of the canine oesophagus.

## LIST OF FIGURES

Figure	Page
1. Photograph, radiographic equipment .....	95
2. Diagram, vagal nerve branches to esophagus .....	96
3. Diagram, pharyngoesophageal nerve .....	97
4. Diagram, origin of pharyngoesophageal nerve, common pattern .....	98
5. Diagram, origin of pharyngoesophageal nerve, variant ...	98
6. Diagram, right pararecurrent and recurrent laryngeal nerves .....	99
7. Diagram, left pararecurrent and recurrent laryngeal nerves .....	100
8. Diagram, origin of left recurrent laryngeal nerves, single origin .....	101
9. Diagram, origin of left recurrent laryngeal nerves, multiple origin .....	101
10. Transverse section of recurrent laryngeal nerves, common nerve sheath .....	102
11. Transverse section of recurrent laryngeal nerves, separate nerve trunks .....	102
12. Diagram, vagal nerve branches to thoracic esophagus ....	103
13. Diagram, vagal nerve branches to thoracoabdominal esophagus, right side .....	104
14. Diagram, vagal nerve branches to thoracoabdominal esophagus, left side .....	105
15. Radiograph, cervical esophagus of dog O5, before neurectomy .....	106

Figure	Page
16. Radiograph, cervical esophagus of dog 05, two days after bilateral pharyngoesophageal neurectomy .....	106
17. Radiograph, thoracic esophagus of dog 05, two days after bilateral pharyngoesophageal neurectomy .....	107
18. Radiograph, cervical esophagus of dog 05, nine days after bilateral pharyngoesophageal neurectomy .....	107
19a. Radiograph, thoracic esophagus of dog 06, one day after bilateral cranial thoracic vagotomy .....	108
19b. Diagram of the above radiograph .....	108
20. Radiograph, caudal thoracic esophagus of dog 06, one day after bilateral cranial thoracic vagotomy .....	109
21. Radiograph, cranial thoracic esophagus of dog 06, one day after bilateral cranial thoracic vagotomy .....	109
22. Radiograph, gastroesophageal junction of dog 06, one day after bilateral cranial thoracic vagotomy .....	110
23a. Radiograph, thoracoabdominal esophagus of dog 10, one day after bilateral cranial thoracic vagotomy .....	111
23b. Diagram of the above radiograph .....	111
24. Radiograph, thoracic inlet of dog 15, before neurectomy	112
25. Radiograph, cranial thoracic esophagus of dog 15, before neurectomy .....	112
26. Radiograph, cervical esophagus of dog 15, one day after right recurrent laryngeal neurectomy .....	113
27. Radiograph, cervical esophagus of dog 14, one day after right recurrent laryngeal neurectomy .....	113
28. Radiograph, cervical esophagus of dog 14, one day after right recurrent laryngeal neurectomy .....	114

Figure	Page
29. Radiograph, cervical esophagus of dog 14, one day after right recurrent laryngeal neurectomy .....	114
30. Radiograph, cranial thoracic esophagus of dog 14, eight days after bilateral recurrent laryngeal neurectomy	115
31. Radiograph, cervicothoracic esophagus of dog 14, eight days after bilateral recurrent laryngeal neurectomy	115
32. Radiograph, cranial thoracic esophagus of dog 14, eight days after bilateral recurrent laryngeal neurectomy	116
33. Radiograph, cranial thoracic esophagus of dog 14, eight days after bilateral recurrent laryngeal neurectomy	116
34. Radiograph, cranial thoracic esophagus of dog 14, eight days after bilateral recurrent laryngeal neurectomy	117
35. Radiograph, cervicothoracic esophagus of dog 15, eight days after bilateral recurrent laryngeal neurectomy	117
36. Radiograph, thoracic esophagus of dog 12, two days after bilateral cranial thoracic vagotomy .....	118
37. Radiograph, thoracoabdominal esophagus of dog 04, before neurectomy, no reflux .....	119
38. Radiograph, thoracoabdominal esophagus of dog 04, before neurectomy, reflux .....	119
39. Radiograph, thoracoabdominal esophagus of dog 04, fifteen days after double trunk caudal thoracic vagotomy .....	120
40. Radiograph, thoracoabdominal esophagus of dog 04, fifteen days after double trunk caudal thoracic vagotomy .....	120
41. Radiograph, thoracoabdominal esophagus of dog 02, four days after dorsal trunk caudal thoracic vagotomy ..	121

Figure	Page
42. Radiograph, thoracoabdominal esophagus of dog 02, fourteen days after double trunk caudal thoracic vagotomy .....	121
43. Photograph, dilated esophagus of dog 10, thirty one days after bilateral cranial thoracic vagotomy .....	122
44. Transverse section of recurrent laryngeal nerves, normal .....	123
45. Transverse section of recurrent laryngeal nerves, postneurectomy, degenerative changes .....	123
46. Transverse section of esophageal epithelium .....	124
47a. Transverse section of esophagus .....	125
47b. Diagram of the above section .....	125
48a. Longitudinal section of gastroesophageal junction .....	126
48b. Diagram of the above section .....	127

INTRODUCTION

In 1838 Reid demonstrated that the vagus nerves were involved in canine esophageal function. It was not until 1899 however, that Meltzer's study pioneered critical investigations into the physiology of this organ in the dog.

An extensive and accurate anatomical description of the esophageal innervation in the dog was provided by Chauveau in 1891. The basis of Chauveau's work was that the cervical portion of the esophagus was supplied by the esophageal branch from the paired pharyngeal nerves, a large unnamed branch descending from the paired cranial laryngeal nerves, and the paired recurrent laryngeal nerves. The cranial portion of the thoracic esophagus was supplied by the proximal parts of the recurrent laryngeal nerves and the thoracic vagi. The remaining thoracic and abdominal portions were supplied by the thoracic and abdominal vagi respectively.

Another major contribution to our knowledge on canine esophageal innervation was presented by Lemere (1932a, 1932b, 1933) who described the fibre type and distribution of the nerves to the cervical and cranial thoracic portions of the canine esophagus. He also gave the name, pararecurrent, to the second recurrent laryngeal nerve which had been recorded previously by Chauveau.

In more recent times Hwang and his coworkers (Hwang, 1953; Hwang, 1954; Hwang et al., 1947; Hwang et al., 1949) carried out many detailed experiments on canine esophageal motility and have greatly contributed to our knowledge in this field. In 1948 they described the motor supply to the cervical esophagus through the

pharyngoesophageal nerve, a nerve that had been described by Chauveau and others under different names.

Adequate knowledge of the actual anatomical structure of the canine esophagus has only become available in recent years since Mann and Shorter (1964) described the microscopical anatomy and Miller et al. (1964) recorded the gross and macroscopic details of the esophagus. A short account on the structure of the canine esophagus has been included as Appendix II.

However, despite the recent increase in our knowledge of this structure, many of the results of the previous experimental studies have been equivocal, probably because most workers confined their attention to only one area of the esophagus. In an attempt to overcome this confusion a study of the vagal innervation of the entire canine esophagus was undertaken and the results are presented here.

In this thesis there are many references to the course of the canine esophagus using anatomical terms which need to be clearly defined. For this reason Appendix I which describes the course and defines the regions of the canine esophagus is included. With this information the relationships between the esophagus and adjacent structures become more clearly understood, and thus enable an accurate interpretation of radiological records.

The nomenclature used throughout follows the recommendations of Nomina Anatomica Veterinaria 1968. Nevertheless, some minor modifications have been necessary to accommodate two unlisted but significant nerve branches.

## MATERIALS AND METHODS

### Experimental Method:

This study was designed to investigate the anatomical disposition of the branches from the vagus nerves to the entire canine esophagus and to observe the effects of nerve transection on esophageal function

Initially, careful dissections were made of a number of cadavers to study the nerve supply to the esophagus and, when this was established, functional studies were initiated. These comprised transections of various nerves which appeared to innervate significant portions of the esophagus, and radiographic observations of the consequent effects. When these studies were completed, the dogs were destroyed and their esophageal nerves examined.

### Experimental Animals:

Thirty seven (37) dogs were used for the study.

The animals were cross-breds, of both sexes, in good health, and between one and six years old.

Eleven adult dogs (7 males and 4 females) were examined in the preliminary dissections: four (3 males and 1 female) had been embalmed and seven (4 males and 3 females) were fresh specimens.

Eleven other adult dogs (9 males and 2 females) were used in the nerve transection experiments. An initial experiment to investigate the various surgical approaches was undertaken on one male dog. The remaining ten animals were arranged in five experimental groups of two dogs each: Group I, two males;

Group II, two males; Group III, two females; Group IV, two males; Group V, two males. When the functional studies were completed these ten dogs were also dissected; three (2 males and 1 female) had been embalmed and seven (6 males and 1 female) were fresh specimens.

Of the above twenty two dogs twenty one (7 embalmed and 14 fresh specimens) were dissected.

Observations on esophageal motility were made on fifteen (15) additional dogs.

#### Dissection Techniques:

The dogs were either dissected immediately they became available or were embalmed and examined later. In each case, a careful and thorough examination was made of all the nerves and their branches which were seen to supply the esophagus.

Particular attention was paid to the vagus nerves and their ramifications throughout the entire length of the esophagus - from their emergence from each occipitotympanic fissure in the base of the cranium, to their divisions on the surface of the stomach.

At the commencement of every dissection the caudal half of each cadaver was discarded after dividing the vertebral column at the third lumbar intervertebral disc, and removing the abdominal viscera distal to the pylorus. The second to thirteenth ribs and the lungs were then cut out and the nerves to the thoracic and abdominal esophagus examined, first from the right and then from

the left side. The ventral neck muscles were next removed so that the nerves supplying the cervical esophagus could be studied. Fine dissections were made of the origin and distribution of the recurrent laryngeal and pharyngoesophageal nerves. The esophagus, stomach, trachea and diaphragm remained intact for most of the dissection, and the first pair of ribs were left in situ as fixed points of reference.

Small nerve branches were examined under a Leitz binocular dissecting microscope, using eyepieces and objectives with a combined total magnification of 3.5X. Numerous photographs were taken and sketches made at various stages throughout the dissection.

#### Embalming and Specimen Preparation:

The seven embalmed specimens were prepared in the following manner: the dogs were anaesthetised with intravenous pentobarbitone sodium and then exsanguinated using the common carotid or the femoral artery. Each cadaver was then infused through this same vessel with an aqueous solution containing 6.4% formaldehyde and 4.0% phenol and after embalming was stored in a cool room at four degrees Celsius for three to ten weeks until dissected.

However these embalmed cadavers were stiff and dried out rapidly. They had an unpleasant odour and the high formaldehyde level was irritating to the dissector. Tissues and organs showed poor colour contrast and were unrealistic in appearance.

It was often difficult to distinguish between the fibrous connective tissue and the small nerves, particularly when connective

tissue and fascia remained firmly adherent to adjacent structures. Local applications of ethyl alcohol whitened the nerves and at the same time brought about their rapid dehydration. This problem was in part overcome by the use of a weak solution of acetic acid which softened and partially dissolved the connective tissue. But the application of these agents was of limited use in embalmed material.

Fourteen dogs were dissected as fresh specimens. When these dogs became available they were anaesthetised with intravenous pentobarbitone sodium and exsanguinated through the femoral artery. Each dissection was completed within forty eight hours.

Ethyl alcohol was applied to some of the smaller nerves and branches to whiten and help distinguish them from the fibrous connective tissue. During the dissection some areas were covered with a weak acetic acid solution to soften and dissolve connective tissue around the nerves. In contrast to its limited usefulness in embalmed cadavers, this treatment of fresh specimens with ethyl alcohol and acetic acid was of considerable benefit in that each of these solutions made for easier and clearer dissections and more accurate identification of nerves.

After gross dissections, the head and neck of six fresh specimens were prepared by a method which was modified from that described by McCrea (1924). Each head and neck was totally immersed for twenty four to forty eight hours in an aqueous solution of: 1.0% picric acid, 1.0% acetic acid, 0.4% formaldehyde, and 5.0% glycerol. Specimens prepared in this way were soft and pliable, the connective tissue could be cleanly and easily dissected through

while the nerves remained as prominent white strands in their gelatinous sheaths. With longer soaking the nerve fibres stained a bright yellow colour. This process was of particular use in helping to distinguish between nerve fibres and fibrous connective tissue found in the vicinity of the distal vagal and the cranial cervical sympathetic ganglia.

Using this technique it was possible to make a detailed examination of the origin of the pharyngoesophageal nerves and, if wrapped in towels moistened with formaldehyde and glycerol, then placed inside a closed plastic bag the specimens could be kept in the cool room for a number of days and still retain their superior appearance over the routinely embalmed cadavers. This treatment was found to be effective on fresh material only.

#### Experimental Groups:

From the pattern of nerve distribution observed in the initial dissections five separate nerve transection experiments were designed. The reference numbers of the dogs in each group are given below in parentheses.

#### Group I : Bilateral pharyngoesophageal neurectomy

Each neurectomy was at the level of the pharyngoesophageal junction so that the nerve branches to the cricopharyngeus muscles were left intact. (03, 05).

#### Group II : Bilateral cranial thoracic vagotomy

Vagotomies were performed immediately caudal to each middle cervical ganglion, and the ~~arm~~ of each ansa subclavia remained intact. (06, 10).

Group III : Recurrent laryngeal neurectomies

The right recurrent laryngeal nerve was transected, and this was followed seven days later by left recurrent laryngeal neurectomy. Both nerves were transected at their origin from the respective vagus nerve. (14, 15).

Group IV : Double bilateral cranial thoracic vagotomy

Two bilateral vagotomies were performed on each dog. The vagi were initially transected immediately distal to the origin of their respective recurrent laryngeal nerves. Seven days later each vagus nerve was again transected, this time immediately proximal to the origin of its respective recurrent laryngeal nerve. (12, 13).

Group V : Caudal thoracic vagotomies

Caudal thoracic vagotomies were performed on two dogs. In one dog both dorsal and ventral vagal trunks were transected in the one operation (02). In the other dog, the operations comprised a dorsal trunk neurectomy followed seven days later by a ventral trunk transection (04).

Surgical Techniques:

Preparation. A bilateral laryngeal ventriculocordectomy was performed on each dog before commencing the functional studies experiment. This was accomplished under thiopentone sodium anaesthesia by using a large Hartmann's nasal conchotome in an oral approach to amputate the vocal folds (Archibald, 1965; Marlow, 1971).

Since no details were available from the literature, it was necessary to investigate various surgical approaches to the nerves that were to be transected, and to develop satisfactory techniques. (These are described in Appendix III). The techniques were developed after a preliminary experiment involving exploratory surgery on one dog not included in the experimental groups.

Anaesthesia. All dogs were fasted for twenty four hours prior to surgery. Preanaesthetic medication was intramuscular atropine sulphate (0.6 mg) and acepromazine maleate (0.15 mg/kg).

Anaesthesia was induced by intravenous thiopentone sodium, followed immediately by intravenous administration of gallamine triethiodide (1.0 mg/kg) to produce adequate muscle relaxation. In two dogs diallyl-bis-nor-toxiferine dichloride (0.05 mg/kg) was used intravenously as an alternative to gallamine triethiodide.

Anaesthesia was maintained with a 50/50 mixture of nitrous oxide and oxygen gases supplemented with halothane vapour (0.5 to 1.0%). In four cases, methoxyflurane replaced halothane.

A circle anaesthetic machine was used to deliver a fresh gas flow of between two and three litres per minute, and ventilation was controlled by a positive pressure cycled respirator.

At the completion of surgery, any residual non-depolarising muscle block was reversed by the intravenous administration of neostigmine methylsulphate in 0.25 mg aliquots. In each case atropine sulphate (0.6 mg) was given intravenously immediately before the initial injection of neostigmine methylsulphate.

Fluid therapy and postoperative medication. Fluid balance during surgery was maintained by intravenous administration of a warmed solution of dextrose saline.

Postoperative pain in the first twenty four hours was controlled by intramuscular pethidine hydrochloride.

Since most dogs exhibited profuse salivation during the immediate postoperative recovery period, up to 7 mg of atropine sulphate was administered intramuscularly within the first twelve hours.

All dogs were injected with a prophylactic intramuscular antibiotic on each of the first three postoperative days.

#### Radiographic Techniques:

Radiography was chosen as the technique to detect any experimentally produced postoperative changes in esophageal motility. The equipment used was a three phase fully rectified Elema-Schonander Triplex Optimatic 1023 unit with automatic dose control, and incorporated a 25 cm diameter image intensifying tube with the fluoroscopic image displayed on a closed circuit television screen. The equipment layout is shown in Figure 1. Plate film, videotape, and cinematographic film (exposed at twelve frames per second) were all used to provide a radiological record of the experiment. Panchromatic 35 mm negative safety film (Kodak-Eastman 4X, type 5224, and Kodak RAR, type 2498) was used for the cineradiological record.

All radiographic observations were on conscious dogs in a normal standing position. Before being admitted to the experiment, the dogs were trained to stand quietly and feed in a normal standing position on the X-ray table. A bowl of barium impregnated food was placed just in front of their forepaws. Radiographs were then taken, some with the head down feeding others with the head up in the normal alert position. A few dogs were also radiographed whilst standing on their hindpaws only, after their bodies were elevated to a near vertical position.

Restraint was always minimal and pharmacological agents were never administered. A leather leash with a loose choker collar was all that was necessary, although in the latter part of the experiment a perspex holding crush was designed and put into use (Fig. 1). The leash with collar was not used when the holding crush was in use.

On each day that records were taken, the dogs were initially screened and then observed and recorded as they ate at will from their food bowls. The impregnated food was made up by mixing a stable dispersion of barium sulphate (95% w/v) with the normal kennel diet until the meal attained the consistency of thick porridge.

Regions of esophageal dysfunction were defined by closely observing interference with the passage of food. Identified vertebrae were used as reference levels whenever possible.

Each dog was radiographed before surgery, as soon as possible after each neurectomy, and then usually twice more during the

following two weeks. One dog was also examined forty five days after surgery. The exact days on which radiographic examination were made on each dog are tabulated in Appendix IV.

The dogs were given no solid food for twenty four hours before being fed the impregnated meal, or for forty eight hours when they were being examined on the first day after surgery.

#### Photographic Techniques:

All the photoradiographs have been so printed that in each case the cranial end of the esophagus lies towards the right side of the photograph

The photographs of radiographic plates have been reproduced in their original negative form viz. the plates were photographed on Ilford Pan F negative 35 mm panchromatic safety film and then printed on positive photographic printing paper.

Although the cineradiographic 35 mm film also recorded a negative image, photographs of frames from the cine-film have been reproduced in their positive form. This was achieved by placing the selected frames in a photographic enlarger and printing on to positive photographic printing paper. Attempts to reproduce frames from the cineradiographs in their original negative form by photographing a projected image with negative film and printing on positive printing paper, resulted in the loss of considerable detail and hence positive reproductions have been used.

All photographic prints were processed on glossy, single weight Ilfobrom IB3.1P or IB4.1P photographic printing paper (Ilford Australia Prop. Ltd. Melbourne).

Nutrition:

The dogs were fed once a day with commercial pet foods. After surgery, each dog was carefully observed for dysphagia and regurgitation, and those with difficulties in eating were given dog meal mixed to a thin consistency with a large quantity of milk. Some others were fed on a liquid diet of milk, glucose, and commercial cereal food. Clean fresh water was provided at all times. Each dog was kept when possible at a relatively constant body weight by daily weight recording with compensating diet changes.

Post Mortem Technique:

During the post mortem examination of all the neurectomised dogs the site of each nerve transection was carefully dissected to verify the site and completeness of the operation. This was in addition to the routine nerve dissection. Histological samples were taken from each nerve distal to the site of transection to examine for postoperative degeneration

The esophagus was also examined for any gross postoperative changes.

### Histological Techniques:

At the time of each nerve transection a short portion was removed for histological processing as a normal control. During the post mortem examination of each experimental dog a similar sample (0.5 to 1.0 cm) was taken distal to the point of transection

All nerve specimens were fixed in 10% formal saline, embedded in paraffin wax and sectioned transversely. From each of the resulting twenty specimens three sections were treated as follows:

(a) One was sectioned at ten micrometers in thickness and stained by Marchi's method for degenerating nerve as modified by Disbrey and Rack (1970). However, no information was available as the results were unsatisfactory, possibly due to adverse factors which Disbrey and Rack (1970) noted with the Marchi method viz:

- i) formal saline fixation prolonged beyond seventy two hours,
- ii) paraffin block processing before dichromate and osmium tetroxide treatments,
- iii) loss of stainable fatty acids from the nerve tissue when Marchi's reaction is applied to individual sections,
- iv) inadequate interval between transection and fixation. Most workers have obtained good results on degenerating nerve removed ten to sixty days after transection but the interval in the present experiment was, in all but two cases, not more than eighteen days.

(b) and (c) Both sections were cut at a thickness of five micrometers and stained with haematoxylin and eosin, and van Gieson's techniques respectively (Culling, 1963). Details of these procedures

are given in Appendix V.

The van Gieson counterstain provided both a sharper colour differentiation of tissues in the nerve trunks and a better contrast for photomicrography than the haematoxylin and eosin.

The sections were examined and photographed under a Leitz Ortholux binocular light microscope with a Leitz Orthomat photographic unit using 10X eye pieces and 4X, 10X, 25X, 40X, and 100X (oil immersion) objectives

## RESULTS

### Anatomical Observations:

From dissections on twenty one dogs it was found that the nerves to the canine esophagus may be conveniently divided into three groups for descriptive purposes:

- i) the right and left pharyngoesophageal nerves,
- ii) the right and left recurrent laryngeal nerves, and
- iii) the right and left vagus nerves distal to the origin of the recurrent laryngeal nerves continuing as the dorsal and ventral vagal nerve trunks.

### Pharyngoesophageal nerves

In every dog, both right and left pharyngoesophageal nerves followed a similar basic pattern of origin and distribution (Figs. 2 and 3).

The pharyngoesophageal nerve always took its origin from the pharyngeal ramus of the vagus nerve (Figs. 4 and 5). In each case, the large pharyngeal ramus of the vagus arose from the cranial pole of the distal vagal ganglion on its ventromedial aspect, or from the interganglionic vagus at a point immediately cranial to the distal ganglion.

In nineteen dogs a conspicuous connection was found between the proximal part of the pharyngeal ramus of the vagus and the more cranially situated glossopharyngeal nerve. This was in the form of either a single large communication or two or three smaller communicating branches. However, in one of the remaining dogs the communication was lacking on the left side, while in the other dog

no vagoglossopharyngeal communication was visible on either side. In these latter two cases the glossopharyngeal nerve was represented by its large lingual ramus and the carotid sinus nerve.

The pharyngeal ramus of the vagus was short and always terminated by dividing into between four and six main branches. The most cranial branch was the largest single branch and continued rostrally, distal to the vagoglossopharyngeal communication as the so called "pharyngeal ramus of the glossopharyngeal nerve." Continuing caudally, the middle group of these terminal branches divided into lesser branches which in turn ramified in the hyopharyngeus muscle.

The most caudal branch of the pharyngeal ramus of the vagus was the root of the pharyngoesophageal nerve. In fourteen dogs the pharyngoesophageal nerve on both sides originated proximal to the level of vagoglossopharyngeal connection (Fig. 4). On the other hand, in one dog this nerve was found to originate on both sides distal to the internerve connection, while in four dogs the site of nerve origin on one side was proximal and on the other side was distal to the vagoglossopharyngeal connection.

In none of the twenty one dogs dissected, was there any direct contribution from the glossopharyngeal nerve to the pharyngoesophageal nerve.

From its single origin, the pharyngoesophageal nerve passed caudally and ventromedially to reach the dorsolateral aspect of the pharynx. In this course the nerve passed over the ventral surface of the cranial cervical sympathetic ganglion from which it always received a contribution.

In thirteen of the specimens dissected, the pharyngoesophageal nerve lay as a distinct nerve free from the cranial cervical ganglion but was connected to it by a short nerve trunk (Fig. 4). In the remaining eight specimens however, it appeared to arise entirely from a large nerve root that originated from the ventromedial surface of the cranial cervical ganglion near its caudal pole. The greater part of this nerve root was distributed to the region of the carotid bifurcation. It was only subsequent to the treatment of six fresh specimens by a modified McCrea (1924) technique and careful dissection that the exact nature of the nerve was clearly demonstrated. In every case the pharyngoesophageal nerve was seen to arise from fibres in the interganglionic vagus, then pass through the base of the pharyngeal ramus of the vagus, across the ventral surfaces of the distal vagal and the cranial cervical ganglia, and finally emerge from the sympathetic nerve root as the definitive nerve (Fig. 5). This group of vagal nerve fibres was firmly and closely bound to the adjacent surfaces of the ganglia by strong fibrous tissue, but could be seen as a fine yellow thread lying in the immediate periganglionic connective tissue.

After receiving a fibre contribution from the cranial cervical sympathetic ganglion, the pharyngoesophageal nerve emerged from the sympathetic root or passed medially to it, and continued caudally over the lateral surface of the pharyngeal musculature. For the initial part of this course it was related medially to the ascending pharyngeal artery. However, in four dogs on the right side and one dog on the left side, the pharyngoesophageal nerve divided so that one branch passed on either side of the artery and then rejoined.

The pharyngoesophageal nerve did not supply any branches to the hyopharyngeus muscles. In one dog, on the right side only, the definitive pharyngoesophageal nerve received a small terminal twig from the most caudal of the branches of the vagus nerve which supplied the hyopharyngeus muscle.

Caudal to the ascending pharyngeal artery, the pharyngoesophageal nerve lay firmly applied to the lateral aspect of thyropharyngeus and, more caudally cricopharyngeus, to both of which it supplied numerous fine nerve branches.

In all but two dogs, and then on one side only, a communicating nerve branch was seen to pass from the pharyngoesophageal nerve to the external branch of the cranial laryngeal nerve. When present, this connection was made about midway along the course of the external branch (Fig. 3). In three cases, two communicating branches were found but only on the one side. In two of the dogs, these connections were from both the parent cranial laryngeal nerve and its external branches while in the other dog both communicating branches arose from the proximal portion of the cranial laryngeal nerve.

As the pharyngoesophageal nerve passed over the cricopharyngeus muscle it usually remained as a single trunk. However, in five dogs the nerve divided into two main branches, and in one other dog no nerve trunks were seen, in their place being a mass of fine nerves arranged in a broad band.

At the pharyngoesophageal junction, a fine nerve filament left the most ventral division of the pharyngoesophageal nerve to enter the recurrent laryngeal nerve. This branch was present in fifteen dogs.

The thyroid gland and region was supplied by a branch from either the pharyngoesophageal nerve or, equally as frequent, the external branch of the cranial laryngeal nerve.

The pharyngoesophageal nerve was then distributed to the cervical esophagus by the one or two main trunks and smaller branches (Fig. 3). The esophageal part of each nerve arose near the tracheoesophageal groove at the level of the pharyngoesophageal border, and then branched over the ventral and lateral aspects of the esophageal musculature in a straight and almost regularly dichotomous manner. These nerve branches were very closely applied to the esophageal muscle fibres, and rapidly penetrated into the deeper layers. Fine branches could be traced to about the level of the fifth cervical vertebra in the caudal third of the cervical esophagus.

#### Recurrent laryngeal nerves

Since the origin and distribution of the two recurrent laryngeal nerves differ, it is necessary to describe each nerve separately. However, both nerves had a similar basic pattern (Fig. 2). Both originated from their respective vagus nerves in the cranial half of the thorax and then curled dorsally around the caudal surface of a large adjacent artery - on the right side, the subclavian artery, and on the left side, the arch of the aorta and the ligamentum arteriosum. From this point they both passed cranially on the trachea to penetrate the larynx. For most of their course, each recurrent laryngeal nerve was paralleled by a similar but slightly smaller nerve lying more dorsally - the pararecurrent laryngeal nerve.

### Right recurrent laryngeal nerve

The right recurrent laryngeal nerve was formed from the right vagus nerve opposite, or just cranial to, the first rib in the cranial extension of the cranial thoracic mediastinum. The point of origin was on the medial aspect of the vagus and was always immediately caudal to the right middle cervical sympathetic ganglion but cranial to the point of communication between the right ansa subclavia and the right vagus nerve. From this origin, the right recurrent laryngeal nerve left the vagus and curled around the caudal and dorsal surfaces of the right subclavian artery, to lie on the trachea. One or two cardiac nerves were detached from the recurrent nerve at this point.

Immediately after its origin, the right recurrent laryngeal nerve always divided into two main trunks: ventrally, the recurrent laryngeal nerve proper and dorsally, a slightly smaller trunk -- the pararecurrent laryngeal nerve (Fig. 6). The distinct division into two nerves at this level was clearly evident in only twelve dogs. In the remaining nine dogs, the division was not apparent until the nerve had passed a short distance cranial to the thoracic inlet. However, after these specimens had been treated with acetic acid, the common trunk was readily separated into the two divisions as far back as their vagal origins. Histological examination revealed two separate nerve trunks within a common fibrous sheath (Fig. 44).

As it passed cranially from the subclavian artery, the right recurrent laryngeal nerve lay on the trachea near the midventral line, and then gradually passed dorsocranially over the right lateral face of the cervical trachea. Although this nerve gave off a few small twigs to the trachea it passed without interruption to

penetrate the larynx at the dorsolateral border of the first tracheal ring. Here the nerve became the right caudal laryngeal nerve and terminated in the internal intrinsic laryngeal muscles of the right side.

Throughout its course in the neck, the right recurrent laryngeal nerve lay on the tracheal surface at a level ventromedial to the vagosympathetic trunk and the common carotid artery. The right pararecurrent laryngeal nerve ran dorsal to, and parallel with, the right recurrent laryngeal nerve proper, and had variable anastomoses with it along its course over the right lateral aspect of the trachea. Despite these anastomoses, the pararecurrent nerve was always clearly distinguishable from the recurrent nerve proper (Fig. 6).

As each of these right recurrent laryngeal nerves passed medial to the right middle cervical ganglion, it received one or two small rami communicantes from this ganglion.

In nine dogs, a third recurrent branch was present on the right side. This short nerve took its origin from the region of connection between the right vagus nerve and the ansa subclavia, and then passed dorsal to the sympathetic trunk to join with the right pararecurrent laryngeal nerve a short distance cranial to the middle cervical ganglion. In one specimen however, this nerve arose from the root of the right recurrent laryngeal nerve. These nerves furnished many fine branches to the trachea in the cranial thoracic and thoracic inlet regions on the right side.

The right pararecurrent laryngeal nerve gave off many large and small branches along its course, some of which terminated in

the trachea while others passed dorsally over the tracheal surface to penetrate the cervical esophagus (Fig. 6). The latter were either small direct nerves, or larger branching and anastomosing nerves. Since most of the cervical esophagus was displaced to the left, these fibres passed completely over the dorsal aspect of the trachea to reach their end organ.

At the level of the seventh tracheal ring the right pararecurrent nerve joined the right recurrent nerve, to form a single nerve trunk, this point being marked by the fanning out of many branches to the trachea and esophagus (Fig. 6). This single nerve trunk then continued cranially and penetrated the caudal larynx beneath the cricoid cartilage. Nevertheless, careful dissection after acetic acid treatment clearly demonstrated two separate nerves within a common sheath, or two nerves lying in close apposition. Histological examination confirmed this arrangement (Figs. 10 and 11).

Just as the right pararecurrent laryngeal nerve penetrated the larynx it received a fine anastomotic branch from the right pharyngoesophageal nerve. This anastomosis was present in fifteen dogs.

Within the larynx the two recurrent laryngeal nerves separated. The right recurrent laryngeal nerve became the right caudal laryngeal nerve and was distributed unilaterally to all the internal intrinsic laryngeal muscles. After its separation from the caudal laryngeal nerve, the right pararecurrent laryngeal nerve continued cranially to anastomose with the ramus from the internal branch of the right cranial laryngeal nerve (Fig. 6). This anastomotic ramus lay between the laryngeal mucosa and the medial surface of the lamina of the thyroid cartilage.

### Left recurrent laryngeal nerve

The left recurrent laryngeal nerve arose from the left vagus nerve near the arch of the aorta (Fig. 7). Five different patterns of origin were found. The most common variant, which was present in eleven dogs, was a single root arising from the dorsomedial aspect of the vagus as it lay on the ventrolateral surface of the descending aorta (Figs. 7 and 8). This point was immediately caudal to the origin of the left subclavian artery. In six other dogs, a number of smaller roots left the vagus at this level; there were two roots in four specimens and three roots of origin in one other specimen (Fig. 9). In the remaining four dogs, the left recurrent laryngeal nerve arose from the cardiac nerve branches lying medial to the left vagus; in three specimens, a single root arose from both the vagus and the main cardiac nerve, whereas in one dog the recurrent nerve appeared to arise solely from the largest medially lying cardiac nerve branch. Several connections were always present between these cardiac nerves and the vagus.

The roots of the left recurrent laryngeal nerve ran from their points of origin caudomedially, crossed the ventral surface of the aorta and then curled cranially, around the caudal and dorsal aspects of the ligamentum arteriosum. When more than one nerve root was present, as in nine dogs, these roots merged into a single trunk as they curled around the ligamentum arteriosum. A short distance cranial to this union the left recurrent laryngeal nerve and the left pararecurrent laryngeal nerve were formed (Figs. 7, 8, and 9).

The larger left recurrent laryngeal nerve proper lay on the ventral surface of trachea in the midline, but gradually passed to the left as it coursed cranially. By the time it reached the

thoracic inlet, this nerve lay along the left lateral surface of the trachea in the tracheoesophageal groove. Several small cardiac nerve branches were given off from the recurrent nerve roots or the most proximal part of the recurrent nerve proper.

In three dogs, a small anastomotic branch passed between the most cranial cardiac nerve branch on the right side and the left recurrent laryngeal nerve. This communication between left and right recurrent laryngeal nerves was dorsal to the proximal half of the brachiocephalic arterial trunk. In one dog it appeared to be from right to left in direction.

Throughout its precardiac course, the left recurrent laryngeal nerve supplied fine branches to the trachea. In one dog, a small nerve passed from the middle cervical ganglion at the thoracic inlet to the left recurrent nerve. This sympathetic nerve passed ventrally over the esophagus.

The smaller left pararecurrent laryngeal nerve diverged dorsolaterally away from the left recurrent laryngeal nerve to ascend over the cranial thoracic esophagus (Fig. 7). Near its origin the left pararecurrent nerve always sent four or five large nerve branches dorsally and slightly caudally to innervate the esophagus dorsal to the base of the heart. The parent nerve then continued over the left lateral and ventral surfaces of the precardiac esophagus, supplying it with a shower of branching and anastomosing fine nerve branches.

As the left pararecurrent laryngeal nerve proceeded into the base of the neck, it passed medially towards the trachea and eventually lay in the left tracheoesophageal groove, dorsolateral

to the left recurrent laryngeal nerve. At the level of the thoracic inlet, in all dogs, most of the left pararecurrent fibres merged with the left recurrent nerve, the few remaining fibres being distributed by fine nerves to the left aspect of the esophagus as it passed through the thoracic inlet and into the base of the neck.

The left recurrent laryngeal and left pararecurrent laryngeal nerves ascended the neck on the left lateral surface of the trachea with similar distribution patterns to the right recurrent nerves in all dogs. Both nerves lay close together in the tracheoesophageal groove over most of their cervical course. From the thoracic inlet to the midcervical region the two nerves were in a common fibrous sheath; and only after acetic acid treatment and fine dissection could the two nerves be separated. Histological examination confirmed this arrangement (Fig. 10). From the midcervical region cranially the two nerves were loosely joined by small amounts of connective tissue (Fig. 11) and a few small nerves communicating between them.

The arrangement immediately caudal to the larynx and cranially from this level on the left side was similar to the pattern on the right side.

Throughout the cervical region the esophageal rami from the left pararecurrent nerve (Fig. 7) were more numerous, and more widespread in their distribution than the esophageal rami from the right nerve (Fig. 6). Those from the right first passed dorsally over the trachea before reaching the esophagus, while those from the left nerve passed directly to their esophageal terminations.

Vagus nerves distal to the origin of each respective recurrent laryngeal nerve

After giving rise to the recurrent laryngeal nerves, each vagus nerve continued caudally and passed dorsally over the lateral surface of the trachea. Each vagus then passed dorsal to its respective lung root where it divided into dorsal and ventral branches (Fig. 12). Caudal to the tracheal bifurcation the ventral branch of the right vagus fused with its left counterpart to form the ventral vagal trunk, and more distally a similar anastomosis occurred between the right and left dorsal vagal branches to form the dorsal vagal trunk. Both vagal nerve trunks continued with the esophagus and passed through the diaphragm in the esophageal hiatus.

Right thoracic vagus nerve

Caudal to the right subclavian artery and the origin of the right recurrent laryngeal nerve, the right vagus nerve continued caudally and gradually passed dorsally over the right lateral face of the trachea. Along this course numerous fine branches left the vagus to supply the trachea. In addition, three or four slightly larger branches supplied both the trachea and the esophagus in this region (Fig. 13).

Dorsal to the root of the right lung the right vagus nerve divided into a large dorsal and a smaller ventral branch (Figs. 12 and 13). This division was always at a level opposite the head of the sixth rib. Two large and several smaller bronchial branches left the ventral branch of the right vagus near this point.

The main trunk of the right vagus nerve continued caudodorsally in a fairly straight line as the right dorsal vagal branch. This branch joined with its left counterpart to form the dorsal vagal trunk. This union always occurred in the postcardiac mediastinum dorsal to the esophagus at a level between the heads of ribs ten and eleven (Fig. 12). In four dogs, a smaller secondary right dorsal vagal branch was present which paralleled the main branch and lay a short distance caudal to it, and so joined the dorsal vagal trunk just caudal to the main confluence. In three other dogs, a small branch left the right dorsal vagal branch, passed dorsally over the esophagus and merged with the left dorsal vagal branch cranial to the formation of the dorsal vagal trunk.

The smaller ventral branch of the right vagus nerve diverged medially from the main trunk and passed towards the left on the esophagus. It passed dorsal to, but immediately caudal to the tracheal bifurcation and soon joined with the left ventral vagal branch. Along this path it always gave off one or two large bronchial branches.

#### Left thoracic vagus nerve

As the left vagus nerve ran caudal to the aortic arch it lay on the left wall of the esophagus between the descending thoracic aorta and the root of the left lung. From this course the left vagus supplied the adjacent portion (i.e. cardiac region) of the esophagus with numerous fine nerves through five or six main branches (Fig. 14).

The left vagus nerve then divided into a dorsal and a ventral branch caudal to the base of the heart but dorsal to the root of the left lung, opposite the space between the heads of ribs seven and eight (Fig. 12).

The larger ventral branch continued the main trunk of the left vagus nerve caudoventrally in a straight line over the left aspect of the esophagus. This branch was relatively short as it passed close to, but caudal to, the tracheal bifurcation and joined with the ventral branch from the right vagus nerve. These ventral branches formed the ventral vagal trunk at a level opposite the head of the eighth rib (Fig. 12). A smaller secondary left ventral branch was present in five dogs. It arose from the left vagus caudal to the primary division and merged into the ventral vagal trunk immediately caudal to the primary junction.

In one dog two equally sized ventral branches were formed from the left vagus, and on the right side a small secondary ventral branch was also present.

The dorsal and ventral vagal branches on both sides lay directly on the esophageal adventitia.

In all dogs, the esophagus dorsal to, and immediately caudal to, the tracheal bifurcation was richly innervated by many fine nerve branches. These esophageal branches were supplied from the terminal parts of the left and right vagus nerves, their dorsal and ventral branches, and the proximal parts of the dorsal and ventral vagal trunks. Branches from the dorsal vagal branches and in particular those from the left side, were most abundant (Fig. 14). Thus an extensive plexus was established, particularly over the ventral portion of the esophagus. Many nerve fibres passed directly to the esophagus, and others supplied the base of the heart, the tracheal bifurcation, and the roots of both lungs.

### Dorsal and ventral vagal nerve trunks

From their points of formation, the dorsal and ventral vagal nerve trunks ran caudally in the postcardiac mediastinum, closely related to the dorsal and ventral borders of the esophagus respectively. The dorsal trunk tended to lie to the right of the esophageal midline, and the ventral trunk lay slightly to the left (Fig. 12). Each vagal trunk lay in the dorsal part of the caudal thoracic mediastinum between the opposed left and right mediastinal pleural sheets. Because of this the vagal trunks were suspended and separated from the esophagus by a short width of double mediastinal pleura. This arrangement made it possible to freely reflect and transect each vagal trunk during surgery without any trauma to the esophagus.

Throughout the caudal thoracic region numerous fine nerves passed from both dorsal and ventral vagal trunks to innervate both sides of the esophagus (Figs. 13 and 14). These fine nerves always passed from their parent trunk to the esophagus in a caudal direction. The dorsal part of the postcardiac esophagus received a more plentiful supply than the ventral part. In particular, the proximal part of the ventral vagal trunk was conspicuous for its sparse supply of esophageal nerve branches.

In none of the dogs was there found any variation in the vagal nerve trunks in the caudal thoracic region, nor were there any significant differences in their esophageal branches.

Both vagal nerve trunks pierced the diaphragm at the esophageal hiatus. The ventral trunk lay in contact with the midventral surface of the esophagus, and the dorsal trunk with the mid-dorsal surface.

The short abdominal esophagus received nerve fibres from both vagal trunks, in a distribution pattern similar to that found in the caudal thoracic region. However the ventral trunk gave off more esophageal branches than the dorsal trunk, since the abdominal esophagus tends to have a greater length in the ventral portion than the dorsal portion.

A very fine connection was found between a terminal esophageal branch of each of the ventral and dorsal vagal trunks. This communication was immediately caudal to the esophageal attachment of the phrenicoesophageal ligament and was present in only five dogs - three on the right side, and two on the left.

The vagal trunks terminated by dividing into four or five main branches which were distributed over the surface of the stomach and to other abdominal viscera. This division of the vagal trunks was usually evident as they passed through the diaphragm.

### Radiographic Observations:

The preoperative radiographs and the radiographic screenings of twenty five normal dogs showed that esophageal motility did not necessarily directly follow each oropharyngeal deglutition sequence, nor did it appear as a smooth continuous peristaltic wave travelling the length of the esophagus. Swallowed boluses were frequently delayed in the most proximal portion of the cervical esophagus, at the thoracic inlet and in that portion between the thoracic inlet and the tracheal bifurcation. Reflux of gastric contents into the caudal part of the thoracic esophagus was observed in all except three dogs.

### Group I : Dogs which underwent bilateral pharyngoesophageal neurectomy

Both dogs in this group had boluses pass smoothly through their cervical esophagus during preoperative observations (Fig. 15). However, when the dogs ate food following transection of both pharyngoesophageal nerves, the cervical esophagus became progressively packed with swallowed food until the paralysed esophagus became distended as far caudally as the thoracic inlet (Fig. 16). With further eating the swallowed mass was gradually pushed into the thoracic esophagus so that eventually, on some occasions, the entire length of the esophagus became packed with food (Fig. 17). On other occasions an esophageal wave formed near the thoracic inlet, pinched off the distal part of the swallowed mass (Fig. 18) and propelled it to the stomach.

These waves started as ineffective non-propulsive waves in the distal cervical esophagus. They travelled for approximately 1 to 4 cm before pinching off part of the swallowed mass and effectively propelling it towards the stomach.

The actual level of origin of the effective waves varied between the two dogs and in fact within each dog. They commenced at levels between the fifth cervical and the first thoracic vertebrae. In each dog as the meal progressed and the esophagus filled with swallowed food, the origin of each successive wave moved more and more caudally. No esophageal contractions were observed in the portion of cervical esophagus between the pharyngoesophageal junction and the above "wave-origin" levels.

In these neurectomised dogs no abnormalities of the pharyngeal phase of deglutition were observed. Indeed a competent pharyngo-esophageal sphincteric action was present. This was most apparent during feeding when the dogs are in a head down position and had a full cervical esophagus yet no food was seen to pass forward into the pharynx.

#### Group II : Dogs which underwent bilateral cranial thoracic vagotomy

Observations within twenty four hours of surgery in both these dogs showed gaseous dilatation of the esophagus from the level of the fifth cervical vertebra to the gastroesophageal junction and a gas filled stomach (Fig. 19). Some watery liquid lay in the dependent parts of the esophagus and a bilateral pneumothorax was also observed.

Unfortunately one dog (06) died on the second postoperative day. In the other (10) the thoracic esophagus was dilated when re-examined on the sixth, ninth and twenty fourth postoperative days.

When these dogs ate barium impregnated food smooth waves of esophageal contractions propelled the boluses down the cervical esophagus to the level of the fifth (dog 06) or the sixth (dog 10) cervical vertebra. The swallowed mass lodged in or near the thoracic inlet but eventually, with the addition of further swallowed material, it was shunted into the dilated thoracic esophagus so that this area then became packed with food (Figs. 20 and 21). Even when this occurred, cervical waves still attempted, albeit unsuccessfully, to propel the increasingly large food mass from the cervical esophagus through the thoracic inlet. These waves were only effective to the base of the neck (Fig. 21). No esophageal contractions were observed caudal to this level.

Although food passed into and filled the dilated caudal thoracic esophagus in the surviving dog (Fig. 20), it was not propelled freely into the stomach. However, on a few occasions during each observation, a small amount of food did pass through the gastroesophageal junction (Fig. 22). Nevertheless most of the meal remained in the thoracic esophagus for at least thirty minutes after feeding, even when the dog was allowed to sit on its haunches (Fig. 23) or when its forelimbs were held high off the ground for two or three minutes. A check radiographic screen of this dog twenty four hours after barium feeding revealed that

no food had remained in the esophagus. During this period the dog was usually observed to regurgitate some of the barium meal.

The gastroesophageal junction in this dog thus appeared to be incompetent as it opened only infrequently and inefficiently.

Group III : Dogs which underwent recurrent laryngeal neurectomies

Before neurectomy in these dogs boluses were observed to pass through the thoracic inlet region and cranial thoracic esophagus without leaving a trace of meal behind (Figs. 24 and 25). However, the majority of boluses were propelled to the thoracic inlet where they remained in a relaxed state until joined by a second bolus. The two boluses became fused into one mass which was then propelled smoothly through the thoracic inlet and thoracic esophagus to the stomach. This second sequence was a relatively smooth and uninterrupted wave from pharynx to stomach.

Following right recurrent laryngeal neurectomy, a small change in esophageal function was observed in the cervical and cranial thoracic portions of the esophagus.

In one dog (15) the esophageal waves became less efficient. They only partially occluded the lumen of the cervical esophagus which resulted in a considerable part of the swallowed meal being left behind after each wave had passed through this area. After

several boluses had been transported in this manner a continuous ribbon of meal remained throughout the cervical esophagus (Fig. 25). This incompetency, or partial paralysis, extended throughout the whole of the cervical esophagus and caudally to a level opposite the second thoracic vertebra, from where the esophageal wave resumed its full propulsive force. The ineffectiveness of the esophageal waves was most obvious on the first postoperative day, when at times the cervical esophagus contained a considerable mass of food. However, the condition was less marked by the sixth postoperative day.

In the second dog (14) the postoperative changes were slightly different. The cervical esophageal wave was more effective, although occasionally a trace of meal was left behind (Fig. 27). However, most cervical waves appeared to pause at the base of the neck, between the levels of the fourth cervical intervertebral disc and the sixth cervical vertebra (Fig. 27). The esophageal contraction then relaxed slightly for a brief moment, and at the same time, the esophagus was drawn cranially by the elevation of the pharynx during swallowing. The result of these two actions combined with a downward sloping of the neck during eating caused some of the food to pass forward into the proximal cervical esophagus (Fig. 28). Immediately this had occurred, the esophageal wave restarted at the same point at which it had stopped thus leaving the proximal part of the bolus in the cervical esophagus (Fig. 29). This wave then continued in an effective manner along the remaining esophagus to

the stomach. The food left behind in the proximal cervical esophagus was incorporated into the next bolus and the sequence was repeated.

After left recurrent laryngeal neurectomy (seven days after right recurrent laryngeal neurectomy) the cranial thoracic esophagus and the part occupying the thoracic inlet were paralysed. The condition remained unchanged during the next eight days.

In one dog (14) a relatively effective wave travelled down the cervical esophagus although sometimes a small trace of barium remained in the distal parts (Fig. 30). However, in the other dog (15) an ineffective wave was still present throughout the cervical esophagus (Fig. 35).

The cervical wave in both dogs ended opposite the sixth cervical vertebra (Fig. 30)

At the completion of each cervical wave the swallowed boluses temporarily lay in the thoracic inlet and cranial thoracic esophagus before partially refluxing into the distal cervical esophagus (Fig. 31).

With the addition of further boluses, the paralysed region became distended and the swallowed mass was gradually shunted more caudally. Often the esophagus would be packed with food from the base of the neck to the tracheal bifurcation. Eventually a new esophageal wave was initiated which pinched off the distal part of the swallowed mass and propelled a new bolus towards the stomach (Figs. 32, 33, and 34).

In both dogs this thoracic wave reappeared at a level opposite the first thoracic intervertebral disc region. However, this wave was ineffective and only made a large indentation in the ventral parts of the esophagus (Figs. 32 and 33). Only after the wave had travelled to about the level of the fourth thoracic vertebra did it become fully effective (Fig. 34). In both dogs the level at which a full propulsive wave reappeared sometimes varied by about one vertebral length either side of fourth thoracic vertebra.

In dog (15) the thoracic wave was diaphasic in origin (Fig. 35) and it was the caudal contraction which became the effective wave.

In one dog (14) the first two boluses swallowed passed through the cranial thoracic esophagus without the usual delays, but, a trail of meal remained behind. This was on the eighth day of postoperative observations. Similar activities were seen in the second dog (15) at the beginning of feeding on the third postoperative day.

In both dogs, food remained in the esophageal segment between the fifth cervical and fourth thoracic vertebrae for no longer than ten minutes after each feeding.

#### Group IV : Dogs which underwent double bilateral cranial thoracic vagotomy

Observations after bilateral vagotomy distal to the recurrent laryngeal nerve origins in both these dogs, showed gaseous dilatation of the esophagus from the level of the first rib to the gastroesophageal junction.

When these dogs swallowed barium impregnated food, smooth waves of esophageal contractions propelled the boluses down the cervical esophagus into the cranial thoracic esophagus. The waves reached a level midway between the thoracic inlet and the base of the heart. In one dog (12) this level was recorded opposite the first thoracic intervertebral disc (Fig. 36). No esophageal contractions were observed caudal to this level.

The swallowed meal was progressively packed into, and within a short time completely filled, the paralysed and dilated thoracic esophagus. However, although the swallowed mass was pushed as far caudally as the gastroesophageal junction, it was not seen to pass freely through this region to the stomach. On several occasions the gastroesophageal junction did open and the distal portions of the swallowed meal passed into the stomach. On other occasions when the dogs were lifted into a vertical position standing on their hindpaws, the gastroesophageal junction opened for a few short periods and food was seen to pour through into the stomach.

Following bilateral vagotomy proximal to the origin of the recurrent laryngeal nerves, the thoracic esophagus was completely paralysed. Cervical esophageal waves travelled to the thoracic inlet in one dog (13) and to between the fifth and sixth cervical vertebrae in the other (12). The gastroesophageal junction was less responsive than before this second operation, and most of the food remained in the thoracic esophagus.

Group V : Dogs which underwent caudal thoracic vagotomies

One dog (04) in this group frequently showed reflux of swallowed material through the gastroesophageal junction into the caudal thoracic esophagus during preoperative observations (Fig. 38) although on a few occasions no reflux was observed (Fig. 37). In the other dog (02) gastric reflux was never observed preoperatively.

After double caudal thoracic vagotomy the waves of esophageal contractions passed smoothly over the entire length of the esophagus and freely propelled boluses to the stomach in an apparently normal manner. However, gastric reflux was observed to be more extensive and was observed more regularly, particularly in one dog (04), (Figs. 39 and 40).

In the other dog (02) reflux after dorsal trunk vagotomy was much less extensive (Fig. 41) than after double trunk vagotomy (Fig. 42).

## Clinical Observations:

### Laryngeal function

After neurectomy, no dog showed any respiratory distress which could clearly be referred to laryngeal malfunction.

### Eating behaviour

Preoperative. At no time during the preoperative period did any of the dogs regurgitate food or show any difficulties in eating.

Postoperative. The oropharyngeal sequence of deglutition was never interfered with, despite the various surgical procedures and neurectomies. Invariably all dogs were able to masticate food, and food boluses passed from the mouth into the cervical esophagus in an apparently normal manner. In contrast, following surgery, all but four dogs often regurgitated food during or after eating.

### Group I : Dogs which underwent bilateral pharyngoesophagal neurectomy

Both dogs (03, 05) in this group regurgitated their food on the first two days after neurectomy. The meal, which consisted of solid pieces of commercial pet food, was eaten slowly. After several mouthfuls had been swallowed, the dogs paused in their eating, stretched out their necks with their heads down, then opened their mouths wide and a column of food poured out freely. This food mass was covered in watery mucus which showed no acid reaction when tested with litmus paper. Both dogs then proceeded

to re-eat their regurgitated food. Whenever they ate rapidly regurgitation was the consequence. However, when these dogs ate small pieces of meal slowly with pauses and raised their heads between swallows, they were able to complete a meal without difficulty.

From the third to the tenth postoperative day both dogs were fed meal mixed to a thin consistency with milk. On this diet regurgitation did not occur. The dogs swallowed several mouthfuls, paused, seemed to concentrate and make an exaggerated swallowing action, then repeated this whole pattern until each meal was completed. The dogs always regurgitated when they were fed solid food during this period.

These dogs were gradually changed on to a total solids diet by the end of the second postoperative week. After this time both dogs could eat solid food without any problems and regurgitated only when large pieces of meal were eaten in a rapid succession.

#### Group II : Dogs which underwent bilateral cranial thoracic vagotomy

Neither of these dogs (06, 10) regurgitated their food during or immediately following a meal. However, the amount that these dogs ate was less than half that eaten before neurectomy. Once the thoracic and distal cervical parts of the esophagus were packed with meal (as seen radiographically) they stopped eating. They then appeared to show some slight discomfort. On the few occasions that these dogs were actually observed to regurgitate, it was a much more forcible act than that seen in the Group I dogs. The food was still in an undigested state and was covered in mucus, some of which was acidic.

From the second day after surgery, the surviving dog (10) was fed frequently with small liquid meals. On this diet it was able to eat satisfactorily, even though on many days a small amount of frothy saliva-like material was found on the floor of its kennel. In addition, within twenty four hours of eating the barium impregnated meal, part of it was always found on the kennel floor.

Group III : Dogs which underwent recurrent laryngeal neurectomies

Both dogs in this group (14, 15) at no time regurgitated their food or showed any problems during eating.

Group IV : Dogs which underwent double bilateral cranial thoracic vagotomy

On the first and second days after the first neurectomy, both dogs (12, 13) regurgitated most of their meal immediately after they had finished eating it. Both looked distressed and uncomfortable after eating the meal and then regurgitated without any effort.

The eating behaviour in these dogs was similar to that of the dogs in Group II. However, after the second neurectomy one dog (12) constantly regurgitated immediately following each meal, whereas the other dog (13) was never observed to regurgitate during this period.

Group V : Dogs which underwent caudal thoracic vagotomies

Both dogs in this group (02, 04) were never observed to have any problems in eating their food.

## Post Mortem Observations:

### Neurectomy site

At autopsy the completeness of nerve transection was confirmed in all dogs. Furthermore the precise site of neurectomy was verified. In all cases this was identical to that which was observed and recorded during surgery.

### Esophageal dilatation

The cervical esophagus in both dogs of Group I (03, 05) was a little more dilated and flaccid than normal. This post neurectomy change was not very obvious at autopsy.

However, the esophagus in each of the dogs from Groups II and IV showed considerable changes from the normal. In these dogs (06, 10, 12, 13) the thoracic esophagus was enlarged to at least twice its normal size (Fig. 43). In addition, the distal one third of the cervical esophagus progressively widened caudally until it joined with the fully dilated thoracic esophagus at the thoracic inlet (Fig. 43).

In gross appearance the lumen of the thoracic esophagus was greatly expanded but the esophageal wall was flaccid and appeared thinner than normal. The gastroesophageal junction remained in what appeared to be the normal state; it was neither readily dilatable nor was it overly constricted. In fresh specimens an index finger could be inserted into the junctional zone without difficulty.

These post mortem findings were anticipated from the earlier radiographic observations (Figs. 19 and 23).

The esophagus in all dogs from Groups II and V (14, 15, 02, 04) showed no detectable changes.

#### Nerve degeneration histology

The nerve samples removed from the embalmed dogs were totally unsatisfactory for histological examination. The architecture of the nerve trunks was considerably destroyed, and in all samples the fine cellular structure was non-existent. These findings were in both the transected and the non-transected nerves.

On the other hand, the nerve samples taken during surgery and from the freshly dissected dogs were adequate for histological examination.

Those taken during surgery were control specimens and demonstrated the normal histology of a nerve trunk (Fig. 44). In contrast, the specimens taken during fresh dissection (from the distal segment of the transected nerves) showed considerable changes from the normal. In all cases the typical pattern of "Wallerian degeneration" (Blackwood et al., 1963; Minckler, 1963) was evident.

Nerve samples were taken at various times after transection and thus a range of degeneration stages were found. Nevertheless all samples showed significant changes, such as extensive areas of neuronal degeneration: swelling, degeneration and fragmentation of the myelin sheath; and areas of complete loss of all nervous elements (Fig. 45).

## DISCUSSION

Little attention has been given to the relationship between the anatomy of the vagal nerve distribution and the function of different portions of the canine esophagus. The present study was designed to overcome this deficiency, by dissections to reveal the nerves supplying the esophagus, and surgical transection of each of the appropriate nerves. The resultant dysfunction of the various portions of the esophagus was then studied radiographically to determine the area of functional involvement of each transected nerve.

The results clearly demonstrate that within the canine esophagus three major regions exist, each with a separate nerve supply derived from branches of the vagus nerves. These regions and nerves are:

1. The cervical esophagus, which is supplied by the paired pharyngoesophageal and the paired pararecurrent laryngeal nerves.
2. The cranial thoracic esophagus, which is mainly supplied by the left pararecurrent laryngeal nerve.
3. The caudal thoracic and abdominal esophagus, which is supplied by the thoracic vagi and the vagal nerve trunks.

The structural and functional aspects of the innervation of the above portions of the esophagus will, for convenience, be discussed separately.

## Structural Considerations:

### Cervical esophagus

Definition. In this thesis the cervical esophagus is defined as that portion of esophagus extending from the pharyngoesophageal junction to the thoracic inlet.

Nerve supply. Two pairs of nerves supply the cervical esophagus: the pharyngoesophageal nerves which descend from the cranial end, and the pararecurrent laryngeal nerves which ascend over the cervical esophagus from the thoracic end.

In the twenty one dissections the cervical esophagus was constantly supplied by the pair of pharyngoesophageal nerves which unilaterally innervated the esophagus from the pharyngoesophageal junction to the distal third of the cervical portion. This confirms the findings of Hwang et al. (1948) who found these nerves to supply a similar area. Reid (1838) was one of the earliest to notice that the cervical esophagus was innervated from the pharyngeal ramus of the vagus nerve, but it was Chauveau in 1891 who was to clearly describe the nerve as the "oesophageal branch of the pharyngeal nerve".

Other authors have stated that the nerve supply to the cervical esophagus in the dog is by variously named descending branches from the pharyngeal ramus of each vagus nerve (Ellenberger and Baum, 1891; Starling, 1900; Lemere, 1932a; Sisson, 1953; Bradley, 1959). *Nomina Anatomica Veterinaria* 1968 lists this nerve as the esophageal

ramus from the pharyngeal plexus which is formed from the pharyngeal ramus of the glossopharyngeal nerve and the pharyngeal rami of the vagus nerve. This nerve was invariably present in the dogs dissected during this study, was clearly defined and was the motor innervation of the thyropharyngeus and cricopharyngeus muscles as well as the cervical esophagus. Thus, on a structural and functional basis it would seem more appropriate to name this nerve the pharyngoesophageal nerve - a term first proposed by Hwang et al. (1943).

It is often stated that the pharyngoesophageal nerve arises from the pharyngeal plexus which has contributions from both the glossopharyngeal and vagus nerves. Neither of these statements could be substantiated by the present findings which are thus in complete agreement with the findings of Lomere (1932a, 1932b, 1935) and Hwang and his coworkers (1947, 1943, 1953, 1954), which were based on many detailed dissections in this area. It is therefore surprising that the modern reference text on canine anatomy by Miller et al. (1964) refers to Hwang's work but at the same time states that the pharyngoesophageal nerve receives branches from the glossopharyngeal and vagus nerves through the pharyngeal plexus.

The pharyngoesophageal nerve always originates from the pharyngeal ramus of the vagus nerve and, furthermore, in almost all cases its origin is proximal to the vagoglossopharyngeal internerve connection. In these cases no fibres from the glossopharyngeal nerve can enter the pharyngoesophageal nerve, unless they cross in the internerve connection and travel retrograde in the vagal pharyngeal ramus before passing into the pharyngoesophageal nerve. Apart from the possibility of some fibres in the vagoglossopharyngeal

communication, no direct contribution from the glossopharyngeal nerve to the pharyngoesophageal nerve was detected in any dog. All the branches from the glossopharyngeal and vagus nerves and the cranial cervical sympathetic ganglion are clearly defined, and no "pharyngeal plexus" of nerves is present on the lateral walls of the pharynx. This so called "pharyngeal plexus" is listed in *Nomina Anatomica Veterinaria* 1968 and *Nomina Anatomica* 1968. It has been a traditional term and is still used in human (Barwick and Williams, 1973) and veterinary anatomy (Chouveau, 1891; Bradley, 1897; McFadyean, 1922; Sisson, 1953; Mizeros, 1955; McLeod, 1958; Reighard and Jennings, 1963; Miller et al., 1964; Hay, 1970; Evans and DeLahunta, 1971). On the other hand, Vaughan (1895), Bradley (1959), Lemere (1932a), Dougherty et al. (1958), and Habel (1970) describe these nerves and their few interconnections but do not use the term "plexus", while others fail to mention any inter-nerve connections (Taylor, 1955; Stokoe, 1967; Rooney et al., 1967; Dyce and Mensing, 1971; Popesko, 1971; Crouch, 1972).

When dissecting embalmed specimens it would be possible to confuse the fascia around the pharyngeal area for a plexus of nerve fibres, unless particular care is taken. However, in fresh cadavers, the nerves are clearly defined and no plexus was detected. In addition, by using the picric and acetic acid solution, the source of fibres entering the pharyngoesophageal nerves was readily distinguished from the surrounding fibrous connective tissue. Kwang et al. (1948) also reported some difficulties with the fibrous tissue about the ganglia and used electrical stimulation as an aid to determine the contribution to the pharyngoesophageal nerve.

From its vagal origin, the pharyngoesophageal nerve passes over the lateral aspect of the caudal pharynx to the cervical esophagus. The nerves on both sides are distributed in a uniform manner over the proximal two thirds of the cervical esophagus. Chauveau (1891) and Hwang et al. (1948) found a similar field of innervation, whereas Lemere (1932a) and Sisson (1953) state that only the proximal third of the cervical esophagus is supplied by the pharyngoesophageal nerves. These reported differences in the extent of this nerve supply to the cervical esophagus most likely reflect differences in the ease with which the various authors have been able to detect the terminal branches of these nerves. It was found during the present study that in the fresh cadavers the nerves could be traced to their greatest visible length, and the longer the fresh material was kept the more difficult it was to trace the nerves. In the formalin embalmed specimens, the nerves were much more difficult to trace than in the fresh specimens.

From the distal end of the cervical esophagus the pair of pararecurrent laryngeal nerves ascend and supply both sides of the cervical esophagus, although more esophageal branches arise from the left nerve. Chauveau (1891) is the only other worker to report the dominance of a left sided nerve supply to the cervical esophagus. This asymmetry may result from the fact that the cervical esophagus lies more to the left side than the right, and so the left nerve, which is in closer proximity to the esophagus, becomes its major supplier. Quantitative measurements on the pararecurrent laryngeal nerves may clarify this point.

### Cranial thoracic esophagus

Definition. In this thesis the cranial thoracic esophagus is defined as that portion of esophagus extending from the thoracic inlet to a level opposite the tracheal bifurcation (or at a level between the fourth and fifth thoracic vertebrae).

Nerve supply. The nerve supply to the cranial thoracic part of the canine esophagus is from two sources. A very extensive supply comes from the left pararecurrent laryngeal nerve, and a minor contribution comes from the right vagus nerve. In fact, the sparsity of esophageal fibres from the right vagus is such that it could almost be considered that the left pararecurrent nerve is the sole supply to the cranial thoracic esophagus. No other branches of the left vagus nerve were found to supply this part of the esophagus.

These findings of the relationship of the right and left vagus nerves to the cranial thoracic esophagus are in agreement with Sha Ban (1970).

An adequate description of the nerve supply to the cranial thoracic esophagus in the dog can not be found in the literature. Some reports simply state that the thoracic vagi supply branches to the thoracic esophagus (Dowgiallo, 1927; Hilsabeck and Hill, 1950; Bradley, 1959), but Chauveau (1891) and Lemere (1932a) imply that the left pararecurrent laryngeal nerve supplies the cranial thoracic portion of the esophagus. It is therefore surprising that, despite the adequate descriptions of the presence of the pararecurrent laryngeal nerves by Chauveau (1891) and Lemere (1932a), later workers

fail to mention them in accounts of esophageal and laryngeal innervation (Starling, 1900; Hilsabeck and Hill, 1950; Vogel, 1952; Bradley, 1959; Miller et al., 1964).

#### Pararecurrent laryngeal nerves

In each of the twenty one dogs dissected in the present study two recurrent laryngeal nerves were constantly found on each side. For most of its course, each recurrent laryngeal nerve proper is paralleled by a similar but slightly smaller nerve lying more dorsally - the pararecurrent laryngeal nerve. This name for the second recurrent nerve was originally proposed by Lemerc (1932a). Neither *Nomina Anatomica* 1968 nor *Nomina Anatomica Veterinaria* 1968 list this nerve, but since it complies with their principles of nomenclature the term has been adopted in this thesis.

In each case, the recurrent laryngeal nerve proper (the more medial and ventral trunk) passes cranially in the neck giving off a few fine twigs to the trachea. Finally, it penetrates the larynx as the caudal laryngeal nerve and terminates by branching to supply the internal intrinsic laryngeal muscles of the same side. No connections were found between any of these branches and the cranial laryngeal nerve.

On the other hand, as each pararecurrent nerve passes cranially it gives off many branches to the trachea and the esophagus. These branches are particularly frequent from the left nerve, especially in the cranial thoracic region. This could be explained by the fact that the left pararecurrent nerve is the sole innervation of the

cranial thoracic esophagus, whereas the cervical esophagus receives a bilateral and dual nerve supply. Despite its development as a midline structure, the esophagus cranial to the tracheal bifurcation has a predominantly left sided innervation from the left pararecurrent laryngeal nerve and in this region lies to the left of the midline. The above facts relating to left sided asymmetry could be correlated on the basis that developmentally, the nerves innervate the esophagus after it becomes a left sided structure, but as yet there is no evidence to support this hypothesis.

At their cranial and caudal ends the recurrent and pararecurrent laryngeal nerves often lie closely apposed, or even within a common nerve sheath, but the two trunks can be clearly separated. From their caudal end both nerves arise either from the vagus nerve in a short common trunk or as two separate nerves from the parent vagus. In the latter case the pararecurrent nerve takes its origin immediately caudal to that of the recurrent nerve proper. At the cranial end, within the larynx, the pararecurrent nerve diverges from the recurrent nerve and continues as the anastomotic ramus of the internal branch from the ipsilateral cranial laryngeal nerve.

This description of the double recurrent laryngeal nerves completely supports the earlier accounts by Chauveau (1891) and Lemere (1932a). Sisson (1953) and Sha Ban (1970) provide similar reports but state that the pararecurrent nerves supply only the cervical esophagus. Miller *et al.* (1964), by stating that the pararecurrent laryngeal nerve is "inconstant", have misinterpreted Lemere's (1932a) paper in which, in fact, Lemere states "the pararecurrent may rarely be included in the recurrent in dogs, but

it usually runs as a separate nerve or as a plexus".

#### Caudal thoracic and abdominal esophagus

Definition. In this thesis that part of the esophagus extending between the levels of the tracheal bifurcation and the diaphragm is defined as the caudal thoracic esophagus, while the abdominal esophagus is the short terminal segment extending between the diaphragm and the stomach.

Nerve supply. The nerve supply to the canine esophagus caudal to the tracheal bifurcation is from the right and left vagus nerves (caudal to the origin of their respective recurrent laryngeal nerves) and their resultant conjugate dorsal and ventral vagal trunks.

The right and left vagus nerves do not divide at the same level, nor are their resultant dorsal and ventral branches of equal diameter and length. Furthermore, the fusion of these dorsal branches to form the dorsal vagal trunk occurs at a different level from its ventral counterpart.

Both vagus nerves divide into dorsal and ventral branches in the region dorsal to the tracheal bifurcation. However, the right vagus always branches cranial to the left vagus, which agrees with the findings of Hilsabeck and Hill (1950) and Bradley (1959). The distance between the levels of division is one to one and one half vertebral lengths; a difference which Chauveau (1891), Dowgialla (1927), Sisson (1953), Mizeres (1955), and Miller et al. (1964) have not reported. In addition, the dorsal branch from the right vagus is greater in diameter than the ventral branch, whereas on the left side

the ventral branch is the larger. These differences are readily visible to the naked eye but Sisson (1953) is the only other worker to report such differences. Despite these differences in diameter of their branches, no visible difference in size can be detected between the right and left thoracic vagus nerves nor between the dorsal and ventral vagal nerve trunks.

Finally, the formation of the dorsal vagal trunk occurs two or three vertebral lengths caudal to the formation of the ventral vagal nerve trunk - a marked difference which was also noted by Hilsabeck and Hill (1950), Mizeres (1955) and Bradley (1959). It is believed that this thesis provides the first accurate record of the actual sites (with reference to vertebral levels) where the vagus nerves divide and again rejoin to form the vagal nerve trunks in the dog.

The nerve supply from the vagus nerves and trunks to the caudal thoracic and abdominal esophagus presented no unusual or new features, and in fact the nerve distribution pattern is essentially in accord with that found by previous workers (Chauveau, 1891; Starling, 1900; Dowgiallo, 1927; Hilsabeck and Hill, 1950; Sisson, 1953; Mizeres, 1955; Bradley, 1959; Miller et al., 1964).

#### Embryonic development of the esophagus and its vagal nerve supply

Studies in esophageal organogenesis are few and completely inadequate, so much so that none provide any information that may lead to a better understanding of the development and distribution of the adult nerve supply to the entire esophagus. Indeed, no literature is available on the organogenesis of the canine esophagus or vagal nerves.

Standard texts on developmental anatomy briefly mention the development of the esophagus, but not the nerves, in man (Baxter, 1953; Patten, 1964; Arey, 1965; Patten, 1968; Langman, 1969; Warwick and Williams, 1973) and in the pig (Patten, 1948; Patten, 1964; Arey, 1965; Marrable, 1971), and the appearance of nerve fibres in the esophageal wall of the fetus has been reported in man (Indar Jit, 1955; Smith and Taylor, 1972) and in the pig (Flint, 1907). Nevertheless, a developmental account of the pattern of nerve supply to the esophagus is still awaited.

In the developing human embryo, the esophagus forms from that portion of primitive foregut which extends between the primitive pharynx and laryngotracheal furrow, and the more caudal dilatation marking the primitive stomach. Initially the esophagus is very short, but it lengthens rapidly during the process of neck development and with the associated descent of the pericardium (Baxter, 1953; Arey, 1965; Langman, 1969). The striated muscle fibres of the esophagus are derived from the branchial arch mesoderm (Schofield, 1968). Even though this account is from human embryology, a similar sequence of events would be expected in the canine embryo.

During development, the primitive stomach undergoes a so called rotation of ninety degrees about its longitudinal axis, so that its original left wall becomes ventral in position and its right wall becomes dorsal. It is suggested that there is probably a similar and concurrent associated rotation of the primitive esophagus caudal to the tracheal bifurcation. The esophagus in this region would be free to rotate since it is not constricted by adjacent structures as are present cranial to this level. The result would be that the original

left wall of the caudal esophagus and stomach now becomes their definitive ventral wall. It is therefore possible that these changes are associated with the change in polarity of the vagus nerves, from right and left lateral to dorsal and ventral vagal nerve trunks.

In addition, rotation of the esophagus and stomach may account for the large component of the left vagus in the ventral vagal trunk and ventral gastric nerves, and a similar large component of right vagal fibres in the dorsal vagal trunk and dorsal gastric nerves. A detailed study of the esophagus and the development of its extrinsic nerve supply could elucidate this hypothesis. Warwick and Williams (1973) briefly explain the different origins of the recurrent laryngeal nerves in man.

Some potentially valuable and interesting research related to esophageal innervation could be carried out on some animals with certain congenital anomalies. In the dog, Fox (1965) states "one of the commonest esophageal anomalies arises from constriction by vascular embryonic remnants of the aortic arch". The list of defects in this species which would be suitable and worthy of more investigation would thus include aberrant right subclavian artery, double aortic arch, right aortic arch, interrupted aortic arch, as well as hereditary achalasia and esophageal fistulae and atresia.

Those presented with an anomalous origin of the right subclavian artery or with aortic arch anomalies could, on embryological grounds, be expected also to have an anomalous right and or left recurrent laryngeal nerve. If these situations were present in the dog, as witness a case of anomalous origin of right subclavian artery in man (Grant, 1962), then it could be expected that the right recurrent

nerve would not supply any branches to the esophagus but course by a shorter direct route to the larynx. According to Grant, however, the deficient recurrent branches to the esophagus and trachea in this case arose directly from the parent vagus nerve. Symmetrical recurrent laryngeal nerves are associated with the double aortic arch anomaly in man (Blincoe et al., 1936).

Although cases of aberrant right subclavian arteries have been reported in the dog (Vitmus, 1962; Henwood and Green, 1964; DeKleer, 1970) the authors were unable to observe the course of the right recurrent laryngeal nerve. Unfortunately such cases are often discovered in the anatomy dissection room or at necropsy after mutilation of the nerve trunks.

There are no reports in the literature of an aberrant right recurrent laryngeal nerve in the dog, thus if any dog were to be presented to a veterinary clinic with suspected vascular ring esophageal obstruction and an aberrant right subclavian artery is diagnosed, it would be informative if electrical stimulation and other experiments on the esophagus and its nerve supply were carried out before surgical treatment or euthanasia. A careful anatomical dissection of the vagi and recurrent nerves and their esophageal rami should be made if possible.

Marks (1969) stated that a giraffe or giraffes (number examined not specified) did not possess recurrent laryngeal nerves, but instead the caudal laryngeal nerves passed directly from the adjacent vagus nerves to the larynx. That this statement is characteristic of the giraffe species, Giraffa camelopardalis, must be seriously questioned since, if it were true, then the sequence of cranial nerve and

cardiovascular development in the giraffe must be significantly different from the otherwise universally accepted pattern of mammalian development (Young, 1957).

## Functional Considerations:

### Methods of study

Many experimental methods have been used to study the function of the esophagus. Among these are direct or radiographic observations on motility, intraluminal pressure recordings, and studies on the effects of either electrical stimulation or nerve transection. In the present study, radiographic techniques were chosen as they allowed observations to be made in a truly physiological manner. To achieve this, the animals under study were trained to stand quietly in a normal posture on an X-ray table, and eat barium impregnated food from a bowl situated just in front of their forepaws. Whilst they freely ate their meal, cineradiographic and video equipment was used to observe and record entire esophageal motility sequences by following each barium impregnated bolus from the mouth to the stomach.

Apart from Longhi and Jordan (1971), who also examined the esophagus in conscious dogs in a normal standing position, previous researchers on this subject have relied on physical means or pharmacological agents to restrain (either by general anaesthesia or sedation) their experimental animals, or have placed the animals in a recumbent position, or used a tube to introduce material into the animal's oral cavity, pharynx, or esophagus (Langley, 1898; Meltzer, 1899; Carlson et al., 1922; Jurica, 1926; Knight, 1934; Burget and Zeller, 1936; Zeller and Burget, 1937; Grondahl and Hancy, 1940; Hwang et al., 1947; Hwang et al., 1948; Hwang, 1953; Hwang, 1954; Doty and Bosma, 1956; Deloyers et al., 1957; Schlegel and Code, 1958; Botha, 1959; Carveth et al., 1962; Greenwood et al.,

1962; Manzano et al., 1964; Higgs and Ellis, 1965). It seems likely that such methods may influence the motility of the esophagus (Meltzer, 1899), as they do other parts of the gastrointestinal tract (Zontine, 1973).

In previous studies on the esophagus, few deleterious side effects from various neurectomies, with the exception of bilateral recurrent laryngeal neurectomy, have been encountered. In this latter case however, bilateral laryngeal paralysis occurs, and aspiration pneumonia has been considered or has often been a likely sequel (Long et al., 1959). For this reason most earlier workers have either avoided this neurectomy or have cautiously ensured that at least one recurrent laryngeal nerve remained intact. Alternatively, artificial airways have been introduced into the experimental animals. For example, Long et al. (1959) and Higgs and Ellis (1965) performed laryngectomies on their experimental dogs, but nevertheless, with their concern to maintain an airway, these and other workers must have unavoidingly severed or at least damaged one or more of the nerves that innervate the cervical esophagus since their reports do not mention any precautions to leave intact the important nerves in and around the laryngeal and tracheal areas. The nerves in this proximity are the pharyngoesophageal, recurrent and pararecurrent laryngeal nerves, and the anastomotic ramus between the pararecurrent and the internal branch of the cranial laryngeal nerves. Since damage to these esophageal nerves does interfere with the normal nervous control of the esophagus, tracheostomy or laryngectomy should not be used in critical studies of esophageal physiology. Furthermore, some doubt must be placed on the validity of results obtained after these preliminary 'precautions'.

In the present study, the only precautionary measure taken was to perform a bilateral laryngeal ventriculocordectomy on each dog before it entered the experiment. The healing fibrosis from this simple surgical procedure fixed the arytenoid cartilages in an abducted position, and a patent airway was thus ensured throughout the experiment. Jurica (1926) achieved similar results with electrocautery.

Six dogs underwent bilateral recurrent laryngeal neurectomies, either directly or indirectly by vagal transection. One, which died shortly after surgery, was found to have bilateral pneumothorax and aspiration asphyxia, but in the remainder no respiratory problems associated with laryngeal paralysis were observed despite the fact that, during the immediate postoperative recovery period most dogs exhibited profuse salivation in conjunction with varying degrees of dysphagia. However, the expected risk of aspiration asphyxia was diminished by using atropine sulphate to control the salivation during this period.

Therefore, for successful animal management in canine esophageal studies, this simple and effective technique of laryngeal ventriculocordectomy and postoperative atropine sulphate administration is recommended.

#### Cervical esophagus

The production of a paralysed cervical esophagus by bilateral transection of the pharyngoesophageal nerves confirms the functional involvement of these nerves in this region of the canine esophagus. These findings support the work of Hwang et al. (1948) who likewise examined their dogs by radiographic means. In addition, by electrically stimulating the pharyngoesophageal nerves, Lemere

(1932b) and Hwang et al. (1948) reached a similar conclusion.

In the present study, the caudal limit of esophageal paralysis varied between the two dogs and within each dog on different occasions, but remained between the level of the fifth cervical and the first thoracic vertebrae.

An unexpected and previously unreported finding following bilateral pharyngoesophageal neurectomy was that, in addition to a paralysed cervical esophagus, the thoracic esophagus also appeared paralysed at certain times during feeding. This occurred especially when the dogs swallowed large boluses in rapid succession, so that the paralysed cervical esophagus soon became fully packed with meal. With continued eating, the mass of meal was progressively shunted into the thoracic esophagus, and sometimes a solid column of meal would extend from the pharyngoesophageal junction to the diaphragm. This is contrary to the finding of Hwang et al. (1943) who reported that, following bilateral pharyngoesophageal neurectomy, the thoracic portion of the esophagus remained functionally normal.

That the thoracic esophagus was not primarily affected by pharyngoesophageal neurectomy was evidenced by the fact that, in the early stages of each meal and at other times during the meal, boluses passed through this region of the esophagus in an apparently normal manner. The thoracic esophagus appeared to function abnormally only when a mass of meal was pushed into the thoracic region in greater volume and at a more rapid rate than was normally experienced with the usual sized boluses. Perhaps a protective mechanism exists, with high threshold inhibitory receptors, which when stimulated (in this case by a large volume suddenly arriving at the thoracic inlet) would,

through the swallowing center, block any contraction waves passing through or being initiated in this region of the esophagus.

Alternatively, these observations could be interpreted as an indication of distal neuromuscular activity being at least partly related to or controlled by the preceding activity in more proximal esophageal segments. It is suggested that the normal function and passage of a bolus through any part of the esophagus is dependent to some extent on the normal neuromuscular responses and the passage of a bolus through the adjacent proximal segment. Longhi and Jordan (1971) reached a similar conclusion and Hendrix (1974) suggests that the control of this interdependence is mediated through the central swallowing center. A paralysed cervical esophagus would interrupt the wave sequence, and perhaps another wave type, albeit less efficient, could be involved distal to the paralysed region.

This phenomenon of temporary paresis and meal retention in an apparently normal segment of esophagus distal to a paralysed segment was similarly observed in two dogs after bilateral recurrent laryngeal neurectomy. Moreover, this phenomenon was also observed in three intact dogs: in the thoracic esophagus in two dogs, and in the cervical and thoracic esophagus of the other dog. If plate radiographs had been taken of these clinically normal dogs when the large mass of meal was temporarily in the thoracic region, a completely false diagnosis of achalasia or megaesophagus may have been indicated.

After bilateral transection of the pharyngoesophageal nerves, the cervical esophagus remained paralysed throughout the 45 day postoperative observation period. This contrasts with the findings of Hwang (1953) who reported that functional recovery occurred

"in the course of a few weeks", and his opinion was that the recurrent laryngeal nerves gained control of the motility of the cervical esophagus and were responsible for its recovery.

Previously, it has been stated that the recurrent laryngeal nerves were entirely sensory to the cervical esophagus (Chauveau, 1891). However, in this current experiment it was found that, when these nerves were transected at their origins, the cervical esophagus functioned abnormally in that the contraction waves appeared to be less efficient than before transection. One explanation could be that these nerves contribute motor supply to this region of the esophagus. Other workers have also concluded that the recurrent nerves are involved in the motor control of the cervical esophagus (Kronecker and Luscher, 1896; Lemere, 1932b; Hwang, 1953), although Lemere (1932b) states that the pararecurrent nerves are motor, secretomotor, and sensory to the lower two thirds of this region, and Hwang (1953) could, by electrically stimulating the recurrent laryngeal nerves at the base of the neck, produce a contraction of the cervical esophagus but only after transection of the pharyngoesophageal nerves and not before.

#### Cranial thoracic esophagus

When both recurrent laryngeal nerves were transected at their origins, no external signs of esophageal dysfunction were observed even though radiographic examination revealed that the esophagus in the cranial thoracic region was paralysed.

The distribution pattern of the left pararecurrent laryngeal nerve indicates that it is the major nerve involved in the function

of the cranial thoracic esophagus. In this study, the transection of the right recurrent laryngeal nerve produced a slight dysfunction in the cervical and cranial thoracic esophagus. Subsequently, when the left recurrent laryngeal nerve was transected, the extent of paralysis increased significantly to include paralysis of the cranial thoracic esophagus. Although this would support the structural findings, the possibility that the increase in the extent of paralysis was a summatory effect of both transected nerves can not be discounted. Such a possibility could be tested by further transection experiments in which only the left recurrent laryngeal nerve is sectioned.

In addition to the paralyzing effect on the cranial thoracic esophagus, some minor changes in motility were also seen immediately cranial and caudal to this region following bilateral recurrent laryngeal neurotomy. Contraction waves passed over these junctional zones in a less effective manner than before neurotomy. It seems reasonable, on structural grounds at least, to assume that these junctional zones correspond to esophageal regions over which the recurrent laryngeal nerves have only partial control, the balance of the innervation being from the pharyngoesophageal nerves cranially, and the thoracic vagi caudally.

In earlier accounts, Kronecker and Luscher (1896) found that the recurrent laryngeal nerves brought motor fibres to the cervical and cranial thoracic portions of the esophagus (species not cited), and Hwang et al. (1948) found that electrical stimulation of the recurrent laryngeal nerves at the base of the neck had no effect on the esophagus. As has already been pointed out earlier in this thesis, it is the cranial thoracic esophagus that is most richly supplied by the (left) pararecurrent laryngeal nerve, and hence to discover its

effect this nerve must be stimulated at its origin in the thorax and not in the base of the neck. Furthermore, when Hwang et al. (1948) stimulated the cervical vagus on either side, which would have meant excitation of the recurrent and pararecurrent laryngeal nerves, the result was contraction of the whole thoracic portion and the lowermost two to three centimeters of the cervical portion of esophagus. However, since of the recurrent branches, the left pararecurrent laryngeal nerve provides the greatest supply to this region, it could have been expected that the result reported by Hwang et al. (1948) would have been obtained by stimulation of the left vagus only, while stimulation of the right vagus would have resulted in contraction starting at a slightly more caudal level in the thorax.

#### Thoracic and abdominal esophagus

Bilateral vagotomy immediately caudal to the middle cervical ganglion resulted in a radiographic picture of paralysis of the thoracoabdominal esophagus, dilatation and meal retention in the thoracic portion, delays in the passage of material from the esophagus into the stomach, and meal regurgitation. This thesis is the first to report this particular bilateral vagotomy. Similar results could have been obtained with bilateral cervical vagotomy but the intrathoracic site was chosen as a standard procedure so that all dogs that underwent vagotomies also underwent intercostal thoracotomies. A cranial thoracic vagotomy with intact ansa subclavia also avoided all elements of Horner's syndrome.

When bilateral vagotomies were performed at more caudal levels, the extent of esophageal paralysis was correspondingly lessened. In fact, when vagotomies were performed immediately caudal to the origins of the recurrent laryngeal nerves, the cranial thoracic esophagus remained functionally normal as its nerve supply - the left pararecurrent laryngeal nerve -- remained intact. However, bilateral vagotomy immediately cranial to the origins of the recurrent laryngeal nerves produced the same effect as bilateral vagotomy immediately caudal to the middle cervical ganglion. Thus the implication is that between the middle cervical ganglia and the origins of their respective recurrent laryngeal nerves, the vagus nerves do not give off any significant innervation to the esophagus -- a fact that is also supported by the earlier dissections.

Similar findings of the functional involvement of the thoracic vagi in the canine esophagus have been well documented by previous workers (Chauveau, 1891; Starling, 1900; Jurica, 1926; Grondahl and Hancy, 1940; Hwang et al., 1947; Ingelfinger, 1950; Long et al., 1959; Carveth et al., 1962; Greenwood et al., 1962).

Concurrent with esophageal paralysis after vagotomy, there was also interference with the normal passage of material from the esophagus into the stomach. A smooth muscle gastroesophageal sphincter does exist and the evidence relating to its presence is discussed by Watson (1973). However, from observations made during this work, it appears that the terminal esophageal segment as well as the sphincter controls the passage of material from esophagus to stomach. Therefore when considering the functional mechanisms in this region the term gastroesophageal junction should be used.

A considerable number of workers have attempted to determine the function and control of the gastroesophageal junction, but still the normal operative mechanisms in this area are not clearly understood (Langley, 1898; Carlson et al., 1922; Knight, 1934; Burget and Zeller, 1936; Lendrum, 1937; Zeller and Burget, 1937; Hwang et al., 1947; Lerche, 1950; Donald, 1952; Hoag et al., 1954; Ingelfinger, 1958; Weiss et al., 1958; Schlegel and Code, 1958; Botha, 1959; Ellis et al., 1960; Carveth et al., 1962; Gahagan, 1962; Greenwood et al., 1962; Manzano et al., 1964; Michelson and Siegel, 1964; Higgs and Ellis, 1965; Higgs et al., 1965; Baue, 1966; Code and Schlegel, 1968). In addition many studies on the esophagus have been undertaken to probe into the pathogenesis of achalasia and similar conditions (Grendahl and Haney, 1940; Deloyers et al., 1957; Long et al., 1959; Ellis, 1962; Hofmeyr, 1966; Lawson and Pirie, 1966; Clifford and Gyorky, 1967; Clifford et al., 1967; Hoffer et al., 1967; Osborne et al., 1967; Cawley and Gendreau, 1969; Ellis and Olsen, 1969; Just-Viera and Haight, 1969; Sokolovsky, 1972). Even though achalasia like syndromes have been reproduced in some of the experimental dogs it is beyond the scope of this present study to examine in detail the physiology of the gastroesophageal junction.

Nevertheless it can be said that the more cranial the thoracic vagotomy, the more severe is the effect on the gastroesophageal junction. Double vagotomy a few centimeters cranial to the diaphragm produces only a very slight alteration in the gastroesophageal junction, whereas cranial thoracic bilateral vagotomy results in an almost total obstruction to food passage between esophagus and stomach. Controversy exists as to whether the functional zone is relaxed or in spasm following vagotomy and in achalasia. The observations from the present study cannot clarify this point, but needless to say the gastroesophageal junction was always less effective after any vagotomy.

### Some comments on normal esophageal motility

This study was not designed to investigate the normal progression of material along the esophagus, but during the work observations were repeatedly made that put in question the validity of the currently held concepts of esophageal physiology.

Textbooks on human and veterinary physiology state that the progression of food material along the esophagus occurs as one continuous muscular movement from the pharynx to the stomach (Starling, 1900; Davson and Eggleton, 1968; Hill, 1970; Hendrix, 1974). In the present study this traditionally accepted concept of esophageal motility was found to be an uncommon occurrence. Propulsive esophageal contraction waves did not necessarily directly follow each oropharyngeal deglutition sequence. Often a bolus would be projected from the pharynx into the cranial cervical esophagus where it would remain for some moments. Sometimes it would remain until a second bolus was swallowed and became fused with it before being propelled along the esophagus. Whereas at some other times, the single stationary bolus, after a short delay, would then be propelled towards the stomach.

Boluses moving in an apparently normal manner along the cervical esophagus were often stopped and delayed in the thoracic inlet region. These boluses usually continued towards the stomach only after being joined by a second bolus. In addition to these two sites where delays and fusion of boluses occurred, boluses sometimes decreased their rate of passage or even stopped momentarily in the cranial thoracic region of the esophagus.

These delays in esophageal motility contradict Ingelfinger's (1958) opinion "that peristalsis sweeps over the normal esophagus without interruption. Moreover, there is both radiologic and manometric evidence that the peristaltic wave starting in the pharyngeal constrictors passes through the upper esophageal sphincter zone and then the esophagus in unbroken succession both in man and the dog."

Hill (1970) does not mention reflux of gastric contents into the caudal part of the thoracic esophagus in the normal dog. In the human it is regarded as abnormal and a cause of esophagitis (Allison, 1972; Lichter, 1974). However, in this study, twenty two of the twenty five dogs examined radiographically exhibited significant reflux of material from the stomach into the caudal thoracic esophagus. Of these, the ten experimental dogs which were later examined post mortem showed no gross pathological signs of esophagitis.

These observations on clinically normal dogs contradict the accepted concepts of esophageal physiology. Hendrix (1974) reports that the nature of the food eaten can influence esophageal motility, and perhaps some of the differences between earlier reports and the present study could be accounted for on this basis. However, a more likely explanation is that the studies from which the current concepts were derived, were in fact carried out under conditions that were not truly physiological. This explanation is considered to be the more acceptable since the esophageal study recorded in this thesis was made on conscious dogs examined radiographically as they stood in a normal posture and freely ate barium impregnated meal.

It is clear from the foregoing that more detailed radiographic studies of the normal canine esophagus under truly physiological conditions are required.

## SUMMARY

The vagal nerve branches supplying the esophagus were carefully dissected in twenty one adult dogs, ten of which had previously undergone various surgical nerve transections. Esophageal function before and after nerve transection was studied radiographically; all radiographs were made on conscious dogs, trained to stand in a normal position freely eating barium impregnated meal.

Contrary to standard texts, it was found in the present study that each parent recurrent laryngeal nerve was always divided into two trunks: the recurrent laryngeal nerve proper which coursed directly to and terminated in the ipsilateral intrinsic laryngeal muscles (excluding cricothyroideus), and a more dorsally lying pararecurrent laryngeal nerve which coursed parallel to the recurrent proper but freely supplied many branches to the esophagus and trachea. These esophageal branches were especially numerous on the left side, as the left pararecurrent nerve richly supplied the cranial thoracic esophagus as well as the cervical portion. However, the right pararecurrent nerve supplied the cervical esophagus only. Each pararecurrent nerve then terminated in the anastomotic ramus from the internal branch of the ipsilateral cranial laryngeal nerve.

From the experimental studies it was concluded that the recurrent laryngeal nerves were functionally involved with the cranial thoracic esophagus, since this region was completely paralysed following bilateral recurrent laryngeal neurectomy. Some dysfunction was also seen in the cervical esophagus after this operation.

The cervical esophagus was primarily innervated and functionally controlled by the pair of pharyngoesophageal nerves which arose solely from the pharyngeal branch of each vagus nerve.

Caudal to the origins of the recurrent nerves, the thoracic and abdominal vagi supplied and controlled the caudal thoracic and abdominal portions of the esophagus.

The vagus nerves innervate and are involved in the normal function of the gastroesophageal junction, since bilateral cranial thoracic vagotomy considerably altered the activity of this region. However, double caudal thoracic vagotomy appeared only slightly to affect the function of the gastroesophageal junction.

Surgical approaches for transection of these esophageal nerves have been investigated and the various techniques are described.

APPENDIX I

## COURSE OF THE CANINE ESOPHAGUS

### INTRODUCTION

This description is based on observations of twenty one dissections for this thesis and elaborates the earlier account by Miller et al. (1964).

### ESOPHAGEAL REGIONS

The canine esophagus is a tubular musculomembranous organ which connects the pharynx with the stomach and conveys food from one organ to the other. In this thesis it is divided into cervical, thoracic, and abdominal portions.

#### Cervical Esophagus:

The cervical portion begins at the pharyngoesophageal junction opposite the middle of the axis dorsally, and the caudal border of the cricoid cartilage ventrally. Externally, the pharyngoesophageal junction lies at the caudal border of the cricopharyngeus muscle where this latter structure blends into esophageal muscle.

Although the esophagus commences in the midline. it immediately inclines to the left so that at the thoracic inlet it usually lies on the left side of the trachea, varying in position from left dorsal to left ventral. The cervical esophagus is mainly related to the left longus colli et capitis muscles dorsally, and the trachea ventrally and to the right.

On the left side, in the groove between the esophagus and longus capitus, lie the left common carotid artery, vagosympathetic trunk, internal jugular vein, and the tracheal lymphatic trunk. On the same side in the tracheoesophageal groove lie the left recurrent laryngeal nerves and small vessels. Conversely on the right side, all the corresponding structures are lateral or dorsolateral to the trachea. The cervical esophagus becomes continuous with the thoracic esophagus at the thoracic inlet.

#### Thoracic Esophagus:

The thoracic portion of the esophagus can be subdivided into cranial and caudal parts, with the junction between the two at the level of the tracheal bifurcation. Some authors, however, prefer to describe this portion in relation to the heart, and consequently divide it into the precardiac, cardiac and postcardiac parts.

The esophagus passes through the thoracic inlet ventral to the subvertebral muscles and on the left side of the trachea, and then passes through the mediastinum to the diaphragm. In this area the thoracic esophagus is situated in the most dorsal part of the mediastinum ventral to the thoracic vertebrae and to the longus colli and, more caudally, quadratus lumborum muscles. Here the esophagus is separated from these muscles, as in the neck region, by the prevertebral fascia.

In the wide dorsal part of the precardiac mediastinum, where the esophagus lies to the left of the trachea, the left common carotid artery crosses and makes a deep indentation on its ventral and left surfaces immediately caudal to the thoracic inlet.

Continuing caudally, the esophagus obliquely crosses the left surface of the trachea and comes to lie on its dorsal surface at the tracheal bifurcation. To reach this median position, the esophagus crosses the right aspect of the aortic arch, and in so doing is usually deflected to the right of the midline by the aortic arch and proximal descending aorta. Also dorsal to the heart and cranial to the tracheal bifurcation, the esophagus passes between two large blood vessels: on the right, the arch of the azygos vein, and on the left, the arch of the aorta.

As it passes between the pleural sacs the postcardiac esophagus lies close to or in the midline. The descending aorta obliquely crosses the left side of the esophagus between the fifth and ninth thoracic vertebrae and, from the sixth vertebra caudally, the thoracic duct and azygos vein lie on its right dorsolateral aspect.

More caudally, the esophagus takes a slight ventral dip to enter the esophageal hiatus of the diaphragm. This hiatus usually lies just to the left of the midline, and through it also pass the dorsal and ventral vagal nerve trunks and some small vessels.

In contrast to the esophagus in the cranial thorax, where it appears somewhat restricted and compressed by the trachea and adjacent structures, the thoracic esophagus distal to the tracheal bifurcation is released from these constraints and is freely suspended from the dorsal body wall by the mediastinal pleurae.

### Abdominal Esophagus:

The abdominal or terminal portion of the esophagus is very short and wedge shaped. The lumen of the esophagus ends at the cardiac opening of the stomach and the wall merges with similar gastric layers a short distance distal to the esophageal attachment of the phrenicoesophageal ligament. Since the termination of the esophagus on the stomach is in an oblique dorsoventral plane, the ventral part of the gastroesophageal junction lies at a level slightly cranial to the dorsal part. Consequently the esophagus distal to its diaphragmatic hiatus immediately joins the stomach dorsally, but ventrally makes an impression on the caudate lobe of the liver before joining the stomach.

The gastroesophageal junction usually lies ventral to the last thoracic vertebra but may vary a vertebral segment cranially or caudally.

### Lumen Diameter:

Throughout the course of the esophagus the lumen diameter varies. According to Miller et al. (1964) the least distensible parts of the esophagus are at the pharyngoesophageal junction, at the gastroesophageal junction, and where it passes through the thoracic inlet.

APPENDIX II

## STRUCTURE OF THE CANINE ESOPHAGUS

### INTRODUCTION

A number of accounts of the structure of the canine esophagus are available (Chauveau, 1891; Goetsch, 1910; Sisson, 1953; Trautmann and Fiebiger, 1957; Botha, 1958; Meiss et al., 1958; Bradley, 1959; Nickel et al., 1973; Mann and Shorter, 1964; Miller et al., 1964), but only in the latter two has the entire organ and its tunics been described in detail. The only histological study of each of the structural tissue layers throughout the length of the canine esophagus was that made by Mann and Shorter (1964). It is not surprising, therefore, that discrepancies exist, particularly in descriptions of the fibre arrangement in the muscular coat, in the presence or absence of an anatomical gastroesophageal sphincter, and in the level of the squamocolumnar epithelial change.

In this present study the histological features of the esophagus were examined in two dogs. Sections were taken from the pharyngoesophageal junction, the cervical and the thoracic portions of the esophagus, and the gastroesophageal junction. They were cut in longitudinal and transverse planes and then stained with either haematoxylin, eosin and alcian blue, or haematoxylin and van Gieson's stain.

## TISSUE LAYERS

The canine esophagus is a musculomembranous tubular organ, and the tissue layers in its wall have been described by Miller et al. (1964) as comprising four distinct coats or tunics: an innermost mucosal tunic, a flexible submucosal tunic, a thick muscular tunic, and an outermost fibrous tunic. In addition, Mann and Shorter (1964) described a gastroesophageal sphincter and a myenteric nerve plexus in the thick muscular tunic.

Mucosal Tunic:

Standard texts of human histology (Bloom and Fawcett, 1962; Ham, 1969) recognize three separate layers within the mucosal tunic: an innermost epithelial lining; a supporting lamina propria; and a thin layer of smooth muscle, the muscularis mucosae. Despite this, some veterinary authors diverge from this definition when describing the mucosal tunic, either to include the submucosal layer (Trautmann and Fiebiger 1957) or to exclude the muscularis mucosae (Mann and Shorter, 1964).

The canine esophagus is lined by a stratified squamous epithelium (Mann and Shorter, 1964). Previous workers (Trautmann and Fiebiger, 1957; Miller et al., 1964) have maintained that the epithelium is superficially cornified but no evidence was found to substantiate this claim in the study by Mann and Shorter (1964) nor in this present study after observations on two dogs (Figs. 46, 47, and 48).

It is generally agreed that the epithelium is a uniform layer throughout most of the esophagus, but changes have been reported in the vicinity of the pharyngeal and gastric junctions.

At the pharyngoesophageal junction, several authors (Goetsch, 1910; Mann and Shorter, 1964; Miller et al., 1964; Evans and DeLahunta, 1971; Nickel et al.: 1973) noted that the esophageal mucosa was demarcated from that of the pharynx by a plicated ridge of mucosa, the annular fold. This fold was most prominent ventrally and caused a local narrowing where the pharyngeal lumen meets the esophageal lumen. Mann and Shorter (1964) termed this constriction the isthmus esophagi, however Evans and DeLahunta (1971) and Nickel et al. (1973) call it the pharyngoesophageal limen.

Near the gastroesophageal junction, the typical esophageal epithelium changed abruptly to the columnar gastric type epithelium (Botha, 1958; Mann and Shorter, 1964). This epithelial change always occurred within the terminal 1 to 2 cm of the esophagus opposite the dorsal esophageal attachment of the phrenicoesophageal ligament, and, furthermore, was always proximal to the gastroesophageal junction. According to these workers the junction between the esophagus and stomach thus did not correspond to the level of the epithelial change, nor to the attachment of the phrenicoesophageal ligament, nor to the level of muscle fibre changes: findings which were fully substantiated in this present study (Fig. 48). In contrast, Gahagan (1962) defined the junction as the point of epithelial change, which, in his opinion, corresponded to the junction of the esophagus with the stomach and was marked externally by the point of attachment of the phrenicoesophageal ligament.

Gahagan thus concluded that there was no such structure as an abdominal esophagus - a view held only by himself and Allison (1948).

According to Mann and Shorter (1964) the columnar epithelium at the gastroesophageal junction was thrown into prominent folds with cores of smooth muscle of the muscularis mucosae. Meiss et al. (1958) described this structure as a mucosal valve or rosette. However, Botha (1958) stated that no special mucosal folds were present in the region of the cardiac opening of the stomach in the dog, but that a sharp crescentic fold arched over the left of the cardiac opening.

The lamina propria comprises loose connective tissue of collagenous, elastic and reticular fibres, small blood vascular and lymphatic vessels, lymphatic cells, fine nerves, and the ducts of esophageal glands (Fig. 47).

The smooth muscle of the muscularis mucosae was described by Mann and Shorter (1964) as being sparsely distributed in the upper esophagus, but increased in quantity caudally until, in the caudal third, a definite layer was formed. This layer was said to be basal to the glandular elements. Trautmann and Fiebiger (1957) described the muscularis mucosae as entirely lacking in the cranial half of the canine esophagus and only forming a continuous layer in the vicinity of the stomach. However, in two dogs examined for this present study a well defined muscularis mucosae layer was present throughout the thoracic and abdominal esophagus (Figs. 47 and 48) **but was** present in the cranial region as separated groups of smooth muscle cells. Moreover, the esophageal glands were always situated

outside the smooth muscle layer although in the terminal segment the glands interrupted the muscularis mucosae (Fig. 48).

#### Submucosal Tunic:

A broad submucosal tunic as described by Mann and Shorter (1964) and Miller et al. (1964) comprised glands, blood vessels, nerves and collagenous connective tissue, which loosely connected the mucosa to the muscular tunic. This allows the mucosal layer to be thrown into large and numerous longitudinal folds when the esophagus is empty and collapsed.

Mann and Shorter (1964) include the muscularis mucosae within the submucosal tunic, but it seems preferable to regard the muscularis mucosae as the defining boundary of the mucosa.

Throughout the canine esophagus, glands of a compound tubulo-alveolar type (Goetsch, 1970; Sisson, 1953) are a prominent feature of the submucosal layer. They are greatest in number and size in the lower third of the esophagus, and disappear from the submucosa opposite the site of squamocolumnar epithelial change (Fig. 48). Most authors refer to these esophageal glands as mucous glands (Trautmann and Piebiger, 1957; Mann and Shorter, 1964; Miller et al., 1964; Mickel et al., 1973). However, in a careful study, Goetsch (1910) was able to demonstrate that "the esophageal glands of the dog are composed of two kinds of cells, mucous cells and serous demilunes," confirming the statements of earlier workers (Klein, 1879; Renaut, 1897; Helm, 1907). In this present study, numerous serous demilunes were always present with the mucous glands, and this association with a constant finding in all fields examined at each level of the esophagus.

### Muscular Tunic:

Mann and Shorter (1964) reported that the muscular tunic or muscularis externa of the canine esophagus was entirely striated muscle, except for a short portion of the inner layer at the gastroesophageal junction.

Bradley (1959) was of the opinion that the muscular tunic consisted of one unbroken layer. However, Miller et al. (1964) described the actual fibre arrangement within this muscle tunic as comprising two oblique layers of striated muscle fibres arranged in a decussating spiral fashion, (each layer crossing the other nearly at right angles), so that the superficial fibres of one side became the deep fibres on the other side. The longitudinal lines of decussation being dorsal and ventral in position. This arrangement is consistent with the findings of Mann and Shorter (1964) who also found a clear differentiation into two layers with much intermingling of fibres across the thin dividing layer of connective tissue (Figs. 47 and 48).

Characteristic changes occur in the muscular tunic at each end of the esophagus where it joins with the pharynx and the stomach. At the pharyngeal end Miller et al. (1964) stated that those muscle fibres which originated from the cricoesophageal tendon blended with the most caudal fibres of the cricopharyngeus muscles but were arranged in a more transverse fashion. These fibres joined similar muscle fibres from the opposite side mid-dorsally. Subsequent fibres were disposed increasingly more obliquely so that the decussating spiral arrangement became established.

The changes at the distal or gastric end have been described by Sisson (1953), Mann and Shorter (1964) and Miller et al. (1964). These authors found that in the distal third of the esophagus the muscle fibres gradually changed direction and the decussations faded out so that, over the terminal segment, the spiral arrangement was replaced by an outer longitudinal and an inner circular muscle layer.

#### Gastroesophageal Sphincter:

In contrast to the general agreement that there is no special pharyngoesophageal thickening serving as an anatomical sphincter in the proximal extremity of the canine esophagus (Mann and Shorter, 1964; Miller et al., 1964), there has been some controversy over the existence of a distinct anatomical sphincter at the gastroesophageal junction in the dog. Experimental evidence for a mechanism serving as a physiological sphincter at both these sites has been well established (Schlegel and Code, 1958; Botha, 1959).

In a histological study, Mann and Shorter (1964) described an anatomically distinct gastroesophageal sphincter. In the terminal 1 to 2 cm of the esophagus they found that the inner circular striated muscle layer was abruptly replaced by a thickened layer of circularly disposed smooth muscle, and stated that this "forms a distinct anatomic basis for a gastroesophageal sphincteric mechanism". The change in type of the internal muscle occurred opposite the attachment of the phrenicoesophageal ligament whereas the outer longitudinal muscle fibres continued for a short distance beyond this ligamentous attachment before gradually blending with the smooth muscle of the stomach (Fig. 48).

### Nerve Plexus:

Mann and Shorter (1964) found no evidence for a submucosal plexus, but a myenteric plexus, containing ganglion cells, was present between the two layers of muscle throughout the length of the esophagus. Ganglion cells were very scanty in the upper third, increased toward the middle third, but were apparently absent in the region of the gastroesophageal sphincter. In contrast, Clifford and Gyorkey (1967) found that ganglion cells were most numerous in the region of the cardiac opening of the stomach.

### Fibrous Tunic:

According to Miller et al. (1964) the loose fibrous tunic or adventitia (Figs. 47 and 48) of the esophagus blended with components of the deep cervical fascia in the neck, endothoracic fascia in the thorax and with the transversalis fascia in the abdominal cavity. In addition, the esophagus was also largely covered by pleura in the thorax and by peritoneum in the abdomen.

## CONCLUSIONS

The main structural features of the canine esophagus as determined in a literature review and the material examined in this present study are:

- (i) the esophageal musculature is composed of two layers of striated muscle fibres. They are arranged in a decussating spiral fashion, except at the distal end where their directions tend to become more circular (inner layer) and longitudinal (outer layer).

(ii) an anatomical gastroesophageal sphincter, is present in the terminal 1 to 2 cm of the inner muscle layer, and comprises a thickened layer of circularly disposed smooth muscle.

(iii) the abrupt change from stratified squamous esophageal epithelium to columnar gastric epithelium, occurs within the esophageal tube, 1 to 2 cm proximal to the gastroesophageal junction.

(iv) the phrenicoesophageal ligament attaches at the level of the mucosal change, and thus a short abdominal esophagus does exist.

(v) a myenteric plexus with ganglion cells, is present between the muscle layers.

(iv) the esophageal glands contain mucous cells and serous demilunes.

APPENDIX III

SURGICAL TECHNIQUES FOR EXPERIMENTAL NEURECTOMIES  
OF THE VAGUS NERVES AND THEIR BRANCHES

Bilateral pharyngoesophageal neurectomy (Group I).

Each dog was placed in dorsal recumbency, and the skin over the cranial half of the ventral neck region was clipped and prepared for surgery. One midventral skin incision was made, extending caudally from the level of the basihyoid bone to about the middle of the neck. The basihyoid was readily identified as the transverse bony ridge immediately cranial to the thyroid cartilage. The incision was extended by blunt dissection through the subcutaneous muscle and underlying connective tissue (part of the superficial cervical fascia) until the sternohyoideus muscles were exposed. The large transversely lying hyoid venous arch, ventral to the basihyoid bone was carefully avoided.

The sternocephalic muscle was reflected laterally and the blunt dissection continued dorsally at the level of the cricoid cartilage, remaining close to the lateral borders of the ipsilateral muscles (sternohyoideus and sternothyroideus) lying on the ventral and ventrolateral aspects of the trachea. Care was taken to isolate and leave intact several large nerves which, running in a ventromedial direction, supplied these muscles at about this level.

Immediately dorsal and cranial to the insertion of sternothyroideus, the external branch of the cranial laryngeal nerve was observed as it passed along the pharyngolaryngeal border to innervate cricothyroideus deep to the proximal end of sternothyroideus.

On reflecting the carotid sheath and contents laterally, the caudal pharynx and the proximal cervical esophagus were visible and the pharyngoesophageal junction was identified dorsal to the cricoid cartilage. The small pharyngoesophageal nerve was found running caudoventrally over the dorsolateral aspect of the pharynx and passing on to the ventrolateral wall of the cervical esophagus. In five of the twenty one dogs dissected two trunks were present. In one other case no main trunk was present but a mass of fine nerves in a broad band spread over the most caudal part of the pharyngeal musculature and on to the esophagus. These nerves lay in particularly intimate contact with the muscle fibres of cricopharyngeus and the esophagus so that some muscle tissue was excised when the nerves were transected.

The pharyngoesophageal nerve was isolated and transected at the pharyngoesophageal junction close to the tracheoesophageal groove. This ensured that any innervation from this nerve to cricopharyngeus remained intact. The same procedure was used for the opposite side from the same midventral skin incision. A square wave electrical stimulator assisted in identifying these nerves.

#### Bilateral cranial thoracic vagotomy (Group II).

Each dog was placed in a left lateral recumbent position with its right forelimb drawn forwards. A skin incision parallel to and equidistant from the ribs was made over the second intercostal space for most of its length.

The muscles overlying the intercostal space were transected in the order, cutaneus trunci, latissimus dorsi, scalenus, serratus ventralis, followed by the intercostals. Latissimus dorsi was split parallel to its muscle fibres (oblique to the skin incision), while all the other muscles were transected parallel to the skin incision. The pectoral muscle group was reflected ventrally, and those muscles lying along the caudal border of the scapula were reflected cranially.

A pair of hand held band retractors provided a more satisfactory operating field than a pair of self retaining Gosset's retractors. The lung was packed off with warm saline moistened towels.

The ansa subclavia was identified lying over the caudoventral surface of the terminal part of the right subclavian artery. The large costocervical-vertebral venous trunk was related caudoventrally to the subclavian artery.

The vagus nerve was isolated and transected immediately caudal to the middle cervical ganglion, this point being medial to the right subclavian artery. The neurectomy site was chosen so that, distally, the ansa subclavia remained attached to the vagus and, proximally, the sympathetic trunk remained in connection with the vagosympathetic trunk. According to Mizeres (1955, 1957, 1958) this would leave intact the great majority of sympathetic fibres on the right side.

As soon as the right thoracotomy wound was closed, the animal was rolled over and placed in a right lateral recumbent position with its left forelimb drawn forwards, so that the left vagus nerve

could be approached through the second intercostal space on the left side.

On the left side the relationships are slightly different with both the ansa subclavia and the sympathetic trunk terminating as one, or close together, on the middle cervical ganglion. The main part of the left thoracic vagus nerve and all the small nerves passing caudally from the middle cervical ganglion were transected immediately caudal to this ganglion, but the ansa subclavia and the sympathetic trunk remained intact.

On closing the thoracotomy wound on each side using Leonard's (1963) method, monofilament nylon was used to bind the ribs together. However, it was found that the second and third ribs were too rigid and too far apart to enable them to be drawn together for good surgical closure of the intercostal space. Subsequent problems with pneumothorax resulted and the first dog (06) died seventy two hours after the operation. The problem was solved with the remaining dog in this group by operating through the third intercostal space and a satisfactory closure of the thoracic cavity was achieved.

#### Recurrent laryngeal neurectomies (Group III).

The actual thoracotomy operations were similar to those for Group II. The right recurrent laryngeal nerve was approached through the third intercostal space on the right side. It was isolated at its origin from the right vagus nerve immediately caudal to the right subclavian artery and was then transected as close as possible to its origin.

The left recurrent laryngeal nerve was approached through the fourth intercostal space on the left side. It was isolated and transected at its origin from the left vagus nerve as the latter passed over the left lateral aspect of the aorta near the ligamentum arteriosum.

Before transection, electrical stimulation and external palpation of the larynx confirmed identification of each recurrent laryngeal nerve.

#### Double bilateral thoracic vagotomy (Group IV).

The surgical approaches were identical to those for Group III. On each side the origin of the recurrent laryngeal nerve was carefully isolated and the left and right vagus nerves were each transected immediately caudal to these identified levels. Seven days later, the thoracotomy wounds were reopened and each vagus nerve was transected immediately cranial to the origin of its respective recurrent laryngeal nerve.

#### Caudal thoracic vagotomies (Group V).

In one dog a dorsal trunk caudal thoracic vagotomy was performed. The approach was through the ninth intercostal space on the left side and the level of vagotomy was just caudal to the point of confluence where the left and right vagal branches formed the dorsal vagal trunk. This point was estimated to be about 6 to 7 cm cranial to the diaphragm in this 18 kg adult dog. Seven days later the ventral trunk was transected opposite the site of the dorsal vagal trunk transection. This was achieved through a thoracotomy

in the sixth intercostal space on the right side.

In the second dog a double trunk vagotomy was performed through the seventh intercostal space on the left side. Each vagal trunk was transected at a similar level to that in the first dog.

APPENDIX IV

SCHEDULE OF POSTOPERATIVE DAYS ON WHICH EACH DOG  
WAS RADIOGRAPHICALLY EXAMINED

<u>Group</u>	<u>Dog Reference Number</u>	<u>Postoperative Days</u>	
		<u>After First</u> <u>Neurectomy</u>	<u>After Second</u> <u>Neurectomy</u>
I	03	2, 6, 15.	
	05	2, 9, 16, 45.	
II	06	1.	
	10	1, 6, 9, 24.	
III	14	1, 3, 6.	1, 3, 8.
	15	1, 3, 6,	1, 3, 8.
IV	12	1, 2, 6.	1, 2, 9.
	13	1, 5.	1.
V	02	4, 6.	4, 11, 14.
	04	1, 5, 15.	

APPENDIX V

### HISTOLOGICAL STAINING TECHNIQUES

Specimens were dehydrated in ethyl alcohol and cleared in chloroform and xylol.

One series of twenty sections was stained with a modified haematoxylin and eosin staining technique as follows: dewax and hydrate: stain in Mayer's haemalum, 10 minutes; rinse in tap water: "blue" in Scott's tap water, 2 minutes; rinse in tap water; stain in 1% eosin yellow water soluble, 90 seconds; rinse rapidly in tap water: dehydrate, clear and mount.

Another series of twenty sections was stained with a van Gieson's stain which utilised the precise and sharp staining features of acid fuchsin, and the permanent staining properties of ponceau S fuchsin. This was accomplished by incorporating a mixture of both these dyes in the van Gieson's stain. The staining schedule was as follows: dewax and hydrate; stain in celestin blue, 10 minutes; rinse in tap water; stain in Mayer's haemalum, 10 minutes; rinse in tap water; "blue" in Scott's tap water, 2 minutes; rinse in tap water; stain in modified van Gieson's stain, 6 minutes; rinse rapidly in tap water; dehydrate, clear and mount.

FIGURES

Fig.1 Photograph of the radiographic equipment and perspex dog crush used in the experimental studies. The cine-camera on the rear of the image intensifier is not visible, nor is the videotape recorder.




Fig.2 Branches from the vagus nerves that innervate the canine esophagus, ventral view (diagrammatic reconstruction and not to scale).

DVB	dorsal vagal branches, right and left
DVT	dorsal vagal trunk
LTV	left thoracic vagus
PRLN	pararecurrent laryngeal nerve, left
PRX	pharyngeal ramus of vagus nerve, left
VST	vagosympathetic trunk, left
VVB	ventral vagal branches, right and left
VVT	ventral vagal trunk
IX	glossopharyngeal nerve, right
X	vagus nerve, left
an.r.	anastomotic ramus of internal branch of cranial laryngeal nerve, right
c.c.s.g.	cranial cervical sympathetic ganglion, right
c.l.n.	cranial laryngeal nerve, right
d.g.v.	distal ganglion of vagus, right
es.	esophagus
ex.b.	external branch of cranial laryngeal nerve, right
m.c.s.g.	middle cervical sympathetic ganglion, right
ph.m.	pharyngeal musculature
r.l.n.	recurrent laryngeal nerve, right
r.t.v.	right thoracic vagus
tr.	trachea
v.g.c.	vagoglossopharyngeal connection, right



Fig.3 The pharyngoesophageal nerve, left lateral view  
(diagrammatic reconstruction and not to scale).

PEN	pharyngoesophageal nerve
PRX	pharyngeal ramus of vagus nerve
VST	vagosympathetic trunk
IX	glossopharyngeal nerve
X	vagus nerve
c.c.s.g.	cranial cervical sympathetic ganglion
c.l.n.	cranial laryngeal nerve
cr.ph.	cricopharyngeus muscle
c.t.	cricothyroides muscle
d.g.v.	distal ganglion of vagus nerve
es.	esophagus
ex.b.	external branch of cranial laryngeal nerve
h.p.	hyopharyngeus muscle
t.h.	thyrohyoideus muscle
th.ph.	thyropharyngeus muscle
tr.	trachea
s.t.	sternothyroides muscle, cut end

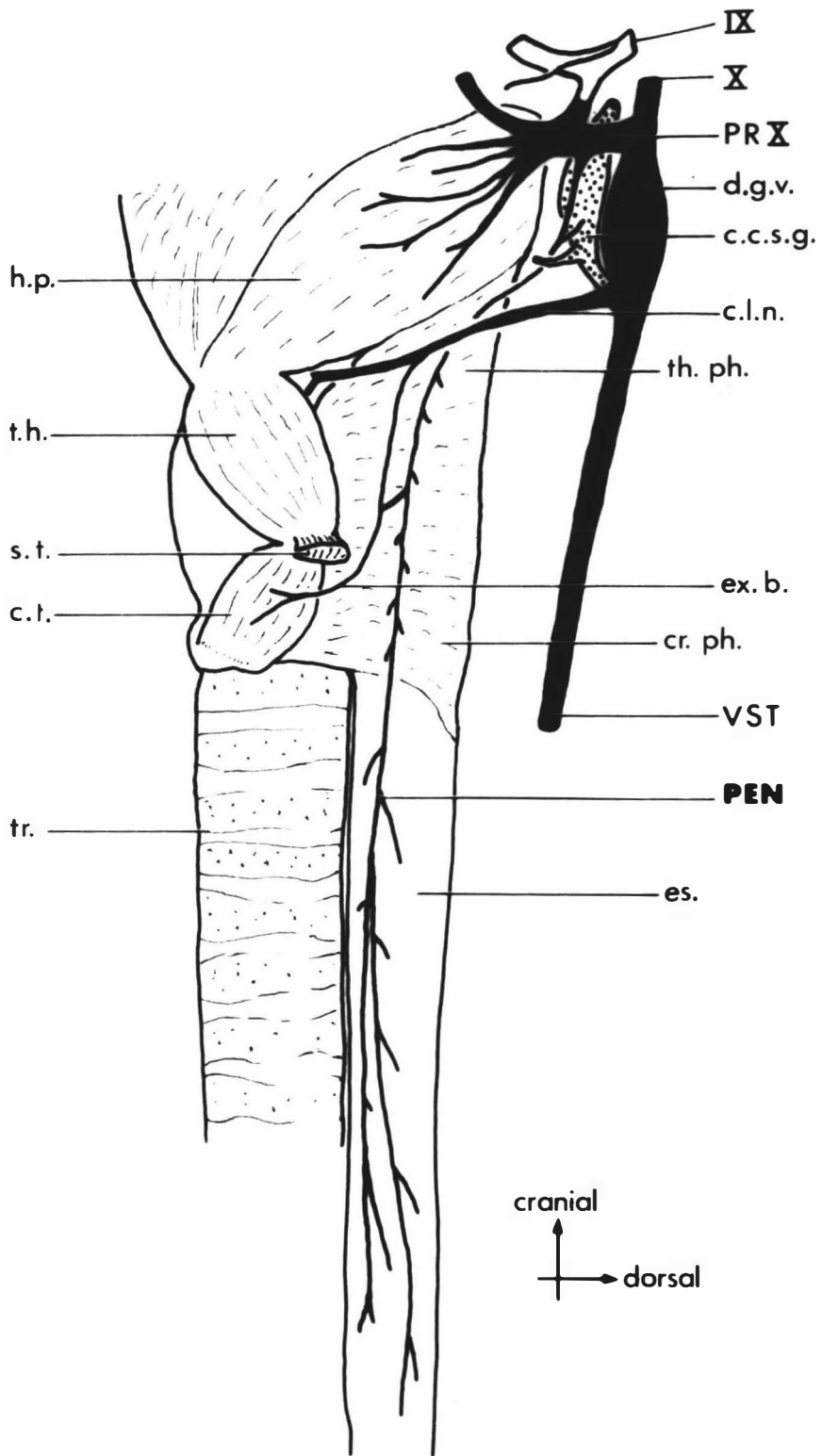


Fig.4 Origin of the pharyngoesophageal nerve, left lateral view (diagrammatic reconstruction and not to scale). Note that the pharyngoesophageal nerve is a distinct nerve from its origin in the pharyngeal ramus of the vagus, across and caudal to the cranial cervical sympathetic ganglion. This, the most common pattern, was found in thirteen dogs.

PEN	pharyngoesophageal nerve
PRX	pharyngeal ramus of vagus nerve
VST	vagosympathetic trunk
IX	glossopharyngeal nerve
X	vagus nerve
c.c.s.g.	cranial cervical sympathetic ganglion
c.l.n.	cranial laryngeal nerve
c.s.n.	carotid sinus nerve
d.g.v.	distal ganglion of vagus nerve
hy.ph.	nerve branches to hyopharyngeus muscle
l.r.g.	lingual ramus of glossopharyngeal nerve
p.n.	pharyngeal nerve
s.r.	sympathetic nerve root
v.g.c.	vagoglossopharyngeal connection

Fig.5 Origin of the pharyngoesophageal nerve, left lateral view (diagrammatic reconstruction and not to scale). Note that the nerve fibres of the pharyngoesophageal nerve are closely associated with the cranial cervical sympathetic ganglion and emerge from it in the sympathetic nerve root. This pattern was found in eight dogs.

\* route of the pharyngoesophageal nerve fibres  
Key as for Figure 4

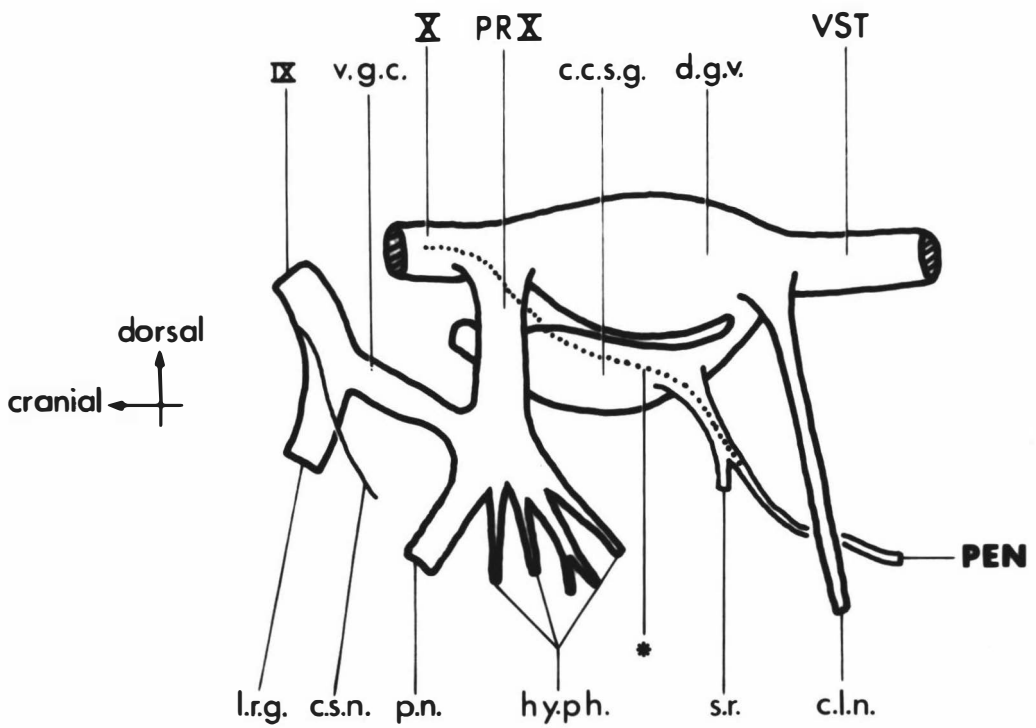
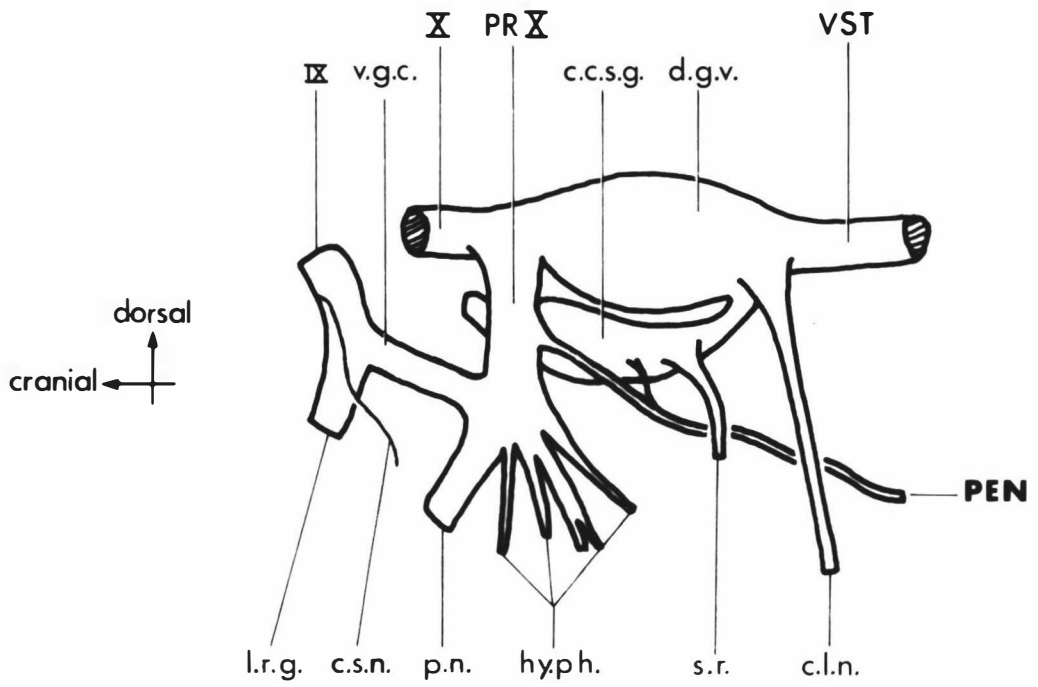


Fig. 6 The right pararecurrent laryngeal and recurrent laryngeal nerves, right lateral view (diagrammatic reconstruction and not to scale).

PRLN	pararecurrent laryngeal nerve
VST	vagosympathetic trunk
an.r.	anastomotic ramus of internal branch of cranial laryngeal nerve with pararecurrent laryngeal nerve
a.s.	ansa subclavia
ca.l.n.	caudal laryngeal nerve
c.l.n.	cranial laryngeal nerve
c.t.s.g.	cervicothoracic sympathetic ganglion
es.	esophagus
ex.b.	external branch of cranial laryngeal nerve
m.c.s.g.	middle cervical sympathetic ganglion
p.e.j.	pharyngoesophageal junction
R.subcl.a.	right subclavian artery
r.l.n.	recurrent laryngeal nerve
s.t.	sympathetic trunk
tr.	trachea

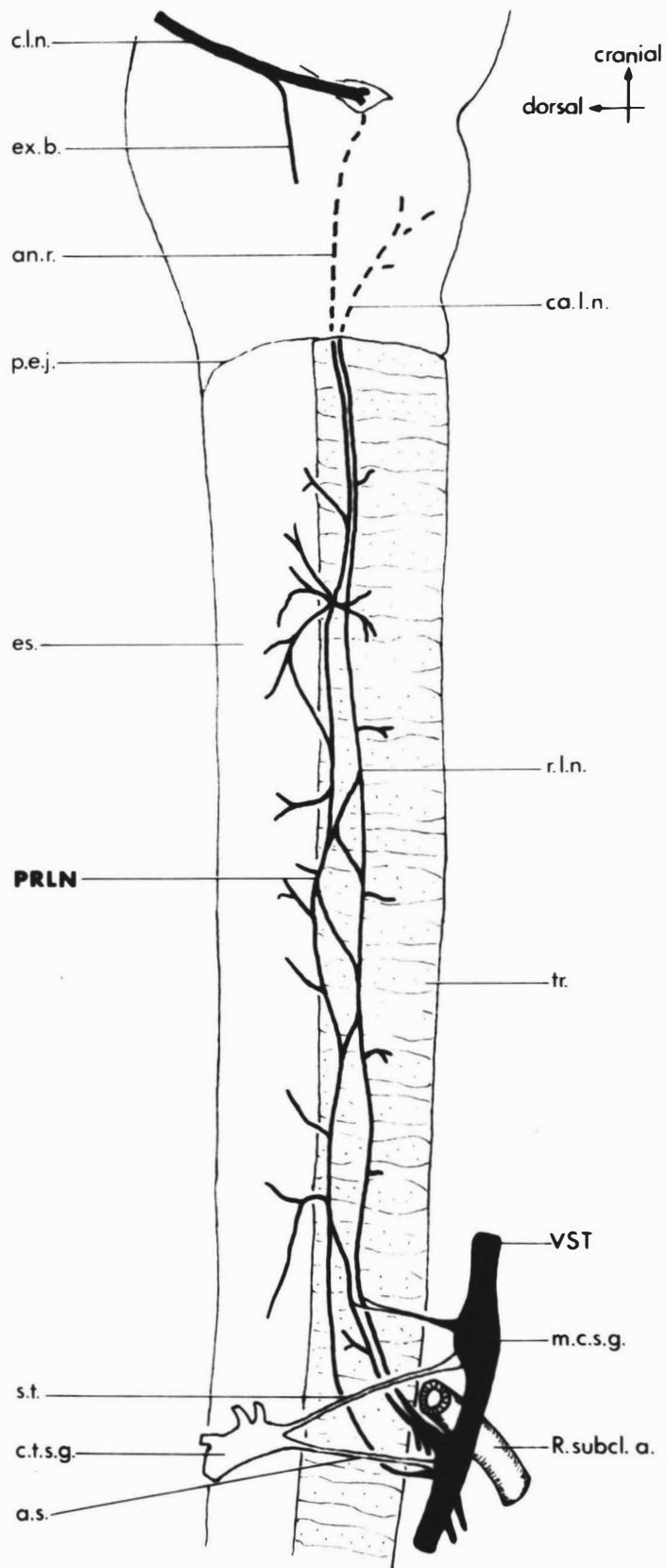


Fig.7 The left pararecurrent laryngeal and recurrent laryngeal nerves, left lateral view (diagrammatic reconstruction and not to scale).

PRLN	pararecurrent laryngeal nerve
a.	arch of aorta
an.r.	anastomotic ramus of internal branch of cranial laryngeal nerve with pararecurrent laryngeal nerve
ca.l.n.	caudal laryngeal nerve
c.l.n.	cranial laryngeal nerve
es.	esophagus
ex.b.	external branch of cranial laryngeal nerve
m.c.s.g.	middle cervical sympathetic ganglion
p.e.j.	pharyngoesophageal junction
p.t.	pulmonary arterial trunk
r.l.n.	recurrent laryngeal nerve
tr.	trachea

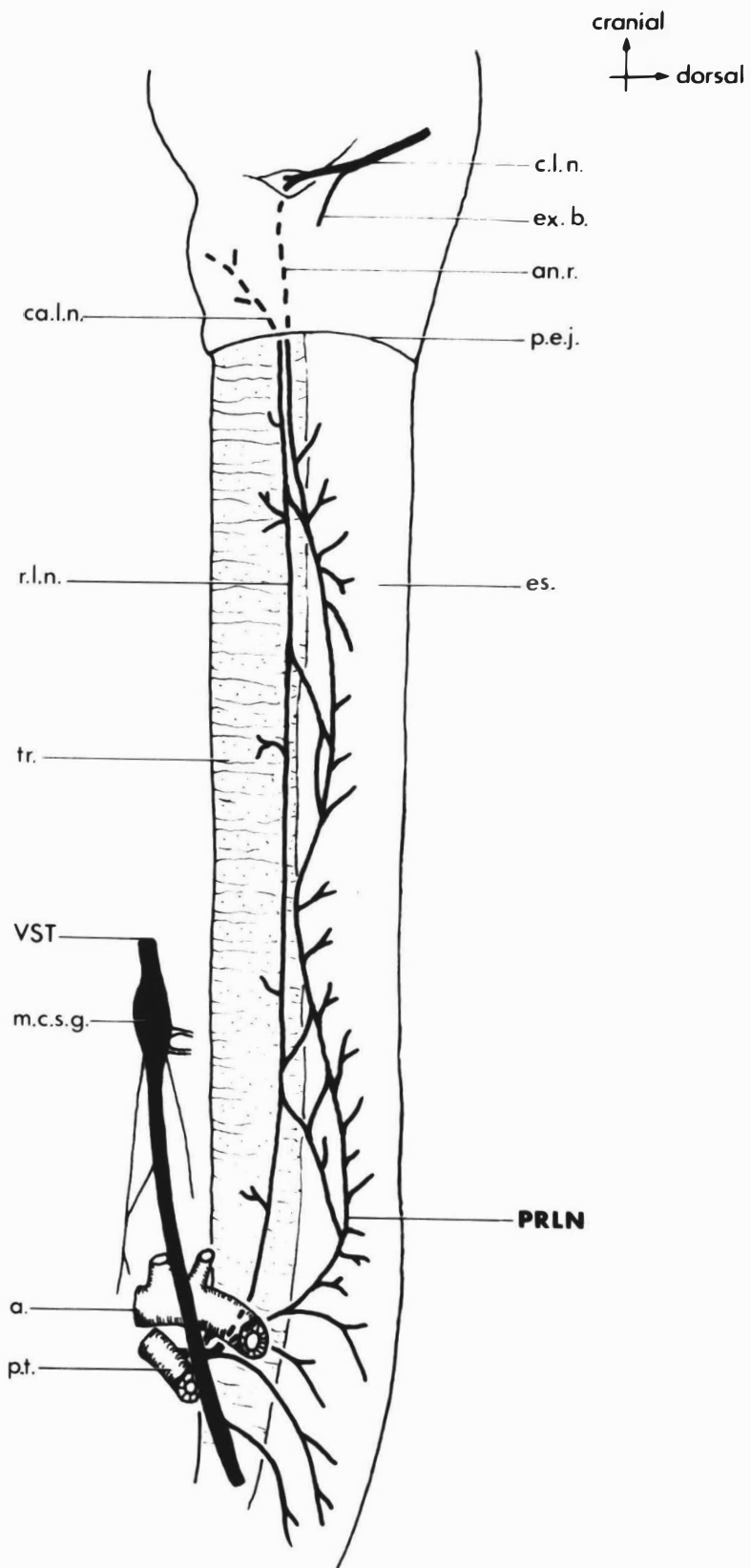


Fig.8 Origin of the left pararecurrent laryngeal and recurrent laryngeal nerves, left lateral view (diagrammatic reconstruction and not to scale). The single root origin for both nerves was found in eleven dogs.

LTV	left thoracic vagus
PRLN	pararecurrent laryngeal nerve
a.	arch of aorta
b.t.	brachiocephalic arterial trunk
l.a.	ligamentum arteriosum
l.s.a.	left subclavian artery
p.t.	pulmonary arterial trunk
r.l.n.	recurrent laryngeal nerve

Fig.9 Origin of the left pararecurrent laryngeal and recurrent laryngeal nerves, left lateral view (diagrammatic reconstruction and not to scale). The multiple vagal root origin for these nerves was found in six dogs.

Key as for Figure 8.

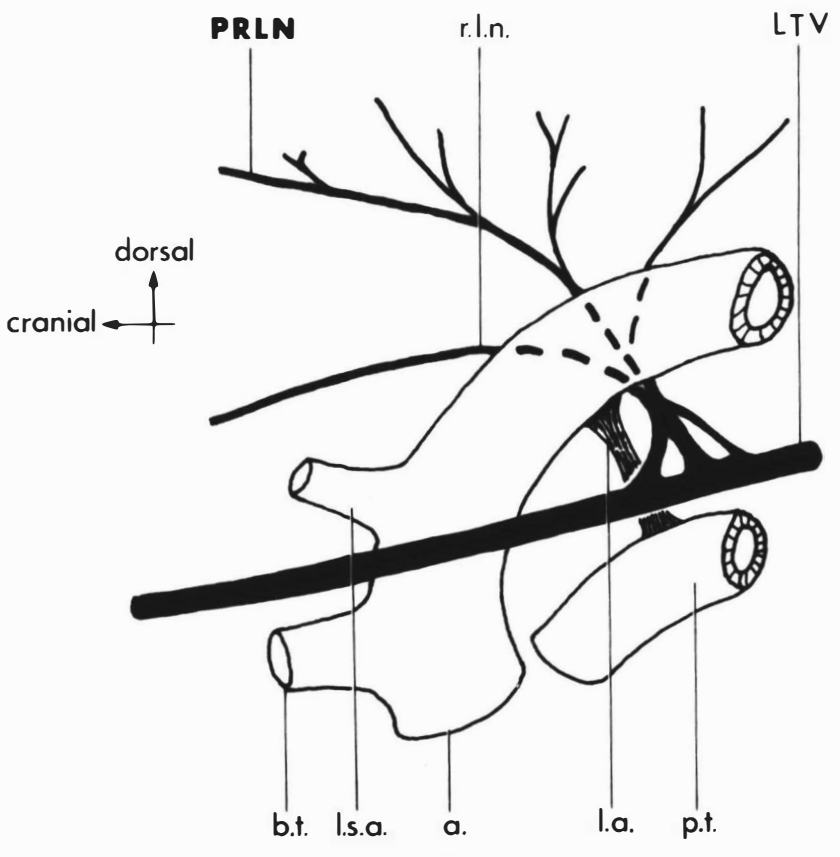
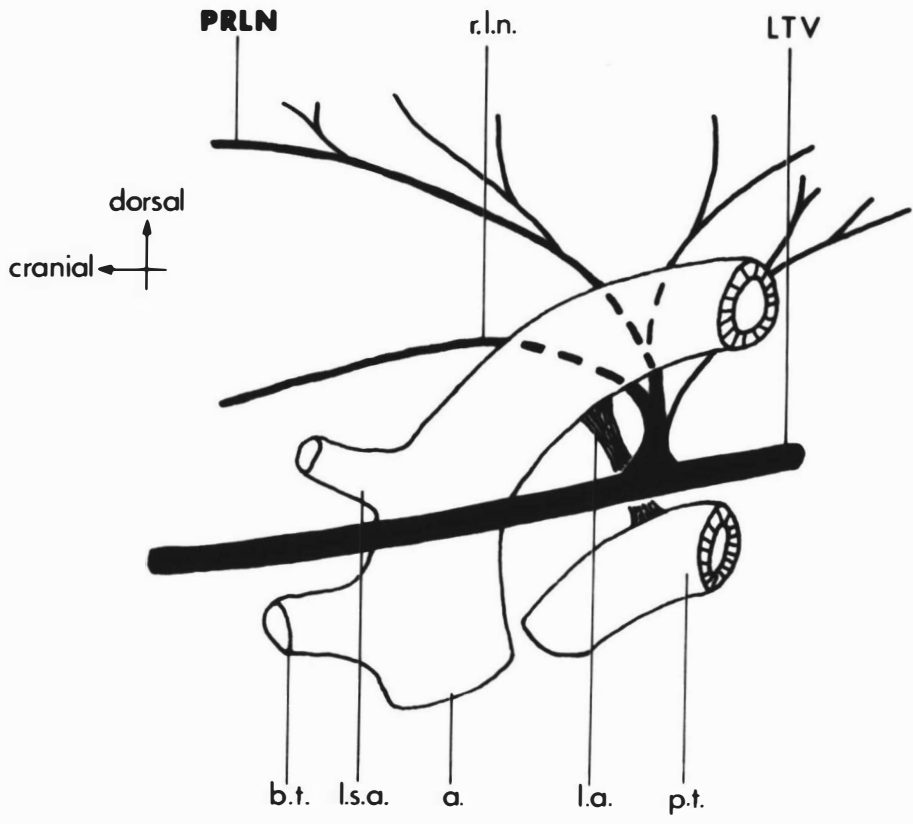


Fig.10 Transverse section through the left pararecurrent and recurrent laryngeal nerves immediately caudal to the larynx. Note the common nerve sheath (arrow) enclosing two separate nerve trunks. (Haematoxylin and van Gieson's; x 130) cf. Figure 11.

Fig.11 Transverse section through the left pararecurrent and recurrent laryngeal nerves caudal to the larynx. This section was taken from another dog and at a level slightly more caudal than that in Figure 10. Note the two separate nerve trunks. (Haematoxylin and van Gieson's; x 130) cf. Figure 10.

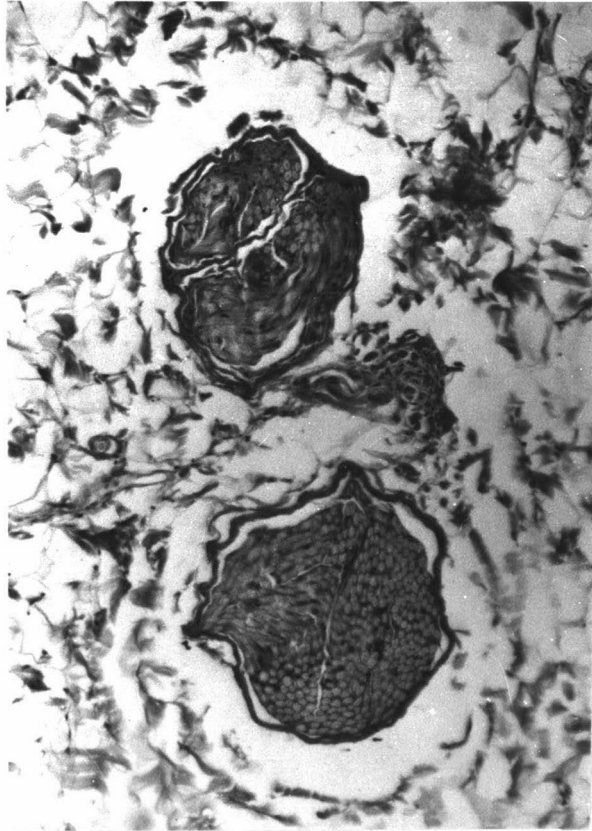
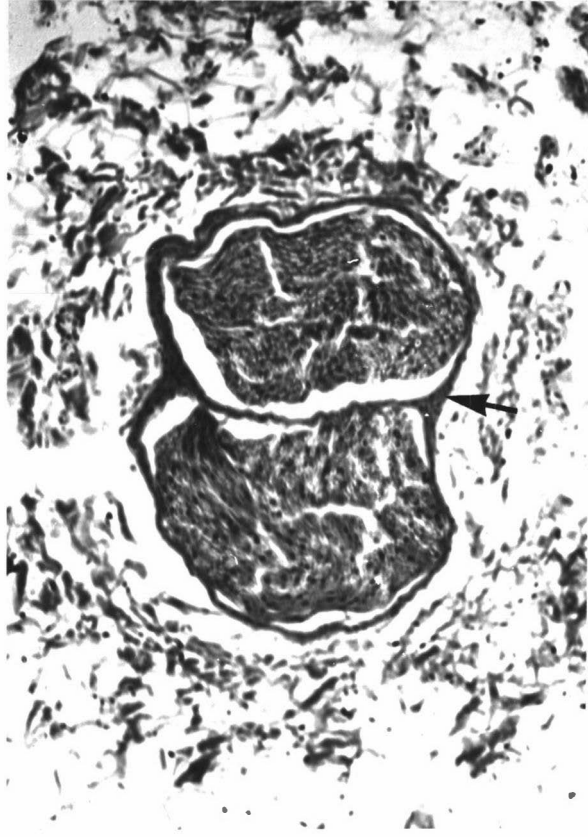


Fig.12 The main vagal nerve branches to the thoracic esophagus, ventral view (diagrammatic reconstruction and not to scale).

DVT	dorsal vagal trunk
LDB	left dorsal vagal branch
LTV	left thoracic vagus
LVB	left ventral vagal branch
PRLN	pararecurrent laryngeal nerve
RDB	right dorsal vagal branch
RVB	right ventral vagal branch
VVT	ventral vagal trunk
m.c.s.g.	middle cervical sympathetic ganglion
r.l.n.	recurrent laryngeal nerve
r.t.v.	right thoracic vagus
R 6	level of the head of the sixth rib
R 7/8	level between the heads of ribs seven and eight
R 8	level of the head of the eighth rib
R 10/11	level between the heads of ribs ten and eleven

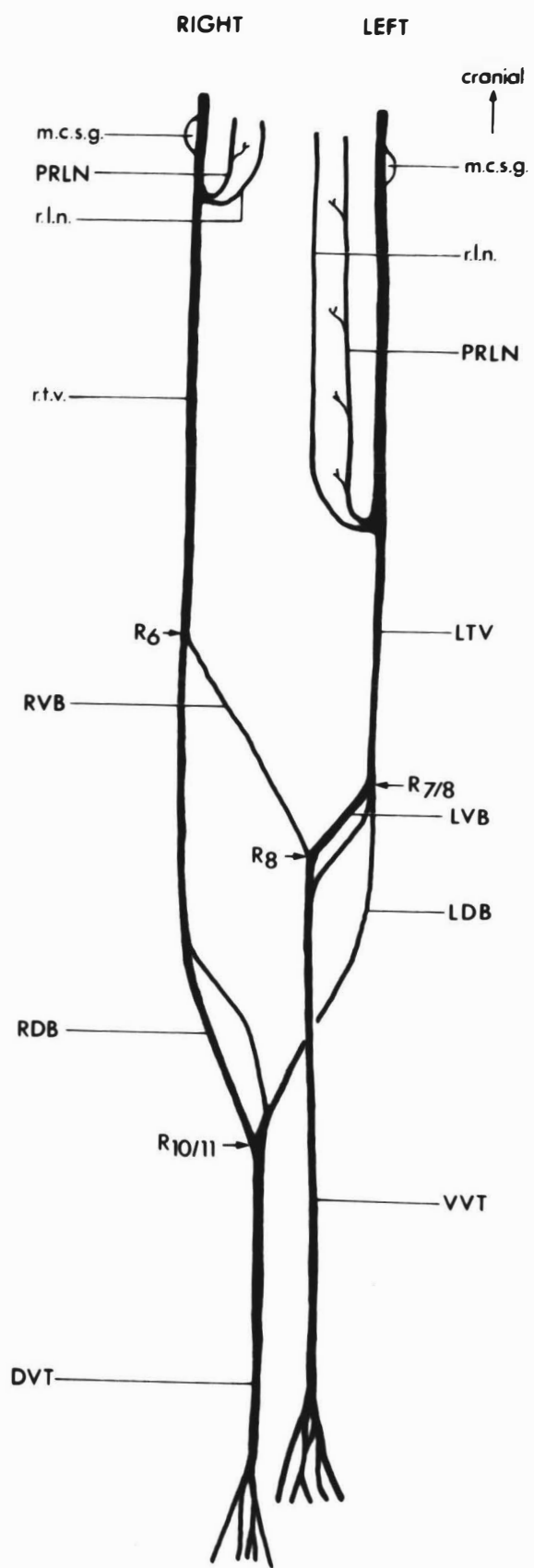


Fig.13 Branches from the vagus nerves to the thoracic and abdominal esophagus, right lateral view (diagrammatic reconstruction and not to scale).

DVT	dorsal vagal trunk
LVVB	left ventral vagal branch
RDVB	right dorsal vagal branch
RVVB	right ventral vagal branch
VST	vagosympathetic trunk
VVT	ventral vagal trunk
c.t.s.g.	cervicothoracic sympathetic ganglion
d.	diaphragm
es.	esophagus
R.subcl.a.	right subclavian artery
r.t.v.	right thoracic vagus
tr.	trachea

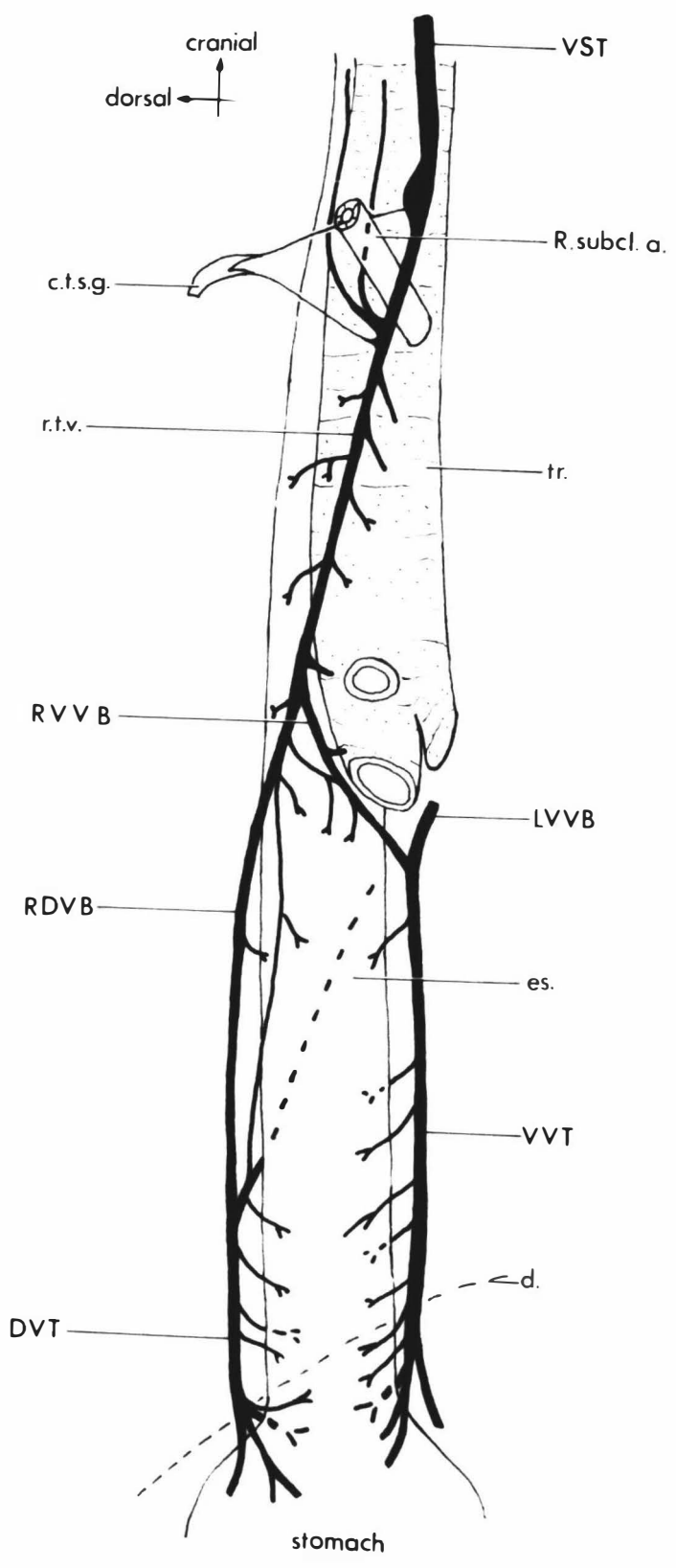


Fig.14 Branches from the vagus nerves to the thoracic and abdominal esophagus, left lateral view (diagrammatic reconstruction and not to scale).

DVT	dorsal vagal trunk
LDVB	left dorsal vagal branch
LVVB	left ventral vagal branch
LTV	left thoracic vagus
RVVB	right ventral vagal branch
VVT	ventral vagal trunk
a.	arch of aorta
d.	diaphragm
es.	esophagus
tr.	trachea

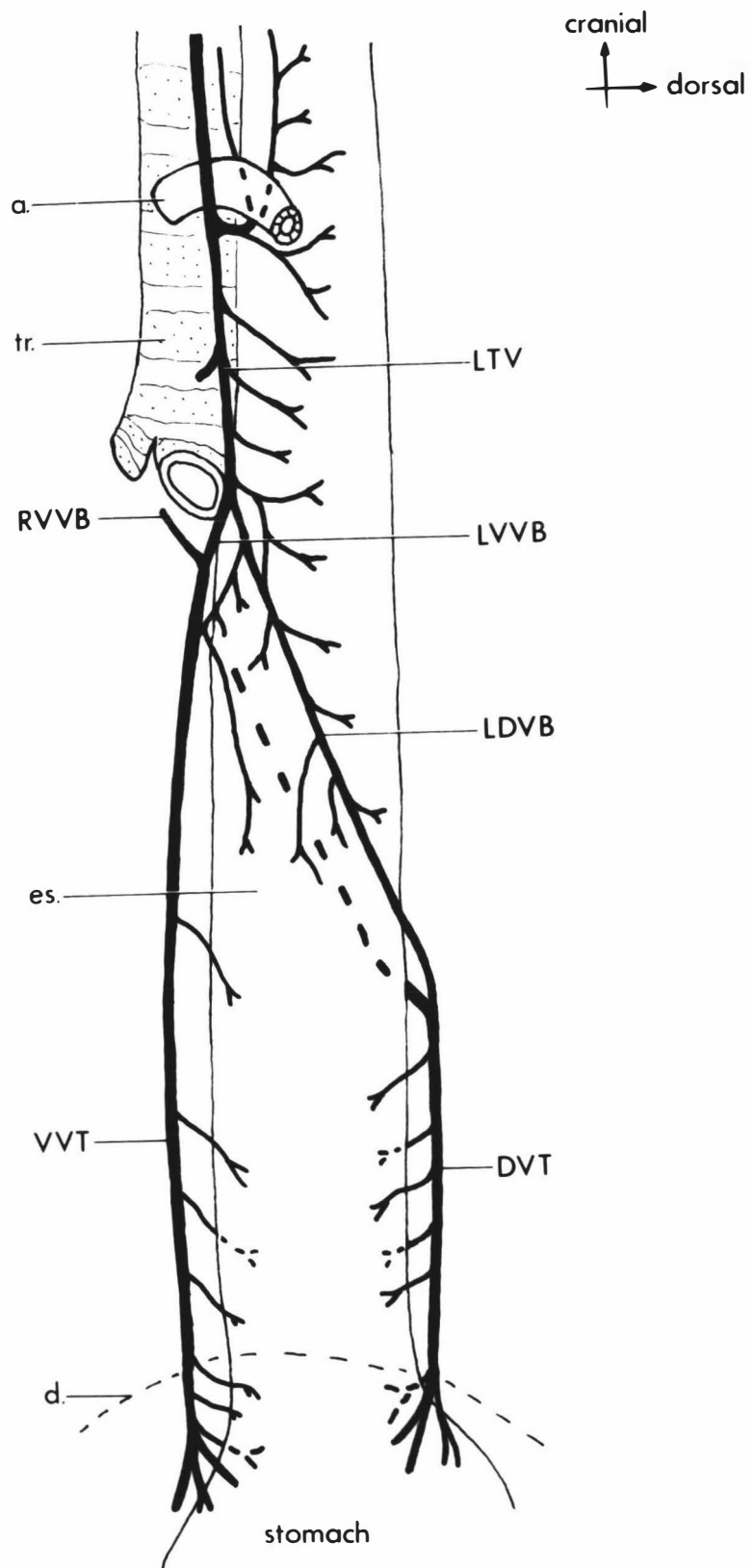


Fig.15 A frame from a cineradiographic film of a Group I dog (05) taken before neurectomy showing a bolus as it passed cleanly through the cervical esophagus.

Fig.16 A frame from a cineradiographic film of a Group I dog (05) taken two days after bilateral pharyngoesophageal neurectomy showing the paralysed cervical esophagus packed full of barium impregnated food. The paralysis and mass of swallowed food can be seen to extend caudally beyond the sixth cervical vertebral level (arrow) into the thoracic inlet.

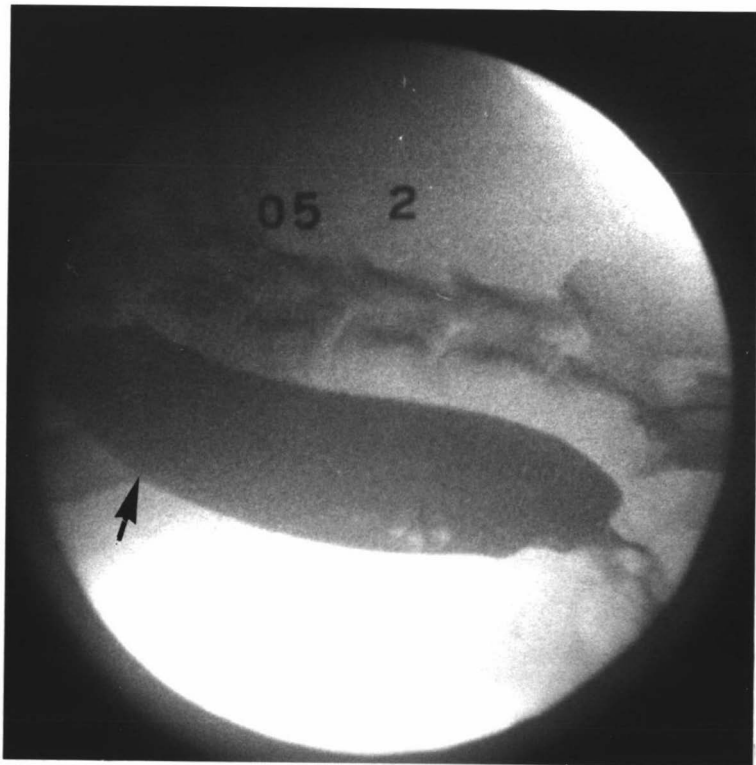
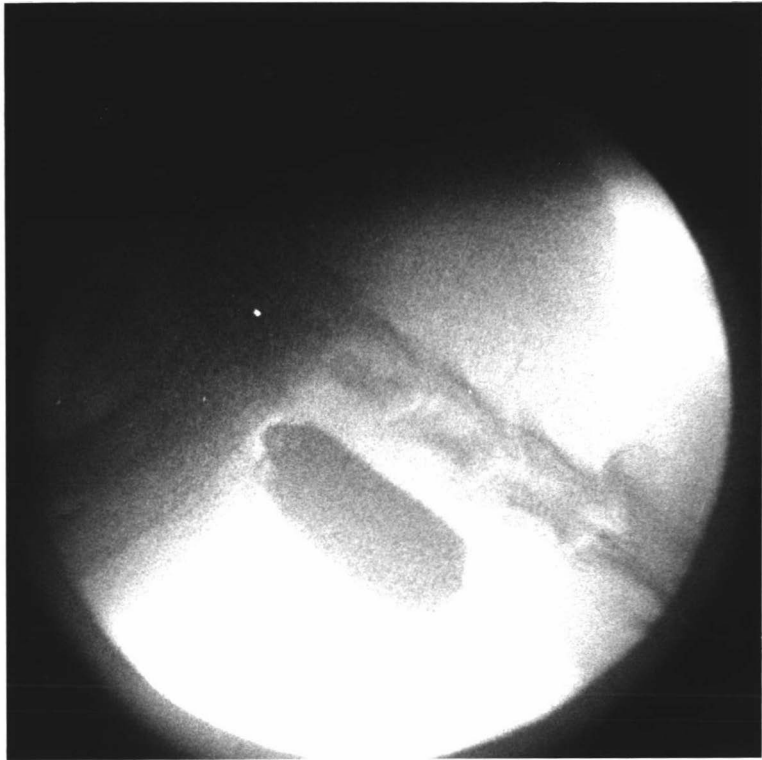


Fig.17 A frame from a cineradiographic film of a Group I dog (05) taken two days after bilateral pharyngoesophageal neurectomy showing the thoracic esophagus packed full of barium impregnated food. A small ineffective esophageal contraction (arrow) can be seen at the moment it started at the thoracic inlet.

Fig.18 A frame from a cineradiographic film of a Group I dog (05) taken nine days after bilateral pharyngoesophageal neurectomy, showing the distal part of the swallowed mass in the paralysed cervical esophagus at the moment it was pinched off by an effective esophageal contraction at a level between the fifth and sixth cervical vertebrae (arrow).

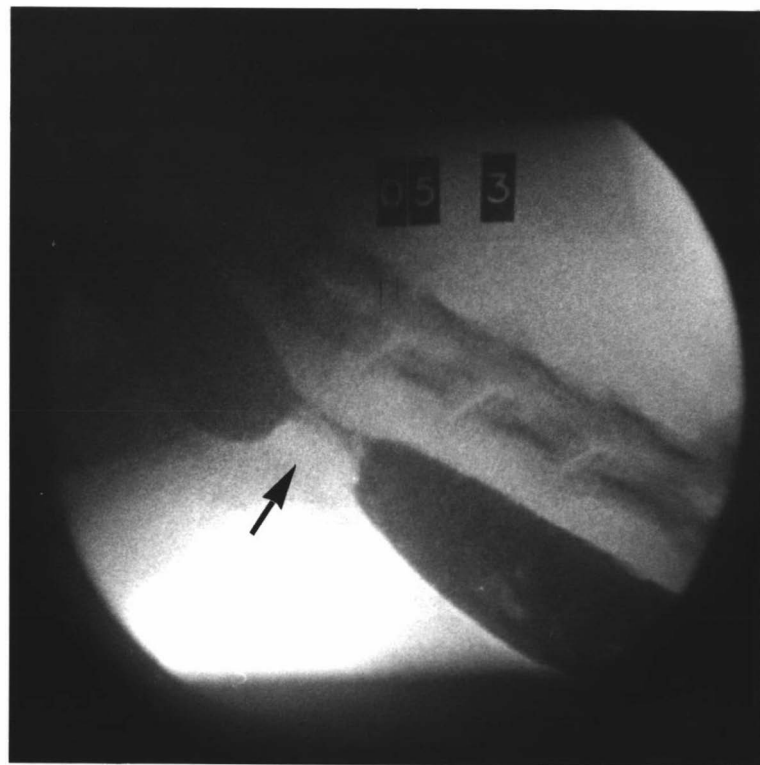
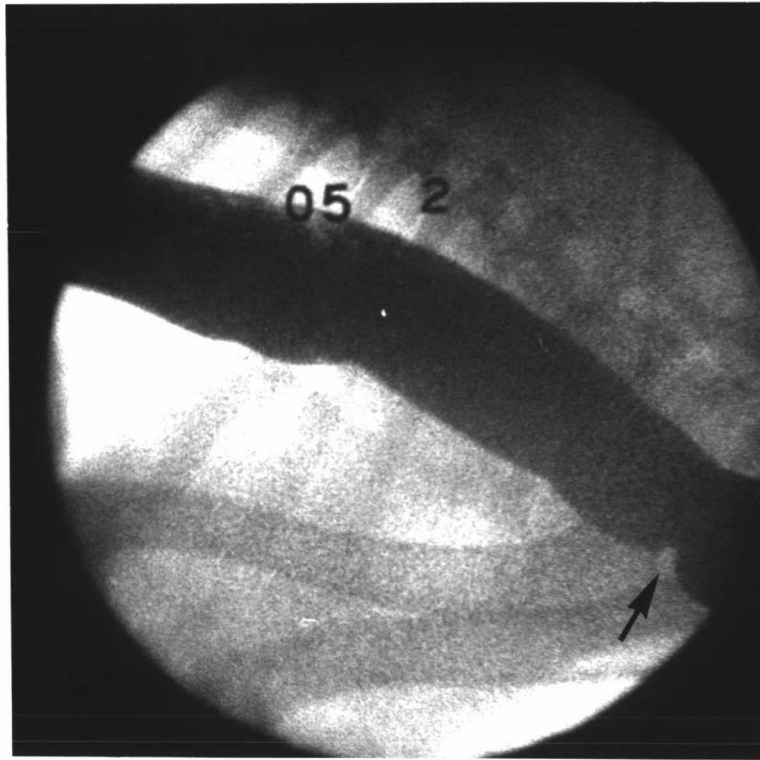


Fig.19a A lateral radiograph of a Group II dog (O6) taken one day after bilateral cranial thoracic vagotomy showing the paralysed thoracic esophagus dilated with gas. A bolus of meal (arrow), which was given as a test swallow, lies in the post-cardiac region of the esophagus. This dog also had a bilateral pneumothorax.

Fig.19b A diagram of the above radiograph.

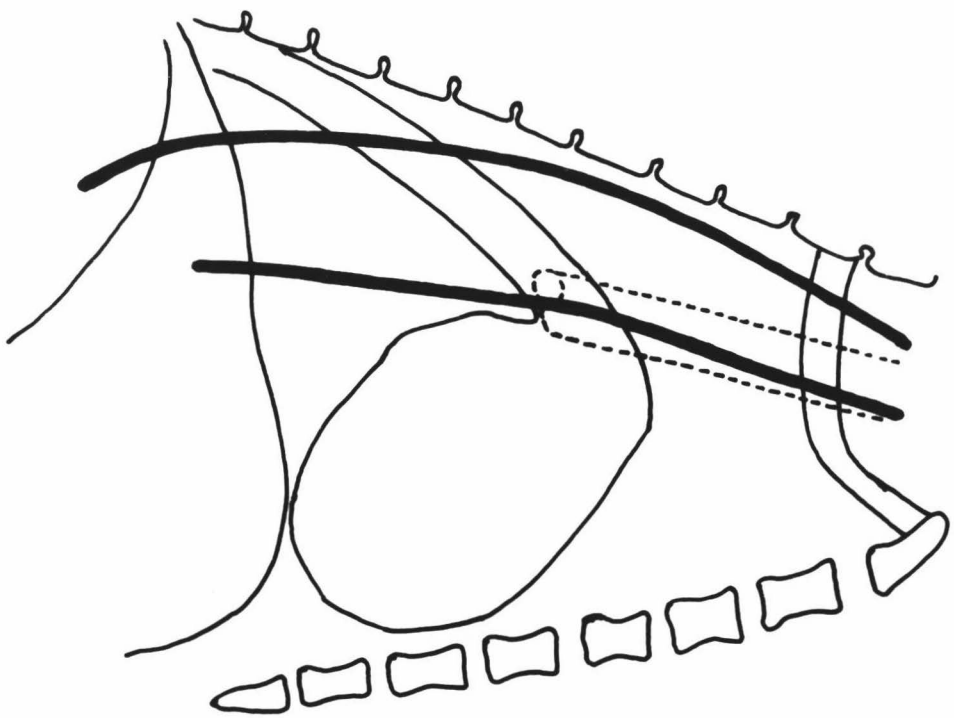
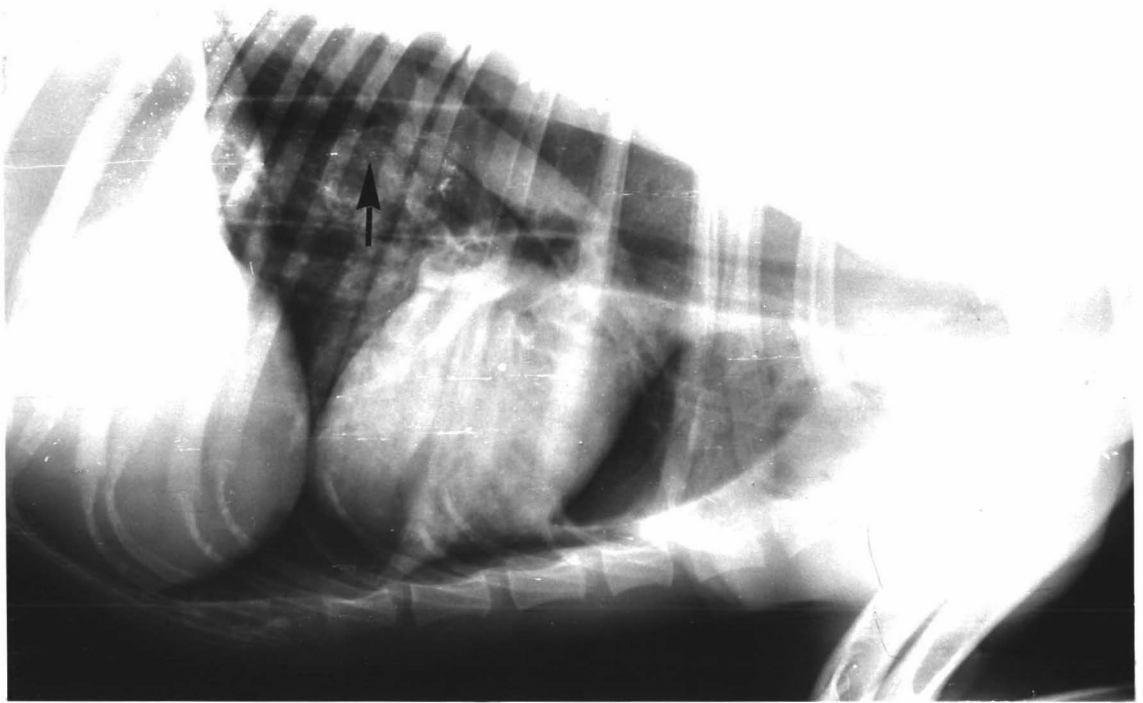


Fig.20 A frame from a cineradiographic film of a Group II dog (06) taken one day after bilateral cranial thoracic vagotomy showing the paralysed thoracic esophagus packed full of barium impregnated food and a closed gastroesophageal junction (arrow).

Fig.21 A frame from a cineradiographic film of a Group II dog (06) taken one day after bilateral cranial thoracic vagotomy showing barium impregnated food packed into the paralysed thoracic esophagus. A cervical esophageal wave can be seen at the moment it ended (arrow) at the base of the neck.

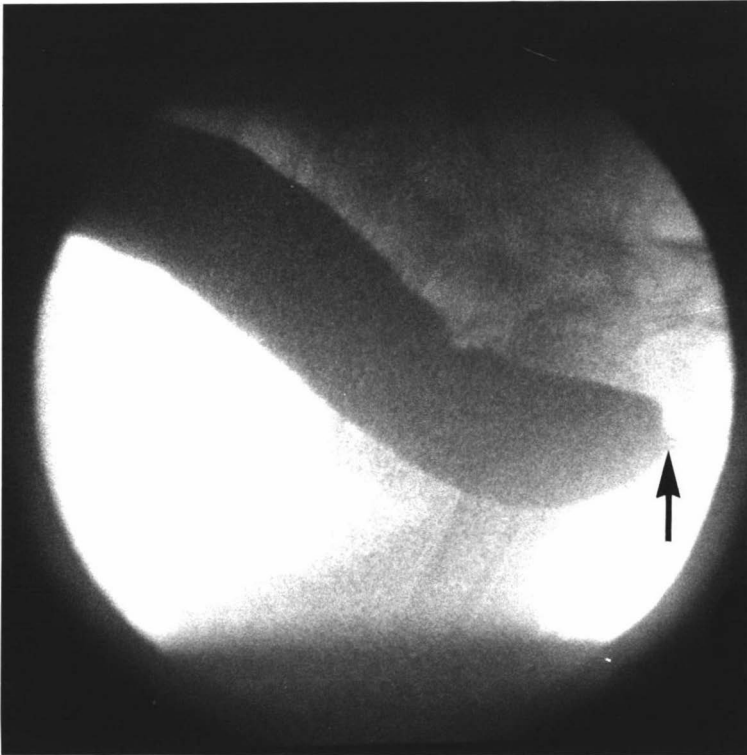
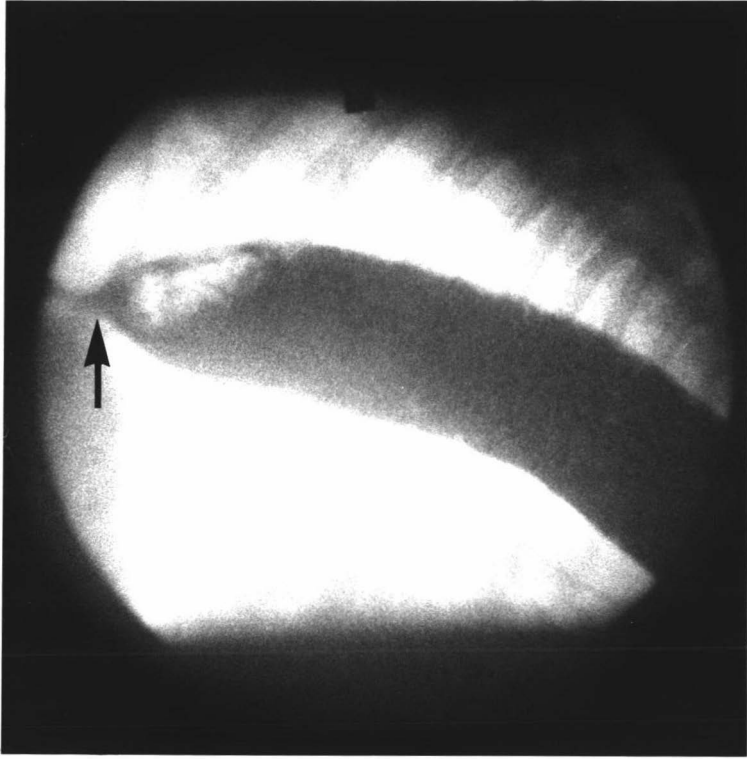


Fig.22 A frame from a cineradiographic film of a Group II dog (06) taken one day after bilateral cranial thoracic vagotomy showing the paralysed caudal thoracic oesophagus packed full with barium impregnated food. A small amount of food can be seen at the moment it passed through the partially opened gastroesophageal junction (arrow).

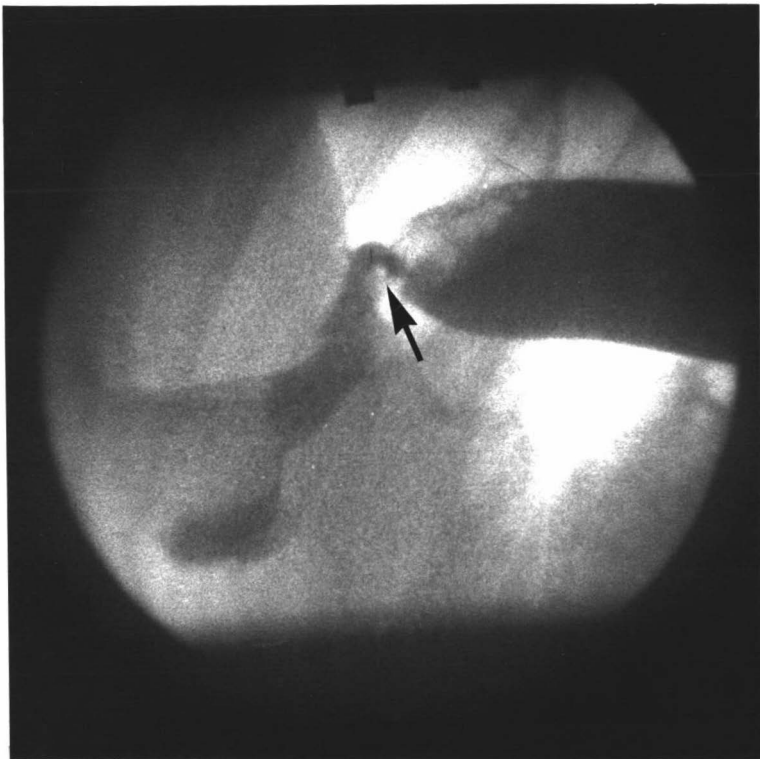


Fig.23a A lateral radiograph of a Group II dog (10) sitting on its haunches taken one day after bilateral cranial thoracic vagotomy, showing a dilated thoracic esophagus and a closed gastroesophageal junction (arrow).

Fig.23b A diagram of the above radiograph.

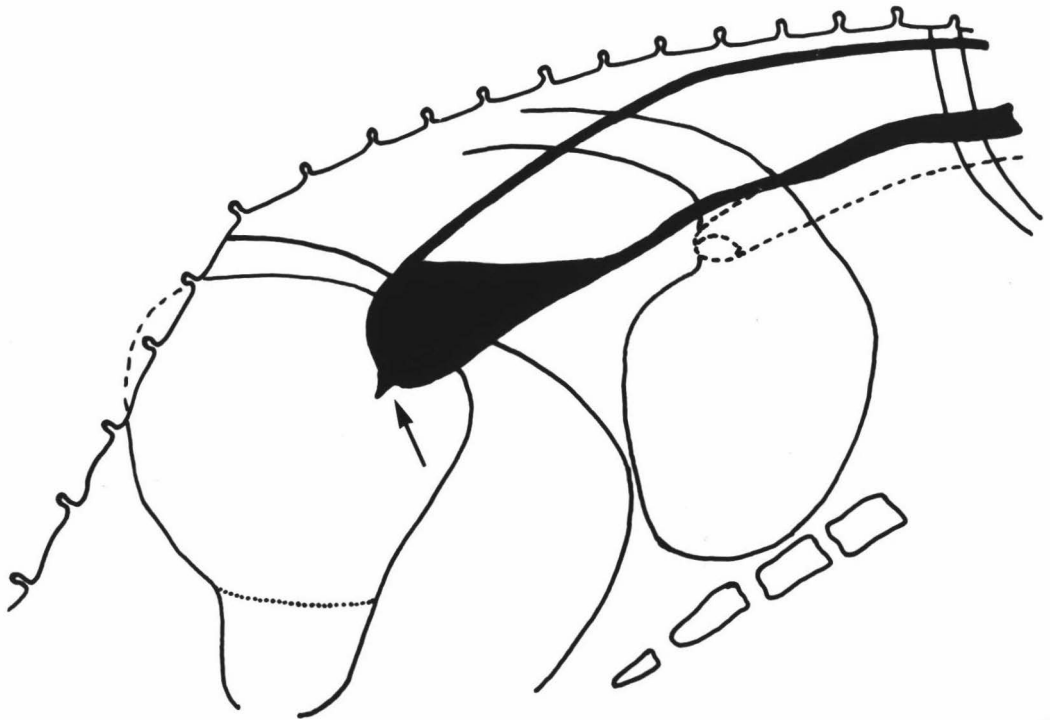
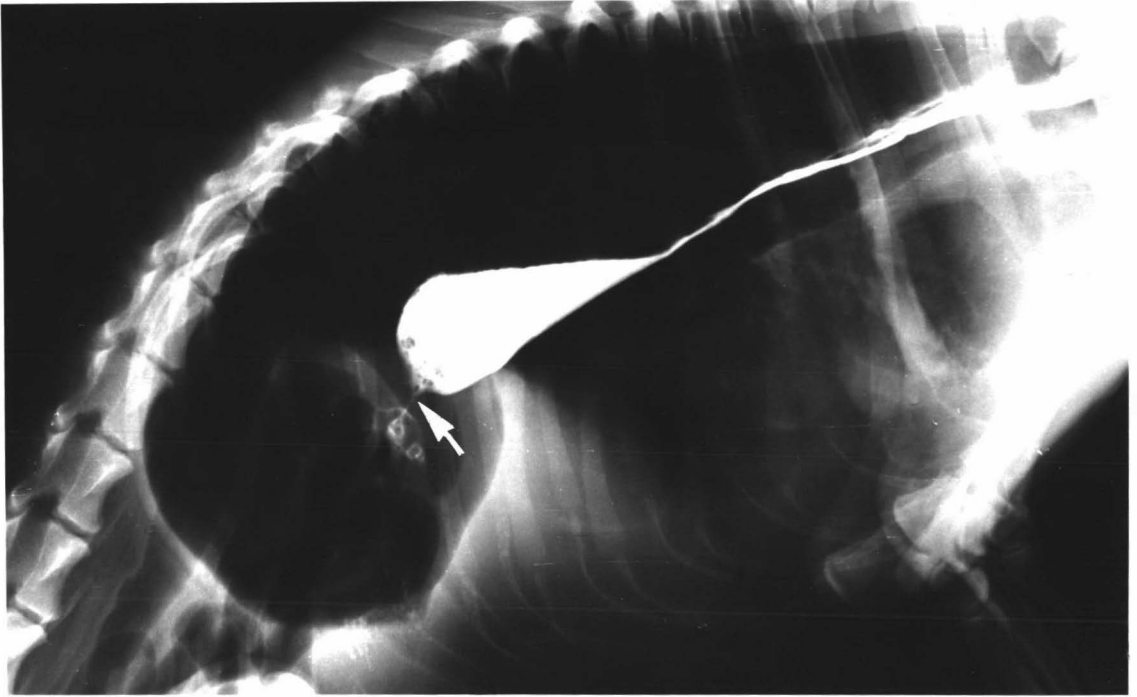


Fig.24 A frame from a cineradiographic film of a Group III dog (15) taken before neurectomy showing a bolus after it had passed cleanly along the esophagus through the thoracic inlet region without leaving a trail of meal behind.

Fig.25 A frame from a cineradiographic film of a Group III dog (15) taken before neurectomy showing a bolus after it had passed cleanly through the cranial thoracic esophagus without leaving a trail of meal behind.

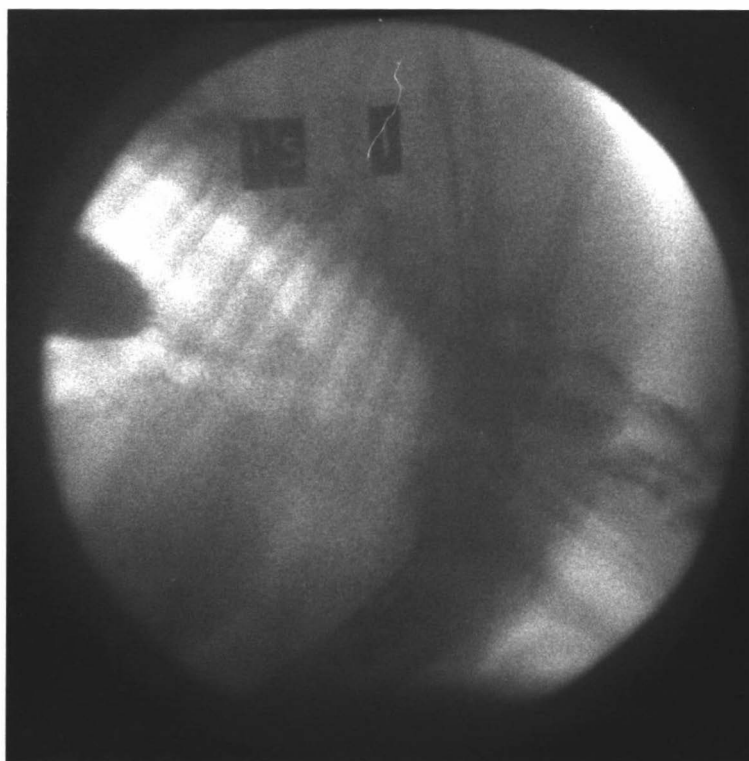
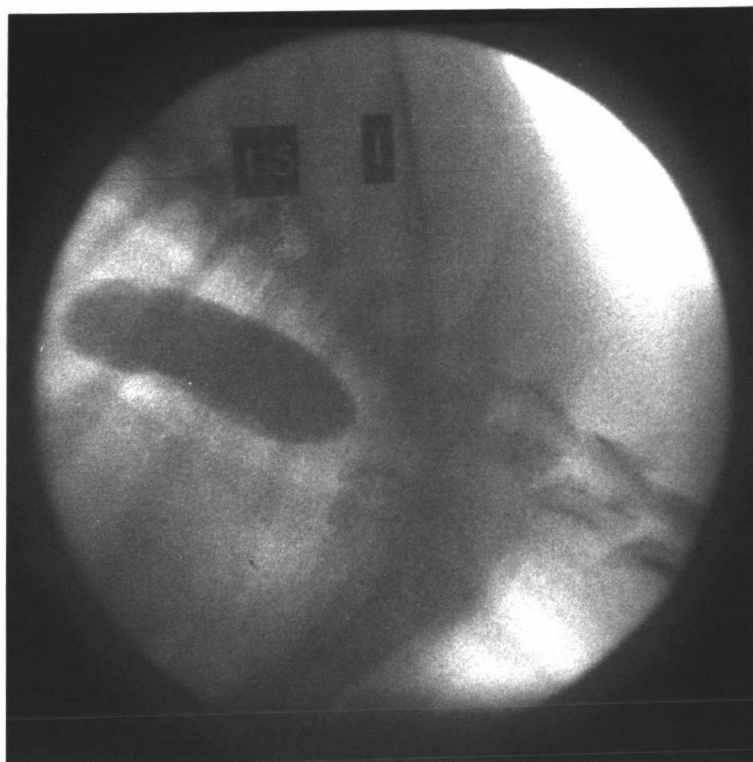
Fig.26 A frame from a cineradiographic film of a Group III dog (15) taken one day after right recurrent laryngeal neurectomy, showing a trail of barium impregnated food which remained throughout the cervical esophagus after the passage of several ineffective cervical waves.

Fig.27 A frame from a cineradiographic film of a Group III dog (14) taken one day after right recurrent laryngeal neurectomy, showing a cervical esophageal contraction wave at the moment it paused at the level of the fourth cervical vertebra (arrow). A trace of meal lies in the proximal part of the cervical esophagus.

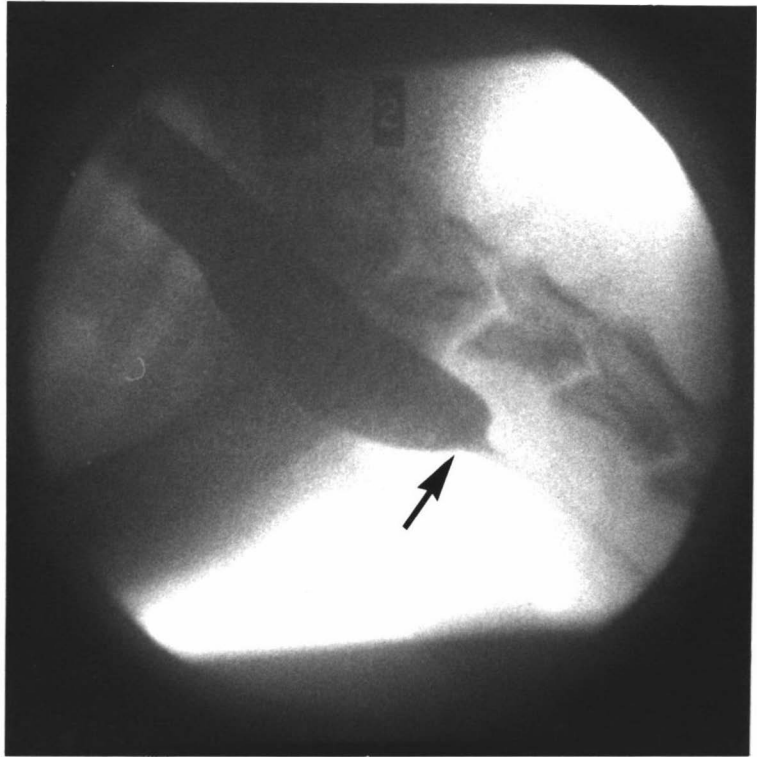
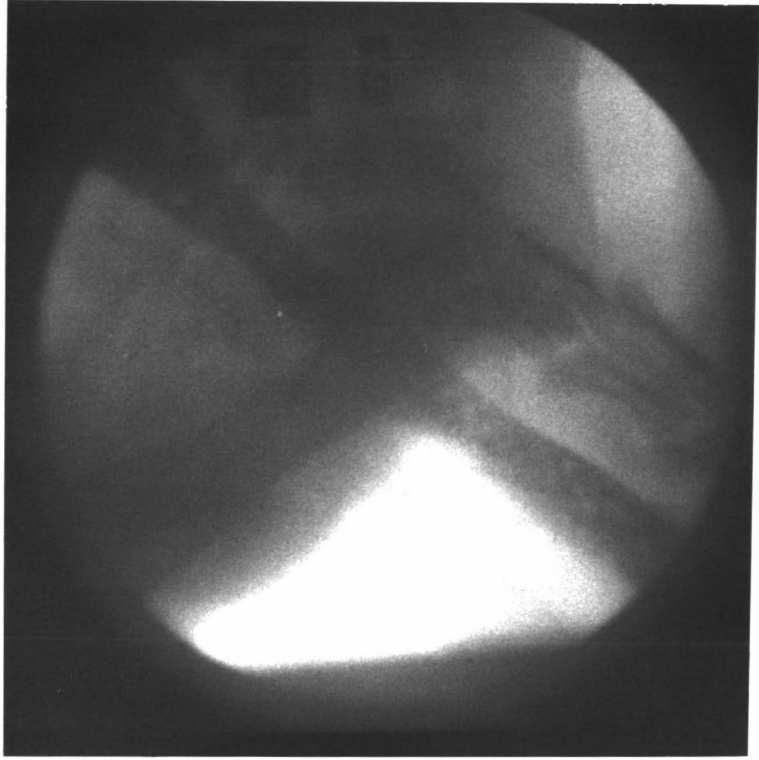


Fig.28 A frame from a cineradiographic film of a Group III dog (14) taken one day after right recurrent laryngeal neurectomy, showing some barium impregnated food (arrow) after it had passed forwards into the proximal cervical esophagus.

Fig.29 A frame from a cineradiographic film of a Group III dog (14) taken one day after right recurrent laryngeal neurectomy, showing the cervical esophageal contraction wave at the moment it restarted and pinched off (arrow) the part of the bolus remaining in the proximal cervical esophagus.

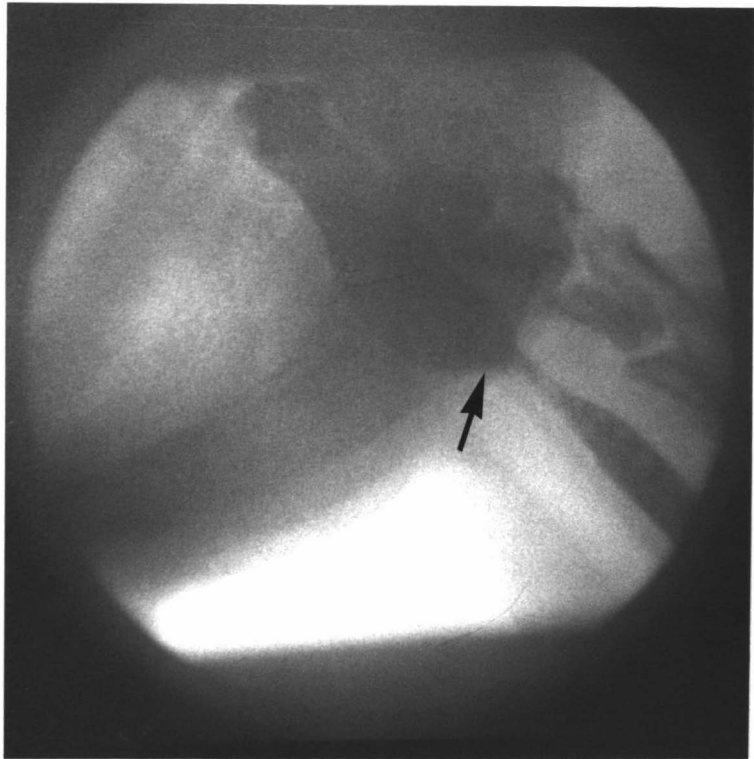
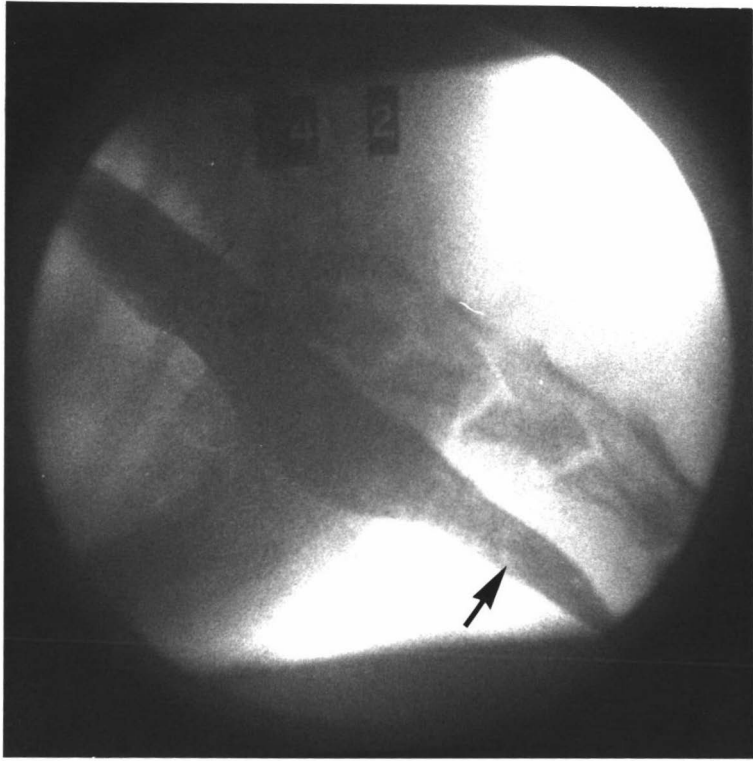
Fig.30 A frame from a cineradiographic film of a Group III dog (14) taken eight days after left recurrent laryngeal neurectomy showing the cervical esophageal wave as it ended (arrow) opposite the sixth cervical vertebra. Swallowed boluses lying in the cranial thoracic esophagus and a trace of meal remaining in the cervical esophagus can also be seen.

Fig.31 A frame from a cineradiographic film of a Group III dog (14) taken eight days after left recurrent laryngeal neurectomy showing swallowed meal lying in the cranial thoracic esophagus, through the thoracic inlet region and the meal that had refluxed into the distal cervical esophagus.

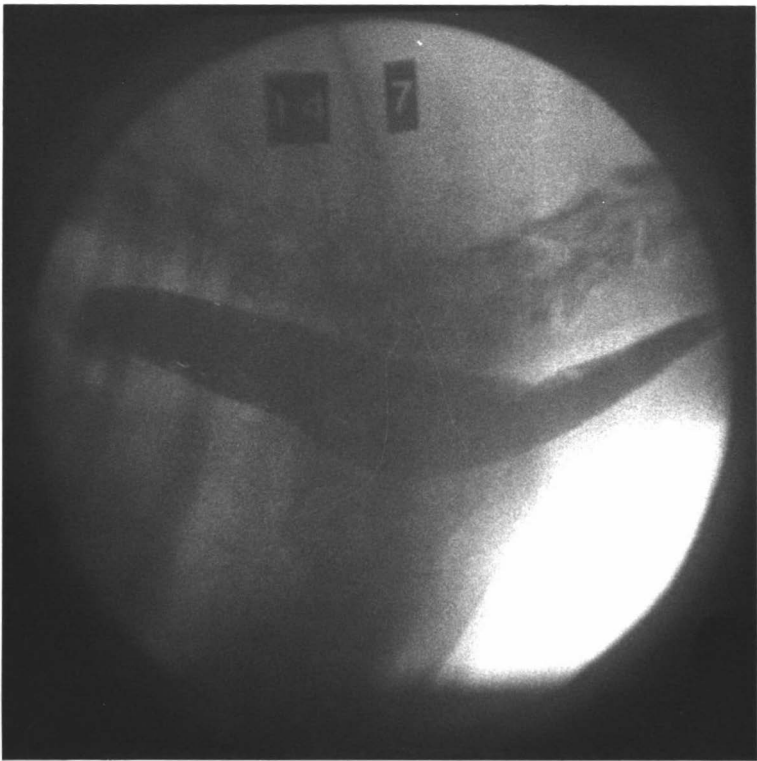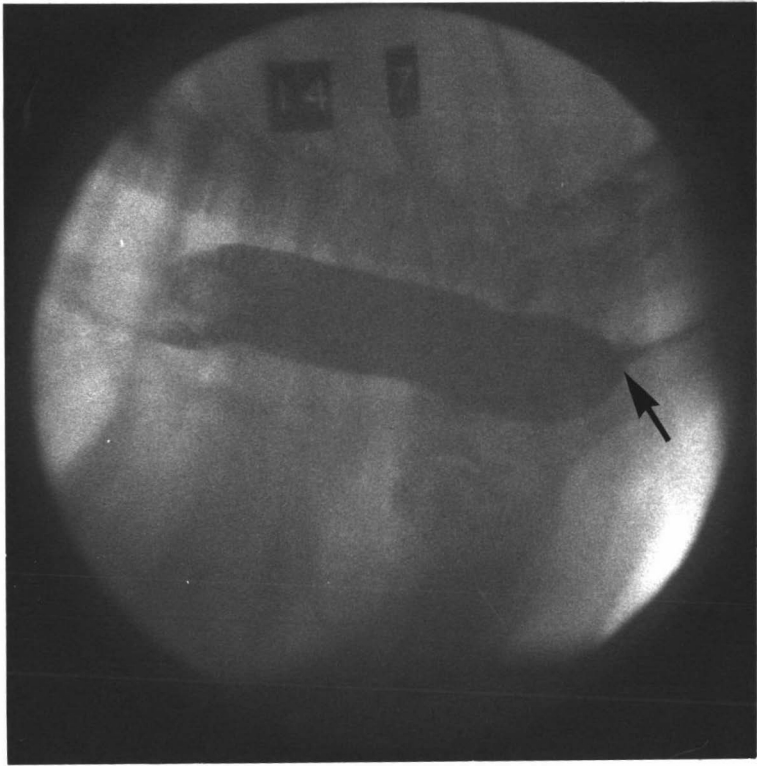


Fig.32 A frame from a cineradiographic film of a Group III dog (14) taken eight days after left recurrent laryngeal neurectomy showing the start of a new thoracic esophageal wave with an ineffective contraction (arrow) opposite the first thoracic intervertebral disc.

Fig.33 A frame from a cineradiographic film of a Group III dog (14), eight days after left recurrent laryngeal neurectomy, taken a moment later than Figure 32, showing the ineffective contraction of the new thoracic esophageal wave.

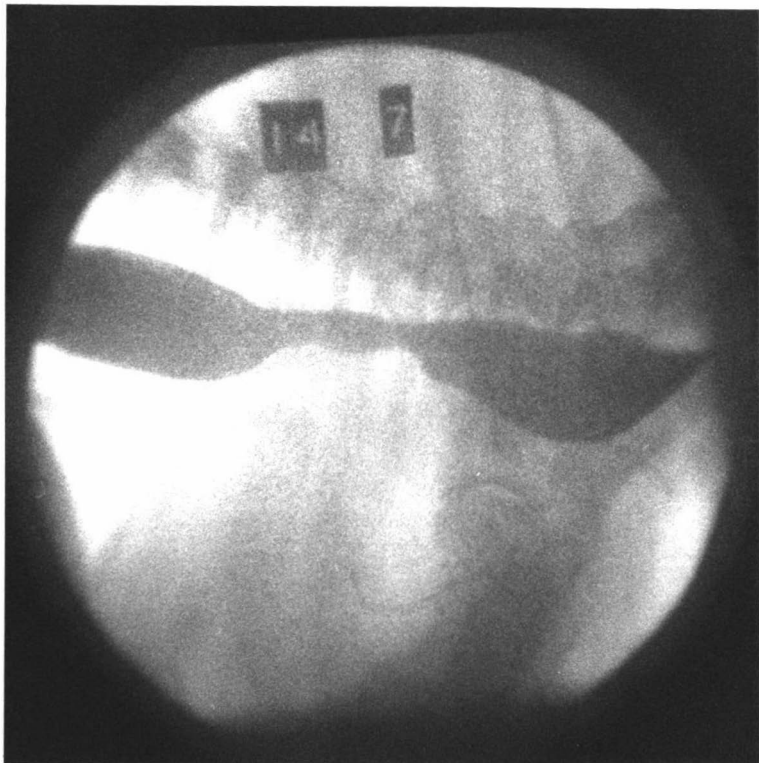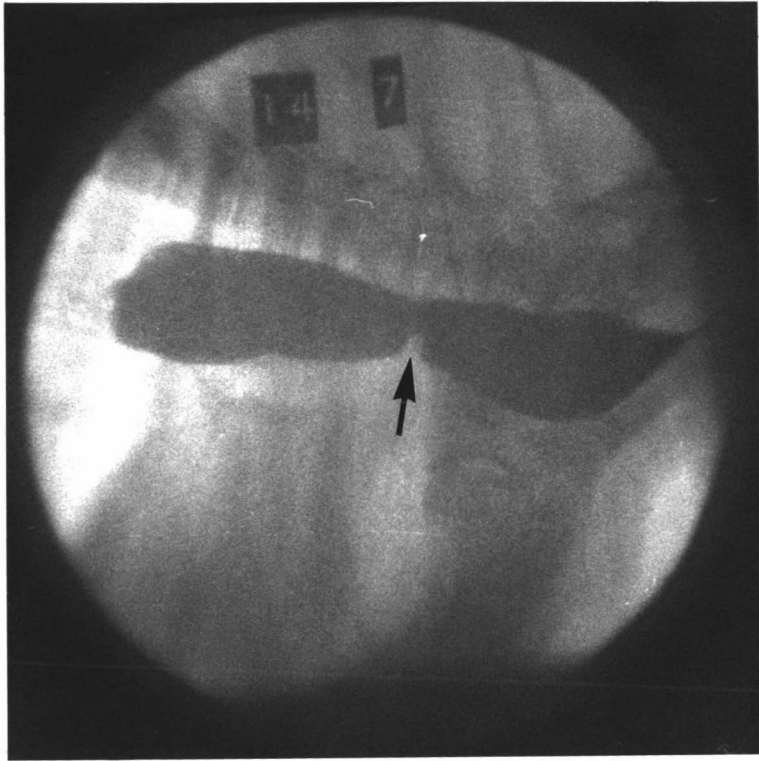


Fig. 34 A frame from a cineradiographic film of a Group III dog (14) taken eight days after left recurrent laryngeal neurectomy showing the thoracic esophageal wave of contraction at the moment it became fully effective (arrow) opposite the fourth thoracic vertebra.

Fig. 35 A frame from a cineradiographic film of a Group III dog (15) taken eight days after left recurrent laryngeal neurectomy showing a trail of barium impregnated meal that remained in the cervical esophagus after the passage of an ineffective cervical wave. The diphasic origin (arrows) of the thoracic contraction wave can also be seen.

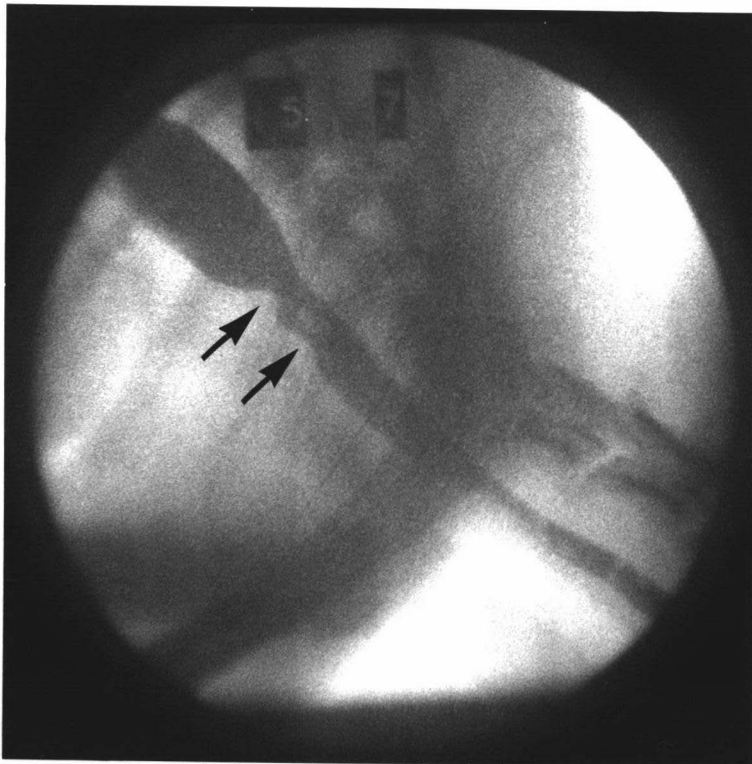
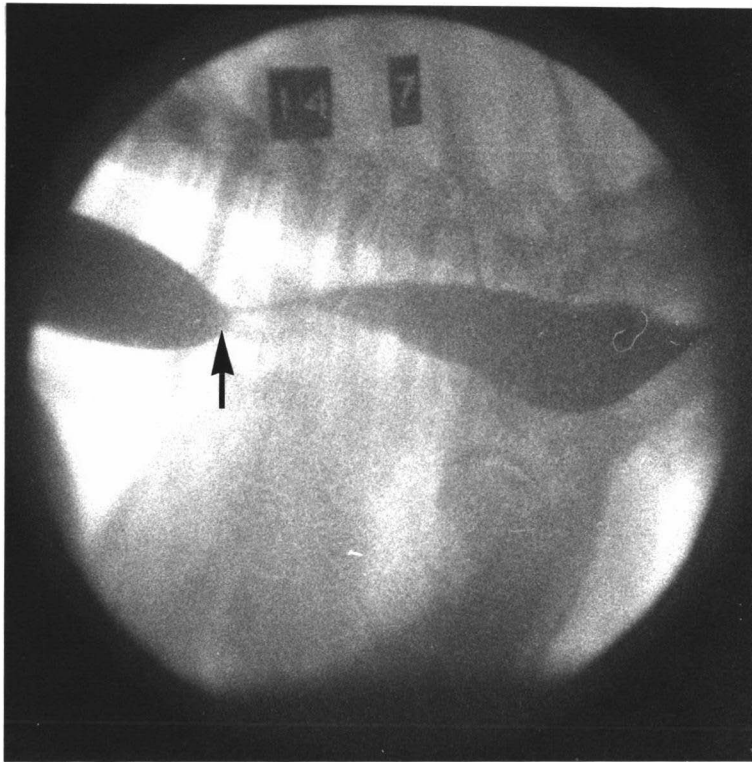


Fig. 36 A frame from a cineradiographic film of a Group IV dog (12) taken two days after bilateral thoracic vagotomy distal to the origin of the recurrent laryngeal nerves showing the esophageal wave of contraction as it terminated (arrow) opposite the first thoracic intervertebral disc.

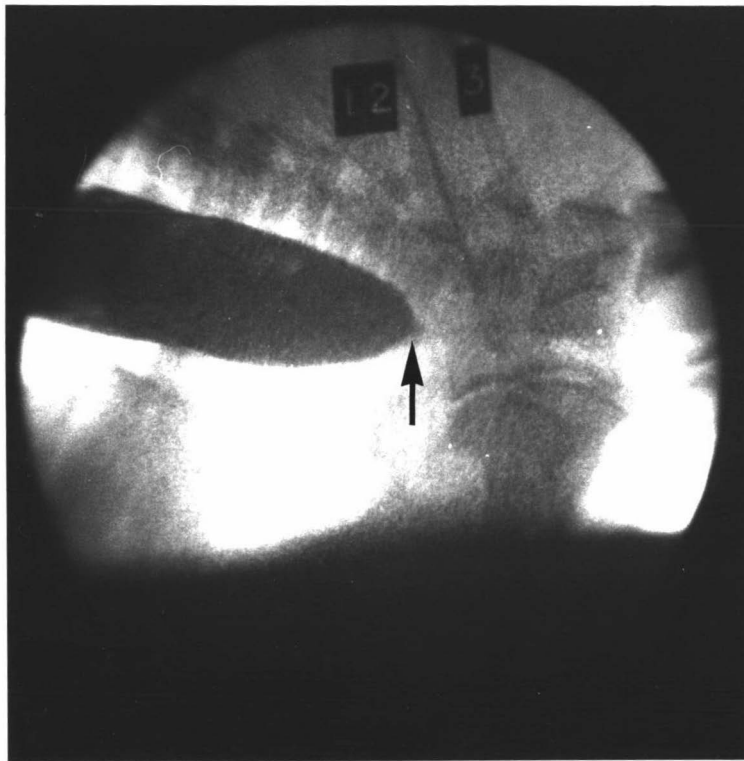


Fig.37 A frame from a cineradiographic film of a Group V dog (04) taken before neurectomy showing a bolus as it passed through the thoracic esophagus. No material has refluxed through the gastroesophageal junction (arrow).

Fig.38 A frame from a cineradiographic film of a Group V dog (04) taken before neurectomy at the moment when swallowed barium impregnated food (arrow) refluxed through the gastroesophageal junction into the caudal thoracic esophagus. A bolus may be seen as it passed through the cranial thoracic esophagus.

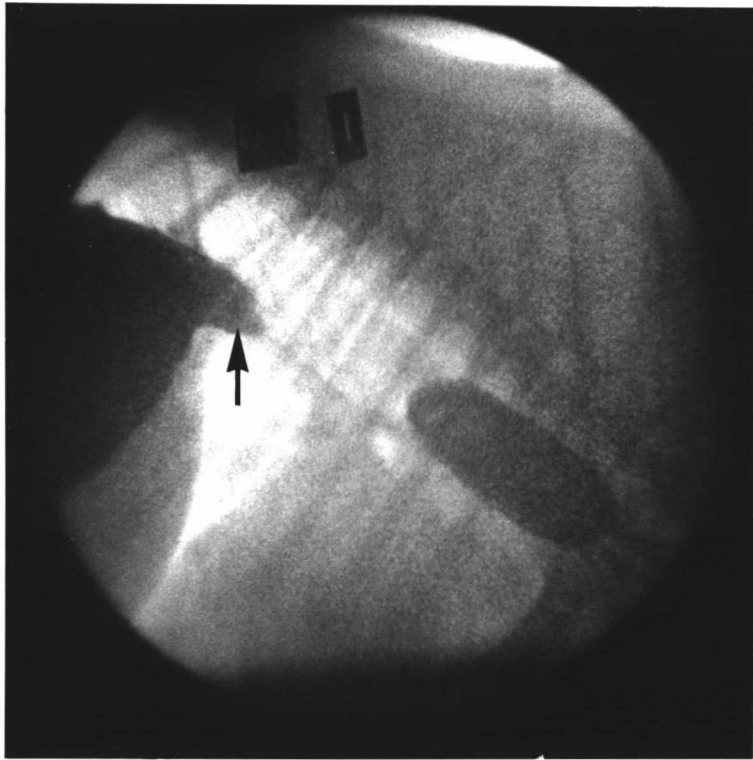
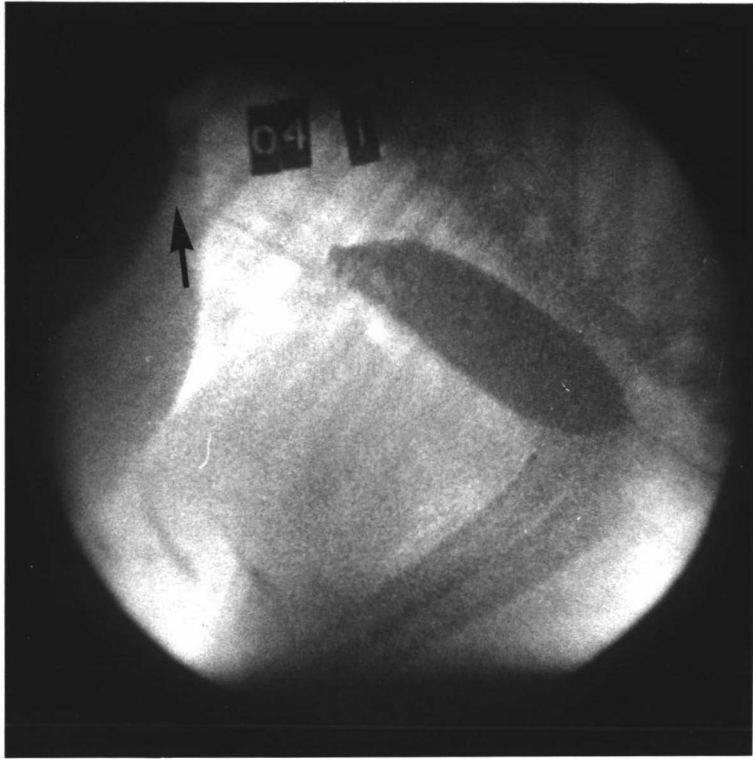


Fig.39 A frame from a cineradiographic film of a Group V dog (04) taken fifteen days after double trunk caudal thoracic vagotomy at the moment when some material refluxed through the gastroesophageal junction (arrow).

Fig.40 A frame from a cineradiographic film of a Group V dog (04) taken fifteen days after double trunk caudal thoracic vagotomy at the moment when a large amount of gastric contents (arrow) refluxed into the caudal thoracic esophagus. A bolus can also be seen cranial to this refluxed mass.

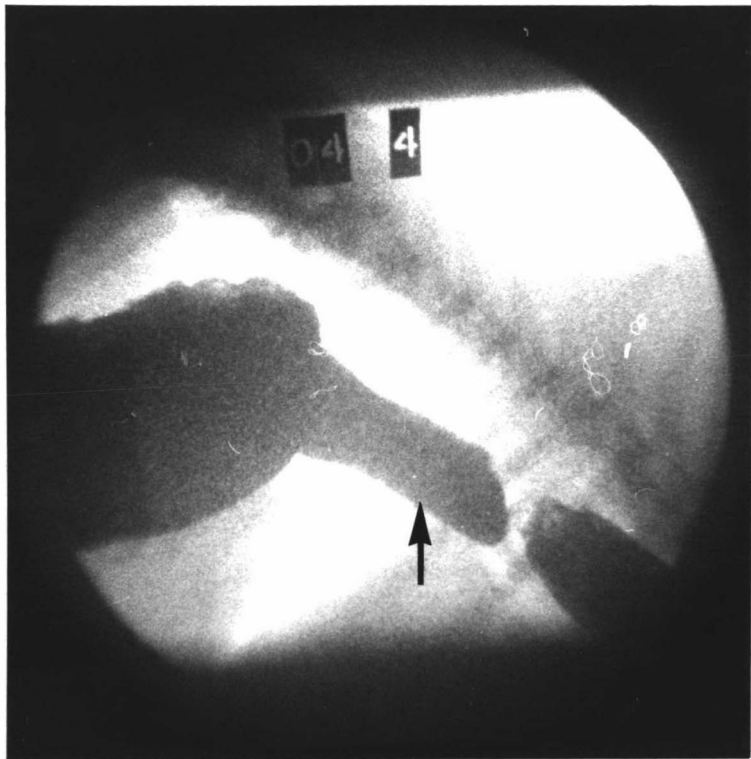
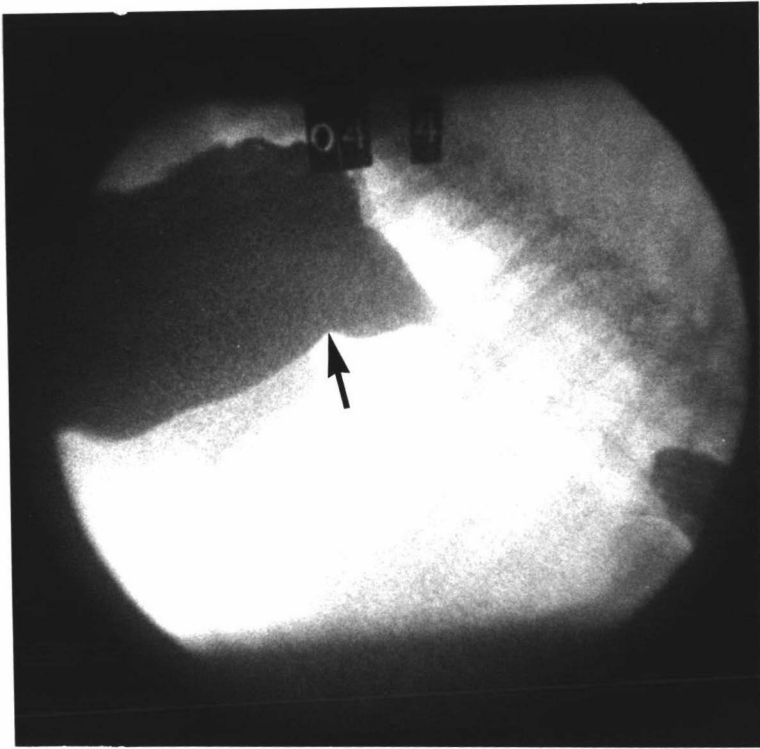


Fig.41 A frame from a cineradiographic film of a Group V dog (02) taken four days after dorsal trunk caudal thoracic vagotomy at the moment when some gastric reflux (arrow) had occurred.

Fig.42 A frame from a cineradiographic film of a Group V dog (02) taken fourteen days after a double trunk caudal thoracic vagotomy at the moment when a considerable amount of gastric contents (arrow) had refluxed into the caudal thoracic esophagus.

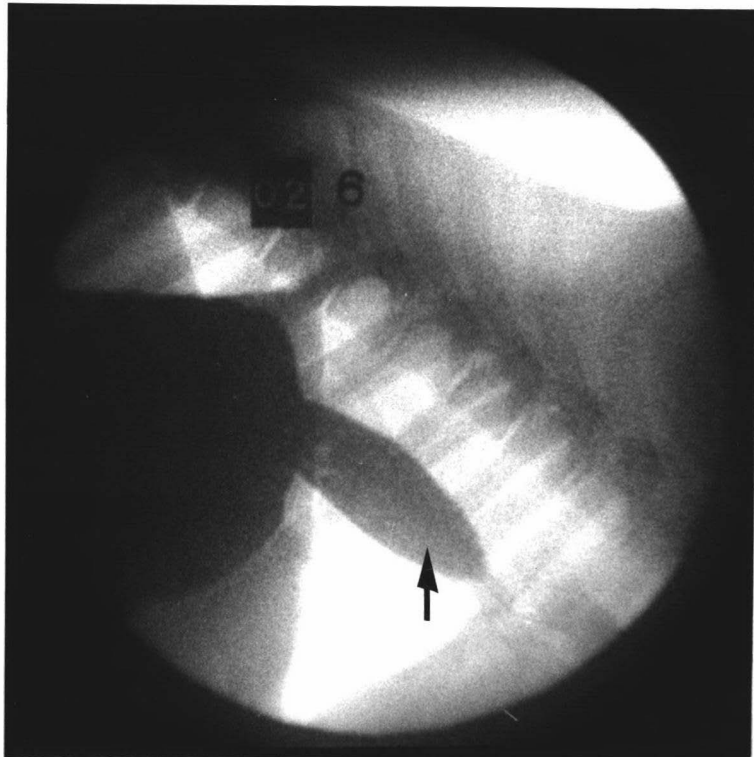
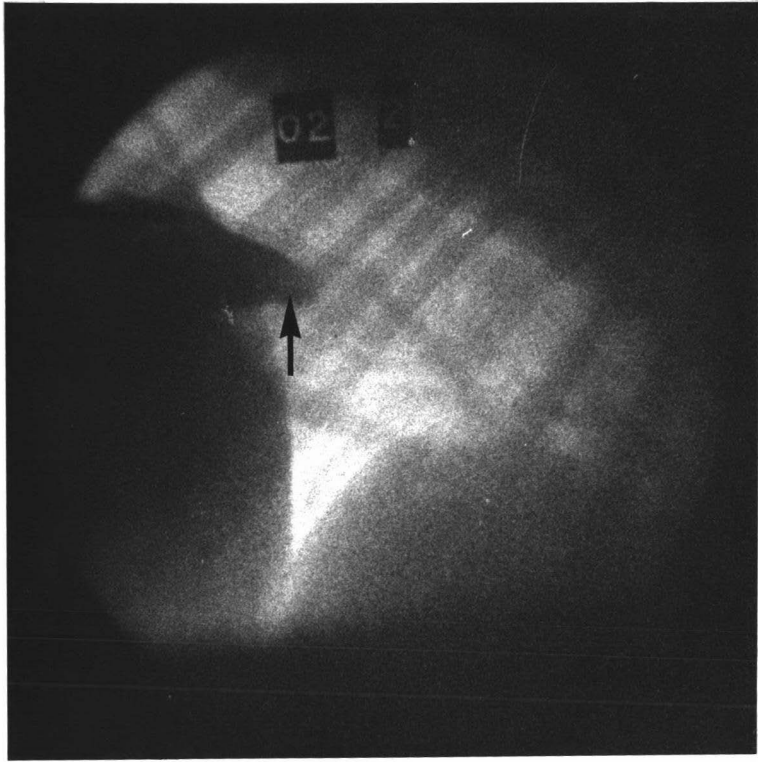


Fig.43 The esophagus of dog 10, thirty one days after bilateral cranial thoracic vagotomy. The lumen has been filled with water to demonstrate the considerable dilatation of the thoracic portion. The larynx has been partially dissected away from the esophagus. This photograph is taken from a left ventrolateral view and the thoracic inlet is indicated (arrow).

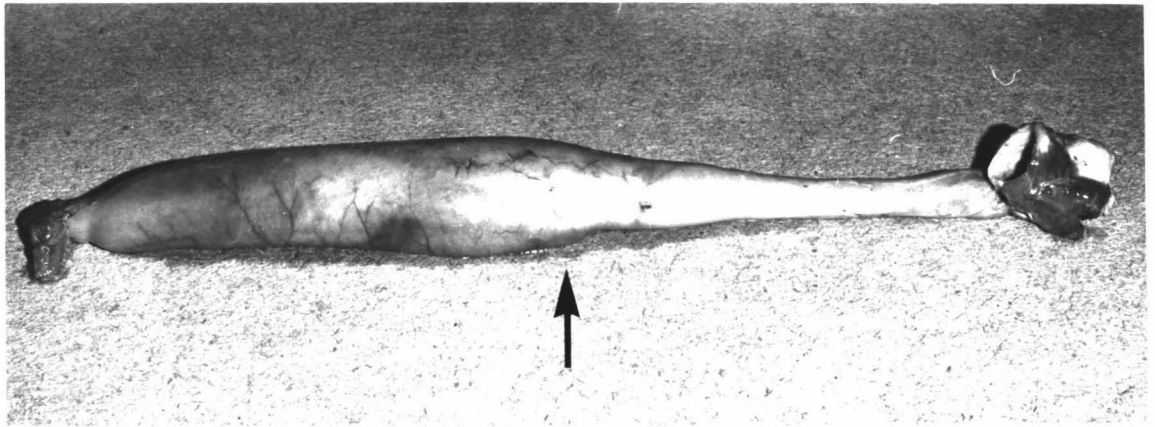


Fig.44 A transverse section through the right pararecurrent laryngeal and recurrent laryngeal nerves immediately distal to their origins from the vagus; control specimen showing the normal histology. (Haematoxylin and van Gieson's; x 130) cf. Figure 45.

Fig.45 A transverse section through the right pararecurrent laryngeal and recurrent laryngeal nerves close to their origins from the vagus; taken at autopsy from dog 13, nine days after bilateral vagotomy proximal to the origins of the recurrent laryngeal nerves. Note the considerable degenerative changes. (Haematoxylin and van Gieson's; x 95) cf. Figure 44.

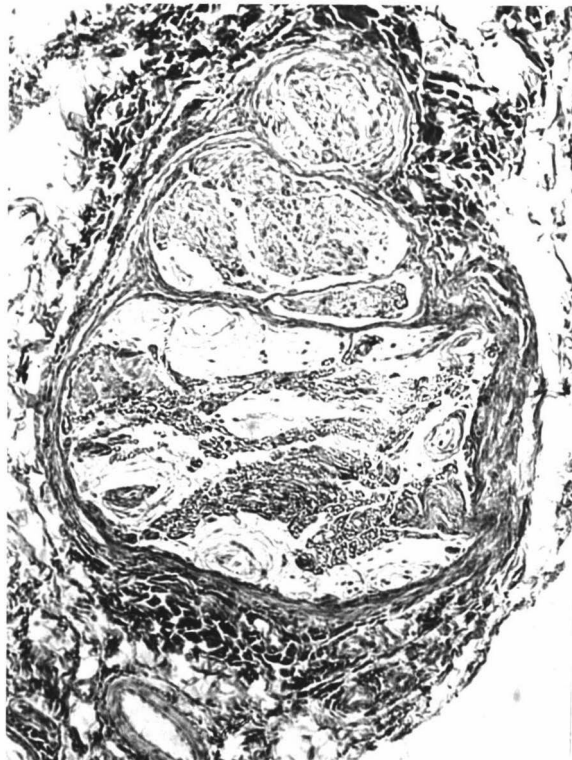
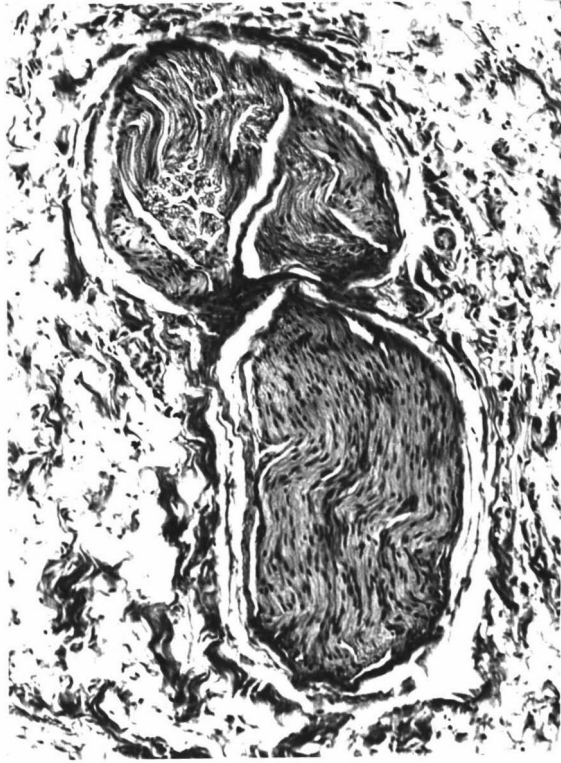


Fig.46 Transverse section through the typical stratified squamous epithelium (non-cornified) of the canine esophagus. This section is from the caudal thoracic region. (Haematoxylin and van Gieson's; x 235).

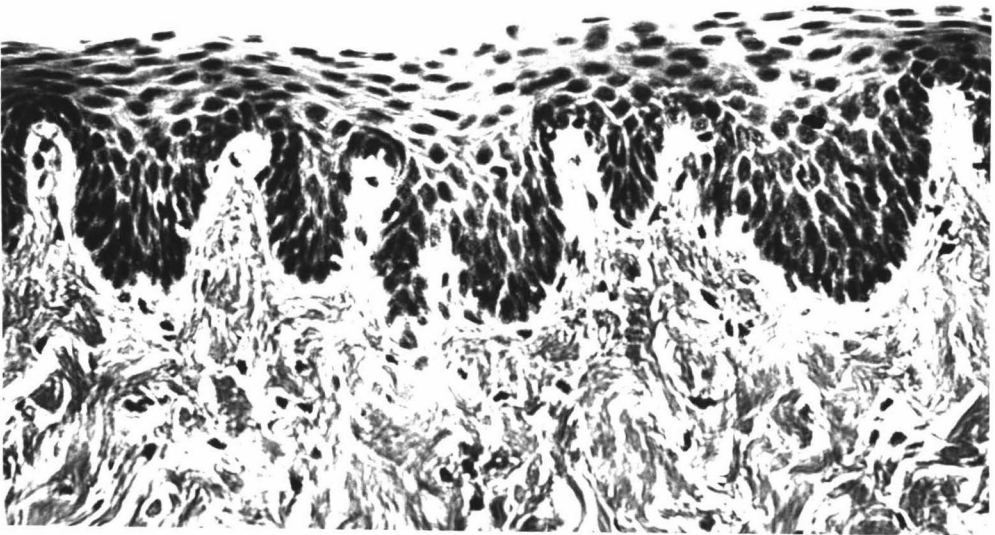


Fig.47a Transverse section through the midthoracic portion of the canine esophagus. (Haematoxylin, van Gieson's and alcian blue; x 8.5).

Fig.47b Diagram of Figure 47a showing: a, stratified squamous epithelium; b, lamina propria; c, smooth muscle of the muscularis mucosae; d, submucosal tunic; e, mucous glands; f, inner and g, outer layers of striated muscle fibres; h, adventitia.

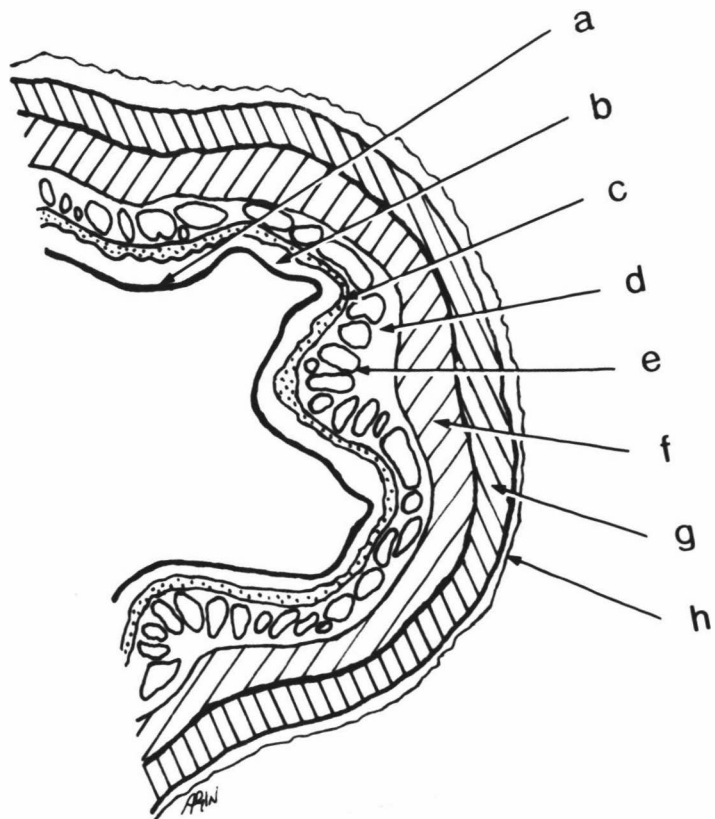
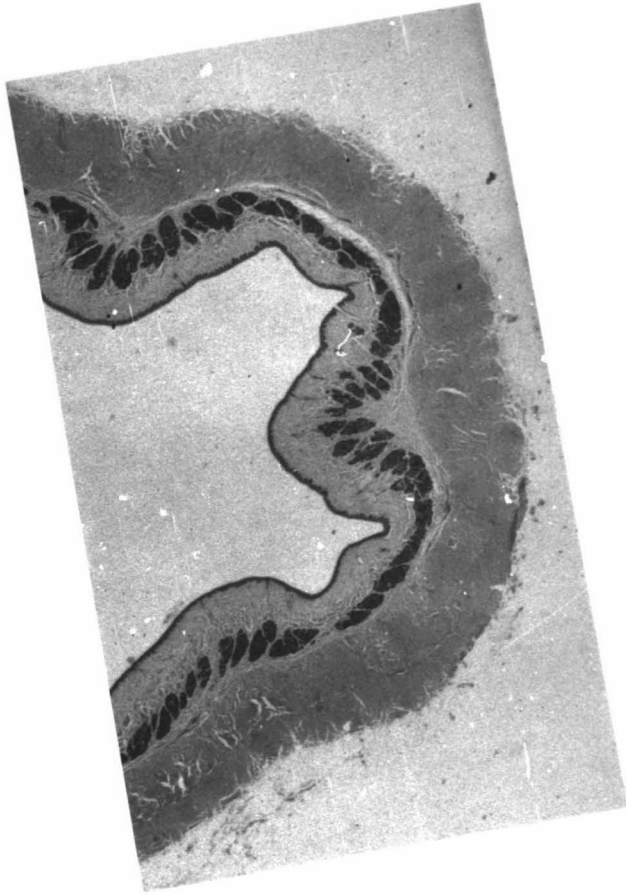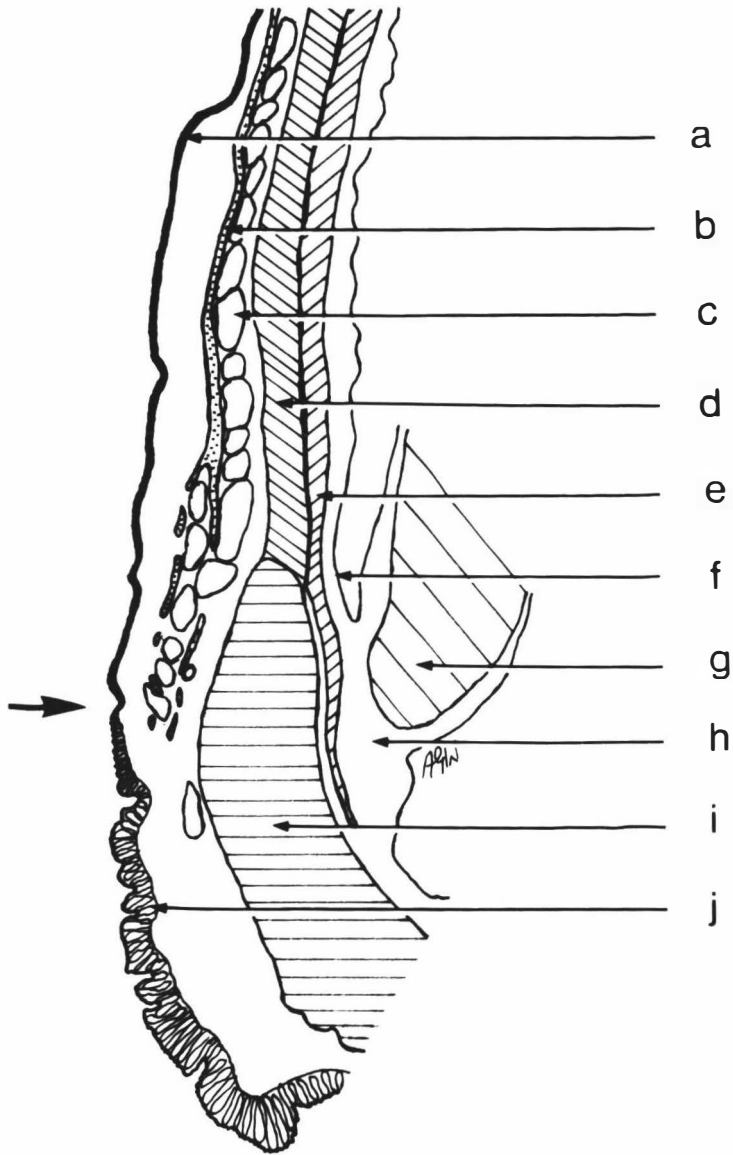


Fig.48a Longitudinal section through the terminal esophagus and the gastroesophageal junction of the dog. (Haematoxylin and van Gieson's; x 5). For diagram see Figure 48b.



Fig.48b Diagram of Figure 48a showing: a, stratified squamous epithelium of the esophagus; b, muscularis mucosae; c, mucous glands; d, inner and e, outer layers of esophageal striated muscle; f, adventitia; g, diaphragm; h, phrenicocosophageal ligament; i, thickened layer of circular smooth muscle; j, columnar gastric epithelium. The abrupt change from esophageal to gastric epithelium is indicated (arrow).



REFERENCES

- ALLISON, P.R. (1948). Cited by Gahagan (1962).
- ALLISON, P.R. (1972). Reflux oesophagitis its pathology and treatment. Scandinavian Journal of Thoracic and Cardiovascular Surgery 6, 318-322.
- ARCHIBALD, J. (Ed.), (1965). Canine Surgery, 1st Archibald edition. pp. 364-365. Wheaton, Illinois: American Veterinary Publications.
- AREY, L.B. (1965). Developmental Anatomy, 7th edition. pp. 246-247, 620. Philadelphia: Saunders.
- BAUE, A.E. (1966). Prevention of experimental reflux esophagitis without an intrinsic esophageal sphincter. Surgery 59, 264-269.
- BAXTER, J.S. (1953). Frazer's Manual of Embryology - The Development of the Human Body, 3rd edition. London: Bailliere, Tindall and Cox.
- BLACKWOOD, W., McHENEMEY, W.H., MEYER, A., NORMAN, R.M. & RUSSELL, D.S. (1963). Greenfield's Neuropathology, 2nd edition. pp. 24-28. London: Arnold.
- BLINCOE, H., LOWANCE, M.I. & VENABLE, J. (1936). A double aortic arch in man. Anatomical Record 66, 505-517.
- BLOOM, W. & FANCETT, D.W. (1962). A Textbook of Histology, 8th edition. pp. 427-431. Philadelphia: Saunders.
- BOTHA, G.S.H. (1958). A note on the comparative anatomy of the cardio-oesophageal junction. Acta Anatomica 34, 52-84.
- BOTHA, G.S.H. (1959). Oesophageal pressure and motility in animals : A cine-radiographic and manometric study. South African Medical Journal 33, 915-920.
- BRADLEY, O.C. (1897). Outlines of Veterinary Anatomy, part III. The Head and Neck. p. 174. London: Bailliere, Tindall and Cox.
- BRADLEY, O.C. (1959). Topographical Anatomy of the Dog, 6th edition, (Revised by T. Grahame). pp. 71-87, 201, 203, 224-226. Edinburgh: Oliver and Boyd.
- BURGET, G.E. & ZELLER, W.E. (1936). A study of the cardia in unanesthetized dogs. Proceedings of the Society for Experimental Biology and Medicine 34, 433-434.
- CARLSON, A.J., BOYD, T.E. & PEARCY, J.F. (1922). Studies on the visceral sensory nervous system. XIII. The innervation of the cardia and the lower end of the esophagus in mammals. American Journal of Physiology 61, 14-41.
- CARVETH, S.W., SCHLEGEL, J.F., CODE, C.F. & ELLIS, F.H. (1962). Esophageal motility after vagotomy, phrenicotomy, myotomy, and myomectomy in dogs. Surgery, Gynecology and Obstetrics 114, 31-42.

- CAWLEY, A.J. & GENDREAU, C.L. (1969). Esophageal achalasia in a cat. Canadian Veterinary Journal 10, 195-197.
- CHAUVEAU, A. (1891). The Comparative Anatomy of the Domesticated Animals, 2nd English edition, (Translated and Edited by G. Fleming). pp. 832-852. London: Churchill.
- CLIFFORD, D.H. & GYORLEY, F. (1967). Myenteric ganglial cells in dogs with and without achalasia of the esophagus. Journal of the American Veterinary Medical Association 150, 205-210.
- CLIFFORD, D.H., WILSON, C.F., WADDELL, E.D. & THOMPSON, H.G. (1967). Esophagomyotomy (Heller's) for relief of esophageal achalasia in three dogs. Journal of the American Veterinary Medical Association 151, 1190-1201.
- CODE, C.F. & SCHLEGEL, J.F. (1968). Motor action of the esophagus and its sphincters. In Handbook of Physiology, Section 6: Alimentary Canal, Volume V: Motility. pp. 1821-1839. Washington: American Physiological Society.
- CROUCH, J.E. (1972). Functional Human Anatomy, 2nd edition. Philadelphia: Lea and Febiger.
- CULLING, C.F.A. (1963). Handbook of Histological Techniques. pp. 179-183, 199-208. London: Butterworths.
- DAVSON, H. & EGGLETON, M.G. (Eds.), (1968). Starling and Lovatt Evans Principles of Human Physiology, 14th edition. pp. 595-597. London: Churchill.
- DEKLEER, V.S. (1970). An anomalous origin of the right subclavian artery in the dog. British Veterinary Journal 127, 76-82.
- DELOYERS, L., CORDIER, R. & DUPREZ, A. (1957). A new approach to the physiology of so-called "cardiospasm". Experimental production of "cardiospasm" in cats after destruction of Auerbach's plexus. Annals of Surgery 146, 167-177.
- DEWITT, L.M. (1900). Arrangement and terminations of nerves in the oesophagus of mammalia. Journal of Comparative Neurology 10, 382-398.
- DISBREY, B.D. & RACK, J.H. (1970). Histological Laboratory Methods. pp. 248-251. Edinburgh: Livingstone.
- DONALD, D.E. (1952). Esophageal dysfunction in the rat after vagotomy. Surgery 31, 251-257.
- DOTY, R.W. & BOSMA, J.F. (1956). An electromyographic analysis of reflex deglutition. Journal of Neurophysiology 19, 44-60.
- DOUGHTERY, R.W., HABEL, R.E. & BOND, H.E. (1958). Esophageal innervation and the eructation reflex in sheep. American Journal of Veterinary Research 19, 115-128.
- DOWGIALLO, N.D. (1927). Die nerven der speiseröhre beim hund. Zeitschrift für die gesamte anatomie 83, Abt. 1 - Zeitschrift für anatomie und entwicklungsgeschichte 591-597.

- DYCE, K.M. & WENSING, C.J.G. (1971). Essentials of Bovine Anatomy. Utrecht: Academische Paperback.
- ELLENBERGER, W. & BAUM, H. (1891). Cited by Hwang et al. (1947).
- ELLIS, F.G. (1962). The aetiology and treatment of achalasia of the cardia. Annals of the Royal College of Surgeons of England 30, 155-182.
- ELLIS, F.H. & OLSEN, A.M. (1969). Achalasia of the Esophagus. Philadelphia: Saunders.
- ELLIS, F.G., KAUNTZE, R. & TROUNCE, J.R. (1960). The innervation of the cardia and lower oesophagus in man. British Journal of Surgery 47, 466-471.
- EVANS, H.E. & DeLAHUNTA, A. (1971). Hiller's Guide to the Dissection of the Dog. p. 232. Philadelphia: Saunders.
- FLINT, J.M. (1907). The organogenesis of the oesophagus. Anatomischer Anzeiger 3, 442-451.
- FOX, H.W. (1966). Canine Pediatrics; Developmental, Neonatal and Congenital Diseases. pp. 95-135. Springfield, Illinois: Thomas.
- GAHAGAN, T. (1962). The function of the musculature of the esophagus and stomach in the esophagogastric sphincter mechanism. Surgery, Gynecology and Obstetrics 114, 293-303.
- GOETSCH, E. (1910). The structure of the mammalian oesophagus. American Journal of Anatomy 10, 1-40.
- GRANT, J.C.B. (1962). An Atlas of Anatomy, 5th edition. p. 532. Baltimore: Williams and Wilkins.
- GREENWOOD, R.K., SCHEGEL, J.F., CODE, C.F. & ELLIS, F.H. (1962). The effect of sympathectomy, vagotomy, and oesophageal interruption on the canine gastro-oesophageal sphincter. Thorax 17, 310-319.
- GRONDAHL, J.W. & HANEY, H.F. (1940). Attempt to produce experimental cardiospasm in dogs. Proceedings of the Society for Experimental Biology and Medicine 44, 126-129.
- HABEL, R.E. (1970). Guide to the Dissection of Domestic Ruminants, 2nd edition. p. 130. Ithaca, New York: Published by Author.
- HAR, A.W. (1969). Histology, 6th edition. pp. 678-683. Philadelphia: Lippincott.
- HELL, R. (1907). Cited by Goetsch (1910).
- HENDRIX, T.R. (1974). The motility of the alimentary canal. In Medical Physiology, 13th edition, (Edited by V.B. Mountcastle). 2, 1208-1234. St. Louis: Mosby.
- HENWOOD, J.K. & GREEN, R.A. (1964). Section of the right subclavian artery to relieve associated regurgitation of food in the dog. Plus anatomical note. Veterinary Record 76, 1155-1160.

- HIGGS, B. & ELLIS, F.H. (1965). The effect of bilateral supranodosal vagotomy on canine esophageal function. Surgery 58, 828-834.
- HIGGS, B., SHORTER, R.G. & ELLIS, F.H. (1965). A study of the anatomy of the human esophagus with special reference to the gastroesophageal sphincter. Journal of Surgical Research 5, 503-507.
- HILL, K.J. (1970). Deglutition and the esophagus. In Dukes' Physiology of Domestic Animals, 8th edition, (Edited by M.J. Swenson). pp. 358-362. Ithaca, New York: Comstock.
- HILSABECK, J.R. & HILL, F.C. (1950). Anatomy of the thoracic vagus in the dog and a technic for its interruption. Proceedings of the Society for Experimental Biology and Medicine 73, 633-637.
- HOAG, E.W., KIRILUK, L.S. & MERENDINO, K.A. (1954). Experiences with upper gastrectomy, its relationship to esophagitis with special reference to the esophagogastric junction and diaphragm. A study in the dog. American Journal of Surgery 88, 44-55.
- HOFFER, R.E., VALDES-DAPENA, A. & BAUE, A.E. (1967). A comparative study of naturally occurring canine achalasia. Archives of Surgery 95, 83-88.
- HOFMEYER, C.F.B. (1966). An evaluation of cardioplasty for achalasia of the oesophagus in the dog. Journal of Small Animal Practice 7, 281-301.
- HWANG, K. (1953). Mechanism of the functional recovery of the cervical portion of the esophagus after bilateral resection of the pharyngoesophageal nerve in the dog. American Journal of Physiology 174, 231-234.
- HWANG, K. (1954). Mechanism of transportation of the content of the esophagus. Journal of Applied Physiology 6, 781-796.
- HWANG, K., ESSEX, H.E. & MANN, F.C. (1947). A study of certain problems resulting from vagotomy in dogs with special reference to emesis. American Journal of Physiology 149, 429-448.
- HWANG, K., GROSSMAN, M.I. & IVY, A.C. (1948). Nervous control of the cervical portion of the esophagus. American Journal of Physiology, 154, 343-357.
- INDAR JIT. (1955). The development of the nerve supply to the human oesophagus and stomach. Journal of the Anatomical Society of India 4, 55-68.
- INGELFINGER, F.J. (1958). Esophageal motility. Physiological Reviews 38, 533-584.
- International Anatomical Nomenclature Committee. (1968). Nomina Anatomica, 3rd edition, 2nd printing with index. New York: Excerpta Medica Foundation.
- International Committee on Veterinary Anatomical Nomenclature. (1968). Nomina Anatomica Veterinaria. Vienna.

- JURICA, E.J. (1926). Studies on the motility of the denervated mammalian esophagus. American Journal of Physiology 77, 371-384.
- JUST-VIEIRA, J.O. & HAIGHT, C. (1969). Achalasia and carcinoma of the esophagus. Surgery, Gynecology and Obstetrics 128, 1081-1095.
- KLEIN, E. (1879). Cited by Goetsch (1910).
- KNIGHT, G.C. (1934). The relation of the extrinsic nerves to the functional activity of the oesophagus. British Journal of Surgery 22, 155-168.
- KRONECKER, H. & LUSCHER, F. (1896). Cited by DeWitt (1900).
- LANGLEY, J.N. (1898). On inhibitory fibres in the vagus for the end of the oesophagus and the stomach. Journal of Physiology 23, 407-414.
- LANGMAN, J. (1969). Medical Embryology: Human Development - Normal and Abnormal, 2nd edition. pp. 249-250. Baltimore: Williams and Wilkins.
- LAWSON, D.D. & PIRIE, H.P. (1966). Conditions of the canine oesophagus. II. Vascular rings, achalasia, tumours and peri-oesophageal lesions. Journal of Small Animal Practice 7, 117-127.
- LEMERE, F. (1932a). Innervation of the larynx. I. Innervation of laryngeal muscles. American Journal of Anatomy 51, 417-437.
- LEMERE, F. (1932b). Innervation of the larynx. II. Ramus anastomoticus and ganglion cells of the superior laryngeal nerve. Anatomical Record 54, 389-407.
- LEMERE, F. (1933). Innervation of the larynx. III. Experimental paralysis of the laryngeal nerve. Archives of Otolaryngology 18, 413-424.
- LENDRUM, F.C. (1937). Anatomic features of the cardiac orifice of the stomach. Archives of Internal Medicine 59, 474-511.
- LEONARD, E.P. (1968). Fundamentals of Small Animal Surgery. pp. 164-169. Philadelphia: Saunders.
- LERCHE, W. (1950). The Esophagus and Pharynx in Action. A Study of Structure in Relation to Function. Springfield, Illinois: Thomas.
- LICHTER, I. (1974). Measurement of gastro-oesophageal acid reflux: its significance in hiatus hernia. British Journal of Surgery 61, 253-258.
- LONG, D.M., NICE, C.M., THAL, A.P. & TRUEX, R.C. (1959). The experimental production of cardiospasm in dogs. Surgical Forum 9, 408-411.
- LONGHI, E.H. & JORDAN, P.H. (1971). Necessity of a bolus for propagation of primary peristalsis in the canine esophagus. American Journal of Physiology 220, 609-612.

- MANN, C.V. & SHORTER, R.G. (1964). Structure of the canine esophagus and its sphincters. Journal of Surgical Research 4, 160-163.
- MANZANO, C., TORRES, E., HALL, R.C. & COBO, A. (1964). Motility of esophagus of dog after high vagotomy. Archives of Surgery 89, 1005-1007.
- MARKS, D. (1969). In the discussion following, Laryngeal hemiplegia in horses - a theoretical analysis, by J.R. Rooney and F.M. Delaney. Proceedings of the 15th Annual Convention of the American Association of Equine Practitioners. p. 19.
- MARLOW, J.B. (1971). Techniques for devocalising small animals: A review. Veterinary Medicine and Small Animal Clinician 66, 129-134.
- MARRABLE, A.W. (1971). The Embryonic Pig: A Chronological Account. pp. 31, 43, 63. London: Pitman.
- MAY, N.D.S. (1970). The Anatomy of the Sheep: A Dissection Manual, 3rd edition. p. 191. Brisbane: University of Queensland Press.
- McCREA, E.D. (1924). The abdominal distribution of the vagus. Journal of Anatomy 59, 18-40.
- McLEOD, W.M. (1958). Bovine Anatomy, 2nd edition, (Revised by D.M. Trotter and J.W. Lumb). pp. 215-216. Minneapolis: Burgess.
- MEISS, J.H., GRINDLAY, J.H. & ELLIS, F.H. (1958). The gastroesophageal sphincter mechanism. II. Further experimental studies in the dog. Journal of Thoracic Surgery 36, 156-165.
- MELTZER, S.J. (1899). On the causes of the orderly progress of the peristaltic movement in the oesophagus. American Journal of Physiology 2, 266-272.
- M'FADYEN, J. (1922). The Anatomy of the Horse, 3rd edition. p. 199. Edinburgh: Johnston.
- MICHELSON, E. & SIEGEL, C.I. (1964). The role of the phrenico-oesophageal ligament in the lower oesophageal sphincter. Surgery, Gynecology and Obstetrics 118, 1291-1294.
- MILLER, H.E., CHRISTENSEN, G.C. & EVANS, H.E. (1964). Anatomy of the Dog. pp. 563-570, 630-635, 663-667. Philadelphia: Saunders.
- MINCKLER, J. (Ed.), (1963). Pathology of the Nervous System 1, 567, 763-765. New York: McGraw-Hill.
- MIZERES, N.J. (1955). The anatomy of the autonomic nervous system in the dog. American Journal of Anatomy 96, 285-318.
- MIZERES, N.J. (1957). The course of the left cardioinhibitory fibers in the dog. Anatomical Record 127, 109-115.
- MIZERES, N.J. (1958). The origin and course of the cardioaccelerator fibers in the dog. Anatomical Record 132, 261-280.

- NICKEL, R., SCHUMMER, A. & SEIFERLE, E. (1973). The Viscera of the Domestic Mammals, (Translated and Revised by W.O. Sack). pp. 99-101, 122. Berlin: Parey.
- OSBORNE, C.A., CLIFFORD, D.H. & JESSEN, C. (1967). Hereditary esophageal achalasia in dogs. Journal of the American Veterinary Medical Association 151, 572-581.
- PATTEN, B.M. (1948). Embryology of the Pig, 3rd edition. pp. 80, 119, 179-181. New York: McGraw-Hill.
- PATTEN, B.M. (1964). Foundations of Embryology, 2nd edition, International Student Edition. pp. 284, 448. New York: McGraw-Hill.
- PATTEN, B.M. (1968). Human Embryology, 3rd edition. p. 85. New York: McGraw-Hill.
- POPESKO, P. (1971). Atlas of Topographical Anatomy of the Domestic Animals, (Translated by R. Getty). Philadelphia: Saunders.
- REID, J. (1838). Cited by Hwang et al. (1948).
- REIGHARD, J. & JENNINGS, H.S. (1963). Anatomy of the Cat, 3rd edition, (Revised by R. Elliott). p. 378. New York: Holt, Rinehart and Winston.
- RENAULT, J. (1897). Cited by Goetsch (1910).
- ROONEY, J.R., SACK, W.O. & HABEL, R.E. (1967). Guide to the Dissection of the Horse. Ithaca, New York: Sack.
- SCHLEGEL, J.F. & CODE, C.F. (1958). Pressure characteristics of the esophagus and its sphincters in dogs. American Journal of Physiology 193, 9-14.
- SCHOFIELD, G.C. (1968). Anatomy of muscular and neural tissues in the alimentary canal. In Handbook of Physiology, Section 6: Alimentary Canal, Volume V: Motility. pp. 1579-1627. Washington: American Physiological Society.
- SHA BAN. (1970). Innervation of the Oesophagus of Dog. Unpublished report, Massey University, Palmerston North.
- SISSON, S. (1953). The Anatomy of Domestic Animals, 4th edition, (Revised by J.D. Grossman). pp. 505, 873-875. Philadelphia: Saunders.
- SMITH, R.B. & TAYLOR, I.M. (1972). Observations on the intrinsic innervation of the human foetal oesophagus between the 10 mm and 140 mm crown-rump length stages. Acta Anatomica 81, 127-138.
- SOKOLOVSKY, V. (1972). Achalasia and paralysis of the canine esophagus. Journal of the American Veterinary Medical Association 160, 943-955.

- STARLING, E.H. (1900). The muscular and nervous mechanisms of the digestive tract. In Text-Book of Physiology, (Edited by E.A. Sharpey-Schafer). 2, 314-321. Edinburgh: Pentland.
- STOKOE, W.M. (1967). A Guide to Comparative Veterinary Anatomy. London: Bailliere, Tindall and Cassell.
- TAYLOR, J.A. (1955). Regional and Applied Anatomy of the Domestic Animals, part I. Head and Neck. Edinburgh: Oliver and Boyd.
- TRAUTMANN, A. & FIEBIGER, J. (1957). Fundamentals of the Histology of Domestic Animals, (Translated and Revised by R.E. Habel and E.L. Biberstein). pp. 177-179. Ithaca, New York: Comstock.
- VAUGHAN, I. (1895). Strangeways' Veterinary Anatomy, 5th edition, (Revised and Edited by I. Vaughan). p. 500. Edinburgh: Bell and Bradfute.
- VITMUS, A. (1962). Anomalous origin of the right subclavian and common carotid arteries in the dog. Cornell Veterinarian 52, 5-15.
- VOGEL, P.H. (1952). The innervation of the larynx of man and the dog. American Journal of Anatomy 90, 427-447.
- WARWICK, R. & WILLIAMS, P.L. (Eds.), (1973). Gray's Anatomy, 35th edition. pp. 172, 1019-1023, 1248. Edinburgh: Longman.
- WATSON, A.G. (1973). Structure of the canine oesophagus. New Zealand Veterinary Journal 21, 195-200.
- YOUNG, J.Z. (1957). The Life of Mammals. London: Oxford University Press.
- ZELLER, W. & BURGET, G.E. (1937). A study of the cardia. American Journal of Digestive Diseases 4, 113-120.
- ZONTINE, W.J. (1973). Effect of chemical restraint drugs on the passage of barium sulphate through the stomach and duodenum of dogs. Journal of the American Veterinary Medical Association 162, 878-884.

STRUCTURE OF THE CANINE OESOPHAGUS

ALASTAIR G. WATSON