

Copyright is owned by the Author of the thesis. Permission is given for a copy to be downloaded by an individual for the purpose of research and private study only. The thesis may not be reproduced elsewhere without the permission of the Author.

**CAUSES OF MORTALITY AND CHARACTERISATION OF
MYCOBACTERIOSIS IN ADULT NEW ZEALAND SEA
LIONS (*PHOCARCTOS HOOKERI*) AT ENDERBY ISLAND**

A thesis presented in partial fulfilment of the requirements for the degree of

Master of Veterinary Science

in

Wildlife Health

at Massey University, Manawatū, Palmerston North

New Zealand.

Baukje Mirjam Lenting

2017

ABSTRACT

The New Zealand sea lion (*Phocarctos hookeri*) is classified as endangered and “Nationally Critical” due to a declining population and restricted population range. There have been recent bacterial epizootic events at the breeding colonies of this species, however the role of disease in the population decline is not known. As part of the investigation into the population decline, the species management plan recommends investigation of disease agents affecting this species, their epidemiology and their long-term effects on population dynamics.

Since the 1998/1999 breeding season, post mortem examinations have been performed on deceased New Zealand sea lions at the Enderby Island breeding colonies during each breeding season, including the collection of samples for histology and bacteriology.

This study describes the causes of mortality in New Zealand sea lions one year of age and older at Enderby Island between the 1998/99 to 2010/11 breeding seasons inclusive, using the archived post mortem reports, histology samples and bacteriology samples. Conspecific trauma was found to be a significant cause of mortality (34.3%), as were various infectious causes (35.7%). The organism *Klebsiella pneumoniae* was isolated from non-pup New Zealand sea lions both from individuals that died from other causes and individuals that showed apparent morbidity as a result of this bacteria. These findings suggest that older animals may be reservoirs of infection for *K. pneumoniae*, which causes significant mortality in neonatal New Zealand sea lions.

Another important infectious agent that was described in non-pup New Zealand sea lions was *Mycobacterium pinnipedii*, which caused both subclinical and clinical disease. Mycobacteriosis of the lymph nodes, lungs, pleura, liver, peritoneum and reproductive tract was described in this study. Strain determination of the *M. pinnipedii* isolates grown show only minor strain variation among isolates, which may reflect the isolated geographic distribution of these animals. There was no apparent association between the individual strains of *M. pinnipedii* and their pathogenicity as indicated by the pathology present in infected animals.

ACKNOWLEDGEMENTS

Many individuals gave time and expertise to help make the research presented in this thesis possible. First and foremost, I cannot thank enough my supervisors Brett Gartrell and Wendi Roe, for all their time, support and teaching as this thesis progressed. Thank you to Brett for teaching me statistics, to Wendi for many hours of teaching me histology, and to both for teaching me to be a more ruthless editor.

The gross post mortem examinations and the collection of samples for histology and bacteriology used by this study were performed by researchers in Department of Conservation (DOC) field expeditions to Enderby Island, as part of ongoing DOC monitoring of the endangered New Zealand sea lion. Many thanks to all those that performed post mortems on New Zealand sea lions over the breeding seasons included in this thesis, in the sometimes wild subantarctic weather and field conditions. Thank you to Kelly Buckle, Wendi Roe, Sarah Michael, Katja Geschke, Pdraig Duignan, Nick Gales, Simon Childerhouse, Jacinda Amey and Amelie Auge, and to all other field researchers involved in the post mortem examinations performed during this study period.

Louise Chilvers from the Department of Conservation led and organised the expedition for the 2009/10 breeding season when I went to Enderby Island for 6 weeks in the position of field veterinarian, as well as many other expeditions. A big thank you to Louise for an extremely well planned and enjoyable expedition, and for much helpful advice on the fieldwork that was performed and day-to-day subantarctic island life. Thanks to my fellow expedition members Nathan, Elaine and Eric for moral and nutritional support, and a lot of rounds of "Uno".

The IVABS histology and pathology departments allowed me to use their work spaces for the trimming of tissues and storage of samples, and performed the processing of tissues for histology. Thank you to Mike Hogan and Evelyn Lupton especially.

Thank you to Stuart Hunter for helping with the interpretation of the histology for some of the cases.

Aerobic bacteriology cultures were performed by the ever helpful and skilled team at NZVP, Palmerston North, and by Hamish at IVABS. Mycobacterial culture, PCR and *Mycobacterium pinnipedii* strain determination were performed by the team at AgResearch Wallaceville, with thanks especially to Geoff de Lisle and Marian Price-Carter. For your many hours of lab work and all your expertise I am very grateful.

And lastly thanks to the wonderful Jon and to my family and friends, for all your support throughout. And to Nicky Denning, for letting me “thesis” by the fire under a handmade quilt on many occasions.

TABLE OF CONTENTS

| | |
|-----------------------------------------------------------------------------------|----------|
| Abstract..... | ii |
| Acknowledgements | iii |
| Table of Contents | v |
| List of Figures | viii |
| List of Tables | xi |
| | |
| CHAPTER 1: Literature Review | 1 |
| 1.1 New Zealand Sea Lion Distribution and Biology..... | 1 |
| 1.2 Causes of Mortality in Pinnipeds..... | 7 |
| 1.2.1 Non-infectious causes of mortality..... | 7 |
| 1.2.1.1 Predation | 7 |
| 1.2.1.2 Conspecific trauma | 8 |
| 1.2.1.3 Biotoxins | 10 |
| 1.2.2 Infectious disease | 10 |
| 1.2.2.1 Mass mortality events in New Zealand sea lions | 10 |
| 1.2.2.2 Other disease agents of potential significance to the NZSL | 12 |
| 1.3 Disease Ecology in Pinnipeds..... | 15 |
| 1.3.1 Disease transmission in pinnipeds | 15 |
| 1.3.2 Effects of disease on pinniped populations..... | 16 |
| 1.4 Tuberculosis..... | 17 |
| 1.4.1 The <i>Mycobacterium tuberculosis</i> complex | 17 |
| 1.4.2 Pathophysiology of tuberculosis..... | 18 |
| 1.4.3 <i>Mycobacterium pinnipedii</i> | 20 |
| 1.4.3.1 Taxonomy..... | 20 |
| 1.4.3.2 Distribution of <i>Mycobacterium pinnipedii</i> | 21 |
| 1.4.3.3 Mycobacterial infection in New Zealand pinnipeds | 22 |
| 1.4.3.4 Pathology of <i>Mycobacterium pinnipedii</i> infection in pinnipeds | 23 |
| 1.4.3.5 Diagnosis of <i>Mycobacterium pinnipedii</i> infection in pinnipeds..... | 25 |
| 1.4.3.6 Zoonotic implications | 27 |

| | |
|---------------------------------------------------------------------------------------------------------------------------------------------------------------------|---------------|
| 1.4.3.7 Implications for other species..... | 27 |
| 1.5 Research Aims | 29 |
| CHAPTER 2: Post Mortem Findings in Non-Pup New Zealand Sea Lions (<i>Phocarctos hookeri</i>) at Enderby Island | 30 |
| 2.1 Introduction | 30 |
| 2.2 Materials and Methods..... | 32 |
| 2.3 Results..... | 34 |
| 2.3.1 General comments | 34 |
| 2.3.2 Causes of mortality | 39 |
| 2.3.2.1 Bacterial and parasitic infections (n = 25) | 39 |
| 2.3.2.2 Conspecific trauma (n = 24) | 42 |
| 2.3.2.3 Predation (n = 2) | 44 |
| 2.3.2.4 Unknown causes of death (n = 19) | 44 |
| 2.3.3 Concurrent and incidental diseases | 45 |
| 2.3.3.1 Bacterial infections | 45 |
| 2.3.3.2 Other bacterial isolates | 45 |
| 2.3.3.3 Parasitism | 48 |
| 2.3.3.4 Predation injuries | 49 |
| 2.3.3.5 Neoplasia..... | 49 |
| 2.4 Discussion | 49 |
| 2.5 Conclusions..... | 57 |
| CHAPTER 3: Characterisation of <i>Mycobacterium pinnipedii</i> infection in New Zealand Sea Lions (<i>Phocarctos hookeri</i>) at Enderby Island..... | 59 |
| 3.1 Introduction | 59 |
| 3.2 Materials and Methods..... | 61 |
| 3.2.1 Archived samples and data | 61 |
| 3.2.2 Sample preparation, lesion review and laboratory analysis..... | 61 |
| 3.3 Results..... | 63 |
| 3.3.1 Gross and histological findings..... | 63 |

| | |
|----------------------------------------------------------------------------------------------|----------------|
| 3.3.2 Identification and characterisation of mycobacterial isolates..... | 64 |
| 3.3.3 Characterisation of pathology associated with confirmed mycobacteriosis in NZSLs | 66 |
| 3.4 Discussion | 87 |
| 3.4.1 Pathology | 87 |
| 3.4.2 Strain variation in <i>Mycobacterium pinnipedii</i> from NZSLs | 92 |
| 3.4.3 Importance of mycobacteriosis to the NZSL..... | 93 |
| 3.4.4 Study limitations | 99 |
| 3.4.5 Implications for livestock health and zoonotic disease | 102 |
| 3.5 Conclusions..... | 103 |
| CHAPTER 4: General Discussion | 104 |
| APPENDIX 1: Post Mortem, Histology and Bacteriology Findings | 110 |
| LITERATURE CITED | 150 |

LIST OF FIGURES

| | | |
|-------------------|------------------------------------------------------------------------------------------------------------------------------------------------------------------------------------------------------------------------------------------------------------------------------------------------------------------------------------------------------------------------------------------------|----|
| Figure 1.1 | A map of the Auckland Islands, showing their location in relation to New Zealand and other sites of interest with regards to the current distribution of the New Zealand sea lion. Figure included with permission from the Department of Conservation | 3 |
| Figure 2.1 | Causes of mortality of non-pup NZSLs at Enderby Island for the breeding seasons 1998/99 to 2010/11 inclusive | 37 |
| Figure 2.2 | Number of tag resights and number of dead NZSLs that had post mortem examinations performed at Enderby Island for the breeding seasons 1998/99 to 2010/11 inclusive | 37 |
| Figure 3.1 | A case of mycobacterial infection in a NZSL examined at IVABS Massey University Palmerston North showing severe consolidation and multifocal coalescing granulomas of various sizes in the lung on cut surface | 69 |
| Figure 3.2 | Haematoxylin and eosin stain. Scale bar represents 2mm. Lung tissue from case E08/09-53Ph showing severe chronic multifocal to coalescing granulomatous bronchopneumonia. There are large areas of necrosis surrounded by granulomatous inflammation. In parts of the lungs that were less severely affected, smaller discrete granulomas were present, with or without necrotic centres | 70 |
| Figure 3.3 | Haematoxylin and eosin stain. Scale bar represents 200µm. Lung tissue from case E08/09-53Ph showing lung granulomas consisting central necrosis surrounded by an inflammatory infiltrate of predominantly macrophages and a small number of lymphocytes and plasma cells | 71 |
| Figure 3.4 | Ziehl-Neelsen stain. Scale bar represents 50µm. Lung granulomas from case E00/01-42Ph showing a small number of visible AFOs intracellularly in macrophages and in necrotic debris | 72 |
| Figure 3.5 | An enlarged middle tracheobronchial lymph node from case E09/10-13Ph, showing a cream-coloured nodular mass 20mm in diameter on cut surface | 73 |
| Figure 3.6 | Haematoxylin and eosin stain. Scale bar represents 2mm. A lymph node from case E09/10-13Ph showing large well-circumscribed and often coalescing areas of necrosis, surrounded by a rim of granulomatous inflammation with a small number of lymphocytes | 74 |

| | | |
|--------------------|--------------------------------------------------------------------------------------------------------------------------------------------------------------------------------------------------------------------------------------------------------------------------------------------------------------------------------------------------|----|
| Figure 3.7 | Ziehl-Neelsen stain. Scale bar represents 50µm. A lymph node from case E09/10-13Ph showing occasional visible AFOs in granulomas. In this case, AFOs were seen in the cytoplasm of macrophages and in necrotic debris | 75 |
| Figure 3.8 | Gingival mucosa of case E09/10-17Ph showing severe jaundice | 76 |
| Figure 3.9 | Haematoxylin and eosin stain. Scale bar represents 500µm. Liver tissue from case E09/10-17Ph showing a severe chronic granulomatous hepatitis. There are multifocal discrete and occasionally coalescing aggregations of macrophages randomly distributed throughout all examined liver sections. Normal hepatic architecture is disrupted | 77 |
| Figure 3.10 | Haematoxylin and eosin stain. Scale bar represents 200µm. Liver tissue from case E09/10-17Ph showing a discrete aggregation of macrophages with a small number of associated lymphocytes and neutrophils. There is mild degeneration and necrosis of hepatic tissue surrounding the granulomatous inflammation | 78 |
| Figure 3.11 | Ziehl-Neelsen stain. Scale bar represents 50µm. Liver tissue from case E09/10-17Ph showing large numbers of intracellular AFOs within the macrophages of hepatic granulomas | 79 |
| Figure 3.12 | Haematoxylin and eosin stain. Scale bar represents 500µm. Peritoneum from case E00/01-42Ph, showing moderate-severe, fibrinous and lymphocytic peritonitis, resulting in marked thickening of the peritoneum | 80 |
| Figure 3.13 | Haematoxylin and eosin stain. Scale bar represents 200µm. Peritoneum from case E00/01-42Ph showing a moderate-severe, fibrinous and lymphocytic peritonitis with small multi-focal accumulations of macrophages throughout areas of thickened peritoneum, forming small granulomas | 81 |
| Figure 3.14 | Haematoxylin and eosin stain. Scale bar represents 500µm. Uterus from case E00/01-42Ph showing a moderate granulomatous endometritis affecting approximately 30% of the endometrium of the examined section of uterus | 82 |
| Figure 3.15 | Haematoxylin and eosin stain. Scale bar represents 200µm. Uterus from case E00/01-42Ph showing a large discrete accumulation of macrophages within the endometrium, with some lymphocytes and plasma cells in the periphery. The larger of these granulomas in other sections of uterus showed central necrosis and mineralisation | 83 |

- Figure 3.16** Opened pleural cavity of case E09/10-10Ph showing severe thickening of the pleura and pericardium. The pleura is 2-3mm thick and white, with a cobblestoned surface of soft villous nodules measuring 3-10mm in diameter. There is a large volume of clear yellow-green viscous fluid in the pleural space. There are multiple soft white round bodies on average 5mm in diameter floating free within the pleural effusion84
- Figure 3.17** Haematoxylin and eosin stain. Scale bar represents 2mm. Lung and pleura from case E09/10-10Ph showing severe chronic granulomatous pleuritis, resulting in a markedly thickened pleura with villous projections. There was a concurrent severe chronic granulomatous pericarditis85
- Figure 3.18** Haematoxylin and eosin stain. Scale bar represents 200µm. Pleura from case E09/10-10Ph showing a severe chronic granulomatous pleuritis consisting of a thick layer of macrophages, fibrous tissue and occasional plasma cells and lymphocytes with no distinct organisation, and with small focal areas of necrosis86

LIST OF TABLES

| | | |
|------------------|---------------------------------------------------------------------------------------------------------------------------------------------------------------------------------------------------------|----|
| Table 2.1 | Causes of mortality in NZSLs at Enderby Island, showing the frequency of causes of mortality by cohort | 38 |
| Table 2.2 | Bacterial isolates grown from post mortem tissues of non-pup NZSLs sampled at Enderby Island for the breeding seasons 1998/99 to 2010/11 inclusive | 47 |
| Table 3.1 | Mycobacterial culture results from NZSL post mortem cases with confirmed mycobacterial infection | 65 |
| Table 3.2 | Table of nine variable number of tandem repeat (VNTR) and two direct repeat (DR) loci for the isolates grown from six cases of <i>Mycobacterium pinnipedii</i> infection in New Zealand sea lions | 65 |
| Table 3.3 | Histological findings, culture results and PCR results in nine New Zealand sea lions with confirmed mycobacterial infection | 67 |

CHAPTER ONE

LITERATURE REVIEW

The species management plan for the New Zealand sea lion (*Phocarctos hookeri*) (NZSL) states that reducing the vulnerability of the NZSL depends on increasing the population size and the breeding distribution, and suggests that a recommended goal for further research is therefore to investigate disease agents affecting this species, their epidemiology and their long-term effects on population dynamics (Department of Conservation 2009). In line with this, this thesis focusses on investigating the causes of mortality in adult NZSLs at the Enderby Island breeding colonies, including trauma and infectious disease.

1.1 NEW ZEALAND SEA LION DISTRIBUTION AND BIOLOGY

The NZSL, previously known as the Hookers sea lion, is endemic to New Zealand. A range of records and archaeological findings show that the NZSL historically ranged along the coasts of all of mainland New Zealand, Stewart Island/Rakiura and the subantarctic islands south of New Zealand (Childerhouse and Gales 1998; Worthy 1994). The current range of the NZSL is much reduced from its historical range, assumed to be

predominantly the result of anthropogenic activity such as sealing by European settlers and hunting by the Maori and Moriori (Smith 1989; Childerhouse and Gales 1998). During the early 19th Century there was extensive hunting of New Zealand fur seals (*Arctocephalus forsteri*) and NZSLs in the subantarctic by European and American sealers and this is believed to have contributed significantly to the population decline observed during this period (Childerhouse and Gales 1998). Sealing became prohibited for both species in 1893 and anecdotal reports indicate partial recovery of NZSL numbers at the Auckland Islands over the century that followed (Childerhouse and Gales 1998). Pup counts at Sandy Bay (Enderby Island, Auckland Islands) during breeding seasons from 1972-1995 indicate probable stability in annual pup production at this location over this time period (Childerhouse and Gales 1998).

The NZSL is classified as 'endangered' by the IUCN (IUCN 2016) and "Nationally Critical due to a decline in abundance" by the New Zealand Threat Classification system based on a declining population and restricted range (Townsend et al. 2008; Baker et al. 2010). Haul outs and sightings of small numbers of individuals without breeding have been reported at Macquarie Island (McMahon, Holley, and Robinson 1999; Robinson, Wynen, and Goldsworthy 1999), Stewart Island/Rakiura (Wilson 1979), the Snares Islands (Crawley and Cameron 1972) and multiple sites around the South Island of New Zealand (Gales 1995; Wilson 1979; Beentjes 1989). These haul outs indicate the likely outer extents of the species' current range. The restricted range of the species is a concern, as an oil spill or natural disaster at the breeding colonies would affect a significant proportion of the population simultaneously (Department of Conservation 2009).

Most of the population is concentrated around the Auckland Islands where the majority of breeding occurs (79-86%), with most of the remaining breeding occurring at Campbell Island (Motu Ihupuku) (Maloney et al. 2009). Within the Auckland Islands, approximately 70% of pup production occurs on Dundas Island and the remainder at Sandy Bay on Enderby Island and the smaller colony at Figure of Eight Island (Gales and Fletcher 1999; Childerhouse and Gales 1998). A small number of pups are born annually at South East Point on Enderby Island (Childerhouse and Gales 1998; Gales and

Fletcher 1999), The Snares Islands (<10 pups) and Stewart Island/Rakiura (Gales and Fletcher 1999; Crawley and Cameron 1972; Cawthorn 1993). Since the 1993/94 breeding season a small number of pups (<5) have been produced annually in Otago on the South Island of New Zealand, a breeding population founded by one female (McConkey, McConnell et al. 2002), indicating a possible recolonisation of historic breeding sites (Childerhouse and Gales 1998; Beentjes 1989). It has only been since 2011 that pupping has been confirmed on Stewart Island/Rakiura with the pup numbers estimated to be just over 30 pups a year and currently at-the-least this appears to be a stable population (B. L. Chilvers pers comm).

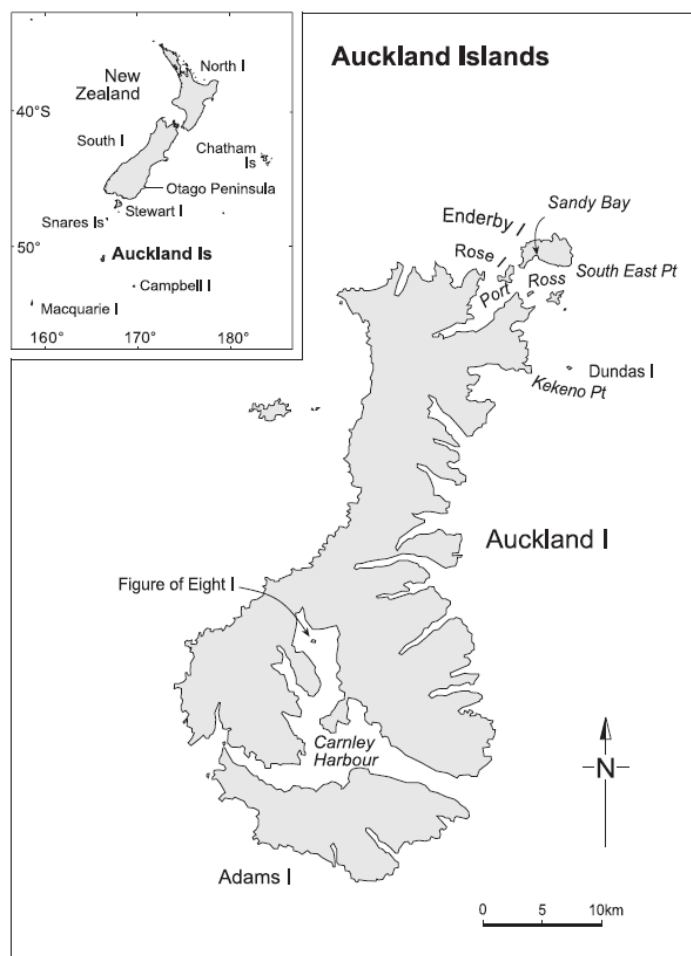


Figure 1.1: A map of the Auckland Islands, showing their location in relation to New Zealand and other sites of interest with regards to the current distribution of the New Zealand sea lion. Figure included with permission from the Department of Conservation.

The NZSL is sexually dimorphic, with males weighing up to 400kg and the smaller, lighter-coloured females weighing between 100-160kg (Department of Conservation 2009). Pupping on the Auckland Islands begins in the first week of December, when females haul out and form harems of approximately 25 individuals around territorial adult males (Department of Conservation 2009). Females produce a pup every 1-2 years (Department of Conservation 2009). Pupping is highly synchronised and is usually finished by the second week of January when the harems break up (Gales and Fletcher 1999). Non-territorial males and subadult males surround the periphery of the harems, attempting to challenge dominant males and mate females as they arrive and depart (Department of Conservation 2009). Mating of the females occurs during post-partum oestrous, usually within 2 weeks of pupping (Marlow 1975; Gales 1995) and most frequently with the territorial male. The females feed their pups for their first year of life (Department of Conservation 2009), returning from foraging at sea to suckle their young every 24-48 hours (Baker 1999).

Pup production is considered to be the most reliable index to estimate the total population size for pinnipeds because pups are initially land bound, they are an easily recognisable age class and they are an index of the number of reproductive females (Gales and Fletcher 1999; Chilvers, Wilkinson, and Childerhouse 2007; Berkson and Demaster 1985). Using pup production estimates, 95% confidence intervals for the population size of the NZSL were 10,500-13,100 for the 1994/95 breeding season and 11,100-14,000 for the 1995/96 breeding season (Gales and Fletcher 1999). Further monitoring from the 1996/97 breeding season to the 2005/06 season showed a 31% reduction in pup production at the Auckland Island colonies during this period (Chilvers, Wilkinson, and Childerhouse 2007). During the 2010/11 field season the estimated pup production for the Auckland Island breeding colonies was 1550 ± 41 , a 49% drop in pup production since 1997/78 (Chilvers and Wilkinson 2011) and the lowest total pup count on record for the Auckland Island sites was for the 2008/09 breeding season at 1501 ± 16 pups (Chilvers 2009). These later publications do not extrapolate their reported pup counts to population size estimates, however the ongoing trend of decreasing annual pup counts likely correlates with an overall decline in the population

(Robertson and Chilvers 2011). The most recent published population size estimate is 9,880 animals with a 95% confidence interval of 8,604-11,297 (Geschke and Chilvers 2009). The decline appears greatest at the Auckland Island breeding colonies, and although the population at Campbell Island is increasing, there is still an overall decline in population size (Robertson and Chilvers 2011).

The reason for the decline is not well understood. It is unusual for NZSL females to breed in areas other than where they were born, therefore dispersal and migration are unlikely to be the cause of local population decline (Chilvers and Wilkinson 2008; Robertson and Chilvers 2011).

Interactions with fisheries may contribute to the NZSL population decline. A no-take Marine Reserve extending 22km out to sea around the Auckland Islands was established in 2003 to protect the NZSL colonies (Chilvers 2008). This complements the Marine Mammal Sanctuary established in 1995 and both are managed by the New Zealand Marine Mammals Protection Act (1978)(Chilvers 2008). The arrow squid (*Nototodarus sloani*) fishery is active around the Auckland Islands between February and May each year, a time period when female NZSLs are lactating (Chilvers 2008; Gales 1995). The arrow squid is part of the NZSL diet and NZSL foraging areas overlap with the fishing area named SQU6T (Chilvers, Wilkinson et al. 2005). The potential effect of fisheries on the NZSL population is two-fold: indirect effects through competition for the same resources and direct effects through death as by-catch (Chilvers, Wilkinson et al. 2005). A variable number of NZSLs die annually as by-catch in the SQU6T fishery and estimated NZSL mortalities from 1992 to 2007 range from 14-123 individuals per year (Chilvers 2008). A smaller number of sea lions are captured in the southern blue whiting (*Micromesistius australis*) fishery around Campbell Island in August-September each year (Robertson and Chilvers 2011). The death of a single female at the time of lactation also causes the death of her dependant pup on land and her foetus in utero (Chilvers 2008). It is unknown what the impact of by-catch is on the NZSL population, some models suggest that it might limit population increase or cause a population decline (Robertson and Chilvers 2011), whereas others state there may be little impact (Chilvers 2008; Woodley and Lavigne 1993).

Other anthropogenic effects on the NZSL that are largely unquantified include marine debris, deliberate harassment and the effects of tourism. Marine debris such as plastic and nets is known to entangle and injure or kill pinnipeds (Hiruki, Gilmartin et al. 1993; Hanni and Pyle 2000), and such events have been described for the NZSL (Gales 1995). Tourists frequent the Auckland Islands during the breeding season and people also have access to the haul out sites and breeding sites in the Otago area. While they are not permitted near the animals and while the animals appear behaviourally to tolerate a small amount of human activity some distance away, it is not known what effect this low level disturbance has on the NZSL (Gales 1995; Beentjes 1989). There have been documented cases of deliberate harassment and shooting of individual NZSLs on the New Zealand mainland (Gales 1995; McConkey, McConnell et al. 2002).

Disease has been documented to be the cause of population declines in wildlife species (McCallum et al. 2007; Gillespie et al. 2015) and similarly, disease in some marine mammal species is thought to have negative implications for the health of the population or potentially impair population recovery (Kreuder et al. 2003). Increased mortality due to disease epizootics occurred in the 1997/98, 2001/02 and 2002/03 NZSL breeding seasons, and will be discussed in more detail in following sections. Robertson and Chilvers (2011) theorise that these mass mortality events are naturally occurring events for the NZSL and consider them to have demographic consequences such as reduced recruitment, but that it is likely that the impact of such disease events leave the Auckland Islands and Campbell Island breeding populations “vulnerable to other factors” rather than being the sole cause of the decline (Robertson and Chilvers 2011). Other studies consider these bacterial epizootics to be a factor affecting population decline directly (Baker et al. 2010; Chilvers, Wilkinson, and Childerhouse 2007).

Environmental toxins, climatic fluctuations leading to prey shortages and reduced genetic diversity have also been investigated as potential causes of immunosuppression and population decline in the NZSL. Initial tests into levels of polychlorinated biphenyls (PCBs), organochlorines (OCs) and other persistent contaminants in NZSL tissue samples have shown low tissue levels by global standards, so it is unlikely that these contaminants play a role in population decline (Baker 1999; Donaldson 2008; Robertson

and Chilvers 2011). Environmental change, such as the cyclic climatic changes seen in the subantarctic areas due to El Nino/Southern Oscillation (ENSO) could affect the abundance of prey species of the NZSL, however this is unlikely to be the sole cause of the decline as the Auckland Islands and Campbell Island should be affected equally by these effects (Robertson and Chilvers 2011). Reduced genetic diversity in the NZSL due to a population bottleneck and inbreeding has also been discounted by two studies: a study investigating heterozygosity and number of alleles at certain loci (Robertson and Chilvers 2011), and a study investigating the genetic diversity of two major histocompatibility complex (MHC) genes (Osborne et al. 2013).

1.2 CAUSES OF MORTALITY IN PINNIPEDS

1.2.1 Non-infectious causes of mortality

1.2.1.1 Predation

Predation is documented in many marine mammal species. Two known predators of sea lions worldwide are sharks and orca (*Orcinus orca*) (Robertson and Chilvers 2011). The most common injuries seen in southern elephant seals (*Mirounga leonina*) in Antarctica were from predators, presumed to be from orca and leopard seals (*Hydrurga leptonyx*) (Tierney 1977). Shark attacks have been witnessed in the Hawaiian monk seal (*Monachus schauinslandi*) (Alcorn and Kam 1986) and examination of individuals at two colonies showed 12.4% and 27.9% had wounds strongly suggestive of shark attacks (Hiruki, Gilmartin et al. 1993). Fatal and non-fatal injuries of NZSLs have been reported due to leopard seals (Gales 1995) and great white sharks (*Carcharodon carcharias*) (Robertson and Chilvers 2011). Wounds suspicious for orca bites (Gales 1995) and shark bites have been recorded in NZSLs (Wilkinson et al. 2011) and annual breeding season surveys of adult sea lions on Enderby Island have shown that approximately 27% of individuals show scarring and/or fresh wounds most likely caused by non-fatal shark bites (Robertson and Chilvers 2011). Animals sustaining injuries from marine predators may die at sea, therefore the true numbers of this kind of mortality are difficult to gauge. There has been

no noticeable increase in predation on NZSLs over the period of population decline (Robertson and Chilvers 2011).

1.2.1.2 Conspecific trauma

Many pinnipeds breed in large polygynous colonies, with a small number of males holding harems or territories containing females, and a number of peripheral males with high libido but limited access to females. Traumatic injury from aggressive conspecific interactions in these harem settings is a cause of morbidity and mortality in marine mammals (Tierney 1977; Mesnick and Le Boeuf 1991; Galimberti, Boitani, and Marzetti 2000; Carrick and Ingham 1962; Hiruki, Gilmartin et al. 1993; Atkinson et al. 1994; Campagna and Le Boeuf 1988; Chilvers, Robertson et al. 2005; Le Boeuf and Mesnick 1991)

Aggressive encounters between adult male pinnipeds may range from highly ritualised displays (Campagna and Le Boeuf 1988) to more violent interactions (Hiruki, Gilmartin et al. 1993; Marlow 1975). Aggressive interactions between adult NZSL males are most commonly territorial disputes and these interactions are highly ritualised and rarely result in wounding serious enough to cause death, while those between adult males and subadult males are less ritualised and more violent (Marlow 1975).

Adult female California sea lions (*Zalophus californianus*), grey seals (*Halichoerus grypus*) and Australian sea lions interact aggressively with other females for space within breeding colonies (Gerber et al. 2010; Boness, Bowen, and Iverson 1995; Marlow 1975). Aggression between adult NZSL females within the harems is infrequent, brief and ritualised (Marlow 1975). These studies do not describe significant injuries due to female-female interactions.

Harem males or males peripheral to the harems can interact aggressively with adult females, especially during attempts at copulation. Male pinnipeds are often significantly larger than females and these encounters can result in injury and death (Le Boeuf and Mesnick 1991; Chilvers, Robertson et al. 2005; Mesnick and Le Boeuf 1991; Galimberti, Boitani, and Marzetti 2000). Le Boeuf et al (1991) recorded 17 female deaths in 20 years in a colony of northern elephant seals (*Mirounga angustirostris*) and described injuries to

the head, skull and spine, or crushing injuries of the ribs and rupture of internal organs in these females (Le Boeuf and Mesnick 1991). Crushing injuries and large wounds along the dorsum are sustained in female Hawaiian monk seals during matings by multiple males (Hiruki, Gilmartin et al. 1993; Johanos and Kam 1986; Atkinson et al. 1994; Hiruki, Stirling et al. 1993), and injuries of this nature were recorded for 87.5% of female Hawaiian monk seals that had a post mortem examination performed between 1983-1989 at one study site (Hiruki, Stirling et al. 1993).

Male pinnipeds may display similar behaviours towards pups and yearlings of both sexes. Northern elephant seal adult and subadult males, especially lower ranking ones, were seen to mount recently weaned pups and yearlings, with approximately 35% of examined dead weanlings showing fatal injuries suspected to be caused by adult males (Rose, Deutsch, and Le Boeuf 1991). Copulation in shallow water was observed to cause the death of a northern elephant seal weanling by drowning (Rose, Deutsch, and Le Boeuf 1991). Hawaiian monk seal males have been shown to inflict injuries on subadult and juvenile males and females similar to those seen in adult females during mating events (Hiruki, Gilmartin et al. 1993).

Reports of deaths by conspecific trauma occasionally show an underlying disease in the animal that died, potentially indicating that disease made them an easier target for aggression (Rose, Deutsch, and Le Boeuf 1991). It seems probable that animals with underlying disease may be weaker or exhibit abnormal behaviour or less efficient avoidance tactics, making them more prone to interactions that cause injury or death. Conversely, secondary infections of traumatic wounds may cause morbidity or mortality after the traumatic event, for example southern elephant seals in Antarctica were observed to rapidly develop infections in superficial fight wounds (Tierney 1977).

Population size and demographics may play a role in aggressive interactions between pinnipeds. A study of California sea lions showed higher aggression rates at a colony where the population was declining but were unable to determine whether this was a cause or a consequence of the decline (Young, Gonzalez-Suarez, and Gerber 2008). The

frequency of death due to conspecific aggression at NZSL breeding colonies is not known, nor whether rates of aggression are related to population decline.

1.2.1.3 Biotoxins

Biotoxins can be agents of mass mortality in marine mammals. The deaths of over 400 wild California sea lions in 1998 were caused by the neurotoxin domoic acid as a result of a *Pseudo-nitzschia australis* (diatom) bloom (Scholin et al. 2000). Other dinoflagellate biotoxins have been diagnosed in marine mammals, including brevetoxicosis in manatees (*Trichechus manatus latirostris*) (Bossart et al. 1998) and saxitoxin poisoning in humpback whales (*Megaptera novaeangliae*) (Geraci et al. 1989). Dinoflagellate blooms producing domoic acid have not been recorded in New Zealand, but blooms of dinoflagellates from the genus *Gymnodinium* have been recorded (Chang 1999; Seki et al. 1995). *Gymnodinium* cf. *mikimotoi* produces the neurotoxin gymnodimine, which can be toxic to fish and humans and can accumulate in organisms like New Zealand oysters (*Tiostrea chilensis*) (Seki et al. 1995). During the 1998 NZSL epizootic event discussed further below; blood, tissue and stomach content samples were tested for brevetoxin, saxitoxin, domoic acid, okadaic acid and unknown biotoxins, and all results were negative for these toxins (Baker 1999).

1.2.2 Infectious disease

A range of infectious agents have been reported to cause morbidity and mortality in pinniped species. This review is confined to agents that have been reported to cause mass mortality events in the NZSL or are diseases of potential significance to pinnipeds of the southern hemisphere.

1.2.2.1 Mass mortality events in New Zealand sea lions

Three epizootic events have caused increased mortality at NZSL breeding colonies in recent history. The first occurred at Enderby and Dundas Islands in January and February 1998 when 74 adults were found dead and pup mortality rose to approximately 60% (Baker 1999). The clinical signs and pathological findings were consistent with septicaemia and vasculitis (Baker 1999). Clinical signs were rare in pups, but many of

the adults that died had large abscesses in the area around the salivary glands and retropharyngeal lymph nodes (Baker 1999). Cell cultures and other virology tests were negative for influenza viruses, morbilliviruses and herpesviruses and serological testing showed that CDV and PDV were not the cause of the outbreak (Baker 1999). Tests for several known marine biotoxins were negative and organochlorine levels in blubber samples of affected animals were low compared to the northern hemisphere, indicating it was unlikely that these toxins and contaminants played a role in mortality (Baker 1999). Pleomorphic gram-negative bacteria were isolated and initial reports stated that the organism shared morphological characteristics with *Haemophilus* spp. but it was revised to being most similar to a *Campylobacter*-like organism (Baker 1999; Duignan 2000). Three hypotheses have been proposed for the epizootic: the bacterium was a novel pathogen to a naïve population, or it was a normal commensal which caused opportunistic infections as a result of a change within the host, or an event such as a viral infection or marine biotoxin predisposed the NZSL population to a range of bacterial infections (Baker 1999).

Klebsiella pneumoniae caused epizootics in the 2001/02 and 2002/03 breeding seasons, when pup mortality increased from a mean of 10.2% in nonepidemic years to 31.3% and 22.1% respectively (Castinel, Duignan et al. 2007). Death was due to bacterial septicaemia (Duignan, Wilkinson, and Alley 2003) resulting from infection by a clonal lineage of a highly pathogenic *K. pneumoniae* (Castinel, Grinberg et al. 2007). The bacterium has been cultured from tissues of dead pups at a lower frequency since these epizootics, but not from tissues preceding these years (Castinel, Duignan et al. 2007). Roe et al showed that during the 2006/07 to 2009/10 breeding seasons, *K. pneumoniae* was the cause of death of 58% of pups at the Enderby island breeding colonies, and affected pups showed neonatal septicaemia and meningitis (Roe et al. 2015). The organism cultured was a hypermucoviscous strain, similar to human strains that cause neuro-invasive disease (Roe et al. 2015). *Klebsiella pneumoniae* has been diagnosed as the cause of death of an adult male NZSL (Robertson et al. 2006) and a pup on the mainland also (Roe et al. 2015). The origin and potential transmission routes for this pathogen in NZSL breeding

colonies are not yet well understood, and the organism remains an important cause of pup mortality.

1.2.2.2 Other disease agents of potential significance to the NZSL

The role of disease in mortality of adult NZSLs outside of documented epizootic events has not been fully determined. There are several known infectious agents in pinnipeds that may be of significance to the NZSL, either via epizootic events or lower levels of mortality.

Leptospirosis, most likely due to serotypes Pomona and Autumnalis, caused an epizootic of acute renal failure among wild California sea lions in 1970, resulting in disease and death predominantly in subadult males (Vedros et al. 1971). Further epizootics of the disease occurred in the autumn of 1984, 1988, 1991 and 1994, where *Leptospira interrogans* serovar Pomona, strain *kenniwicki* was believed to be the causative agent (Gulland et al. 1996). Mortality due to leptospirosis has been documented in northern fur seals (*Callorhinus ursinus*) due to serovar Pomona (Smith et al. 1977), captive harbour seals due to serovar Icterohaemorrhagiae (Kik et al. 2006) and captive pacific harbour seals due to serovar Grippotyphosa (Stamper, Gulland, and Spraker 1998). A serological study of New Zealand fur seal pups on the New Zealand mainland detected positive or suspicious titres for the organisms *L. interrogans* serovar Canicola, *L. interrogans* serovar Pomona and *L. borgpetersenii* serovar Hardjo, indicating exposure to these serovars, although no cases of clinical disease were reported (Mackereth et al. 2005). In a study of 138 adult NZSLs from Sandy Bay, Enderby Island and 9 from the Otago Peninsula, one female from Enderby Island had a low titre against *L. interrogans* serovar Pomona (Roe et al. 2010). It is therefore unlikely that leptospirosis caused by these serovars is actively maintained in the NZSL population and also unlikely that it currently has a significant effect on population dynamics, however continued surveillance for *Leptospira* serovars is recommended due to the potential risk to human and livestock health (Roe et al. 2010), as well as the health of the NZSL population.

Brucella isolates have been found in a large number of marine mammal species (Jahans, Foster, and Broughton 1997) and have recently been reclassified as *B. pinnipediae* for seal

isolates and *B. cetaceae* for cetacean isolates (Cloeckaert et al. 2001). Serological studies show evidence of exposure to *Brucella* spp. in marine mammal populations worldwide (Abalos et al. 2009; Retamal et al. 2000; Nielsen et al. 2001). It therefore appears that *Brucella* is enzootic in many marine mammal populations around the world (Foster et al. 2002). Lesions include mastitis, lymphadenitis, peritonitis, sub-blubber abscessation, splenic and hepatic necrosis, epididymitis, abortion, spinal discospondylitis and meningitis, however in general the organism seems to behave as a secondary or opportunistic pathogen (Foster et al. 2002). Marine strains of *Brucella* are zoonotic (Brew et al. 1999; McDonald et al. 2006). Serological studies of wild New Zealand fur seal pups showed no evidence of *Brucella* exposure (Mackereth et al. 2005). Serological studies for *Brucella* on serum from adult female NZSL from Sandy Bay, Enderby Island and the Otago peninsula showed that one female on Enderby Island had a weak positive result for *Brucella abortus* antibodies (Roe et al. 2010). Based on this result, it would appear that the Enderby Island and Otago populations are naïve to brucellosis, and therefore highly susceptible, however the sensitivity and specificity for these tests in the NZSL are not known and only adult females were tested, so this study should be extrapolated to the entire population with care (Roe et al. 2010).

Pinniped species can carry several pathogenic *Salmonella* serotypes (Fenwick et al. 2004). Rectal swabs from healthy wild northern fur seal and California sea lion pups recovered *S. enterica* Newport, *S. enterica* Oranienburg and *S. enterica* Heiderberg, indicating that the pups were probably asymptomatic carriers (Gilmartin, Vainik, and Neill 1979). *Salmonella* serotype Typhimurium DT104 has been isolated from a grey seal (Foster et al. 1998). Of 1,123 California sea lions, harbour seals and northern elephant seals admitted to a rehabilitation centre in the USA, *Salmonella* spp. were isolated from liver, lung, gastrointestinal tract and abscess samples from 49 individuals and *S. enterica* Newport was the most common of nine serotypes isolated (Thornton, Nolan, and Gulland 1998). During the 1997/98 breeding season NZSL epizootic event, four *Salmonella* serotypes were isolated from post mortem samples: *S. enterica* Cerro, *S. enterica* Newport, *S. enterica* Derby and *S. enterica* Enteritidis, but were considered to be opportunists rather than primary pathogens (Fenwick et al. 2004).

Morbilliviruses have caused large-scale epizootics in phocids (Grachev et al. 1989; Dietz, Heidejorgensen, and Harkonen 1989; Hofmeister et al. 1988; Kennedy et al. 1988; Cosby et al. 1988; Jensen et al. 2002; Harkonen et al. 2006). Disease due to PDV has not been reported in otariid species (Duignan 2000) and only preliminary research has been done so far regarding this pathogen in New Zealand pinnipeds. The serology results of 28 convalescent adult female NZSLs sampled during the 1998 Auckland Islands mass mortality event were negative for canine distemper virus (CDV) and 14% had moderate titres against phocine distemper virus (PDV) (Baker 1999). These levels indicate exposure to a PDV-like virus in the past but were not high enough for PDV to be implicated as the cause of the mass mortality (Baker 1999; Duignan 2000).

During the 1979-1980 influenza A epizootic of harbour seals, a new species of *Mycoplasma* was isolated from the lungs of six affected seals, *Mycoplasma phocidae* (Ruhnke and Madoff 1992). A further two *Mycoplasma* species (*M. phocarhinis* and *M. phocacerebralis*) were isolated from harbour seals during the 1988 morbillivirus epizootic (Giebel et al. 1991). Their role as pathogens is unclear, although Giebel et al. (1991) propose that *Mycoplasma* spp. may have contributed to morbidity (Giebel et al. 1991). *Mycoplasma zalophi* was isolated from California sea lions in rehabilitation centres and was likely associated with pneumonia and polyarthritis (Haulena et al. 2006). *Mycoplasma zalophi*, *M. phocae* (prev *M. phocidae*) and an unnamed *Mycoplasma* sp. were isolated from the nasal cavities of 72% of healthy wild Australian fur seals (*Arctocephalus pusillus doriferus*) and based on pathological findings these may be associated with respiratory disease and abortions in this species (Lynch et al. 2011). No research on mycoplasmas has been performed in New Zealand pinnipeds but it is possible that these organisms are present here, given that they have been found in Australia.

Herpesviruses, influenza viruses and adenoviruses have been documented to cause disease and mortality in pinnipeds (Osterhaus et al. 1985; Gulland et al. 1997; KennedyStoskopf et al. 1986; Harder et al. 1996; Stenvers, Plotz, and Ludwig 1992; Geraci et al. 1982; Goldstein et al. 2011; Inoshima et al. 2013), however these viruses have not been reported or investigated in New Zealand marine mammals.

1.3 DISEASE ECOLOGY IN PINNIPEDS

1.3.1 Disease transmission in pinnipeds

Disease transmission in pinnipeds is facilitated by their life history. Many pinniped species have regular periods of close co-habitation, especially during breeding seasons, during which the introduction of a disease or toxin may affect large numbers of individuals (Harwood and Hall 1990). As there will always be contact between individuals during the breeding season, the probability of disease transmission may change very little if the overall population density declines (Harwood and Hall 1990). Marlow describes coughing, sneezing, reciprocal face rubbing, defaecating, urinating, parturition and vomiting behaviours occurring in the NZSL harems, where animals are aggregated in close proximity (Marlow 1975). The inevitable contact that occurs between individuals and these bodily fluids in a crowded harem facilitates the spread of pathogens. Other interactions that occur between individual sea lions such as aggressive interactions, mother-pup interactions and cannibalism (Wilkinson et al. 2000) result in contact with bodily fluids and therefore also allow disease transmission.

The Auckland Islands NZSL breeding colonies could be considered as one population in terms of pathogen exposure, as seen in the 1998 epizootic event occurring simultaneously at three Auckland Island sites (Dundas Island, Sandy Bay and South East Point) (Baker 1999). Adult male NZSLs move readily between the Auckland Island breeding colonies during the breeding season and have been shown to disperse throughout the known range of the species after the breeding season, therefore acting as potential disease vectors throughout the species' range (Geschke and Chilvers 2009; Robertson et al. 2006). Breeding colonies and aggregations outside of the breeding season should therefore be thought of as a single population when considering disease spread (Robertson et al. 2006). Disease studies performed at individual breeding colonies therefore could have applications to the population as a whole.

Other wildlife species have the potential to act as reservoirs of disease for NZSLs due to inter-species interactions described as follows. Scavenging and potentially active predation by NZSLs on New Zealand fur seal pups (Bradshaw, Lalas, and McConkey 1998) and predation on antarctic and subantarctic fur seal pups (*Arctocephalus gazella* and *A. tropicalis*) (Robinson, Wynen, and Goldsworthy 1999) has been documented. Individual southern elephant seals and leopard seals have been observed to haul out near NZSL aggregations on Enderby Island (Marlow 1975). There are reports of NZSLs preying on southern royal albatross (*Diomedea epomophora*) (Moore, Charteris, and Larsen 2008), gentoo penguins (*Pygoscelis papua*) (McMahon, Holley, and Robinson 1999) and yellow-eyed penguins (*Megadyptes antipodes*) (Lalas et al. 2007). The faeces, placentae and vomit of the NZSL are eaten by sea birds present at the harem beaches, particularly gulls (*Larus* spp.) and southern skua (*Catharacta lonnbergi*) (Marlow 1975). Skua and giant petrels (*Macronectes giganteus*) feed on sea lion carcasses (Marlow 1975). Gilmartin et al (1979) suggest that gulls and other birds may be partially responsible for the high prevalence of salmonellae in some pinniped populations, as they have been implicated as carriers of these pathogens (Gilmartin, Vainik, and Neill 1979), and avian species may act as disease reservoirs for other NZSL pathogens also.

In the early 1990's goats were eradicated from the Auckland Islands and rabbits, cattle and mice were eradicated from Enderby Island (Peat 2003), although pigs remain on some of the Auckland Islands. Historically the NZSL may have had contact with these domestic species and pathogens they may have carried.

1.3.2 Effects of disease on pinniped populations

Periodic mass mortality events may be important in the natural dynamics of marine mammal populations, and have major implications for the genetics and evolution of these populations (Harwood and Hall 1990). Investigating disease-related mortality is difficult in wild populations, and an additional difficulty in the investigation of mortality in marine mammals is that most die at sea and the bodies are never found to count or for post mortem examination (Harwood and Hall 1990). Presumably diseases that progress rapidly, affect many animals or affect animals that are land bound will be

easier to describe as more cases can be analysed, but it may still not be possible to describe the full effects on the population.

Our knowledge of the disease status of New Zealand marine mammals is rudimentary and this can make it difficult to interpret test results during investigations into disease events such as the 1997/98 breeding season NZSL epizootic event (Duignan 2000). Causes of mortality have been studied for the pups of the NZSL and research on adult mortality was performed as part of the response to recent epizootic events, but disease related data for adult NZSLs preceding and following the epizootic events is scarce and limited mostly to gross post mortem reports and archived tissue samples.

1.4 TUBERCULOSIS

Tuberculosis is an endemic disease that has been recognised through passive surveillance of NZSL post mortem examinations but has yet to be studied in detail in this host-pathogen system.

1.4.1 *The Mycobacterium tuberculosis complex*

Bacteria within the genus *Mycobacterium* are rod-shaped acid fast bacteria and several of these species can cause granulomatous lesions in animals and humans (Jones, Hunt, and King 1997). Within the genus *Mycobacterium* is the grouping called the *Mycobacterium tuberculosis* complex (MTC), which contains those species that cause the disease “tuberculosis” (Cousins et al. 2003). The MTC consists of *Mycobacterium tuberculosis*, *M. bovis*, *M. bovis* Bacille Calmette-Guérin (BCG), *M. africanum*, *M. microti*, *M. canetti*, *M. caprae* and *M. pinnipedii*, which are differentiated to the species level via a combination of host specificity, phenotypic properties and genotypic properties (Cousins et al. 2003). Species within the MTC generally cause disease within a natural host or range of hosts but can infect species outside this range, including domestic animals, wild animals and humans (Jones, Hunt, and King 1997; Cousins et al. 2003). For example, the causative agents of tuberculosis are predominantly *M. tuberculosis* in humans and non-human

primates, *M. bovis* in cattle (*Bos taurus*), *M. microti* in voles (Jones, Hunt, and King 1997) and *M. pinnipedii* in pinnipeds (Cousins et al. 2003).

Several other mycobacterial species are pathogens that cause diseases without the classical lesions of tuberculosis, including *M. avium* subspecies *paratuberculosis*, which causes Johne's disease in ruminants, *M. leprae*, which causes leprosy in humans and armadillos and *M. lepraemurium*, which causes rat and feline leprosy (Jones, Hunt, and King 1997). A further group of mycobacteria including *M. fortuitum*, *M. marinum* and *M. chelonae* are free-living saprophytes in soil or water which are occasional opportunistic pathogens in animals and humans, usually causing granulomatous infections of the skin (Jones, Hunt, and King 1997; Lewis 1987).

1.4.2 Pathophysiology of tuberculosis

The immune response produced by a host with mycobacterial infection is aimed at containing the slow growing intracellular bacterium (de Lisle et al. 2002). In the early stages of the disease, the cell-mediated immune response is the predominant immune response and in the advanced stages of the disease when there are large numbers of organisms present, high levels of antibodies can occur also (de Lisle et al. 2002). The host response to the pathogen results in the formation of the classical presentation of the disease, which is a tubercle consisting of epithelioid macrophages surrounded by a capsule of fibroblasts and interspersed lymphocytes, and often containing a necrotic and calcified centre (Jones, Hunt, and King 1997). Macrophages phagocytose the mycobacteria and bacterial glycolipids prevent the fusion of phagosomes with cellular lysosomes, so the organisms continue to multiply intracellularly (Jones, Hunt, and King 1997). When infected cells enter the lymphatic system, the organisms can be transported to lymph nodes and systemically, and if lesions erode into blood vessels then haematological spread may also occur (Jones, Hunt, and King 1997). Development of central necrosis, calcification, a fibrous capsule and growth and coalescence of lesions occurs especially as the tubercles increase in size and age (Jones, Hunt, and King 1997). Coalescence of epithelioid cells can result in the formation of multinucleated giant cells (Jones, Hunt, and King 1997). The mycobacterial organisms are acid fast with Ziehl-

Neelsen (ZN) staining and the number of acid-fast organisms (AFOs) visible within lesions at histology ranges from large numbers to very few or none (Jones, Hunt, and King 1997). Grossly the lesions are usually soft or hard nodules, white, grey or yellow in colour, with a caseous or necrotic centre apparent on cut surface (Jones, Hunt, and King 1997). Differences may occur in the gross and histological appearance of lesions depending on the species of animal infected and the species of the mycobacterial pathogen (de Lisle et al. 2002; Jones, Hunt, and King 1997). For example, the most common histological findings of *M. bovis* lesions in cattle are the classic tuberculosis lesions described above, whereas lesions in Eurasian badgers (*Meles meles*) and brushtail possums (*Trichosurus vulpecula*) infected with *M. bovis* rarely have mineralisation and have little or no encapsulating fibrosis so can grossly resemble pyogenic abscesses (Jones, Hunt, and King 1997; de Lisle et al. 2002).

The distribution of lesions depends on the route by which the animal was infected and whether further disease dissemination has occurred within the body (de Lisle et al. 2002). Infection of the lungs and thoracic cavity by mycobacterial organisms is believed to be the result of aerosol spread and inhalation of the organism, as occurs for example in the majority of bovids infected with *M. bovis* and humans and non-human primates infected with *M. tuberculosis* (de Lisle et al. 2002; Jones, Hunt, and King 1997; Kissane and Anderson 1985). Ingestion of organisms can result in infection of the tonsils and mesenteric lymph nodes, as is documented in humans ingesting unpasteurised milk from cows with *M. bovis* mastitis (Kissane and Anderson 1985). Where only the lymph nodes of the head and neck are affected, the route of infection is likely inhalation or ingestion, but it can be difficult to determine which (de Lisle et al. 2002). Infection of the kidneys in badgers (*Meles meles*) with *M. bovis* infection indicates the potential for spread via contaminated urine (de Lisle et al. 2002).

The clinical signs resulting from mycobacterial infections vary depending on the location, severity and nature of the lesions present. The slow growth of *M. tuberculosis* and *M. bovis* in vivo means that the course of active tuberculosis can take weeks to years, with animals and humans often remaining clinically normal for the majority of this period (de Lisle et al. 2002; Kissane and Anderson 1985). Mycobacterial infection of the

lungs in humans and animals typically causes pulmonary symptoms such as a cough, and potentially systemic effects such as fever, weight loss and fatigue (Kissane and Anderson 1985; de Lisle et al. 2002; Thompson et al. 1993; Cousins et al. 1993). The most common sign of *M. bovis* infection in any of the aforementioned hosts of this pathogen is weight loss (de Lisle et al. 2002). Infected superficial lymph nodes may be noticeably enlarged and in some species these may fistulate and drain (de Lisle et al. 2002). *Mycobacterium bovis* infection in brushtail possums can result in behavioural changes, including venturing onto farmland in daylight in a disoriented manner (de Lisle et al. 2002).

1.4.3 *Mycobacterium pinnipedii*

1.4.3.1 Taxonomy

Early investigations isolated mycobacteria from tuberculous lesions in a range of pinniped species and these isolates showed phenotypic and genotypic similarities to each other as well as to members of the MTC, suggesting the isolates were related and were possibly a separate species within the complex (Cousins et al. 1993; Cousins et al. 2003; Ahmed et al. 2003; Cousins et al. 1990; Bernardelli et al. 1996; Woods et al. 1995; Bastida et al. 1999). Cousins et al. (2003) tested 30 mycobacterial isolates from six pinniped species from Argentina, Australia, Great Britain, New Zealand and Uruguay, which showed that while the phenotypic characteristics of the isolates were consistent with *M. bovis*, DNA spoligotyping showed that they formed a unique cluster within the MTC (Cousins et al. 2003). Based on this and the apparent host specificity the isolates were classified as a new species, *Mycobacterium pinnipedii* (Cousins et al. 2003).

It was initially theorised that the source of mycobacterial disease in seals before it became endemic as *M. pinnipedii* may have been through contact between pinnipeds and humans or livestock (alive or dead) infected with mycobacterial disease (Cousins et al. 1993), however the current hypothesis is that a southern hemispheric pinniped species acquired a *M. pinnipedii* progenitor that was part of the MTC approximately 2500 years ago, from an unknown African host, and carried the disease throughout the southern

hemisphere including South America (Bos et al. 2014). There are no published cases of *M. pinnipedii* infection in marine mammals other than pinnipeds (Cousins 2008).

1.4.3.2 Distribution of *Mycobacterium pinnipedii*

Tuberculosis confirmed to be due to *M. pinnipedii* has been described in wild and captive pinnipeds around the world. According to the available literature, four species of fur seal and three species of sea lion have been shown to be infected (Cousins 2008).

Cases of *M. pinnipedii* infection and disease in wild pinnipeds have only been reported in the southern hemisphere, including in a New Zealand fur seal and two Australian sea lions in Western Australia (Cousins et al. 1993), an Australian fur seal (*Arctocephalus pusillus doriferus*) from Tasmania (Woods et al. 1995), an Australian fur seal from South Australia (Boardman et al. 2014), a subantarctic fur seal from Argentina (Bastida et al. 1999), a South American sea lion from Brazil (de Amorim et al. 2014) and a South American sea lion and five South American fur seals from the southwestern Atlantic coast (Bernardelli et al. 1996; Cousins et al. 2003). These studies show that tuberculosis caused by *M. pinnipedii* is likely endemic in several wild pinniped populations of the southern hemisphere

Vagrant subantarctic fur seals have been reported in the Indian, South Atlantic and South Pacific oceans, often associated with the wild breeding colonies of the Juan Fernández fur seal (*Arctocephalus philippii*), South American fur seal (*Arctocephalus australis*), antarctic fur seal (*Arctocephalus gazella*), Australian fur seal, New Zealand fur seal, South American sea lion (*Otaria flavescens*), Australian sea lion (*Neophoca cinerea*), NZSL and southern elephant seal (Bastida et al. 1999). *Mycobacterium pinnipedii* infection has been described in all but the Juan Fernández fur seal, antarctic fur seal and southern elephant seal, and the subantarctic fur seal may act as a possible physical link carrying this pathogen between the populations it associates with (Bastida et al. 1999).

Mycobacterium pinnipedii has also been documented in captive pinnipeds, in both wild caught and captive born animals (Jurczynski et al. 2012; Kiers et al. 2008; Kriz et al. 2011; Moser et al. 2008; Forshaw and Phelps 1991). *Mycobacterium pinnipedii* infection was diagnosed in a captive colony of New Zealand fur seals and Australian sea lions in

Western Australia (Forshaw and Phelps 1991; Cousins et al. 2003). A South American sea lion in a German zoo died from respiratory disease caused by *M. pinnipedii* (Moser et al. 2008) and subsequent testing confirmed a further 10 animals of the colony were infected (Jurczynski et al. 2012). Thirteen out of 29 captive South American sea lions at a zoo in the Netherlands (Kiers et al. 2008) and one out of four captive South American sea lions at a Czech zoo had tuberculosis caused by *M. pinnipedii* (Kriz et al. 2011). All of these colonies contained one or more individuals sourced from the wild (Moser et al. 2008; Forshaw and Phelps 1991; Jurczynski et al. 2012; Kiers et al. 2008; Kriz et al. 2011). Thorel et al. (1998) report a captive South American sea lion that died from tuberculosis and the organism isolated was classified as *M. bovis* using a test unable to differentiate between *M. bovis* and *M. pinnipedii*, so it is possible the latter was the cause in this case also (Thorel et al. 1998).

The geographic spread of this organism and the epidemiology in infected populations is not entirely understood therefore further research is required to better understand this pathogen, the disease it causes and the effect it has on populations (Cousins 2008).

1.4.3.3 Mycobacterial infection in New Zealand pinnipeds

Two cases of mycobacterial infection have been reported in wild New Zealand fur seals. One case was an adult male that was accidentally killed as fishery by-catch and showed focal granulomatous lymphadenitis of one axillary lymph node and no other abnormalities (Hunter et al. 1998). The second case was a juvenile male with granulomatous bronchopneumonia, pleuritis and pericarditis and a generalised lymphadenopathy (Hunter et al. 1998). Both cases had visible AFOs in affected tissues and cultured a mycobacterial organism from the MTC, which was not further described (Hunter et al. 1998). In a conference proceedings abstract, Roe et al. (2006) report a wild adult male NZSL from the Otago coastline with caseous granulomas in the lungs and the subcutaneous, thoracic and mesenteric lymph nodes, where granulomas had large numbers of intra-lesional AFOs (Roe et al. 2006). The causal organism was determined to be in the MTC by restriction enzyme analysis (Roe et al. 2006). These publications indicate that mycobacterial disease is present in at least two New Zealand pinniped

species. Further research is required to confirm the mycobacterial species involved and the pathogenesis and epidemiology of the disease.

1.4.3.4 Pathology of *Mycobacterium pinnipedii* infection in pinnipeds

Mycobacterium pinnipedii infection in fur seals and sea lions generally presents as gross and microscopic granulomatous lesions, predominantly seen in the lungs (Kriz et al. 2011; Forshaw and Phelps 1991; Woods et al. 1995; Bastida et al. 1999; Bernardelli et al. 1996; Jurczynski et al. 2012; Kiers et al. 2008; Boardman et al. 2014; de Amorim et al. 2014), pleura (Kriz et al. 2011; Forshaw and Phelps 1991; Woods et al. 1995; Bastida et al. 1999; Bernardelli et al. 1996; Boardman et al. 2014), thoracic lymph nodes (Forshaw and Phelps 1991; Woods et al. 1995; Bastida et al. 1999; Bernardelli et al. 1996; Jurczynski et al. 2012; Kiers et al. 2008; Boardman et al. 2014) and peripheral lymph nodes (Cousins 2008; Woods et al. 1995; Bernardelli et al. 1996; Jurczynski et al. 2012). Lymph node lesions may be accompanied by gross enlargement of the nodes.

Lesions have less frequently been described in the liver (Forshaw and Phelps 1991; Cousins 2008; Bernardelli et al. 1996; Kiers et al. 2008), hepatic lymph nodes (Cousins 2008; Bernardelli et al. 1996), peritoneum (Cousins 2008; Bernardelli et al. 1996), spleen (Bernardelli et al. 1996; Cousins 2008; Kiers et al. 2008; Woods et al. 1995) and mesenteric lymph nodes (Kiers et al. 2008; Kriz et al. 2011; Cousins 2008; de Amorim et al. 2014). Cases with disseminated disease have also been described, with granulomatous lesions affecting multiple sites including the spleen, liver, kidney and mesenteric lymph nodes (Cousins 2008; Forshaw and Phelps 1991; Kiers et al. 2008). Some studies describe marked thickening of the pleura (Forshaw and Phelps 1991; Woods et al. 1995; de Amorim et al. 2014; Boardman et al. 2014), ulcerative tracheitis and/or bronchitis (Jurczynski et al. 2012; Kiers et al. 2008) or pleural effusions (Cousins et al. 1993; Forshaw and Phelps 1991; Woods et al. 1995; Bastida et al. 1999; Bernardelli et al. 1996; Jurczynski et al. 2012; de Amorim et al. 2014). A single case of meningeal infection has been described (Forshaw and Phelps 1991).

Histological findings vary slightly between studies but the lesions associated with *M. pinnipedii* in pinnipeds can generally be described as granulomatous inflammation or

discrete granuloma formation, with granulomas consisting predominantly of epithelioid macrophages and often containing central areas of caseous necrosis (Cousins et al. 1993; Forshaw and Phelps 1991; Woods et al. 1995; Bastida et al. 1999; Bernardelli et al. 1996; Kiers et al. 2008; de Amorim et al. 2014; Boardman et al. 2014). There may be lymphocytes associated with the periphery of lesions (Cousins et al. 1993; Forshaw and Phelps 1991; Bastida et al. 1999; Bernardelli et al. 1996; de Amorim et al. 2014) and some cases also have associated neutrophils (pyogranulomatous inflammation) (Cousins et al. 1993; Woods et al. 1995; Jurczynski et al. 2012; Cousins 2008; Boardman et al. 2014). Mineralisation is seen in some lesions (Kriz et al. 2011; Bastida et al. 1999; Bernardelli et al. 1996; Jurczynski et al. 2012; Kiers et al. 2008; de Amorim et al. 2014). The presence of acid fast organisms in lesions is variable; some lesions show visible organisms ranging from a few to large numbers (Kriz et al. 2011; Forshaw and Phelps 1991; Woods et al. 1995; Bernardelli et al. 1996; Jurczynski et al. 2012; Kiers et al. 2008; de Amorim et al. 2014; Boardman et al. 2014), whereas AFOs are not visible in other lesions (Cousins 2008; Forshaw and Phelps 1991). Multinucleated giant cell formation is not described in any of the reviewed studies.

Given that the lungs are one of the most common sites for *M. pinnipedii* infection in pinnipeds, inhalation of aerosols is considered a primary route of disease transmission, similar to other species in the MTC (Cousins 2008; Cousins et al. 1993). Infection of the mesenteric lymph nodes and liver in some cases indicate that an alimentary route of infection is also possible, either primarily by ingestion of infectious material or secondarily, where an individual swallows infected sputum coughed up from its primary lung disease (Cousins 2008; Kriz et al. 2011).

Infections with atypical mycobacteria are also recorded in pinnipeds, although less commonly, and some of these cases present with lesions similar to those in MTC-associated disease. *Mycobacterium smegmatis* was isolated from a California sea lion which showed granulomatous dermatitis, cellulitis, myositis and peritonitis, with no lung lesions (Gutter, Wells, and Spraker 1987). *Mycobacterium fortuitum* was cultured from a captive South American sea lion in a zoo in the United Arab Emirates from multiple raised skin nodules consisting of a mixed inflammatory cell infiltrate and no

visible AFOs, and was believed to have been an opportunistic infection (Lewis 1987). *Mycobacterium fortuitum* was also the causative agent of disease in a harbour seal which had pyogranulomatous dermatitis, lymphadenitis and pneumonia (Wells, Gutter, and Vanmeter 1990). *Mycobacterium bovis* was documented to cause systemic infection and widespread granulomatous inflammation in a grey seal pup following infection of a wound with this pathogen (Barnett et al. 2013).

1.4.3.5 Diagnosis of *Mycobacterium pinnipedii* infection in pinnipeds

The clinical signs, gross findings and histological appearance of mycobacterial lesions can be strongly suggestive of mycobacterial infection but further testing is required to diagnose this definitively. The most common clinical signs in pinnipeds with advanced tuberculosis are the non-specific signs of anorexia and weight loss (Forshaw and Phelps 1991; de Amorim et al. 2014). Clinical signs rarely include a cough, even in cases with thoracic disease (Forshaw and Phelps 1991; Jurczynski et al. 2012). Some animals have been reported to show dyspnoea in the later stages of disease (Woods et al. 1995; Bastida et al. 1999; Bernardelli et al. 1996; Jurczynski et al. 2012). This is similar to *M. bovis* infections in the natural, maintenance and spillover hosts for this pathogen, where infections are largely asymptomatic and those showing clinical signs will often be in the later stages of the disease (de Lisle et al. 2002).

The gold standard for the diagnosis of tuberculosis is culture (de Lisle et al. 2002) of tissue samples or swabs. The disadvantage of mycobacterial culture is that it requires specialised facilities and methods to perform and that it can take 6 to 8 weeks or longer to isolate a mycobacterial organism, due to their slow growth (de Lisle et al. 2002). Mycobacteria have been recovered by culture from lesions in the liver, mesenteric lymph nodes, lung and thoracic lymph nodes of pinniped species (Cousins 2008).

To increase the sensitivity of necropsy and histology for detecting small mycobacterial lesions, whole lungs and lymph nodes may be preserved in formalin and then cut into thin serial sections (ie 3mm thick) to then be examined for lesions (Forshaw and Phelps 1991). Out of 16 pinnipeds undergoing a post mortem examination due to a high

suspicion of tuberculosis, nine showed signs consistent with tuberculosis but two of these cases had lung lesions seen only by this method (Forshaw and Phelps 1991).

Polymerase chain reaction (PCR) protocols and other DNA amplification techniques allow the differentiation of species within the MTC, including *M. pinnipedii* (Huard et al. 2006; Warren et al. 2006). The advantages of DNA amplification techniques are their sensitivity and their rapid turnover times compared to mycobacterial culture (Warren et al. 2006; Wards, Collins, and de Lisle 1995). Warren et al (2006) describe a multiplex PCR method using six markers (RD1, RD1^{mic}, RD2^{seal}, RD4, RD9 and RD12) allowing differentiation of the members of the MTC, including *M. pinnipedii* (Warren et al. 2006).

Differentiation of members of the MTC can also be done by spacer oligotyping ("spoligotyping") on *in vitro* amplified DNA, a technique which utilises polymorphisms of the arrangement of spacer sequences at the chromosomal DR locus (Kamerbeek et al. 1997). Spacer sequences are highly variable, and can be used both to differentiate between MTC species and to distinguish strains within a species (Kamerbeek et al. 1997). Spoligotyping can be performed on tissue samples without prior mycobacterial culture or DNA purification and has been used on 40-year-old paraffin-embedded formalin-fixed tissue (Kamerbeek et al. 1997). Spoligotyping has been used in cases of tuberculosis in pinnipeds to determine *M. pinnipedii* as the causative agent (Jurczynski, Lyashchenko et al. 2011; Cousins et al. 2003).

Antemortem testing for tuberculosis in pinnipeds is mainly documented for captive pinnipeds, largely due to the difficulties involved with animal capture, immobilisation and sample collection in pinniped species as well as the cost of testing. As with antemortem testing for other mycobacterial species in a wide range of hosts, the accuracy of diagnostic tests is limited by low sensitivity and specificity (de Lisle et al. 2002). Given the focus of this thesis is based on post mortem studies, the antemortem tests will not be further considered here. Due to the difficulties associated with diagnosing infection via antemortem testing, preliminary investigations describing pathological findings and mycobacterial culture of further cases of tuberculosis in the NZSL are recommended, with speciation of any mycobacterial isolates.

1.4.3.6 Zoonotic implications

Mycobacterium pinnipedii infection in pinnipeds is a documented zoonotic risk, and transmission between captive pinnipeds and zoological staff has resulted in a case of severe pulmonary disease (Thompson et al. 1993; Cousins et al. 2003) and several asymptomatic infections (Kiers et al. 2008).

It is strongly recommended that individuals working with wild and captive pinnipeds or their tissues are aware of this disease and take precautions to avoid exposure. Aerosols appear to be the most common route of spread of the disease to humans and therefore high-pressure steam cleaning of enclosures is a risk factor (Kiers et al. 2008), however the organism is also present in infected tissues and most likely in bodily fluids.

1.4.3.7 Implications for other species

Mycobacterium pinnipedii infection in pinnipeds has the potential to spread to and affect other animal species in captive settings, and transmission of the organism between wild species has been hypothesised but not documented (Jurczynski, Lyashchenko et al. 2011; Moser et al. 2008; Cousins 2008; Cousins et al. 2003). It is currently unknown whether non-pinniped species infected by *M. pinnipedii* are part of the normal host range or if they are maintenance hosts or spillover hosts (Cousins 2008), although transfer among Malayan tapirs (*Tapirus indicus*) and among Bactrian camels (*Camelus bactrianus bactrianus*) is believed to have occurred (Jurczynski, Lyashchenko et al. 2011; Moser et al. 2008). A case of *M. bovis* infection is reported to have caused disease in three leopards (*Panthera uncia* and *Panthera pardus*) and one South American sea lion at a zoo in the early 1990's (Thorel et al. 1998). The paper pre-dates studies describing how to distinguish *M. pinnipedii* from other members of the MTC and later papers reference this study as having been *M. pinnipedii* infection (Kriz et al. 2011; Jurczynski, Lyashchenko et al. 2011).

Rare cases of *M. pinnipedii* infection have been reported in domestic cattle in New Zealand (Cousins et al. 2003; Loeffler et al. 2014) indicating that there is potential for this organism to cause disease in cattle and other domestic animals. Seven cases of *M. pinnipedii* infection in cattle have been detected through testing performed as part of New Zealand's bovine tuberculosis control program for *M. bovis*, and New Zealand fur

seals were thought to be the most likely source of infection (Loeffler et al. 2014). Each of these cases were determined to have tuberculosis via skin testing or at slaughter and meat inspection and showed single lymph node lesions only, with histological appearance similar to that caused by *M. bovis* however when cultured and speciated using VNTR/DR testing, *M. pinnipedii* was confirmed (Loeffler et al. 2014). These cases indicate that when relying on skin testing, meat inspection and culture alone to diagnose *M. bovis* infection in cattle, rare and isolated occurrences of *M. pinnipedii* infection may be misdiagnosed as *M. bovis*. This may interfere with New Zealand's *M. bovis* eradication scheme, which is a potential problem for farmers and the eradication scheme. All affected farms had grazing areas with either direct access to the ocean or indirect access via creeks etc and a significantly higher number of affected farms had sighted NZ fur seals on their properties compared to neighbouring non-affected farms (Loeffler et al. 2014). The behaviour of *M. pinnipedii* infection in cattle is largely unknown and Loeffler et al (2014) described single cases only, indicating that no cattle to cattle spread had occurred in the affected herds (Loeffler et al. 2014). Disease transmission between non-pinnipeds has been reported for *M. pinnipedii* (Jurczynski, Lyashchenko et al. 2011; Moser et al. 2008), indicating that transmission between cattle may be possible. Further research is required to determine what risk the presence of mycobacterial disease in New Zealand marine mammals poses to livestock.

The Enderby Island NZSLs are a geographically isolated population with limited exposure to humans, livestock and terrestrial mammals. However the recent establishment of satellite colonies of NZSLs on Stewart Island/Rakiura and the South Island of New Zealand increase opportunities for such contact. Understanding the importance of mycobacteriosis in the main NZSL colony on Enderby Island may aid us in predicting the likely impacts of overlap between NZSLs, humans and domestic animals.

1.5 RESEARCH AIMS

This study aims to:

- Determine the causes of death in individual non-pup NZSLs and thus begin investigations to determine which pathogens are present in the population as well as the importance of other causes of mortality.
- Investigate and describe mycobacterial infection in deceased NZSLs, including speciation of mycobacterial isolates cultured.

This study will utilise post mortem reports and archived tissues from post mortems performed on non-pup NZSLs at Enderby Island to characterise the causes of mortality in this species. Analysis of archived tissues to determine what the natural causes of mortality are would be very valuable in furthering the knowledge of this species, including the knowledge of any pathogens that may cause mortality or reduce reproductive success and therefore have implications for population dynamics. This knowledge could then be used for response planning for potential future epizootic events and for management of this threatened species.

POST MORTEM FINDINGS IN NON-PUP NEW ZEALAND SEA LIONS (*PHOCARCTOS* *HOOKERI*) AT ENDERBY ISLAND

2.1 INTRODUCTION

The New Zealand sea lion (*Phocarcctos hookeri*) (NZSL) is endemic to New Zealand and is classified as “endangered” by the IUCN (IUCN 2016) and “Nationally Critical due to a decline in abundance” by the New Zealand Threat Classification system (Baker et al. 2010; Townsend et al. 2008). The population size was estimated at 10,500-13,100 for the 1994/95 breeding season (Gales and Fletcher 1999), but there has been a significant population decline in the last decade, with the most recent published estimate being 9,880 individuals (Geschke and Chilvers 2009). Some studies estimate that there are currently <3,000 mature individuals (Baker et al. 2010). The exact causes of the population decline are not yet well understood but it is likely that multiple factors play a role. Disease epizootics and interactions with fisheries have been discussed as probable significant contributors to the decline (Robertson and Chilvers 2011; Chilvers 2008; Baker et al. 2010). Factors such as dispersal, migration, predation, environmental change,

genetic effects and the effects of environmental contaminants have also been discussed but are considered less likely (Robertson and Chilvers 2011).

Causes of mortality have been investigated in NZSL pups at the Sandy Bay, Enderby Island breeding colony during the breeding seasons from 1998/99 to 2004/05 (Castinel, Duignan et al. 2007) but similar investigations are lacking for all other age groups and locations.

Infectious disease epizootic events have caused increased mortality at the Sandy Bay NZSL breeding colony in three past breeding seasons (see Chapter 1), but the role of infectious agents in non-pup deaths at this location is not currently understood. An epizootic event in the 1997/98 breeding season caused the death of 74 adult sea lions at Sandy Bay, and presented as neck abscesses with septicaemia and vasculitis. An unidentified gram negative organism that was difficult to culture was believed to be the cause (Baker 1999). Subsequent epizootics in 2001/02 and 2002/03 have been caused by a hypermucoviscous strain of *Klebsiella pneumoniae* and only pups were known to be clinically affected in the Auckland Islands (Castinel, Duignan et al. 2007; Castinel, Grinberg et al. 2007; Duignan, Wilkinson, and Alley 2003; Roe et al. 2015). One adult male on the mainland was also found to have died from *K. pneumoniae* infection in 2002 (Robertson et al. 2006).

Conspecific aggression resulting in injury and death has been reported between adult individuals in a range of pinniped species including the NZSL, and is predominantly due to breeding related aggression of adult males towards adult females (Tierney 1977; Le Boeuf and Mesnick 1991; Mesnick and Le Boeuf 1991; Galimberti, Boitani, and Marzetti 2000, 2000; Carrick and Ingham 1962; Hiruki, Gilmartin et al. 1993; Atkinson et al. 1994; Campagna and Le Boeuf 1988; Chilvers, Robertson et al. 2005).

Given the ongoing population decline of this endangered species and the fact that bacterial disease epizootics could be contributing to this decline, this chapter aims to investigate the causes of mortality and the role of bacterial disease in non-pup NZSLs at Enderby Island during the breeding seasons between 1998 and 2011.

2.2 MATERIALS AND METHODS

Expeditions to the NZSL breeding colonies on Enderby Island in the Auckland Islands have been undertaken annually during the NZSL breeding season (early December to late February) to collect biological data on this species. As a component of the research performed on these expeditions, post mortem examinations were performed on NZSLs that were found dead. This study includes data from post mortem examinations of 70 non-pup individuals examined during the field seasons from 1998/99 to 2010/11 inclusive. The term “non-pup” indicates any individual that was not born in that breeding season, and therefore includes animals of one-year-old and older. Post mortem examinations were performed by a veterinarian or by a trained and experienced sea lion biologist. The author conducted post mortem examinations for six weeks of the 2009/10 breeding season.

For each post mortem examination, a gross post mortem report was written. The author reviewed the archived post mortem reports and formulated a list of gross diagnoses and a preliminary primary cause of death from these.

In 60 cases, selected tissue samples from a range of internal organs were preserved in 10% neutral buffered formalin for histology and stored until the time of this study. Formalin-fixed tissues were embedded in paraffin and routinely processed for histology. Sections were cut at 4 μ m, mounted on slides and stained with haematoxylin and eosin (H&E). The author reviewed the slides using a light microscope and lesions were identified and described. Where required to characterise lesions further, additional stains were used, including Gram, Ziehl-Neelsen, Warthin-Starry silver, Giemsa, Perl’s iron, Young’s fungal, Congo red, Masson’s trichrome, PAS, Von Kossa and Verhoeff’s stains.

Aerobic bacterial cultures and/or mycobacterial cultures were performed on tissues from 30 cases, to describe further an infectious aetiology as suggested by the gross or

histological findings. Bacteriology samples were stored in liquid nitrogen during the expeditions and then stored at -80°C until the time of this study. Aerobic bacterial cultures from all years were performed at the New Zealand Veterinary Pathology laboratory, Palmerston North, New Zealand, except for the samples from the 2008/09 field season, which were performed by a microbiologist at Massey University, Palmerston North, New Zealand. Tissue samples or culture swabs were inoculated onto Columbia sheep blood agar, MacConkey agar and Columbia CNA sheep blood agar and incubated for 48 hours at 37°C. Sheep blood agar plates were incubated in 10% CO₂ and MacConkey plates in O₂. Cultures were identified to species level based on colony morphology where possible. Suspected *Nocardia* sp. were cultured on Sabouraud Dextrose agar in O₂. Cases where *Leptospira* sp. were suspected were cultured in Ellinghausen-McCullough-Johnson-Harris (EMJH) medium at 28°C for up to 12 weeks.

Mycobacterial infection was a differential diagnosis for granulomatous lesions in any tissue. For cases where this was described, Ziehl-Neelsen (ZN) staining of formalin fixed tissue was performed to examine for acid fast organisms (AFOs). Where fresh-frozen tissues were available, mycobacterial cultures were performed at the AgResearch laboratory in Wallaceville, Upper Hutt, New Zealand. The tissues for mycobacterial culture were homogenised in phosphate buffer, decontaminated with NaOH, then neutralised in phosphate buffered saline. Samples were then centrifuged and the spun deposit reconstituted in phosphate buffer. This was used to inoculate a vial containing liquid 7H9 and antibiotics (PANTA, BD), and a solid slope of 7H11 medium supplemented with pyruvate. The media were incubated at 37°C for 30 days for the liquid 7H9 and 90 days for the solid 7H11pyruvate. The liquid media were examined for AFOs while the solid media were examined for bacterial colonies. DNA was extracted from the mycobacterial colonies and a multiplex PCR was performed to differentiate between *Mycobacterium pinnipedii* and the other members of the *Mycobacterium tuberculosis* complex (MTC) as described by Warren et al 2006 (Warren et al. 2006).

Using the gross pathology descriptions, the histological findings and the ancillary test results, a cause of death (COD) was determined for each animal. Cases were grouped into four categories defined as follows: infectious conditions (fatal bacterial and/or

parasitic disease); conspecific trauma (fatal traumatic injuries as a result of conspecific aggression); predation (fatal traumatic injuries inflicted by a predator); and unknown (no primary COD diagnosed). Animals that had both infectious disease and traumatic lesions were categorised by the ultimate COD. For example, individuals with severe secondary infections of traumatic wounds were classified as infectious disease deaths. Cases which sustained fatal traumatic injuries but where there was a degree of underlying disease were categorised as trauma (predation or conspecific trauma). Two animals that were euthanased due to being found in a severely debilitated condition were categorised according to the nature of the disease process that caused the debilitation.

A linear regression analysis was performed to examine the relationship between the length of time that the researchers were in the field for each season and the number of non-pup NZSLs found dead in each season, and also the relationship between tag re-sight data (an estimate of the size of the breeding population for the season) and the number of animals found dead for that season. The tag re-sight data is publicly available data made available under a Creative Commons License (Department of Conservation 2015). A Chi-square test was performed using online software (Preacher 2001) to determine if the sex ratio of cases that died from conspecific trauma was significantly different to the sex ratio of the remainder of the cases and to the sex ratio of adult NZSLs present on the island as predicted from Marlow (1975) (Marlow 1975).

2.3 RESULTS

2.3.1 General comments

Included in this study are 70 cases which had post mortem examinations performed and gross post mortem reports written. Sixty cases had samples collected and processed for histological examination and 30 had bacterial cultures performed.

The gross post mortem reports showed variation between prosectors in terms of the detail with which lesions were described. The post mortem and sampling protocols showed minor variations between field seasons, resulting in differences in the number and type of samples that were taken for each case.

Of the sixty cases that had samples taken for histology, 23 had incomplete tissue sets due to: scavenging by southern skuas (*Catharacta lonnbergi*) and/or giant petrels (*Macronectes giganteus*) (n = 12), shark predation (n = 1), field restraints such as rising tide, time limitations or large size of the animal (n = 3), or where a limited range of samples was electively preserved at post mortem examination (n = 8). In one case, samples for histology were reported to have been taken but these samples were not able to be located in the archives. Two cases had two of the above factors affecting the tissue set. Similarly, with the bacteriology samples; of the cases where infectious disease was detected on gross or histological examination, two cases did not have tissue samples collected for some of the lesions detected, and six cases had reported taking bacteriology samples but these were not able to be located in the archives. Significant autolysis of tissue samples was apparent on histological examination in four cases. Of the seven adult males examined, in three cases the large size of the animal contributed to an “unknown” classification being given, due to the difficulty of performing a full post mortem on an animal of that size in the available field conditions. In total, 31 cases (44.3%) had their dataset limited by one or more of: limited histology samples, limited bacteriology samples or significant autolysis. Fifteen out of the 19 cases with an “unknown” diagnosis fell into this category, indicating that the limited dataset may have contributed to a diagnosis not being able to be made in these cases. Four of the 19 cases with an “unknown” diagnosis did not have a limited dataset. Overall, tissue preservation and sample availability enabled an adequate diagnostic investigation to be conducted in 55/70 cases (78.6%). The remainder of the cases have been left in this study to maintain an accurate sex ratio of the deceased animals, and to utilise some of the additional data from these cases around concurrent and incidental diseases such as mastitis, metritis, non-fatal predation injuries, parasitism and bacterial culture results.

Figure 2.1 shows the number of animals that had a post mortem examination performed in each breeding season during the study period, and the distribution of these 70 cases into the categories of COD within each breeding season. There was no significant relationship ($R^2 = 0.003$, $df = 1,11$, $F = 0.039$, $p = 0.874$) between the number of non-pup NZSL deaths recorded in a breeding season and the number of days that observers were present on the island. There was also no significant relationship ($R^2 = 0.028$, $df = 1,11$, $F = 0.327$, $p = 0.579$) between the number of NZSLs present on the island in any given year (as estimated from tag re-sight data), and the number of non-pup NZSL deaths recorded, suggesting that deaths are not density dependent (Figure 2.2).

The 70 cases consisted of five yearling females, 43 adult females, eight yearling males, seven subadult males and seven adult males. The ratio of males to females examined in this study is 1:2.18 (22:48) (Table 2.1).

The gross post mortem and histological findings for each case are included in Appendix 1. The sections below describe major findings and diagnoses, including causes of death and concurrent infectious or traumatic processes.

Figure 2.1: Causes of mortality of non-pup NZSLs at Enderby Island for the breeding seasons 1998/99 to 2010/11 inclusive.

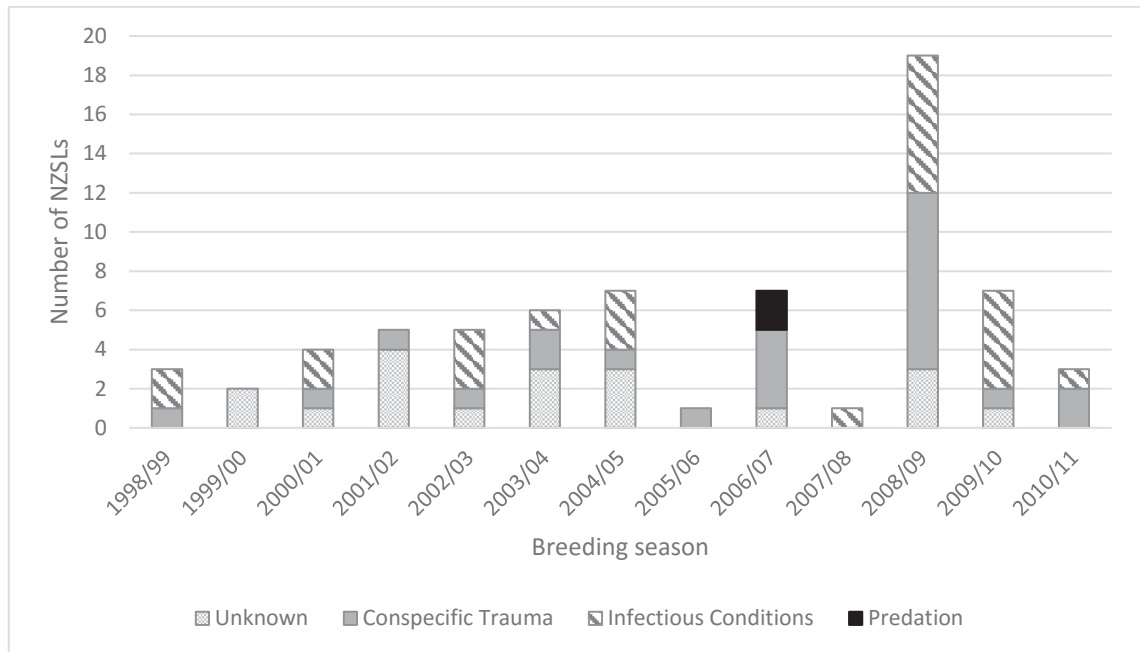


Figure 2.2: Number of tag resights and number of dead NZSLs that had post mortem examinations performed at Enderby Island for the breeding seasons 1998/99 to 2010/11 inclusive.

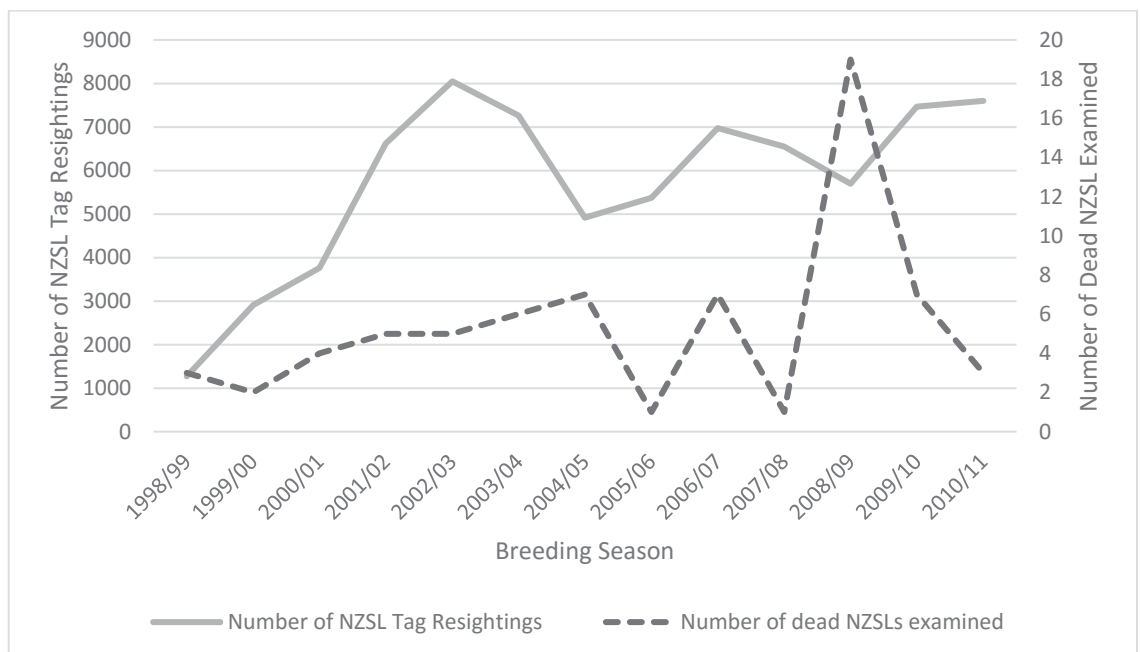


Table 2.1: Causes of mortality in NZSLs at Enderby Island, showing the frequency of causes of mortality by cohort

| Year | Infectious (M:F) | Conspecific Trauma (M:F) | Predation (M:F) | Unknown (M:F) | Total (M:F) |
|---------|---------------------|--------------------------------|--------------------|------------------|----------------|
| 1998/99 | (0:2) | (0:1) | (0:0) | (0:0) | (0:3) |
| 1999/00 | (0:0) | (0:0) | (0:0) | (1:1) | (1:1) |
| 2000/01 | (1:1) | (0:1) | (0:0) | (0:1) | (1:3) |
| 2001/02 | (0:0) | (0:1) | (0:0) | (1:3) | (1:4) |
| 2002/03 | (2:1) | (0:1) | (0:0) | (1:0) | (3:2) |
| 2003/04 | (0:1) | (0:2) | (0:0) | (1:2) | (1:5) |
| 2004/05 | (0:3) | (1:0) | (0:0) | (2:1) | (3:4) |
| 2005/06 | (0:0) | (0:1) | (0:0) | (0:0) | (0:1) |
| 2006/07 | (0:0) | (0:4) | (2:0) | (0:1) | (2:5) |
| 2007/08 | (0:1) | (0:0) | (0:0) | (0:0) | (0:1) |
| 2008/09 | (1:6) | (4:5) | (0:0) | (2:1) | (7:12) |
| 2009/10 | (1:4) | (0:1) | (0:0) | (1:0) | (2:5) |
| 2010/11 | (0:1) | (1:1) | (0:0) | (0:0) | (1:2) |
| Totals: | (5:20) | (6:18) | (2:0) | (9:10) | (22:48) |

2.3.2 Causes of mortality

2.3.2.1 Bacterial and parasitic infections (n = 25)

Bacterial and parasitic infections were the primary COD in 25 cases (35.7%). The following sections describe the most commonly diagnosed syndromes where infectious disease was the COD. Bacterial culture results are summarised in Table 2.2.

Visceral and systemic infections (n=16)

Eleven animals had bacterial pneumonia, four due to *Mycobacterium* spp. and seven due to other bacteria. Four of the non-mycobacterial cases had suppurative embolic pneumonia with concurrent suppurative subcutaneous lesions (abscesses, cellulitis and/or myositis)(E98/99-01Ph, E02/03-103Ph, E08/09-33Ph, E09/10-08Ph). In all four cases the same bacteria were cultured from the subcutaneous tissue and the lung, suggesting embolic spread from a primary subcutaneous site of infection. One case (E02/03-103Ph) grew a beta-haemolytic *Streptococcus* species as a moderate and heavy growth from the lung and abscess respectively, with an additional scant growth of *E. coli* grown from the lung and a scant mixed growth from the muscle. The other three cases grew mixed bacteria, suggestive of contamination, including a growth of *S. constellatus* from the lungs but not the abscess in one case (E08/09-33Ph). Three further cases of bacterial pneumonia did not have concurrent subcutaneous tissue infection. In two of these cases the pattern of lesions suggested a blood-borne source of infection: one (E98/99-03Ph) had granulomatous interstitial pneumonia with mild pleuritis and no bacterial or mycobacterial isolates grown from the lungs, and one (E04/05-37Ph) had pyothorax, pericarditis and multifocal pulmonary abscessation but no samples were collected for histology or bacteriology. One case (E08/09-19Ph) had severe suppurative bronchopneumonia and multifocal suppurative bacterial hepatitis due to *Streptococcus constellatus*.

As mentioned above, in four cases the COD was severe chronic granulomatous bronchopneumonia as a result of mycobacterial infection (E00/01-42Ph, E08/09-24Ph, E08/09-53Ph, E10/11-12Ph). In two of these cases *Mycobacterium pinnipedii* was confirmed as the causative agent using culture and PCR. In the remaining two, mycobacterial

infection was confirmed by the presence of acid fast organisms within the lesions, but culture was unsuccessful.

In addition to the four cases of severe chronic bronchopneumonia caused by mycobacterial infection described above, mycobacterial infection was diagnosed as the COD in an additional two individuals (E09/10-10Ph, E09/10-17Ph). One of these cases had a severe chronic granulomatous pleuritis and pericarditis and the other had a severe chronic granulomatous hepatitis resulting in jaundice. Both of these cases had *Mycobacterium pinnipedii* confirmed as the causative agent via PCR. The range of lesions seen in these cases and the implications of mycobacterial infection for the NZSL population will be discussed further in Chapter 3.

Two adult females were diagnosed with suppurative pyelonephritis, and the COD in these cases was likely either renal failure or septicaemia as a result. One (E07/08-46Ph) had moderate acute bacterial pyelonephritis with a focus of secondary perinephric abscessation. This case grew a heavy growth of an alpha-haemolytic *Streptococcus* and a light growth of *E. coli* from the kidney, and had no growth on specific culture for *Leptospira* spp. No bladder was available for histology. Warthin-Starry staining was not performed due to the lesions not being typical of *Leptospira* infections in pinnipeds. The second case (E08/09-25Ph) had severe acute suppurative pyelonephritis and bacterial cystitis. Two strains of *E. coli* were cultured from the kidneys and a gram-positive rod from the bladder. A *Leptospira* specific culture was not performed, however a Warthin-Starry stain of the kidney was negative.

One adult female (E04/05-09Ph) had a large abscess dorsal and cranial to the point of the left shoulder and a smaller abscess in the mandibular region. There was an acute severe haemorrhagic suppurative bacterial tonsillitis and congestion of multiple head and neck lymph nodes. The submandibular node grew a light growth of a non-haemolytic *Streptococcus* sp. and a beta-haemolytic *Streptococcus* sp.

Wound infections (n=5)

In five cases the COD was secondary infection of injuries sustained from conspecific aggression or predation events.

One yearling male (E02/03-94Ph) and two yearling females (E04/05-03Ph, E03/04-13Ph) had multiple deep puncture wounds around the head and neck consistent with punctures caused by the canines of adult NZSLs. Severe oedema, cellulitis, abscessation and haemorrhage was associated with the wounds, penetrating deep into the subcutis and muscle layers. In one case (E04/05-03Ph) a beta-haemolytic *Streptococcus* sp. was cultured from an abscess in the throat area and an abscess in the inguinal area. There were no tissues available for bacterial culture from the other two cases.

One adult female (E09/10-13Ph) had a full-thickness tear in the wall of the dorsal rectum, starting within the pelvic canal and extending cranially into the abdomen. A section of the jejunum was herniated through the tear. There was a resulting severe peritonitis as well as severe subacute necrotising pneumonia (aspiration pneumonia). Liver, lung and tracheobronchial lymph node each grew a light mixed growth of organisms, including *Proteus mirabilis* and an *Enterococcus* sp. The liver also grew a light growth of *E. coli* and the lung a light growth of an alpha-haemolytic *Streptococcus* sp.

A subadult male (E00/01-53Ph) had a large healing shark bite wound around the prepuce, with balanoposthitis and severe suppurative cellulitis. There was a severe cystitis and urethritis, presumably an ascending infection from the cellulitis, resulting in urethral stenosis and obstruction. There was bilateral ureteral dilation on gross examination and severe subacute ascending pyelonephritis histologically. Death was assumed to be the result of azotaemia and septicaemia. Bacterial culture was not performed.

Concurrent parasitism and bacterial infection (n=4)

There were four cases where more than one infectious disease process was present, which when combined resulted in severe debilitation, emaciation and death, even though each disease process individually would not have killed the animal and no disease process appeared to be the primary COD. In all these cases, parasitism was a

significant factor. These combinations included: cutaneous myiasis (fly larvae infestation) of a shark bite wound in combination with a high gastrointestinal parasite burden in a subadult male (E02/03-01Ph); metritis, with a high gastrointestinal parasite burden and a high lung worm burden in an adult female (E08/09-10Ph); an enteritis suspected to be of bacterial origin combined with a high gastrointestinal parasite burden in an adult female (E08/09-26Ph); and a moderate parasitic bronchopneumonia due to lung worm combined with a mild endometritis in an adult female (E09/10-21Ph).

2.3.2.2 Conspecific trauma (n=24)

Twenty-four cases (34.3%) had traumatic injuries determined to be the COD, which were most likely the result of conspecific aggression. Of the NZSLs that died from fatal conspecific trauma, the ratio of males to females is 6:18 (Table 2.1), which is not significantly different ($\chi^2= 0.7$, $df = 1$, $p=0.403$) to the male to female ratio for all other investigated deaths (16:30) (total 22:48). It is also not significantly different ($\chi^2= 0.403$, $df = 1$, $p=0.526$) from the ratio of adult NZSLs expected on the island during the breeding season (Marlow 1975). Of the six males that died from conspecific trauma, four were yearling males and two were subadult males, and of the females 16 were adult females and two were yearling females.

Three females were observed by researchers to have been mated in shallow water by adult males prior to their death. One female was observed to drown during the event, and the other two were in a very debilitated state and were strongly suspected to have drowned. In all three cases, there were no significant changes associated with drowning seen on gross or histological examination.

In an additional two cases the aggression that caused the trauma and death was witnessed by field workers. One case (E06/07-19Ph) was an adult female who sustained a penetrating wound to the vestibule and herniation of the small intestines through the wound as a result of mating attempts from an adult male. The other case (E08/09-12Ph) was a yearling male which sustained bites, severe extensive bruising to all aspects of the head and neck, and haemorrhage over the surface of the brain as a result of mating by an adult male.

There were 22 cases in total in this study where a male NZSL was found guarding the carcass. Of these, in 13 cases conspecific trauma was determined to be the COD. This indicates that male NZSLs may guard sea lions that they discover dead, and that the presence of a guarding male does not imply that the attending male caused that death.

Lesions seen in cases where the COD was conspecific trauma include moderate to severe bite wounds (n = 9) mostly around the head, neck and shoulders, and also to a hind flipper (E01/02-01Ph), pectoral flippers (E00/01-16Ph) and ventral thorax (E08/09-09Ph). Cases showed moderate to severe bruising of the trachea (n = 3), head (n = 10), neck (n = 12) and body (n = 10). One case had a haemoabdomen (E08/09-15Ph), and another had 2-3L of frank haemorrhage into the allantoic space of a full-term pregnancy (E08/09-07Ph). Fractures were documented of the spine (n = 1), ribs (n = 1) and skull (n = 3), and each of the three cases of skull fractures had concurrent laceration of the brain. One case with an intact skull but with extensive subcutaneous bruising over the head and neck reported haemorrhage on examination of the surface of the brain (E08/09-12Ph). Torn muscles were reported around the head (n = 2), neck (n = 1) and shoulder (n = 1).

Five animals had sand in their airways at post mortem examination, likely due to either aspiration of sand during prolonged mating events, or passive movement of sand and water through an open glottis after death. Cases with sand in the airways were considered likely to be associated with conspecific aggression if there were concurrent signs of trauma on post mortem examination (n = 4).

Penetrating wounds of the perineum, vestibule or rectum with or without herniation of the gastrointestinal tract and/or reproductive tract were observed in 11 cases. Scavenging by birds peri-mortem or post-mortem, or mating related injuries were considered to be the most likely causes for these changes. In six of these cases conspecific trauma was assessed to be the cause of the injuries, based on concurrent gross lesions present. These gross lesions included the presence of haemorrhage and bruising at the site of the injuries indicating ante-mortem injury, concurrent significant traumatic lesions elsewhere on the body suggestive of mating attempts (subcutaneous bruising over the pelvis, shoulders and head, moderate to severe bruising of the internal pelvic

canal (n = 2), aspiration pneumonia or sand inhalation into the nasal cavities and bronchi) and/or the presence of a male aggressively guarding the body.

Nine animals that died from traumatic injuries due to conspecific aggression had a concurrent bacterial infection or parasite burden detected. These concurrent diseases were not severe enough to kill the animals. Details are included in Appendix 1.

2.3.2.3 Predation (n=2)

Predation was the COD for two cases (2.9%) and predisposed to the death of two others (see sections on wound infections and concurrent parasitism and bacterial infection, in section 2.3.2.1). Researchers in the 2006/07 breeding season witnessed a fatal great white shark (*Carcharodon carcharias*) attack on an adult male sea lion (E06/07-18Ph). On post mortem examination there were severe bite wounds to the abdomen with herniation of the abdominal organs. No other significant disease processes were detected. A second adult male (E06/07-17Ph) was found dead that same field season missing the abdomen, spine and pelvic limbs caudal to the kidneys, with serrated wound edges diagnostic of a shark bite. The proximate COD was predation, but the sea lion also had severe, chronic, granulomatous pleuritis and pericarditis due to *M. pinnipedii* infection, which may have predisposed it to this attack.

2.3.2.4 Unknown cause of death (n=19)

In 19 cases (27.1%) the COD was not able to be determined. Five out of the total of seven adult males examined were in this category. The remainder comprised one subadult male, three yearling males and ten adult females. Of these cases, one adult female (E08/09-23Ph) with a full-term pup in utero and histological lesions of acute placental separation was diagnosed as a possible dystocia, although the definitive COD of the female could not be determined. Another adult female (E01/02-39Ph) showed fibrin clots in lung capillaries on histology, consistent with disseminated intravascular coagulation (DIC). No other significant findings were found and no samples for bacteriology were taken so the cause of the DIC was not able to be determined and the COD was classified as unknown.

2.3.3 Concurrent and incidental diseases

2.3.3.1 Bacterial infections

Klebsiella spp. were isolated as incidental findings in two animals. In one (E98/99-01Ph), a light growth of *K. oxytoca* was isolated from the liver of a yearling female that died of bacterial pneumonia. There were no histological lesions in the liver. An adult female (E09/10-13Ph) that died of conspecific trauma-induced intestinal rupture and aspiration pneumonia had a light growth of *Klebsiella pneumoniae* cultured from the tracheobronchial lymph node.

A yearling female (E08/09-22Ph) that died due to conspecific trauma had *Klebsiella pneumoniae* cultured from the liver. Histologically, there were multifocal accumulations of neutrophils in the meninges, liver and corticomedullary junction of the adrenals, consistent with septicaemia. *K. pneumoniae* was therefore considered to have played a role in the morbidity of this animal.

Five out of 22 cases (22.7%) where mammary gland samples were available for histology showed mild subacute to chronic mastitis.

Due to sample collection being performed during the pupping season, uterine changes consistent with post-parturition involution were frequent. In addition, there was one case of mild endometritis (E09/10-21Ph), one case of mild focal metritis (E09/10-10Ph), one case of moderate metritis (E08/09-10Ph) and one case where there were retained foetal cranial bone remnants in utero and an associated moderate chronic endometritis (E03/04-52Ph).

2.3.3.2 Other bacterial isolates

Table 2.2 shows the bacterial isolates grown from NZSL tissues during this study. Some tissues grew a mixed growth on aerobic culture, which included such organisms as: *Escherichia coli*, alpha-haemolytic *Streptococcus* species, beta-haemolytic *Streptococcus* species, non-haemolytic *Streptococcus* species, *Staphylococcus aureus*, coagulase negative *Staphylococcus* species, *Enterobacter*, *Edwardsiella*, *Proteus mirabilis*, *Proteus vulgaris*, *Pasteurella* species, *Pseudomonas stutzeri* and *Klebsiella oxytoca*.

Some of the *Streptococcus* isolates from the 2008/09 breeding season were speciated and five cases had *Streptococcus constellatus* isolated, including from the liver in two cases that died from conspecific trauma (E08/09-15Ph, E08/09-20Ph), from the liver and spleen of the unborn foetus in the case where the mother was suspected to have died from dystocia (E08/09-23Ph), and from the lungs of two animals with severe bronchopneumonia (E08/09-19Ph, E08/09-33Ph). The lack of speciation of *Streptococcus* isolates in other years means that it was not known if *S. constellatus* was present in lesions in those years.

Table 2.2: Bacterial isolates grown from post mortem tissues of non-pup NZSLs sampled at Enderby Island for the breeding seasons 1998/99 to 2010/11 inclusive.

| Bacteria cultured | Site cultured from |
|-------------------------------------------------------------|-------------------------------------------------------------------------------------------------------------------------------------------------------------------------------------------------------------------------------------------------------------------------------------------|
| <i>Mycobacterium pinnipedii</i> | Lung (n=4/14) Lymph node (n=2/9) Pleural fluid (n=1/2) Liver (n=1/4) |
| <i>Klebsiella pneumoniae</i> | Liver (n=1/15) Lymph node (n=1*/9) |
| <i>Streptococcus</i> species | |
| <i>Streptococcus constellatus</i> | Lung (n=2*/17) Abscess (n=1/8) Liver (n=3/15) Uterus (n=1*/2) Spleen (n=1*/10) Foetal liver (n=1*/1) Foetal spleen (n=1*/1) |
| Pure growth of beta-haemolytic <i>Streptococcus</i> species | Lung (n=2/17) Lymph node (n=1/9) Unspecified tissue (n=1/3) Abscess (n=2/8) |
| Pure growth of other <i>Streptococcus</i> species | Spleen (n=2/10) |
| Pure growth of <i>Staphylococcus</i> species | Kidney (n=1/5) Abscess (n=1/8) Adrenal (n=1/1) |
| Pure growth of <i>Escherichia coli</i> | Lung (n=1/17) Liver (n=1/15) Spleen (n=1/10) |
| Pure growth of Gram positive rod | Bladder (n=1/1) |
| Mixed growth | Lung (n=12/17) Lymph node (n=8/9) Unspecified tissue (n=2/3) Mammary gland (n=1/1) Kidney (n=4/5) Abscess (n=4/8) Liver (n=10/15) Uterus (n=2/2) Muscle (n=1/1) Spleen (n=5/10) Foetal spleen (n=1/1) Foetal liver (n=1/1) Unspecified lesion (n=1/1) |

* = One isolate listed here was grown as part of mixed growth in this tissue

The numerator in the fractions shown indicates the number of positive cultures of this bacterial species that were grown from a particular tissue, whereas the denominator indicates the total number of mycobacterial or aerobic cultures that were performed of that particular tissue type.

2.3.3.3 Parasitism

In addition to the four cases where parasitism contributed to mortality (section 2.3.2.1: Bacterial and parasitic infections), there were other cases where parasitism was considered to be incidental to the COD. Seven of the 63 cases that had lungs available for gross examination (11.1%) showed grossly visible lung worms. The lung worms were described as white thread-like nematodes <1mm in diameter and 10-30mm long, predominantly found within bronchi and bronchioles. Thirty-six of the 55 cases that had lungs available for histological examination (65.5%) showed visible lung worms on histology, within the lung parenchyma and occasionally in the airways. Six cases where lung worms were visible on histology (6/35, 17.1%) showed an inflammatory response associated with the parasites, ranging from focal or multifocal granulomas containing degenerating parasites (n = 1; E10/11-08Ph), to moderate parasitic bronchopneumonia with associated changes such as congestion, collapse, mucous gland hyperplasia, inflammatory cell infiltration (mainly lymphocytes and plasma cells) in and around airways and proteinaceous fluid within the airways (n = 5; E08/09-10Ph, E08/09-20Ph, E08/09-21Ph, E09/10-21Ph, E09/10-22Ph). The remaining 29 cases where lung worms were seen histologically (29/35, 82.9%) showed no inflammatory reaction associated with the parasites. Two additional cases (E98/99-03Ph (died from infectious causes) and E02/03-26Ph (died from conspecific trauma)) showed a moderate pneumonia with granuloma formation, in which some granulomas contained dead lung worms, for which the histological appearance was more suggestive of early mycobacterial infection but for which an inflammatory response to parasites could not be ruled out.

Of the 65 animals that had at least part of the gastrointestinal tract available for examination, 48 (73.8%) had either gross or histological evidence of gastrointestinal parasitism. These parasites were found in the oesophagus (n = 14), stomach (n = 42) and small intestine and large intestine (n = 28). Although the descriptions within the gross post mortem reports vary, the gastrointestinal parasites that were reported were predominantly described as roundworms in the stomach and oesophagus, acanthocephalans in the small and large intestines and a single case of a several meters long adult tapeworm in the small intestine. There were no hookworms reported in any

of the non-pup individuals examined in this study. Further identification of parasites found falls outside of the scope of this study.

Twenty-seven cases (38.6%) showed cestode larval cysts in the subcutaneous tissues, predominantly over the ventral abdomen. The number of cysts varied from low numbers to severe localised burdens, without associated lesions in the subcutis or overlying skin.

Sarcocysts were observed within myocytes of two adult females (E01/02-03Ph, E02/03-103Ph), with no associated inflammatory reaction.

No ectoparasites were reported in any of the cases examined by this study.

2.3.3.4 Predation injuries

One adult female (E99/00-18Ph) was missing a pelvic flipper, and the amputation site had healed completely. This was an incidental finding and did not contribute to the death of the animal. The exact cause of the injury was not able to be confirmed, however it was hypothesised to be most likely the result of a shark attack.

2.3.3.5 Neoplasia

Neoplasia was present in three cases. One adult female (E09/10-22Ph) had a 1cm diameter uterine leiomyoma as well as multiple vaginal papillomas. A single 1.5cm diameter hepatoma was present in an adult female (E08/09-23Ph), and an infected biliary cystadenoma was described in a subadult male (E08/09-33Ph).

2.4 DISCUSSION

The important common causes of death in NZSLs identified in this study were conspecific trauma and bacterial infections. This is similar to what is found in pups of the NZSL at Enderby Island (Castinel, Duignan et al. 2007), and in subadult and adult northern fur seals (*Callorhinus ursinus*) (Spraker and Lander 2010).

The high incidence of mortality in non-pup NZSLs caused by conspecific trauma and/or wound infections (n=29/70; 41.4%) revealed in this study reflects the conditions

associated with harem breeding. There is a high density of individuals at the breeding colonies and the aggressive conspecific interactions within the colonies can result in often fatal trauma and infections. Despite the nature of the social interactions within the harems, in this study female NZSLs were not significantly more likely to be killed by conspecific trauma than males.

No adult males in this study died as a result of conspecific trauma, which is consistent with observations of aggressive interactions between adult male NZSLs being ritualised and brief (Marlow 1975). Aggressive interactions between female NZSLs are very rarely severe (Marlow 1975; Chilvers, Robertson et al. 2005), suggesting that the female conspecific trauma deaths in this study were likely to be the result of interactions with males. Observational studies show that interactions between adult male and adult female NZSLs are less ritualised and more likely to result in injury or death (Chilvers, Robertson et al. 2005; Marlow 1975). As females attempt to move between the sea and the harems on land, they pass adult and subadult males that are peripheral to the harems (Marlow 1975). These “peripheral males” pursue the females and attempt to bite, restrain and/or mate them on land or in shallow water, sometimes using their whole bodyweight to do so (Marlow 1975; Chilvers, Robertson et al. 2005). Dominant adult males controlling a harem rarely show aggression towards females (Marlow 1975).

In keeping with these findings, each of the five observed fatal cases of conspecific aggression reported in this study involved peripheral males attempting to mate with a female or in one case a yearling male. Lesions present included bite wounds, bruising of the head and neck, brain contusions, perineal trauma and penetrating wounds with herniation of the gastrointestinal or reproductive tract. Similar patterns of injuries present in unwitnessed cases of traumatic death suggest that these were also most likely the result of peripheral males attempting to mate the individual. Overall, penetrating wounds of the perineum, vagina, vestibule or rectum were present in 11 cases (10 females and one yearling male) in this study, eight of which had herniation of abdominal organs through the wounds. In six cases the penetrating wounds were assessed to be the result of penile penetration during mating attempts by males. Similar lesions are described in juvenile Pacific harbour seals (*Phoca vitulina*) and southern sea otter

(*Enhydra lutris nereis*) females as a result of forced matings by adult male southern sea otters (Harris et al. 2010).

Three of the five observed aggression cases involved adult females that drowned during mating attempts in shallow water. While a range of characteristic histological lesions have been reported to occur in association with drowning in cetaceans (Knieriem and Hartmann 2001; Kirkwood et al. 1997), none of these lesions were present in the three NZSLs. In human forensic medicine, drowning is difficult to diagnose grossly or histologically as many of the lesions reported are non-specific (Piette and De Letter 2006). The diagnosis of drowning appears similarly difficult in the NZSL, possibly resulting in under-reporting of this mode of death.

Not all fatal aggressive interactions by adult males were directed against females: two juvenile males also died of mating-related aggressive injuries inflicted by peripheral males. Juvenile male NZSLs are similar to adult females in size and colour in their first two years of life, darkening as they mature (Gales and Fletcher 1999), so mating attempts from peripheral males may be the result of yearling males being mistaken for females. Mating related injury and death of immature animals has been documented in other species of pinniped (Atkinson et al. 1994; Rose, Deutsch, and Le Boeuf 1991), where males appear to choose juveniles that most resemble females in size and colour (Rose, Deutsch, and Le Boeuf 1991).

Nine animals that died from conspecific trauma had concurrent disease processes that may have resulted in an increased incidence of aggression towards the diseased individual, due to changes in behaviour (e.g. the way the affected animal exhibits or responds to social cues). It is also possible that animals with underlying disease are weakened and therefore less able to evade conspecific aggression or less able to tolerate the same degree of traumatic injuries as a healthy animal. A similar theory is proposed for female southern sea otters suffering from cardiac disease, a common illness in this species, which may make these females less effective at defending themselves against mating related aggression from males (Kreuder et al. 2003). In southern elephant seals (*Mirounga leonina*), females that are isolated from the harems encounter more aggression from peripheral males (Galimberti, Boitani, and Marzetti 2000), and although this study

reported only healthy isolated southern elephant seal females, females that become isolated due to debilitation might experience similar aggression. Rose et al (1991) describe underlying disease in a yearling northern elephant seal (*Mirounga angustirostris*) that died from conspecific aggression, in the form of enlarged lymph nodes and a skin condition called “scabby molt” (Rose, Deutsch, and Le Boeuf 1991).

Conspecific trauma was a frequent COD in this study. Although some studies state that conspecific trauma is not likely to be a significant contributing factor to the decline of the NZSL population (Robertson and Chilvers 2011), others suggest that it affects the fitness of the population by changing female behaviour and decreasing reproductive success, health and survival (Chilvers, Robertson et al. 2005). Further study of conspecific trauma is recommended in this species, especially to determine the effect of this on the population and whether sex ratios and a declining population affect the frequency and intensity of the aggression, as it does in other species (Harris et al. 2010; Le Boeuf and Mesnick 1991; Galimberti, Boitani, and Marzetti 2000; Hiruki, Gilmartin et al. 1993).

Bacterial infections were also a common cause of mortality in non-pup NZSLs in this study and this may reflect the high densities of animals that occur during the breeding season, the combined stresses of reproduction and a heavily contaminated environment. The most notable bacterial COD identified in this study was mycobacteriosis. Disease caused by mycobacterial infection was the COD of six NZSLs in this study and was an incidental finding in three others. The range of lesions seen in these cases and the implications for the NZSL population will be discussed further in Chapter 3.

Klebsiella pneumoniae infection was the cause of increased NZSL pup mortality at Sandy Bay during the 2001/02 and 2002/03 breeding seasons (Castinel, Duignan et al. 2007; Castinel, Grinberg et al. 2007). *Klebsiella pneumoniae* isolates grown from pups since the epizootic events have been described as a hypermucoviscous strain that is phenotypically similar to strains that cause neuro-invasive disease and septicaemia in humans (Roe et al. 2015). *Klebsiella* species were cultured from tissues of non-pup NZSLs in this study, from two yearling females and one adult female. The individuals that had *Klebsiella* spp. grown died in the breeding seasons of 1998/99 (*K. oxytoca*), 2008/09 (*K.*

pneumoniae) and 2009/10 (*K. pneumoniae*), indicating that these pathogens were present in the non-pup population in years outside of the pup epizootic events. It is not known if these isolates were from the same clonal lineage as the bacterium that caused the epizootic events, nor if the isolates were a hypermucoviscous strain, and this warrants further investigation.

Subcutaneous abscessation around the head and neck, grossly similar to that seen in the epizootic event in the 1997/98 breeding season, was present in 9 animals (E02/03-94Ph, E04/05-03Ph, E03/04-13Ph, E06/07-11Ph, E98/99-01Ph, E02/03-103Ph, E08/09-33Ph, E09/10-08Ph, E04/05-09Ph). However, these were sporadic in occurrence (0-2 per year over this study period), and none had intralesional pleomorphic gram negative bacteria as described by Duignan 2000 (Duignan 2000). Six animals had subcutaneous abscesses with cellulitis and myositis in the absence of an apparent traumatic cause of the abscessation. In four of these cases there was a concurrent bacterial pneumonia, which may represent embolic spread of bacteria from the subcutaneous lesions. In three of these cases the same bacteria were isolated from both sites, supporting this hypothesis.

Although interstitial nephritis and renal failure due to leptospirosis is a frequent cause of morbidity and mortality in California sea lions (*Zalophus californianus*) (Gulland et al. 1996; Vedros et al. 1971), only two animals in the current study had renal lesions, both of which were pyelonephritis and therefore not consistent with leptospirosis. Serological surveys of 147 NZSLs at Enderby Island and Otago, New Zealand for anti-leptospiral antibodies showed a low titre against *Leptospira interrogans* serovar Pomona in only one adult female (Roe et al. 2010), further indicating that leptospirosis is unlikely to contribute to morbidity and mortality in the Enderby Island sea lion population.

Although many of the bacteria isolated in this study are not primary pathogens, this baseline knowledge of the bacteria present in the NZSL population may aid in future investigations, including interpretation of results during future disease outbreaks. The most frequent bacterial species cultured in this study were *Staphylococcus* spp., *Streptococcus* spp. and *Escherichia coli* (Table 2.2). *Proteus*, *Enterococcus*, *Edwardsiella*, *Enterobacter*, *Pseudomonas* and *Pasteurella* spp. were cultured less commonly. These findings are similar to other reported pinniped studies (Thornton, Nolan, and Gulland

1998; Spraker and Lander 2010; Vedros, Quinlivan, and Cranford 1982). The presence of *Staphylococcus* spp., *Streptococcus* spp. and *E. coli* in infected wounds and pyelonephritis in the current study suggests probable opportunistic infection of wounds and the urinary tract by skin and faecal flora. Breeding colonies of the NZSL are contaminated with faeces and urine (Marlow 1975), and wounds would be readily exposed to these sources of infection.

Speciation of future *Streptococcus* isolates from NZSLs in conjunction with post mortem findings is recommended, to determine if *S. constellatus* is a significant pathogen of the NZSL, and therefore also whether the fact that it was cultured from five cases in the 2008/09 season was a contributing factor to the higher number of NZSL deaths that year. Similarly, future speciation of *Streptococcus* isolates may allow *Streptococcus* species that have been documented to cause disease in other pinniped species to be identified. *Streptococcus phocae*, for example, is a beta-haemolytic *Streptococcus* that has been isolated from the lungs of seals with pneumonia (Skaar et al. 1994).

Parasite burdens of the gastrointestinal and respiratory tract of the NZSLs in this study have been described in section 2.3.3 (Concurrent and incidental diseases). Although parasitism alone was not a COD, heavy parasite burdens of the lungs and/or gastrointestinal tract are likely to have contributed to morbidity and mortality in some cases. The cases of lung worm infection seen in this study show that the pathogenicity of lung worm burdens in the NZSL can range from no associated inflammatory reaction to a moderate parasitic bronchopneumonia which may contribute to morbidity and mortality. Lung worms found in California sea lions (Howard 1983) and the Australian sea lion (*Neophoca cinerea*) (Nicholson and Fanning 1982) are from the genus *Parafilaroides* and it seems likely that the lung worms seen in the NZSLs in this study are of the same or a related genus. In California sea lions, moderate to severe inflammation in the lungs is associated with migrating larvae of *Parafilaroides decorum*, whereas there is minimal or no associated inflammatory response to adult worms residing in alveoli (Howard 1983). The histological lesions seen in the current study are similar to those seen in California sea lions infected with *P. decorum* (Howard 1983). Based on these similarities, lung worm infection in the NZSL may follow a similar

pathogenesis to *P. decorum* infection in the California sea lion. Speciation of lung worm specimens from NZSLs would help with further description of this disease.

Infectious agents detected by this study were a range of bacteria and internal parasites, however specific testing for viral pathogens was outside of the scope of this study. There were no gross or histological lesions consistent with morbillivirus, herpesvirus, influenza A virus or adenovirus infection, however no specific viral testing such as serology, PCR or immunohistochemistry was performed for these pathogens. Some bacteria require specific culture techniques to grow and are therefore unlikely to be grown by the routine aerobic cultures performed on tissue samples in this study. This includes *Salmonella* and *Mycoplasma* species, some of which are potential pathogens to pinnipeds around the world (Fenwick et al. 2004; Haulena et al. 2006; Lynch et al. 2011).

There is considerable inter-annual variation in the number of NZSLs that are found dead and subject to post mortem examination at Enderby Island during the breeding season (Fig 2.1). Linear regression showed no relationship between the number of NZSLs found dead and the time researchers spent on the island for that season, and also no relationship between the number of NZSLs found dead and the number of tag re-sights reported for that season. The number of tag re-sights reported for a season are an estimate of the number of animals on the beach and therefore the breeding population for that season. The inter-annual variation in the frequency of non-pup NZSL mortality in this study was therefore possibly due to a variety of factors including removal of bodies by predators and scavengers, weather/tidal conditions preventing access to bodies, the date that the researchers arrive on the island, and random fluctuation. For example, if researchers arrive after harems have already started to form, they may have missed early season deaths from infectious causes and conspecific aggression. The largest number of animals examined was in the 2008/09 season, during which there were 19 NZSLs found dead. Conspecific trauma in that season was the COD of three adult females, two yearling females, two yearling males and one subadult male; however, the factors that caused the peak of mortality during this season are not readily apparent.

The incidence of predation is probably under-reported in this study. The apparently low incidence of fatal predation is likely to be an artefact of study design, since the majority

of sea lions killed by sharks would die at sea and not be detected as on-shore mortalities. The two major predators of sea lions worldwide are sharks and orca (*Orcinus orca*) (Robertson and Chilvers 2011). The only known natural predator of non-pup NZSLs is the great white shark, a species known to inhabit the waters around the Auckland Islands (Robertson and Chilvers 2011). Researchers witnessed predation of a NZSL by a great white shark in this current study, confirming this species as a predator of the NZSL. Orca predation has been suspected historically based on the appearance of some wounds, and leopard seals (*Hydrurga leptonyx*) have been seen to predate on NZSL pups (Gales 1995). Five cases (7.1%) in this study had predator injuries, either fatal (n = 2; 2.9%) or non-fatal (n = 3; 4.3%). This suggests a much lower incidence of predation than reported by Robertson et al. (2011) where 27% of adult NZSLs on Enderby Island showed scarring consistent with shark attacks (Robertson and Chilvers 2011).

Although the findings of neoplasia in three NZSLs in this study is interesting and worth documenting, it is unlikely that these findings are significant with regards to the health of the population, and none of the reported neoplastic lesions were the COD of the individuals in which they were found. In California sea lions, metastatic carcinomas originating in the genital tract and often spreading rapidly to the sublumbar lymph nodes and other internal sites have been described, and frequently contain eosinophilic intranuclear inclusion bodies (Lipscomb et al. 2000). A novel gammaherpesvirus was detected in the lesions (Otarine herpesvirus-1) (King et al. 2002), and the virus is probably a contributing factor to the pathogenesis of the carcinomas (Lipscomb et al. 2000; King et al. 2002; Buckles et al. 2006). The adult female NZSL with multiple vaginal papillomas in this dataset showed no sign of metastasis or inclusion bodies, but further investigation of this case and any future cases with a similar presentation for viral involvement, especially herpesviruses and papillomaviruses, is recommended.

Overall, tissue preservation and sample availability enabled an adequate diagnostic investigation to be conducted 55/70 cases (78.6%), meaning the diagnosis of 21.4% of cases were affected by factors such as scavenging, autolysis, missing samples and variation in the style and detail of the gross post mortem reports. This highlights the

difficulties that are inherent in performing post mortem examinations in an isolated field setting such as Enderby Island.

2.5 CONCLUSIONS

During the breeding season large numbers of NZSLs accumulate at the breeding colonies for a period of close co-habitation, and within the harems animals readily come in contact with the respiratory fomites, vomit, faeces, urine and birthing fluids of other individuals (Marlow 1975), all of which may result in pathogen spread between individuals, including those documented in this study. The introduction of a pathogen into a population of pinniped species at this time can result in rapid disease spread and epizootic events (Harwood and Hall 1990). The breeding season is an important consideration with regards to pathogen transmission for the NZSL, as even with a declining population animals will always aggregate during the breeding season and the probability of pathogen transfer may not decline significantly even if the population does, as is theorised for other pinniped species also (Harwood and Hall 1990). Outside of the breeding season, the animals disperse from the harems and the density of individuals is reduced, presumably reducing pathogen transmission between individuals. Individual NZSLs have been documented to move between breeding colonies and throughout the extents of the species' range outside of the breeding season (Baker 1999; Robertson et al. 2006; Geschke and Chilvers 2009), indicating that the entire NZSL population should be considered a single population with regards to pathogen spread (Robertson et al. 2006). Therefore, the findings of this study with regards to the pathogens and disease processes found at the Enderby Island breeding colony are applicable to the rest of the NZSL population, but further research at other locations is required.

While the nature of this study (post mortem investigation of animals found dead during breeding seasons) means that the results cannot be directly extrapolated to indicate population-level mortality, some useful conclusions could be made. No known causes

of pinniped epizootics were identified in this group of animals. The presence of *Klebsiella* and *Mycobacterium* species is of interest, due to being primary pathogens and their persistence in the population over time. Further investigation into the epidemiology of these pathogens is required to determine the effects of these agents on the population, and whether these diseases could contribute to population decline.

In other pinniped species, it has been documented that rates of conspecific aggression can differ significantly between different breeding colonies of the same species (Galimberti, Boitani, and Marzetti 2000; Hiruki, Gilmartin et al. 1993). The findings of death due to conspecific trauma at the Enderby Island breeding colonies as part of this study can therefore not be directly extrapolated to other breeding colonies, as they may be related to terrain, sex-ratio and other population demographics, which may differ between colonies. Further research is required to determine if the incidence of death due to conspecific trauma varies between NZSL breeding colonies. Given the dispersal of individuals that occurs after the breeding season and the reduced breeding activity outside of the breeding season, conspecific aggression in the NZSL is likely to be less frequent and intense and result in less injury and death outside of the breeding season. Conspecific trauma is unlikely a sole cause of the population decline, however if a male-biased sex ratio increases the frequency and severity of mating related injuries in this pinniped species, as has been suggested in others (Hiruki, Gilmartin et al. 1993; Galimberti, Boitani, and Marzetti 2000; Harris et al. 2010; Le Boeuf and Mesnick 1991), then the resulting increased levels of individual mortality through conspecific trauma could be contributing to higher mortality rates and lower reproductive rates than expected, resulting in faster population decline. Further research into the sex ratio and other demographics in the population and throughout the breeding season, and the effects of these on levels of conspecific aggression, is strongly recommended.

CHARACTERISATION OF *MYCOBACTERIUM PINNIPEDII* INFECTION IN NEW ZEALAND SEA LIONS (*PHOCARCTOS HOOKERI*) AT ENDERBY ISLAND

3.1 INTRODUCTION

Tuberculosis due to infection with *Mycobacterium pinnipedii* has been described in wild and captive pinnipeds around the world (Cousins et al. 2003; Kriz et al. 2011; Jurczynski et al. 2012; Moser et al. 2008). The organism is zoonotic (Thompson et al. 1993; Kiers et al. 2008; Cousins et al. 2003) and is also known to cause infections in domestic cattle in New Zealand (Cousins et al. 2003; Loeffler et al. 2014). While confirmed cases of *M. pinnipedii* in the New Zealand sea lion (*Phocarctos hookeri*) (NZSL) have not been reported in the literature, mycobacterial infections due to organisms from within the *Mycobacterium tuberculosis* complex (MTC) have been reported in two wild New Zealand fur seals (*Arctocephalus forsteri*) in New Zealand (Hunter et al. 1998) and a wild New Zealand sea lion (Roe et al. 2006). At present, mycobacterial infection has not been investigated in NZSLs, and the presence of *M. pinnipedii* has not been confirmed in this species.

Mycobacterium pinnipedii was first described as a novel species within the MTC with pinnipeds as the natural host by Cousins et al (Cousins et al. 2003). Disease caused by *M. pinnipedii* infection in pinnipeds typically manifests as granulomatous lesions in the lungs, pleura, lymph nodes, spleen and peritoneum, but lesions of the liver and meninges as well as disseminated disease have also been recorded (Cousins 2008). The pathological findings in cases of tuberculosis can allow inferences to be made regarding the route of infection, for example infection of the lungs and thoracic cavity indicates aerosol spread and inhalation of the organism (de Lisle et al. 2002; Jones, Hunt, and King 1997; Kissane and Anderson 1985), whereas ingestion of organisms results in infection of the tonsils and mesenteric lymph nodes (Kissane and Anderson 1985). A case series describing the lesions associated with tuberculosis in the NZSL population would increase understanding of aspects of the pathogenesis of the disease, which may be of use in management decisions for the species.

The gross pathological findings and histological appearance of lesions can be strongly suggestive of mycobacterial infection but further testing is required to confirm the diagnosis and characterise the organism involved. Culture of a mycobacterial organism from suspicious lesions is the gold standard for diagnosis of mycobacterial infection (de Lisle et al. 2002). Characterising the mycobacterial species and strains involved is important for understanding the epidemiology of the disease. Cousins et al (2003) used phenotypic and genetic tests including DNA spoligotyping on culture isolates to differentiate *M. pinnipedii* from other members of the MTC (Cousins et al. 2003). Since then, several molecular techniques for rapid differentiation of the species in the MTC have also been described (Huard et al. 2006; Warren et al. 2006).

The aim of this chapter was to: a) evaluate post mortem records of NZSLs to identify cases with gross and histological lesions suggestive of mycobacteriosis; b) characterise the species and strains of mycobacteria present; and c) characterise the pathology associated with confirmed mycobacterial infections.

3.2 MATERIALS AND METHODS

3.2.1 *Archived samples and data*

Expeditions to the NZSL breeding colonies on Enderby Island in the Auckland Islands have been undertaken annually during the NZSL breeding season (early December to late February) to collect biological data on this species. As part of the research performed on these expeditions, post mortem examinations were performed on most sea lions of all age groups that were found dead. This study utilises post mortem reports and archived tissues from these expeditions for all seasons between 1998/99 and 2010/11 inclusive.

Seventy individuals one year of age or older had post mortem results available from this time period (see Chapter 2). Of these, tissue samples were taken for histology from 60 individuals. Only those 60 individuals that had tissues available for histology were included in this chapter, due to the importance of histology in diagnosing and describing mycobacterial infection.

The post mortem examinations were performed either by a veterinarian or by a trained and experienced sea lion biologist. For each post mortem examination, a gross post mortem report was recorded and further samples were taken for most cases. The author was in this role for six weeks during the 2009/10 breeding season.

Tissue samples taken for histology were preserved in 10% neutral buffered formalin until the time of this study. Where further samples were taken for bacteriology they were stored in liquid nitrogen during the field season and then stored at -80°C until the time of this study. There were minor changes in the post mortem protocol during the study period, which caused minor differences in the samples collected each year. Field conditions, degree of scavenging of the carcass and degree of autolysis also affected the sample set taken per post mortem.

3.2.2 *Sample preparation, lesion review and laboratory analysis*

The cause of death (COD) of each animal was determined as described in Chapter 2. To investigate further for mycobacterial infection, gross post mortem reports were reviewed

and gross lesions consistent with mycobacterial infection were identified, including lung nodules/granulomas, lung abscesses, pneumonia, pleuritis, enlargement of lymph nodes and nodules in lymph nodes. Histological findings were also reviewed and lesions consistent with mycobacterial infection were identified, including granulomatous inflammation of any size/severity in any tissue, especially the lungs, pleura, liver, spleen and lymph nodes.

Formalin-fixed tissues were embedded in paraffin and routinely processed for histology. Sections were cut at 4µm and stained with haematoxylin and eosin (H&E). Slides were examined using a light microscope. For histological lesions consistent with mycobacterial infection detected microscopically, Ziehl-Neelsen (ZN) staining was performed and the tissue examined under oil immersion at 100x magnification to assess for acid fast organisms (AFOs). Von Kossa staining was performed to assess for the presence of mineralisation in these lesions.

Where available, frozen tissues from organs showing lesions consistent with mycobacterial infection on gross or histological examination were retrieved for mycobacterial culture. Mycobacterial cultures were performed at the AgResearch laboratory in Wallaceville, Upper Hutt, New Zealand. The tissue samples were homogenised in phosphate buffer and then decontaminated using NaOH. Following neutralisation with phosphate buffered saline the samples were centrifuged and the spun deposit reconstituted in phosphate buffer. This was used to inoculate a vial containing liquid 7H9 plus antibiotics (PANTA, BD) and a solid slope of 7H11 medium supplemented with pyruvate. The media were incubated at 37°C for 30 days for the liquid 7H9 and 90 days for the solid 7H11 pyruvate.

The liquid media were examined for the presence of AFOs while the solid media were examined for bacterial colonies. The initial identification was based on a sensitivity test to isoniazid (INH) and thiophen-2-carboxylic acid hydrazide (TCH). This identifies the organisms as being either *Mycobacterium bovis* or *M. pinnipedii* as both these species are sensitive to INH and TCH.

Individual species within the MTC are able to be distinguished from each other using deletions of gene sequences that are specific to individual species within the MTC. Mycobacterial isolates from the solid media were subjected to a multiplex PCR test, which determines the absence (168bp product – *M. pinnipedii*) or presence (293bp product – all other members of the *M. tuberculosis* complex) of the DNA region of difference named RD2-seal as described in Warren et al. (Warren et al. 2006).

To type the mycobacterial isolates grown, DNA was extracted from liquid cultures using the protocol described by Subharat et al. (Subharat et al. 2012). The method used for DNA typing was the combination of 9 variable number tandem repeat (VNTR) assays and 2 PCR direct repeat (DR) assays as described by Price-Carter et al. (Price-Carter, Rooker, and Collins 2011). The loci examined were Miru40, EtrD, EtrC, EtrE, NZ2, QUB 18, QUB 11a, QUB 26, DR 2, DR 1 and QUB 3232 and are the same loci that are routinely used to type *M. bovis* isolates in the Wallaceville AgResearch laboratory.

For individuals where mycobacterial disease was confirmed by culture and PCR, a full histological description of all lesions was given. This was combined with the gross findings, culture, PCR and typing results to describe the full extent of mycobacterial disease in the individual.

3.3 RESULTS

3.3.1 Gross and histological findings

There were 60 NZSL cases which had post mortem examinations performed and tissue samples collected and processed for histology. Thirteen out of the 60 cases (21.7%) showed gross and histological findings consistent with mycobacterial infection (E00/01-42Ph, E08/09-53Ph, E08/09-24Ph, E10/11-12Ph, E06/07-17Ph, E09/10-10Ph, E09/10-17Ph, E09/10-13Ph, E09/10-14Ph, E98/99-03Ph, E00/01-16Ph, E02/03-26Ph, E09/10-22Ph) (See Appendix 1). Ziehl-Neelsen staining was performed on these cases, and six cases had visible acid fast organisms (AFOs).

A further five cases had microscopic granulomas in the hepatic parenchyma either singly or in small numbers, but no other gross or microscopic lesions suggestive of mycobacterial infection (E00/01-15Ph, E01/02-03Ph, E01/02-39Ph, E01/02-53Ph, E06/07-02Ph). When ZN staining of these lesions was performed, the granulomas either did not show AFOs or were cut out of section due to their small size and were not able to be examined for AFOs. The affected livers were not available for culture.

3.3.2 Identification and characterisation of mycobacterial isolates

Thirty individual tissue samples from 18 animals were cultured for mycobacterial organisms. Six animals grew *Mycobacterium* spp. from a range of tissues (Table 3.1). All six isolates were identified as *M. pinnipedii*, using the multiplex PCR test to examine for the RD2 seal deletion. Two other individuals had AFOs present histologically and in the liquid culture media but gave no growth on the solid culture media, indicating there were mycobacterial organisms present but that these were not viable, therefore the species of *Mycobacterium* remains unknown for these two cases.

Table 3.2 shows the VNTR/DR typing results from the six cases with confirmed mycobacterial infection. All mycobacterial isolates recovered were confirmed as *M. pinnipedii*. For all cases where isolates were grown from more than one tissue, the VNTR results were identical for all isolates and only a single VNTR result is therefore shown for each case. That is, each animal only had a single strain of *M. pinnipedii* detected. All isolates had an identical number of repeats at every locus except for the QUB3232 locus, at which there was some variation as there were three different patterns of repeats seen. The isolates from two cases (cases E08/09-24Ph and E09/10-10Ph) showed 12 repeats at this locus, the isolate from another case (E08/09-53Ph) showed 26/18 repeats and all other isolates (cases E06/07-17Ph, E09/10-17Ph and E09/10-13Ph) showed 17 repeats. These results indicate that there is minor strain variation among the *M. pinnipedii* isolates within the NZSL population.

Table 3.1: Mycobacterial culture results from NZSL post mortem cases with confirmed mycobacterial infection.

| Case number | Organs cultured | Positive culture results (organ) | ZN +ve org in liquid medium but no growth |
|-------------|-------------------------|----------------------------------|-------------------------------------------|
| E00/01-42Ph | TF | - | - |
| E08/09-53Ph | Li, Lu | Lu | - |
| E08/09-24Ph | Lu | Lu | - |
| E10/11-12Ph | Lu | - | Lu |
| E06/07-17Ph | Ln, Lu, PS | Ln, Lu, PS | - |
| E09/10-10Ph | Lu with pleura attached | Lu with pleura attached | - |
| E09/10-17Ph | Li, GLN/HLN | Li | - |
| E09/10-13Ph | Li, Lu, MTBLN | MTBLN | - |
| E09/10-14Ph | Lu, MTBLN | - | Lu, MTBLN |

GLN/HLN = gastric or hepatic lymph node, Li = liver, Ln = lymph node, Lu = lung, MTBLN = middle tracheobronchial lymph node, PS = pleural swab, TF = thoracic fluid

Table 3.2: Table of nine variable number of tandem repeat (VNTR) and two direct repeat (DR) loci for the isolates grown from six cases of *Mycobacterium pinnipedii* infection in New Zealand sea lions.

| Case number | MIRU 40 | ETRD | ETRC | ETRE | NZ2 | QUB 18 | QUB 11a | QUB 26 | DR2 | DR1 | QUB 3232 |
|-------------|---------|------|------|------|-----|--------|---------|--------|-----|-----|----------|
| E08/09-53Ph | 2 | 7 | 3 | 3 | 4 | 13 | 10 | 7 | 0 | 11 | 26/18 |
| E08/09-24Ph | 2 | 7 | 3 | 3 | 4 | 13 | 10 | 7 | 0 | 11 | 12 |
| E06/07-17Ph | 2 | 7 | 3 | 3 | 4 | 13 | 10 | 7 | 0 | 11 | 17 |
| E09/10-10Ph | 2 | 7 | 3 | 3 | 4 | 13 | 10 | 7 | 0 | 11 | 12 |
| E09/10-17Ph | 2 | 7 | 3 | 3 | 4 | 13 | 10 | 7 | 0 | 11 | 17 |
| E09/10-13Ph | 2 | 7 | 3 | 3 | 4 | 13 | 10 | 7 | 0 | 11 | 17 |

3.3.3 Characterisation of pathology associated with confirmed mycobacteriosis in NZSLs

In total, nine out of the 60 individuals (15%) had mycobacterial infection confirmed by either positive mycobacterial culture results or visible AFOs in lesions on histology. Table 3.3 documents the lesions in these nine cases, as well as their gender, age grouping, blubber depths and ZN staining, culture and PCR results. The details of the main pathological findings are described below. In six (10%) of these individuals, mycobacterial disease was determined to be severe enough to cause the death of the animal. One of the 60 individuals (1.7%) was witnessed to be killed in a shark attack but had concurrent severe mycobacterial disease (E06/07-17Ph), sufficient to cause morbidity. Two of 60 individuals (3.3%) had subclinical mycobacterial lesions in lymph nodes but no detectable lesions due to mycobacterial infection in other organs (case E09/10-13Ph and E09/10-14Ph). These two individuals died from causes unrelated to these lymph node lesions. E10/11-12Ph had concurrent head trauma, which may have contributed to the death of the animal.

The most common lesions were multifocal granulomas present in the lymph nodes (7 of 9), lung (5 of 9), pleura (3 of 9), pericardium (3 of 9), liver (1 of 9), endometrium and ovary (1 of 9), and peritoneum (1 of 9). The granulomas were typically unencapsulated aggregations of macrophages with small numbers of associated lymphocytes and plasma cells, with or without central areas of necrosis, mineralisation or coalescence. Necrotic areas in the lung lesions of cases E08/09-24Ph and E10/11-12Ph contained degenerate neutrophils.

Pleural effusion was associated with respiratory mycobacteriosis in three cases and all animals with respiratory mycobacteriosis showed concurrent lesions in one or more lymph nodes (Table 3.3). Cases E08/09-24Ph and E10/11-12Ph showed a generalised lymphadenopathy grossly and reactive nodes microscopically but no granuloma formation or necrosis.

Table 3.3: Histological findings, culture results and PCR results in nine New Zealand sea lions with confirmed mycobacterial infection

| Predominant disease process present | Case number | Field Season | Age/Gender | Blubber depth (mm) | Histological findings | | | | | | | | | | | | | | | AFOs seen in lung lesions | AFOs seen in lymph node lesions | AFOs seen in liver lesions | Mycobacterial culture | PCR for <i>M. pinnipedi</i> |
|-------------------------------------|-------------|--------------|---------------|--------------------|----------------------------------|---------------------------------------------|------------------------------------|-------------------------------------|-----------------------------------|-------------------------|----------------------------|------------------|-------------------------|----------------------------|-------------------|---------------------------|-----------------------------|-------------------------------------------|-----------------------------------------|---------------------------|---------------------------------|----------------------------|-----------------------|-----------------------------|
| | | | | | Multifocal small lung granulomas | Large multifocal coalescing lung granulomas | Thickening of lobular interstitium | Central necrosis of lung granulomas | Mineralisation of lung granulomas | Granulomatous pleuritis | Granulomatous pericarditis | Pleural effusion | Granulomatous hepatitis | Granulomatous endometritis | Ovarian granuloma | Granulomatous peritonitis | Granulomatous lymphadenitis | Central necrosis of lymph node granulomas | Mineralisation of lymph node granulomas | | | | | |
| Pneumonia | E00/01-42Ph | 2000/01 | Adult female | 4 | - | + | - | + | + | - | + | - | + | - | + | + | - | + | + | + | 1+ | 1+ | - | Neg |
| | E08/09-53Ph | 2008/09 | Adult female | 4 | - | + | - | + | - | - | - | - | - | - | - | - | - | - | - | - | - | - | Pos | |
| | E08/09-24Ph | 2008/09 | Adult female | 10 | - | + | + | + | + | - | - | - | - | - | - | - | - | - | - | 1+ | - | - | Pos | |
| | E10/11-12Ph | 2010/11 | Adult female | 6 | - | + | + | + | - | + | + | - | - | - | - | - | - | - | - | 1+ | - | - | (+) | |
| Pleuritis | E06/07-17Ph | 2006/07 | Adult Male | 25 | - | - | - | - | - | + | + | - | - | - | - | - | TBLN, +1 unknown | + | - | - | - | Pos | | |
| | E09/10-10Ph | 2009/10 | Adult female | 30 | + | - | - | + | - | + | + | - | - | - | - | - | MLN, TBLN | + | - | - | - | Pos | | |
| Hepatitis | E09/10-17Ph | 2009/10 | Subadult Male | NM | - | - | - | - | - | - | - | - | + | - | - | - | GLN and/or HLN | + | + | - | - | 2+ | 2+ | |
| Lymph node lesions only | E09/10-13Ph | 2009/10 | Adult female | 19 | - | - | - | - | - | - | - | - | - | - | - | - | TBLN, MLN or SLN | + | + | - | 1+ | - | Pos | |
| | E09/10-14Ph | 2009/10 | Subadult Male | 26 | - | - | - | - | - | - | - | - | - | - | - | - | TBLN | + | + | - | 1+ | - | (+) | |

+ = lesion present, - = lesion absent, NM = blubber depth not measured, Pos = positive test result, Neg = negative test result
For AFOs section: - = no AFOs seen, 1+ = low numbers of AFOs seen, 2+ = large numbers of AFOs seen
GLN = gastric lymph node, HLN = hepatic lymph node, MLN = mediastinal lymph node, SLN = sternal lymph node, TBLN = tracheobronchial lymph node
If the lymph node affected is not stated, the origin of the node/s affected histologically was not able to be determined from records
(+) = ZN positive organisms seen in inoculated liquid medium but no growth, (-) = PCR not performed due to no organisms being grown on culture

Acid fast organisms were visible in low numbers in the lung lesions in three cases, in the lymph node lesions of four cases and in the liver lesions of one case (Table 3.3). The AFOs were intracellular in macrophages in six cases (E00/01-42Ph, E08/09-24Ph, E10/11-12Ph, E09/10-17Ph, E09/10-13Ph, E09/10-14Ph) and were also seen in necrotic debris in four cases (E00/01-42Ph, E10/11-12Ph, E09/10-17Ph and E09/10-14Ph).

There was some variation in the appearance of pleuritis. Case E10/11-12Ph showed a granulomatous pleuritis and pericarditis that appeared to be an extension of the concurrent bronchopneumonia. The pleura and pericardium were diffusely thickened by macrophages which were organising into small granulomas in some places, the larger of which had necrotic centres. Cases E06/07-17Ph and E09/10-10Ph showed severe chronic granulomatous pleuritis and pericarditis consisting of a thick layer of macrophages, fibrous tissue and occasional plasma cells and lymphocytes with no distinct organisation. There were occasional small focal areas of necrosis throughout the thickened pleura. Multifocally, hyperplastic mesothelial cells formed villous projections (Figures 3.16-3.18). There was little or no lung involvement in these second two cases of pleuritis with E06/07-17Ph showing no granulomatous change of the lung parenchyma, and E09/10-10Ph showing multifocal discrete small lung granulomas only.

There is no association evident between the VNTR/DR typing results and the variation of lesions seen in the cases of *M. pinnipedii* infection examined by this study.

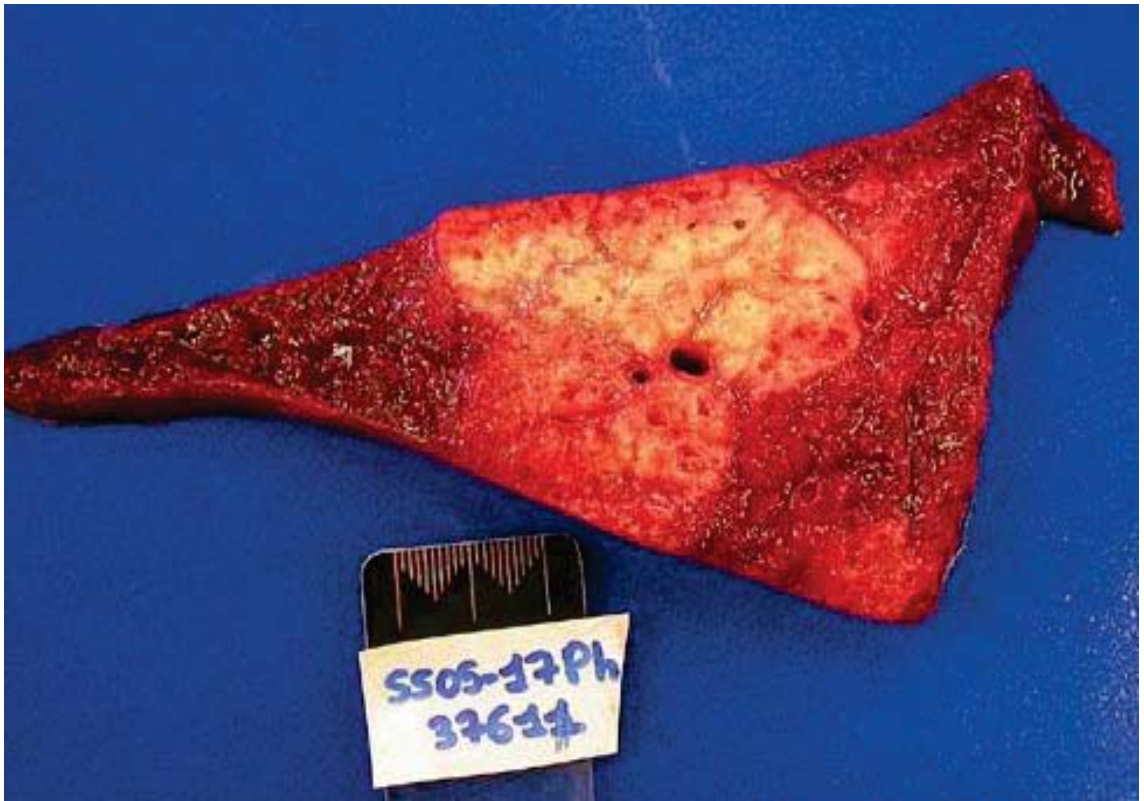

Figure 3.1: A case of mycobacterial infection in a NZSL examined at IVABS Massey University Palmerston North showing severe consolidation and multifocal coalescing granulomas of various sizes in the lung on cut surface.

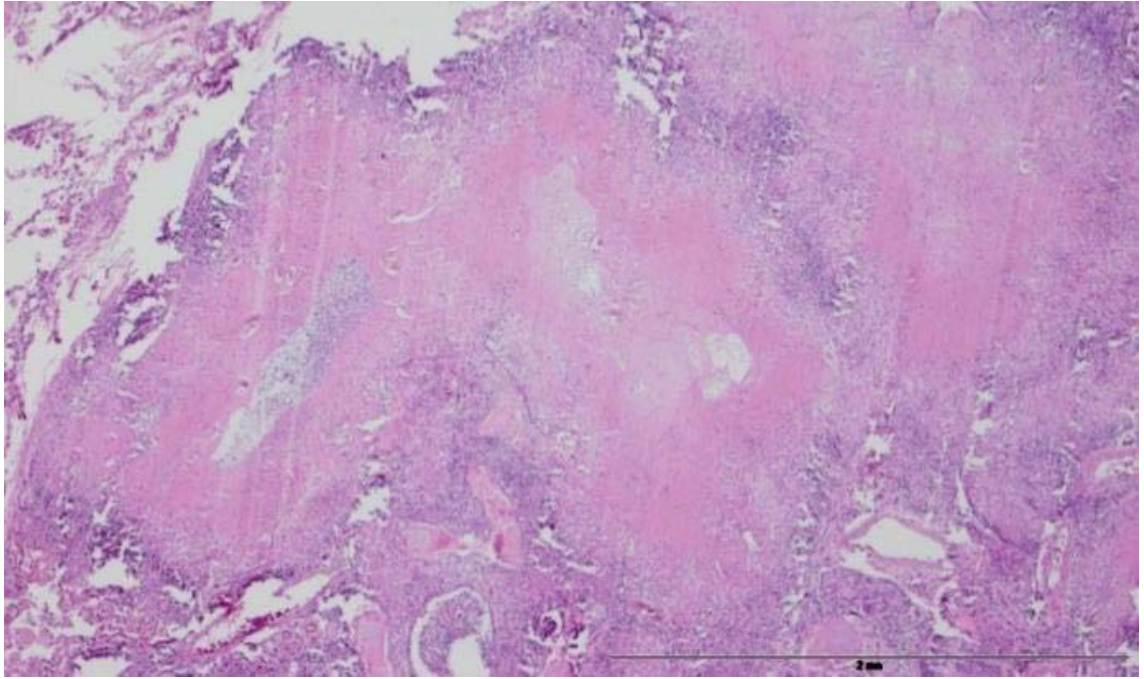


Figure 3.2: Haematoxylin and eosin stain. Scale bar represents 2mm. Lung tissue from case E08/09-53Ph showing severe chronic multifocal to coalescing granulomatous bronchopneumonia. There are large areas of necrosis surrounded by granulomatous inflammation. In parts of the lungs that were less severely affected, smaller discrete granulomas were present, with or without necrotic centres.

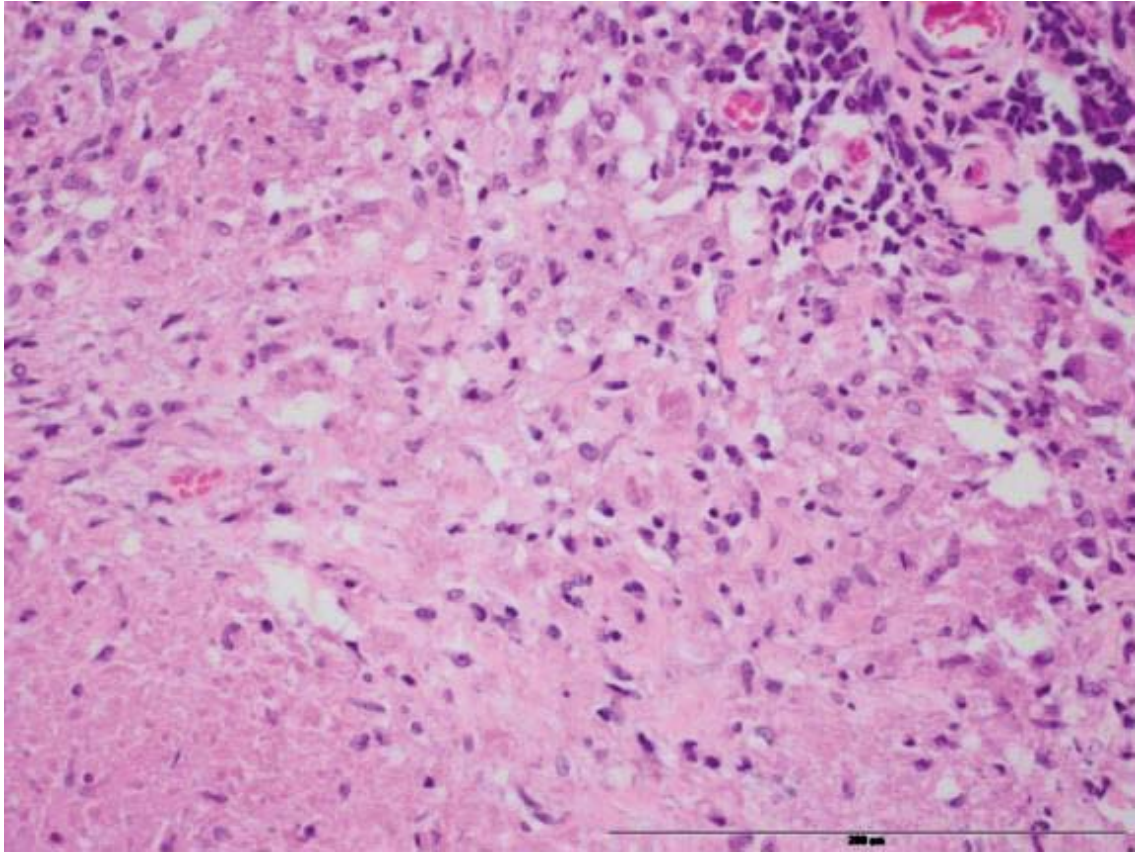


Figure 3.3: Haematoxylin and eosin stain. Scale bar represents 200 μ m. Lung tissue from case E08/09-53Ph showing lung granulomas consisting central necrosis surrounded by an inflammatory infiltrate of predominantly macrophages and a small number of lymphocytes and plasma cells.

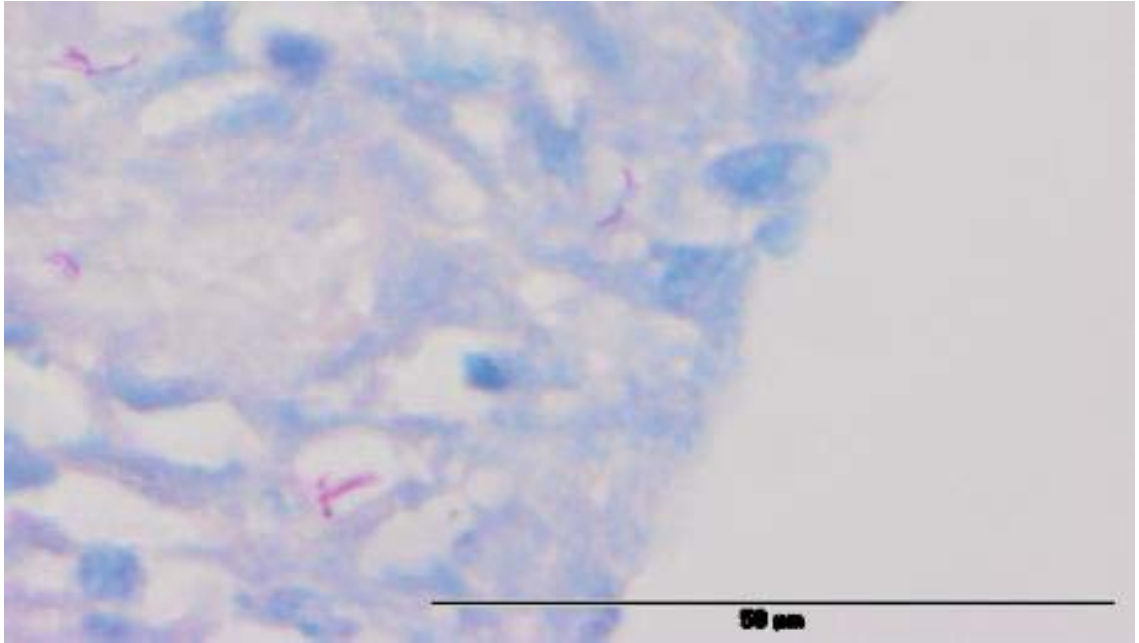


Figure 3.4: Ziehl-Neelsen stain. Scale bar represents 50μm. Lung granulomas from case E00/01-42Ph showing a small number of visible AFOs intracellularly in macrophages and in necrotic debris.

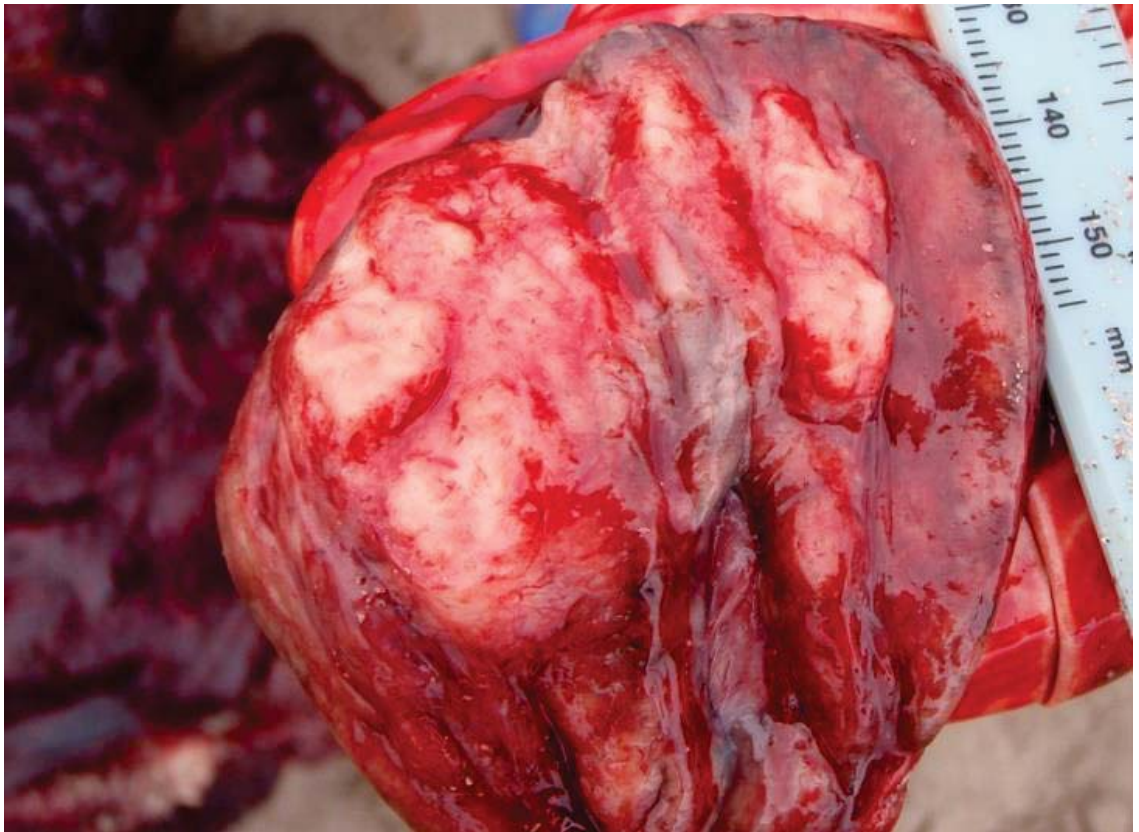

Figure 3.5: An enlarged middle tracheobronchial lymph node from case E09/10-13Ph, showing a cream-coloured nodular mass 20mm in diameter on cut surface.

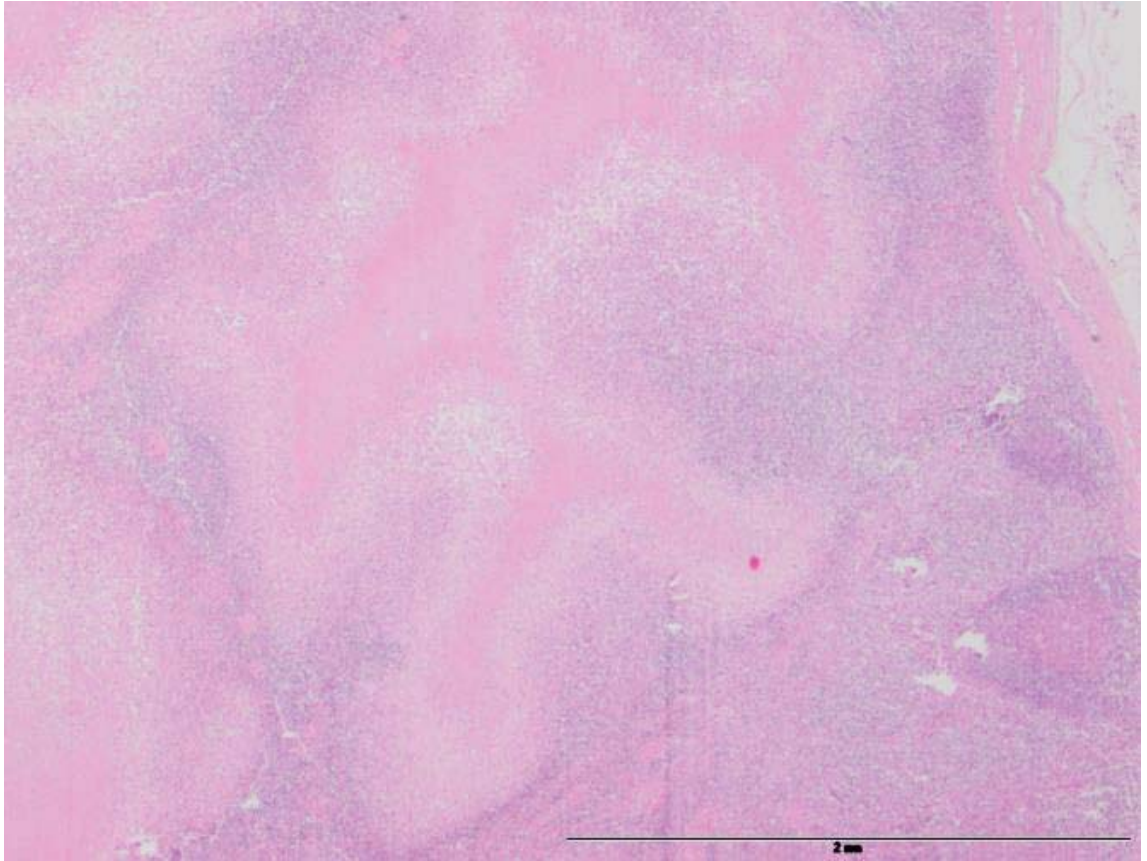


Figure 3.6: Haematoxylin and eosin stain. Scale bar represents 2mm. A lymph node from case E09/10-13Ph showing large well-circumscribed and often coalescing areas of necrosis, surrounded by a rim of granulomatous inflammation with a small number of lymphocytes.

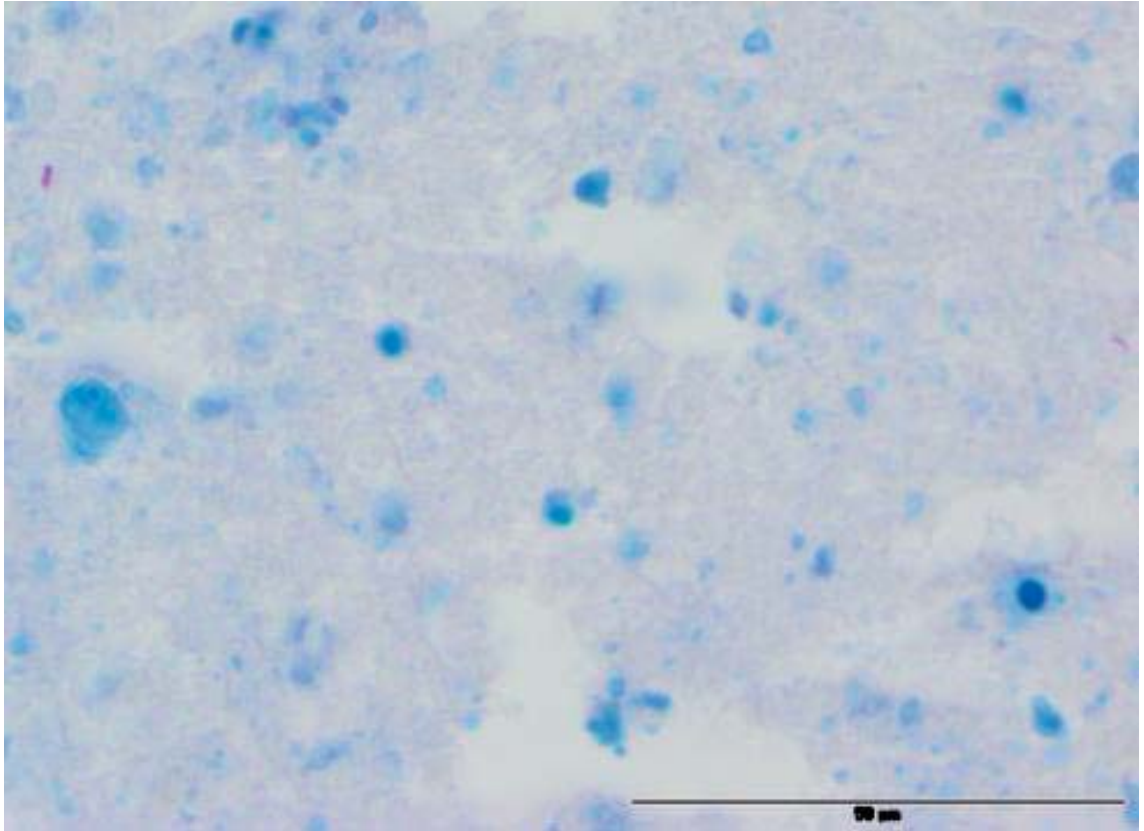


Figure 3.7: Ziehl-Neelsen stain. Scale bar represents 50µm. A lymph node from case E09/10-13Ph showing occasional visible AFOs in granulomas. In this case, AFOs were seen in the cytoplasm of macrophages and in necrotic debris.

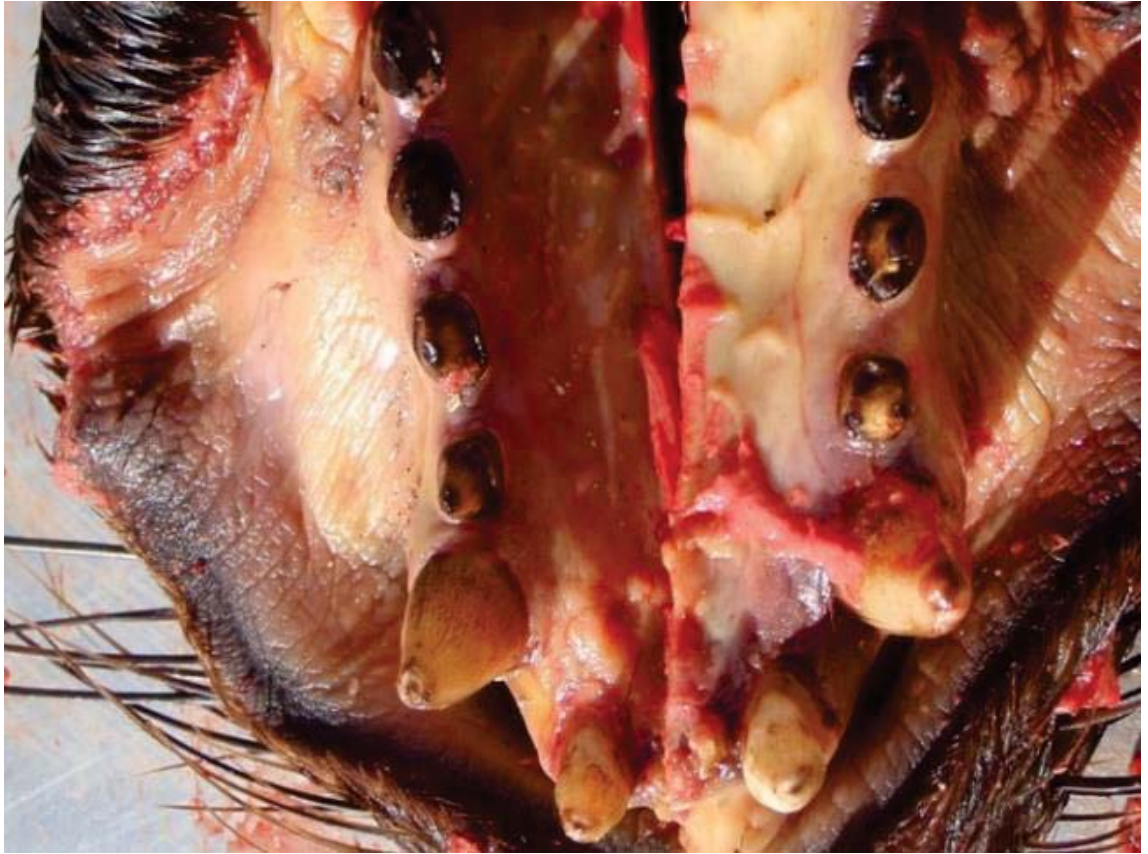


Figure 3.8: Gingival mucosa of case E09/10-17Ph showing severe jaundice.

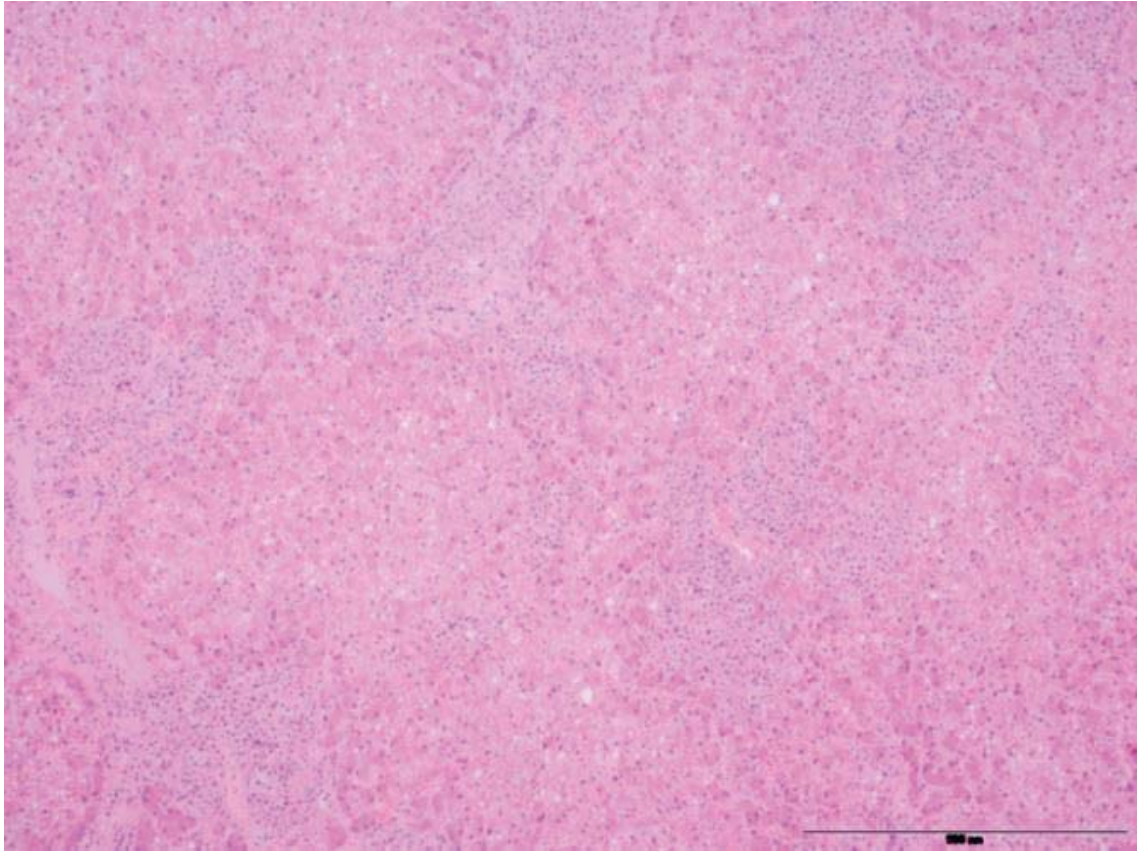


Figure 3.9: Haematoxylin and eosin stain. Scale bar represents 500 μ m. Liver tissue from case E09/10-17Ph showing a severe chronic granulomatous hepatitis. There are multifocal discrete and occasionally coalescing aggregations of macrophages randomly distributed throughout all examined liver sections. Normal hepatic architecture is disrupted.

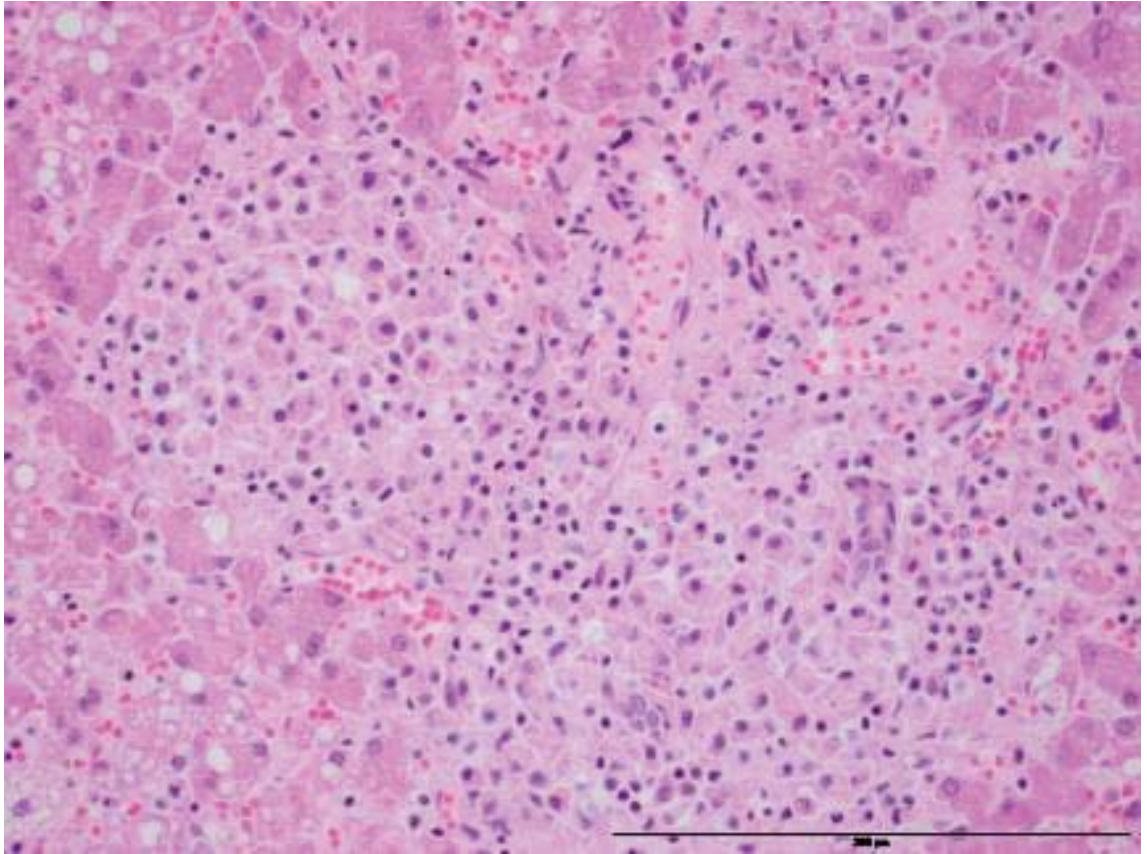


Figure 3.10: Haematoxylin and eosin stain. Scale bar represents 200 μ m. Liver tissue from case E09/10-17Ph showing a discrete aggregation of macrophages with a small number of associated lymphocytes and neutrophils. There is mild degeneration and necrosis of hepatic tissue surrounding the granulomatous inflammation.

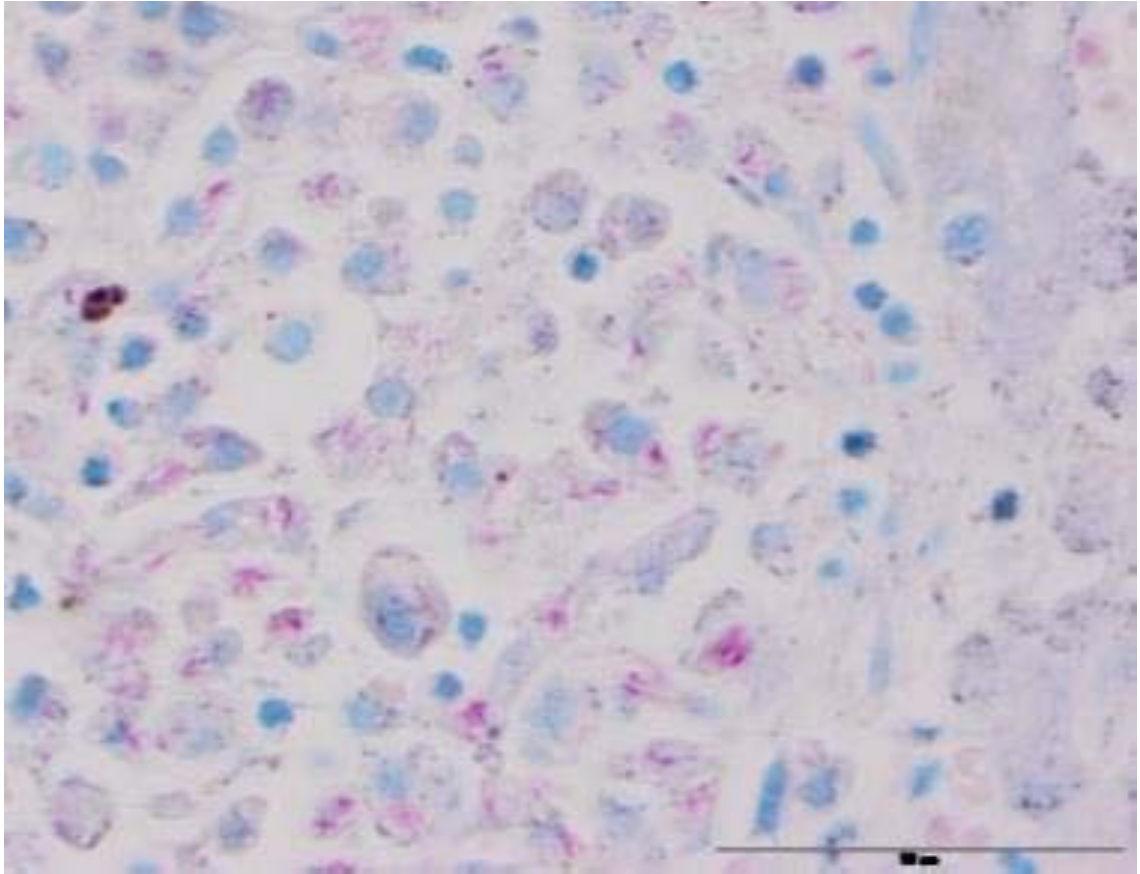


Figure 3.11: Ziehl-Neelsen stain. Scale bar represents 50 μ m. Liver tissue from case E09/10-17Ph showing large numbers of intracellular AFOs within the macrophages of hepatic granulomas.

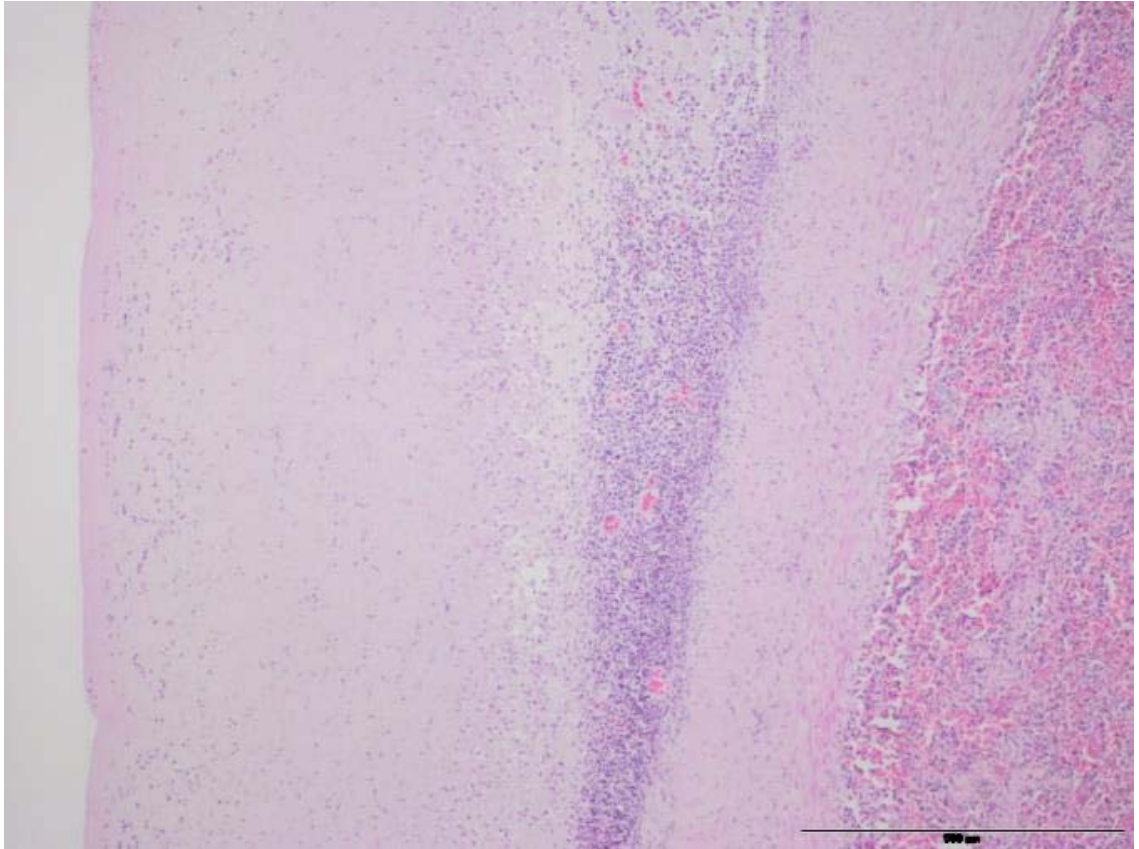


Figure 3.12: Haematoxylin and eosin stain. Scale bar represents 500µm. Peritoneum from case E00/01-42Ph, showing moderate-severe, fibrinous and lymphocytic peritonitis, resulting in marked thickening of the peritoneum.

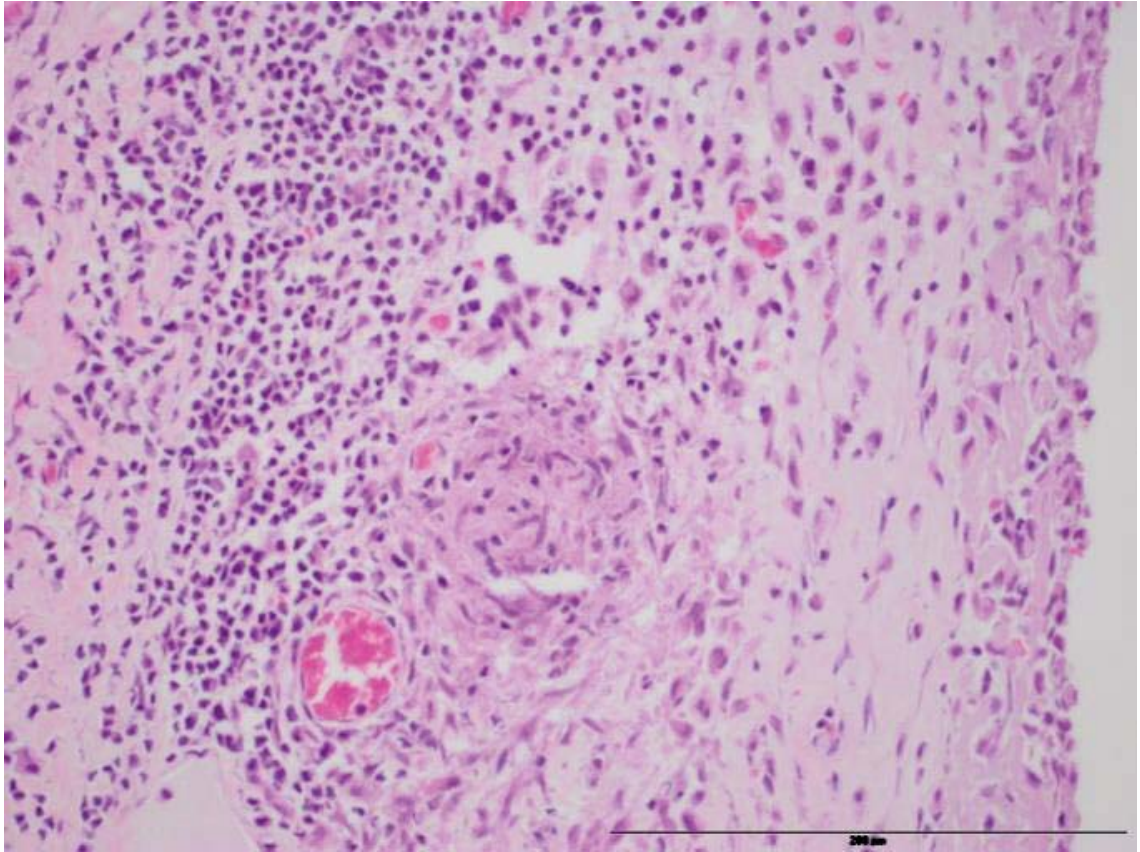


Figure 3.13: Haematoxylin and eosin stain. Scale bar represents 200µm. Peritoneum from case E00/01-42Ph showing a moderate-severe, fibrinous and lymphocytic peritonitis with small multi-focal accumulations of macrophages throughout areas of thickened peritoneum, forming small granulomas.

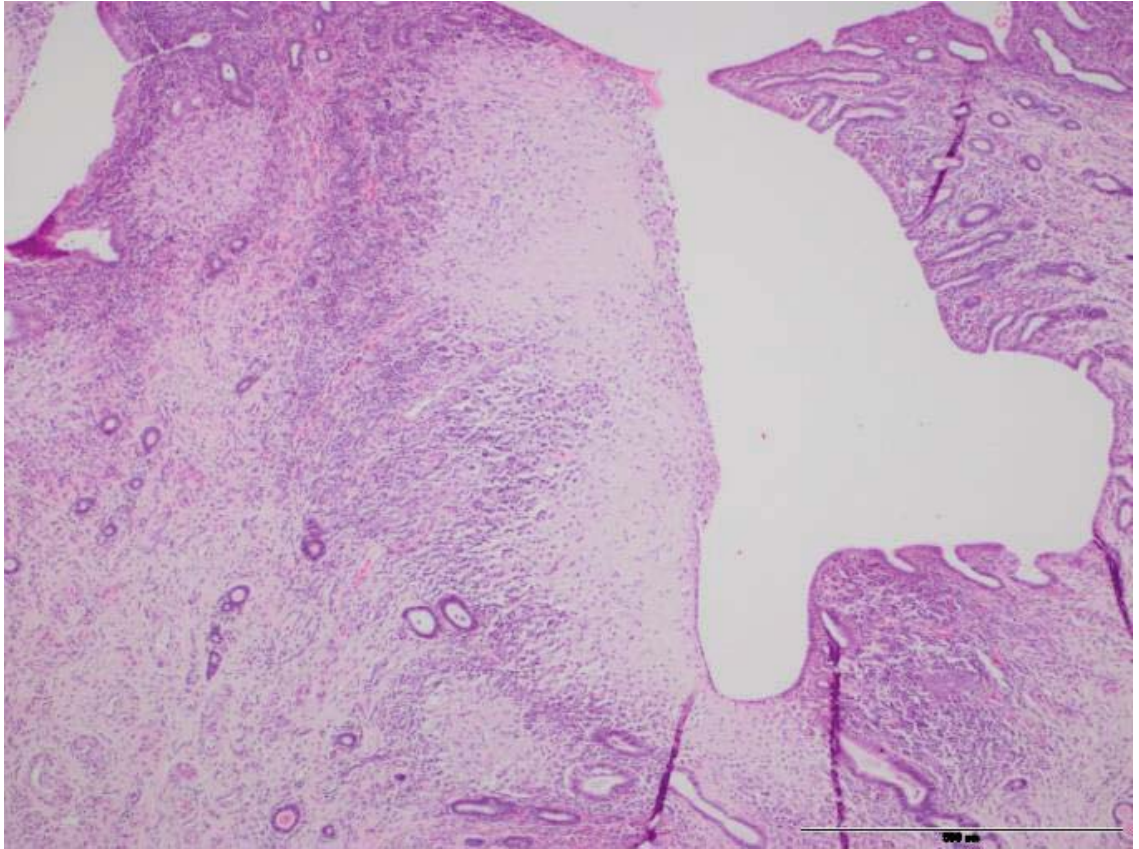


Figure 3.14: Haematoxylin and eosin stain. Scale bar represents 500μm. Uterus from case E00/01-42Ph showing a moderate granulomatous endometritis affecting approximately 30% of the endometrium of the examined section of uterus.

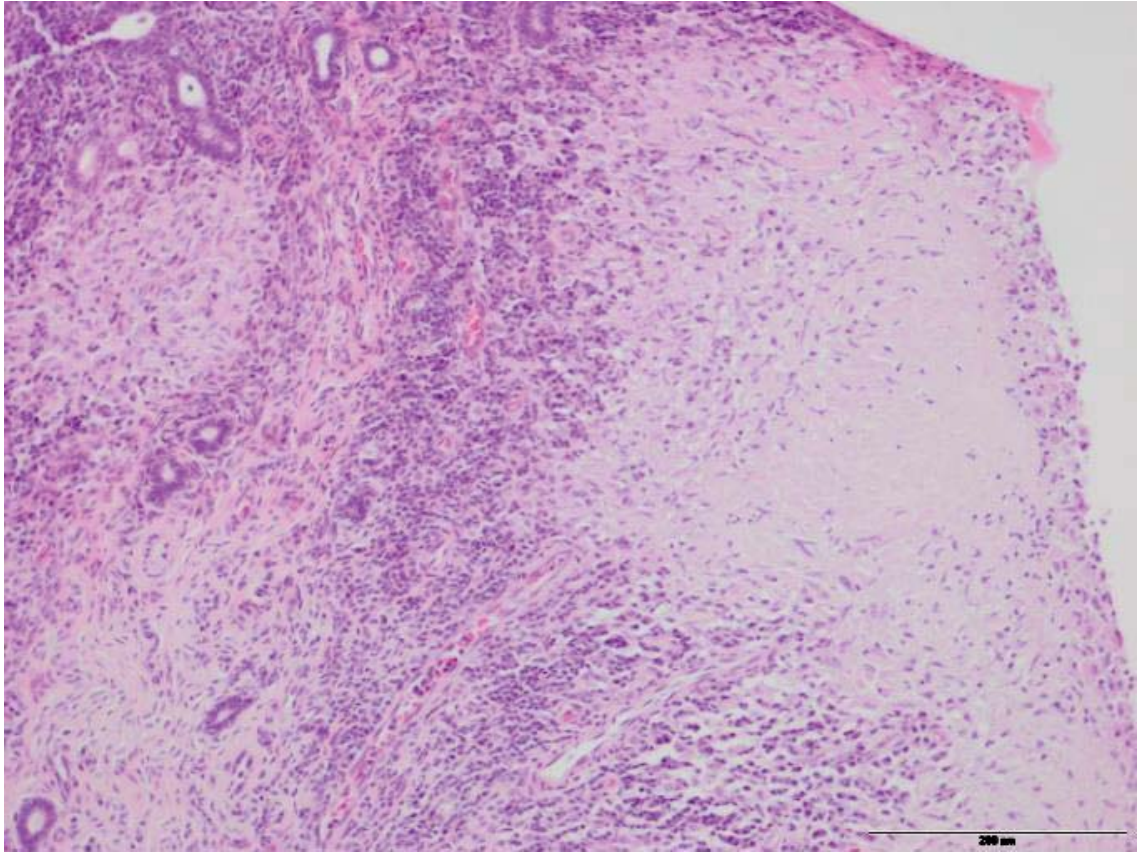


Figure 3.15: Haematoxylin and eosin stain. Scale bar represents 200μm. Uterus from case E00/01-42Ph showing a large discrete accumulation of macrophages within the endometrium, with some lymphocytes and plasma cells in the periphery. The larger of these granulomas in other sections of uterus showed central necrosis and mineralisation.




Figure 3.16: Opened pleural cavity of case E09/10-10Ph showing severe thickening of the pleura and pericardium. The pleura is 2-3mm thick and white, with a cobblestoned surface of soft villous nodules measuring 3-10mm in diameter. There is a large volume of clear yellow-green viscous fluid in the pleural space. There are multiple soft white round bodies on average 5mm in diameter floating free within the pleural effusion.

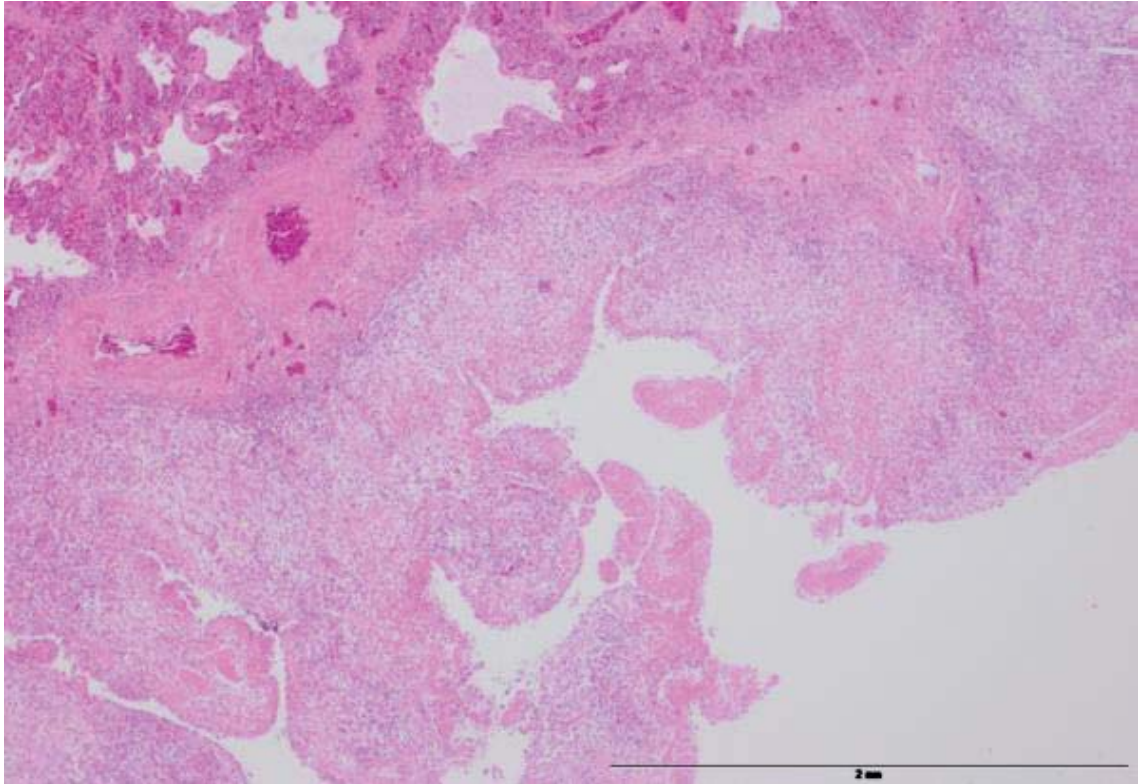


Figure 3.17: Haematoxylin and eosin stain. Scale bar represents 2mm. Lung and pleura from case E09/10-10Ph showing severe chronic granulomatous pleuritis, resulting in a markedly thickened pleura with villous projections. There was a concurrent severe chronic granulomatous pericarditis.

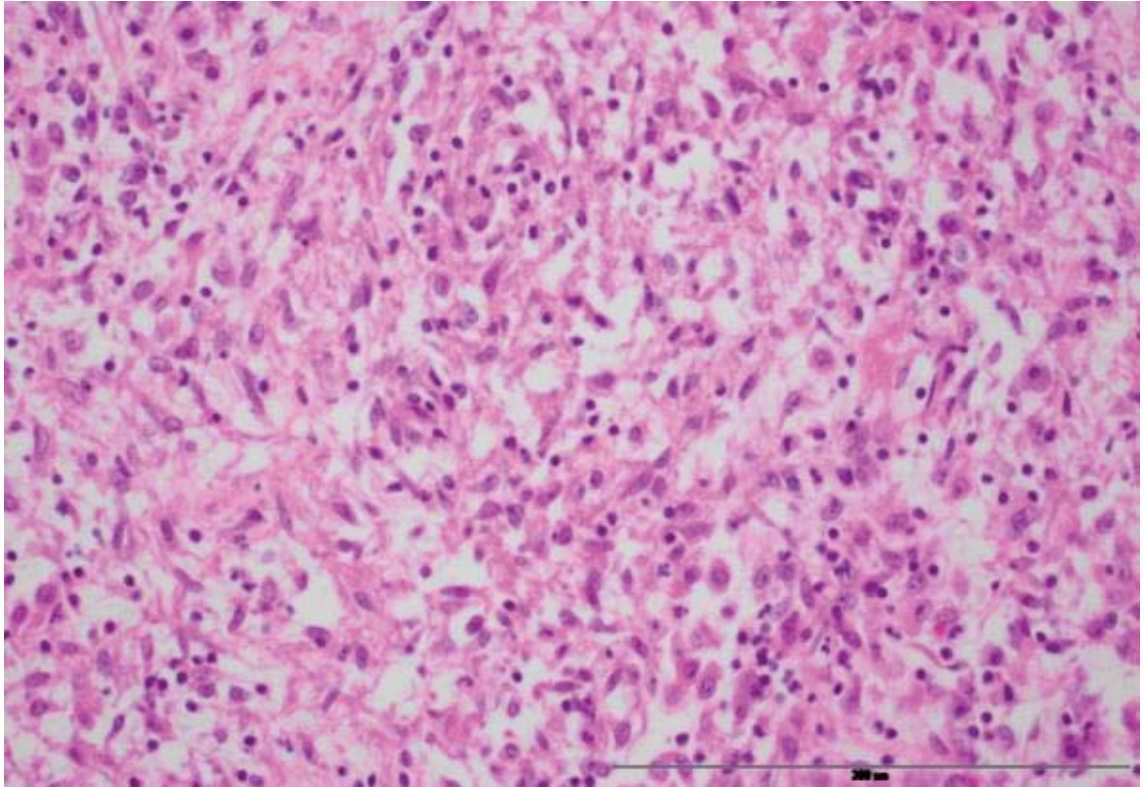


Figure 3.18: Haematoxylin and eosin stain. Scale bar represents 200μm. Pleura from case E09/10-10Ph showing a severe chronic granulomatous pleuritis consisting of a thick layer of macrophages, fibrous tissue and occasional plasma cells and lymphocytes with no distinct organisation, and with small focal areas of necrosis.

3.4 DISCUSSION

The key findings of this chapter are that mycobacteriosis is a common cause of disease and mortality in non-pup NZSLs on Enderby Island, that *M. pinnipedii* was the only mycobacterial species isolated from cases of mycobacteriosis in NZSLs, and that there is only minor strain variation in the isolates of *M. pinnipedii* recovered from animals examined on Enderby Island.

3.4.1 Pathology

The pathological findings in NZSLs infected with *M. pinnipedii* described here show some variation between individuals but are generally similar to those described in pinnipeds infected with *M. pinnipedii* around the world (Boardman et al. 2014; Moser et al. 2008; Kriz et al. 2011; Bernardelli et al. 1996; Forshaw and Phelps 1991; Jurczynski et al. 2012; Woods et al. 1995; Bastida et al. 1999; de Amorim et al. 2014). It seems likely that *M. pinnipedii* infection results in a spectrum of lesions at varying locations and of varying severity depending on factors such as the host immunity and the portal of entry, as for animals with *Mycobacterium bovis* infection (de Lisle et al. 2002; Gavier-Widen et al. 2009).

Lymph node granulomas were the most common finding of mycobacterial infection in this study. The lymph node lesions are similar to those described by other studies, with the exception that no suppuration was seen in this study. The lymph nodes of the thoracic cavity are most commonly reported to show lesions (Kiers et al. 2008; Moser et al. 2008; Kriz et al. 2011; Bastida et al. 1999; Bernardelli et al. 1996; Woods et al. 1995; Forshaw and Phelps 1991; Jurczynski et al. 2012; Boardman et al. 2014), but abdominal and peripheral node lesions are also described (Kiers et al. 2008; Kriz et al. 2011; Forshaw and Phelps 1991; de Amorim et al. 2014; Bernardelli et al. 1996; Woods et al. 1995; Jurczynski et al. 2012). Lymph node granulomas are described as nodules of varying size (Forshaw and Phelps 1991; Jurczynski et al. 2012; Kriz et al. 2011; Bastida et al. 1999; de Amorim et al. 2014) and may be microscopic only (Forshaw and Phelps 1991; Woods et al. 1995). Histologically the lesions generally resemble those found in other organs,

showing granulomatous inflammation with central necrosis of the larger lesions (Moser et al. 2008; Kriz et al. 2011; Jurczynski et al. 2012; de Amorim et al. 2014; Boardman et al. 2014; Kiers et al. 2008; Bastida et al. 1999; Bernardelli et al. 1996; Woods et al. 1995; Forshaw and Phelps 1991). There is occasional visible mineralisation (Kriz et al. 2011; Kiers et al. 2008; Bastida et al. 1999; Bernardelli et al. 1996; Jurczynski et al. 2012; Forshaw and Phelps 1991; de Amorim et al. 2014) and occasional visible AFOs (Kiers et al. 2008; Kriz et al. 2011; Bernardelli et al. 1996; Woods et al. 1995; Forshaw and Phelps 1991; Jurczynski et al. 2012; de Amorim et al. 2014). Suppuration of some lesions is also described (Jurczynski et al. 2012; Woods et al. 1995; Boardman et al. 2014).

Respiratory mycobacteriosis causing lesions such as chronic granulomatous pneumonia, pleuritis and pericarditis was a common presentation of disease due to *M. pinnipedii* in this study. This pattern of infection and the associated gross and histological changes seen in this study are similar to what has been described in other pinniped species with *M. pinnipedii* infection (Moser et al. 2008; Kriz et al. 2011; Bernardelli et al. 1996; Forshaw and Phelps 1991; Jurczynski et al. 2012; Woods et al. 1995; Kiers et al. 2008; Cousins et al. 1993; Bastida et al. 1999; Boardman et al. 2014; de Amorim et al. 2014; Cousins 2008) or infection by mycobacteria within the MTC (Roe et al. 2006; Hunter et al. 1998; Cousins et al. 1993). Lesions of the lung and pleura caused by *M. pinnipedii* infection are common but are variable in their appearance grossly and histologically. A few studies report lesions as being pyogranulomatous (Woods et al. 1995; Jurczynski et al. 2012; Cousins et al. 1993; Boardman et al. 2014) or purulent (Jurczynski et al. 2012) and some reports describe the presence of liquid or inspissated pus in lesions at post mortem examination (Boardman et al. 2014; Woods et al. 1995). These findings were mostly absent in this study, however case E10/11-12Ph describes a purulent exudate on incision of the lungs. Some studies report a concurrent interstitial fibrosis (Cousins et al. 1993), a finding also seen in cases E08/09-24Ph and E10/11-12Ph of this study. A concurrent ulcerative tracheitis (Kiers et al. 2008) or ulcerative bronchitis and tracheitis (Jurczynski et al. 2012) have been reported, which is a lesion that was seen in one of the NZSLs that had tissues examined histologically in this study but in which mycobacterial disease was not able to be confirmed by culture or visualisation of AFOs (E98/99-03Ph). Forshaw 1991 and Boardman 2014 describe pleuritis changes similar to cases E06/07-17Ph and E09/10-10Ph

in this study (Forshaw and Phelps 1991; Boardman et al. 2014) however both studies describe the presence of neutrophils in the pleuritis, and the lesions are described as diffuse pyogranulomatous and granulomatous pleuro- and bronchopneumonia, which was not seen in this study.

It has been hypothesised that *M. pinnipedii* is most commonly spread via inhalation of infectious particles, due to the frequency of primary lesions in the lungs and thorax (Cousins et al. 1993; Kriz et al. 2011). This is also the primary route of transmission for tuberculosis in cattle and humans (Cousins et al. 1993; Cousins 2008). Inhalation of *M. pinnipedii* was likely the route of infection in the four cases of granulomatous bronchopneumonia in this study.

Most of the cases described by the literature have lymph node lesions accompanying granulomatous lesions in the organ systems that they drain, however some cases of single lymph node lesions without any further detectable mycobacterial lesions are described with *M. pinnipedii* infection, predominantly of lymph nodes of the thoracic cavity (Kiers et al. 2008; Jurczynski et al. 2012). Similarly, case E09/10-13Ph and E09/10-14Ph in this study show detectable lesions in thoracic lymph nodes only, most likely indicating the early and subclinical stages of infection with *M. pinnipedii*, after infection via inhalation of infectious particles.

In humans, tuberculous pleuritis is thought to most likely develop as a result of a subpleural caseous tuberculous focus communicating with the pleural space (Abrams and Small 1960). Alternatively, it might also be the result of direct extension of infection from a subdiaphragmatic infectious focus or infected thoracic lymph nodes, or via haematogenous spread (Gopi et al. 2007). There may or may not be associated lung parenchymal lesions in humans with tuberculous pleuritis (Kim et al. 2006; Valdes et al. 1998). None of the published articles reporting pleural lesions in pinnipeds infected with *M. pinnipedii* propose a pathogenesis for these lesions, however it is likely that the pathogenesis of the pleural lesions described in this study is similar to that in humans with tuberculosis. The difference in the pleuritis lesions between case E10/11-12Ph and cases E06/07-17Ph and E09/10-10Ph of this study may be related to the route or timing of spread of infection to the pleura.

Mycobacterial infection of the liver and mesenteric lymph nodes can be the result of infection via the alimentary route (Cousins 2008), which may be the result of the ingestion of infectious material or the swallowing of sputum that has been coughed up from lung lesions (Kriz et al. 2011). The carnivorous ferrets (*Mustelida putorius*), bobcats (*Felis rufus*) and lions (*Panthera leo*) infected with *M. bovis* most commonly show lesions in the mesenteric lymph nodes (de Lisle et al. 2002). Infection via the alimentary route is the most likely portal of entry for case E09/10-17Ph given the lesions in the liver and the hepatic/gastric lymph nodes, however scavenging of most of the lung tissue means that it is not possible to determine if this may have been the result of swallowing infected sputum from primary lung lesions. Haematogenous spread can also not be ruled out in this case. Granulomas in the liver have been described in other pinnipeds with *M. pinnipedii* infection, usually in conjunction with lesions elsewhere in the body or disseminated infection (Kiers et al. 2008; Bernardelli et al. 1996; Forshaw and Phelps 1991).

In humans with *Mycobacterium tuberculosis* infection, infection of the female reproductive tract is usually the result of haematogenous spread from infection at other sites (Bose 2011; Sutherland 1985) and peritoneal involvement may be the result of direct local spread from a salpingitis (Hughes, Carr, and Geraci 1960). A similar disease progression may have occurred in case E00/01-42Ph.

The microscopic appearance of lesions of mycobacterial infection varies depending on several factors, including the host species, host immunity and age of lesions (Gavier-Widen et al. 2009) as well as the mycobacterial species and strain. Carnivores often don't show the "classic tubercle" as seen in cattle with *M. bovis* infection and giant cells may be absent or arranged in a disorganised manner in several wild carnivore species (Gavier-Widen et al. 2009). None of the cases described here had multinucleated giant cells associated with lesions, the lack of which therefore appears to be a feature of *M. pinnipedii* infection in pinnipeds, as shown by other studies also (Boardman et al. 2014; Woods et al. 1995; Forshaw and Phelps 1991; Moser et al. 2008; Jurczynski et al. 2012; Bastida et al. 1999; Bernardelli et al. 1996; Cousins et al. 1993; de Amorim et al. 2014; Kiers et al. 2008; Kriz et al. 2011). One study in the reviewed literature does describe

multinucleated giant cells in tuberculosis lesions in a sea lion, however *M. pinnipedii* was not reported as being isolated from that case (Cousins 2008). Based on the findings in this study and a review of the literature, it appears that the most common histological appearance of lesions caused by *M. pinnipedii* infection in pinnipeds is discrete or coalescing granulomatous inflammation consisting of epithelioid macrophages occasionally surrounded by a thin layer of connective tissue, the centre of which becomes necrotic with increasing size and age, and which may contain areas of mineralisation and occasionally suppuration.

In this study, AFOs were seen in lesions in six out of the nine cases of mycobacterial infection. When seen in lung and lymph node lesions of cases with granulomatous bronchopneumonia they were present in low numbers and not visible in every lesion (Table 3.3). In contrast, in the case with granulomatous hepatitis (E09/10-17Ph) there were large numbers of AFOs visible in the liver and lymph node lesions. Where AFOs were visible, they were generally seen intracellularly in macrophages or within the necrotic debris of lesions, similar to what is described by Woods et al (Woods et al. 1995). Those cases where no AFOs were seen but which subsequently grew *M. pinnipedii* on culture, emphasises the importance of culture as a diagnostic tool. Some studies describe AFOs as being visible in all cases or lesions, sometimes in large numbers (Cousins et al. 1993; Kriz et al. 2011; Bernardelli et al. 1996; Woods et al. 1995; Boardman et al. 2014), whereas others describe them as only being visible in some cases or lesions (de Amorim et al. 2014), with some cases showing no AFOs (Forshaw and Phelps 1991; Kiers et al. 2008; Jurczynski et al. 2012), as seen in this study. In animals with small or early lesions, the lack of visible AFOs possibly relates to the lower bacterial load in these earlier lesions (Kiers et al. 2008). The number of visible AFOs may also be reduced by the use of formalin or xylene in the tissue fixation process (Fukunaga et al. 2002). Mycobacterial lesions are caused by a type IV hypersensitivity reaction from the host's immune system, and the severity of the lesions seen may not correlate well with the levels of mycobacterial antigen present in the lesions (Fukunaga et al. 2002), therefore host immunity and other host effects may play a role in the severity of the lesions relative to the number of visible AFOs.

The number of visible AFOs do not correlate with the VNTR/DR results for the strains isolated in this study. For example, case E09/10-17Ph had large numbers of AFOs visible in lesions, but was of the same strain type as case E06/07-17Ph (no AFOs visible in lesions) and case E09/10-13Ph (low numbers of visible AFOs).

The most common sign of *M. bovis* infection in any host is weight loss (de Lisle et al. 2002). Blubber depth is a measurement of body condition score in the NZSL and Table 3.3 shows that the four individuals with severe bronchopneumonia had thinner blubber layers than the other cases. This might reflect that the cases with bronchopneumonia had experienced a longer and/or more severe disease process than the other presentations of mycobacterial infection in this study.

3.4.2 Strain variation in *Mycobacterium pinnipedii* from NZSLs

The characterisation of *M. pinnipedii* in this study suggests there is only minor strain variation in the isolates recovered from animals examined on Enderby Island. A low level of strain variation within a species of pathogen may indicate a lack of evolutionary selection pressure from either host immune defences or external agencies such as exposure to antibiotics (Homolka et al. 2010). If there is indeed a lack of genetic variation between strains, it may represent the relatively isolated nature of these animals which tends to preclude mixing of pathogen strains or exposure to anthropogenic mediators of bacterial evolution. The low strain variation seen may also have important implications for the immunogenicity of *M. pinnipedii* isolates and variations in virulence and pathology.

Limited strain variation was initially reported in *M. tuberculosis* and *M. bovis* isolates based on sampling a relatively small proportion of the pathogen genome (Gutacker et al. 2002; Fitzgerald and Musser 2001). More recent studies that include whole genome analysis have reported a greater extent and relevance of strain variation within the *M. tuberculosis* complex than was initially reported (Gagneux 2014; Sreenu et al. 2006). While it is possible that the limited strain variation I report here in the Enderby Island NZSLs may reflect the limited gene sequences examined, the technique has been able to show

more diversity in *M. pinnipedii* strains than reported in this study (Price-Carter pers comm).

There does not appear to be an association with the VNTR/DR typing results and the lesions described by this study, including lesion distribution, lesion appearance grossly and histologically or the number of visible acid fast organisms. This sample size of nine animals is very limited, and it is worth mentioning that success in linking *M. tuberculosis* genetic variation in clinical samples with phenotypic traits such as virulence, antimicrobial resistance and immunogenicity has been very slow despite the global research effort expended on this globally significant pathogen of humans (Gagneux 2014). Much more work is needed to understand the significance of the limited strain variation of *M. pinnipedii* seen in NZSLs.

3.4.3 Importance of mycobacteriosis to the NZSL

Mycobacterial infection is a relatively common finding in dead NZSLs sampled during post mortem examination on Enderby Island, with 15% of individuals examined by this study having confirmed mycobacterial infection. When compared to the other infectious causes of mortality as described in the previous chapter, of the 25 cases where infectious conditions were the COD, mycobacterial infection was the infectious agent in six of these cases (24%). This indicates that mycobacterial disease, predominantly as caused by *M. pinnipedii* infection, is an important infectious agent of NZSLs at Enderby Island. However, caution is advised before extrapolating this figure to the wider NZSL population.

This study documents the presence of both clinical and subclinical disease caused by mycobacterial infection in NZSLs. The slow growth of mycobacteria in vivo means that the course of infection can take weeks to years, with infected individuals often remaining clinically normal for the majority of this period (Kissane and Anderson 1985; de Lisle et al. 2002). Fitting with this, all cases diagnosed with mycobacterial infection in this study were over one year of age. Mycobacterial infection of the lungs in humans and animals typically causes a cough and systemic effects such as fever, weight loss and fatigue (de Lisle et al. 2002; Kissane and Anderson 1985; Cousins et al. 1993; Thompson et al. 1993),

and low blubber depths were reported in NZSLs with severe lung disease due to mycobacterial infection in this study. NZSLs that are debilitated from mycobacterial infection are likely more susceptible to predation by the known NZSL predators such as the great white shark (*Carcharodon carcharias*) (Robertson and Chilvers 2011) and leopard seal (Gales 1995), and this may have been a contributing factor to the predation in one case in this study. Similarly, debilitated animals may be more prone to injury from conspecific aggression in the harems due to changes in their movement or behaviour, which may have been a factor in two cases of this study where injuries from conspecific trauma contributed to morbidity and mortality (E10/11-12Ph and E09/10-13Ph respectively).

During the breeding season, NZSLs aggregate in close proximity on beaches and behaviours such as coughing, sneezing, reciprocal face rubbing, vomiting, defaecating, urinating and parturition occur in the harems that form (Marlow 1975). This results in individuals within the harem being exposed to the pathogens that these fluids might contain, including *M. pinnipedii*, particularly in the respiratory secretions. In humans, tuberculosis is a disease that spreads more readily in crowded conditions (Kissane and Anderson 1985) and it is probable that the same is true for the NZSL, with more transmission potentially occurring in the breeding harems than at other times of year when the harems have dispersed.

European badgers (*Meles meles*) can transmit *M. bovis* through fighting and bite wounds and this is thought to be due to pulmonary disease causing contamination of the oral cavity with mycobacterial organisms (Gallagher and Clifton-Hadley 2000). In badgers it is hypothesised that single lesions in peripheral lymph nodes only might be caused by bite wounds into the nearby subcutis or muscle (Gallagher and Clifton-Hadley 2000). While none of the NZSLs in this study or pinnipeds in the reviewed literature had bite wounds infected with *M. pinnipedii* reported, it is possible that some cases of peripheral lymph node lesions (Bernardelli et al. 1996; Jurczynski et al. 2012) might be caused by bite wounds. A case of a grey seal (*Halichoerus grypus*) pup with a wound infected by *M. bovis* has been reported, and the source of the infection was hypothesised to be via a bite wound or via secondary wound contamination (Barnett et al. 2013). In the NZSL, fighting and biting among adult and subadult individuals is seen, particularly as part of

territorial disputes between harem holding males (Marlow 1975) and this is therefore a potential mode of transmission of *M. pinnipedii*.

Another potential route of infection is ingestion of food items containing mycobacteria. The NZSL has been reported to scavenge and possibly predate on New Zealand fur seal pups (Bradshaw, Lalas, and McConkey 1998) and actively predate on antarctic (*Arctocephalus gazella*) and subantarctic (*Arctocephalus tropicalis*) fur seal pups (Robinson, Wynen, and Goldsworthy 1999). *Mycobacterium pinnipedii* has been reported in wild New Zealand fur seals in Australia (Cousins et al. 1993; Cousins et al. 2003), in a wild subantarctic fur seal in Argentina (Bastida et al. 1999; Cousins et al. 2003) and an organism from the MTC has been isolated from a New Zealand fur seal in New Zealand (Hunter et al. 1998). Ingestion of predated or scavenged fur seals infected with *M. pinnipedii* could be a source of infection for NZSLs, and while no pinniped younger than 1 year of age has been reported to show disease or lesions associated with *M. pinnipedii* infection, if scavenging or predation of older fur seals by NZSLs also occurs this could be a route of pathogen transmission between fur seals and the NZSL. Sea bird remains have been found in faecal samples of the NZSL (Childerhouse, Dix, and Gales 2001) and southern skua (*Catharacta lonnbergi*) and giant petrels (*Macronectes giganteus*) feed on NZSL carcasses, indicating that there is potential for pathogen transmission between the NZSL and avian species in both directions. While *M. pinnipedii* infection is yet to be diagnosed in birds, many other mycobacterial species have been shown to infect birds (Shivaprasad and Palmieri 2012). In the post mortem database at IVABS, Massey University a case of mycobacterial infection in a giant petrel has been described, but the organism was not speciated so it is not known if this was a pathogen of avian or pinniped origin. The role of sea birds in the epidemiology of mycobacterial disease in the NZSL population is not yet well understood.

On Enderby Island, New Zealand fur seals and individual southern elephant seals (*Mirounga leonina*) and leopard seals (*Hydrurga leptonyx*) haul out near NZSL aggregations (Marlow 1975), meaning that there is the potential for these species to come in contact with each other or their bodily fluids and thereby potentially transmit pathogens including *M. pinnipedii*. To the author's knowledge *M. pinnipedii* has not been

reported in any phocid species, however *M. bovis* has been reported in a grey seal (Barnett et al. 2013) and it is possible that phocids could be infected by other MTC species also.

The location of the breeding colonies and the overall range of the NZSL have been discussed in the literature review of this thesis. Individual NZSLs have been documented to move between breeding colonies during the breeding season (Baker 1999; Robertson et al. 2006; Geschke and Chilvers 2009) and adult males disperse throughout the known range of the species outside of the breeding season, including the New Zealand mainland (Robertson et al. 2006). Similarly, NZSLs of all age and gender groupings, although predominantly juveniles and males, have been seen hauled out at Otago on the New Zealand mainland, including animals that were tagged originally as pups at the Auckland Island breeding colonies (McConkey, Heinrich et al. 2002; McConkey, McConnell et al. 2002). Because of these documented movements between breeding colonies, it has been suggested that the breeding colonies of the Auckland Islands can be considered as one population with regards to pathogen spread, with individuals potentially carrying pathogens between colonies during the breeding seasons and also throughout the species range (Robertson et al. 2006; Baker 1999; Geschke and Chilvers 2009). Disease research performed at individual breeding colonies may therefore tentatively have applications to the whole population, including the findings of this study of *M. pinnipedii* infections at Enderby Island. The agent *M. pinnipedii* therefore seems likely to be a cause of morbidity and mortality throughout the range of the NZSL, including on the New Zealand mainland, however the true prevalence of this disease is unknown.

Several ante-mortem diagnostic tests have been used for diagnosing *M. pinnipedii* infection in pinnipeds and may be of use in the NZSL, although there are limitations to these tests including that they have not been validated for use in pinniped species and their sensitivity and specificity is largely untested. The intradermal tuberculin test has been used in captive pinnipeds for the detection of *M. pinnipedii*, however this test showed poor correlation with post mortem findings and both false positives and negative results were seen (Forshaw and Phelps 1991; Kiers et al. 2008; Woods et al.

1995). The tuberculin test needs to be standardised for each species with regards to doses and expected responses (de Lisle et al. 2002). Serological tests overall are less effective than intradermal tuberculin testing for detecting mycobacterial infection but may be useful in more advanced disease, when the levels of specific antibody may rise (de Lisle et al. 2002). An ELISA test using bovine and avian purified protein derivative (PPD) as antigens showed good correlation with intradermal skin testing results in a small colony of captive pinnipeds (Cousins 1987) but this test has been described by another publication as having limited success in diagnosing infection when used to opportunistically screen wild-caught Australian pinnipeds (Cousins 2008). Another study describing *M. pinnipedii* ante-mortem diagnostic testing in a colony of captive pinnipeds achieved sensitivities ranging from 58-87.5% using three different serological tests alone or in combination (Jurczynski et al. 2012). The sensitivity and specificity may vary when using pre-existing serological tests in species that they are not specifically designed for. Sputum samples tested using microscopy, PCR and culture had a sensitivity of 28.6% in this same population (Jurczynski et al. 2012). Computed tomography (CT) imaging of sea lions with suspected tuberculosis was useful for detecting calcification in affected lymph nodes, and is therefore a useful diagnostic tool when used in conjunction with other testing (Jurczynski et al. 2012; Jurczynski, Scharpegge et al. 2011) but is not particularly useful as a field method. Higher sensitivities are achieved when applying more than one test for the diagnosis of *M. pinnipedii* infection in pinnipeds (Jurczynski et al. 2012). Antemortem testing is a possible option for future research into *M. pinnipedii* infection in NZSLs, however testing is difficult to perform on a large scale in wild pinniped populations as acquiring a blood sample may require sedation or anaesthesia, and intradermal tuberculin testing requires two sedation or anaesthetic events, one to perform the injections and the other to read the test 48-96 hours later, which is a significant limitation for testing in free-ranging wildlife (de Lisle et al. 2002; Cousins 1987).

The prevalence and other aspects of the epidemiology of *M. pinnipedii* infection in the NZSL population are not known, and further research into these fields is recommended to better understand this pathogen and its effects on the population. During previous field expeditions to the NZSL breeding colonies, samples such as serum, throat swabs

and faecal swabs have been collected as part of various studies into this species' biology, and are currently held frozen at Massey University, Palmerston North. The next steps in researching this disease could involve using the stored serum samples for serological testing, and using the throat and faecal swabs to examine for AFOs and perform mycobacterial cultures, matching these results to any known post mortem results where available. Although testing of sputum samples as described above may have a low sensitivity for detecting mycobacterial infection (Jurczynski et al. 2012), such samples may have some applications for the testing of wild pinnipeds, especially in combination with other tests, and is worth investigating for the NZSL. Further field research is also recommended, and may involve opportunistic sampling and/or testing when animals are captured or anaesthetised for other reasons (ie collection of serum, throat swabs, faecal swabs and performing intradermal tuberculin testing), or potentially capturing and/or anaesthetising animals directly for this purpose, provided that the initial testing has indicated that the available tests are valid.

The documented population decline of the NZSL in recent times has been discussed in the literature review of this thesis. It is unknown at this stage if disease caused by *M. pinnipedii* has contributed in a significant way to this decline, however continued population decline may have some implications for *M. pinnipedii* in the population. In marine mammal species that aggregate annually it has been hypothesised that the probability of disease transmission may decrease very little as the size of a population declines because even as the overall density of animals reduces, susceptible animals come in contact with infected animals during the periods of high density (Harwood and Hall 1990). *Mycobacterium pinnipedii* will likely continue to be transmitted between NZSLs during periods of breeding aggregation and continue to be present in the population even if further population decline occurs.

In wild lions, the susceptibility to infection by *M. bovis* acquired from ingesting infected prey species may increase as a result of inbreeding depression (Trinkel et al. 2011). Inbred New Zealand white rabbits are more susceptible to tuberculosis caused by *M. tuberculosis* than outbred rabbits (Dorman et al. 2004). European wild boars (*Sus scrofa*) heterozygous for a specific gene are more resistant to systemic spread of *M. bovis*

(Naranjo et al. 2008). In California sea lions (*Zalophus californianus*), inbreeding seems to be a factor in susceptibility to gut parasites (Acevedo-Whitehouse et al. 2003). If similar genetic effects are present in the NZSL with regards to disease resistance, and if the NZSL population continues to decline, an increase in the resulting inbreeding may increase the susceptibility of individuals to *M. pinnipedii* infection and therefore increase the morbidity and mortality due to this disease in the population.

The development of mycobacterial vaccines for wildlife is still in its infancy and stems from research into better tuberculosis vaccines for humans (de Lisle et al. 2002). Although the development of such a vaccine requires rigorous testing so that the efficacy can be known and sufficient and so that there is a cost-effective way of delivering the vaccine (de Lisle et al. 2002), there may be a time that such vaccines can also be used in pinnipeds for *M. pinnipedii* infection.

3.4.4 Study limitations

The study population of this research can be described as those non-pup NZSLs that were found dead and had post mortem examinations performed on Enderby Island during the breeding season field expeditions between 1998-2011. Several factors encountered by this study may have affected the results so that these are not an entirely accurate representation of the true prevalence of mycobacterial disease in the study population.

Most marine mammals die at sea and their bodies are not available for examination (Harwood and Hall 1990). Post mortems were performed on dead NZSLs found on land where and when field conditions such as tides, weather and location of the body permitted. Some bodies couldn't be accessed for post mortem examination and were excluded from the study. Within the study set there were some cases that were more autolysed than others, which affected the quality of the gross and histological interpretation. Scavenging of dead NZSLs of all age groups at Enderby Island by southern skua and giant petrels (Marlow 1975) usually begins soon after death, which means that for some cases examined there were organs partially or completely missing, which may have resulted in some lesions going undetected. The most severely

scavenged of the animals diagnosed with mycobacterial disease was case E09/10-17Ph and in this case a diagnosis could still be made, however the full extent of the disease could not be determined.

There were some variations between field seasons in the post mortem protocol and which samples were collected. Some cases did not have full tissue sets taken for histology, some cases that described gross lesions did not sample affected tissues for histology or culture and some cases reported that samples had been taken for bacteriology, but these could not be found in the archives. Not all cases reported examining a range of lymph nodes and in several cases where lymph nodes were sampled they were stored collectively with the other tissues and were not labelled as to their origin, limiting this study's description of lymph node lesions. For future post mortem examinations of NZSLs it is recommended to examine and incise a larger number of lymph nodes around the body as well as storing preserved lymph nodes in such a way that their anatomical origin is able to be identified, to aid in detecting subclinical mycobacterial infection and continue to describe the pathogenesis of the disease.

Three cases in this study had AFOs visible in lesions but no growth of mycobacterial organisms with culture, therefore the species of mycobacterium was not able to be confirmed. Given the host species, the presence of *M. pinnipedii* in other NZSLs and the limited contact of individuals of this species with humans and livestock, it is most likely that the causative agent in these three cases was *M. pinnipedii* also. Other less likely possibilities include *M. bovis* and *M. tuberculosis*, potentially via interactions with livestock, humans, fur seals or wildlife maintenance or spillover hosts for *M. bovis*. Factors such as age of samples, method of storage of samples, the density of organisms within a sample and whether tissue samples or swabs of lesions were cultured could have affected the number of viable organisms present in a sample and therefore the culture result in these cases. A recommendation for future research is to develop a PCR test for *M. pinnipedii* that can be performed on formalin-fixed paraffin-embedded (FFPE) tissues, to avoid the limitations around the requirement for viable mycobacterial organisms in order to perform culture.

Mycobacterial lesions may be very small in size, and difficult to detect at gross post mortem (Gavier-Widen et al. 2009; de Lisle et al. 2002), for example infection can present as a single small lesion (<2mm) in a single lymph node, without lymph node enlargement (Gavier-Widen et al. 2009). The technique of slicing fixed or fresh lung tissue or commonly infected lymph nodes very thinly (3-5mm thickness) has been described in pinnipeds with known exposure to *M. pinnipedii* or wildlife species as part of investigation for *M. bovis* infection, in order to increase the sensitivity for detecting small gross mycobacterial lesions (Gavier-Widen et al. 2009; Forshaw and Phelps 1991). To the author's knowledge this was not performed on any of the cases in this sample set. During the field season 2009/10, in an attempt to increase the sensitivity of gross post mortem for detecting mycobacterial disease, most lymph nodes were incised during post mortem examinations, including all that were enlarged or abnormal. This may be a reason why the only two subclinical cases of this case series (cases E09/10-13Ph and E09/10-14Ph) were detected during this season. This emphasises the importance of incising and finely slicing the lungs and a range of lymph nodes when performing post mortems on NZSLs, in order to detect small and early lesions caused by *M. pinnipedii* infection, and therefore more accurately detect the presence of mycobacterial disease.

The "no visible lesion" (NVL) presentation of *M. bovis* infection is defined as infection without macroscopic lesions at gross post mortem and this presentation occurs in a wide range of wildlife hosts for this pathogen, making diagnosis of infection difficult and resulting in underestimating the total number of infected animals if diagnosis is done via detecting macroscopic lesions followed by culture (Gavier-Widen et al. 2009). Those individuals with NVLs usually have detectable microscopic mycobacterial lesions at histological examination and these lesions may be small granulomas or aggregations of macrophages in a range of different organs, especially the liver, lungs, lymph nodes and tonsils (Gavier-Widen et al. 2009). To aid in the detection of the NVL state, as well as small macroscopic lesions, Gavier-Widen et al recommend careful standardised post mortem examination with particular focus on the organs known to be commonly affected by infection in a particular species, including the fine slicing of the lungs and lymph nodes as previously described and taking particular note of small microscopic lesions on histology (Gavier-Widen et al. 2009). Mycobacterial culture of individual or

pooled lymph nodes from an individual may allow for detection of infection in an animal with NVLs (Gavier-Widen et al. 2009).

Further research is required into whether the NVL state exists commonly in NZSLs with *M. pinnipedii* infection and what the implications are for pathogen shedding and disease spread. It is recommended to use the techniques described above for detection of the NVL state for future post mortem examinations of NZSLs to maximise the chances of diagnosing macroscopic and NVL presentations of *M. pinnipedii* infections in the NZSL and therefore describe this disease further. In this study, five cases had microscopic granulomatous inflammation seen in the form of small hepatic granulomas, with no other findings of mycobacterial disease grossly. There were no visible AFOs in these cases and none of the livers were available for mycobacterial culture so whether *M. pinnipedii* infection was involved remains unknown. Differential diagnoses for these microscopic granulomas include parasite migration tracks and localised bacterial infections.

3.4.5 Implications for livestock health and zoonotic disease

Rare individual cases of *M. pinnipedii* infection have been reported in domestic cattle in New Zealand (Cousins et al. 2003; Loeffler et al. 2014). Loeffler et al (2014) describe seven isolated cases of *M. pinnipedii* infection in cattle where the affected cattle tested positive for tuberculosis at skin testing or slaughter and meat inspection, procedures in place as part of New Zealand's *M. bovis* eradication scheme, but that culture and VNTR/DR testing allowed the isolates to be differentiated from *M. bovis* (Loeffler et al. 2014). All affected farms had direct or indirect access to the ocean and New Zealand fur seals were considered to be the most likely source of infection (Loeffler et al. 2014). This shows that *M. pinnipedii* can spread to cattle and has the potential to interfere with the *M. bovis* eradication scheme, at least on initial testing, and that this pathogen may therefore pose a potential problem for farmers and the eradication scheme. For this reason, the presence of *M. pinnipedii* in the NZSL population may be perceived as an issue by the New Zealand public, especially if recolonization of the mainland continues (Childerhouse and Gales 1998; Beentjes 1989) and approaches farmland. However, cases originating from New Zealand fur seals are rare and sporadic, it is possible to differentiate *M. bovis* and

M. pinnipedii with further testing and no cattle to cattle spread has been documented (Loeffler et al. 2014), so the overall risk to New Zealand agriculture is very low.

Mycobacterium pinnipedii infection has resulted in a case of severe pulmonary disease and several cases of asymptomatic infections in seal trainers and zoo workers working with pinnipeds infected with the organism (Thompson et al. 1993; Cousins et al. 2003; Kiers et al. 2008), highlighting the zoonotic potential of this organism and the potential for serious disease in humans. Individuals working with New Zealand pinnipeds or their tissues should be made aware of the existence of this disease so that precautions can be taken to minimise exposure.

3.5 CONCLUSIONS

The key findings of this study are that mycobacteriosis is a common cause of disease and mortality in non-pup NZSLs on Enderby Island, that *M. pinnipedii* was the only mycobacterial species isolated from cases of mycobacteriosis in NZSLs, and that there is only minor strain variation in the isolates of *M. pinnipedii* recovered from animals examined on Enderby Island. These findings suggest that mycobacteriosis is a stable endemic disease in the NZSL population at Enderby Island, and probably throughout the species' range. The chronic nature of the disease, the colonial nature of NZSL breeding and its inherent prolonged close contact between individuals creates multiple opportunities for transmission and persistence in this isolated population of endangered marine mammals.

GENERAL DISCUSSION

The research aims of this study were to:

- a. Determine the causes of death in individual non-pup NZSLs and thus begin investigations to determine which pathogens are present in the population as well as the importance of other causes of mortality.
- b. Investigate and describe mycobacterial infection in deceased NZSLs, including speciation of mycobacterial isolates cultured.

One of the key findings of this study is that death due to conspecific trauma is a major cause of mortality of NZSLs on Enderby Island during the breeding season, resulting in 34.3% of deaths. Mating related aggression directed from males peripheral to the harems towards females, yearling males and subadult males is the predominant aggression behind this trauma. Mating attempts from peripheral males manifest as pursuing, biting, lunging and using their larger body weight to restrain or mate the other individual, resulting in injuries such as bites, bruising, crushing, smothering, drowning and injuries to the perineal area. Further research is recommended into what factors affect the frequency and severity of mating related aggression in a NZSL breeding colony. Possible factors include sex ratios, which appear to affect the rate of aggression in other species (Le Boeuf and Mesnick 1991; Harris et al. 2010; Hiruki, Gilmartin et al. 1993; Galimberti,

Boitani, and Marzetti 2000), other population demographics and terrain. Knowing the significance of such factors and the rate of deaths due to conspecific aggression at each of the different NZSL breeding colonies will help to assess the importance of this cause of mortality to the population as a whole, and answer questions such as whether a higher frequency of conspecific aggression is a result of a declining population or a skewing sex-ratio, or whether the aggression could be contributing to population decline due to reduced reproductive success or direct mortalities.

Klebsiella pneumoniae, a known cause of epizootics in NZSL pups (Castinel, Duignan et al. 2007; Castinel, Grinberg et al. 2007; Roe et al. 2015), was isolated from two non-pup NZSLs on Enderby Island in this study and contributed to morbidity in one of these cases. It is not known if these isolates of *K. pneumoniae* were of the same clonal lineage as the bacterium that caused the recent epizootic events in pups, nor if the isolates were a hypermucoviscous strain. The role that non-pup NZSLs play in the epidemiology of disease caused by *K. pneumoniae* in pups is not known, and this is an important aspect of the epidemiology to investigate. It would be important to establish whether non-pup NZSLs can carry and shed the organism, therefore acting as a potential source for pups, and at what prevalence it is carried. It would also be important to determine what strains of the organism are involved with any such carrier states found. Performing bacterial culture on faeces from non-pup NZSLs and determining the strains of organisms that are isolated would be a useful preliminary study to gain further insight into the epidemiology of this pathogen. Determining the strain of *K. pneumoniae* isolates detected in non-pup NZSL tissues from future post mortem examinations is also recommended.

Mycobacterium pinnipedii infection causes disease and mortality in non-pup NZSLs, with common presentations being bronchopneumonia, pleuritis, systemic disease and subclinical lymph node infections. Disease attributed to *M. pinnipedii* was found in nine out of the 70 cases examined by this study (12.9%). The prevalence of clinical and subclinical disease due to *M. pinnipedii* in the wider NZSL population is not known, and this would be useful additional information when attempting to determine the extent and severity of this disease. The disease is likely to remain present in the population even if population decline continues, due to annual aggregation for breeding. Several

future investigations in this field have been proposed in chapter 3 of this thesis to better gauge the prevalence of this disease. A preliminary study including testing archived serum and throat swab samples using serology and culture/examination for AFOs respectively is proposed, before considering further antemortem testing of NZSLs. Ongoing post mortem examinations of deceased NZSLs is important, to continue to describe lesions found, to perform cultures and PCR testing for *M. pinnipedii*, and to describe the strains of the isolates grown. The development of a PCR test for *M. pinnipedii* that can be performed on formalin-fixed paraffin-embedded (FFPE) tissue would be useful, to avoid the limitations around the requirement for viable mycobacterial organisms in order to perform culture, especially for tissue samples collected in the field or stored for long periods.

There is the potential for misinformation around the presence of *M. pinnipedii* infection in NZSLs to result in persecution of NZSLs by the public, if they are perceived to be a threat to the TB-free status of farms or to public health. Proactive dissemination of information to communities in areas where potential conflict may arise is important, for example in the areas where there is currently apparent NZSL recolonisation of the mainland, and around Stewart Island/Rakiura. It is especially important to highlight to farming communities that it is possible to differentiate between *M. pinnipedii* and *M. bovis* infections in cattle and that no cow-to-cow spread of *M. pinnipedii* has been documented (Loeffler et al. 2014) and therefore that the risk to a farm's TB-free status if marine mammals such as NZSLs and NZFSs are nearby or on the property is minimal. Similarly, education of the community in general is important, and the risk of *M. pinnipedii* infection in NZSLs may be used as an example to help reinforce the Department of Conservation guideline to the public to keep at least 20m between themselves (and their dogs) and NZSLs (Department of Conservation 2016). Improved adherence to this recommendation is beneficial to both the public, their dogs and NZSLs.

The presence of *M. pinnipedii* in the NZSL population also has implications for researchers, especially those working with potentially infected tissues at post mortem examination or antemortem testing, given the zoonotic potential of this disease. The Institute of Veterinary and Biomedical Sciences (IVABS) at Massey University,

Palmerston North, New Zealand has a General Biosecurity Standard Operating Procedure and in the 2014 version of this SOP the recommendations for minimising the risk to personnel when performing post mortem examinations in the presence of *Mycobacterium bovis* or *M. tuberculosis* include wearing a face mask, double-gloving, thorough hand washing, disinfection of equipment and tables, careful waste disposal and careful laundering of lab-coats/overalls (Institute of Veterinary and Biomedical Sciences 2014). The author recommends following a similar safety protocol when performing post mortem examinations or antemortem testing for *M. pinnipedii* infection on any non-pup NZSL. Field post mortem examinations sometimes allow for the use of a stainless steel table or similar surface for the examination of smaller animals and such surfaces could be cleaned using the protocol described above, however larger animals are examined on the ground due to their size and weight, and disinfection of such a natural surface may not be possible or practical in a field setting. "TriGene" is a quaternary ammonium compound product available in New Zealand which claims to be effective against *M. bovis*, *M. avium*, *M. terrae* and *M. fortuitum* (Ethical Agents International Ltd 2014) and therefore is an appropriate disinfectant to use for equipment and surfaces after a NZSL post mortem examination, to be used according to label directions regarding general use, dilutions and contact times, and after prior removal of organic material from equipment and surfaces. Alternatively, other disinfectants with a claim against *Mycobacterium* species could be used, using the specifications and dilutions as recommended by the product.

In the New Zealand Ministry of Health's "Guidelines for Tuberculosis Control in New Zealand 2010", a recommendation is made for staff that are working with patients infected with *M. tuberculosis* to wear particulate respirators (Ministry of Health 2010), and their use could be considered for staff performing post mortem examinations on NZSLs with mycobacterial infections, especially if advanced or pulmonary disease is suspected. Inhalation of aerosols is considered the most likely route of transmission in cases of *M. pinnipedii* transmission from infected pinnipeds to humans (Thompson et al. 1993; Cousins et al. 2003; Kiers et al. 2008). As a result, the use of particulate respirators is also essential for humans working with captive pinnipeds if infection with *M. pinnipedii* is confirmed or suspected within the group, and should also be considered for

researchers working in close proximity with wild live NZSLs. Another consideration for the health and safety of staff and researchers would be to consider regular screening for mycobacterial infection in those staff that are regularly performing work with the tissues of NZSLs infected with *M. pinnipedii* or with live NZSLs.

Experimental inoculation of some avian species with *Mycobacterium tuberculosis* complex (MTC) organisms results in no disease nor shedding of the organism (Fitzgerald et al. 2005; Clarke et al. 2006), whereas other species may shed the organism (Fitzgerald et al. 2003) or develop lesions (Butler et al. 2001; Fitzgerald et al. 2003; Ledwon et al. 2008). Cases of infection by MTC organisms is also described for several bird species (Hoop 2002; Hoop, Bottger, and Pfyffer 1996; Steinmetz et al. 2006; Sanchez et al. 2016). It is not known whether scavenging birds such as southern skuas (*Catharacta lonnbergi*) and giant petrels (*Macronectes giganteus*) shed or develop disease due to *M. pinnipedii* infection if infected NZSL tissues are ingested. It is also not known how well *M. pinnipedii* survives in soil were a body to be buried after post mortem examination. Further research into these aspects must be considered, so that it can be advised how best to dispose of a NZSL carcass infected with *M. pinnipedii* after post mortem examination in the field, and understand these aspects of the epidemiology of the disease. In the interim, performing post mortem examinations of non-pup NZSLs well away from the harems and burial of the remains seems likely to be the technique that will best minimise contamination of the harem areas and limit disease spread. Therefore this approach is recommended, field conditions permitting. On the mainland, it would be recommended that a body is transported to a veterinary post mortem facility and that the examination is performed there, to prevent infectious material from contaminating public areas or areas that livestock can access. Where logistical constraints make such transport impossible, post mortem examination should be conducted on site with minimum personnel using personal protective equipment (PPE), followed by burial of the body above the high tide line.

Bacterial and parasitic infections were a major cause of mortality of NZSLs in this study, resulting in the death of 25 cases (35.7%). No pathogens known to cause epizootics in other pinniped species were identified, nor was a pathogen similar to that found during

the 1997/98 epizootic identified. Ongoing post mortem examinations of deceased NZSLs and the documentation of lesions and pathogens found is recommended, to allow monitoring for potential causes of epizootics over time. The findings of this study suggest that the Enderby Island NZSL population may be naïve to some pathogens that cause significant disease in other pinniped species, which is a potential risk to the population should such a pathogen be introduced. The causative agent of the 1997/98 epizootic remains unknown, and the chance of a similar event reoccurring is therefore also unknown.

The New Zealand sea lion is endangered and the population is in decline. This study has highlighted that *M. pinnipedii* causes morbidity and mortality in this species and that *K. pneumoniae*, a cause of disease epizootics in pups, is present and can cause morbidity in non-pup NZSLs. Conspecific aggression also causes significant morbidity and mortality among the harems during the breeding season. All three of these findings will likely cause persistent morbidity and mortality despite the population decline due to annual gathering of individuals during the breeding season, and their effects on a smaller population or one with a different sex-ratio may be more severe than currently. Even if disease and trauma would not on their own result in population decline in this species, when applied to a population that is under stress from other natural and anthropogenic factors they may well contribute to population decline. Therefore, further research is required into the effects of disease and trauma on the NZSL population, to allow for management planning to minimise their effects where possible.

APPENDIX 1

POST MORTEM, HISTOLOGY AND BACTERIOLOGY FINDINGS

| Field Season | ID number | Sex/Age | Cause of Death | Gross Post Mortem Findings | Histology Findings | Additional Findings | Bacteria Isolated |
|--------------|-------------|-----------------|----------------|-----------------------------------------------------------------------------------------------------------------------------------------------------------------------------------------------------------------------------------|---------------------------------------|------------------------------------------------------------------------------------------------|---------------------------------------------------------------------------------------------------------------------------------------------------------------------------------------------------------------------------------------------------------------------------------------------------------------------------------------------------------------------------------------------------------------------------------------------------------------------------------------------------------------------------------------------------------------------------------------------------------------------------------------------------------------------------------------------------------------------------------------------------------------------------------------------------------------------------------------------|
| 1998/99 | E98/99-01Ph | Yearling Female | Infectious | <p>Abscess (22 x 12cm) in subcutis over right shoulder with cellulitis, myositis and steatitis.</p> <p>Cellulitis extending down the right forelimb to the carpus.</p> <p>Multifocal 3 x 3cm lung abscesses in the left lung.</p> | Severe suppurative embolic pneumonia. | <p>Incidental finding of a light growth of <i>Klebsiella oxytoca</i> grown from the liver.</p> | <p>Liver:</p> <ul style="list-style-type: none"> - Heavy growth of an alpha-haemolytic <i>Streptococcus</i> sp. - Light growth of <i>Klebsiella oxytoca</i> - Light growth of <i>Escherichia coli</i> <p>Abscess:</p> <ul style="list-style-type: none"> - Moderate growth of a non-haemolytic <i>Streptococcus</i> sp. - Moderate growth of <i>Staphylococcus aureus</i> - Moderate growth of <i>Escherichia coli</i> - Light Mixed Growth <p>Lung:</p> <ul style="list-style-type: none"> - Moderate growth of a non-haemolytic <i>Streptococcus</i> sp. - Moderate growth of <i>Staphylococcus aureus</i> - Moderate growth of <i>Escherichia coli</i> - Light growth of a beta-haemolytic <i>Streptococcus</i> sp. |

| Field Season | ID number | Sex/Age | Cause of Death | Gross Post Mortem Findings | Histology Findings | Additional Findings | Bacteria Isolated |
|--------------|-------------|--------------|--------------------|----------------------------------------------------------------------------------------------------------------------------------------------------------------------------------------------------------------------------|---------------------------------|----------------------------------------------------------------------------|------------------------------------|
| 1998/99 | E98/99-02Ph | Adult Female | Conspecific trauma | <p>Sea lion bites to neck.</p> <p>Extensive bruising of head and neck.</p> <p>Fractured rib 7 and 8 on right side.</p> <p>Traumatic abdominal hernia at the xiphoid, with exteriorisation of loops of small intestine.</p> | No samples taken for histology. | Cestode larval cysts in the subcutaneous tissues over the ventral abdomen. | No samples taken for bacteriology. |

| Field Season | ID number | Sex/Age | Cause of Death | Gross Post Mortem Findings | Histology Findings | Additional Findings | Bacteria Isolated |
|--------------|-------------|--------------|----------------|--------------------------------------------------------------------------------------------------------------------------------|-----------------------------------------------------------------------------------------------------------------------------------------------------------------------------------------------------------------------------------------------------------------------------------------------------------------------------------------------------------------------------------------------------------------------------------------------------------------------------------------------------------------------------------------------------------------------|------------------------------------------------------------------------------------------------------------------------------------------------------|--------------------------------------------------------------------------------------------------------------------------------------------------------------------------------------------------------------------------------------------------------------------------------------------------------------------------------------------------------------------------|
| 1998/99 | E98/99-03Ph | Adult Female | Infectious | Small erosions of the mucosa of the right bronchus. Small cyst-like structures on the ventral surface of the left lung. | Moderate subacute/chronic embolic interstitial bacterial pneumonia with granuloma formation and mild pleuritis. No visible AFOs. Localised, moderate-severe chronic (lymphocytic/plasmacytic) erosive tracheitis and associated chondritis. Some granulomas contained dead lung worms, for which the histological appearance was more suggestive of bacterial (possibly mycobacterial) infection but for which an inflammatory response to parasites could not be ruled out. Some large germinal centres in spleen with necrotic centres. | Cestode larval cysts in the subcutaneous tissues over the ventral abdomen. Worms in stomach on gross examination. Late term pregnancy. | Lung, liver and spleen were negative on mycobacterial culture. Liver: - Scant growth of a beta-haemolytic <i>Streptococcus</i> sp. - Scant mixed growth Lung: No bacteria isolated Spleen: - Moderate growth of an alpha-haemolytic <i>Streptococcus</i> sp. - Moderate growth of <i>Pasteurella</i> species - Light Mixed Growth |

| Field Season | ID number | Sex/Age | Cause of Death | Gross Post Mortem Findings | Histology Findings | Additional Findings | Bacteria Isolated |
|--------------|-------------|---------------|----------------|---------------------------------------------------------------------------------------------------------------------------|----------------------------------------|----------------------------------------------------------------------------------------------------------------------------------------------------------------------------------------------------------------------------------------------------------------------------------------------|--------------------------------------------------------------------------------------------------------------------------------------------------------------------------------------------------------------------------------------------------------------------------------------------------------------------------------------------------------|
| 1999/00 | E99/00-06Ph | Yearling Male | Unknown | Emaciated. No other abnormalities detected on gross examination. Adult male guarding body. | No significant abnormalities detected. | Significantly limited histology set. Scavenging of the entire small and large intestine aboral to the duodenum. | No bacterial cultures performed. |
| 1999/00 | E99/00-18Ph | Adult Female | Unknown | Nodular appearance to the gastric and/or mesenteric lymph nodes. No other abnormalities detected on gross examination. | No significant abnormalities detected. | Missing right pelvic flipper from probable shark attack. Amputation site healed completely. Cestode larval cysts in the subcutaneous tissues over the ventral abdomen. Intestinal parasites seen on histology. Significant widespread autolysis and putrefaction seen on histology. | Mesenteric lymph node was negative on mycobacterial culture. Mesenteric Lymph Node: - Moderate growth of <i>Enterobacter</i> species - Light growth of a beta-haemolytic <i>Streptococcus</i> sp. - Light growth of an alpha-haemolytic <i>Streptococcus</i> sp. - Light growth of <i>Staphylococcus aureus</i> - Light mixed Growth |

| Field Season | ID number | Sex/Age | Cause of Death | Gross Post Mortem Findings | Histology Findings | Additional Findings | Bacteria Isolated |
|--------------|-------------|--------------|----------------|-----------------------------------------------------------------------------------------|----------------------------------------|------------------------------------------------------------------------------------------------------------------------------------------------------------------------------------------------------------------------------------------------------------------------------------------------------------------------------------------------------------------------------------------------------------------------------------------------------------------------------------------------------------------------------------------------------------------------------------------------------------------------------------------|----------------------------------------------------------------------------------------------------------------------------------------------------------------|
| 2000/01 | E00/01-15Ph | Adult Female | Unknown | Adult male guarding body. Enlargement of right axillary lymph node. Thyroid cyst. | No significant abnormalities detected. | <p>Microscopic granuloma in the hepatic parenchyma, cut out of section when ZN stain attempted. Liver not available for culture.</p> <p>Significant widespread autolysis.</p> <p>Cestode larval cysts in the subcutaneous tissues over the ventral abdomen.</p> <p>High burden of roundworms in oesophagus and stomach on gross examination. Parasites seen on histology of the GIT.</p> <p>Foreign body within left kidney, spine-like, 8 x 0.2cm. No apparent associated trauma or inflammation.</p> <p>Scavenging of the lower intestinal tract and lower reproductive tract.</p> <p>Mild multifocal subacute localised mastitis.</p> | <p>Unidentified tissue was negative on mycobacterial culture.</p> <p>Unidentified tissue: - Heavy growth of a beta-haemolytic <i>Streptococcus</i> sp.</p> |

| Field Season | ID number | Sex/Age | Cause of Death | Gross Post Mortem Findings | Histology Findings | Additional Findings | Bacteria Isolated |
|--------------|-------------|--------------|--------------------|--------------------------------------------------------------------------------------------------------------------------------------------------------------------------------------------------------------------------------------------------------------------------------------------------------------|-----------------------------------------------------------------------------------------------------------------------------------------------------------------------|--------------------------------------------------------------------------------------------------------------------------------------------------------------------|-----------------------------------------------------------------------------------------------------------------------------------------------------------------------------------------------------------------------------------------------------------------------------------------------------------------------------------------------------------------------------------------------------------------------------------------------------------------------------------------------------------------------------------------------------------------------------------------------------------------|
| 2000/01 | E00/01-16Ph | Adult Female | Conspecific trauma | <p>Adult male guarding body.</p> <p>Sea lion bites to neck and pectoral flippers.</p> <p>Extensive bruising of the tissues of the head.</p> <p>The right ear was partially ripped off.</p> <p>Thyroid cyst.</p> <p>Multiple small yellow nodules on cut surface of mediastinal lymph node (0.3 x 0.3cm).</p> | <p>No significant abnormalities detected.</p> <p>Granulomatous lymphadenitis of two lymph nodes with multiple small granulomas through the node. No visible AFOs.</p> | <p>Cestode larval cysts in the subcutaneous tissues over the ventral abdomen.</p> <p>High burden of roundworms in oesophagus and stomach on gross examination.</p> | <p>Two pieces of lymph node were negative on mycobacterial culture.</p> <p>Lymph Node 1:</p> <ul style="list-style-type: none"> - Light growth of a beta-haemolytic <i>Streptococcus</i> sp. - Light growth of an alpha-haemolytic <i>Streptococcus</i> sp. - Light growth of a non-haemolytic <i>Streptococcus</i> sp. <p>Lymph Node 2:</p> <ul style="list-style-type: none"> - Scant growth of an alpha-haemolytic <i>Streptococcus</i> sp. - Scant growth of mixed coliforms - Scant growth of a beta-haemolytic <i>Streptococcus</i> sp. |

| Field Season | ID number | Sex/Age | Cause of Death | Gross Post Mortem Findings | Histology Findings | Additional Findings | Bacteria Isolated |
|--------------|-------------|--------------|----------------|-------------------------------------------------------------------------------------------------------------------------------------------------------------------------------------------------------------------------------------------------------------------------------------|-------------------------------------------------------------------------------------------------------------------------------------------------------------------------------------------------------------------------------------------------------------------------------------------------------------------------------------------------------------------------------------------------------------------|-------------------------------------------------------------------------------------------------------------|----------------------------------------------------------------------------------------------------------------------------------------------|
| 2000/01 | E00/01-42Ph | Adult Female | Infectious | Consolidation of the left lung and the caudal and medial lobes of the right lung, with caseous foci. Pleural effusion of 1L of clear fluid. Enlargement of the mediastinal and bronchial lymph nodes. Fibrinous tags over the parietal peritoneum. Poor body condition. | Severe chronic granulomatous bronchopneumonia. Central necrosis and mineralisation of lung granulomas. Granulomatous lymphadenitis of unspecified nodes. Occasional visible AFOs in the lung and lymph node lesions. Moderate-severe, fibrinous and lymphocytic peritonitis with granuloma formation. Moderate granulomatous endometritis. A single large granuloma within the ovarian parenchyma. | Cestode larval cysts in the subcutaneous tissues over the ventral abdomen. Lung worms seen on histology. | A sample of thoracic fluid was negative on mycobacterial culture. A sample of thoracic fluid gave no growth on aerobic bacterial culture. |

| Field Season | ID number | Sex/Age | Cause of Death | Gross Post Mortem Findings | Histology Findings | Additional Findings | Bacteria Isolated |
|--------------|-------------|---------------|--------------------|------------------------------------------------------------------------------------------------------------------------------------------------------------------------------------------------------------------------------------------|---------------------------------------------------------------------------------------------------------------------------------------------------------------------------------------------------------------------------------------------------------------------------------------------------------------|------------------------------------------------------------------------------------------------------------------------------------------------------------------------------------------------------------------------------------------------------------|--------------------------------------------------------------------------------|
| 2000/01 | E00/01-53Ph | Subadult Male | Infectious | Large healing shark bite wound around the prepuce, with associated balanoposthitis and cystitis. Bilateral ureteral dilation. | Balanoposthitis, severe suppurative cellulitis and scar tissue formation associated with the shark bite wound. Severe cystitis and urethritis, presumably an ascending infection from the cellulitis, resulting in urethral stenosis and obstruction. Severe subacute ascending pyelonephritis. | High burden of roundworms in oesophagus and stomach on gross examination. | No bacterial cultures performed. |
| 2001/02 | E01/02-01Ph | Adult Female | Conspecific trauma | The anus and genital area were torn and bleeding on the left side. Sea lion bite to right hind flipper causing a laceration. Sand in airways, a small amount accumulated immediately cranial to the bronchial bifurcation. | No significant abnormalities detected. Congestion and haemorrhage of trachea. Thyroid cyst. | Cestode larval cysts in the subcutaneous tissues over the ventral abdomen. Roundworms in stomach and "small 3mm long parasites" in small intestine on gross examination. Lung worms in lung parenchyma on histology, some larvae in airways. | Swab of lymph: - Heavy growth of a beta-haemolytic <i>Streptococcus</i> sp. |

| Field Season | ID number | Sex/Age | Cause of Death | Gross Post Mortem Findings | Histology Findings | Additional Findings | Bacteria Isolated |
|--------------|-------------|--------------|----------------|-----------------------------------------------------------------------------------------------------------------|--------------------------------------------------------------------------------------------------------------------------------------------------------------------|---------------------------------------------------------------------------------------------------------------------------------------------------------------------------------------------------------------------------------------------------------------|------------------------------------|
| 2001/02 | E01/02-03Ph | Adult Female | Unknown | Adult male guarding body. Small skua-induced tear in perineal area. Superficial sea lion bites to dorsum. | No significant abnormalities detected. One sarcocyst observed within a skeletal myocyte and a cardiac myocyte, with no associated inflammatory reaction. | Roundworms in stomach and oesophagus on gross examination. Cestode larval cysts in the subcutaneous tissues over the ventral abdomen. Three microscopic granulomas in the hepatic parenchyma. No visible AFOs. Liver not available for culture. | No samples taken for bacteriology. |
| 2001/02 | E01/02-07Ph | Adult Female | Unknown | Two holes into the abdominal cavity with intestines protruding through. Torn rectum caused by birds. | No significant abnormalities detected. Chronic mild mastitis. | Significantly limited histology set. Most of intestines scavenged. Roundworms in stomach and oesophagus on gross examination. Occasional lung worm seen on histology with little inflammatory reaction. | No samples taken for bacteriology. |
| 2001/02 | E01/02-39Ph | Adult Female | Unknown | | Fibrin clots in lung capillaries on histology - consistent with disseminated intravascular coagulation (DIC), but the cause of this was not able to be determined. | Microscopic granuloma in the hepatic parenchyma, cut out of section when ZN stain attempted. Liver not available for culture. Occasional lung worm seen on histology. | No samples taken for bacteriology. |

| Field Season | ID number | Sex/Age | Cause of Death | Gross Post Mortem Findings | Histology Findings | Additional Findings | Bacteria Isolated |
|--------------|-------------|---------------|----------------|----------------------------------------------------------------------------------------------------------------------------------------------------------------------------------------------------------------------------------------------------------------------------------------------------------------------------------------------------------------------------|----------------------------------------|----------------------------------------------------------------------------------------------------------------------------------------------------------------------------------------------------------------------------------------------------------------------------------------------------------|--------------------------------------------------------------|
| 2001/02 | E01/02-53Ph | Adult Male | Unknown | | No significant abnormalities detected. | Cestode larval cysts in the subcutaneous tissues over the ventral abdomen. Parasites reported in lower trachea on gross examination. Occasional microscopic granulomas in the hepatic parenchyma. No visible AFOs. Liver not available for culture. Roundworms in stomach on gross examination. | Bacteriology samples not able to be located in the archives. |
| 2002/03 | E02/03-01Ph | Subadult Male | Infectious | Large, partially healed shark bite on left side of abdomen: 2 lines of rake marks, full skin thickness in places, approx. 30cm apart. Cutaneous myiasis of the wound. High gastrointestinal parasite burden on gross examination. Large numbers of nematodes in stomach and oesophagus, abundant acanthocephalans in small intestine and colon. Poor body condition. | No significant abnormalities detected. | Cestode larval cysts in the subcutaneous tissues over the ventral abdomen. Lung worms present on histology, including a larva visible in an airway. | No samples taken for bacteriology. |

| Field Season | ID number | Sex/Age | Cause of Death | Gross Post Mortem Findings | Histology Findings | Additional Findings | Bacteria Isolated |
|--------------|-------------|--------------|--------------------|--------------------------------------------------------------------------------------------------------------------------------------------------------------------------------------------------------------------------------------------------------------------------------------------------------------------------------------------------------------------------|----------------------------------------|------------------------------------------------------------------------------------------------------------------------------------------------------------------------------------------------------------------------------------------------------------------------------------------------------------------------------------------------------------------------------------------------------------------------------------------------------------------------------------------------------------------------------------------|--------------------------------------------------------------------------------------------------------------------------------------------------------------------------------------------------------------------------------------------------------------------------------------------------------|
| 2002/03 | E02/03-26Ph | Adult Female | Conspecific trauma | Extensive bruising around a puncture wound (sea lion bite) to the right-hand side of the head. Depression fracture of the right side of the skull, brain parenchyma lacerated underneath the skull fracture. Small pale granuloma-like lesions (1-3mm diameter) throughout the lung parenchyma and on lung surface. Tiny roundworms present in these on incision. | No significant abnormalities detected. | Cestode larval cysts in the subcutaneous tissues over the ventral abdomen. Roundworms in stomach on gross examination. A few acanthocephalans in colon on gross examination. Underlying disease: Moderate broncho-interstitial pneumonia with granuloma formation, in which some granulomas contained dead lung worms. The histological appearance is suggestive of early mycobacterial infection or an inflammatory response to lung worms. No visible AFOs and no growth on the mycobacterial cultures performed. | Tonsil was negative on mycobacterial culture. Tonsil: - Moderate growth of a beta-haemolytic <i>Streptococcus</i> sp. - Light growth of <i>Proteus mirabilis</i> - Light growth of an alpha-haemolytic <i>Streptococcus</i> sp. No other tissue samples taken for bacteriology. |

| Field Season | ID number | Sex/Age | Cause of Death | Gross Post Mortem Findings | Histology Findings | Additional Findings | Bacteria Isolated |
|--------------|-------------|---------------|----------------|----------------------------------------------------------------------------------------------------------------------------------------------------------------------------------------------------------------------------------------------------------------------------------------------------------------------------------------------------------------------------------------------------------------------------|------------------------------------------------------------------------|-------------------------------------------------------------------------------------------------------------------------------------------------------------------------------------|------------------------------------|
| 2002/03 | E02/03-94Ph | Yearling Male | Infectious | Multiple deep puncture wounds around the head and neck consistent with punctures caused by the canine teeth of adult NZSLs. Severe oedema, cellulitis, abscessation and haemorrhage was associated with the wounds, penetrating deep into the subcutis and muscle layers. Sea lion bite wounds to the caudal abdomen immediately cranial to the anus and overlying the pubis. Bite wounds to the pectoral flippers. | No significant abnormalities detected. | Roundworms in stomach on gross examination. Acanthocephalans in colon on gross examination. Occasional lung worm seen on histology with little inflammatory reaction. | No samples taken for bacteriology. |
| 2002/03 | E02/03-99Ph | Yearling Male | Unknown | Scavenging by birds of the lungs, heart, stomach, most of the spleen, most of the liver and most of the intestine (except cranial duodenum and caudal colon). | No significant abnormalities detected. Mild meningeal fibrosis. | Nematodes in oesophagus on gross examination. Acanthocephalans in colon on gross examination. | No samples taken for bacteriology. |

| Field Season | ID number | Sex/Age | Cause of Death | Gross Post Mortem Findings | Histology Findings | Additional Findings | Bacteria Isolated |
|--------------|--------------|--------------|----------------|-----------------------------------------------------------------------------------------------------------------------------------------------------------------------------------------------------------------------------------------------------------------------------------------------------------------------------------------------------------------------------------------------------------------------------------------------------------------------------------------------------------------------------------------------------------------------------------------------------------------------------|-----------------------------------------------------------------|----------------------------------------------------------------------------------------------------------------------------------------------------------------------------------------------------------------------------------------------------------------------------------------------------------------|--------------------------------------------------------------------------------------------------------------------------------------------------------------------------------------------------------------------------------------------------------------------------------------------------------------------------------------------------------------------------------------------------------------------------------|
| 2002/03 | E02/03-103Ph | Adult Female | Infectious | <p>The right ventro-lateral abdomen had a 30 x 40cm abscess in the subcutis, extending into the underlying muscle, with surrounding oedema, necrosis and haemorrhage.</p> <p>The lungs contained multiple abscesses up to 10cm diameter. Some contained fine nematodes up to 3cm long on incision. There was a large volume of clotted blood in the trachea that extended caudally to a large focus of abscessation in the right caudal lung lobe.</p> <p>An abscess containing about 10mls of pus was excised on removing the reproductive tract in the right pelvic region but its exact location was not determined.</p> | Suppurative embolic bacterial pneumonia with lung abscessation. | <p>Sarcocysts observed within skeletal myocytes, with no associated inflammatory reaction.</p> <p>Mild chronic mastitis.</p> <p>Nematodes in the stomach on gross examination.</p> <p>Cestode larval cysts in the subcutaneous tissues over the ventral abdomen.</p> <p>Some lung worms seen on histology.</p> | <p>Lung and muscle were negative on mycobacterial culture.</p> <p>Lung:</p> <ul style="list-style-type: none"> - Moderate growth of a beta-haemolytic <i>Streptococcus</i> sp. - Scant growth of <i>Escherichia coli</i> <p>Muscle from near abscess:</p> <ul style="list-style-type: none"> - Heavy growth of a beta-haemolytic <i>Streptococcus</i> sp. - Scant mixed growth |

| Field Season | ID number | Sex/Age | Cause of Death | Gross Post Mortem Findings | Histology Findings | Additional Findings | Bacteria Isolated |
|--------------|-------------|-----------------|--------------------|--------------------------------------------------------------------------------------------------------------------------------------------------------------------------------------------------------------------------------------------------------------------|-----------------------------------------------------------------------------|-------------------------------------------------------------------------------------------------------------------------------------------------------------------------------|--------------------------------------------------------------|
| 2003/04 | E03/04-10Ph | Adult Female | Conspecific trauma | Observed by researchers to have been killed by drowning while being mated in shallow water by an adult male. Adult male guarding body. | Premature placental separation possibly secondary to the drowning/struggle. | Several meters long tapeworm in small intestine on gross examination. Late term pregnancy. A few lung worms seen on histology with no associated inflammatory reaction. | No samples taken for bacteriology. |
| 2003/04 | E03/04-13Ph | Yearling Female | Infectious | Multiple deep puncture wounds around the head and neck consistent with punctures caused by the canines of adult NZSLs. Associated severe oedema, cellulitis, abscessation and haemorrhage. | No significant abnormalities detected. | A few lung worms seen on histology with no inflammatory reaction. Nematodes in the stomach on gross examination. | Bacteriology samples not able to be located in the archives. |
| 2003/04 | E03/04-23Ph | Adult Female | Unknown | Adult male guarding body. Spine had a "major kink" at last thoracic vertebra and skull is "crushed". No bruising was seen around these fractures but minimal further descriptions prevent determining if these lesions are ante-mortem or post-mortem findings. | Histology samples not able to be located in the archives. | | No samples taken for bacteriology. |

| Field Season | ID number | Sex/Age | Cause of Death | Gross Post Mortem Findings | Histology Findings | Additional Findings | Bacteria Isolated |
|--------------|-------------|--------------|--------------------|--------------------------------------------------------------------------------------------------------------------------------------------------------------------|------------------------------------------------------------------------------------------|-----------------------------------------------------------------------------------------------------------------------------------------------------------------------------------------------------------------------------------------------------------------------------------------------------|--------------------------------------------------------------|
| 2003/04 | E03/04-36Ph | Adult Female | Conspecific trauma | Observed by researchers to have been mated in shallow water by adult males prior to death. Found dead shortly after, therefore strongly suspected to have drowned. | No significant abnormalities detected. | Underlying disease: Subcutaneous abscess on the cranio-ventral abdomen with surrounding area of necrosis ~25cm diameter. Retrobulbar abscess left eye. Adrenal abscess. Moderate number of lung worms seen on histology with little or no associated inflammatory reaction. | Bacteriology samples not able to be located in the archives. |
| 2003/04 | E03/04-39Ph | Adult Male | Unknown | No abnormalities on gross examination of the thoracic, abdominal organs and lymph nodes of the axillae and neck. | Histology samples not taken due to field restraints around the large size of the animal. | | No samples taken for bacteriology. |

| Field Season | ID number | Sex/Age | Cause of Death | Gross Post Mortem Findings | Histology Findings | Additional Findings | Bacteria Isolated |
|--------------|-------------|--------------|----------------|-------------------------------------------------|---------------------------------------------------------------------------------------------------------------------------------------------------------------------------------------------------------------------------------------------------------------------------------------------------|----------------------------------------------------------------------------------------------------------------------------------------------------------------------------------------------------------------------------|--------------------------------------------------------------|
| 2003/04 | E03/04-52Ph | Adult Female | Unknown | Retained foetal cranial bone remnants in utero. | Moderate chronic endometritis. Severe interstitial fibrosis of the lung on some sections examined histologically. Unknown how much of the lung was actually affected in this manner based on the gross report, therefore overall significance of this lesion not able to be determined. | Part of the small intestine scavenged through the vaginal wall. Roundworms in stomach on gross examination. Thyroid cyst. Ovarian cyst. Lung worms seen on gross and histological examination. | Bacteriology samples not able to be located in the archives. |

| Field Season | ID number | Sex/Age | Cause of Death | Gross Post Mortem Findings | Histology Findings | Additional Findings | Bacteria Isolated |
|--------------|-------------|-----------------|--------------------|--------------------------------------------------------------------------------------------------------------------------------------------------------------------------------------------------------------------------------------------------------------------------------------------------------------------------------------------------------------------------------------------------------------------------------------------------|----------------------------------------|--------------------------------------------------------------------------------------|----------------------------------------------------------------------------------------------------------------------------------------------------------------------------------------------------------------------------------------------|
| 2004/05 | E04/05-03Ph | Yearling Female | Infectious | Multiple deep puncture wounds around the head and neck consistent with punctures caused by the canines of adult NZSLs. Severe oedema, cellulitis, abscessation and haemorrhage was associated with the wounds, penetrating deep into the subcutis and muscle layers. Septic arthritis of an interphalangeal joint of the left forelimb. Subcutaneous abscessation of the left hindlimb - over the hip and extending down the limb. | No significant abnormalities detected. | Roundworms in stomach on gross examination. Lung parasites seen on histology. | Phalangeal joint swab: - No bacteria isolated Throat abscess swab: - Heavy growth of a beta-haemolytic <i>Streptococcus</i> sp. "Inguinal" abscess swab: - Heavy growth of a beta-haemolytic <i>Streptococcus</i> sp. |
| 2004/05 | E04/05-05Ph | Yearling Male | Conspecific trauma | Severe scavenging: all internal organs missing apart from stomach. Multiple skull fractures, severe bruising of head and neck. | Histology samples not taken. | Roundworms in stomach on gross examination. | No samples taken for bacteriology. |

| Field Season | ID number | Sex/Age | Cause of Death | Gross Post Mortem Findings | Histology Findings | Additional Findings | Bacteria Isolated |
|--------------|-------------|--------------|----------------|----------------------------------------------------------------------------------------------------------------------------------------------------------------------------------------|-----------------------------------------------------------------------------------------------------------------------|----------------------------------------------------------------------------------------------------------------------------------------------------------------------------------------------|----------------------------------------------------------------------------------------------------------------------------------------------------------------------------------|
| 2004/05 | E04/05-09Ph | Adult Female | Infectious | Large abscess dorsal and cranial to the point of the left shoulder (with a ~12 x 8cm necrotic cavity) and a smaller abscess in the mandibular region. Adult male guarding body. | Acute severe haemorrhagic suppurative bacterial tonsillitis. Congestion of multiple head and neck lymph nodes. | Roundworms in stomach and oesophagus on gross examination. Cestode larval cysts in the subcutaneous tissues over the ventral abdomen. Occasional lung worms seen on histology. | Submandibular lymph node: - Light growth of a non-haemolytic <i>Streptococcus</i> sp. - Light growth of a beta-haemolytic <i>Streptococcus</i> sp. - Scant mixed growth |

| Field Season | ID number | Sex/Age | Cause of Death | Gross Post Mortem Findings | Histology Findings | Additional Findings | Bacteria Isolated |
|--------------|-------------|------------|----------------|-----------------------------------------------------------------------------------------------------------------------------------------------------------------------------------------------------------------------------------------------------------------------------------------------------------------------------------------------------------------------------------------------------------------------------------------------------------------------------------------------------------------------------------------------------------------------------------------------------------------------------------------------------------------------------------------------------------------------|------------------------------|--------------------------------------------------------------------------------------------------------------------------------------------------------|--------------------------------------------------------------------------------------------------------------------------------------------------------------------------------------------------------------------------------------------------------------------------------------------------------------------|
| 2004/05 | E04/05-13Ph | Adult Male | Unknown | <p>The gross post mortem report gave the following description of the thorax: "There is a moderate volume of clotted blood in the thoracic cavity (150-200ml). The lungs show a bicolour texture (lobular) and darker (haemorrhagic) zones on the edge of the caudal lobes. A few abscesses (2 to 3 cm long) are found throughout the right and left caudal lobes. They are very superficial and of firm consistency. No parasites were found."</p> <p>These descriptions could be consistent with trauma, bacterial infection (including mycobacterial) and lung worm infection. No histology samples were taken, and an inconclusive culture result means no cause of death could be determined with certainty.</p> | Histology samples not taken. | <p>Cestode larval cysts in the subcutaneous tissues over the ventral abdomen.</p> <p>Worms in stomach on gross examination ("nematodes/cestodes").</p> | <p>Tracheal lymph node was negative on mycobacterial culture.</p> <p>Tracheal lymph node:</p> <ul style="list-style-type: none"> - Scant growth of an alpha-haemolytic <i>Streptococcus</i> sp. - Scant growth of a beta-haemolytic <i>Streptococcus</i> sp. - Scant mixed growth |

| Field Season | ID number | Sex/Age | Cause of Death | Gross Post Mortem Findings | Histology Findings | Additional Findings | Bacteria Isolated |
|--------------|-------------|---------------|----------------|------------------------------------------------------------------------------------------------------------------------------------------------------------------------------------------------------------------------------------------|------------------------------------------------------------------------------------------------------------------------------------------------------------------------------------------------------------------------|----------------------------------------------------------------------------------------------------------------------------------|-------------------------------------------------------------------------------------------------------------------------------------------------------------------------------------------------------------------------------------------------|
| 2004/05 | E04/05-23Ph | Yearling Male | Unknown | The gross post mortem report gave the following description of the lungs: "The lungs show lesion typical of pneumonia, lobular." Sea lion bite wounds around the neck. Subcutaneous haemorrhage around the laryngeal area. | Histology samples not taken, therefore the significance of the gross lung findings is not known, the traumatic injuries around the neck may also be significant. No cause of death could be determined with certainty. | Large number of nematodes in the stomach on gross examination. Acanthocephalans in the intestines on gross examination. | Lung was negative on mycobacterial culture. Lung: - Light growth of a beta-haemolytic <i>Streptococcus</i> sp. - Light Mixed Growth - Scant growth of <i>Enterococcus</i> species - Scant growth of <i>Proteus mirabilis</i> |
| 2004/05 | E04/05-37Ph | Adult Female | Infectious | Pyothorax, pericarditis and multifocal pulmonary abscessation. | Histology samples not taken. | Cestode larval cysts in the subcutaneous tissues over the ventral abdomen. Nematodes in the stomach on gross examination. | Bacteriology samples not able to be located in the archives. |

| Field Season | ID number | Sex/Age | Cause of Death | Gross Post Mortem Findings | Histology Findings | Additional Findings | Bacteria Isolated |
|--------------|-------------|--------------|--------------------|------------------------------------------------------------------------------------------------------------------------------------------------------------------------------------------------------|-----------------------------------------------------------------------------------------------------------------------------------------------------------------------|------------------------------------------------------------------------------------------------------------------------------|-----------------------------------------------------------------------|
| 2004/05 | E04/05-46Ph | Adult Female | Unknown | Adult male guarding body. The gross post mortem report gave the following description of the lungs: "Pneumonia with necrotizing foci. However the lesions are not extended but uniformly spread." | Only the genital tract was submitted for histology and the bacteriology samples couldn't be found therefore the significance of the gross lung findings is not known. | Nematodes in the stomach and oesophagus on gross examination. | Bacteriology samples not able to be located in the archives. |
| 2005/06 | E05/06-58Ph | Adult Female | Conspecific trauma | Sand in airways. Fractured spine. | Histology samples not taken. | | No samples taken for bacteriology. |
| 2006/07 | E06/07-01Ph | Adult Female | Conspecific trauma | Adult male guarding body. Partially buried in sand below the high tide mark. Sand present in mouth, oesophagus and trachea. Bruising to side of body. | No significant abnormalities detected. | Roundworms in stomach on gross examination. Tapeworm in intestines on gross examination. Lung worms seen on histology. | Lung: - Scant growth of a beta-haemolytic <i>Streptococcus</i> sp. |

| Field Season | ID number | Sex/Age | Cause of Death | Gross Post Mortem Findings | Histology Findings | Additional Findings | Bacteria Isolated |
|--------------|-------------|--------------|--------------------|---------------------------------------------------------------------------------------------------------------------------------------------------------------------------------------------------------------------------------|---------------------------------------------------------------------------------------------------------------------|----------------------------------------------------------------------------------------------------------------------------------------------------------------------------------------------------------------------------------------------------------------------------------------------------------------------------------------------------------------------|-------------------------------------------------------------------------------------------------------------------------------------------------------------------------------------------------------------------------------------------------------------------------------------------|
| 2006/07 | E06/07-02Ph | Adult Female | Conspecific trauma | Extensive haemorrhage throughout the subcutaneous tissue of the right side of the neck, around the bifurcation of the trachea and all of the cranial chest. | No significant abnormalities detected other than signs of haemorrhage in tracheal sections and subcutaneous tissue. | Cestode larval cysts in the subcutaneous tissues over the ventral abdomen. Mammary cyst. Renal cyst. A small number of microscopic granulomas in the hepatic parenchyma, cut out of section when ZN stain attempted. Liver not available for culture. Lung worms seen on histology. Gastrointestinal parasites seen on histology. | Kidney: - Heavy growth of <i>Escherichia coli</i> - Moderate growth of <i>Staphylococcus</i> species (Coagulase Negative) - Light Mixed Growth Mammary Swab: - Scant growth of <i>Staphylococcus</i> species (Coagulase Negative) - Scant growth of Mixed coliforms |
| 2006/07 | E06/07-11Ph | Adult female | Conspecific trauma | Observed by researchers to have been mated in shallow water by adult males prior to death. Found dead shortly after, therefore strongly suspected to have drowned. Internal organs largely scavenged, especially thorax. | Adrenals show cortical haemorrhage, indicating possible septicemia | Underlying disease: Large subcutaneous abscess on right neck, ~15cm diameter. | Kidney was negative on mycobacterial culture. |

| Field Season | ID number | Sex/Age | Cause of Death | Gross Post Mortem Findings | Histology Findings | Additional Findings | Bacteria Isolated |
|--------------|-------------|--------------|----------------|-------------------------------------------------------------------------------------------------------------------------------------------------------------------------------------------------------------|--------------------------------------------------------------------------------------------------------------------------------------------------------------------------------------------------|------------------------------------|---------------------------------------------------------------------------------------------------------------------------------------------------------------------------------------------------------------------------------------------------------------------------------------------------------------------------------------------------------------------------------------------------------------------------------|
| 2006/07 | E06/07-13Ph | Adult Female | Unknown | Severe scavenging of abdomen and thorax. | No abnormalities detected in a limited tissue set collected for histology. Significant widespread autolysis. | | No bacterial cultures performed. |
| 2006/07 | E06/07-17Ph | Adult Male | Predation | Missing caudal ¼ of body (from mid-abdomen) due to large shark bite, based on serrated edges to the wound. Concurrent severe chronic granulomatous pleuritis and pericarditis, and pleural effusion. | Severe chronic granulomatous pleuritis and pericarditis. Granulomatous lymphadenitis of multiple lymph nodes of unknown location, with areas of central necrosis. No visible AFOs. | Some lung worms seen on histology. | A sample of lung, lymph node and pleural fluid were positive on mycobacterial culture. PCR confirmed <i>M. pinnipedii</i> . Pleural fluid: - No bacteria isolated Lung: - Scant growth of a non-haemolytic <i>Streptococcus</i> sp. - Scant growth of an alpha-haemolytic <i>Streptococcus</i> sp. - Scant mixed growth Lymph Node: - Scant mixed growth No <i>Nocardia</i> isolated |

| Field Season | ID number | Sex/Age | Cause of Death | Gross Post Mortem Findings | Histology Findings | Additional Findings | Bacteria Isolated |
|--------------|-------------|--------------|--------------------|------------------------------------------------------------------------------------------------------------------------------------------------------------------------------------------------------------------------------------------------------------------------------------------------|-----------------------------------------------------------------------------------------------------------------------------------------------------|----------------------------------------------------------------------------------------------------------------------------------------------------------------------------|----------------------------------|
| 2006/07 | E06/07-18Ph | Adult Male | Predation | <p>A shark attack on this sea lion by a large shark was witnessed by researchers.</p> <p>Shark bite wound to right abdomen, ~53cm in diameter, abdominal wall damaged and abdominal organs herniating through the deficit.</p> <p>Right shoulder dislocated and deep bite at right carpus.</p> | Low grade localised enteritis of unknown aetiology, with moderate infiltration of neutrophils and some lymphocytes/plasma cells into the submucosa. | <p>Some lung worms seen on histology.</p> <p>Cystic thyroid hyperplasia.</p> | No bacterial cultures performed. |
| 2006/07 | E06/07-19Ph | Adult Female | Conspecific trauma | <p>Sustained a penetrating wound to the vestibule and herniation of the small intestines through the wound as a result of mating attempts from an adult male.</p> <p>Adult male guarding body.</p> | No significant abnormalities detected. | <p>Cystic thyroid.</p> <p>Active, involuting uterus from recent (but not new) pregnancy with some uterine milk and a small number of inflammatory cells in the glands.</p> | No bacterial cultures performed. |

| Field Season | ID number | Sex/Age | Cause of Death | Gross Post Mortem Findings | Histology Findings | Additional Findings | Bacteria Isolated |
|--------------|-------------|--------------|--------------------|---------------------------------------------------------------------------------------------------------------------------------------------------------------------------------|----------------------------------------------------------------------------------------------------------------------------------------------------------------------------------------------------------------------------------------------------------------------------------------------------------------------------------------|------------------------------------------------------------------------------------------------------------------------------------------------------------------------------------------------|-----------------------------------------------------------------------------------------------------------------------------------------------------------------------------------|
| 2007/08 | E07/08-46Ph | Adult Female | Infectious | When the left kidney was incised, purulent material was seen and also a cyst-like structure. | Moderate acute ascending bacterial pyelonephritis with a focus of secondary perinephric abscessation, likely resulting in either renal failure or septicaemia. No bladder available for histology. Warthin-Starry staining was not performed due to the lesions not being typical of <i>Leptospira</i> infections in pinnipeds. | Nematodes in the stomach and oesophagus on gross examination. One cross section of a parasite is seen on examination of the intestines on histology. Some lung worms seen on histology. | Kidney swab: - Heavy growth of an alpha-haemolytic <i>Streptococcus</i> sp. - Light growth of <i>E. coli</i> No growth on specific culture for <i>Leptospira</i> sp. |
| 2008/09 | E08/09-01Ph | Adult Female | Conspecific trauma | Extensive severe bruising of neck and cranial thorax. Extensive severe bruising of left shoulder and dorsal right shoulder. Severe oedema of mediastinal tissues. | Set of tissues for histology severely limited by scavenging of thorax and abdomen. | Some lung worms seen on histology. Mild associated inflammation. | No samples taken for bacteriology. |

| Field Season | ID number | Sex/Age | Cause of Death | Gross Post Mortem Findings | Histology Findings | Additional Findings | Bacteria Isolated |
|--------------|-------------|-----------------|--------------------|------------------------------------------------------------------------------------------------------------------------------------------------------------------------------------------------------------------------------------------------------------------------------------------------------------------------------------------------------------------------------------------------------------|---------------------------------------------------------------------------------|--------------------------------------------------------------------------------------------------------------------------------------------------------------------------------|------------------------------------|
| 2008/09 | E08/09-07Ph | Adult Female | Conspecific trauma | <p>Adult male guarding body.</p> <p>Extensive multiple puncture wounds (sea lion bites) to shoulder, neck, head.</p> <p>Moderate bruising of the muscle of the left skull.</p> <p>Bruising of left shoulder area, corresponding to bite marks.</p> <p>2-3L of blood in the allantoic space of a full-term pregnancy.</p> | Pathological/premature detachment of placenta seen on examination of cotyledon. | <p>Roundworms in stomach on gross examination.</p> <p>Acanthocephalans in small intestine on gross examination.</p> <p>One lung worm seen with associated small granuloma.</p> | Amniotic fluid: No growth |
| 2008/09 | E08/09-09Ph | Yearling Female | Conspecific trauma | <p>Adult male guarding body.</p> <p>Extensive punctures (sea lion bites) penetrating into subcutaneous tissue of head, neck, shoulders and ventral thorax. Bruising of subcutaneous tissue associated with all bite wounds.</p> <p>A 4cm x 3 cm area of the right skull was crushed under the bite wounds, with multiple bone fragments and compression and maceration of the underlying brain tissue.</p> | Histology samples not taken. | <p>Roundworms in oesophagus on gross examination.</p> <p>Acanthocephalans in small intestine on gross examination.</p> | No samples taken for bacteriology. |

| Field Season | ID number | Sex/Age | Cause of Death | Gross Post Mortem Findings | Histology Findings | Additional Findings | Bacteria Isolated |
|--------------|-------------|---------------|--------------------|-------------------------------------------------------------------------------------------------------------------------------------------------------------------------------------------------------------------------------------------------------------------------------------------------------------------|-----------------------------------------------------------------------------------------------------------------------------------------------------------------------|-----------------------------------------------------------------------------------------------------------------------------------------------------|------------------------------------------------------------------------------|
| 2008/09 | E08/09-10Ph | Adult female | Infectious | Emaciated. Large numbers of worms in stomach (~200) on gross examination. | Moderate parasitic bronchopneumonia, adult worms and larvae seen, with associated, congestion, collapse, and mucous and inflammatory exudate in airways. Metritis. | | A gastrointestinal swab was cultured for <i>Salmonella</i> : - No growth. |
| 2008/09 | E08/09-12Ph | Yearling Male | Conspecific trauma | Adult male guarding body. Aggression by this male towards the yearling was witnessed by researchers: mating and aggressive biting of the head and neck. Severe extensive subcutaneous bruising to all aspects of the head and neck. Skull was intact. Haemorrhage over the ventral surface of the brain. | No significant abnormalities detected. | Significantly limited histology set due to extensive scavenging of thoracic and some abdominal organs. Worms in oesophagus on gross examination. | Liver: - Mixed growth. |

| Field Season | ID number | Sex/Age | Cause of Death | Gross Post Mortem Findings | Histology Findings | Additional Findings | Bacteria Isolated |
|--------------|-------------|--------------|--------------------|----------------------------------------------------------------------------------------------------------------------------------------------------------------------------------------------------------------------------------------|-------------------------------------------------------------------------------------------------------------------------------|----------------------------------------------------------------------------------------------------------------------------------------------------------------------------------------------------------------|------------------------------------------------------------------------------------------------------------------------------------------------------------------------------------------------------------------------------------------------------------------------------|
| 2008/09 | E08/09-15Ph | Adult Female | Conspecific trauma | Adult male guarding body. Mild to moderate subcutaneous bruising centred on the left neck/shoulder area, extending throughout the dorsal thoracic area Haemoabdomen of approximately 1L frank blood. Torn muscles of scapula. | No significant abnormalities detected. | Cestode larval cysts in the subcutaneous tissues over the ventral abdomen. Roundworms in stomach on gross examination. Parasites seen on histology of intestines. Adult lung worms seen on histology. | Liver: - <i>Streptococcus constellatus</i> |
| 2008/09 | E08/09-19Ph | Adult Female | Infectious | Mucopurulent material containing lung worms in bronchi and bronchioles. | Severe suppurative bronchopneumonia and multifocal suppurative bacterial hepatitis due to <i>Streptococcus constellatus</i> . | Cestode larval cysts in the subcutaneous tissues over the ventral abdomen. Parasites seen on histology of intestines. Adult lung worms seen on histology. | Lung: - <i>Streptococcus constellatus</i> Liver: - <i>Streptococcus constellatus</i> Spleen: - <i>Streptococcus constellatus</i> - <i>Escherichia coli</i> Uterus swab: - <i>Streptococcus constellatus</i> - <i>Escherichia coli</i> |

| Field Season | ID number | Sex/Age | Cause of Death | Gross Post Mortem Findings | Histology Findings | Additional Findings | Bacteria Isolated |
|--------------|-------------|---------------|--------------------|-----------------------------------------------------------------------------------------------------------------------------------------------------------------------------------------------------------------------|----------------------------------------|---------------------------------------------------------------------------------------------------------------------------------------------------------------------------------------------------------------------------------------------------------------------------------------------------------------------------------------------------------------------------------------------------------------------------------------------|-----------------------------------------------------------------------------------------------------------|
| 2008/09 | E08/09-20Ph | Yearling Male | Conspecific trauma | Adult male guarding body. Mild bruising of neck and body. Herniation of jejunum through a penetrating wound in perineum. | No significant abnormalities detected. | Underlying disease: Moderate parasitic bronchopneumonia with adult lung worms in parenchyma and airways, and associated changes such as congestion, collapse, mucous gland hyperplasia, inflammatory cells in airways and proteinaceous fluid within the airways. Worms seen on gross and histological examination. Worms in stomach on gross examination. Small paralumbar abscess (~1.25cm diameter) inside dorsal abdomen. | Abscess swab: - <i>Streptococcus constellatus</i> Liver: - <i>Streptococcus constellatus</i> |
| 2008/09 | E08/09-21Ph | Yearling Male | Conspecific trauma | Moderate ventral subcutaneous oedema around penis. Moderate haemorrhage and oedema of neck subcutaneous and muscle tissue. Areas of haemorrhage deep to tracheal cartilage indicating deep neck trauma. | No significant abnormalities detected. | Underlying disease: Moderate parasitic bronchopneumonia with associated changes such as congestion, collapse and inflammatory cell infiltration in and around airways. Lung worms were seen on gross examination in bronchi and bronchioles, and on histology. Large number of worms in stomach on gross examination. Parasites seen on histology of intestines. Thyroid cyst. | Liver: - Mixed growth Spleen: - No growth |

| Field Season | ID number | Sex/Age | Cause of Death | Gross Post Mortem Findings | Histology Findings | Additional Findings | Bacteria Isolated |
|--------------|-------------|-----------------|--------------------|---------------------------------------------------------------------------------------------------------------------------------------------------------------------------------------------------------------------------------------------------------------------------------------------|----------------------------------------|------------------------------------------------------------------------------------------------------------------------------------------------------------------------------------------------------------------------------------------------------------------------------------------------------------------------------------------------------------------------------------------------------|-----------------------------------------------------|
| 2008/09 | E08/09-22Ph | Yearling Female | Conspecific trauma | <p>Severe subcutaneous bruising diffusely of all aspects of the pelvic region</p> <p>Severe bruising of the internal pelvic canal.</p> <p>Herniation of GIT through a wound of the perineum.</p> <p>Mild to moderate subcutaneous bruising of the ventral neck and right shoulder area.</p> | No significant abnormalities detected. | <p>Significantly limited histology set due to significant scavenging of abdominal organs.</p> <p>Underlying disease: Multifocal accumulations of neutrophils in the meninges, liver and corticomedullary junction of the adrenals, consistent with septicæmia. <i>Klebsiella pneumoniae</i> (grown from the liver) is therefore considered to have played a role in the morbidity of the animal.</p> | <p>Liver:</p> <p>- <i>Klebsiella pneumoniae</i></p> |

| Field Season | ID number | Sex/Age | Cause of Death | Gross Post Mortem Findings | Histology Findings | Additional Findings | Bacteria Isolated |
|--------------|-------------|--------------|----------------|----------------------------------------------------------------------------------------------------|----------------------------------------|------------------------------------------------------------------------------------------------------------------------------------------------------------------------------------------------------------------------------------------------------------------------------------------------------------------------------------------|----------------------------------------------------------------------------------------------------------------------------------------------------------------------------------------------------------------------------------------------------------------------------------------------------------------------------------------------------------------------------------------------------------------------------------------------------------------------------------------------------------------------------------------|
| 2008/09 | E08/09-23Ph | Adult Female | Unknown | Full-term pup in utero and histological lesions of acute placental separation - possible dystocia. | No significant abnormalities detected. | <p>A single 1.5cm diameter hepatoma.</p> <p>Partial scavenging of small intestine through hole in the vagina.</p> <p>Cestode larval cysts in the subcutaneous tissues over the ventral abdomen.</p> <p>Worms in stomach on gross examination.</p> <p>Lung worms seen on histology.</p> <p>Parasites seen on histology of intestines.</p> | <p>Foetal spleen:</p> <ul style="list-style-type: none"> - <i>Streptococcus constellatus</i> - <i>Escherichia coli</i> - <i>Streptococcus</i> species <p>Foetal liver:</p> <ul style="list-style-type: none"> - <i>Streptococcus constellatus</i> - <i>Escherichia coli</i> <p>Maternal spleen:</p> <ul style="list-style-type: none"> - <i>Streptococcus</i> species. <p>Maternal liver:</p> <ul style="list-style-type: none"> - Mixed growth |

| Field Season | ID number | Sex/Age | Cause of Death | Gross Post Mortem Findings | Histology Findings | Additional Findings | Bacteria Isolated |
|--------------|-------------|--------------|----------------|------------------------------------------------------------------------------------------------------------------------------------------------------------------------------------------------------------------------------------------------------------------------------------------|-------------------------------------------------------------------------------------------------------------------------------------------------------------------------------------------------------------------------------------------------------------------------------------------------------------------------------------------|----------------------------------------------------------------------------------------------------------------------|-------------------------------------------------------------------------------------------------------------------------------------------------------------------------------------------------------------------------------|
| 2008/09 | E08/09-24Ph | Adult Female | Infectious | <p>The caudodorsal half of the right lung is severely consolidated by multinodular coalescing pale tan granulomas of various sizes.</p> <p>Generalised lymphadenopathy of peripheral, thoracic, and abdominal lymph nodes, with lymph nodes appearing diffusely enlarged and smooth.</p> | <p>Severe chronic granulomatous bronchopneumonia. Some of the larger granulomas have central necrosis and mineralisation.</p> <p>Concurrent interstitial fibrosis of the lungs.</p> <p>Occasional visible AFOs in the lung lesions.</p> <p>Microscopically the lymph nodes are reactive, but with no granuloma formation or necrosis.</p> | <p>Lung worms seen on gross and histological examination.</p> <p>Roundworms in the stomach on gross examination.</p> | <p>Lung: - <i>Escherichia coli</i></p> <p>Spleen: - No significant organisms grown</p> <p>Liver: - Mixed growth</p> <p>Lung was positive on mycobacterial culture.</p> <p>PCR confirmed <i>M. pinnipedii</i>.</p> |

| Field Season | ID number | Sex/Age | Cause of Death | Gross Post Mortem Findings | Histology Findings | Additional Findings | Bacteria Isolated |
|--------------|-------------|--------------|----------------|----------------------------------------------------------------------------------------------------------------------------------------------------------------------------------------------------------------------------------------------------------------------------------------------------------------------------------------------------------------------------------------------------------------------------------------------------|-----------------------------------------------------------------------------------------------------------------------------------|----------------------------------------------------------------------------------------------------------|--------------------------------------------------------------------------------------------------------------------------------------------------------------------------------------|
| 2008/09 | E08/09-25Ph | Adult Female | Infectious | <p>Approximately 8 kidney corpuscles within each kidney are diffusely severely reddened, softened and variably cavitated. One kidney contained a single 1x1x1.25cm smooth-walled cyst which contains clear pale yellow fluid.</p> <p>The bladder was small and filled with fibrinopurulent material that was loosely adherent to the bladder wall.</p> <p>There was a thick plug of sand present within 5 cm of trachea just aboral to larynx.</p> | <p>Severe acute suppurative pyelonephritis and bacterial cystitis.</p> <p>Warthin-Starry staining of the kidney was negative.</p> | <p>Roundworms in the stomach on gross examination.</p> <p>Parasites seen on histology of intestines.</p> | <p>Kidney: - Two strains of <i>Escherichia coli</i></p> <p>Bladder: - Gram-positive rod from the bladder.</p> <p>A <i>Leptospira</i> specific culture was not performed.</p> |

| Field Season | ID number | Sex/Age | Cause of Death | Gross Post Mortem Findings | Histology Findings | Additional Findings | Bacteria Isolated |
|--------------|-------------|---------------|--------------------|-------------------------------------------------------------------------------------------------------------------------------------------------------------------------------------------------------------------------------------------------------------------------------------------------------------------------------|------------------------------------------------------------------------------------------------------------------------------------|--------------------------------------------------------------------------------------------------------------------------------------------------------------------------------------------------------------------------------------------------------------|-------------------------------------------------------------------------------------------------------|
| 2008/09 | E08/09-26Ph | Adult Female | Infectious | Emaciated. Jejunum, ileum and large intestine mucosa diffusely reddened, contains melena. High burden of acanthocephalans throughout the small and large intestine (~20-50 per 3cm length of intestine) on gross examination. Also seen on histology. Moderate number of roundworms in stomach on gross examination. | Moderate enteritis - mixed inflammatory infiltrate in several sections of intestinal mucosa. Cause unknown, most likely bacterial. | Mesentery eviscerated through a tear in the perineum, animal seen alive and being scavenged prior to death. Cestode larval cysts in the subcutaneous tissues over the ventral abdomen. Cystic thyroids. Lung worms seen on histological examination | Spleen: - No growth Liver: - No significant organisms grown. No intestinal content taken. |
| 2008/09 | E08/09-27Ph | Subadult Male | Conspecific trauma | Severe extensive haemorrhage and oedema of subcutaneous tissue and muscle on all aspects of neck, most severe ventrally. | No significant abnormalities detected. | Significantly limited histology set due to significant scavenging of abdominal organs. Significant widespread autolysis seen on histology. | No samples taken for bacteriology. |
| 2008/09 | E08/09-31Ph | Adult Male | Unknown | Abscess-like lesion around the left submandibular region ~6cm diameter. | No significant abnormalities detected. | A partial necropsy was performed due to the difficult position and size of the animal, and the incoming tide. Significantly limited histology set as a result. | No samples taken for bacteriology. |

| Field Season | ID number | Sex/Age | Cause of Death | Gross Post Mortem Findings | Histology Findings | Additional Findings | Bacteria Isolated |
|--------------|-------------|---------------|----------------|-----------------------------------------------------------------------------------------------------------|-------------------------------------------------------------------------------------------------------------------------------------------------------------------------------------------------------------------------------------------------|----------------------------------------------|--------------------------------------------------------------------------------------------------------------------------------------------------------------------------------------------------------------------------------------------------------------------------------------------------------------------------------------------------------------------------------------------------------------------------------------------------------------------------------------------------------------------------------------------------------------------|
| 2008/09 | E08/09-33Ph | Subadult Male | Infectious | Large subcutaneous abscess containing ~3L of pus located in the ventral and left neck and thoracic inlet. | Moderate to severe suppurative fibrinous embolic bronchopneumonia with pleural involvement. The same bacteria were cultured from the subcutaneous tissue and the lung, suggesting embolic spread from a primary subcutaneous site of infection. | Infected biliary cystadenoma 8cm in diameter | <p>Spleen:</p> <ul style="list-style-type: none"> - <i>Staphylococcus</i> species - <i>Streptococcus</i> species <p>Liver and pus from liver:</p> <ul style="list-style-type: none"> - Two <i>Staphylococcus</i> species <p>Lung:</p> <ul style="list-style-type: none"> - <i>Staphylococcus</i> species - <i>Streptococcus constellatus</i> <p>Abscess wall, right kidney, right adrenal and abscess liquid:</p> <ul style="list-style-type: none"> - <i>Staphylococcus</i> species |
| 2008/09 | E08/09-51Ph | Adult Male | Unknown | | Size of the animal and time restraints around the post mortem examination meant no samples for histology were taken. | Significant scavenging of thoracic organs. | <p>Liver and spleen:</p> <ul style="list-style-type: none"> - No significant organisms |

| Field Season | ID number | Sex/Age | Cause of Death | Gross Post Mortem Findings | Histology Findings | Additional Findings | Bacteria Isolated |
|--------------|-------------|--------------|----------------|--------------------------------------------------------------------------------|----------------------------------------------------------------------------------------------------------------------------------------------------------------------------------------------------------------------------------------------------------------------------------------------------------------------------------------------------------------------------------------------------------------------------------------------------------------------------------------------------------------------------------------------------------------------------------------|-----------------------------------------------------------------------------------------------------------------------------------|---------------------------------------------------------------------------------------------------------------------------------------------------------------------------------------------------------------------------------------------------------------------------------------------------------------------------|
| 2008/09 | E08/09-53Ph | Adult Female | Infectious | The right lung had multiple granuloma-like lesions with a diameter of 5-20 mm. | Severe chronic multifocal to coalescing granulomatous bronchopneumonia, consisting of large areas of central necrosis surrounded by an inflammatory infiltrate of predominantly macrophages and a small number of lymphocytes and plasma cells. In parts of the lungs that were less severely affected, macrophages formed smaller discrete granulomas with or without necrotic centres. Severe chronic granulomatous lymphadenitis in two lymph nodes. Multiple small granulomas through the nodes, the larger of which have necrotic centres. No AFOs seen in lesions. | Nematodes in stomach on gross examination. Lung worms seen on histology. Parasites seen on histology of intestines. | Liver and spleen: - <i>Escherichia coli</i> Lung: - Scant growth of an alpha-haemolytic <i>Streptococcus</i> sp. - Light growth of <i>Escherichia coli</i> Lung was positive on mycobacterial culture. Liver was negative on mycobacterial culture. PCR confirmed <i>M. pinnipedii</i> . |

| Field Season | ID number | Sex/Age | Cause of Death | Gross Post Mortem Findings | Histology Findings | Additional Findings | Bacteria Isolated |
|--------------|-------------|--------------|----------------|----------------------------------------------------------------------------------------------------------------------------------------------------------------------------------------------------------------------------------------------------------------------------------------------------------------------------------------------------------------------------------------|-------------------------------------------------------------------------------------------------------------------------------------------------------------------------------------------------------------------------|--------------------------------------------------------------------------------------------------------------------------------------------------------------------------------------------------------------------------------------|-------------------------------------------------------------------------------------------------------------------------------------------------------------------------------------------------------------------------------------------------------------------------------------------------------------------------------------------------------------------------------------------------------------------------------------------------------------------------------------------------------------------------------------------------------------------------------------------------------------------------------------------------------------------------------------------------------|
| 2009/10 | E09/10-08Ph | Adult Female | Infectious | <p>Large subcutaneous abscess on the left-hand side of the cranial neck, approximately 22x28cm in diameter, extending to the larynx, trachea and neck muscles at its deep border.</p> <p>Oedema of the left cranial lung, with multifocal 1-3mm diameter nodules throughout the parenchyma on cut surface.</p> <p>Enlargement of the middle and left tracheobronchial lymph nodes.</p> | <p>Severe fibrinous, necrotizing, suppurative bronchopneumonia. The same bacteria were cultured from the subcutaneous tissue and the lung, suggesting embolic spread from a primary subcutaneous site of infection.</p> | <p>Cestode larval cysts in the subcutaneous tissues over the ventral abdomen.</p> <p>Roundworms in oesophagus and stomach on gross examination.</p> <p>Acanthocephalans in the colon. Parasites seen on histology of intestines.</p> | <p>Abscess piece 1:</p> <ul style="list-style-type: none"> - Heavy growth of an alpha-haemolytic <i>Streptococcus</i> sp. - Light growth of <i>Escherichia coli</i> <p>Abscess piece 2:</p> <ul style="list-style-type: none"> - Heavy growth of an alpha-haemolytic <i>Streptococcus</i> sp. - Light growth of <i>Edwardsiella</i> species - Light growth of <i>Escherichia coli</i> <p>Lung:</p> <ul style="list-style-type: none"> - Heavy growth of a beta-haemolytic <i>Streptococcus</i> sp. - Heavy growth of an alpha-haemolytic <i>Streptococcus</i> sp. - Scant growth of <i>Escherichia coli</i> |

| Field Season | ID number | Sex/Age | Cause of Death | Gross Post Mortem Findings | Histology Findings | Additional Findings | Bacteria Isolated |
|--------------|-------------|--------------|----------------|---------------------------------------------------------------------------------------------------------------------------------------------------------------------------------------------------------------------------------------------------------------------------------------------------------------------------------------------------------------------------------------------------------------------------------------------------------------------------------------------------------------------------------------------|-----------------------------------------------------------------------------------------------------------------------------------------------------------------------------------------------------------------------------------------------------------------------------------------------------------------------------------------------------------------------------------------------------------------------------------------------------------------------------------------------------------------------------------|----------------------------------------------------------------------------------------------------------------------------------------------------------------------------|----------------------------------------------------------------------------------------------------------------------------------------------------------------------------------------------------------------------------------------------------------------------------------------------------------------------------------------------------------------------------|
| 2009/10 | E09/10-10Ph | Adult Female | Infectious | Severe thickening of the pleura and pericardium. The pleura was 2-3mm thick and white, with a cobblestoned surface of soft villous nodules measuring 3-10mm in diameter. There was a large volume of clear yellow-green viscous fluid in the pleural space. There were multiple soft white round bodies on average 5mm in diameter floating free within the pleural effusion. The tracheobronchial lymph nodes and mediastinal lymph nodes were enlarged. The left axillary lymph node and gastric lymph nodes were enlarged. | Severe chronic granulomatous pleuritis and pericarditis consisting of a thick layer of macrophages, fibrous tissue and occasional plasma cells and lymphocytes with no distinct organisation. Occasional small foci of necrosis. Multifocally, hyperplastic mesothelial cells formed villous projections. Multifocal small lung granulomas with areas of central necrosis. Granulomatous lymphadenitis of tracheobronchial and mediastinal lymph nodes with some areas of central necrosis. No visible AFOs. | Cestode larval cysts in the subcutaneous tissues over the ventral abdomen. Mastitis. Mild focal metritis. Roundworms in stomach on gross examination. | Lung: - Scant growth of an alpha-haemolytic <i>Streptococcus</i> sp. - Light Mixed Growth No <i>Nocardia</i> was isolated. Uterus swab: - Moderate growth of a beta-haemolytic <i>Streptococcus</i> sp. - Light growth of <i>Escherichia coli</i> Lung was positive on mycobacterial culture. PCR confirmed <i>M. pinnipedii</i> . |

| Field Season | ID number | Sex/Age | Cause of Death | Gross Post Mortem Findings | Histology Findings | Additional Findings | Bacteria Isolated |
|--------------|-------------|--------------|----------------|-------------------------------------------------------------------------------------------------------------------------------------------------------------------------------------------------------------------------------------------------------------------------------------------------------------------------------------------------------------------------------------------------------------------------------|-----------------------------------------------------------------------------------------------------------------------------------------------------------------------------------------------------------------------------------------------------------------------------------------------------------------------------------------------------------------|---------------------------------------------------------------------------------------------------------------------------------------------------|----------------------------------------------------------------------------------------------------------------------------------------------------------------------------------------------------------------------------------------------------------------------------------------------------------------------------------------------------------------------------------------------------------------------------------------------------------------------------------------------------------------------------------------------------------------------------------------------------------------------------------------------------------------------------------------------------|
| 2009/10 | E09/10-13Ph | Adult Female | Infectious | Adult male guarding body. Full-thickness tear in the wall of the dorsal rectum, starting within the pelvic canal and extending cranially into the abdomen. A section of the jejunum was herniated through the tear and had been scavenged. There was a resulting severe peritonitis. The middle tracheobronchial lymph node was enlarged and on cut surface contained a cream-coloured nodular mass 20mm in diameter | Severe subacute necrotising pneumonia (aspiration pneumonia). Granulomatous lymphadenitis of the sternal and middle tracheobronchial lymph nodes with a small number of associated lymphocytes. Some areas showed central necrosis. There was visible mineralisation of the necrotic areas. There were occasional visible AFOs in the lymph node lesions. | Cestode larval cysts in the subcutaneous tissues over the ventral abdomen. Roundworms in stomach on gross examination. Hepatic microabscess | Liver: - Light growth of <i>Escherichia coli</i> - Light growth of <i>Enterococcus</i> species - Scant growth of <i>Proteus mirabilis</i> Lung: - Light growth of an alpha-haemolytic <i>Streptococcus</i> sp. - Light growth of <i>Proteus mirabilis</i> - Light growth of <i>Enterococcus</i> species Tracheobronchial lymph node: - Heavy growth of <i>Enterococcus</i> species - Light growth of <i>Klebsiella pneumoniae</i> - Scant growth of <i>Proteus mirabilis</i> Tracheobronchial lymph node was positive on mycobacterial culture. Lung and liver were negative on mycobacterial culture. PCR confirmed <i>M. pinnipedii</i> . |

| Field Season | ID number | Sex/Age | Cause of Death | Gross Post Mortem Findings | Histology Findings | Additional Findings | Bacteria Isolated |
|--------------|-------------|------------------|----------------|------------------------------------------------------------------------------------------------------------------------------------------------|-------------------------------------------------------------------------------------------------------------------------------------------------------------------------------------------------------------------------------------|-------------------------------------------------------------------------------------------------------------------------------|-----------------------------------------------------------------------------------------------------------------------------------------------------------------------------------------------------------------------------------------------------------|
| 2009/10 | E09/10-14Ph | Subadult Male | Unknown | The middle tracheal lymph node was enlarged and on incision, 60% of it consisted of a cream coloured nodular lobulated mass (5x2.4cm in size). | Granulomatous lymphadenitis of the middle tracheobronchial lymph node. Large coalescing areas of necrosis surrounded by macrophages. Some granulomas show mineralisation. Occasional visible AFOs in the lymph node lesions. | Cestode larval cysts in the subcutaneous tissues over the ventral abdomen. Roundworms in stomach on gross examination. | Tracheobronchial lymph node and lung were negative on mycobacterial culture. When the liquid culture medium was examined for ZN positive organisms there were some seen, indicating the presence of dead non-culturable mycobacteria - a positive result. |

| Field Season | ID number | Sex/Age | Cause of Death | Gross Post Mortem Findings | Histology Findings | Additional Findings | Bacteria Isolated |
|--------------|-------------|---------------|----------------|------------------------------------------------------------------------------------------------------------------------------------------------------------------------|-------------------------------------------------------------------------------------------------------------------------------------------------------------------------------------------------------------------------------------------------------------------------------------------------------------------------------------------------------------------------------------------------------------------------------------------------------------------------------------------------------------------------------------------------------------------------------------------------------------|------------------------------------------------------------------------------------------------------------------------------------------------------------------------------------------------------------------------------------------------|--------------------------------------------------------------------------------------------------------------------------------------------|
| 2009/10 | E09/10-17Ph | Subadult Male | Infectious | Severe jaundice of the carcass. Enlargement of a hepatic or gastric lymph node. On cut surface there was a 2cm diameter firm nodule that was pale yellow in colour. | Severe chronic granulomatous hepatitis. Multifocal discrete and occasionally coalescing aggregations of macrophages randomly distributed throughout the liver with a small number of associated lymphocytes and neutrophils. Normal hepatic architecture was disrupted and there was mild degeneration and necrosis of hepatic tissue surrounding the granulomatous inflammation. Granulomatous lymphadenitis of either the hepatic or gastric lymph nodes, with some areas of central necrosis and mineralisation. There were large numbers of visible AFOs in liver and lymph node lesions. | Moderate decomposition and significant scavenging of most of the thoracic and abdominal organs (a piece of liver, some lymph nodes, a piece of stomach wall and the trachea with a scrap of lung attached were the only organs that remained). | Liver was positive on mycobacterial culture. Lymph node was negative on mycobacterial culture. PCR confirmed <i>M. pinnipedii</i> . |

| Field Season | ID number | Sex/Age | Cause of Death | Gross Post Mortem Findings | Histology Findings | Additional Findings | Bacteria Isolated |
|--------------|-------------|--------------|----------------|----------------------------|-----------------------------------------------------------------------------------------------------------------------------------------------------------------------------------------------------------------------------------------------------------|-------------------------------------------------------------------------------------------------------------------------------|----------------------------------------------------------------------------------------------------------------------------------------------------------------------------------------------------------------------------------------|
| 2009/10 | E09/10-21Ph | Adult Female | Infectious | Adult male guarding body. | Moderate parasitic bronchopneumonia. Adult lung worms seen, with associated collapse, cellular infiltration into interstitium and around airways (lymphocytes and plasma cells) and occasional microscopic granuloma formation. Mild endometritis. | Cestode larval cysts in the subcutaneous tissues over the ventral abdomen. Roundworms in stomach on gross examination. | Kidney: - Light growth of a beta-haemolytic <i>Streptococcus</i> sp. - Light growth of <i>Escherichia coli</i> . Lung: - Light growth of a beta-haemolytic <i>Streptococcus</i> sp. Duodenum swab: No growth |

| Field Season | ID number | Sex/Age | Cause of Death | Gross Post Mortem Findings | Histology Findings | Additional Findings | Bacteria Isolated |
|--------------|-------------|--------------|--------------------|--------------------------------------------------------------------------------------------------------------------------------------------------------------------------------------------------------------------------------------------------------------------------------------------------------------------------------------------------------------------------------------------------------------------------------------------------------------------------------------------------------------------------------------------------------------------------------------------------------------------------------------------------------------------------------------------------------------------------------------------------------------------|--------------------------------------------------------------------------------------------------------|----------------------------------------------------------------------------------------------------------------------------------------------------------------------------------------------------------------------------------------------------------------------------------------|----------------------------------------------------------------------------------------------------------------------------------------------------------------------------------------------------------------------------------------------------------------------------------------------------------------------------------------------------------------------------------------------------------------------------------------------------------------------------------------------------------------------------------------------------------------------------------|
| 2009/10 | E09/10-22Ph | Adult Female | Conspecific trauma | <p>Adult male guarding body.</p> <p>Tear in the right lateral perineum, communicating with the pelvic canal, through which most of the jejunum was prolapsed and then scavenged. Bruising of the remaining intestinal mesentery, lateral ligaments of the bladder and muscles forming the internal wall of the right pelvic canal.</p> <p>Large area of subcutaneous bruising, 30x17cm, directly caudal to the right shoulder. Mild bruising of head.</p> <p>The left bronchus was fully obstructed with sand at the point where it entered the lung and caudally to this. Moderate amount of sand within nasal cavities and the nasopharynx.</p> <p>One of the gastric lymph nodes was enlarged, measuring 5.8x3.4cm. Pale green pus was seen on cut surface.</p> | Granulomatous lymphadenitis of the gastric lymph node with areas of central necrosis. No visible AFOs. | <p>Underlying disease: Moderate parasitic bronchopneumonia. Lung worms seen on histology.</p> <p>Uterine leiomyoma ~1cm in diameter.</p> <p>Multiple vaginal papillomas.</p> <p>Thyroid cyst.</p> <p>Renal cysts.</p> <p>Mild periportal hepatitis.</p> <p>Mild subacute mastitis.</p> | <p>Gastric LN:</p> <ul style="list-style-type: none"> - Moderate growth of a beta-haemolytic <i>Streptococcus</i> sp. - Moderate growth of an alpha-haemolytic <i>Streptococcus</i> sp. - Light growth of <i>Escherichia coli</i> <p>Lung:</p> <ul style="list-style-type: none"> - Light growth of an alpha-haemolytic <i>Streptococcus</i> sp. - Scant growth of a beta-haemolytic <i>Streptococcus</i> sp. - Light Mixed Growth. <p>Lung and gastric lymph node were negative on mycobacterial culture.</p> |

| Field Season | ID number | Sex/Age | Cause of Death | Gross Post Mortem Findings | Histology Findings | Additional Findings | Bacteria Isolated |
|--------------|-------------|--------------|--------------------|---------------------------------------------------------------------------------------------------------------------------------------------------------------------------------------------------------------------------------------------------------------------|----------------------------------------|-------------------------------------------------------------------------------------------------------------------------------------------------------------------------------------------------------------------------------------------------------------------------------------------------------------------------------------------------------------------------------------------------------------------------------------------------------------------------------------------------------------------------|------------------------------------------------------------------------------------------------------------------------------------------------------------------------------------------------------------------------------------------------------------------------------------------------|
| 2010/11 | E10/11-08Ph | Adult Female | Conspecific trauma | Adult male guarding body. Large bruised area on the left side of the head from the midline to the angle of the jaw. Sea lion bite wound to the head, resulting in a groove in the cranial bone under the bruising. Torn masseter muscle, 3cm long on left. | No significant abnormalities detected. | Underlying disease: Moderate parasitic bronchopneumonia with multifocal microscopic granuloma formation. Granulomas consist of macrophages, lymphocytes and plasma cells, with some eosinophils and neutrophils, and some contain degenerating parasites. Cestode larval cysts in the subcutaneous tissues over the ventral abdomen. Roundworms in stomach and oesophagus on gross examination. Acanthocephalans in lower colon and rectum on gross examination. Parasites seen on histology of intestines. | Lung: - Moderate growth of a beta-haemolytic <i>Streptococcus</i> sp. - Moderate growth of an alpha-haemolytic <i>Streptococcus</i> sp. - Light growth of <i>Escherichia coli</i> - Scant growth of <i>Enterobacter</i> species Lung was negative on mycobacterial culture. |

| Field Season | ID number | Sex/Age | Cause of Death | Gross Post Mortem Findings | Histology Findings | Additional Findings | Bacteria Isolated |
|--------------|-------------|--------------|----------------|-------------------------------------------------------------------------------------------------------------------------------------------------------------------------------------------------------------------------------------------|-----------------------------------------------------------------------------------------------------------------------------------------------------------------------------------------------------------------------------------------------------------------------------------------------------------------------------------------------------------------------------------------------------------------------------------------------------------------------------------------------------------------------------------------------------------------------------------------------------------------------------------|--------------------------------------------------------------------------------------------------------------------------------------------------------------------------------------------------------------------------------|----------------------------------------------------------------------------------------------------------------------------------------------------------------------------------------------------------------------------------------------------------------------------------------------------------------------------------|
| 2010/2011 | E10/11-12Ph | Adult Female | Infectious | Adult male guarding body. Purulent exudate on incision of the lungs. Thickened pericardium and pleura. Generalised lymphadenopathy grossly. Left lower jaw fractured at the vertical ramus. Bruising of overlying tissues. | Severe chronic granulomatous bronchopneumonia with granulomatous pleuritis and pericarditis. Occasional small discrete granulomas forming in areas of less affected lung. Central necrosis of some granulomas. Granulomatous pleuritis and pericarditis. The pleura and pericardium were diffusely thickened by macrophages, organising into small granulomas in some places, the larger of which had necrotic centres. Lymph nodes were reactive microscopically but with no granuloma formation or necrosis. Concurrent interstitial fibrosis of the lungs. There were occasional visible AFOs in the lung lesions. | Cestode larval cysts in the subcutaneous tissues over the ventral abdomen. Roundworms in stomach on gross examination. Acanthocephalans in lower colon and rectum on gross examination. Lung worms seen on histology. | Lung: - Scant growth of <i>Proteus vulgaris</i> - Scant growth of <i>Escherichia coli</i> Lung was negative on mycobacterial culture. When the liquid culture medium was examined for ZIN positive organisms there were some seen, indicating the presence of dead non-culturable mycobacteria - a positive result. |

| Field Season | ID number | Sex/Age | Cause of Death | Gross Post Mortem Findings | Histology Findings | Additional Findings | Bacteria Isolated |
|--------------|-------------|---------------|--------------------|------------------------------------------------------------------------------------------------------------------------------------------------------------------------------------------------------------------------------------------------------------------------------------|----------------------------------------|---------------------------------------------------------------------------------------------------------------------------------------------------|-------------------------------------------------------------------------------------------------------------------------------------------------------------------------------------------------------------------------------------------------------------------|
| 2010/2011 | E10/11-15Ph | Subadult Male | Conspecific trauma | Adult male guarding body. Sea lion bite wound to right neck. Considerable associated bruising. Torn neck muscle and blubber underneath the bite. Sea lion bite to head, no wound to the skin but the underlying tissues were torn from the bone at the dorsal midline. | No significant abnormalities detected. | Underlying disease: Large chronic subcutaneous abscess above hips. Lung worms seen on histology. Parasites seen on histology of intestines. | Back Abscess: - Heavy growth of a beta-haemolytic <i>Streptococcus</i> sp. - Scant growth of <i>Proteus mirabilis</i> Neck wound: - Heavy growth of an alpha-haemolytic <i>Streptococcus</i> sp. - Scant growth of <i>Pseudomonas stutzeri</i> |

LITERATURE CITED

- Abalos, P., P. Retamal, O. Blank, D. Torres, and V. Valdenegro. 2009. *Brucella* infection in marine mammals in Antarctica. *Veterinary Record* 164 (8):250-250.
- Abrams, W. B., and M. J. Small. 1960. Current concepts of tuberculous pleurisy with effusion as derived from pleural biopsy studies. *Diseases of the chest* 38 (1):60-65.
- Acevedo-Whitehouse, K., F. Gulland, D. Greig, and W. Amos. 2003. Disease susceptibility in California sea lions. *Nature* 422 (6927):35-35.
- Ahmed, Niyaz, Mahfooz Alam, A. Abdul Majeed, S. Asad Rahman, Angel Cataldi, Debby Cousins, and Seyed E. Hasnain. 2003. Genome sequence based, comparative analysis of the fluorescent amplified fragment length polymorphisms (FAFLP) of tubercle bacilli from seals provides molecular evidence for a new species within the *Mycobacterium tuberculosis* complex. *Infection Genetics and Evolution* 2 (3):193-199.
- Alcorn, D. J., and A. K. H. Kam. 1986. Fatal Shark Attack on a Hawaiian Monk Seal (*Monachus schauinslandi*). *Marine Mammal Science* 2 (4):313-315.
- Atkinson, S., B. L. Becker, T. C. Johanos, J. R. Pietraszek, and B. C. S. Kuhn. 1994. Reproductive morphology and status of female Hawaiian monk seals (*Monachus schauinslandi*) fatally injured by adult male seals. *Journal of Reproduction and Fertility* 100 (1):225-230.
- Baker, A. 1999. Unusual mortality of the New Zealand sea lion, *Phocarctos hookeri*, Auckland Islands, January-February 1998. edited by Department of Conservation. Wellington: Department of Conservation.
- Baker, C. S., B. L. Chilvers, R. Constantine, S. DuFresne, R. H. Mattlin, A. van Helden, and R. Hitchmough. 2010. Conservation status of New Zealand marine mammals (suborders Cetacea and Pinnipedia), 2009. *New Zealand Journal of Marine and Freshwater Research* 44 (2):101-115.
- Barnett, J. E. F., P. Booth, J. I. Brewer, J. Chanter, T. Cooper, T. Crawshaw, N. J. Davison, A. Greenwood, P. Riley, N. H. Smith, and M. Wessels. 2013. *Mycobacterium bovis* infection in a grey seal pup (*Halichoerus grypus*). *Veterinary Record* 173 (7):168-170.
- Bastida, R., J. Loureiro, V. Quse, A. Bernardelli, D. Rodriguez, and E. Costa. 1999. Tuberculosis in a Wild Subantarctic Fur Seal from Argentina. *Journal of Wildlife Diseases* 35 (4):796-798.
- Beentjes, M. P. 1989. Haul-out patterns, site fidelity and activity budgets of male Hooker's sea lions (*Phocarctos hookeri*) on the New Zealand mainland. *Marine Mammal Science* 5 (3):281-297.
- Berkson, J. M., and D. P. Demaster. 1985. Use of Pup Counts in Indexing Population-Changes in Pinnipeds. *Canadian Journal of Fisheries and Aquatic Sciences* 42 (5):873-879.
- Bernardelli, A., R. Bastida, J. Loureiro, H. Michelis, M. I. Romano, A. Cataldi, and E. Costa. 1996. Tuberculosis in sea lions and fur seals from the south-western Atlantic coast. *Revue Scientifique Et Technique De L'Office International Des Epizooties* 15 (3):985-1005.

- Boardman, W. S. J., L. Shephard, I. Bastian, M. Globan, J. A. M. Fyfe, D. V. Cousins, A. Machado, and L. Woolford. 2014. *Mycobacterium pinnipedii* tuberculosis in a free-ranging Australian fur seal (*Arctocephalus pusillus doriferus*) in South Australia. *Journal of Zoo and Wildlife Medicine* 45 (4):970-972.
- Boness, D. J., W. D. Bowen, and S. J. Iverson. 1995. Does Male Harassment of Females Contribute to Reproductive Synchrony in the Grey Seal by Affecting Maternal Performance. *Behavioral Ecology and Sociobiology* 36 (1):1-10.
- Bos, K. I., K. M. Harkins, A. Herbig, M. Coscolla, N. Weber, I. Comas, S. A. Forrest, J. M. Bryant, S. R. Harris, V. J. Schuenemann, T. J. Campbell, K. Majander, A. K. Wilbur, R. A. Guichon, D. L. W. Steadman, D. C. Cook, S. Niemann, M. A. Behr, M. Zumarraga, R. Bastida, D. Huson, K. Nieselt, D. Young, J. Parkhill, J. E. Buikstra, S. Gagneux, A. C. Stone, and J. Krause. 2014. Pre-Columbian mycobacterial genomes reveal seals as a source of New World human tuberculosis. *Nature* 514 (7523):494-497.
- Bose, M. 2011. Female genital tract tuberculosis: How long will it elude diagnosis? *Indian Journal of Medical Research* 134 (1):13-14.
- Bossart, G. D., D. G. Baden, R. Y. Ewing, B. Roberts, and S. D. Wright. 1998. Brevetoxicosis in manatees (*Trichechus manatus latirostris*) from the 1996 epizootic: Gross, histologic, and immunohistochemical features. *Toxicologic Pathology* 26 (2):276-282.
- Bradshaw, C. J. A., C. Lalas, and S. McConkey. 1998. New Zealand sea lion predation on New Zealand fur seals. *New Zealand Journal of Marine and Freshwater Research* 32 (1):101-104.
- Brew, S. D., L. L. Perret, J. A. Stack, A. P. MacMillan, and N. J. Staunton. 1999. Human exposure to *Brucella* recovered from a sea mammal. *Veterinary Record* 144 (17):483-483.
- Buckles, E. L., L. J. Lowenstine, C. Funke, R. K. Vittore, H. N. Wong, J. A. St Leger, D. J. Greig, R. S. Duerr, F. M. D. Gulland, and J. L. Stott. 2006. Otarine herpesvirus-1, not papillomavirus, is associated with endemic tumours in California sea lions (*Zalophus californianus*). *Journal of Comparative Pathology* 135 (4):183-189.
- Butler, K. L., S. D. Fitzgerald, D. E. Berry, S. V. Church, W. M. Reed, and J. B. Kaneene. 2001. Experimental inoculation of European starlings (*Sturnus vulgaris*) and American crows (*Corvus brachyrhynchos*) with *Mycobacterium bovis*. *Avian Diseases* 45 (3):709-718.
- Campagna, C., and B. J. Le Boeuf. 1988. Reproductive Behaviour of Southern Sea Lions. *Behaviour* 104 (3/4):233-261.
- Carrick, R., and S. E. Ingham. 1962. Studies on the southern elephant seal, *Mirounga leonina* (L.). V. Population dynamics and utilization. *Wildlife Research* 7 (2):198-206.
- Castinel, A., P. J. Duignan, W. E. Pomroy, N. Lopez-Villalobos, N. J. Gibbs, B. L. Chilvers, and I. S. Wilkinson. 2007. Neonatal mortality in New Zealand sea lions (*Phocarctos hookeri*) at Sandy Bay, Enderby Island, Auckland Islands from 1998 to 2005. *Journal of Wildlife Diseases* 43 (3):461-474.
- Castinel, A., A. Grinberg, R. Pattison, P. Duignan, B. Pomroy, L. Rogers, and I. Wilkinson. 2007. Characterization of *Klebsiella pneumoniae* isolates from New Zealand sea lion (*Phocarctos hookeri*) pups during and after the epidemics on Enderby Island, Auckland Islands. *Veterinary Microbiology* 122 (1-2):178-184.
- Cawthorn, M. 1993. Census and population estimation of Hooker's sea lion at the Auckland Islands, December 1992-February 1993. edited by Department of Conservation. Wellington.
- Chang, F. H. 1999. *Gymnodinium brevisulcatum* sp. nov. (Gymnodiniales, Dinophyceae), a new species isolated from the 1998 summer toxic bloom in Wellington Harbour, New Zealand. *Phycologia* 38 (5):377-384.
- Childerhouse, S., B. Dix, and N. Gales. 2001. Diet of New Zealand sea lions (*Phocarctos hookeri*) at the Auckland Islands. *Wildlife Research* 28 (3):291-298.
- Childerhouse, S., and N. Gales. 1998. Historical and modern distribution and abundance of the New Zealand sea lion *Phocarctos hookeri*. *New Zealand Journal of Zoology* 25 (1):1-16.

- Chilvers, B. L. 2008. New Zealand sea lions *Phocarctos hookeri* and squid trawl fisheries: bycatch problems and management options. *Endangered Species Research* 5 (2-3):193-204.
- . 2009. Demographic parameters and at-sea distribution of New Zealand sea lions breeding on the Auckland Islands (POP2007/01). Department of Conservation.
- Chilvers, B. L., B. C. Robertson, I. S. Wilkinson, P. J. Duignan, and N. J. Gemmell. 2005. Male harassment of female New Zealand sea lions, *Phocarctos hookeri*: mortality, injury, and harassment avoidance. *Canadian Journal of Zoology-Revue Canadienne De Zoologie* 83 (5):642-648.
- Chilvers, B. L., and I. S. Wilkinson. 2008. Philopatry and site fidelity of New Zealand sea lions (*Phocarctos hookeri*). *Wildlife Research* 35 (5):463-470.
- . 2011. Research to assess the demographic parameters of New Zealand sea lions, Auckland Islands: Draft Final Report November 2011. In *Conservation Services Programme*: Department of Conservation.
- Chilvers, B. L., I. S. Wilkinson, and S. Childerhouse. 2007. New Zealand sea lion, *Phocarctos hookeri*, pup production 1995 to 2006. *New Zealand Journal of Marine and Freshwater Research* 41 (2):205-213.
- Chilvers, B. L., I. S. Wilkinson, P. J. Duignan, and N. J. Gemmell. 2005. Summer foraging areas for lactating New Zealand sea lions *Phocarctos hookeri*. *Marine Ecology-Progress Series* 304:235-247.
- Clarke, K. R., S. D. Fitzgerald, J. A. Hattey, C. A. Bolin, D. E. Berry, S. V. Church, and W. M. Reed. 2006. Experimental inoculation of wild turkeys (*Meleagris gallopavo*) with *Mycobacterium bovis*. *Avian Diseases* 50 (1):131-134.
- Cloeckaert, A., J. M. Verger, M. Grayon, J. Y. Paquet, B. Garin-Bastuji, G. Foster, and J. Godfroid. 2001. Classification of *Brucella* spp. isolated from marine mammals by DNA polymorphism at the *omp2* locus. *Microbes and Infection* 3 (9):729-738.
- Cosby, S. L., S. McQuaid, N. Duffy, C. Lyons, B. K. Rima, G. M. Allan, S. J. McCullough, S. Kennedy, J. A. Smyth, F. McNeilly, C. Craig, and C. Orveli. 1988. Characterization of a seal morbillivirus. *Nature* 336 (6195):115-116.
- Cousins, D. 2008. Tuberculosis in Fur Seals and Sea Lions Caused by *Mycobacterium pinnipedii*. In *Mycobacterium bovis infection in animals and humans*, edited by C. O. Thoen, J. H. Steele and M. J. Gilsdorf. Ames: Blackwell Publishing.
- Cousins, D. V. 1987. ELISA for Detection of Tuberculosis in Seals. *Veterinary Record* 121 (13):305-305.
- Cousins, D. V., R. Bastida, A. Cataldi, V. Quse, S. Redrobe, S. Dow, P. Duignan, A. Murray, C. Dupont, N. Ahmed, D. M. Collins, W. R. Butler, D. Dawson, D. Rodriguez, J. Loureiro, M. I. Romano, A. Alito, M. Zumarraga, and A. Bernardelli. 2003. Tuberculosis in seals caused by a novel member of the *Mycobacterium tuberculosis* complex: *Mycobacterium pinnipedii* sp. nov. *International Journal of Systematic and Evolutionary Microbiology* 53:1305-1314.
- Cousins, D. V., B. R. Francis, D. M. Collins, C. H. McGlashan, A. Gregory, and R. M. Mackenzie. 1990. Tuberculosis in captive seals: bacteriological studies on an isolate belonging to the *Mycobacterium tuberculosis* complex. *Research in Veterinary Science* 48 (2):196-200.
- Cousins, D. V., S. N. Williams, R. Reuter, D. Forshaw, B. Chadwick, D. Coughran, P. Collins, and N. Gales. 1993. Tuberculosis in wild seals and characterisation of the seal bacillus. *Australian Veterinary Journal* 70 (3):92-97.
- Crawley, M. C., and D. B. Cameron. 1972. New Zealand sea lions, *Phocarctos hookeri*, on the Snares Islands. *New Zealand Journal of Marine and Freshwater Research* 6 (1 & 2):127-32.
- de Amorim, D. B., R. A. Casagrande, M. M. Alievi, F. Wouters, L. G. S. De Oliveira, D. Driemeier, M. Tavares, C. Y. Ikuta, E. O. Telles, and J. S. Ferreira-Neto. 2014. *Mycobacterium*

- pinnipedii* in a stranded South American sea lion (*Otaria byronia*) in Brazil. *Journal of Wildlife Diseases* 50 (2):419-422.
- de Lisle, G. W., R. G. Bengis, S. M. Schmitt, and D. J. O'Brien. 2002. Tuberculosis in free-ranging wildlife: detection, diagnosis and management. *Revue Scientifique et Technique de l'Office International des Epizooties* 21 (2):317-334.
- Department of Conservation. 2009. New Zealand sea lion species management plan: 2009-2014. edited by Department of Conservation. Wellington.
- . 2016. *New Zealand sea lion demographic database*. Department of Conservation 2015 [cited 06 November 2016]. Available from <https://data.dragonfly.co.nz/nzsl-demographics/>.
- . 2016. *Department of Conservation Te Papa Atawhai* 2016 [cited 07 November 2016]. Available from <http://www.doc.govt.nz/observing-seals>.
- Dietz, R., M. P. Heidejorgensen, and T. Harkonen. 1989. Mass Deaths of harbor seals (*Phoca vitulina*) in Europe. *Ambio* 18 (5):258-264.
- Donaldson, L. P. C. 2008. The distribution of fatty acids and presence of environmental contaminants in the blubber of the New Zealand sea lion (*Phocarctos hookeri*), Massey University, Palmerston North.
- Dorman, S. E., C. L. Hatem, S. Tyagi, K. Aird, J. Lopez-Molina, M. L. M. Pitt, B. C. Zook, A. M. Dannenberg, W. R. Bishai, and Y. C. Manabe. 2004. Susceptibility to tuberculosis: clues from studies with inbred and outbred New Zealand white rabbits. *Infection and Immunity* 72 (3):1700-1705.
- Duignan, P. J. 2000. Diseases in New Zealand sea mammals. *Surveillance* 27 (3):9-15.
- Duignan, P. J., I. Wilkinson, and M. R. Alley. 2003. New Zealand sea lion (*Phocarctos hookeri*) epidemic 2002. *New Zealand Veterinary Journal* 51 (1):46.
- Ethical Agents International Ltd. 2016. *Trigene Advance* 2014 [cited 07 November 2016]. Available from <http://www.eai.co.nz/product/trigene-advance/>.
- Fenwick, S. G., P. J. Duignan, C. M. Nicol, M. J. Leyland, and J. E. B. Hunter. 2004. A Comparison of *Salmonella* Serotypes Isolated from New Zealand Sea Lions and Feral Pigs on the Auckland Islands by Pulsed-field Gel Electrophoresis. *Journal of Wildlife Diseases* 40 (3):566-570.
- Fitzgerald, J. R., and J. M. Musser. 2001. Evolutionary genomics of pathogenic bacteria. *Trends in Microbiology* 9 (11):547-553.
- Fitzgerald, S. D., K. G. Boland, K. R. Clarke, A. Wismer, J. B. Kaneene, D. E. Berry, S. V. Church, J. A. Hattey, and C. A. Bolin. 2005. Resistance of mallard ducks (*Anas platyrhynchos*) to experimental inoculation with *Mycobacterium bovis*. *Avian Diseases* 49 (1):144-146.
- Fitzgerald, S. D., L. S. Zwick, D. E. Berry, S. V. Church, J. B. Kaneene, and W. M. Reed. 2003. Experimental inoculation of pigeons (*Columba livia*) with *Mycobacterium bovis*. *Avian Diseases* 47 (2):470-475.
- Forshaw, D., and G. R. Phelps. 1991. Tuberculosis in a captive colony of pinnipeds. *Journal of Wildlife Diseases* 27 (2):288-295.
- Foster, G., A. P. MacMillan, J. Godfroid, F. Howie, H. M. Ross, A. Cloeckaert, R. J. Reid, S. Brew, and I. A. P. Patterson. 2002. A review of *Brucella* sp. infection of sea mammals with particular emphasis on isolates from Scotland. *Veterinary Microbiology* 90 (1-4):563-580.
- Foster, G., H. M. Ross, I. A. P. Patterson, R. J. Reid, and D. S. Munro. 1998. *Salmonella* typhimurium DT104 in a grey seal. *Veterinary Record* 142 (22):615-615.
- Fukunaga, H., T. Murakami, T. Gondo, K. Sugi, and T. Ishihara. 2002. Sensitivity of acid-fast staining for *Mycobacterium tuberculosis* in formalin-fixed tissue. *American Journal of Respiratory and Critical Care Medicine* 166 (7):994-997.
- Gagneux, S. 2014. Genetic Diversity in *Mycobacterium tuberculosis*. In *Pathogenesis of Mycobacterium tuberculosis and its interaction with the host organism*, edited by J. Pieters and J. D. McKinney: Springer.

- Gales, N. 1995. Hooker's sea lion recovery plan (*Phocarctos hookeri*). edited by Department of Conservation. Wellington.
- Gales, N. J., and D. J. Fletcher. 1999. Abundance, distribution and status of the New Zealand sea lion, *Phocarctos hookeri*. *Wildlife Research* 26 (1):35-52.
- Galimberti, F., L. Boitani, and I. Marzetti. 2000. The frequency and costs of harassment in southern elephant seals. *Ethology Ecology & Evolution* 12 (4):345-365.
- . 2000. Harassment during arrival on land and departure to sea in southern elephant seals. *Ethology Ecology & Evolution* 12 (4):389-404.
- Gallagher, J., and R. S. Clifton-Hadley. 2000. Tuberculosis in badgers; a review of the disease and its significance for other animals. *Research in Veterinary Science* 69 (3):203-217.
- Gavier-Widen, D., M. M. Cooke, J. Gallagher, M. A. Chambers, and C. Gortazar. 2009. A review of infection of wildlife hosts with *Mycobacterium bovis* and the diagnostic difficulties of the 'no visible lesion' presentation. *New Zealand Veterinary Journal* 57 (3):122-131.
- Geraci, J. R., D. M. Anderson, R. J. Timperi, D. J. St. Aubin, G. A. Early, J. H. Prescott, and C. A. Mayo. 1989. Humpback Whales (*Megaptera novaeangliae*) Fatally Poisoned by Dinoflagellate Toxin. *Canadian Journal of Fisheries and Aquatic Sciences* 46 (11):1895-1898.
- Geraci, J. R., D. J. St. Aubin, I. K. Barker, R. G. Webster, V. S. Hinshaw, W. J. Bean, H. L. Ruhnke, J. H. Prescott, G. Early, A. S. Baker, S. Madoff, and R. T. Schooley. 1982. Mass Mortality of Harbor Seals: Pneumonia Associated with Influenza A Virus. *Science* 215 (4536):1129-1131.
- Gerber, L. R., M. Gonzalez-Suarez, C. J. Hernandez-Camacho, J. K. Young, and J. L. Sabo. 2010. The Cost of Male Aggression and Polygyny in California Sea Lions (*Zalophus californianus*). *PLoS ONE* 5 (8):1-8.
- Geschke, K., and B. L. Chilvers. 2009. Managing big boys: a case study on remote anaesthesia and satellite tracking of adult male New Zealand sea lions (*Phocarctos hookeri*). *Wildlife Research* 36 (8):666-674.
- Giebel, J., J. Meier, A. Binder, J. Flossdorf, J. B. Poveda, R. Schmidt, and H. Kirchhoff. 1991. *Mycoplasma phocarhinis* sp. nov. and *Mycoplasma phocacerebrale* sp. nov., Two New Species from Harbor Seals (*Phoca vitulina* L.). *International Journal of Systematic Bacteriology* 41 (1):39-44.
- Gillespie, G. R., D. Hunter, L. Berger, and G. Marantelli. 2015. Rapid decline and extinction of a montane frog population in southern Australia follows detection of the amphibian pathogen *Batrachochytrium dendrobatidis*. *Animal Conservation* 18 (3):295-302.
- Gilmartin, W. G., P. M. Vainik, and V. M. Neill. 1979. Salmonellae in Feral Pinnipeds Off the Southern California Coast. *Journal of Wildlife Diseases* 15 (4):511-514.
- Goldstein, T., K. M. Colegrove, M. Hanson, and F. M. D. Gulland. 2011. Isolation of a novel adenovirus from California sea lions *Zalophus californianus*. *Diseases of Aquatic Organisms* 94 (3):243-248.
- Gopi, A., S. M. Madhavan, S. K. Sharma, and S. A. Sahn. 2007. Diagnosis and treatment of tuberculous pleural effusion in 2006. *CHEST* 131 (3):880-889.
- Grachev, M. A., V. P. Kumarev, L. V. Mamaev, V. L. Zorin, L. V. Baranova, N. N. Denikina, S. I. Belikov, E. A. Petrov, V. S. Kolesnik, R. S. Kolesnik, V. M. Dorofeev, A. M. Beim, V. N. Kudelin, F. G. Nagieva, and V. N. Sidorov. 1989. Distemper virus in Baikal seals. *Nature* 338 (6212):209-209.
- Gulland, F. M. D., M. Koski, L. J. Lowenstine, A. Colagross, L. Morgan, and T. Spraker. 1996. Leptospirosis in California sea lions (*Zalophus californianus*) stranded along the central California coast, 1981-1994. *Journal of Wildlife Diseases* 32 (4):572-580.
- Gulland, F. M. D., L. J. Lowenstine, J. M. Lapointe, T. Spraker, and D. P. King. 1997. Herpesvirus infection in stranded Pacific harbor seals of coastal California. *Journal of Wildlife Diseases* 33 (3):450-458.

- Gutacker, M. M., J. C. Smoot, C. A. L. Migliaccio, S. M. Ricklefs, S. Hua, D. V. Cousins, E. A. Graviss, E. Shashkina, B. N. Kreiswirth, and J. M. Musser. 2002. Genome-wide analysis of synonymous single nucleotide polymorphisms in *Mycobacterium tuberculosis* complex organisms: Resolution of genetic relationships among closely related microbial strains. *Genetics* 162 (4):1533-1543.
- Gutter, A. E., S. K. Wells, and T. R. Spraker. 1987. Generalized Mycobacteriosis in a California Sea Lion (*Zalophus-Californicus*). *Journal of Zoo Animal Medicine* 18 (2-3):118-120.
- Hanni, K. D., and P. Pyle. 2000. Entanglement of pinnipeds in synthetic materials at South-east Farallon Island, California, 1976-1998. *Marine Pollution Bulletin* 40 (12):1076-1081.
- Harder, T. C., M. Harder, H. Vos, K. Kulonen, S. KennedyStoskopf, B. Liess, M. J. G. Appel, and A. D. M. E. Osterhaus. 1996. Characterization of phocid herpesvirus-1 and -2 as putative alpha- and gammaherpesviruses of North American and European pinnipeds. *Journal of General Virology* 77:27-35.
- Harkonen, T., R. Dietz, P. Reijnders, J. Teilmann, K. Harding, A. Hall, S. Brasseur, U. Siebert, S. J. Goodman, P. D. Jepson, T. D. Rasmussen, and P. Thompson. 2006. A review of the 1988 and 2002 phocine distemper virus epidemics in European harbour seals. *Diseases of Aquatic Organisms* 68:115-130.
- Harris, H. S., S. C. Oates, M. M. Staedler, M. T. Tinker, D. A. Jessup, J. T. Harvey, and M. A. Miller. 2010. Lesions and Behavior Associated with Forced Copulation of Juvenile Pacific Harbor Seals (*Phoca vitulina richardsi*) by Southern Sea Otters (*Enhydra lutris nereis*). *Aquatic Mammals* 36 (4):331-341.
- Harwood, J., and A. Hall. 1990. Mass Mortality in Marine Mammals: Its Implications for Population-Dynamics and Genetics. *Trends in Ecology & Evolution* 5 (8):254-257.
- Haulena, M., F. M. D. Gulland, J. A. Lawrence, D. A. Fauquier, S. Jang, B. Aldridge, T. Spraker, L. C. Thomas, D. R. Browns, L. Wendland, and M. K. Davidsons. 2006. Lesions associated with a novel *Mycoplasma* sp. in California sea lions (*Zalophus californianus*) undergoing rehabilitation. *Journal of Wildlife Diseases* 42 (1):40-45.
- Hiruki, L. M., W. G. Gilmartin, B. L. Becker, and I. Stirling. 1993. Wounding in Hawaiian monk seals (*Monachus schauinslandi*). *Canadian Journal of Zoology-Revue Canadienne De Zoologie* 71 (3):458-468.
- Hiruki, L. M., I. Stirling, W. G. Gilmartin, T. C. Johanos, and B. L. Becker. 1993. Significance of wounding to female reproductive success in Hawaiian monk seals (*Monachus schauinslandi*) at Laysan Island. *Canadian Journal of Zoology - Revue Canadienne de Zoologie* 71 (3):469-474.
- Hofmeister, R., E. Breuer, R. Ernst, J. Hentschke, G. Molle, and H. Ludwig. 1988. Distemper-like disease in harbor seals - virus isolation, further pathologic and serologic findings. *Journal of veterinary medicine series B - Zentralblatt fur veterinarmedizin reihe B - Infectious diseases and veterinary public health* 35 (10):765-769.
- Homolka, S., S. Niemann, D. G. Russell, and K. H. Rohde. 2010. Functional Genetic Diversity among *Mycobacterium tuberculosis* Complex Clinical Isolates: Delineation of Conserved Core and Lineage-Specific Transcriptomes during Intracellular Survival. *PLOS Pathogens* 6 (7):1-17.
- Hoop, R. K. 2002. *Mycobacterium tuberculosis* infection in a canary (*Serinus canaria*) and a blue-fronted Amazon parrot (*Amazona amazona aestiva*). *Avian Diseases* 46 (2):502-504.
- Hoop, R. K., E. C. Bottger, and G. E. Pfyffer. 1996. Etiological agents of mycobacterioses in pet birds between 1986 and 1995. *Journal of Clinical Microbiology* 34 (4):991-992.
- Howard, E. B. 1983. *Pathobiology of marine mammal diseases*. Edited by E. B. Howard. Vol. 1. Boca Raton, Florida: CRC Press, 1983.
- Huard, R. C., M. Fabre, P. de Haas, L. C. O. Lazzarini, D. van Soelingen, D. Cousins, and J.L. Ho. 2006. Novel Genetic Polymorphisms That Further Delineate the Phylogeny of the *Mycobacterium tuberculosis* Complex. *Journal of Bacteriology* 188 (12):4271-4287.

- Hughes, H. J., D. T. Carr, and J. E. Geraci. 1960. Tuberculous peritonitis: a review of 34 cases with emphasis on the diagnostic aspects. *CHEST* 38 (1):42-50.
- Hunter, J. E. B., P. J. Duignan, C. Dupont, L. Fray, S. G. Fenwick, and A. Murray. 1998. First report of potentially zoonotic tuberculosis in fur seals in New Zealand. *New Zealand Medical Journal* 111 (1063):130-131.
- Inoshima, Y., T. Murakami, N. Ishiguro, K. Hasegawa, and M. Kasamatsu. 2013. An outbreak of lethal adenovirus infection among different otariid species. *Veterinary Microbiology* 165 (3-4):455-459.
- Institute of Veterinary and Biomedical Sciences, Massey University. 2014. General Biosecurity Standard Operating Procedures (SOP).
- IUCN. 2016. *The IUCN Red List of Threatened Species* (Version 2016-2) 2016 [cited 06 November 2016]. Available from <http://www.iucnredlist.org>.
- Jahans, K. L., G. Foster, and E. S. Broughton. 1997. The characterisation of *Brucella* strains isolated from marine mammals. *Veterinary Microbiology* 57 (4):373-382.
- Jensen, T., M. van de Bildt, H. H. Dietz, T. H. Anderson, A. S. Hammer, T. Kuiken, and A. Osterhaus. 2002. Another Phocine Distemper Outbreak in Europe. *Science* 297 (5579):209-209.
- Johanos, T. C., and A. K. H. Kam. 1986. The Hawaiian monk seal on Lisianski Island: 1983. edited by U. D. o. C. National Oceanic and Atmospheric Administration.
- Jones, T. C., R. D. Hunt, and N. W. King. 1997. *Veterinary Pathology*. 6th ed. Baltimore: Williams & Wilkins.
- Jurczynski, K., K. P. Lyashchenko, D. Gomis, I. Moser, R. Greenwald, and P. Moisson. 2011. Pinniped Tuberculosis in Malayan Tapirs (*Tapirus indicus*) and Its Transmission to Other Terrestrial Mammals. *Journal of Zoo and Wildlife Medicine* 42 (2):222-227.
- Jurczynski, K., K. P. Lyashchenko, J. Scharpegge, M. Fluegger, G. Lacave, I. Moser, S. Tortschanoff, and R. Greenwald. 2012. Use of Multiple Diagnostic Tests to Detect *Mycobacterium pinnipedii* Infections in a Large Group of South American Sea Lions (*Otaria flavescens*). *Aquatic Mammals* 38 (1):43-55.
- Jurczynski, K., J. Scharpegge, J. Ley-Zaporozhan, S. Ley, J. Cracknell, K. Lyashchenko, R. Greenwald, and J. P. Schenk. 2011. Computed tomographic examination of South American sea lions (*Otaria flavescens*) with suspected *Mycobacterium pinnipedii* infection. *Veterinary Record* 169 (23):608-612.
- Kamerbeek, J., L. Schouls, A. Kolk, M. van Agterveld, D. van Soolingen, S. Kuijper, A. Bunschoten, H. Molhuizen, R. Shaw, M. Goyal, and J. van Embden. 1997. Simultaneous detection and strain differentiation of *Mycobacterium tuberculosis* for diagnosis and epidemiology. *Journal of Clinical Microbiology* 35 (4):907-914.
- Kennedy, S., J. A. Smyth, S. J. McCullough, G. M. Allan, F. McNeilly, and S. McQuaid. 1988. Confirmation of cause of recent seal deaths. *Nature* 335 (6189):404-404.
- Kennedy-Stoskopf, S., M. K. Stoskopf, M. A. Eckhaus, and J. D. Strandberg. 1986. Isolation of a retrovirus and a herpesvirus from a captive California sea lion. *Journal of Wildlife Diseases* 22 (2):156-164.
- Kiers, A., A. Klarenbeek, B. Mendelts, D. Van Soolingen, and G. Koeter. 2008. Transmission of *Mycobacterium pinnipedii* to humans in a zoo with marine mammals. *International Journal of Tuberculosis and Lung Disease* 12 (12):1469-1473.
- Kik, M. J. L., M. G. Goris, J. H. Bos, R. A. Hartskeerl, and G. M. Dorrestein. 2006. An outbreak of leptospirosis in seals (*Phoca vitulina*) in captivity. *Veterinary Quarterly* 28 (1):33-39.
- Kim, H. J., H. J. Lee, S. Y. Kwon, H. I. Yoon, S. Chung, C. T. Lee, S. K. Han, Y. S. Shim, and J. J. Yim. 2006. The prevalence of pulmonary parenchymal tuberculosis in patients with tuberculous pleuritis. *CHEST* 129 (5):1253-1258.
- King, D. P., M. C. Hure, T. Goldstein, B. M. Aldridge, and F. M. D. Gulland. 2002. Otarine herpesvirus-1: a novel gammaherpesvirus associated with urogenital carcinoma in California sea lions (*Zalophus californianus*). *Veterinary Microbiology* 86 (1-2):131-137.

- Kirkwood, J. K., P. M. Bennett, P. D. Jepson, T. Kuiken, V. R. Simpson, and J. R. Baker. 1997. Entanglement in fishing gear and other causes of death in cetaceans stranded on the coasts of England and Wales. *Veterinary Record* 141 (4):94-98.
- Kissane, J. M., and W. A. D. Anderson, eds. 1985. *Anderson's Pathology*. 8 ed. Vol. 1: The C. V. Mosby Company.
- Knieriem, A., and M. G. Hartmann. 2001. Comparative histopathology of lungs from by-caught Atlantic white-sided dolphins (*Leucopleurus acutus*). *Aquatic Mammals* 27 (2):73-81.
- Kreuder, C., M. A. Miller, D. A. Jessup, L. J. Lowenstein, M. D. Harris, J. A. Ames, T. E. Carpenter, P. A. Conrad, and J. A. K. Mazet. 2003. Patterns of mortality in southern sea otters (*Enhydra lutris nereis*) from 1998-2001. *Journal of Wildlife Diseases* 39 (3):495-509.
- Kriz, P., P. Kralik, M. Slany, I. Slana, J. Svobodova, I. Parmova, V. Barnet, V. Jurek, and I. Pavlik. 2011. *Mycobacterium pinnipedii* in a captive Southern sea lion (*Otaria flavescens*): a case report. *Veterinarni Medicina* 56 (6):307-313.
- Lalas, C., H. Ratz, K. McEwan, and S. D. McConkey. 2007. Predation by New Zealand sea lions (*Phocarctos hookeri*) as a threat to the viability of yellow-eyed penguins (*Megadyptes antipodes*) at Otago Peninsula, New Zealand. *Biological Conservation* 135 (2):235-246.
- Le Boeuf, B. J., and S. Mesnick. 1991. Sexual behavior of male northern elephant seals: I. Lethal injuries to adult females. *Behaviour* 116 (1-2):143-162.
- Ledwon, A., P. Szeleszczuk, Z. Zwolska, E. Augustynowicz-Kopec, R. Sapierzynski, and M. Kozak. 2008. Experimental infection of budgerigars (*Melopsittacus undulatus*) with five *Mycobacterium* species. *Avian Pathology* 37 (1):59-64.
- Lewis, J. C. M. 1987. Cutaneous mycobacteriosis in a Southern sealion. *Aquatic Mammals* 13 (3):105-108.
- Lipscomb, T. P., D. P. Scott, R. L. Garber, A. E. Krafft, M. M. Tsai, J. H. Lichy, J. F. Taubenberger, F. Y. Schulman, and F. M. D. Gulland. 2000. Common metastatic carcinoma of California sea lions (*Zalophus californianus*): Evidence of genital origin and association with novel gammaherpesvirus. *Veterinary Pathology* 37 (6):609-617.
- Loeffler, S. H., G. W. de Lisle, M. A. Neill, D. M. Collins, M. Price-Carter, B. Paterson, and K. B. Crews. 2014. The seal tuberculosis agent, *Mycobacterium pinnipedii*, infects domestic cattle in New Zealand: epidemiologic factors and DNA strain typing. *Journal of Wildlife Diseases* 50 (2):180-187.
- Lynch, M., T. K. Taylor, P. J. Duignan, J. Swingler, M. Marenda, J. P. Y. Arnould, and R. Kirkwood. 2011. Mycoplasmas in Australian fur seals (*Arctocephalus pusillus doriferus*): identification and association with abortion. *Journal of Veterinary Diagnostic Investigation* 23 (6):1123-1130.
- Mackereth, G. F., K. M. Webb, J. S. O'Keefe, P. J. Duignan, and R. Kittelberger. 2005. Serological survey of pre-weaned New Zealand fur seals (*Arctocephalus forsteri*) for brucellosis and leptospirosis. *New Zealand Veterinary Journal* 53 (6):428-432.
- Maloney, A., B. L. Chilvers, M. Haley, C. G. Muller, W. D. Roe, and I. Debski. 2009. Distribution, pup production and mortality of New Zealand sea lion (*Phocarctos hookeri*) on Campbell Island/Motu Ihupuku, 2008. *New Zealand Journal of Ecology* 33 (2):97-105.
- Marlow, B. J. 1975. The comparative behaviour of the Australasian sea lions *Neophoca cinerea* and *Phocarctos hookeri* (Pinnipedia: Otariidae). *Mammalia* 39 (2):159-230.
- McCallum, H., D. M. Tompkins, M. Jones, S. Lachish, S. Marvanek, B. Lazenby, G. Hocking, J. Wiersma, and C. E. Hawkins. 2007. Distribution and impacts of Tasmanian devil facial tumor disease. *EcoHealth* 4 (3):318-325.
- McConkey, S. D., S. Heinrich, C. Lalas, H. McConnell, and N. McNally. 2002. Pattern of immigration of New Zealand sea lions *Phocarctos hookeri* to Otago, New Zealand: Implications for management. *Australian Mammalogy* 24 (1):107-116.
- McConkey, S. D., H. McConnell, C. Lalas, S. Heinrich, A. Ludmerer, N. McNally, E. Parker, C. Borofsky, K. Schimanski, and G. McIntosh. 2002. A northward spread in the breeding

- distribution of the New Zealand sea lion *Phocarctos hookeri*. *Australian Mammalogy* 24 (1):97-106.
- McDonald, W. L., R. Jamaludin, G. Mackereth, M. Hansen, S. Humphrey, P. Short, T. Taylor, J. Swingler, C. E. Dawson, A. M. Whatmore, E. Stubberfield, L. L. Perret, and G. Simmons. 2006. Characterization of a *Brucella* sp strain as a marine-mammal type despite isolation from a patient with spinal osteomyelitis in New Zealand. *Journal of Clinical Microbiology* 44 (12):4363-4370.
- McMahon, C. R., D. Holley, and S. Robinson. 1999. The diet of itinerant male Hooker's sea lions, *Phocarctos hookeri*, at sub-Antarctic Macquarie Island. *Wildlife Research* 26 (6):839-846.
- Mesnick, S. L., and B. J. Le Boeuf. 1991. Sexual behavior of male northern elephant seals: II. female response to potentially injurious encounters. *Behaviour* 117 (3-4):262-280.
- Ministry of Health. 2010. Guidelines for Tuberculosis Control in New Zealand. Wellington: Ministry of Health.
- Moore, P. J., M. Charteris, and E. J. Larsen. 2008. Notes on New Zealand mammals 8. Predation on nesting southern royal albatrosses *Diomedea epomophora* by a New Zealand sea lion *Phocarctos hookeri*. *New Zealand Journal of Zoology* 35 (3):201-204.
- Moser, I., W. M. Prodinger, H. Hotzel, R. Greenwald, K. P. Lyashchenko, D. Bakker, D. Gomis, T. Seidler, C. Ellenberger, U. Hetzel, K. Wuennemann, and P. Moisson. 2008. *Mycobacterium pinnipedii*: Transmission from South American sea lion (*Otaria byronia*) to Bactrian camel (*Camelus bactrianus bactrianus*) and Malayan tapirs (*Tapirus indicus*). *Veterinary Microbiology* 127 (3-4):399-406.
- Naranjo, V., K. Acevedo-Whitehouse, J. Vicente, C. Gortazar, and J. de la Fuente. 2008. Influence of methylmalonyl-CoA mutase alleles on resistance to bovine tuberculosis in the European wild boar (*Sus scrofa*). *Animal Genetics* 39 (3):316-320.
- Nicholson, A., and J. C. Fanning. 1982. Parasites and associated pathology of the respiratory tract of the Australian sea lion: *Neophoca cinerea*. Paper read at Wildlife diseases of the Pacific Basin and other countries. (Proc. 4th Internat. Conf. of the Wildlife Dis. Ass.), 25-28 August 1981, at Sydney, Australia.
- Nielsen, O., R. E. A. Stewart, K. Nielsen, L. Measures, and P. Duignan. 2001. Serologic survey of *Brucella* spp. antibodies in some marine mammals of North America. *Journal of Wildlife Diseases* 37 (1):89-100.
- Osborne, A. J., M. Zavodna, B. L. Chilvers, B. C. Robertson, S. S. Negro, M. A. Kennedy, and N. J. Gemmell. 2013. Extensive variation at MHC *DRB* in the New Zealand sea lion (*Phocarctos hookeri*) provides evidence for balancing selection. *Heredity* (111):44-56.
- Osterhaus, A. D. M. E., H. Yang, H. E. M. Spijkers, J. Groen, J. S. Teppema, and G. van Steenis. 1985. The Isolation and Partial Characterization of a Highly Pathogenic Herpesvirus from the Harbor Seal (*Phoca vitulina*). *Archives of Virology* 86 (3-4):239-251.
- Peat, N. 2003. *Subantarctic New Zealand: A Rare Heritage*: New Zealand Department of Conservation.
- Piette, M. H. A., and E. A. De Letter. 2006. Drowning: Still a difficult autopsy diagnosis. *Forensic Science International* 163 (1-2):1-9.
- Preacher, K. J. 2016. *Calculation for the chi-square test: An interactive calculation tool for chi-square tests of goodness of fit and independence* 2001 [cited 06 November 2016]. Available from <http://quantpsy.org/>.
- Price-Carter, M., S. Rooker, and D. M. Collins. 2011. Comparison of 45 variable number tandem repeat (VNTR) and two direct repeat (DR) assays to restriction endonuclease analysis for typing isolates of *Mycobacterium bovis*. *Veterinary Microbiology* 150 (1-2):107-114.
- Retamal, P., O. Blank, P. Abalos, and D. Torres. 2000. Detection of anti-*Brucella* antibodies in pinnipeds from the Antarctic territory. *Veterinary Record* 146 (6):166-167.
- Robertson, B. C., and B. L. Chilvers. 2011. The population decline of the New Zealand sea lion *Phocarctos hookeri*: a review of possible causes. *Mammal Review* 41 (4):253-275.

- Robertson, B. C., B. L. Chilvers, P. J. Duignan, I. S. Wilkinson, and N. J. Gemmell. 2006. Dispersal of breeding, adult male *Phocarctos hookeri*: Implications for disease transmission, population management and species recovery. *Biological Conservation* 127 (2):227-236.
- Robinson, S., L. Wynen, and S. Goldsworthy. 1999. Predation by a Hooker's sea lion (*Phocarctos hookeri*) on a small population of fur seals (*Arctocephalus* spp.) at Macquarie Island. *Marine Mammal Science* 15 (3):888-893.
- Roe, W. D., P. J. Duignan, L. Meynier, G. W. de Lisle, and D. V. Cousins. 2006. Tuberculosis in a New Zealand (Hooker's) sea lion. *New Zealand Veterinary Journal* 54 (1):51-51.
- Roe, W. D., L. E. Rogers, B. D. Gartrell, B. L. Chilvers, and P. J. Duignan. 2010. Serologic Evaluation of New Zealand Sea Lions for Exposure to *Brucella* and *Leptospira* spp. *Journal of Wildlife Diseases* 46 (4):1295-1299.
- Roe, W. D., L. Rogers, K. Pinpimai, K. Dittmer, J. Marshall, and B. L. Chilvers. 2015. Septicaemia and meningitis caused by infection of New Zealand sea lion pups with a hypermucoviscous strain of *Klebsiella pneumoniae*. *Veterinary Microbiology* 176 (3-4):301-308.
- Rose, N. A., C. J. Deutsch, and B. J. Le Boeuf. 1991. Sexual behavior of male northern elephant seals: III. The mounting of weaned pups. *Behaviour* 119 (3-4):171-192.
- Ruhnke, H. L., and S. Madoff. 1992. *Mycoplasma phocidae* sp. nov., Isolated from Harbor Seals (*Phoca vitulina* L.). *International Journal of Systematic Bacteriology* 42 (2):211-214.
- Sanchez, F. D., I. J. Yela, E. Alfonseca, J. Campuzano, E. Morales, and C. Aguilar. 2016. Respiratory tract infection caused by *Mycobacterium bovis* in a black swan (*Cygnus atratus*). *Avian Pathology* 45 (1):126-131.
- Scholin, C. A., F. Gulland, G. J. Doucette, S. Benson, M. Busman, F. P. Chavez, J. Cordaro, R. DeLong, A. De Vogelaere, J. Harvey, M. Haulena, K. Lefebvre, T. Lipscomb, S. Loscutoff, L. J. Lowenstein, R. Marin, P. E. Miller, W. A. McLellan, P. D. R. Moeller, C. L. Powell, T. Rowles, P. Silvagni, M. Silver, T. Spraker, V. Trainer, and F. M. Van Dolah. 2000. Mortality of sea lions along the central California coast linked to a toxic diatom bloom. *Nature* 403 (6765):80-84.
- Seki, T., M. Satake, L. MacKenzie, H. F. Kaspar, and T. Yasumoto. 1995. Gymnodimine, a New Marine Toxin of Unprecedented Structure Isolated from New Zealand Oysters and the Dinoflagellate, *Gymnodinium* sp. *Tetrahedron Letters* 36 (39):7093-7096.
- Shivaprasad, H. L., and C. Palmieri. 2012. Pathology of mycobacteriosis in birds. *Veterinary Clinics of North America - Exotic Animal Practice* 15 (1):41-55.
- Skaar, I., P. Gaustad, T. Tonjum, B. Holm, and H. Stenwig. 1994. *Streptococcus phocae* sp. nov., a new species isolated from clinical specimens from seals. *International Journal of Systematic Bacteriology* 44 (4):646-650.
- Smith, A. W., R. J. Brown, D. E. Skilling, H. L. Bray, and M. C. Keyes. 1977. Naturally-occurring leptospirosis in Northern fur seals (*Callorhinus ursinus*). *Journal of Wildlife Diseases* 13 (2):144-148.
- Smith, I. W. G. 1989. Maori Impact on the Marine Megafauna: Pre-European Distributions of New Zealand Sea Mammals. *New Zealand Archaeological Association Monograph* 17:76-108.
- Spraker, T. R., and M. E. Lander. 2010. Causes of Mortality in Northern Fur Seals (*Callorhinus Ursinus*), St. Paul Island, Pribilof Islands, Alaska, 1986-2006. *Journal of Wildlife Diseases* 46 (2):450-473.
- Sreenu, V. B., P. Kumar, J. Nagaraju, and H. A. Nagarajaram. 2006. Microsatellite polymorphism across the *M. tuberculosis* and *M. bovis* genomes: Implications on genome evolution and plasticity. *BMC Genomics* 7 (78).
- Stamper, M. A., F. M. D. Gulland, and T. Spraker. 1998. Leptospirosis in rehabilitated Pacific harbor seals from California. *Journal of Wildlife Diseases* 34 (2):407-410.

- Steinmetz, H. W., C. Rutz, R. K. Hoop, P. Grest, C. R. Bley, and J. M. Hatt. 2006. Possible human-avian transmission of *Mycobacterium tuberculosis* in a green-winged macaw (*Ara chloroptera*). *Avian Diseases* 50 (4):641-645.
- Stenvers, O., J. Plotz, and H. Ludwig. 1992. Antarctic seals carry antibodies against seal herpesvirus. *Archives of Virology* 123 (3-4):421-424.
- Subharat, S., D. R. Shu, D. N. Wedlock, M. Price-Carter, G. W. de Lisle, D. W. Luo, D. M. Collins, and B. M. Buddle. 2012. Immune responses associated with progression and control of infection in calves experimentally challenged with *Mycobacterium avium* subsp *paratuberculosis*. *Veterinary Immunology and Immunopathology* 149 (3-4):225-236.
- Sutherland, A. M. 1985. Tuberculosis of the female genital tract. *Tubercle* 66 (2):79-83.
- Thompson, P. J., D. V. Cousins, B. L. Gow, D. M. Collins, B. H. Williamson, and H. T. Dagnia. 1993. Seals, Seal Trainers, and Mycobacterial Infection. *American Review of Respiratory Disease* 147 (1):164-167.
- Thorel, M. F., C. Karoui, A. Varnerot, C. Fleury, and V. Vincent. 1998. Isolation of *Mycobacterium bovis* from baboons, leopards and a sea-lion. *Veterinary Research* 29 (2):207-212.
- Thornton, S. M., S. Nolan, and F. M. D. Gulland. 1998. Bacterial isolates from California sea lions (*Zalophus californianus*), harbor seals (*Phoca vitulina*), and northern elephant seals (*Mirounga angustirostris*) admitted to a rehabilitation center along the central California coast, 1994-1995. *Journal of Zoo and Wildlife Medicine* 29 (2):171-176.
- Tierney, T. J. 1977. Disease and injury in the southern elephant seal. *Australian Veterinary Journal* 53 (2):91-92.
- Townsend, A. J., P. J. de Lange, C. A. J. Duffy, C. M. Miskelly, J. Molloy, and D. A. Norton. 2008. New Zealand Threat Classification System manual. edited by D. o. Conservation. Wellington: Science & Technical Publishing.
- Trinkel, M., D. Cooper, C. Packer, and R. Slotow. 2011. Inbreeding depression increases susceptibility to bovine tuberculosis in lions: an experimental test using an inbred-outbred contrast through translocation. *Journal of Wildlife Diseases* 47 (3):494-500.
- Valdes, L., D. Alvarez, E. San Jose, P. Penela, J. M. Valle, J. M. Garcia-Pazos, J. Suarez, and A. Pose. 1998. Tuberculous pleurisy - A study of 254 patients. *Archives of Internal Medicine* 158 (18):2017-2021.
- Vedros, N. A., J. Quinlivan, and R. Cranford. 1982. Bacterial and fungal flora of wild northern fur seals (*Callorhinus ursinus*). *Journal of Wildlife Diseases* 18 (4):447-456.
- Vedros, N. A., A. W. Smith, J. Schonewald, G. Migaki, and R. C. Hubbard. 1971. Leptospirosis Epizootic among California Sea Lions. *Science* 172 (3989):1250-1251.
- Wards, B. J., D. M. Collins, and G. W. de Lisle. 1995. Detection of *Mycobacterium bovis* in tissues by polymerase chain reaction. *Veterinary Microbiology* 43:227-240.
- Warren, R. M., N. C. Gey van Pittius, M. Barnard, A. Hesseling, E. Engelke, M. de Kock, M. C. Gutierrez, G. K. Chege, T. C. Victor, E. G. Hoal, and P. D. van Helden. 2006. Differentiation of *Mycobacterium tuberculosis* complex by PCR amplification of genomic regions of difference. *International Journal of Tuberculosis and Lung Disease* 10 (7):818-822.
- Wells, S. K., A. Gutter, and K. Vanmeter. 1990. Cutaneous Mycobacteriosis in a Harbor Seal - Attempted Treatment with Hyperbaric-Oxygen. *Journal of Zoo and Wildlife Medicine* 21 (1):73-78.
- Wilkinson, I. S., S. J. Childerhouse, P. J. Duignan, and F. M. D. Gulland. 2000. Infanticide and cannibalism in the New Zealand sea lion, *Phocarctos hookeri*. *Marine Mammal Science* 16 (2):494-500.
- Wilkinson, I. S., B. L. Chilvers, P. J. Duignan, and P. A. Pistorius. 2011. An evaluation of hot-iron branding as a permanent marking method for adult New Zealand sea lions, *Phocarctos hookeri*. *Wildlife Research* 38 (1):51-60.

- Wilson, G. J. 1979. Hooker's sea lions in southern New Zealand. *New Zealand Journal of Marine and Freshwater Research* 13 (3):373-375.
- Woodley, T. H., and D. M. Lavigne. 1993. Potential effects of incidental mortalities on the Hooker's sea lion (*Phocarctos hookeri*) population. *Aquatic Conservation: Marine and Freshwater Ecosystems* 3 (2):139-148.
- Woods, R., D. V. Cousins, R. Kirkwood, and D. L. Obendorf. 1995. Tuberculosis in a Wild Australian Fur Seal (*Arctocephalus pusillus doriferus*) from Tasmania. *Journal of Wildlife Diseases* 31 (1):83-86.
- Worthy, T. H. 1994. Holocene breeding of sea lions (*Phocarctos hookeri*) at Delaware Bay, Nelson, South Island, New Zealand. *New Zealand Natural Sciences* 21:61-70.
- Young, J. K., M. Gonzalez-Suarez, and L. R. Gerber. 2008. Determinants of agonistic interactions in California sea lions. *Behaviour* 145:1797-1810.