

Copyright is owned by the Author of the thesis. Permission is given for a copy to be downloaded by an individual for the purpose of research and private study only. The thesis may not be reproduced elsewhere without the permission of the Author.

STRUCTURAL OBSERVATIONS ON THE
NORMAL AND DENERVATED CAROTID BODY
AND CAROTID SINUS IN THE SHEEP

(Ovis aries)

A thesis presented in partial fulfilment of the
requirements for the degree of Doctor of Philosophy
in Veterinary Anatomy at
Massey University

MAUNG SHA-BAN

1974

Dedicated to my parents,
Daw Nu Ron and Maulvi U Maung Gale

ABSTRACT

Structural and ultrastructural observations on the normal and denervated carotid body and carotid sinus of 50 lambs and 7 adult sheep (*Ovis aries*) were made employing various anatomical, histological, fluorescent, microscopical and ultrastructural techniques. Chronic denervation experiments were performed by (i) unilateral sectioning of the carotid sinus nerve with or without sectioning of the glossopharyngeal nerve and pharyngeal branches of the vagus nerve, and (ii) unilateral sectioning of the sympathetic filament (external carotid nerve) to the carotid trifurcation, or unilateral cranial cervical ganglionectomy.

The gross anatomical studies demonstrated that there is variation in the mode of branching of the common carotid artery and the pattern of the venous drainage of the entire carotid region. The position, blood supply and venous drainage of the carotid body were also found to be variable. The major arterial source of supply for almost all the structures associated with the carotid trifurcation is the occipital artery. The dual innervation of the carotid body and the carotid sinus from the glossopharyngeal nerve (via the carotid sinus nerve) and the cranial cervical ganglion (via the external carotid nerve) is described.

From the histological studies it was found that there is widespread distribution of carotid body tissue at the carotid trifurcation. Two major cell types were seen in the carotid body, the chief or type I cells and the sustentacular or type II cells. The former included "light" and "dark" cells but it was not possible to identify these cells with certainty under the electron microscope.

The carotid body and carotid sinus receive predominantly glossopharyngeal fibres which were traced close to the type I cells in the carotid body, and in the carotid sinus to the deeper tunica adventitia. The large diameter nerve fibres which degenerated after sectioning of the carotid sinus nerve, were seen to terminate in close association with the type I cells. The carotid body cells or the carotid sinus wall did not exhibit any marked morphological changes after sectioning of the carotid sinus nerve or after sympathectomy; however, a marked dilatation of the blood vessels was seen in both the carotid body and carotid sinus.

The carotid sinus is a swelling, dilatation or diverticulum at the origin of the occipital artery or the occipitoascending pharyngeal arterial trunk. The extent of the elastic tissue varies according to the position of the carotid body. The carotid sinus is predominantly of the elastic type. The terminal nerve fibres end as diffuse endings. The large diameter myelinated nerve fibres which degenerated after sectioning of the carotid sinus nerve are suggested to be of glossopharyngeal origin, whereas the fine nonmyelinated fibres which could be traced to the medioadventitial border or superficial media are suggested to be of sympathetic origin.

Both the normal and sympathetically denervated carotid body cells exhibited intense fluorescence, the intensity of the fluorescence remaining the same up to 8 weeks after sympathectomy. It is suggested that normal carotid body cells contain catecholamines consisting mainly of noradrenaline and dopamine which are not affected by chronic sympathetic denervation.

Fluorescent nerve fibres were seen on the outermost layer of the adventitia of the normal carotid sinus, along the carotid body artery, and in the adventitia and the medio-adventitial border of the common carotid and external carotid arteries. They were not present in the denervated specimens. It is suggested that the carotid sinus, carotid body artery and the common carotid and external carotid arteries receive sympathetic adrenergic innervation.

Ultrastructural studies confirmed the presence of type I and type II cells in the carotid body. The predominant type I cells are characterized by the presence of numerous dark-cored osmiophilic vesicles and mitochondria. The type II cells are irregular shaped cells with a characteristic nucleus, extensive cytoplasmic processes, fewer mitochondria and indistinct endoplasmic reticulum. Blood vessels are numerous in the carotid body. The nerve endings are of two types - large and small, the former being particularly associated with type I cells. Sometimes fine nonmyelinated small axons were seen in the small grooves of the type I cells. Most of the large diameter myelinated nerve fibres and the large type of nerve endings degenerated after sectioning of the carotid sinus nerve. The degeneration was almost complete at 2-8 weeks after nerve transection. After sympathectomy small diameter nonmyelinated nerve fibres which were usually related to the blood vessels, degenerated. It is suggested that the large diameter myelinated nerve fibres and large nerve endings belong to the glossopharyngeal system, and the small diameter nonmyelinated nerve fibres, which are usually related to the blood vessels, are from the sympathetic system.

The ovine carotid sinus presented a very similar fibre architecture to that found in the laboratory animals, and the endothelial cells possessed complex endothelial folds. Those nerve terminals which possessed indistinct perineural sheaths and few electron dense-cored vesicles degenerated after sectioning of the carotid sinus nerve, and these nerve terminals are suggested to be derived from the glossopharyngeal nerve. As the nonmyelinated sheathed nerve terminals at the medioadventitial border of the carotid sinus degenerated after sectioning of the external carotid nerve or cranial cervical ganglionectomy, they are suggested to be from the sympathetic system.

ACKNOWLEDGEMENTS

I am indebted to my supervisors, Professor R.E. Munford for his advice, interest and generous provision of facilities, and to Mr. J.C. Newhook for his helpful supervision in the shaping and production of this thesis and for his constructive criticism during the course of this study.

I would like to extend my sincere gratitude to Mr. D.A. Dowd for his great help during the first half of the study, and to Mr. B.P. O'Sullivan and Mr. M. Ratumaitavuki for their considerable technical assistance. I am also grateful to Mr. M.J. Birtles and Mrs. W.J. Lang and her staff for their friendly advice and enthusiastic help in histological preparations; and to Mr. A. Craig and Mr. D. Hopcroft, of the Applied Biochemistry Division, D.S.I.R., for their careful assistance in electron microscopical preparations.

Massey University library staff, especially Miss E.K. Green, assisted in many ways in obtaining most of the references cited in this thesis. Histological photographs were produced by Mr. J.D. Austin whose assistance was greatly appreciated.

I am also sincerely grateful to Miss T. Intuseth for her valuable encouragement throughout the study.

My particular thanks are due to Mrs. J. Franks for typing most of the draft copy of the manuscript, and to Miss Sue Shirriffs for her careful and efficient typing of the final copy of the thesis.

TABLE OF CONTENTS

	Page
<u>ACKNOWLEDGEMENTS</u>	(viii)
<u>TABLE OF CONTENTS</u>	(ix)
<u>LIST OF TABLES</u>	(xii)
<u>LIST OF FIGURES</u>	(xiii)
<u>LIST OF PLATES</u>	(xv)
<u>LIST OF ABBREVIATIONS</u>	(xvii)
<u>CHAPTER I. GENERAL INTRODUCTION</u>	1
<u>CHAPTER II. MATERIALS AND METHODS</u>	
1. <u>Methods for Gross Anatomical Dissections</u> ...	4
2. <u>Histological Methods</u>	
A. Normal Histology	6
B. Methods for Denervated Carotid Trifurcations	10
3. <u>Surgical Approach for Denervation Experiments</u> (<u>Carotid Sinus Nerve Section and</u> <u>Sympathectomy</u>)	12
4. <u>Methods for Fluorescence Microscopy</u>	15
5. <u>Methods for Electron Microscopy</u>	17

CHAPTER III. TOPOGRAPHICAL ANATOMY OF THE CAROTIDTRIFURCATION

Introduction	21
Literature Review	21
Results	26
Discussion	62
Summary	66

CHAPTER IV.LIGHT MICROSCOPY OF THE CAROTID BODY

Introduction	68
Literature Review	69
Results	79
Discussion	95
Summary	97

CHAPTER V.LIGHT MICROSCOPY OF THE CAROTID SINUS

Introduction	100
Literature Review	101
Results	119
Discussion	129
Summary	132

CHAPTER VI.FLUORESCENCE MICROSCOPICAL STUDIES OF THE
CAROTID BODY AND CAROTID SINUS

Introduction	134
Literature Review	134
Results	139

LIST OF TABLES

<u>Table</u>	<u>Page</u>
I. Methods Employed for Normal Histology of the Carotid Body and Carotid Sinus	7-8
II. Type of Nerve Sections Performed in Denervation Experiments and their Respective Post- operative Times	11
III. Type of Nerve Sections Performed for Fluorescence Microscopical Studies and their Respective Post- operative Times	16
IV. Type of Nerve Sections Performed for Electron Microscopical Studies and their Respective Post- operative Times	18
V. The Size of the Normal Carotid Body	81
VI. Size of the Normal (Control) and Denervated (After sectioning of the Carotid Sinus Nerve) Carotid Body	82
VII. Sizes of the Normal (Control) and Sympathectomized Carotid Body	82
VIII. Arterial Wall Thickness of the Normal Carotid Trifurcations	122
IX. Arterial Wall Thickness of the Normal Carotid Trifurcation	123
X. Arterial Wall Thickness of the Normal Carotid Trifurcation	124

LIST OF FIGURES

<u>Figure</u>		<u>Following Page</u>
1,2,3,4.	Branching Patterns of the Carotid Trifurcation and variation of the Position of Carotid Body. Lateral Views	27
5,6.	Origin of the Arteries of the Carotid Trifurcation as seen from within. Lateral Views	29
7,8,9, 10,11.	Innervation of the Carotid Trifurcation by the Carotid Sinus Nerve. Lateral Views	31
12,13, 14,15.	Innervation of the Carotid Trifurcation by the External Carotid Nerve (Sympathetic). Lateral Views	33
16.	Variations in the Origin of the External Carotid Nerve (Sympathetic Branch from the Cranial Cervical Ganglion to the Carotid Trifurcation). Lateral Views	35
17.	Innervation of the Right Carotid Trifurcation. Lateral View	35
18.	Innervation of the Left Carotid Trifurcation. Lateral View	37
19.	Innervation of the Right Carotid Trifurcation. Lateral View	38
20.	Innervation of the Left Carotid Trifurcation. Lateral View	40
21.	Venous Drainage of the Left Carotid Trifurcation. Lateral View	41
22.	Arterial Supply and Venous Drainage of the Left Carotid Trifurcation. Lateral View	43
23.	Venous Drainage of the Right Carotid Trifurcation. Lateral View	44
24.	Arterial Supply of the Left Carotid Region. Lateral View	46

<u>Figure</u>	<u>Following</u> <u>Page</u>
25.	Arterial Supply and Venous Drainage of the Right Carotid Trifurcation. Lateral View 47
26.	Arterial Supply and Venous Drainage of the Left Carotid Region. Lateral View 49
27.	Arterial Supply and Venous Drainage of the Right Carotid Trifurcation. Lateral View 50
28.	Arterial Supply and Venous Drainage of the Left Carotid Trifurcation. Lateral View 52
29.	Arterial Supply and Venous Drainage of the Left Carotid Trifurcation. Lateral View 53
30.	Arterial Supply and Venous Drainage of the Right Carotid Region. Lateral View 55
31.	Venous Drainage of the Left Carotid Trifurcation. Lateral View 56
32.	Venous Drainage of the Left Carotid Trifurcation. Lateral View 58
33.	Venous Drainage of the Right Carotid Trifurcation. Lateral View 59
34.	The Arterial Branches of the Left Carotid Trifurcation. Lateral View 61
35.	The Elastic Tissue Composition of the Carotid Trifurcation 120

LIST OF PLATES

<u>Plate</u>		<u>Following Page</u>
I	Gross Innervation of the Carotid Trifurcation	198
II	Position of the Carotid Body	198
III	Structure of the Normal Carotid Body	199
IV	Structure of the Normal Carotid Body Lobules	199
V	Innervation of the Normal Carotid Body	200
VI	Innervation of the Normal Carotid Body Lobules	200
VII	Relationships of Nerve Fibres to the Carotid Body Cells	201
VIII	Structure of the Carotid Body Artery and Vein	201
IX	Structure of the Denervated Carotid Body	202
X	Structure of the Denervated Carotid Body	202
XI	Structure of the Sympathectomized Carotid Body	203
XII	Innervation of the Sympathectomized Carotid Body	203
XIII	Structure of the Normal Carotid Sinus	204
XIV	Structure of the Denervated Carotid Sinus and Occipital Artery	205
XV	Structure of the Occipital and Internal Carotid Arteries	205
XVI	Structure of the Denervated Carotid Sinus	206
XVII	Structure of the Normal and Sympathectomized Carotid Sinus	206
XVIII	Fluorescent Microscopy of the Carotid Body	207
XIX	Fluorescent Microscopy of the Sympathectomized Carotid Body	207
XX	Fluorescent Microscopy of the Carotid Body	208
XXI	Fluorescent Microscopy of the Carotid Sinus and Common Carotid Artery	208

<u>Plate</u>		<u>Following Page</u>
XXII	Ultrastructure of the Normal Carotid Body	209
XXIII	Ultrastructure of the Normal Carotid Body	209
XXIV	Ultrastructure of the Normal Carotid Body	210
XXV	Ultrastructure of the Denervated Carotid Body	210
XXVI	Ultrastructure of the Normal Carotid Sinus	211
XXVII	Ultrastructure of the Normal and Denervated Carotid Sinus	211
XXVIII	Ultrastructure of the Normal and Denervated Carotid Sinus	212

LIST OF ABBREVIATIONS

a, ap	ascending pharyngeal artery
br	communicating branch to the external carotid nerve or the carotid sinus nerve
cb	carotid body
cc	common carotid artery
ccg	cranial cervical ganglion
cct	cervical sympathetic trunk
cl, b	cranial laryngeal artery
csn	carotid sinus nerve
csn1	carotid sinus nerve, first branch
csn2	carotid sinus nerve, second branch
ecn	external carotid nerve
ic, c	internal carotid artery
icn	internal carotid nerve
la	lingual artery
m	muscular branch
o	occipital artery
opt	occipitoascending pharyngeal arterial trunk
vb	a small branch from the pharyngeal branch of the vagus nerve

CHAPTER ONE

GENERAL INTRODUCTION

The carotid body and the carotid sinus of certain vertebrate species have been studied very extensively. The rabbit and cat have been used widely in various experimental studies relating to the structural, ultrastructural, physiological and biochemical aspects of the carotid body and the carotid sinus. Lambs and sheep have been used increasingly for many investigations including physiological and pharmacological studies on the carotid body and the carotid sinus. The interpretation of functional studies relating to the carotid body and the carotid sinus in the sheep requires a detailed knowledge of the gross anatomy, histology and the ultrastructure of the carotid body and carotid sinus. The effects of chronic denervation on the carotid body and the carotid sinus structures may be useful in correlating and interpreting the structure and function of these intricate structures.

The gross anatomy of the carotid trifurcation region, especially of the carotid body and the carotid sinus, in the sheep have not been worked out in detail. Waites (1960) was probably the first one who described the gross anatomy of this region briefly and demonstrated the importance of carotid sinus nerve (nerve of Hering) in the carotid sinus reflex function. However, as yet no work has been done on the blood supply, nerve supply and venous drainage of the carotid trifurcation region in the sheep. Also no published information was available on the blood supply and venous drainage of the associated nerves and ganglia - the glossopharyngeal, the carotid sinus nerve, vagus and its pharyngeal rami, accessory and hypoglossal nerves, and the sympathetic trunk, external carotid nerve, and the nodose and cranial cervical ganglia.

A very little work could be consulted on the histological structure of the carotid body and the carotid sinus of the sheep. Studies on these areas have been documented briefly by Abraham (1958, 1967, 1968a, 1969), Waites (1960) and de Kock (1954). De Kock's (1950, 1954) findings of two types of carotid body cells, type I and type II, in the carotid body of several species including sheep was confirmed in many other vertebrate species. However, the receptor idea of de Kock is not accepted by many observers. de Kock (1950, 1954) studied the carotid body using only Holmes' silver technique and classified type I and type II cells. Later cytological studies by Abraham (1969) did not favour this categorization based only on nuclear differential staining reaction.

The histology of the carotid sinus has received little attention in sheep in comparison with other vertebrate species. Abraham (1958, 1959) described its innervation briefly. In his later study (1969) he described the nerve end systems in detail and emphasized the specificity of these systems as characteristic of the ovine species. However, the shape, the extent of elastic tissue composition, the detailed glossopharyngeal and sympathetic innervation have not yet been worked out. Also, no attempt has been made to study the glossopharyngeal and sympathetic fibres to the carotid body of the sheep.

The presence of biogenic amines in the carotid trifurcation have been described by several workers in various vertebrate species including rat, rabbit, guinea-pig, cat and man. The tracing of the adrenergic fibres to the carotid body or carotid sinus in the sheep, either by light histological methods or by fluorescent microscopical techniques, has not been performed. The localization of biogenic

amines, their nature in the carotid body and carotid sinus before and after chronic sympathectomy could be helpful in interpreting the significance of the sympathetic influence on the functions of the carotid body and carotid sinus.

Although the ultrastructure of the carotid body and the carotid sinus of various species have been studied extensively, similar studies of sheep have not been published. The cell types, the nature and distribution of nerve fibres and the nerve endings, and their morphology before and after denervation still await further investigation.

In the present study of the carotid body and the carotid sinus of the lambs, various gross anatomical, histological, fluorescent microscopical, and electron microscopical methods were employed in the hope that this study might fill a gap in the understanding of the structure and function of the controversial carotid body and carotid sinus.

CHAPTER TWO

MATERIALS AND METHODS

1. Methods for Gross Anatomical Dissections

A total of twenty-two animals (17 lambs and 5 sheep) were dissected for gross anatomical studies. Nine lambs and three sheep were dissected after they had been embalmed and injected with rubber latex through the common carotid artery and the external jugular vein. Five lambs and two sheep were dissected in the fresh state. Three lambs were injected with thrombin and indian ink into the external jugular vein and the common carotid artery.

Nine lambs and three sheep were anaesthetized and were exsanguinated through the common carotid artery and the external jugular vein. Embalming fluid was infused by gravity through the common carotid artery and the external jugular vein while keeping the animal's head in the normal position. They were kept in the cool room for a week after which rubber latex was injected into the common carotid artery and the external jugular vein. After the latex had set, the animals' necks were severed just in front of the thoracic inlet and were dissected by naked eye or stereo dissecting microscope. For better differentiation of nerves and their surrounding tissues the dissected specimens were kept in one of the following solutions:

- (A) 1% glacial acetic acid solution,
- (B) 0.1 - 1.0% saturated aqueous picric acid solution,
- (C) 1% glacial acetic acid and 0.1 - 1.0% saturated aqueous picric acid,
- (D) 1% glacial acetic acid, 0.1 - 1.0% saturated aqueous picric acid and 1 - 5% ethyl alcohol,
- (E) treated by Perman's method as described by McCrea (1959).

Five lambs and two sheep were anaesthetized by intravenous pentothal sodium and were exsanguinated through the external jugular vein. The head and neck portions of the animals were removed and they were dissected under Olympus zoom-stereo microscope. The detailed innervation pattern of the carotid trifurcations were drawn during each of the dissections. The specimens were kept during and after dissections in the following solution (F):

(Percentages are by volume)

- 3% formaldehyde
- 1% glacial acetic acid,
- 0.1 - 1% saturated aqueous picric acid,
- 3% ethyl alcohol, and
- 10% glycerine.

The specimens could be kept in this solution for a long time without being distorted or unduly hardened.

To study the venous drainage of the carotid region, another three lambs were anaesthetized by intravenous injection of thiopental sodium. In one lamb, a modified technique of thrombin and indian ink injection based on a method employed by Chungcharoen, Daly and Schweitzer (1952) was used. An injection of Pelikan ink (C11/1431a, Günther Wagner) incorporated with 5 ml of 5,000 N.I.H. units thrombin (Park, Davis & Co.) was made bilaterally into the common carotid arteries at the caudal third of the neck. Both arteries were ligated above their points of injection and the animals were fixed in 10% formalin tank for one week. In the other two lambs both external jugular veins were injected with thrombin and indian ink preparation, and the specimens were fixed in the 10% formalin for one week. The specimens were dissected under Olympus zoom-stereo microscope and sketches were made during each of the

dissections. The specimens were kept in the solution (F).

Apart from the above mentioned twenty-two animals, animals which were used to study the normal histology of the carotid body and the carotid sinus, and animals used for denervation experiments, were also examined for the mode of branching of the carotid tree, the position of the carotid body and their innervation patterns. Sketches made from these observations were also included in the illustrations. Three carotid trifurcations were dissected out to make photographic records of their innervating patterns.

2. Histological Methods

A. Normal Histology

A total of 9 animals (7 lambs and 2 adult sheep) were used to study the normal histology of the carotid body and carotid sinus. Animals were freshly killed or anaesthetized by intravenous thiopental sodium and were exsanguinated through a jugular vein. The carotid trifurcations were dissected out immediately, and were fixed in various fixatives as described in Table I. The following stains and methods were used:

(a) For General Cytology

Meyer's Haematoxylin and Eosin,

Harris' Haematoxylin and Eosin,

(b) For Elastin and Collagen

Verhoeff's Elastin Stain according to Culling (1963),

Orcein (Romeis, 1948),

Gomori's Aldehyde Fuchsin (1950),

TABLE I.

METHODS EMPLOYED FOR NORMAL HISTOLOGY OF THE CAROTID BODY AND CAROTID SINUS

No.	Animals	Carotid-trifurcation	Fixative	Section	Stains requiring special fixatives
1	Lamb	Left	10% formol-saline	5 μ , serial, longitudinal, paraffin sections	
		Right	10% formol-saline	5 μ , serial, transverse, paraffin sections	
2	Lamb	Left	Formol-acetic alcohol	10-50 μ , longitudinal, frozen sections	Winkelmann and Schmit (1957)
		Right	10% formol-saline	10 μ , serial, longitudinal, paraffin sections	
3	Lamb	Left	Formol-acetic alcohol	12 μ , serial, longitudinal, paraffin sections	Bodian (1936, 1937)
		Right	Formol-sucrose ammonium hydroxide	15-20 μ , longitudinal, frozen sections	Winkelmann (1959)
4	Lamb	Left	10% formalin	25-40 μ , frozen sections	Bielschowsky-Gros-Cauna Procedure
		Right	Formol-sucrose ammonium hydroxide	15-20 μ , transverse, frozen sections	Winkelmann (1959)

Animals 1 to 7 were between six and eight months old; animals 8 and 9 were between one-and-a-half and two years old.

TABLE I (continued)

No.	Animals	Carotid-trifurcation	Fixative	Section	Stains requiring special fixatives
5	Lamb	Left	10% formalin	15-20 μ , longitudinal frozen sections	Abraham (1969)
		Right	Formol-glycerin	15-20 μ , serial, longitudinal, frozen sections	Winkelmann (1959)
6	Lamb	Left	Formol-acetic alcohol	14 μ , serial, longitudinal, paraffin sections	Bodian (1936, 1937)
7	Lamb	Left	Bouin's fluid	12-14 μ , serial, longitudinal, paraffin sections	
		Right	Bouin's fluid modified by Davenport (1960)	12-14 μ , serial, longitudinal, paraffin sections	Davenport (1960)
8	Sheep	Left	10% formol-saline	12-14 μ , serial, paraffin sections	
		Right	Regaud's fluid	5-6 μ , serial, transverse, paraffin sections	
9	Sheep	Left	10% formol-saline	12-14 μ , serial, longitudinal, paraffin sections	
		Right	10% formalin	5-6 μ , serial, transverse paraffin sections	

Masson's Trichrome Stain (1929),
 Picro-Ponceau with Haematoxylin (Gurr, 1956),
 Lillie's Allochrome Method (1951, 1954),

(c) For Reticulin

Gordon and Sweet's (1936),

(d) For Nervous Tissue

Abraham's Technique (1969),
 Bielschowsky-Gros-Cauna Procedure according to
 Abraham (1969),
 Bodian's Activated Protargol Method (1936, 1937),
 Bodian's Method as described by Humason (1967),
 Davenport's Two Hour Silver Method (1960),
 Holmes' Silver Method (1942, 1943),
 Holmes' Silver Technique according to Culling (1963),
 Rogers' New Silver Methods (1931),
 Rogers' Method according to Foot (1932),
 Romanes' Silver Chloride Method (1950),
 Ungewitter's Urea Silver Nitrate Method (1951),
 Winkelmann and Schmit's Simple Silver Method (1957),
 Winkelmann's Hydroxyl-Dependent Silver Method (1959).

The following tissue specimens were also taken: glosso-pharyngeal nerve, carotid sinus nerve, cervical vagus nerve, nodose ganglion, pharyngeal branches of the vagus nerve, cranial cervical ganglion, origin of cervical sympathetic trunk, and external carotid nerve. They were fixed in 10% formol-saline, formol-acetic alcohol, Bouin's fluid and Bouin's fluid modified by Davenport (1960). From them 5-14 μ longitudinal and transverse paraffin sections were cut and stained by Meyer's haematoxylin and

eosin, Picro-ponceau with haematoxylin, Bodian's method (1936, 1937), Holmes' silver (1942), Rogers' method (1931), Foot (1932), Romanes' method (1950), and Ungewitter's method (1957).

To compare their elastic tissue composition with that of the carotid trifurcation, specimens were taken of the following blood vessels: origin of the common carotid artery, bicarotid trunk, brachiocephalic and external carotid arteries. They were fixed in 10% formol-saline or Helly's fluid, and transverse sections of 5-14 μ were stained by Meyer's haematoxylin and eosin, picro-ponceau with haematoxylin, orcein, and Verhoeff's elastin stain.

Photographic records were made from the tissue slides prepared from the normal and denervated specimens. Photomicrographs were taken from a Leitz microscope using either Ilford Pan F or Kodak Panatomix-X films.

B. Methods for Denervated Carotid Trifurcations

A total of 9 lambs were used. Five lambs (N1, N2, N3, N4 & N5) were used for carotid sinus nerve section with or without the inclusion of the glossopharyngeal and pharyngeal branches of the vagus nerve. The other 4 lambs (G1, G2, G3 & G4) were used for sympathetic denervation (Table II). Two lambs (N1 and N2) were anaesthetized by intravenous pentothal sodium one month after section of the carotid sinus nerves. The animals were perfused by gravity bilaterally into the common carotid arteries at the neck with 10% neutral formol-saline (using Li_2CO_3). The animals were exsanguinated through an external jugular vein during perfusion. The carotid trifurcations were dissected out quickly and were fixed for 2-3 months. In one animal (N1) the carotid

TABLE II.

TYPE OF NERVE SECTIONS PERFORMED IN DENERVATION
EXPERIMENTS AND THEIR RESPECTIVE POST-OPERATIVE
TIMES

Number	Animal	Type of nerve section	Post operative time
1.	N1	Carotid sinus nerve, and glosso-pharyngeal and pharyngeal branches of vagus nerve.	1 month
2.	N2	Carotid sinus nerve.	1 month
3.	N3	Carotid sinus nerve.	1 month
4.	N4	Carotid sinus nerve, and glosso-pharyngeal nerve.	1 month
5.	N5	Carotid sinus nerve, and glosso-pharyngeal nerve.	1 month
6.	G1	External carotid nerve.	1 month
7.	G2	Cranial cervical ganglionectomy	1 month
8.	G3	Cranial cervical ganglionectomy	6 weeks
9.	G4	External carotid nerve	6 weeks

All animals were approximately 7 months old

trifurcations were treated by Guillery, Shirra and Webster's method (1961) for degenerated nerves. In the other animal (N2), 18 μ longitudinal, frozen serial sections were made and were treated by Hamlyn's method (1957) for degenerated nerves.

The rest of the denervated animals (N3, N4, N5; G1, G2, G3 & G4) were anaesthetized by intravenous thiopental sodium and were exsanguinated through a jugular vein at different times after the nerves had been sectioned (Table II). The carotid trifurcations were removed immediately and were fixed in 10% formol-saline. Longitudinal, 12-14 μ serial paraffin sections were made from each carotid trifurcation. Selected sections from each denervated and control carotid trifurcation were stained by Romanes' silver chloride method (1950) for nerve fibres. At the region of carotid body and carotid sinus, from each of the carotid trifurcations, 4-7 μ sections were also made to be stained with Meyer's haematoxylin and eosin, picro-ponceau and haematoxylin, Verhoeff's elastin stain, orcein, and Gordon and Sweet's (1936) reticulin stain.

3. Surgical Approach for Denervation Experiments (Carotid Sinus Nerve Section and Sympathectomy)

The surgical approach described here is the modified surgical approach of Appleton and Waites' (1957) for the superior cervical ganglion and related structures in the sheep.

Three to eight-month-old lambs were anaesthetized by intravenous injection of 2.5% solution of thiopental sodium ("Pentothal" sodium, Abbot or 'Intraval' sodium, M & B) at the rate of 11-16 mg/lb body weight. A skin incision about 5 cm long was made obliquely ventrocaudad starting at a point midway between the base of the ear

and the caudal angle of the mandible. The incision line was approximately parallel to and about half a centimeter dorsal to the internal maxillary and external jugular veins. The platysma muscle was transected carefully to expose the caudal auricular, internal maxillary and cranial part of the external jugular veins. The caudal auricular vein just above its entry into the internal maxillary vein, and the small muscular and cutaneous tributaries of the external jugular vein were ligated and severed. The incised area now exposed cranially the middle of the caudal border of the parotid salivary gland, dorsally the great auricular nerve and the sternomastoideus muscle, and ventrally the external jugular and the internal maxillary veins. The cervical fascia and the surrounding adipose tissue were bluntly dissected, and the lateral retropharyngeal lymph node was retracted against the ventral neck muscles. The common carotid artery and the hypoglossal nerve were separated by blunt dissection from the caudal belly of the digastric and stylohyoid muscles. A self-retaining dilator was applied to widen the incision and to obtain a clear view of the cranial nerves and the cranial cervical ganglion. A focussed light was directed obliquely through the incision at the cranial nerves and the ganglion. It was not necessary to transect the occipitohyoideus muscle but this muscle together with the caudal belly of the digastric and the stylohyoid muscles had to be retracted upwards. Adipose tissue between the angle of the occipital and external carotid arteries was cleaned to expose the carotid sinus nerve and the glossopharyngeal nerve. The cranial cervical ganglion lay cranial or medial to cranial nerves IX, X, XI, and XII in the live animal according to the degree of extension of the head. The pharyngeal branches of the vagus nerve (either a single trunk or two separate branches, the dorsal one to the pharyngeal muscles and the

ventral one, the pharyngoesophageal nerve, to the cervical oesophagus) ran rostroventrally medial to the carotid sinus nerve from the vagus nerve proximal to the nodose ganglion. The internal carotid artery and a branch from the cranial cervical ganglion to the carotid trifurcation, the external carotid nerve, ran caudoventrally medial to the pharyngeal branches of the vagus nerve. The carotid sinus nerve, glossopharyngeal nerve, pharyngeal branches of the vagus and the external carotid nerve were sectioned, and about 4-5 mm length of nerve was removed at the appropriate levels (Table II). The incised skin together with the platysma muscle and cervical fascia were sutured by Michel's metal clips.

A total of twenty-two lambs were used for denervation experiment. Nine lambs were denervated for light microscopy, three lambs for fluorescence microscopy, and ten lambs for ultrastructural studies.

A. Light Microscopy.

In two lambs, the carotid sinus nerve was sectioned; in the other two animals, the carotid sinus nerve together with the glossopharyngeal nerve were sectioned; and in one animal, the carotid sinus, the glossopharyngeal nerve and also the pharyngeal branches of the vagus nerve were sectioned. In three lambs, cranial cervical sympathetic ganglionectomies were performed, and the external carotid nerve was sectioned in the other two lambs.

B. Fluorescence Microscopy.

For fluorescence microscopical studies, the left cranial cervical ganglion was removed in two lambs, and in one animal the

external carotid nerve was sectioned (Table III).

C. Electron Microscopy.

For ultrastructural studies, the carotid sinus nerve was sectioned in three lambs; the carotid sinus nerve and the glossopharyngeal nerve were sectioned in the other two lambs. Three lambs were used for left side cranial cervical ganglionectomy, and in the other two lambs only the external carotid nerve was sectioned (Table IV).

In all experimental animals, only the left side nerves were sectioned or left cranial cervical ganglionectomies were performed leaving the right side nerves and ganglia intact as controls.

4. Methods for Fluorescence Microscopy

Experimental animals were kept for one month, six weeks and eight weeks after unilateral sympathectomy or sympathetic ganglionectomy (Table III). They were either killed without anaesthetic or anaesthetized by intravenous injection of thiopental sodium and exsanguinated through the jugular veins. The carotid trifurcations were dissected out immediately after death, blotted with blotting paper, trimmed, and very quickly frozen on cryostat chucks. The cryostat internal temperature was set at -25°C to -30°C , and serial longitudinal (one animal) or cross sections (two animals), $15-18\mu$ thick were collected and thawed on the fluorescence-free microscopic glass slides. They were immediately placed in the desiccator to dry over fresh phosphorous pentoxide for a few hours. At frequent intervals during serial sectioning some of the sections were stained by haematoxylin and eosin stain to identify the carotid body. A few

TABLE III.

TYPE OF NERVE SECTIONS PERFORMED FOR FLUORESCENCE
MICROSCOPICAL STUDIES AND THEIR RESPECTIVE POST-
OPERATIVE TIMES

No.	Animal	Type of nerve section	Post-operative time
1.	F1	Cranial cervical ganglionectomy	1 month
2.	F2	Cranial cervical ganglionectomy	6 weeks
3.	F3	External carotid nerve	8 weeks

All animals were between 7 and 8 months of age

sections among the series in the region of the carotid body and the carotid sinus were fixed in 10% formol saline for staining of collagen, elastin, reticulin and nervous tissues. The rest of the selected serial sections from the denervated and control carotid trifurcations were treated by methods described by Spriggs et al. (1966), and Rees (1967) to demonstrate the biogenic amines. The gassed and ungassed specimens from denervated and control carotid trifurcations were mounted on the clean microslides with Fluormount (Edward Gurr Ltd) and were examined under a Leitz microscope using Blau B G 12 and K530 filters. Photographs were taken on Ilford FP3 or FP4 films with average exposure times 45 sec - 1 min. Objective lenses of 3.5, 12.5 and 25 magnifications were used with a 10 power eye piece.

5. Methods for Electron Microscopy

Four lambs were used for normal ultrastructural studies and ten lambs were used for denervation experiments (Table IV).

Tissue samples for ultrastructural studies were obtained and fixed by the following methods:

- i) Animals were killed without anaesthetic. The carotid trifurcations were immediately dissected out and trimmed in cold, modified Karnovsky's (1965) fixative (2% paraformaldehyde, 3% glutaraldehyde, in phosphate buffer, pH. 7.2) or in cold buffered 5% glutaraldehyde (phosphate buffer, pH. 7.2). The carotid bodies were dissected out under a zoom-stereo dissecting microscope. During the dissections, the specimens were completely immersed in the cold fixative. Pieces of tissue, 1-2 mm thick, from the carotid sinus (origin of

TABLE IV.

TYPE OF NERVE SECTIONS PERFORMED FOR ELECTRON
MICROSCOPICAL STUDIES AND THEIR RESPECTIVE POST-
OPERATIVE TIMES

No.	Animal	Type of nerve section	Post operative time
1.	EMN 1	Carotid sinus nerve	2 weeks
2.	EMN 2	Carotid sinus nerve and glosso-pharyngeal nerve	3 weeks
3.	EMN 3	Carotid sinus nerve	5 weeks
4.	EMN 4	Carotid sinus nerve	5 weeks
5.	EMN 5	Carotid sinus nerve and glosso-pharyngeal nerve	8 weeks
6.	EMG 1	External carotid nerve	3 weeks
7.	EMG 2	Cranial cervical gangli-nectomy	4 weeks
8.	EMG 3	Cranial cervical gangli-nectomy	5 weeks
9.	EMG 4	External carotid nerve	6 weeks
10.	EMG 5	Cranial cervical gangli-nectomy	8 weeks

All animals were between 6 and 8 months of age.

occipital or occipito-ascending pharyngeal arterial trunk), the common carotid and external carotid arteries from both denervated and control carotid trifurcations were fixed in the fresh fixative for 3-24 hours at 4°C.

- ii) Animals were anaesthetized by intravenous pentothal sodium, and the arterial branches of the carotid trifurcations on both sides of the animals were exposed. All the arterial branches were clamped and the entire carotid trifurcations were removed and fixed within $\frac{1}{2}$ - $\frac{3}{4}$ min after clamping.
- iii) Animals were given primary anaesthetic induction by intravenous thiopental sodium (5%) and were maintained by endotracheal ether or halothane inhalation. Common carotid arteries and jugular veins were exposed on both sides of the animals. Cold, modified Karnovsky's fluid or buffered, 5% glutaraldehyde solution was perfused bilaterally through common carotid arteries under a pressure of 120-150 mm Hg or by gravity, and the animals were exsanguinated through external jugular veins. The carotid trifurcations were removed after 20-30 min and were fixed as above.

Tissue blocks were either vacuum infiltrated in fixatives for 15-30 min and fresh fixatives were replaced, or were subjected to buffer wash. Tissue blocks were washed twice with a half hour interval, or kept overnight in 0.1 M phosphate buffer, pH. 7.1, and were post fixed in buffered, 2% osmium tetroxide solution (0.1 M phosphate buffer, pH. 7.2) for 2-4 hours. Tissue blocks were again washed with the phosphate buffer twice with an interval of 10 min and were dehydrated through ascending grades of ethanol to propylene oxide; or blocks were kept overnight in 75% ethanol incorporated

with 1% uranyl acetate. Blocks were embedded in Araldite and sections were cut at about 50 -60nm. The sections were stained on grids with one of the following: 1% uranyl acetate, 1% lead citrate (Reynolds, 1963), 1% uranyl acetate followed by 1% lead citrate. The stained sections were examined in a Philips EM-200 electron microscope. Photographic records were made during each observation.

Thick sections of 1-2 μ were made, before cutting ultra-thin sections from each tissue block, to be stained with 1% methylene blue, 1% safranin O, and 1% toluidine blue in 1% borax.

CHAPTER THREE

TOPOGRAPHICAL ANATOMY OF THE

CAROTID TRIFURCATION

INTRODUCTION

The gross anatomy of the carotid trifurcation region in man and in a large number of vertebrates has been studied in detail, but reports on that of the sheep are still deficient in the literature. As the sheep is being increasingly utilized in various anatomical and physiological studies, detailed information on the gross anatomy of the carotid trifurcation region in this species may be useful, the following comparative anatomical observations on the carotid trifurcation region were carried out in lambs and adult sheep. Studies were made of the mode of branching of the carotid trifurcation, the gross anatomy of the carotid body and the carotid sinus, and the relationship of the carotid tree to the surrounding structures. Also studies were made on the blood supply nerve supply, and venous drainage of the carotid body and carotid sinus, and the associated nerves and ganglia, the glosso-pharyngeal, vagus, hypoglossal and spinal accessory nerves, and the cranial cervical and nodose ganglia.

LITERATURE REVIEW

A. Mode of Branching of the Carotid Tree

The earliest account of the mode of branching of the common carotid artery in the sheep was given by Chauveau (1891). He described the carotid arteries as furnishing a thyroid branch, a laryngeal branch and a very slender occipital artery. A more detailed description of the ovine carotid trifurcation was given by May (1964, 1965).

The internal carotid artery has been found to be developed in the young and absent in the adult sheep (Chauveau, 1891;

Vaughan, 1895; Daniel, Dawes and Prichard, 1953; Balankura, 1954; Baldwin and Bell, 1963; May, 1965).

The occipital artery and its branches were described by Chauveau (1891) and May (1964, 1965). The condyloid artery, according to May (1964, 1965), arises from the occipital artery near the origin of the latter, but he also points out that it may, in some cases, arise directly from the external carotid artery. The cranial branch of the condyloid artery arises near the condyloid foramen and enters the posterior foramen lacerum caudal to the vagus and accessory nerve and then ramifies in the meninges dorsal to the foramen (May, 1965). This cranial branch of the condyloid artery of May was illustrated as the middle meningeal artery by Popesko (1970). However, *Nomina Anatomica Veterinaria* (1968) lists the middle meningeal artery as a separate branch of the occipital artery in the ruminant.

The origin of the pharyngeal artery (ascending pharyngeal), according to Chauveau (1891), was nearly confounded with that of the occipital artery. However its origin, according to Daniel, Dawes and Prichard (1953) and May (1964, 1965), was from near the origin of the parent vessel (the occipital artery).

The caudal pharyngeal artery, first identified by May (1965), arises from the occipital or external carotid artery. Because this artery pursued a course with the same relationships as the internal carotid artery in other animals, May regarded it as the "original internal carotid artery".

B. Gross Anatomy of the Carotid Body and the Carotid Sinus

According to Adams (1958) the carotid body in the sheep was first mentioned by Pflüger in 1869 without any detail. Also, Adams cited Schaper (1892) as stating that the position and form of the organ were variable. In 1960, Waites found that the carotid body and the carotid sinus of the sheep were located at the junction of the occipital and carotid arteries. He also confirmed physiologically that the baro- and chemoreceptor reflexes were mediated by a branch of the glossopharyngeal nerve which was therefore analogous to the nerve of Hering.

C. Blood Supply of the Carotid Body, Carotid Sinus and the Associated Nerves and Ganglia

The arterial blood supply to the carotid body of the rabbit, dog, cat, rat, guinea-pig, Rhesus monkey, and man has been studied by a number of observers (Addison, 1945; Addison and Comroe, 1937; Chungcharoen, Daly and Schweitzer, 1952a, 1952b, 1952c; Murphy and Hughes, 1965); also the venous drainage and the arteriovenous anastomoses between the carotid body and the carotid sinus in the above laboratory animals have been extensively described by Chungcharoen, Daly and Schweitzer (1955b, c), Murphy and Hughes (1965) and Hughes (1965); yet descriptions of the arterial supply and venous drainage of the carotid body and the carotid sinus in the sheep are still deficient in the literature. Waites (1960) seems to have been the only one to describe the carotid bodies as being supplied by arteries arising from the cranial or medial surface of either the occipital artery or one of the nearby branches of the carotid artery.

Studies have also been made on the arterial blood supply to the superior cervical ganglion in man (Patterson, 1950) and the superior cervical sympathetic and nodose ganglia in cats, dogs, and rabbits (Chungcharoen, Daly and Schweitzer, 1952c). The latter workers also found that in these animals the blood supply to the carotid body, and superior cervical sympathetic and nodose ganglia were derived from the same arterial source and, moreover, the veins from these structures drained into common channels. However, no work has been done on the arterial supply or venous drainage of the cranial cervical sympathetic ganglion, external carotid nerve, cervical sympathetic trunk or cranial nerves IX, X, XI and XII in the sheep.

D. Gross Innervation of the Carotid Trifurcation

The gross innervation of the carotid body and carotid sinus region has been studied in a variety of vertebrates including man (Adams, 1952, 1955, 1957a, 1957b; Chowdhary, 1950, 1953; Code and Dingle, 1935; Gerard and Billingsley, 1923; Dowd, 1964, 1966).

A small nerve (carotid sinus nerve) branching from the glossopharyngeal nerve was described as early as 1891 by Chauveau, and later observers (Dougherty, Habel and Bond, 1958; Waites, 1960; May, 1964, 1965) consistently described it. May was probably the only one who stated that the stylopharyngeal nerve may arise from the branch of the glossopharyngeal nerve which goes to the vagus and carotid sinus.

Waites (1960) made brief mention of the gross innervation of the carotid trifurcation in the sheep and also noted that there was sympathetic innervation of the carotid body and that

sympathetic filaments continued along the common carotid, external carotid and lingual arteries. The contribution of fibres, not only from the glossopharyngeal and cranial cervical ganglion but also from the vagus nerve, to the formation of the external carotid plexus (Plexus caroticus externus) was described by Chauveau (1891), Waites (1960) and May (1964, 1965). May (1964) stated that from the caudal end of the ganglion, fibres went to the pharyngeal and carotid plexus or to the cranial laryngeal nerve. In addition he found that fibres connected the ganglion with the last four cranial nerves and the first cervical nerve.

The communication between the glossopharyngeal and vagus nerves was known (Chauveau, 1891; Dougherty, Habel and Bond, 1958; May, 1964, 1965). It was Chauveau who stated that the jugular ganglion "also receives a division of the glossopharyngeal, and it gives one to this nerve and the external branch of the spinal accessory". May (1964, 1965) described the branches of the vagus to the cranial cervical ganglion.

Only a single carotid sinus nerve filament has been reported in the sheep (Dougherty, Habel and Bond, 1958; Waites, 1960; May, 1964, 1965). However, more than one carotid sinus filament has been reported in man, primates, Anthropeidea, Lama glama (Mitchell, 1956; Adams, 1958) and African elephant (Elephas africanus) (Eales, 1926).

Also noted in vertebrates was vagal innervation from pharyngeal branches, nodose ganglion or superior laryngeal nerve. It has been reported in man, Marsupials (Didelphys virginiana), Trichosurus, Chiroptera (Pteropus gouldi), Edentata, Primates (A. lorisiformes), Anthropeidea, Glires (rats and rabbits),

Hydrochoerus (guinea-pig), Phocaena, Carnivora (Zalopus), Felidae (cat), Capra, horse, okapi, camel and Lama glama (Adams, 1958); and also in Insectivora (Erinaceus europaeus) (Adams, 1957a) and in the dog (Gerard and Billingsley, 1923).

RESULTS

A. MODE OF BRANCHING OF THE CAROTID TREE

(see footnotes on p 27)

The common carotid artery (A. carotis communis) terminated in all but two specimens at the level of the jugulothyroid and digastric muscles by dividing into internal carotid, occipital, ascending pharyngeal, cranial laryngeal and external carotid arteries. In the other two specimens, its termination was about 1-1½ cm caudal to the jugulothyroid and digastric muscles. The occipital and ascending pharyngeal arteries arose separately in 11 specimens (Figs. 2-3,4; 3-1,2; 4-1,2; 6), by a common trunk (the occipito-ascending pharyngeal trunk) in 25 specimens (Figs. 1; 2-1,2; 3-3,4; 5), or both in common with the cranial laryngeal artery in 4 specimens (Fig. 4-3,4). In 3 specimens the occipital artery arose separately and only the ascending pharyngeal artery arose in common with the cranial laryngeal artery.

The internal carotid artery (A. carotis interna) was the first arterial branch given off from the dorsomedial aspect of the common carotid artery immediately caudal to the occipital or occipito-ascending pharyngeal trunk (Figs. 5; 6; 34). In all the lambs only a few millimetres of the artery at or near its origin, was fibrosed and occluded while the rest of the artery was still patent. In the adults the internal carotid artery was merely a white fibrous cord which extended dorsocranially to the petro-

Key to Figs. 1, 2, 3 and 4.

Branching Patterns of the Carotid Trifurcation and Variations
in the Position of the Carotid Body. Lateral Views.

Figs. 1, 2, 3 and 4: 1 - left, 2 - right, 3 - left, 4 - right

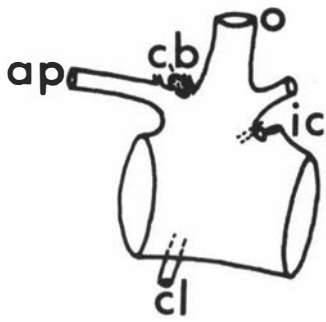
Abbreviations

- ap - ascending pharyngeal artery
- cb - carotid body
- cc - common carotid artery
- cl - cranial laryngeal artery
- ic - internal carotid artery
- m - muscular branch
- o - occipital artery
- opt - occipitoascending pharyngeal arterial trunk

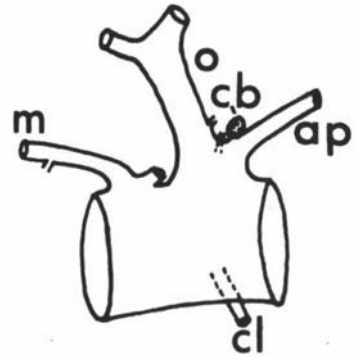
The gross anatomical studied were made on the 22 animals referred to on p 4, plus the 18 animals used for histology and denervation experiments (see p 6 and p 10).

Each of the illustrations in Figs 1-34 is from a separate animal, except for Figs 21 and 26 which are from the same animal.

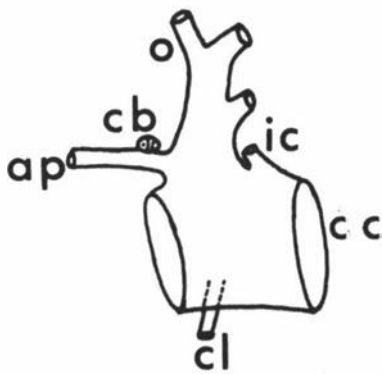
Fig. 1



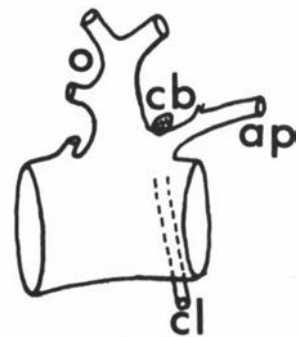1



2

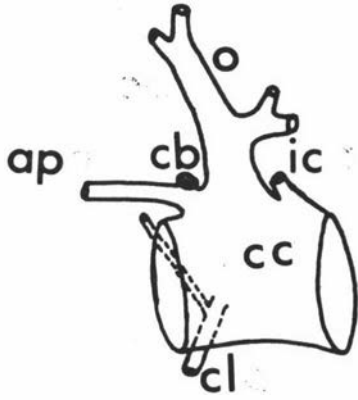


3

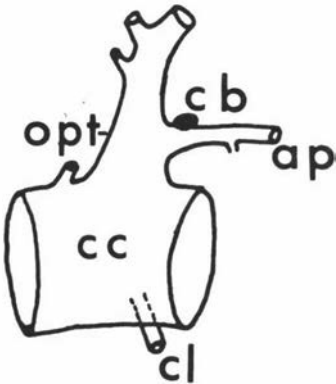


4

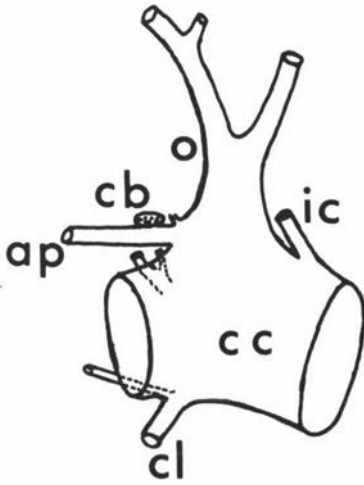
Fig. 2



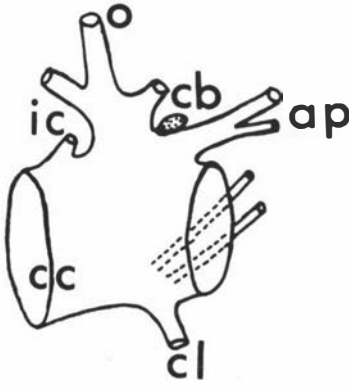
1



2

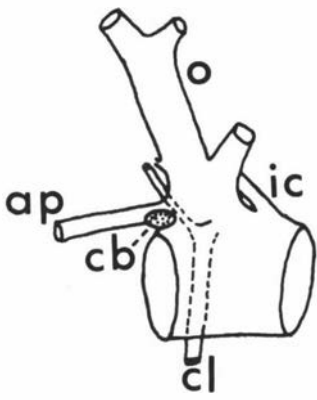


3

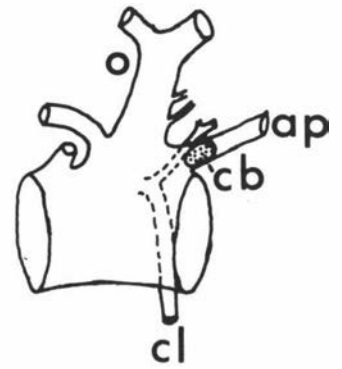


4

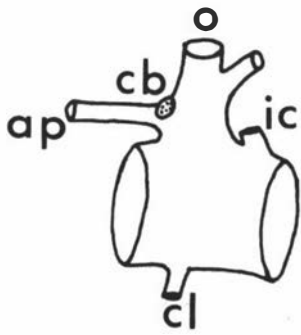
Fig. 3



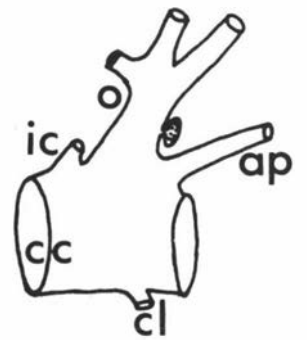1



2

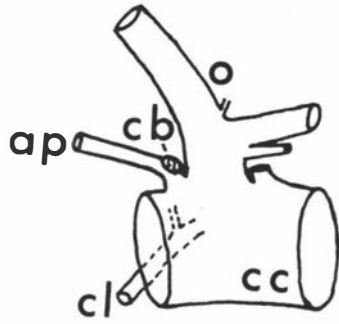


3

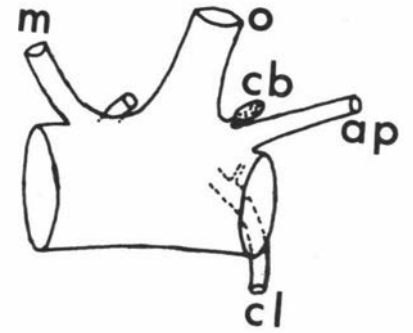


4

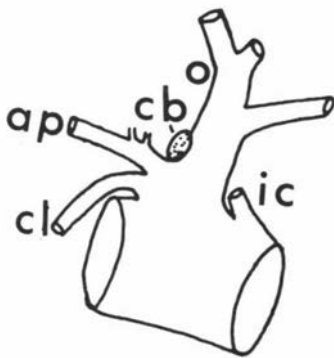Fig. 4



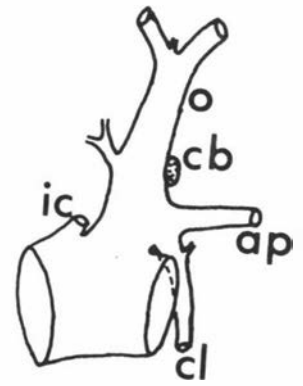
1



2



3



4

occipital fissure. In one specimen (a lamb) the internal carotid, a muscular branch, and the cranial laryngeal arteries arose by a common trunk.

The occipital artery (A. occipitalis) arose from the common trunk formed by the occipitoascending pharyngeal trunk with the cranial laryngeal artery in 4 specimens (Fig. 4-3,4).

In a true sense, the occipital, ascending pharyngeal, cranial laryngeal, and caudal pharyngeal arteries arose from the external carotid artery, if the origin of the internal carotid artery is regarded as the termination of the common carotid artery. The major branches of the occipital artery are: ascending pharyngeal artery, a muscular branch, middle meningeal artery, condyloid artery, and an occipital branch. The middle meningeal and condyloid arteries sometimes arose as a common trunk.

The ascending pharyngeal artery (A. pharyngea ascendens) arose from the medial aspect of the common carotid artery close to the occipital artery in 11 specimens, from the occipitoascending pharyngeal trunk in 25 specimens, or from the common trunk formed by the occipitoascending pharyngeal trunk with the cranial laryngeal artery in 4 specimens. In three specimens it arose in common with the cranial laryngeal artery. Its origin, anteromedial to the origin of occipital artery, was guarded dorsolaterally by the arterial cushion projected caudoventrad from the junction of the external carotid artery and the anterolateral part of the occipitoascending pharyngeal trunk (Figs. 5; 6).

The arterial branch which May (1965) designated as the caudal pharyngeal artery arose usually from the external carotid

Key to Figs. 5 and 6.

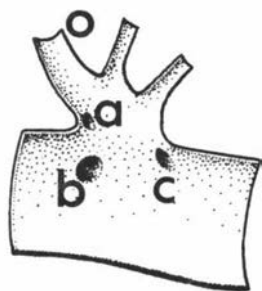
Origin of the Arteries of the Carotid Trifurcation as Seen
from Within. Lateral Views.

1 - left, 2 - right, 3 - left, 4 - right

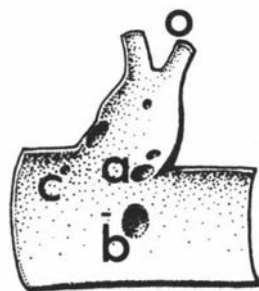
Abbreviations

- a - ascending pharyngeal artery
- b - cranial laryngeal artery
- c - internal carotid artery
- o - occipital artery

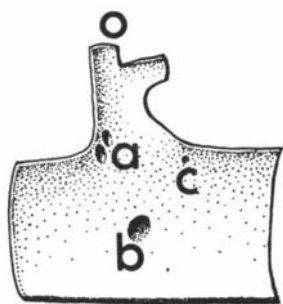
Fig. 5



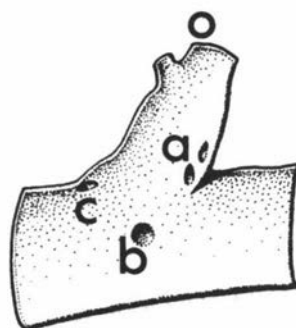
1



2

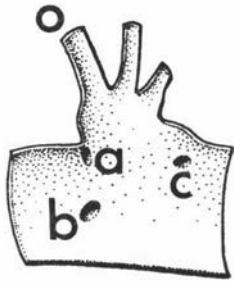


3

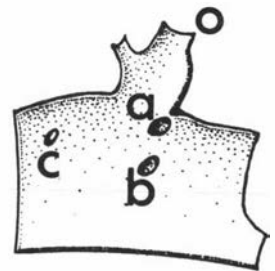


4

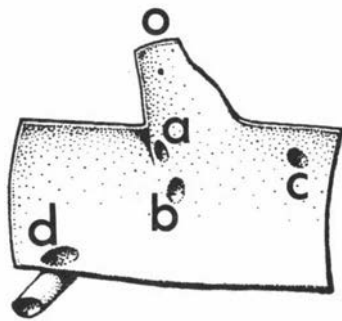
Fig. 6



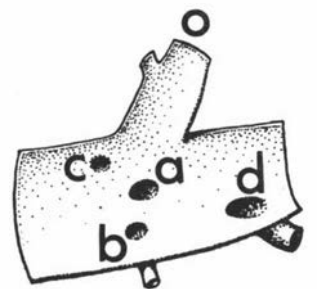
1



2



3



4

artery. In a few specimens one or two arterial branches were usually seen.

The cranial laryngeal artery (A. laryngea cranialis) arose from the medial wall of the common carotid artery slightly ventral to or close to the origin of the ascending pharyngeal artery in 32 specimens, or from the occipitoascending pharyngeal trunk in 4 specimens, or it arose in common with ascending pharyngeal artery in 3 specimens (Fig. 12-1). In one specimen it arose from the common carotid artery in common with the internal carotid artery and a muscular branch (Fig. 11-1). In 7 specimens it gave off a small pharyngeal branch (Ramus pharyngeus) (Figs. 2-1,3; 3-1,2; 4-1,2,4; 34).

B. RELATIONSHIP OF THE CAROTID TREE TO THE SURROUNDING STRUCTURES

The glossopharyngeal nerve (N. glossopharyngeus) emerged from the jugular foramen (Foramen lacerum posterius) and lay cranial to the vagus nerve, medial to the osseous bulla and caudal to the internal carotid nerve (Figs. 17 to 19). It received one or two communicating branches from the vagus nerve within the jugular foramen. The petrosal ganglion (Ganglion distale, N.A.V., 1968) was not distinct in the lambs. It detached the carotid sinus nerve (Ramus sinus carotici) at the level of its emergence from the jugular foramen or a few millimetres below the foramen (Figs. 17 to 20; Plate I). It lay cranial to or lateral to the cranial cervical ganglion and ran cranioventrad to the lateral aspect of the medial retropharyngeal lymph node where it divided into pharyngeal and lingual branches. It also detached a small branch (Ramus n. stylopharyngei caudalis) to the caudal

Key to Figs. 7, 8, 9, 10 and 11.

Innervation of the Carotid Trifurcation by the Carotid Sinus Nerve. Lateral Views.

Figs. 7, 8, 9 and 10: 1 - left, 2 - right, 3 - left, 4 - right

Fig. 11: 1 - right, 2 - left, 3 - right, 4 - left

Abbreviations

- ap - ascending pharyngeal artery
- br - communicating branch to external
carotid nerve
- cl - cranial laryngeal artery
- csn - carotid sinus nerve
- csn1 - carotid sinus nerve first branch
- csn2 - carotid sinus nerve second branch
- ic - internal carotid artery
- m - muscular branch
- o - occipital artery
- opt - occipitoascending pharyngeal arterial trunk
- vb - a small branch from pharyngeal branch of
vagus nerve

Fig. 7

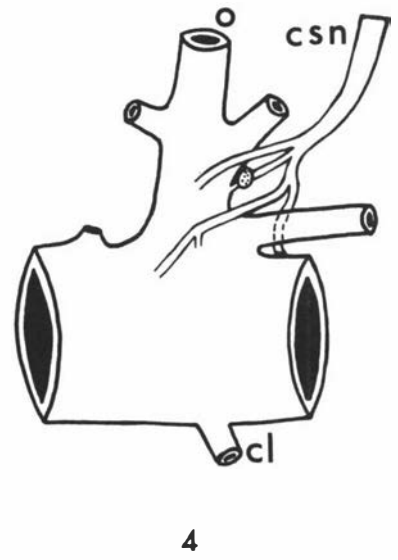
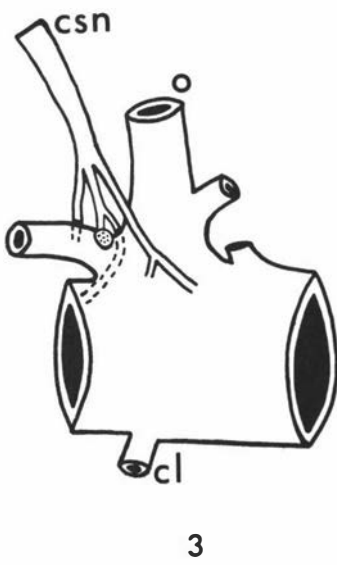
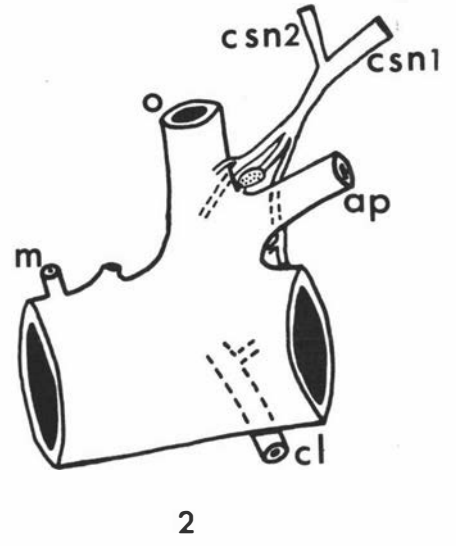
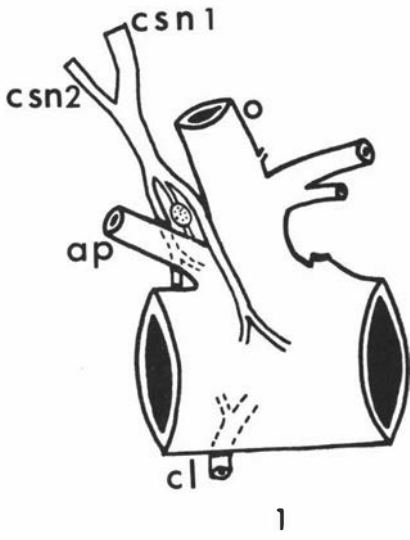


Fig. 8

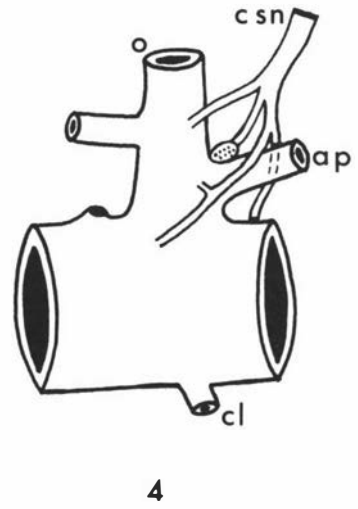
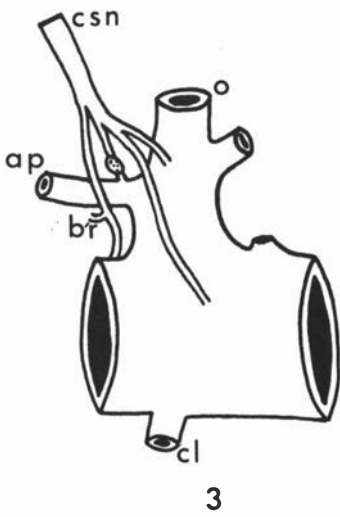
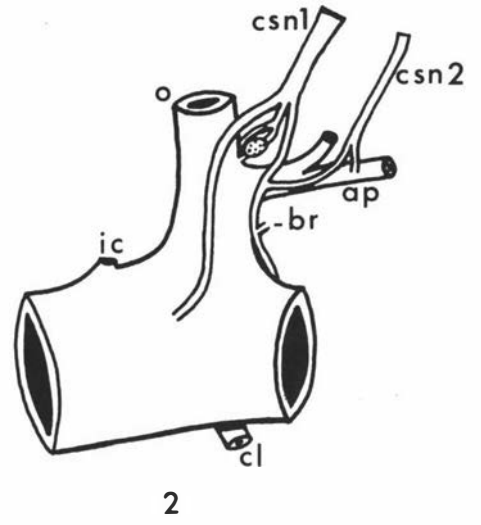
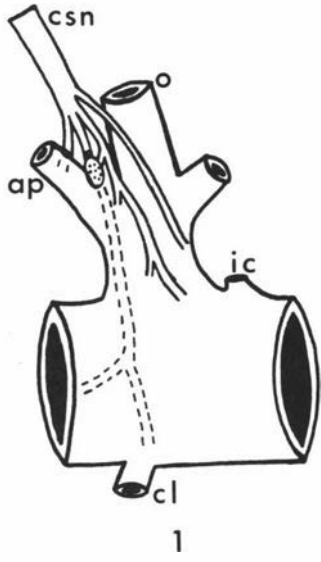
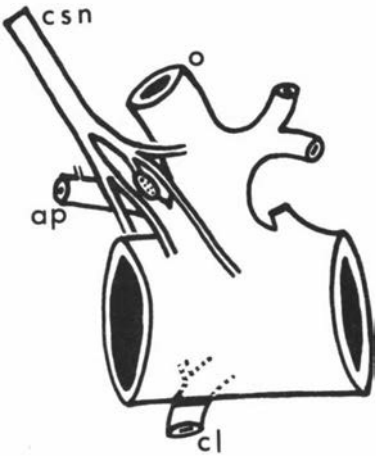
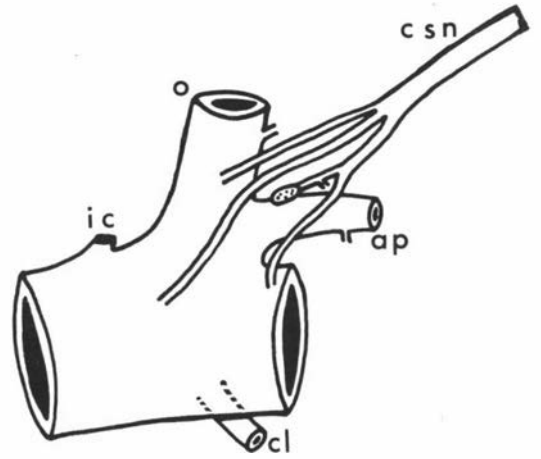


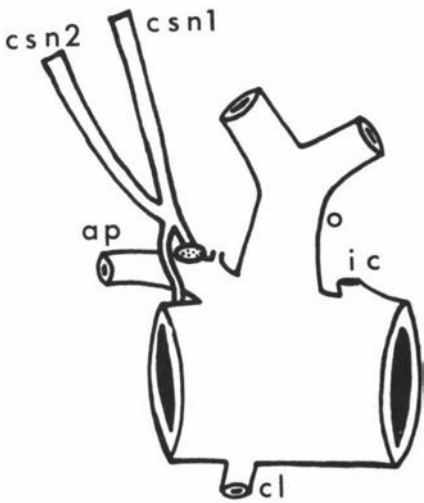
Fig. 9



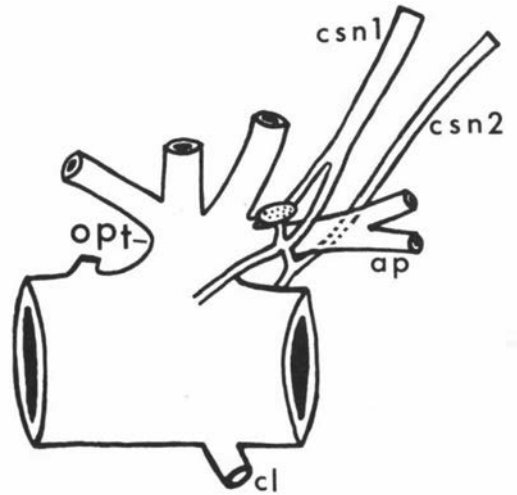
1



2



3



4

Fig.10

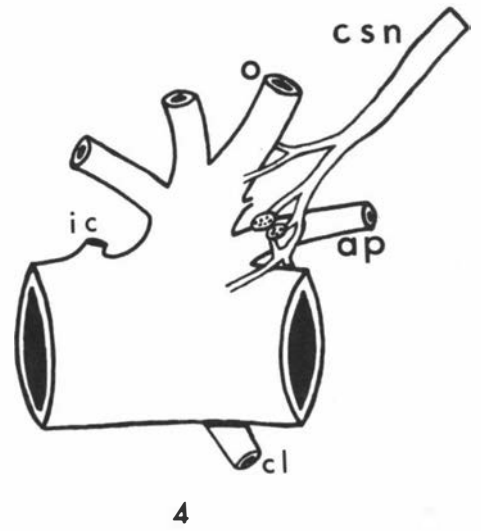
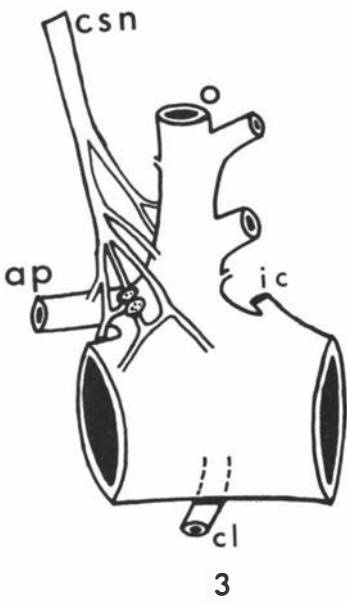
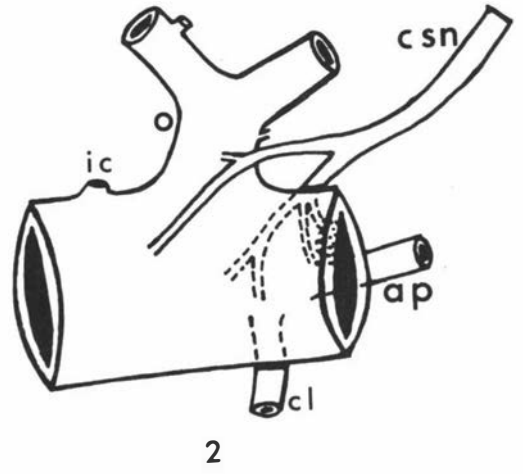
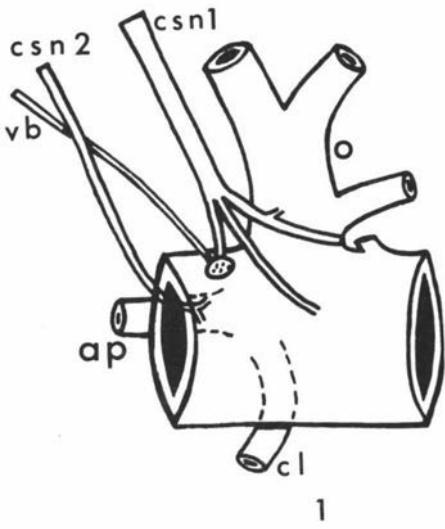
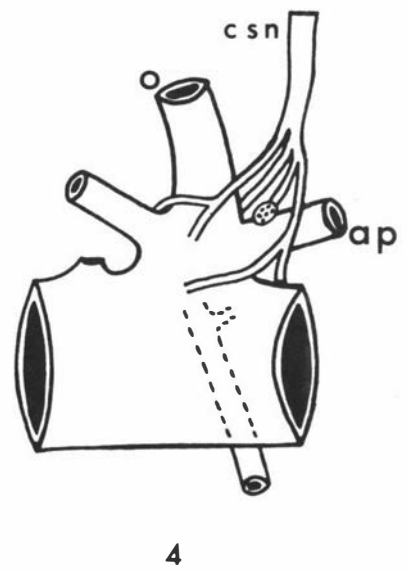
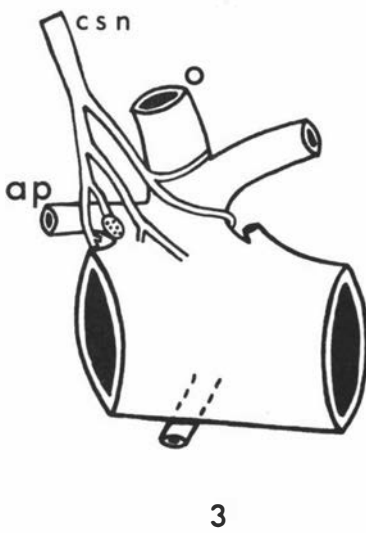
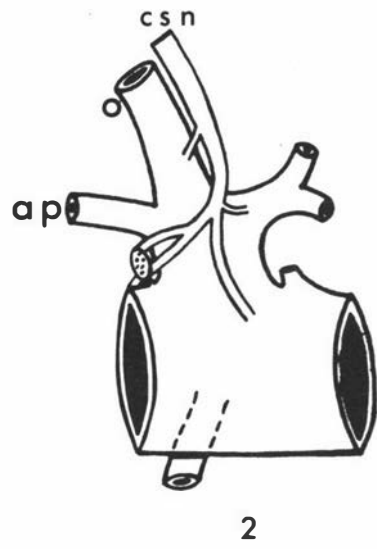
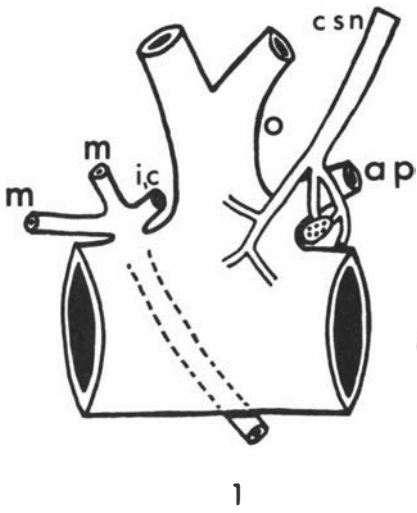


Fig.11



stylopharyngeus muscle. The pharyngeal branch was usually associated with the dorsal of the two pharyngeal rami of the vagus, but there was no distinct formation of a classical pharyngeal plexus in the fresh specimens. The pharyngeal plexus was seen in the routinely embalmed specimens. The glossopharyngeal nerve also received communicating branches from the vagus (Ramus communicans cum n. glossopharyngeo) in 8 specimens (Figs. 24; 28; 31), and from the pharyngeal branches of the vagus in 10 specimens (Figs. 19; 22; 25 to 27).

The cranial cervical ganglion was a pale yellow, fusiform body and was approximately 6-9 mm long and 4-5 mm wide in the lambs. It was related cranially or laterally to the glossopharyngeal nerve, caudolaterally to the internal carotid artery and caudally to the condyloid artery in the lambs (Figs. 17 to 20). The internal carotid nerve (N. caroticus internus) arose from the cranial extremity of the ganglion to enter the jugular foramen cranial to the glossopharyngeal nerve. The cervical sympathetic trunk and the external carotid nerve (N. caroticus externus) usually left the caudal extremity of the ganglion (Fig. 16; Plate I-3). The cervical sympathetic trunk was related laterally to the internal carotid and occipital arteries, pharyngeal branches of the vagus and cranial laryngeal nerve, and caudally to the vagus. Usually there was a big connection between the external carotid nerve and the pharyngeal branch (ventral) of vagus nerve and the cranial laryngeal nerve.

The vagus nerve (N. vagus) emerged from the jugular foramen caudal to the glossopharyngeal nerve and cranial to the accessory nerve. In its ventrocaudal course it was related medially to the

Key to Figs. 12, 13, 14 and 15.

Innervation of the Carotid Trifurcation by the External Carotid Nerve (Sympathetic). Lateral Views.

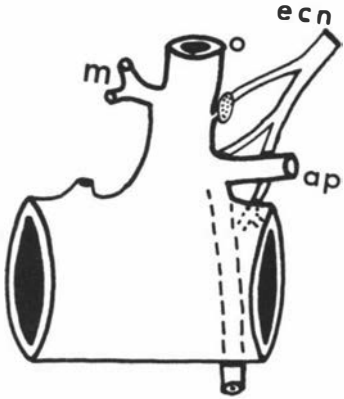
Figs. 12 and 15: 1 - right, 2 - left, 3 - left, 4 - right

Figs. 13 and 14: 1 - left, 2 - right, 3 - left, 4 - right

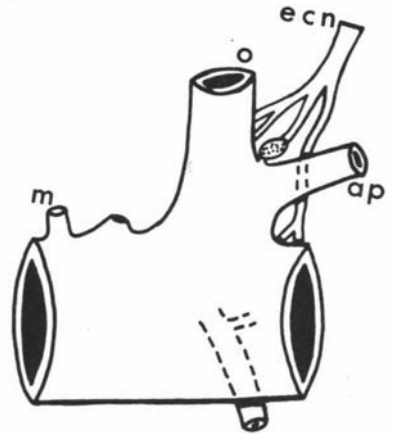
Abbreviations

- ap - ascending pharyngeal artery
- br - communicating branch to carotid
sinus nerve
- ecn - external carotid nerve (sympathetic
branch from cranial cervical ganglion
to carotid trifurcation)
- la - lingual artery
- m - muscular branch
- o - occipital artery

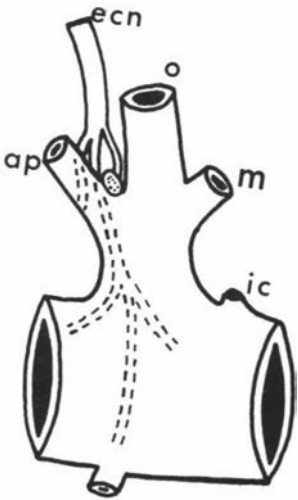
Fig.12



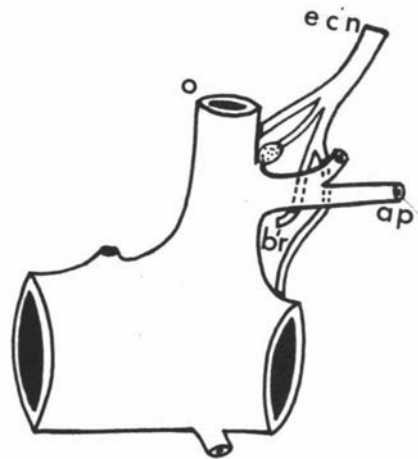
1



2

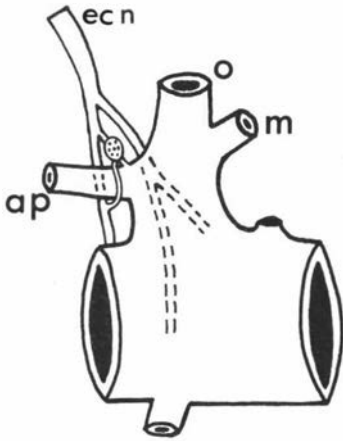


3

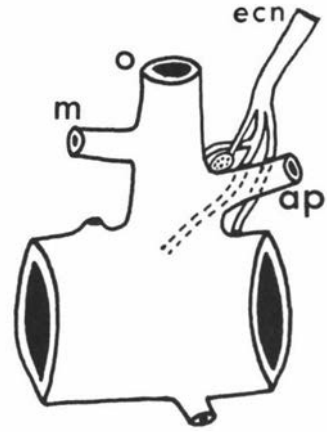


4

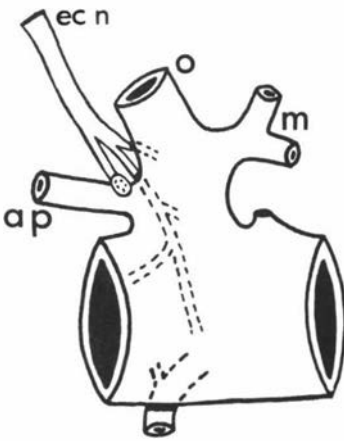
Fig. 13



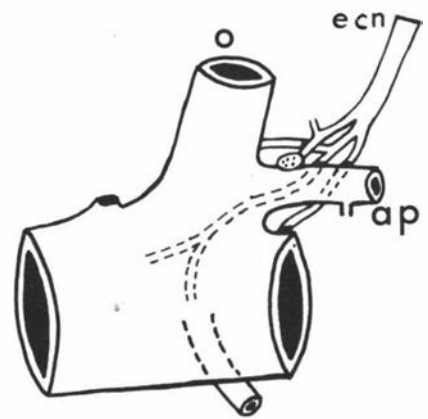
1



2



3



4

Fig. 14

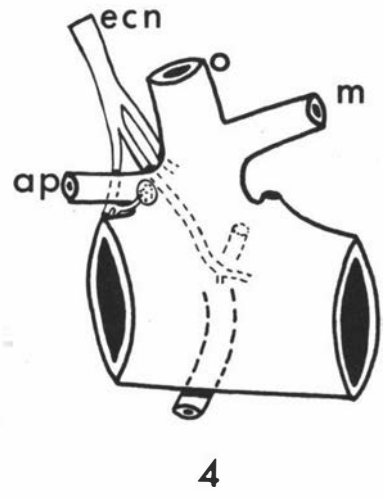
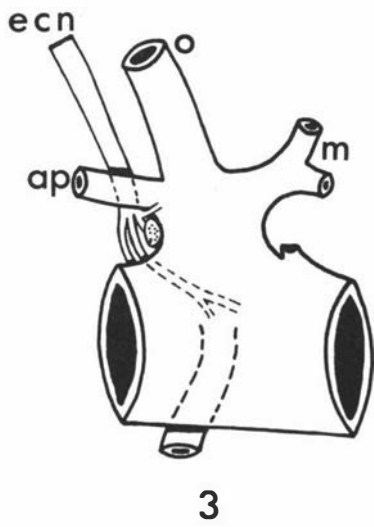
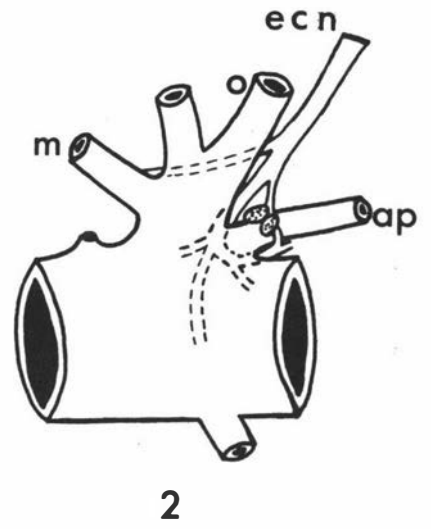
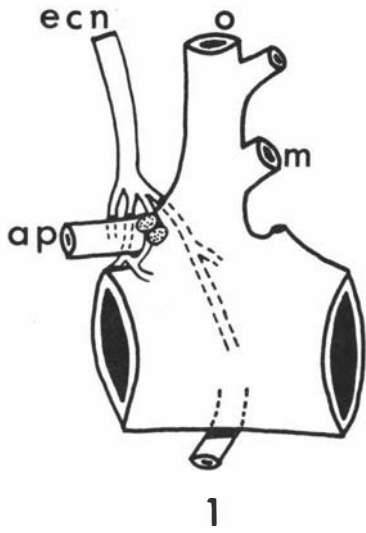
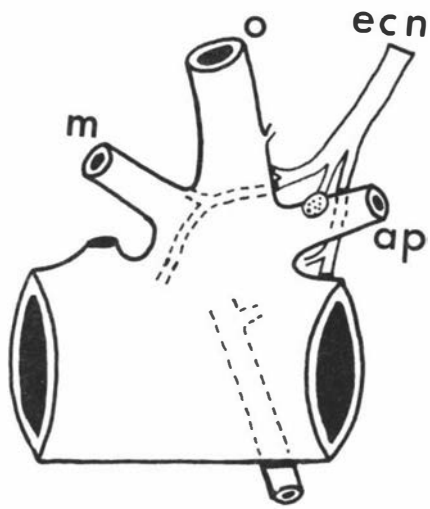
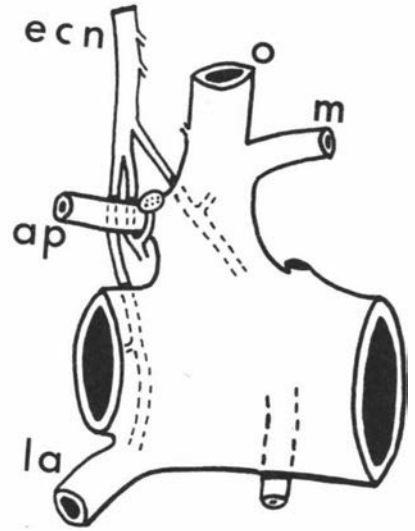


Fig. 15



1



2

accessory nerve with which it was enclosed in a common fibrous sheath, and caudally to the hypoglossal nerve only up to the level of the origin of the occipital artery where it was separated from the accessory nerve by the hypoglossal nerve (Figs. 19; 20). It gave off the cranial laryngeal nerve before it became associated ventrally with the cervical sympathetic trunk at the dorsal aspect of the termination of the common carotid artery. Above the origin of the cranial laryngeal nerve it exhibited a broad and flattened nodose ganglion (Ganglion distale, N.A.V., 1968). The pharyngeal branch(es) (pharyngoesophageal nerve), usually a dorsal one and a ventral one (Ramus oesophageus, N.A.V., 1968), were detached from the vagus just above the nodose ganglion. One or two anastomoses between the glossopharyngeal and vagus nerves were found in 8 specimens, and in 10 specimens communicating branches were present between the glossopharyngeal and pharyngeal branches of the vagus nerve.

The accessory nerve (N. accessorius) emerged from the jugular foramen caudal to the vagus nerve and ran caudoventrad lateral to the **vagus**. It was then separated from the vagus by the hypoglossal nerve and continued in the atlantal fossa. On the lateral aspect of the longus capitis muscle it divided into a dorsal and a ventral branch. The dorsal branch was associated with the muscular branch of the occipital artery while the ventral branch accompanied the tendon of the sternomastoid muscle.

The hypoglossal nerve (N. hypoglossus), after its emergence from the hypoglossal foramen, became associated with the medial aspect of the accessory nerve to which it was attached by loose connective tissue. It then passed between the vagus and accessory nerve and curved around the medial aspect of the origin of the occipital

Key to Fig. 16.

Variations in the Origin of the External Carotid Nerve
(Sympathetic Branch from the Cranial Cervical Ganglion to
the Carotid Trifurcation). Lateral Views.

Abbreviations

- c cg - cranial cervical ganglion
- c ct - cervical sympathetic trunk
- e cn - external carotid nerve
- i cn - internal carotid nerve

Key to Fig. 17.

Innervation of the Right Carotid Trifurcation. Lateral View.

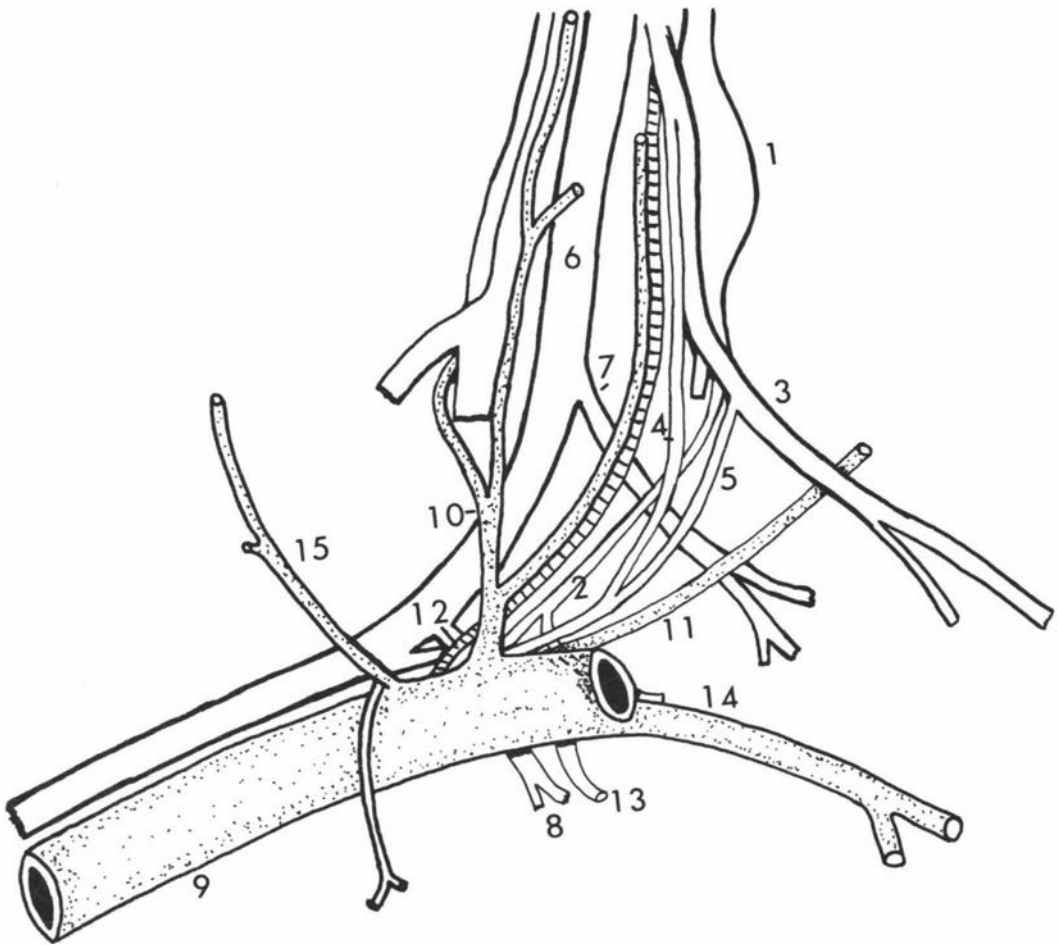
- 1 - cranial cervical ganglion
- 2 - external carotid nerve
- 3 - glossopharyngeal nerve
- 4 - carotid sinus nerve, first branch
- 5 - carotid sinus nerve, second branch
- 6 - vagus nerve
- 7 - pharyngeal branch of vagus nerve
- 8 - cranial laryngeal nerve
- 9 - common carotid artery
- 10 - occipital artery
- 11 - ascending pharyngeal artery
- 12 - internal carotid artery
- 13 - cranial laryngeal artery
- 14 - lingual artery
- 15 - muscular branch

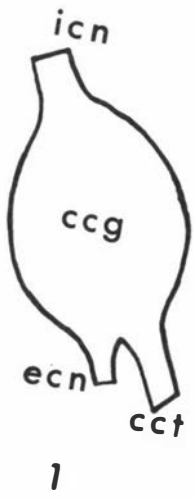

Fig.16

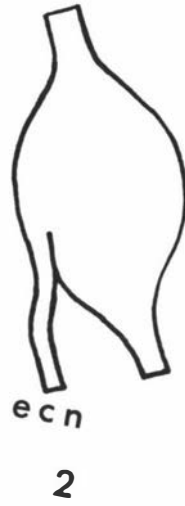

Fig. 17



artery or the occipitoascending pharyngeal trunk to gain the lateral surface of the common carotid artery. It detached a communicating branch to the ventral branch of the first cervical nerve before or after it passed between the vagus and accessory nerve. While it was related to the dorsal or lateral aspect of the common carotid artery it gave off a muscular branch which passed along and crossed the lateral surface of the common carotid artery to innervate the omohyoid, sternohyoid and sternothyroid muscles, with or without receiving anastomoses from the first two or three ventral branches of the cervical nerves. The hypoglossal nerve then ran cranio-ventrad, lying under cover of the caudal belly of the digastric muscle and the submandibular salivary gland to be associated with the lateral aspect of the lingual artery.

C. GROSS ANATOMY OF THE CAROTID BODY AND CAROTID SINUS

(a) Carotid Body

The carotid body of the lamb, examined under the dissecting microscope, appeared usually as oval or rounded, richly vascularized organs approximately 1 mm long and 1 mm wide. A single carotid body was found on each carotid tree in all specimens except two lambs in which they were seen as distinctly bilobed organs (Figs. 10-3,4; 14-1,2). The lobulation of the organ was distinct in the adults.

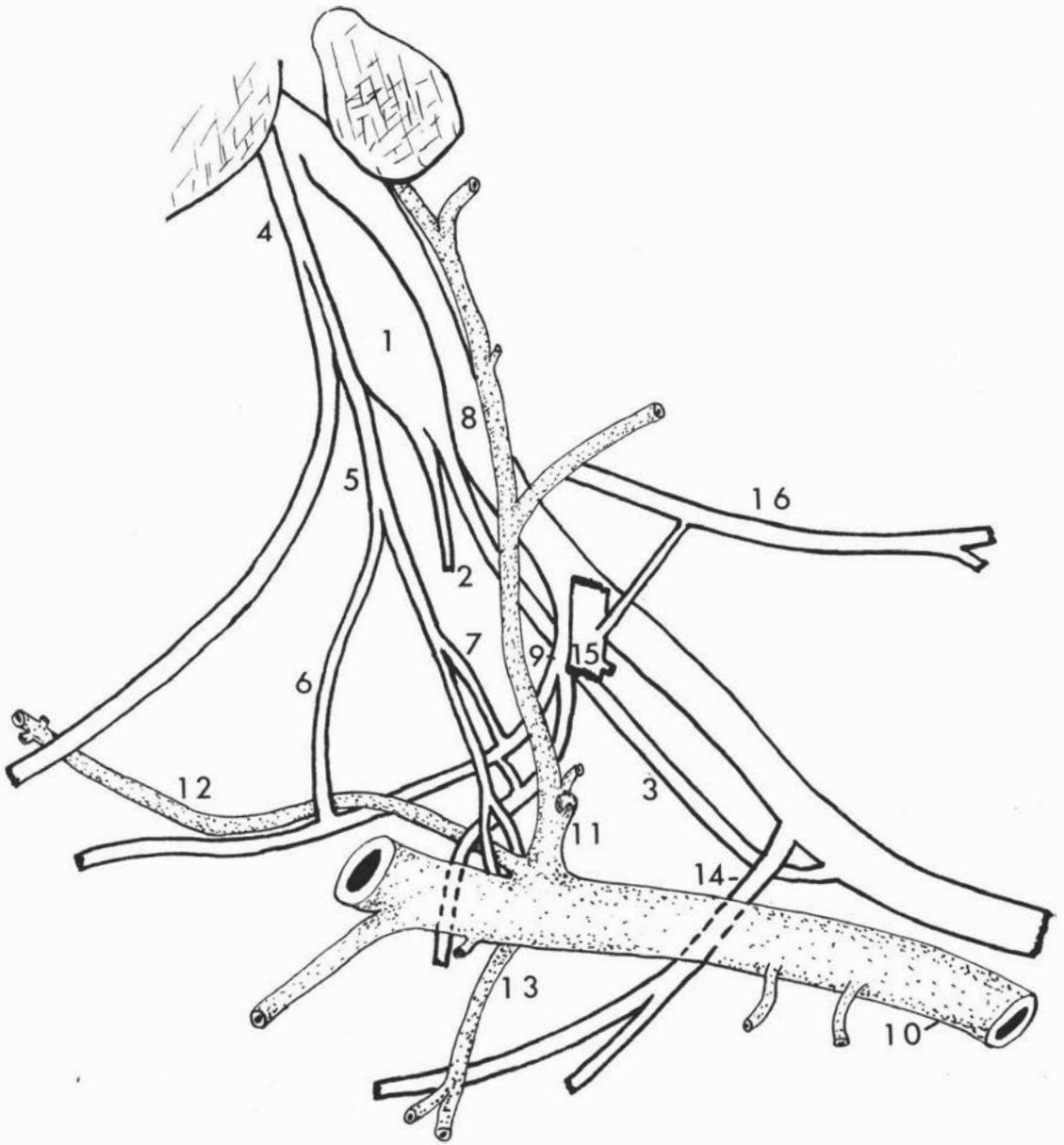
The position of the carotid body was on the anterolateral aspect of the origin of the occipital artery in 7 specimens (Figs. 3-4; 4-4), at or near the origin of the ascending pharyngeal artery in 38 specimens, and on the dorsal aspect of the origin of the external carotid artery in one specimen. The position of the carotid body on the ascending pharyngeal artery was found to be

Key to Fig. 18.

Innervation of the Left Carotid Trifurcation. Lateral
View.

- 1 - cranial cervical ganglion
- 2 - external carotid nerve
- 3 - cervical sympathetic trunk
- 4 - glossopharyngeal nerve
- 5 - carotid sinus nerve
- 6,7 - communicating branches to pharyngeal
branch of vagus nerve
- 8 - vagus nerve
- 9 - pharyngeal branch of vagus nerve
- 10 - common carotid artery
- 11 - occipital artery
- 12 - ascending pharyngeal artery
- 13 - cranial laryngeal artery
- 14 - cranial laryngeal nerve
- 15 - hypoglossal nerve
- 16 - spinal accessory nerve

Fig. 18

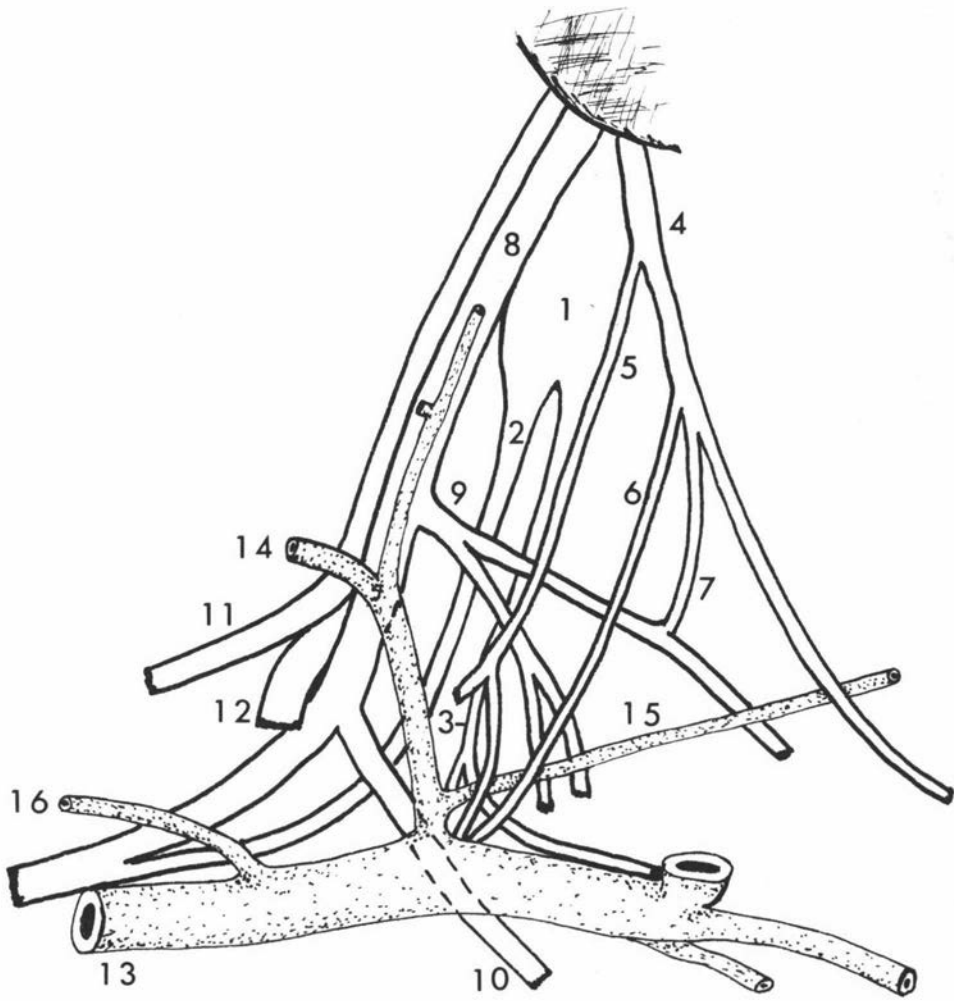


Key to Fig. 19.

Innervation of the Right Carotid Trifurcation. Lateral
View.

- 1 - cranial cervical ganglion
- 2 - cervical sympathetic trunk
- 3 - external carotid nerve
- 4 - glossopharyngeal nerve
- 5 - carotid sinus nerve, first branch
- 6 - carotid sinus nerve, second branch
- 7 - communicating branch between glossopharyngeal
nerve and pharyngeal branch of vagus nerve
- 8 - vagus nerve
- 9 - pharyngeal branch of vagus nerve
- 10 - cranial laryngeal nerve
- 11 - spinal accessory nerve
- 12 - hypoglossal nerve
- 13 - common carotid artery
- 14 - occipital artery
- 15 - ascending pharyngeal artery
- 16 - muscular branch

Fig.19



variable. It was on the ventrolateral aspect of the origin of this artery, lying between it and the origin of the external carotid artery, in 7 specimens (Fig. 3-1,2); on the dorsal or lateral aspect, slightly away from the origin of the artery, in 17 specimens (Figs. 1-2,3; 2-3); and on the dorsal aspect of the origin of the artery, lying between it and the occipital artery, in 14 specimens (Figs. 1-4; 2-4; 4-3).

(b) Carotid Sinus

For a few millimetres from its origin the occipital artery or the occipito-ascending pharyngeal trunk was slightly dilated in the lambs, but much more so in the adults. The wall of this "bulb" was thinner than that of the external or common carotid arteries. It corresponds to the carotid sinus in other species.

D. GROSS BLOOD SUPPLY OF THE CAROTID BODY, CAROTID SINUS AND THE ASSOCIATED NERVES AND GANGLIA

(a) Carotid Body

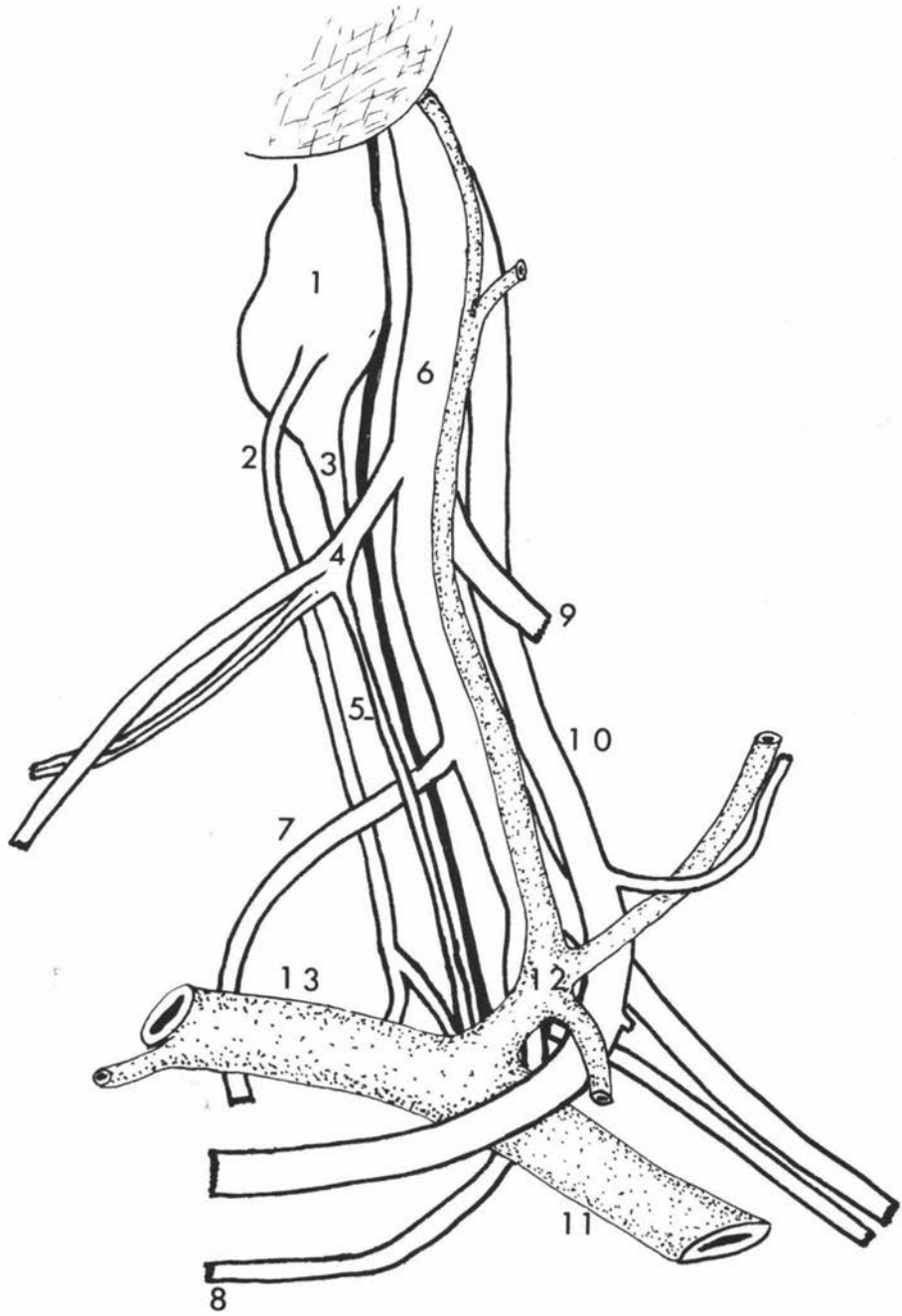
The carotid body in the lamb received a separate arterial branch from the ascending pharyngeal artery (Figs. 24; 35) in 27 specimens (61%), from the occipital artery (Figs. 26; 27) in 9 specimens (20%), from the angle between the origin of ascending pharyngeal and occipital arteries (Fig. 30) in 6 specimens (15%), and from the origin of the external carotid artery in 2 specimens (4%). The artery of the carotid body usually gave off a twig just below the carotid body to supply the distal part of the carotid sinus nerve, the external carotid nerve, the anterolateral aspect of the origin of the occipital artery or occipitoascending

Key to Fig. 20.

Innervation of the Left Carotid Trifurcation. Lateral
View.

- 1 - cranial cervical ganglion
- 2 - external carotid nerve
- 3 - cervical sympathetic trunk
- 4 - glossopharyngeal nerve
- 5 - carotid sinus nerve
- 6 - glossopharyngeal, vagus and spinal
nerves in a common fibrous sheath
- 7 - pharyngeal branch of vagus nerve
- 8 - cranial laryngeal nerve
- 9 - spinal accessory nerve
- 10 - hypoglossal nerve
- 11 - common carotid artery
- 12 - occipital artery
- 13 - external carotid artery

Fig. 20



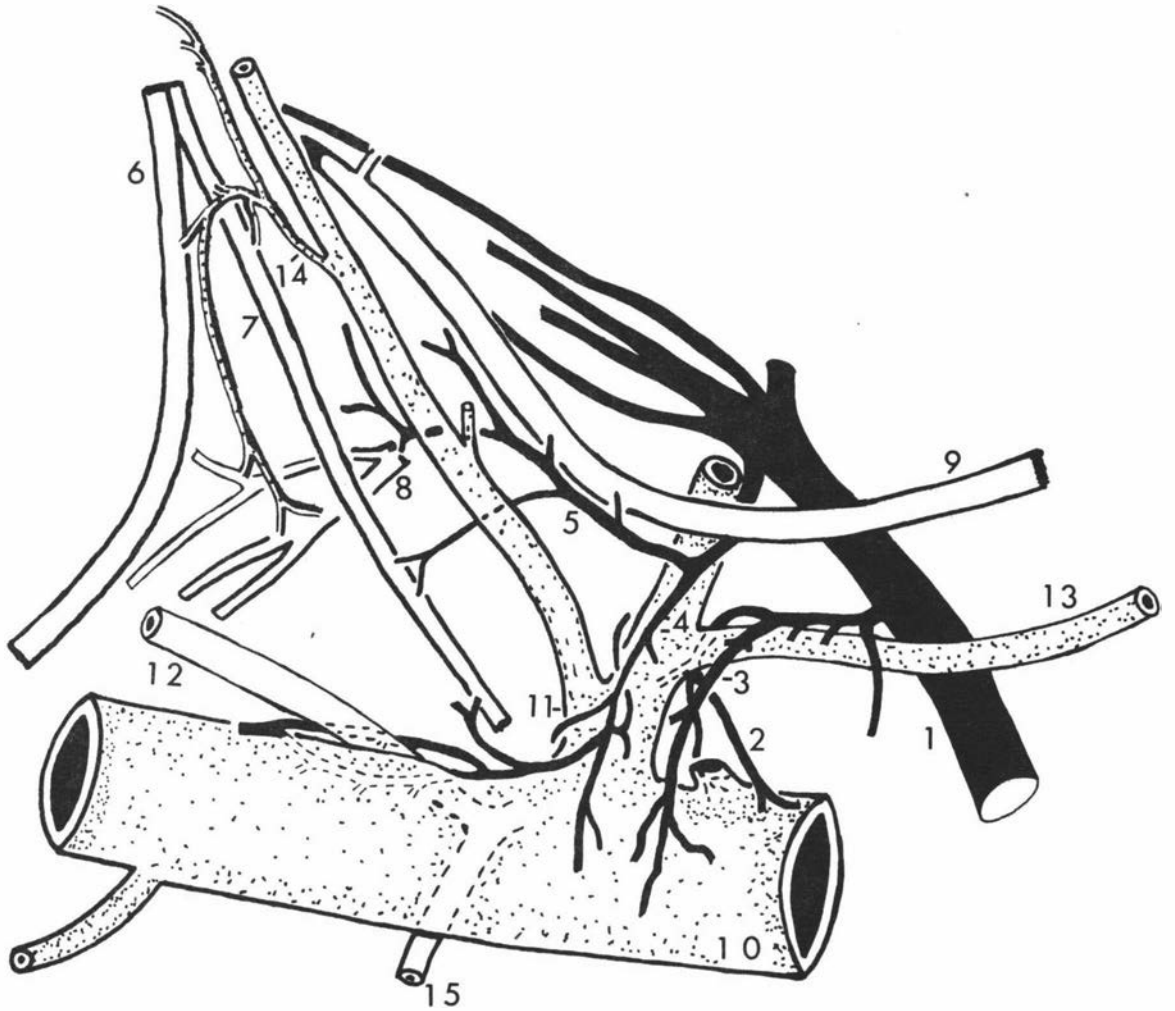
Key to Fig. 21.

Venous Drainage of the Left Carotid Trifurcation.

Lateral View.

- 1 - cranio-occipital vein
- 2,3 - small veins draining common carotid artery
- 4 - vein draining external carotid artery,
carotid sinus and occipital artery
- 5 - vein draining carotid sinus nerve, pharyngeal
branch of vagus nerve, vagus and spinal
accessory nerve
- 6 - glossopharyngeal nerve
- 7 - carotid sinus nerve
- 8 - pharyngeal branch of vagus nerve
- 9 - spinal accessory nerve
- 10 - common carotid artery
- 11 - occipital artery
- 12 - ascending pharyngeal artery
- 13 - muscular branch
- 14 - small artery supplying cranial cervical
ganglion, glossopharyngeal nerve, carotid
sinus nerve and pharyngeal branch of vagus
nerve
- 15 - cranial laryngeal artery

Fig. 21



pharyngeal trunk, and occasionally that part of the hypoglossal nerve which curved around the origin of the occipital artery or occipitoascending pharyngeal trunk and the common carotid artery (Fig. 24). This arterial twig sometimes arose separately, either from the ascending pharyngeal or occipital artery, or from the angle between the origin of the occipital and ascending pharyngeal arteries. The carotid body artery entered the organ at the ventral or caudal aspect to form a glomus (Glomus caroticus).

The veins of the carotid body in the lambs lay superficially on the surface of the organ. There were approximately 8-12 small veins emerging from the carotid body. These soon united to form 1-3 large veins which finally joined other veins from the lateral and medial aspects of the occipital artery or occipitoascending pharyngeal trunk, distal part of the carotid sinus nerve, the external carotid nerve, and the common and external carotid arteries (Figs. 21 to 23; 25 to 29; 31 to 33). This confluent vein then ran alongside the muscular branch of the occipital artery and/or along the occipital artery itself to open finally into the cranio-occipital vein (ventral cerebral vein of Popesko, 1970, or V. occipitalis, N.A.V., 1968) (Figs. 21; 23; 25 to 28; 31; 32) in 15 specimens (68%), into the linguofacial vein (Figs. 22; 33) in 2 specimens (9%) and into both cranio-occipital and linguofacial veins (Fig. 29) in 5 specimens (23%).

(b) Carotid Sinus

The lateral aspect of the origin of the occipital artery or the occipitoascending pharyngeal trunk was supplied by an arterial twig which was detached from the artery of the carotid body in 21 specimens (81%), or came directly from the ascending pharyngeal artery in 4

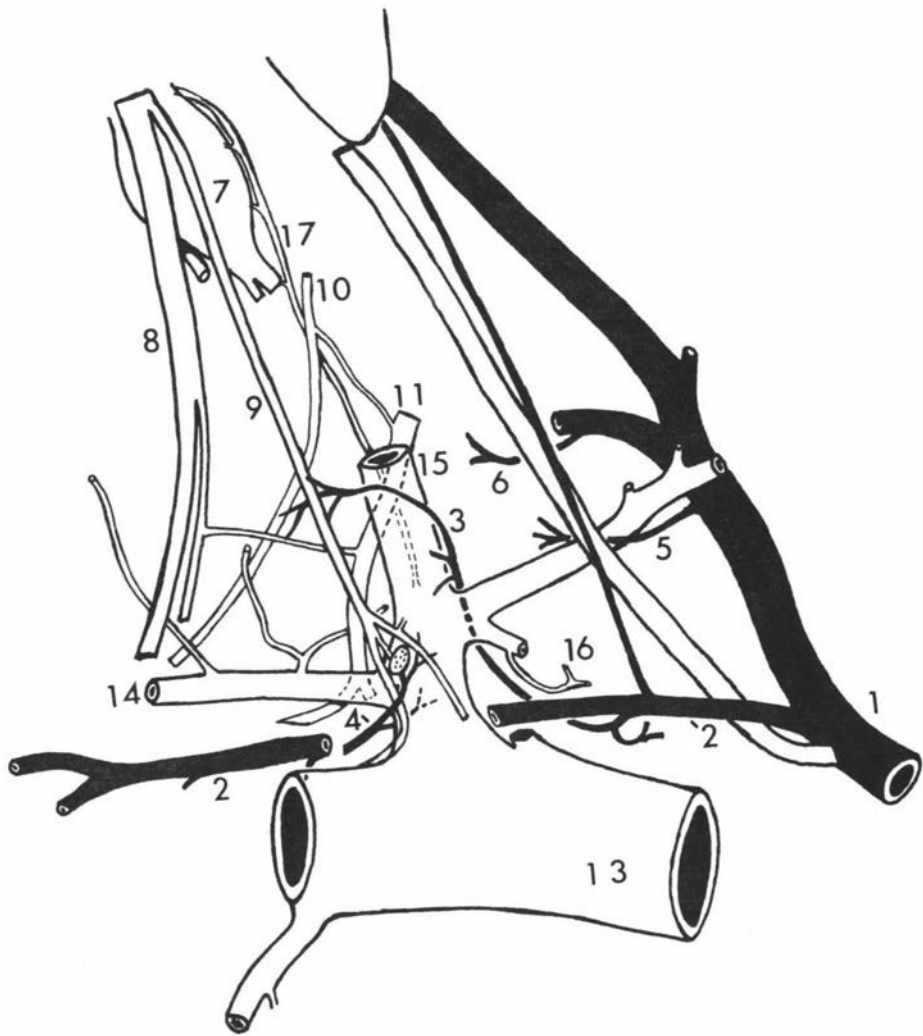
Key to Fig. 22.

Arterial Supply and Venous Drainage of the Left Carotid

Trifurcation. Lateral View.

- 1 - cranio-occipital vein
- 2 - vein draining pharyngeal and carotid regions
- 3 - small vein draining carotid sinus nerve,
occipital artery and hypoglossal nerve
- 4 - small vein draining carotid body and
carotid sinus
- 5,6 - veins draining vagus, spinal accessory
and hypoglossal nerves
- 7 - cranial cervical ganglion
- 8 - glossopharyngeal nerve
- 9 - carotid sinus nerve
- 10,11 - pharyngeal branches of vagus nerve
- 13 - common carotid artery
- 14 - ascending pharyngeal artery
- 15 - occipital artery
- 16 - small artery supplying hypoglossal nerve
- 17 - artery supplying cranial cervical ganglion
and cervical sympathetic trunk

Fig. 22



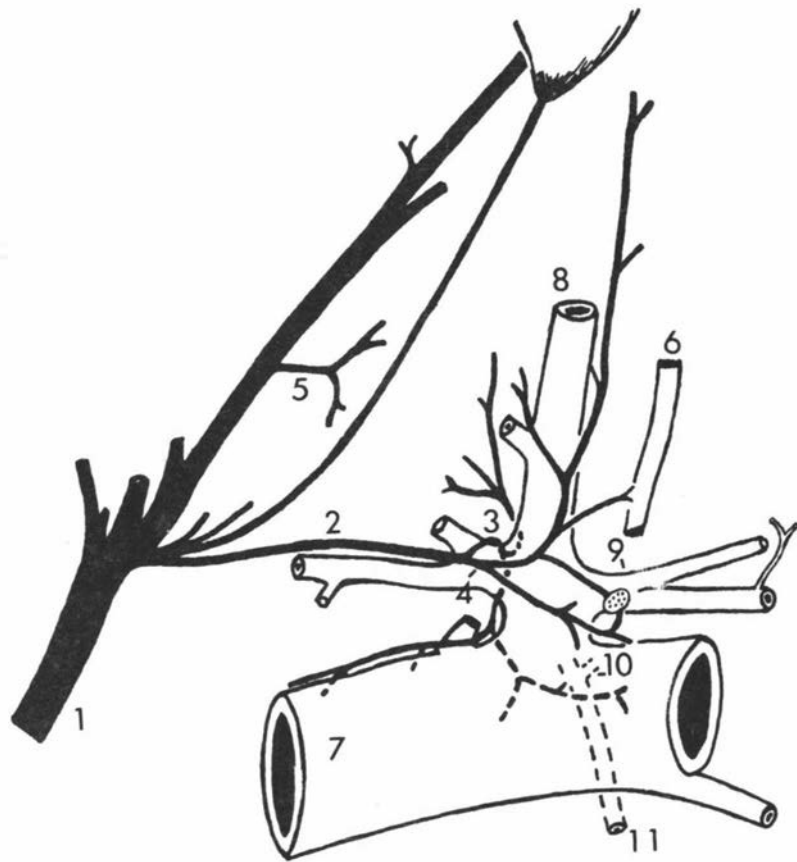
Key to Fig. 23.

Venous Drainage of the Right Carotid Trifurcation.

Lateral View.

- 1 - cranio-occipital vein
- 2 - vein draining carotid trifurcation
- 3 - small vein draining common carotid and external carotid arteries, vagus and spinal accessory nerve
- 4 - vein draining carotid body, carotid sinus, carotid sinus nerve, occipital artery and cranial cervical ganglion
- 5 - vein draining hypoglossal, spinal accessory and vagus nerves
- 6 - carotid sinus nerve
- 7 - common carotid artery
- 8 - occipital artery
- 9 - ascending pharyngeal artery
- 10 - small artery to external carotid nerve, medial retropharyngeal lymph node and muscles of pharynx

Fig. 23



specimens (15%), or from the occipital artery in one specimen (4%). It was not possible to examine grossly the arterial supply to the medial aspect of the sinus.

There were usually two small veins draining the lateral and medial aspects of the origin of the occipital artery or occipito-ascending pharyngeal trunk (Figs. 21 to 23; 27; 29; 31). These veins also drained the carotid body, carotid sinus nerve, external carotid nerve and common carotid and external carotid arteries. In 68% of specimens they either united first or opened separately into the cranio-occipital vein, in 9% they opened into the linguofacial vein, and in 23% the carotid sinus region was drained into both cranio-occipital and linguofacial veins. It was found that the vein draining the medial aspect of the carotid sinus region was usually larger than that draining the lateral aspect.

(c) Glossopharyngeal Nerve

The blood supply to the glossopharyngeal nerve at the pharyngeal region came from the occipital, ascending pharyngeal or external carotid arteries (Figs. 21; 24 to 26; 29). The venous drainage was principally into the cranio-occipital (Figs. 25; 32) or rarely into the linguofacial vein (Fig. 33).

(d) Carotid Sinus Nerve

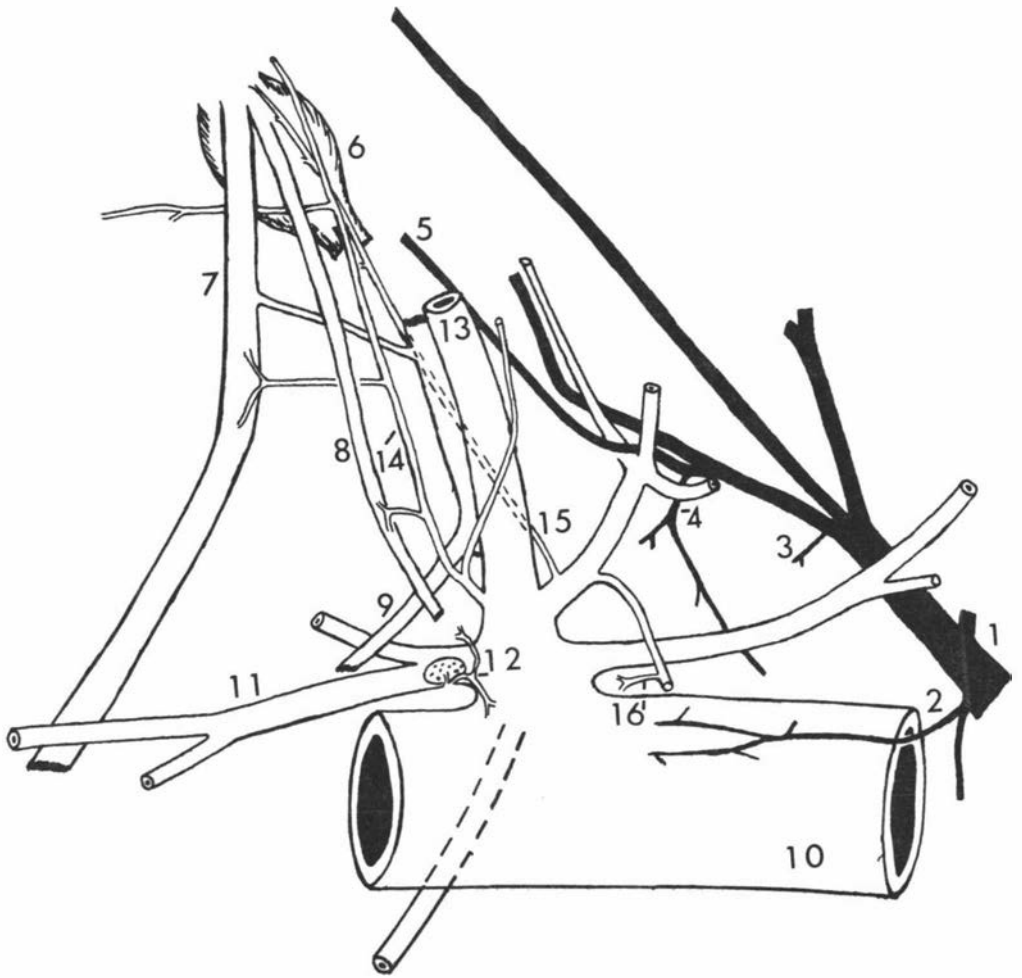
The blood supply to the proximal part of the carotid sinus nerve was from the occipital artery (Figs. 21; 24 to 26; 29; 30), and that to the distal part was usually from the artery of the carotid body (Fig. 24). In a few specimens the blood supply to the distal part of the nerve came from the ascending pharyngeal artery

Key to Fig. 24.

Arterial Supply of the Left Carotid Region. Lateral View.

- 1 - cranio-occipital vein
- 2 - small vein draining lateral aspect of
common carotid artery
- 3 - small vein draining spinal accessory nerve
- 4 - vein draining hypoglossal and vagus nerves
and vago-sympathetic trunk
- 5 - vein draining cranial cervical ganglion
- 6 - cranial cervical ganglion
- 7 - glossopharyngeal nerve
- 8 - carotid sinus nerve
- 9 - pharyngeal branch of vagus nerve
- 10 - common carotid artery
- 11 - ascending pharyngeal artery
- 12 - carotid body artery supplying carotid sinus,
external carotid and carotid sinus nerves
- 13 - occipital artery
- 14 - artery supplying glossopharyngeal nerve and
carotid sinus nerve
- 15 - artery supplying cranial cervical ganglion,
external carotid nerve and cervical
sympathetic trunk

Fig. 24



Key to Fig. 25.

Arterial Supply and Venous Drainage of the Right Carotid

Trifurcation. Lateral View.

- 1 - cranio-occipital vein
- 2 - small vein draining accessory, hypoglossal and vagus nerves
- 3 - vein draining cranial cervical ganglion, external carotid nerve and cervical sympathetic trunk
- 4 - vein draining pharynx, carotid body, carotid sinus and common carotid artery
- 5 - small vein draining vagus nerve
- 6 - vein draining glossopharyngeal nerve, carotid sinus nerve and pharyngeal branch of vagus nerve
- 7 - small vein draining medial side of common carotid artery, cranial laryngeal artery and external carotid artery
- 8 - glossopharyngeal nerve
- 9 - carotid sinus nerve
- 10 - communicating branch between glossopharyngeal nerve and pharyngeal branch of vagus nerve
- 11 - pharyngeal branch of vagus nerve
- 12 - common carotid artery
- 13 - artery to hypoglossal nerve
- 14 - artery to cranial cervical ganglion, cervical sympathetic trunk, external carotid nerve, carotid sinus nerve, glossopharyngeal nerve and pharyngeal branch of vagus nerve
- 15 - ascending pharyngeal artery

or from both the carotid body artery and the cranial laryngeal artery. The venous drainage was usually into the cranio-occipital vein (Figs. 21 to 23; 25; 26; 28; 32) or rarely into the linguofacial vein (Fig. 33).

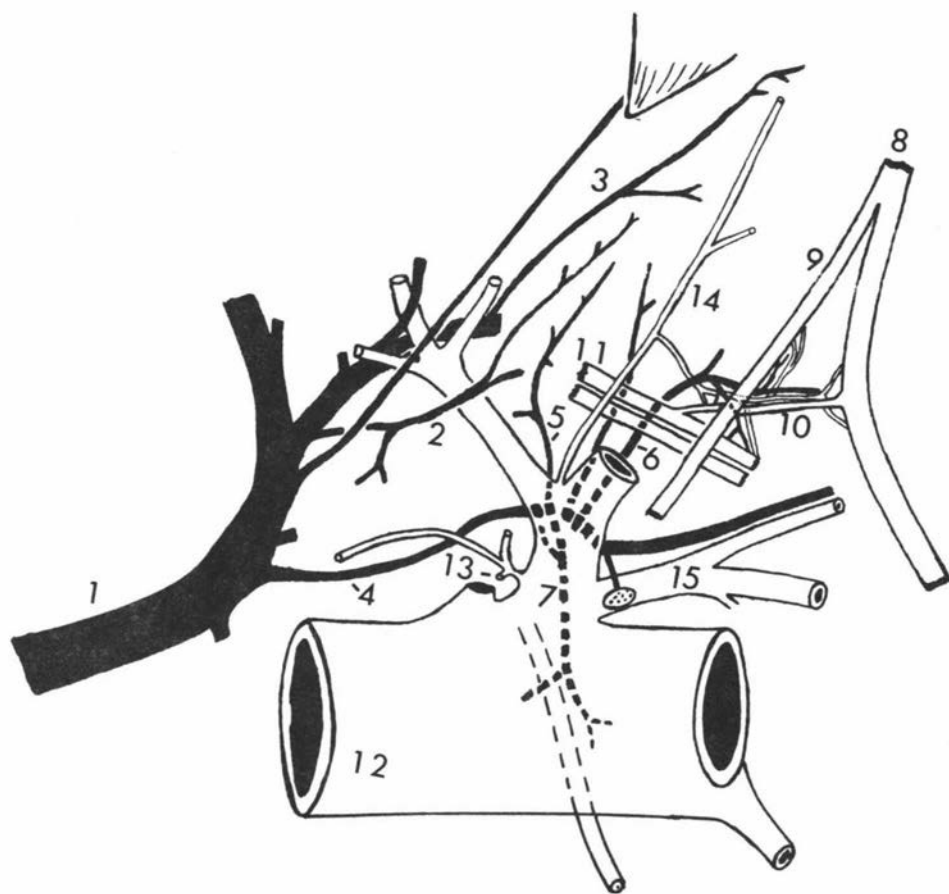
(e) Cranial Cervical Ganglion

The blood supply to the cranial cervical ganglion was from the cranial laryngeal artery (Fig. 27) in one specimen (6%), from the ascending pharyngeal artery in 4 specimens (24%), and from the occipital artery (Figs. 21 to 25; 25 to 29; 31) in the remaining 10 specimens (70%). However, in 2 specimens, in addition to the occipital arterial supply, one received blood from the ascending pharyngeal artery (Fig. 30) and the other from the external carotid artery (Fig. 34). The venous drainage was usually into the cranio-occipital vein (Figs. 23 to 25; 30 to 32) or rarely into the linguofacial vein (Fig. 33).

(f) External Carotid Nerve

The arterial supply to the external carotid nerve was usually from the artery of the carotid body. In some specimens, in addition to the blood supply from the artery of the carotid body, it also received arterial blood from the ascending pharyngeal, occipital or from both occipital and cranial laryngeal arteries (Fig. 27). The venous drainage was always into the cranio-occipital vein (Fig. 25) and rarely into the linguofacial vein (Fig. 33).

Fig. 25



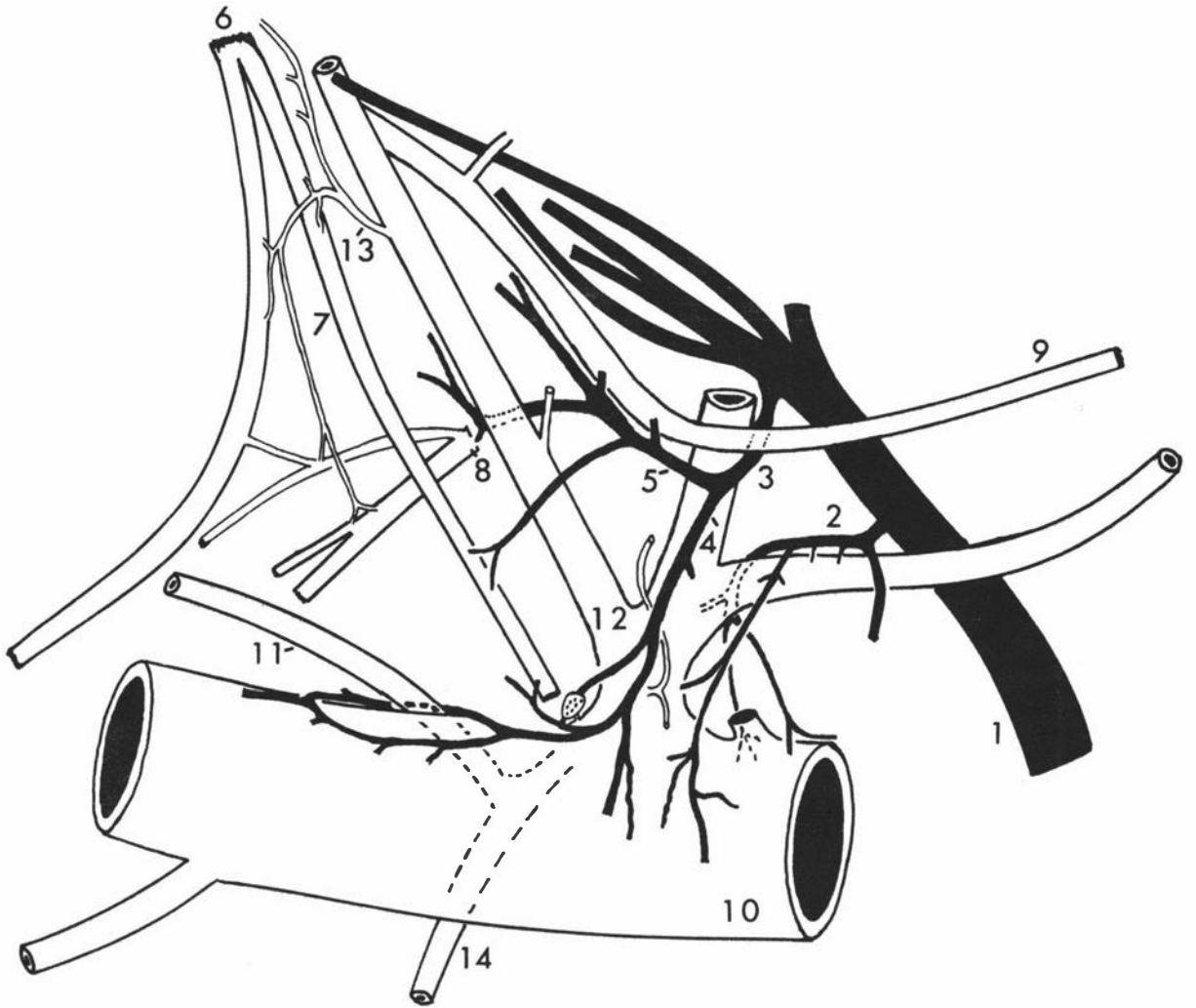
Key to Fig. 26.

Arterial Supply and Venous Drainage of the Left Carotid

Region. Lateral View.

- 1 - cranio-occipital vein
- 2 - vein draining common carotid and occipital arteries
- 3 - vein draining carotid trifurcation and associated nerves
- 4 - vein draining external carotid, common carotid and occipital arteries, and carotid body
- 5 - vein draining vagus, spinal accessory, pharyngeal branch of vagus and carotid sinus nerve
- 6 - glossopharyngeal nerve
- 7 - carotid sinus nerve
- 8 - pharyngeal branch of vagus nerve
- 9 - spinal accessory nerve
- 10 - common carotid artery
- 11 - ascending pharyngeal artery
- 12 - occipital artery
- 13 - artery supplying cranial cervical ganglion, glossopharyngeal nerve, carotid sinus nerve and pharyngeal branch of vagus nerve
- 14 - cranial laryngeal nerve

Fig.26



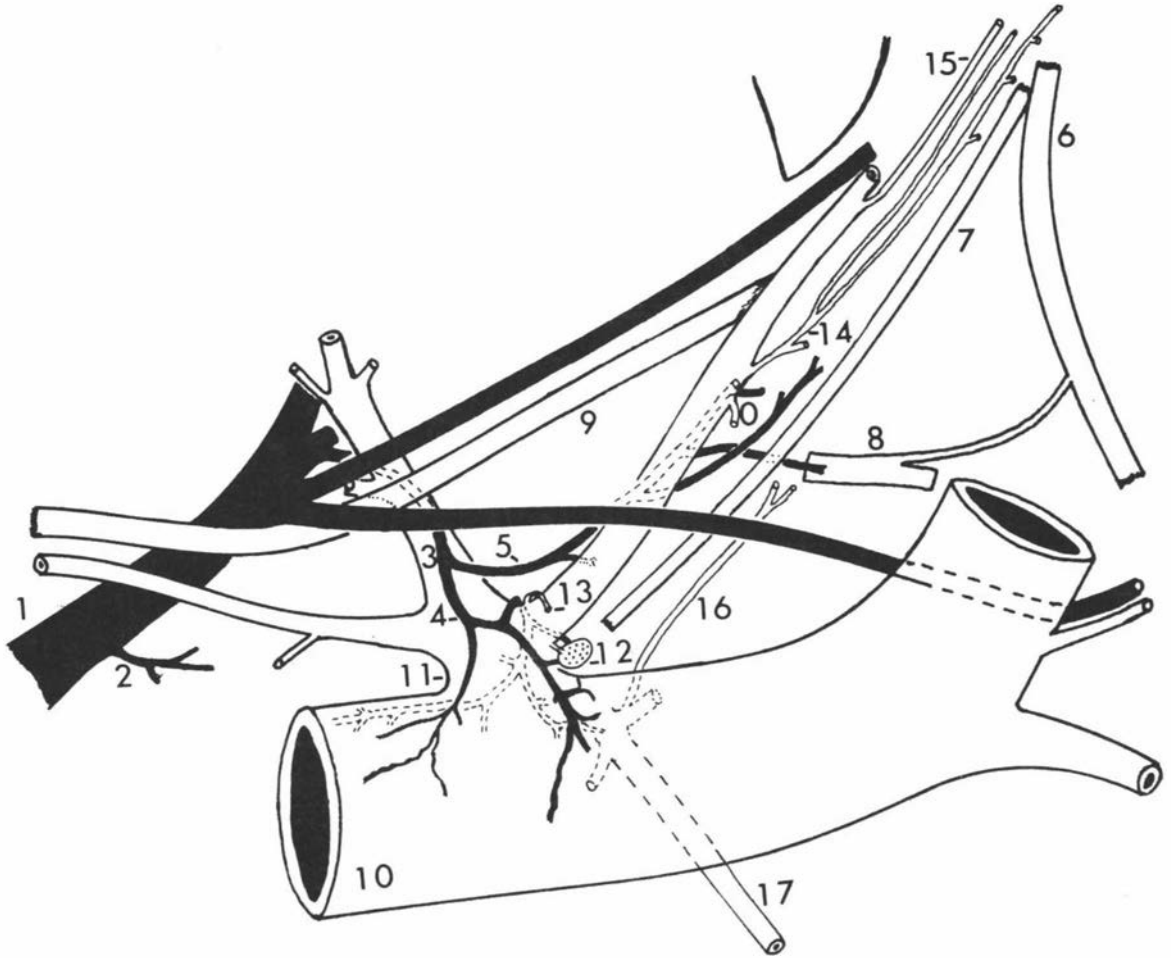
Key to Fig. 27.

Arterial Supply and Venous Drainage of the Right Carotid

Trifurcation. Lateral View.

- 1 - cranio-occipital vein
- 2 - small vein from hypoglossal nerve
- 3 - vein draining carotid trifurcation and associated structures
- 4 - vein draining the common carotid, external carotid arteries and carotid body and carotid sinus
- 5 - vein draining vagus, accessory and hypoglossal nerves, pharyngeal branch of vagus and occipital artery
- 6 - glossopharyngeal nerve
- 7 - carotid sinus nerve
- 8 - pharyngeal branch of vagus nerve
- 9 - spinal accessory nerve
- 10 - common carotid artery
- 11 - occipital artery
- 12 - carotid body
- 13 - artery to carotid sinus nerve and external carotid nerve
- 14,15 - artery to cranial cervical ganglion, sympathetic trunk
- 16 - artery to cranial cervical ganglion, cervical sympathetic trunk and external carotid nerve
- 17 - cranial laryngeal nerve

Fig. 27



(g) Cervical Sympathetic Trunk

The blood supply to the cervical sympathetic trunk from its origin up to the level where it became associated with the cervical vagus nerve was nearly always from the occipital artery (Figs. 22; 24; 25; 27), but in a very few instances it was from the cranial laryngeal artery. The venous drainage was usually into the cranio-occipital vein (Figs. 25; 31) or rarely into the linguofacial vein (Fig. 33).

(h) Vagus, Accessory and Hypoglossal Nerves

The occipital artery supplied the vagus nerve, including its pharyngeal branches and the nodose ganglion, the accessory and the hypoglossal nerves (Figs. 21; 24 to 26; 34). The venous drainage was usually into the cranio-occipital vein (Figs. 21 to 33). That part of the hypoglossal nerve which curved around the common carotid artery was supplied by an arterial twig from the carotid body artery in most of the specimens but occasionally was supplied by twigs from the ascending pharyngeal, occipital (Figs. 22; 24) or cranial laryngeal arteries.

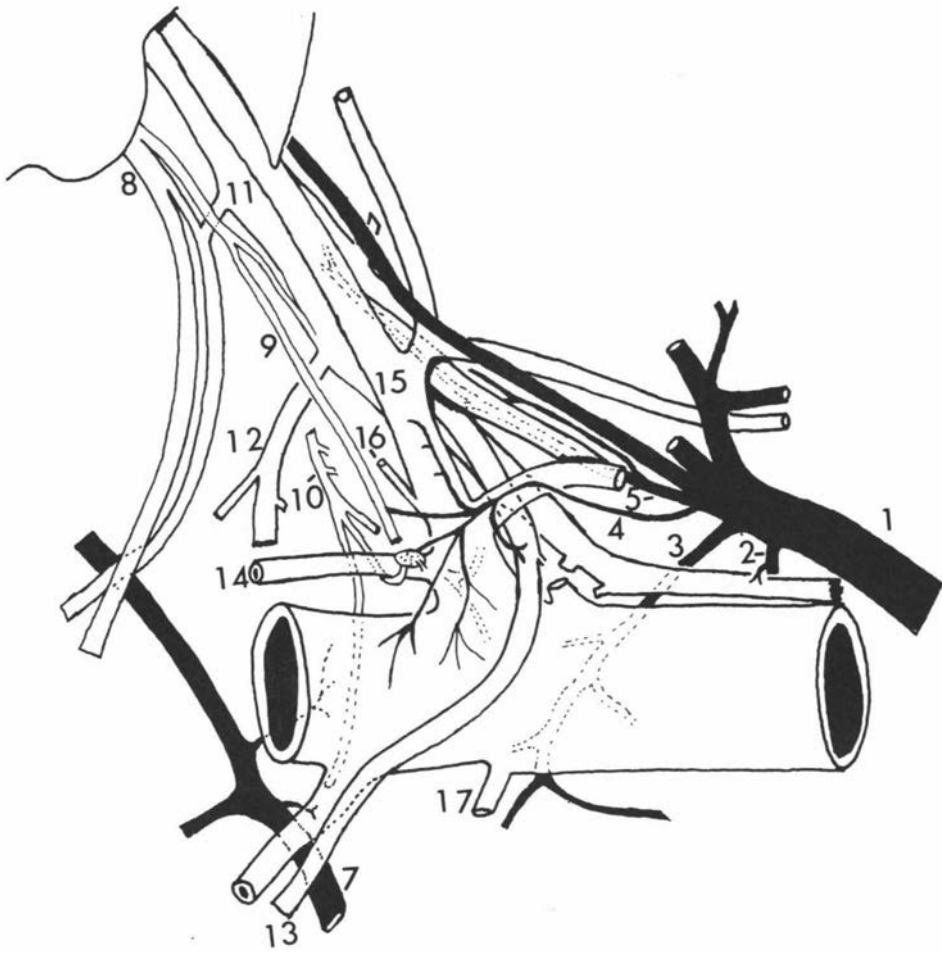
E. THE GROSS NERVE SUPPLY TO THE CAROTID BODY AND THE CAROTID SINUS REGION

The major nerves responsible for the innervation of the carotid body and carotid sinus were the carotid sinus nerve (Ramus sinus carotici) from the glossopharyngeal nerve, and the external carotid nerve (N. caroticus externus) from the cranial cervical ganglion (Fig. 16). Vagal and hypoglossal contributions were occasionally seen but no contribution from the accessory nerve was observed.

Key to Fig. 28.Arterial Supply and Venous Drainage of the Left Carotid
Region. Lateral View.

- 1 - cranio-occipital vein
- 2 - vein draining vago-sympathetic trunk
- 3 - vein draining laryngeal region
- 4 - vein draining carotid sinus nerve occipital
artery, carotid body, carotid sinus and external
carotid artery
- 5 - vein draining vagus, spinal accessory and
hypoglossal nerves
- 7 - vein draining into linguofacial vein
- 8 - glossopharyngeal nerve
- 9 - carotid sinus nerve
- 10 - external carotid nerve
- 11 - vagus nerve, communicating branch to
glossopharyngeal nerve
- 12 - pharyngeal branch of vagus nerve
- 13 - hypoglossal nerve
- 14 - ascending pharyngeal artery
- 15 - occipital artery
- 16 - artery to cranial cervical ganglion
- 17 - cranial laryngeal artery

Fig .28



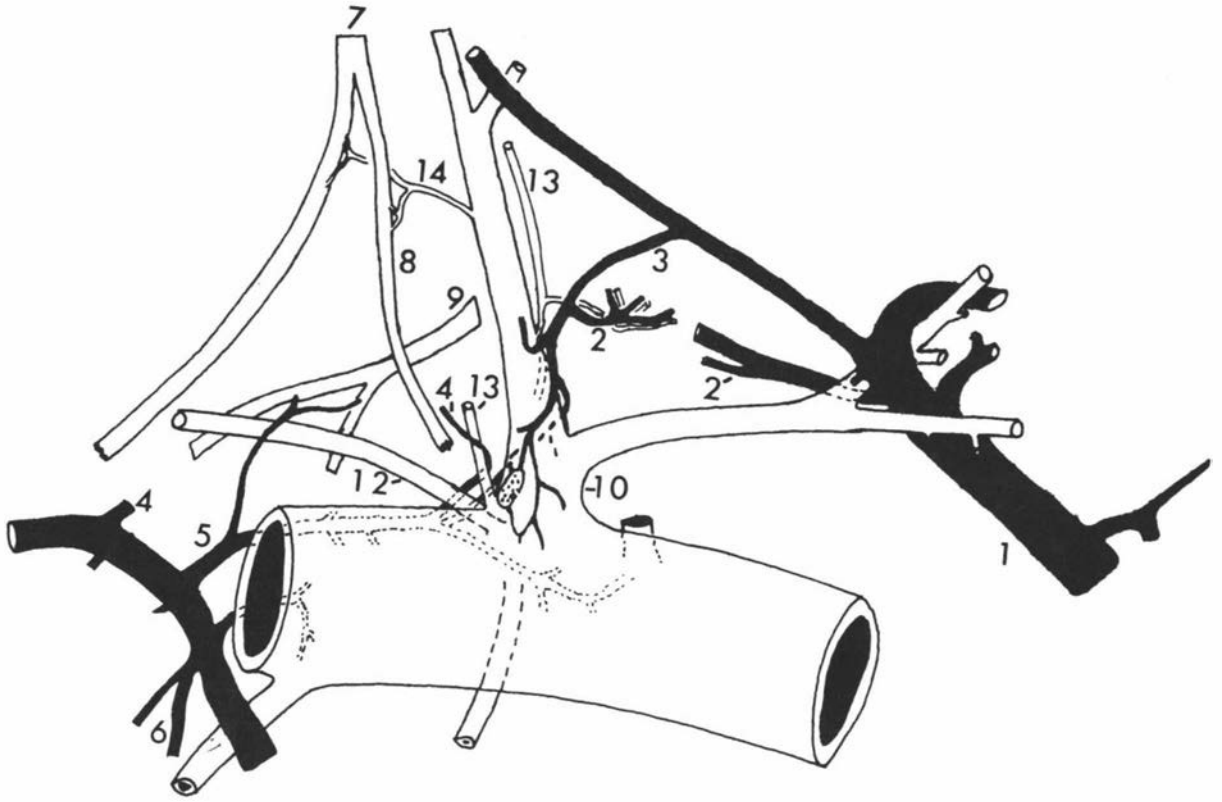
Key to Fig. 29.

Arterial Supply and Venous Drainage of the Left Carotid

Trifurcation. Lateral View.

- 1 - cranio-occipital vein
- 2 - small veins from vagus, spinal accessory
and hypoglossal nerves
- 3 - vein draining common carotid artery, carotid
body, carotid sinus and occipital artery
- 4 - small veins from medial retropharyngeal
lymph node
- 5 - vein draining pharyngeal branch of vagus,
carotid body and medial aspect of the carotid
trifurcation
- 6 - vein draining parotid salivary gland
- 7 - glossopharyngeal nerve
- 8 - carotid sinus nerve
- 9 - pharyngeal branch of vagus nerve
- 10 - occipital artery
- 12 - ascending pharyngeal artery
- 13 - arteries to cranial cervical ganglion
- 14 - artery to glossopharyngeal nerve and
carotid sinus nerve

Fig. 29



(a) Vagus Nerve

In one specimen only was there a delicate branch from the pharyngeal branch of the vagus nerve to the carotid sinus region, especially to the carotid body (Fig. 10-1). It was also noted that in most of the specimens there was a communicating branch between the glossopharyngeal nerve and the dorsal branch of the pharyngeal rami of the vagus nerve.

(b) Hypoglossal Nerve

In only two specimens was the sinus region supplied by a delicate branch from that part of the hypoglossal nerve which curved around the common carotid artery.

(c) Spinal Accessory Nerve

There was no contribution from the accessory nerve to the carotid trifurcation in any of the animals examined.

(d) Carotid Sinus Nerve

The glossopharyngeal nerve detached the carotid sinus nerve (Ramus sinus carotici) just before its emergence from the jugular foramen in 12 specimens (Fig. 21) or from some point ventral to the foramen in the remaining 45 specimens (Figs. 17 to 20; 22). In specimens having double carotid sinus nerve, the first one was detached while the glossopharyngeal nerve was in or just outside the jugular foramen (Figs. 17; 19). There were double carotid sinus nerves (Figs. 7-2,2; 8-2; 9-3,4; 10-1) in 13 specimens (22%) and a single carotid sinus nerve (Figs. 7-3,4; 8-1,3,4; 9-1,2; 10-2,3,4; 11; 18; 20) in the remaining 45 specimens (78%).

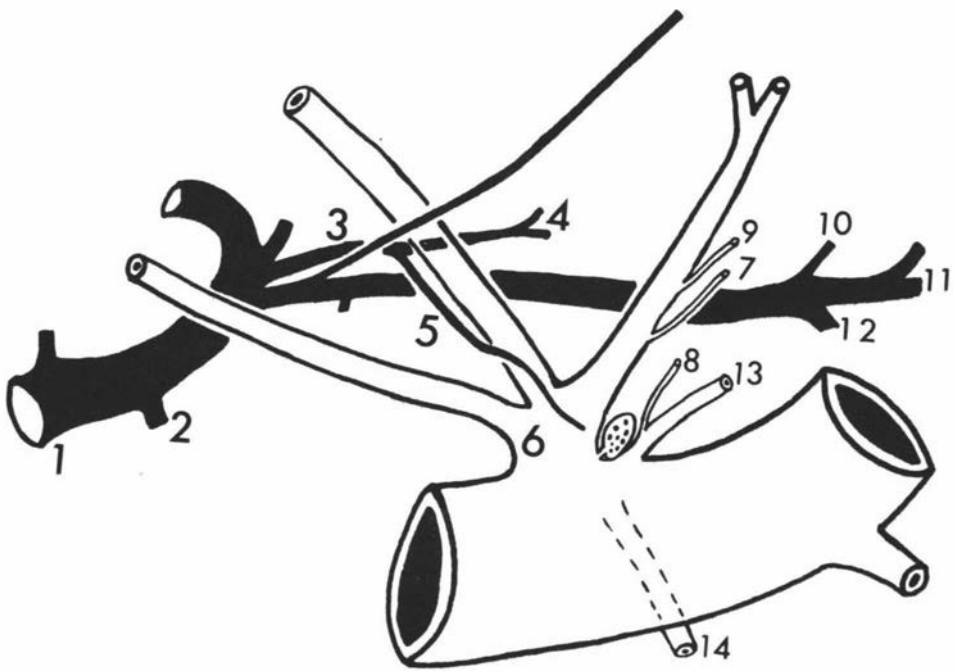
Key to Fig. 30.

Arterial and Venous Drainage of the Right Carotid Region.

Lateral View.

- 1 - cranio-occipital vein
- 2 - vein draining parotid salivary gland
- 3 - vein draining carotid trifurcation and last three cranial nerves
- 4 - vein draining vagus, spinal accessory and hypoglossal nerves
- 5 - vein draining carotid trifurcation
- 6 - occipital artery
- 7 - artery to cranial cervical ganglion
- 8 - artery to cranial cervical ganglion and pharyngeal branch of vagus nerve
- 9 - artery to cranial cervical ganglion, carotid sinus nerve and glossopharyngeal nerve
- 10 - vein from cranial cervical and nodose ganglia
- 11 - vein from pharyngeal region
- 12 - vein from laryngeal region
- 13 - ascending pharyngeal artery
- 14 - cranial laryngeal artery

Fig. 30



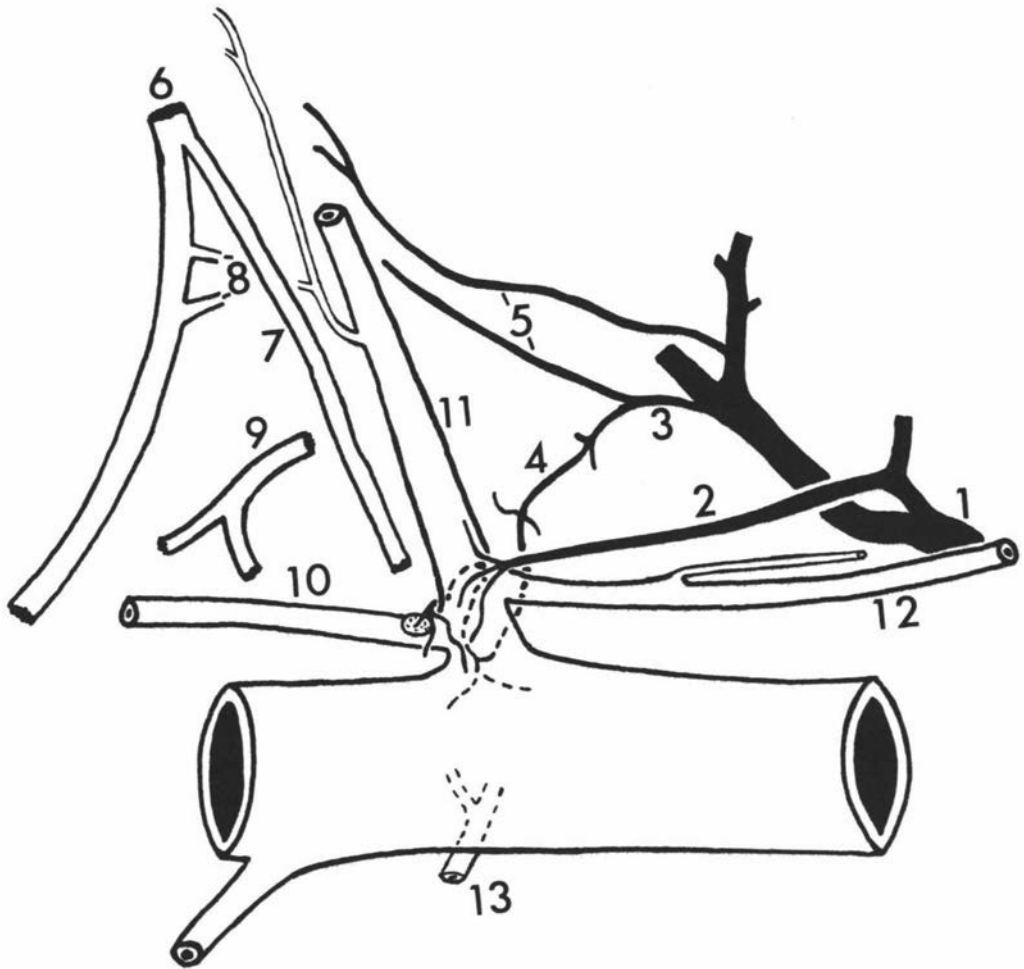
Key to Fig. 31.

Venous Drainage of the Left Carotid Trifurcation.

Lateral View.

- 1 - cranio-occipital vein
- 2 - vein draining occipital artery and carotid sinus
- 3 - vein draining carotid body, medial aspect
of carotid trifurcation and last three cranial
nerves
- 4 - vein draining vagus, spinal accessory and
hypoglossal nerves, carotid body and carotid
sinus
- 5 - veins draining cranial cervical ganglion and
cervical sympathetic trunk
- 6 - glossopharyngeal nerve
- 7 - carotid sinus nerve
- 8 - communicating branches to vagus nerve
- 9 - pharyngeal branch of vagus nerve
- 10 - ascending pharyngeal artery
- 11 - occipital artery
- 12 - muscular branch
- 13 - cranial laryngeal artery

Fig. 31



There was a communicating branch between the carotid sinus nerves in 8 specimens (Figs. 8-2; 9-4) out of the total 13 specimens having double carotid sinus nerves. There was also a communicating branch between the carotid sinus nerve and the pharyngeal branch of the vagus in one specimen (Fig. 18; Plate I-1), between the sinus nerve and the vagus nerve trunk in 2 specimens (Fig. 28; Plate I-2), and between it and the glossopharyngeal nerve in one specimen.

The name, carotid sinus nerve, is misleading in its implication as it has been found to innervate not only the carotid body and carotid sinus, but also the entire carotid trifurcation. The carotid sinus nerve, just before it reached the trifurcation, divided into 3-5 filaments which supplied the carotid body, carotid sinus, and occipital, ascending pharyngeal, common carotid, external carotid, cranial laryngeal and lingual arteries (Figs. 7 to 11). There were two sets of filaments, the medial ones which supplied the medial aspects of the carotid sinus, common carotid, caudal pharyngeal, cranial laryngeal and lingual arteries, and the lateral filaments which supplied the lateral aspect of the carotid trifurcation. The most prominent of all the filaments was the one which coursed along the lateral aspect of the common carotid artery. Usually either a filament supplying the carotid body or one of the other filaments of the carotid sinus nerve received a communication from the filament of the external carotid nerve supplying the carotid body, about the ventral or lateral aspect of the origin of the ascending pharyngeal artery.

The two carotid sinus nerves, observed in 13 specimens (22%), either united with each other before reaching the carotid trifurcation or had a communication with each other near the origin of the

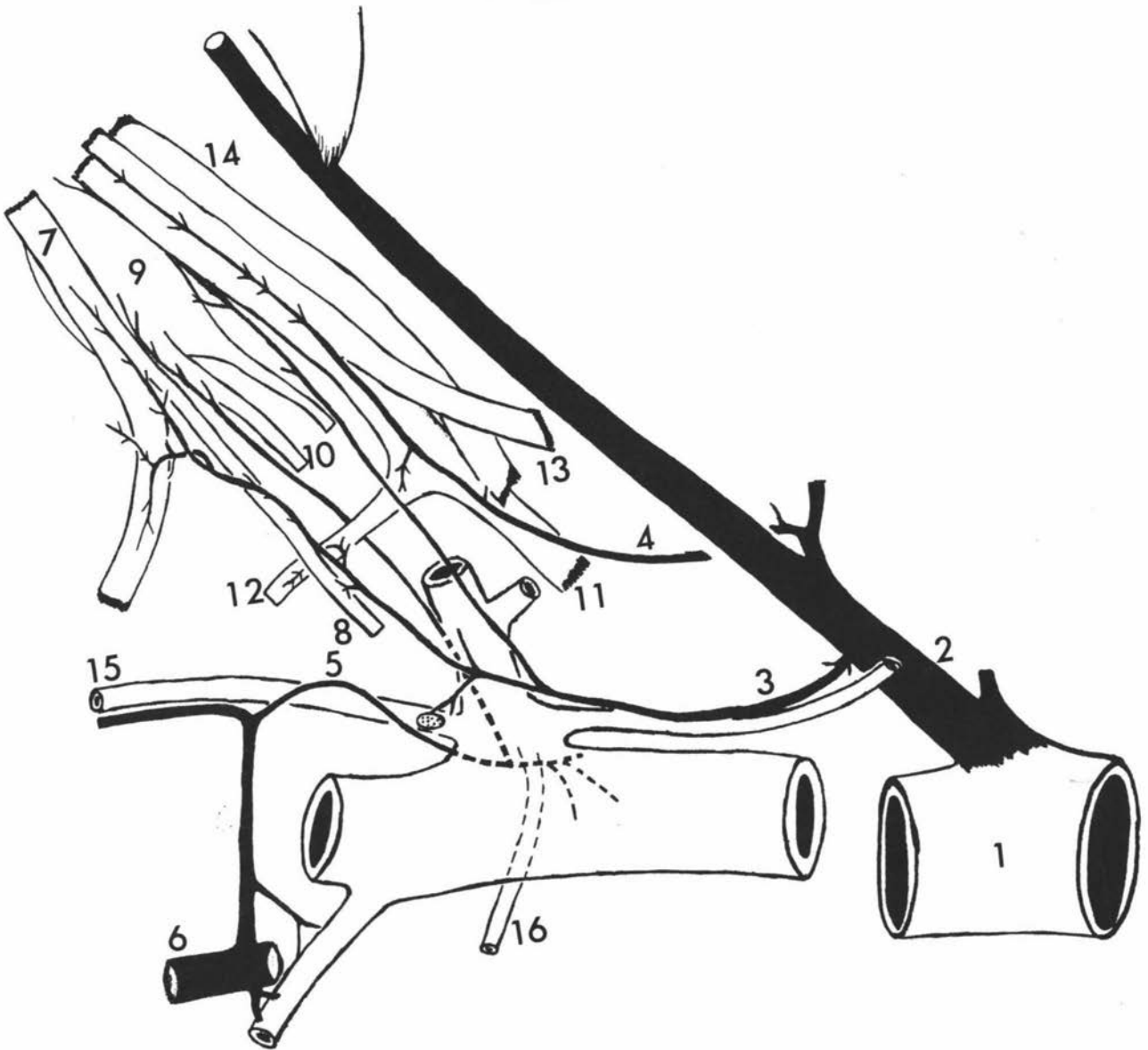
Key to Fig. 32.

Venous Drainage of the Left Carotid Trifurcation.

Lateral View.

- 1 - external jugular vein
- 2 - cranio-occipital vein
- 3 - vein draining cranial cervical ganglion and sympathetic trunk, glossopharyngeal nerve, carotid sinus nerve, pharyngeal branch of vagus, and carotid body and carotid sinus
- 4 - vein draining vagus, spinal accessory and hypoglossal nerves and nodose ganglion
- 5 - vein draining cranial cervical ganglion, external carotid nerve, medial aspects of common carotid and carotid sinus
- 6 - vein draining into **linguofacial vein**
- 7 - glossopharyngeal nerve
- 8 - carotid sinus nerve
- 9 - cranial cervical ganglion
- 10 - external carotid nerve
- 11 - vagus nerve
- 12 - pharyngeal branch of vagus nerve
- 13 - spinal accessory nerve
- 14 - hypoglossal nerve
- 15 - ascending pharyngeal artery
- 16 - cranial laryngeal artery

Fig. 32



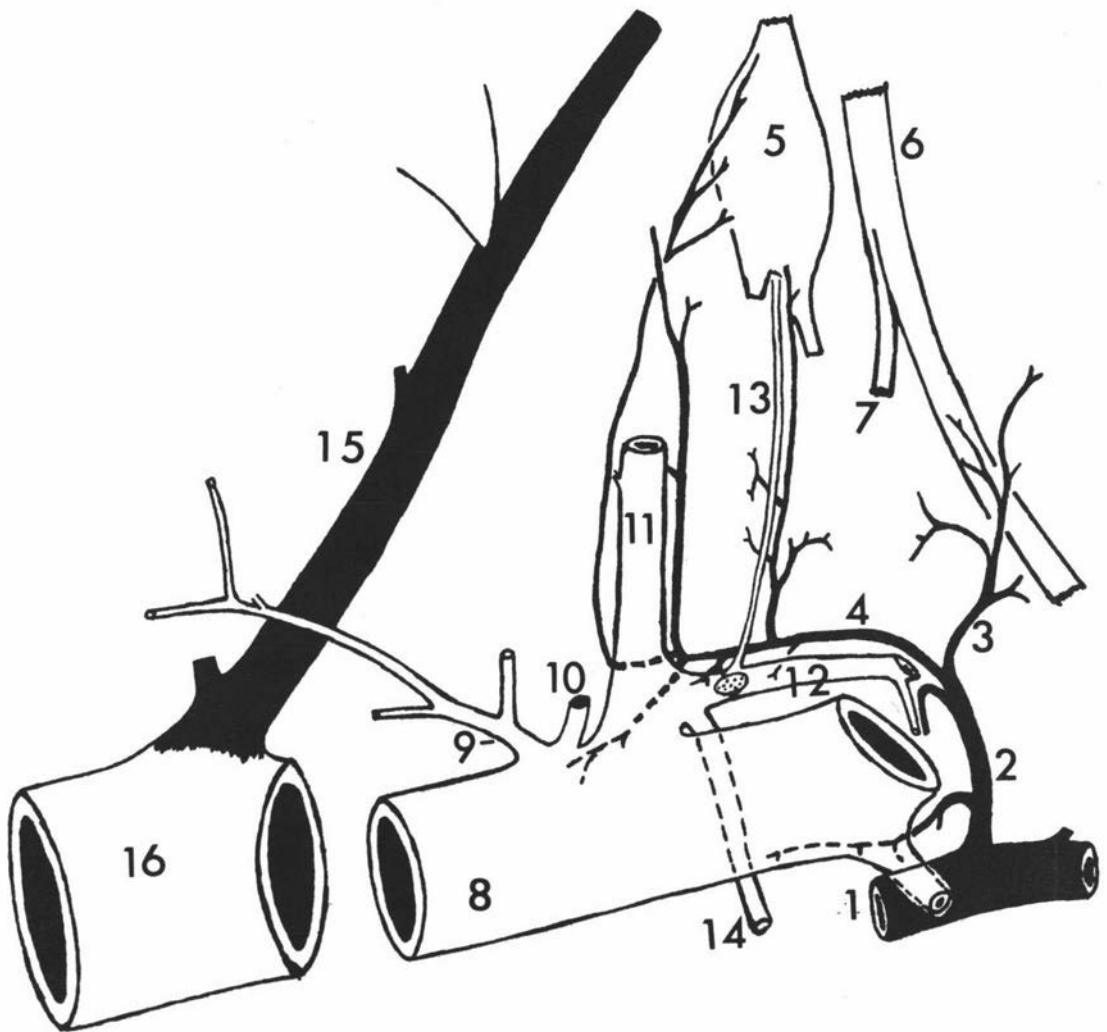
Key to Fig. 33.

Venous Drainage of the Right Carotid Trifurcation.

Lateral View.

- 1 - vein draining into **linguofacial vein**
- 2 - vein draining entire carotid trifurcation region
- 3 - vein draining carotid sinus nerve and
glossopharyngeal nerve
- 4 - vein draining medial aspect of common carotid
artery, carotid sinus, occipital artery, cranial
cervical ganglion, external carotid nerve,
cervical sympathetic trunk and last three
cranial nerves
- 5 - cranial cervical ganglion
- 6 - glossopharyngeal nerve
- 7 - carotid sinus nerve
- 8 - common carotid artery
- 9 - muscular branch
- 10 - internal carotid artery
- 11 - occipital artery
- 12 - ascending pharyngeal artery
- 13 - artery to cranial cervical ganglion and
sympathetic trunk
- 14 - cranial laryngeal artery
- 15 - cranio-occipital vein
- 16 - external jugular vein

Fig.33



ascending pharyngeal artery. Usually the smaller carotid sinus nerve supplied the origin of the ascending pharyngeal artery and also had communications between the larger sinus nerve and a filament from the external carotid nerve. The filaments from the external carotid nerve and the carotid sinus nerves tended to form a diffuse plexus at and around the vicinity of the carotid body in the embalmed specimens.

(e) External Carotid Nerve

The external carotid nerve (N. caroticus externus) contributed the sole sympathetic innervation to the carotid body, carotid sinus and the entire carotid trifurcation (Figs. 12 to 15; Plate I-3). The fibres of this nerve had a variable origin from the cranial cervical ganglion. The fibres arose usually from the caudal extremity, but occasionally from the cranial border, from the lateral side or from just below the cranial extremity of the ganglion (Fig. 16). Very rarely the origin was by two roots which soon united below the caudal extremity of the ganglion (Fig. 16-5).

The external carotid nerve was related laterally to the glosso-pharyngeal nerve and pharyngeal branches of the vagus, and medially to the pharynx. It ran ventrocaudad to the origin of the occipital and the external carotid arteries. Before it reached the medial aspect of the origin of the ascending pharyngeal artery, it divided into 3-5 filaments. Some filaments supplied the carotid body at the medial or ventral aspect of the origin of the ascending pharyngeal artery and usually this filament had a communication with a filament of the carotid sinus nerve just ventral to or lateral to the origin of the artery (Figs. 12-4; 14-1,2,3; 15). Other filaments

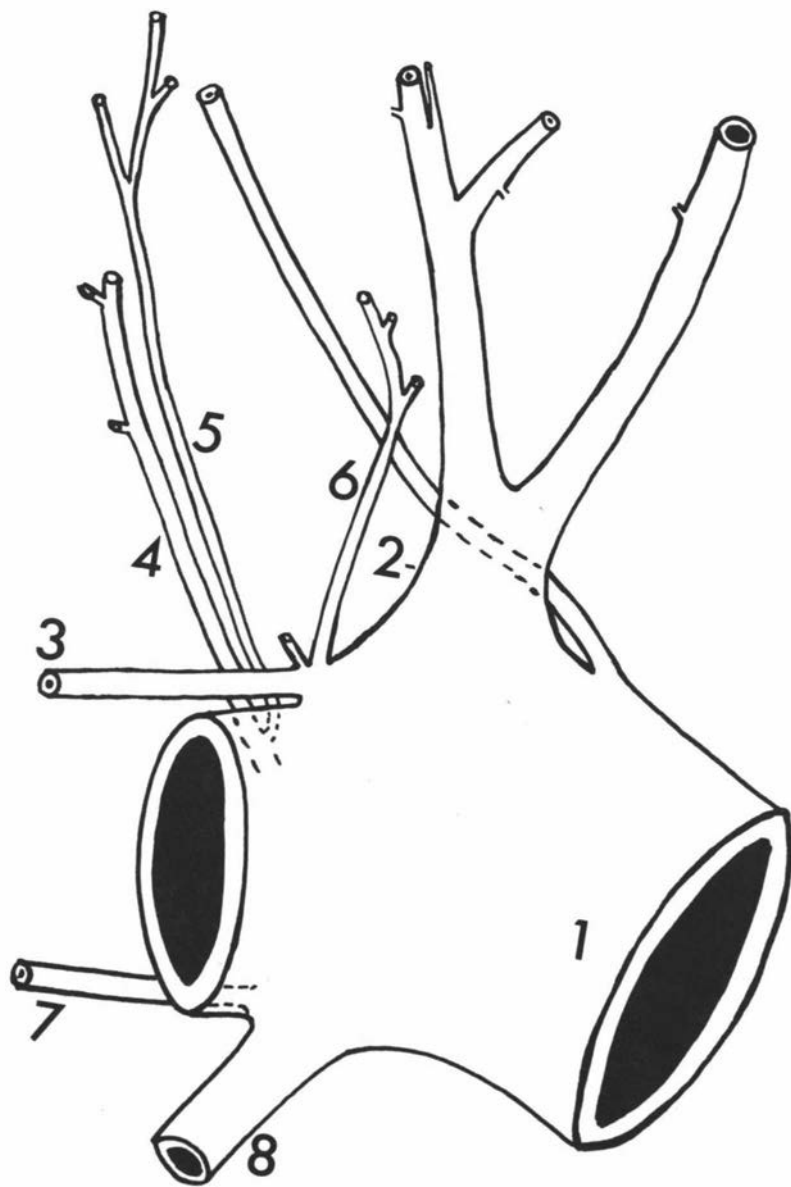
Key to Fig. 34.

The Arterial Branches of the Left Carotid Trifurcation.

Lateral View.

- 1 - common carotid artery
- 2 - occipital artery
- 3 - ascending pharyngeal artery
- 4 - artery to longus capitis muscle, medial retropharyngeal lymph node, and pharyngeal branch of vagus nerve
- 5 - artery to cranial cervical ganglion, glossopharyngeal nerve and carotid sinus nerve
- 6 - artery to cranial cervical ganglion, cervical sympathetic trunk, vagus, spinal accessory and hypoglossal nerves
- 7 - a branch to pharyngeal branch of vagus nerve and hypopharyngeus muscle
- 8 - cranial laryngeal artery

Fig. 34



followed the medial aspects of the occipital artery and its muscular branch, and the common carotid, external carotid, cranial laryngeal and lingual arteries. The filament that followed the medial aspect of the lingual artery was the most prominent of all the filaments. The origin of the occipital artery or the occipito-ascending pharyngeal trunk received innervation from one or more of the filaments of the external carotid nerve except from those passing along the external carotid and lingual arteries. The tendency of these external carotid nerve filaments to form a plexus around the carotid body has already been mentioned.

DISCUSSION

The carotid trifurcation in the sheep was found to vary considerably in the mode of branching of the main arteries. Not only did the branching pattern vary in the individual animal, but also mode of venous drainage and innervation pattern of the carotid trifurcation region varied in each individual animal. The mode of branching of the carotid trifurcation also differed from that of the bovine species. The ascending palatine artery, according to N.A.V. (1968), arises from the common carotid artery in the ovine and caprine species whereas in the bovine species it arises from the occipital artery. N.A.V. (1968) also listed the deep stylomastoid artery as a branch of the occipital artery in the bovine species. The middle meningeal and condyloid arteries in the sheep may arise as a common trunk from the occipital artery.

The regression of the internal carotid artery in the lamb seemed to be slow, as the patent distal portion of this artery was found consistently in most of the lambs examined. As it can be

easily and certainly identifiable in lambs, its origin should be regarded as the termination of the common carotid artery.

The variable position of the carotid body on either the occipital or ascending pharyngeal artery or on the occipitoascending pharyngeal trunk, and its relative smallness in size compared to other laboratory animals such as the cat (Gerard and Billingsley, 1923; Sato, 1932), rabbit (Stilling, 1892; Sato, 1932), and dog (Comroe and Schmidt, 1938; Sato, 1932) should be born in mind when performing experiments dealing with the organ.

The origin of the carotid body artery was also variable in sheep as it came from the occipital or ascending pharyngeal artery or occipitoascending pharyngeal trunk. More or less the same situation has been reported in the dog and cat by many observers. In the cat it has been described as arising from the occipital artery (de Castro, 1940) or from the occipitoascending pharyngeal trunk (Muratori, 1943; Addison, 1945; Chungcharoen et al., 1952 a, b; Murphy and Hughes, 1965). In the dog two carotid body arterial branches which originated from the occipital artery and the occipitoascending pharyngeal trunk were described by de Castro (1940), Muratori (1943), and Chungcharoen et al., (1952 a, b); or from the occipital and external carotid arteries by Addison and Comroe (1937). Three to four arterial branches to the carotid body of the dog, arising from the occipital and external carotid arteries, from the ascending pharyngeal artery alone, or from the ascending pharyngeal and external carotid arteries have also been reported by Chungcharoen et al., (1952 a, b). In the rabbit, the carotid body has been described as receiving one or two arterial branches from the external carotid and internal carotid arteries, or the carotid

bifurcation (Chungcharoen et al., 1952a, b), from the carotid sinus close to the bifurcation of the common carotid (Addison, 1945), or from the occipitoascending pharyngeal trunk (Murphy and Hughes, 1965). In man, the carotid body arterial branches arise from the bifurcation itself and the external carotid or, rarely, the internal carotid artery, but there is no recorded case where it comes from the ascending pharyngeal artery (Adams, 1958).

The carotid body artery in the sheep supplied the carotid sinus area, as recorded in the dog and cat by Hughes (1965), and also supplied the distal parts of the carotid sinus nerve and external carotid nerve, whereas in the dog, cat and rabbit, the carotid body artery has been reported to supply the superior cervical and nodose ganglia in addition to the carotid sinus area (Chungcharoen et al., 1952c).

The variation in the venous drainage of the carotid body and the carotid sinus area of the sheep within individuals and between individuals was similar to that reported in the dog, cat and rabbit (Chungcharoen et al., 1952b, c). In the sheep the final channel for blood draining from the carotid region, including the carotid body, carotid sinus, associated nerves and ganglia, was the cranio-occipital (occipital) vein or, rarely, the linguofacial vein, and thence blood drained solely into the external jugular vein. In the dog and cat, the venous drainage has been reported to be directly into the internal jugular vein and indirectly into the external jugular vein via the posterior pharyngeal and laryngeal veins (dog) or via the transverse posterior pharyngeal vein (cat), while in the rabbit it was solely into the internal jugular vein (Chungcharoen et al., 1952b). When the internal jugular vein was

absent, the drainage was solely via the laryngeal vein into the external jugular vein in the dog (Chungcharoen et al., 1952b), and through the prevertebral vein and thence into the external jugular vein in the rabbit (Chungcharoen et al., 1952c).

It is noteworthy that in the dog, cat and rabbit the blood supply to the cranial cervical and nodose ganglia, although mainly from the occipital artery, was also from the carotid body artery (Chungcharoen et al., 1952c), whereas in the sheep, it was entirely from the occipital artery. The ascending pharyngeal artery only occasionally contributes to the vascularization of these structures in the dog and cat (Chungcharoen et al., 1952c) but in the human this artery is the main source of blood supply to these structures (Patterson, 1950). In the sheep, the cranio-occipital vein, which drained into the external jugular vein, was responsible for the venous drainage from the cranial cervical and nodose ganglia.

It was reported that the carotid sinus nerve might arise from the nerve to the styloglossus in man (Boyd, 1937b) and in the sheep the stylopharyngeal nerve might arise from it (May, 1964, 1965), but it was not so in any of the animals examined. The presence of two carotid sinus nerve filaments in the sheep is not peculiar to that species as it has been reported also in other vertebrates such as man, primates, Anthropoidea, Lama glama and African elephant (Adams, 1958).

The major innervation of the carotid body and carotid sinus in the sheep was from the carotid sinus nerve and the external carotid nerve. Vagal innervation through the pharyngeal branches and the hypoglossal nerve was occasionally seen but, since fibres

were usually very small and inconstant, they probably are of no significance in the sheep. Hypoglossal and vagal innervation from pharyngeal branches, nodose ganglion or superior (cranial) laryngeal nerve has been recorded in most vertebrates (Adams, 1958).

SUMMARY

1. The topographical anatomy of the carotid trifurcation region in lambs and sheep was studied. Studies were made on fresh, embalmed, embalméd and latex injected, and india ink injected specimens for the blood and nerve supply, and the venous drainage, of the carotid body, carotid sinus, and associated nerves and ganglia.
2. The carotid trifurcation in the sheep has been found to vary considerably in the mode of branching of the main arteries.
3. In young lambs the carotid bodies are difficult to identify with certainty by gross inspection.
4. The occipital artery or occipitoascending pharyngeal arterial trunk near its origin has been found to be dilated and this "bulb" corresponds to the carotid sinus in other species.
5. The position, blood supply and venous drainage of the carotid body have been found to be variable. The carotid body is found on the occipital artery, on the ascending pharyngeal artery, or the occipitoascending pharyngeal arterial trunk. The artery of the carotid body usually arises from one of these arteries to supply the carotid body, the carotid sinus, and the distal parts of the carotid sinus nerve and the external carotid nerve.

6. The occipital artery is the major arterial source of supply for almost all the structures associated with the carotid trifurcation. It supplies the proximal part of the carotid sinus nerve, the vagus nerve including pharyngeal and oesophageal rami, the nodose and cranial cervical ganglia, the cranial part of the cervical sympathetic trunk, and the glossopharyngeal, accessory and hypoglossal nerves.
7. The final channel for blood draining the carotid trifurcation region, including the carotid body, carotid sinus, and associated nerves and ganglia, is the cranio-occipital or linguofacial vein, and thence solely into the external jugular vein.
8. The origin and the number of the carotid sinus nerve or nerves vary between individuals.
9. The carotid sinus nerve may or may not anastomose with the glossopharyngeal or pharyngeal branches of the vagus nerve.
10. The name of the carotid sinus nerve is misleading because the nerve not only innervates the carotid sinus and the carotid body but also supplies the entire carotid trifurcation.
11. The sole sympathetic innervation of the carotid trifurcation is from the cranial cervical ganglion through the external carotid nerve whose point of origin may vary between individuals.
12. Vagal and hypoglossal contributions to the carotid trifurcation are uncommon and there is no spinal accessory nerve innervation.

CHAPTER FOUR

LIGHT MICROSCOPY OF THE CAROTID BODY

INTRODUCTION

The carotid body of various vertebrate species has been studied extensively since the discovery of the carotid body by Haller in 1742. Although the carotid body of the sheep has been studied by de Kock (1954) and Abraham (1968a, 1969), it is felt that a detailed description of the histological structure of the organ is still needed. The following work was conducted in the normal carotid body of lambs and sheep to study:

- (i) the size, shape, position and connective tissue,
- (ii) whether there is any scattered carotid body-like tissue at the carotid trifurcation,
- (iii) the structure of the artery and veins of the carotid body, and the carotid sinus and external carotid nerves,
- (iv) the cell types, and
- (v) the innervation of the organ.

The carotid bodies of 9 lambs (N1 to N5 and G1 to G4) were also studied after chronic denervation (sectioning of the carotid sinus nerve, cranial cervical ganglionectomy, or sectioning of the external carotid nerve, the sympathetic branch to the carotid body and the carotid sinus). Studies were made of the denervated specimens:

- (i) to determine whether there are any detectable morphological changes in the carotid body cells or in the blood vessels,
- (ii) to trace the degenerated nerves (glossopharyngeal fibres) using the modification techniques of Nauta and Gyax (1951, 1954) as recommended by Hamlyn (1957) and Guillery et al. (1961), and

- (iii) the nature of persisting nerve fibres, their distribution and mode of terminations in the carotid body using Ungewitter's (1951) urea-silver nitrate staining technique, and Romanes' (1950) silver chloride method.

LITERATURE REVIEW

Very comprehensive reviews of the carotid body can be consulted in Funke (1904), Hollinshead (1940a), Schmidt and Comroe (1940), Pick (1959), Heymans (1955), Adams (1958), Heymans and Neil (1958), de Kock (1958, 1959), Anichkov and Belen'kii (1962), Torrance (1968), and Abraham (1969).

The carotid body of the sheep, dog and rabbit, according to Adams (1958), was first mentioned by Pfortner in 1869, more than a century after the discovery of the carotid body of man by Haller in 1742. The carotid body of various vertebrates has been studied by light microscopy in the bird (Chowdhary, 1953; de Kock, 1958, 1959; Abraham, 1969; Jones and Purves, 1969, 1970), Rana tigrina (Chowdhary, 1951), guinea-pig (Engstrom et al., 1957; Kondo, 1971), cat (Gerard and Billingsley, 1923; Hollinshead, 1942a,b, 1943; de Kock, 1951, 1954; Ross and Hunt, 1954; Ross, 1957b), dog (Gerard and Billingsley, 1923; Bloom, 1943; Abraham, 1969), rat (de Kock, 1954; Ross and Hunt, 1954), mouse (Hollinshead, 1945), Veranus monitor (Chowdhary, 1950), Veranus varius, opossum, hedgehog, Nyceticebus (Adams, 1952, 1955, 1957a, 1957c), pilot-whale (de Kock, 1956), Weddell-seal (Morita et al., 1970), man (Funke, 1904; Keen and Funke, 1906; Gomez, 1908; Hollinshead, 1942a; Gerard and Billingsley, 1923; Kushiro, 1949; Lattes, 1950; Willis and Tange, 1959b; Prys-Davies et al., 1964; Karnachow, 1965; Kraus, 1966;

Grimley and Glenner, 1967), man and various mammals (Gerard and Billingsley, 1923; Abraham, 1958, 1968a, 1969). References have been made to developmental aspects of the carotid body in the amphibian (Boyd, 1933), in the rat (Smith, 1924; Rogers, 1965), in vertebrates (Boyd, 1936), in the sheep (Batten, 1960a,b) and in the human (Celestino da Costa, 1935; Boyd, 1937a).

The carotid body of the sheep has been studied by Pfortner in 1869, and Schaper in 1892, according to Adams (1958), and also by de Kock (1954), Waites (1960) and Abraham (1968a, 1969). De Kock studied the intraglomerular tissue of the sheep, cat and rat by using Holmes' silver technique, and Abraham studied the innervation of the carotid body of man and various vertebrates including sheep. However, only one observation of Abraham (1968a) described briefly the innervation of the carotid body of the sheep. Although Waites studied the carotid body of the sheep, he merely confirmed the presence of the carotid body tissue at the carotid trifurcation.

CELL TYPES IN THE CAROTID BODY

De Kock (1951) reported for the first time that there are two types of cells in the carotid body of the cat; a typical rounded glomus cell (type I) and an irregular, smaller second glomus cell (type II). Her observations in 1954 in the sheep, cat and rat, using Holmes' silver technique, confirmed the presence of type I and type II cells. She also mentioned some other cells such as interstitial cells, ganglion cells and unidentified acidophil cells.

Chief Cells

The chief cells (Adams, 1958; Grimley and Glenner, 1966b; Kondo, 1971) of the carotid body appear under a variety of names in the literature as follows: "chemoreceptor" cells (De Castro, 1926, 1951; Heymans, 1955; Ross, 1957a,b, 1959), "type I" cells (de Kock, 1951, 1954), "epithelioid" cells (de Castro, 1951; Chowdhary, 1950; Adams, 1952), "glomus" cells (Lever and Boyd, 1957; Garner and Duncan, 1958), "specific" cells (Hoffman and Birrell, 1958), "distinct" cells (Garner and Duncan, 1958), "medial" cells (Hoffman and Birrell, 1958), "enclosed" cells (Al-Lami and Murray, 1958a,b), "main" cells (Morita et al., 1970), "typical" cells, "principal" cells (Adams, 1958), "granular" cells (Molyneux and Scott, 1966).

The chief cells (type I), according to de Kock (1951, 1954) stain bluish grey with a granular cytoplasm, while their nuclei remain unstained with Holmes' silver stain and they contain up to three nucleoli. However a contradictory report came from Abraham (1969). He claimed that "the distinction of chief [type I] and accessory cells [type II] appeared to be partly justified, type II cells of de Kock (1954) being only vaguely distinguishable from the chief cells on the basis of the features given in the literature". At the same time he admitted that there are certain cells which differ from the chief cells mainly in respect of the shape of their nuclei and their staining reactions.

Types of Chief Cells

In most mammalian species, there are two types of chief cells, "light" or chromophobe and "dark" or chromophil cells as in the rabbit (Lever and Boyd, 1957; Lever et al., 1959), mouse and cat

(Garner and Duncan, 1958). However no such cell types were mentioned by Ross (1957a,b) in the cat and Engstrom et al. (1957) in the guinea-pig and man.

The "light" cells, according to Adams (1958) are larger and have a very reticular, vacuolated and faintly eosinophilic cytoplasm. They have a vesicular nucleus, containing delicate strands of chromatin, which has one or more nucleoli. The smaller "dark" cells have been described as having a strong eosinophilic and homogenous cytoplasm and the small and dark nucleus is rich in chromatin (de Castro, 1929; cited by Adams, 1958). In some animals the dark cells were reported to be the majority of the glomus cell population (Sato, 1932; Lever and Boyd, 1957; Lever et al., 1959; Morita et al., 1970) while in the others no specific light or dark cells have been reported (Engstrom et al., 1957; Ross, 1957a,b; Hollinshead, 1942a,b, 1945; Chowdhary, 1950, 1953; Adams, 1952; Willis and Tange, 1959b; Dowd, 1966; Kondo, 1971; Abraham, 1969). It is not yet settled regarding the origin of the light and dark cells, whether they are actually two different types of cells or are formed as a result of external or internal factors.

The shape of the chief cells in various vertebrates has been reported as typically rounded (de Kock, 1954), ovoid, cuboidal or even columnar (Hoffman and Birrell, 1958) in the rat; rounded or oval (Hollinshead, 1945), ovoid or polygonal (Garner and Duncan, 1958) in the mouse; polygonal or rounded (Engstrom et al., 1957) rounded or angular (Kondo, 1971) in the guinea-pig; complex shape in the rabbit (Biscoe and Stehbins, 1966); polygonal or rounded (Hollinshead, 1942a,b, 1943; Ross, 1959), rounded (de Kock, 1951,

1954; de Kock and Dunn, 1964), ovoid (Hess, 1968), complex shape (Biscoe and Stehbens, 1966) or irregular (Al-Lami and Murray, 1968a) in the cat; rounded or slightly elongated (Abraham, 1969) in the dog; typically rounded (de Kock, 1954) in the sheep; multiangular (Hollinshead, 1942a), polygonal or rounded (Abraham, 1969) in man. The size of the chief cells in various vertebrates has been reported: in the duck, 8-11 μ in diameter (Jones and Purves, 1970), guinea-pig, 15 μ in diameter (Engstrom et al., 1957), cat, 6-10 μ (Ross, 1959) or 8-12 μ (Hess, 1968), calf, 15-18 μ (Ostermann, 1952), horse, 10-20 μ (de Boissezon, 1942) and man, 7.5 μ (Martinez, 1939) or 15-30 μ (Watzka, 1943).

The chief cell contains a number of organoids in its cytoplasm: mitochondria, granules, Golgi complex, centrioles and fibrils. The cytoplasmic processes will be reviewed under ultrastructural studies of the carotid body. The granular mitochondria previously reported by de Castro (1926), Argoud and de Boissezon (1938) and de Boissezon (1942) were later found to be fuchsinophilic granules (Hollinshead, 1942b, 1943) which disappeared under anoxia (Hollinshead, 1945). De Castro (1926) had found these to be plentiful in the dark cells but Hollinshead (1945) reported that they were not mitochondria. Many observers have described the glomus cells as having cytoplasmic processes but Abraham (1969) denied their presence. Neurofibrils or neurofibrillar networks were claimed by Meijling (1938) and de Kock (1951, 1954) to be present in the glomus cells, but later observers were unable to detect their existence (Hammond, 1941; Hollinshead, 1943; Abraham, 1969).

Glomus Cells of the Second Type

The glomus cells of the second type (de Kock, 1951, 1954) also have appeared under a variety of names; "type II" cells (de Kock, 1951, 1954), "sustentacular" cells (Ross, 1959; Grimley and Glenner, 1966b; Kondo, 1971), "receptor" cells (de Kock, 1954), "perisinusoidal" or "pericapillary" cells (Adams, 1957a), "pericytes" (Lever et al., 1959), "capsule" or "supporting" cells (Hess, 1968), "satellite" cells (Hoffman and Birrell, 1958; Duncan and Yates, 1967; de Castro and Rubio, 1968, Kondo, 1971), "enclosing" cells (Al-Lami and Murray, 1968b).

The type II cells were first reported by de Kock (1951) in the cat and then later she confirmed their presence in the sheep, cat and rat in 1954. These cells, according to her, are smaller than the chief or type I cells, irregular in shape, stain (Holmes' silver) pinkish red and are devoid of cytoplasmic granules. She found them interposed between the sinusoidal blood spaces and between groups of type I cells or closely applied to the latter. She stated that they are found sparingly in glomeruli, are much less common than type I, and "their relative number increases towards the entrance area of the blood supply to the carotid body" (de Kock, 1954). These type II cells or cells resembling them have also been reported in various animals: in the guinea-pig (Engstrom et al., 1967; Kondo, 1971), rabbit (Lever et al., 1959; Biscoe and Stehbens, 1966), cat (Lever et al., 1959; Ross, 1959; de Kock and Dunn, 1964; Biscoe and Stehbens, 1966; Duncan and Yates, 1967; Hess, 1968; Dearnaley et al., 1968, see ultrastructural studies of the carotid body), Weddell seal (Morita et al., 1970) and man (Willis and Tange, 1959b). The type II cells, according

to Lever et al. (1959) are more often observed in the rabbit than in the cat.

The type II cells were claimed by de Kock (1951, 1954) to be a special type of receptor cell due to the fact that they exhibited neurofibrillar network. However, Hollinshead (1940b, 1943) and Abraham (1969) did not find the neurofibrillar network. Many observers do not accept the "receptor" idea of de Kock (Hollinshead, 1940b, 1943; Adams, 1957a; Abraham, 1969).

Interstitial Cells

Meijling (1938) first described the interstitial cells and later de Kock (1954) reported that they were of two types, stellate and non-stellate in the carotid body of the sheep, cat and rat. It was their idea that these cells played the part of intermediaries between the afferent fibres and the glomus cells. Adams (1958) stated that the precise relationships of these cells to the nerve terminations is by no means clear. Abraham (1969) denied the presence of these cells in the carotid body.

Fuchsinophilic Cells

According to Hollinshead (1945), there are usually a few stellate cells, whose cytoplasm is crowded with granules brilliantly stained with fuchsin, wedged among the larger and more rounded chemoreceptor cells of the mouse. One or two irregular shaped cells, which stain brilliantly red with Holmes' silver stain, have been reported to be usually present in the carotid body of the sheep, cat and rat (de Kock, 1954). These small stellate cells have also been reported to be apparently unchanged either in

number or granulation under anoxia (Hollinshead, 1945). In 1957, Ross demonstrated both fuchsinophilic and siderophilic granules in the carotid body of the cat.

Ganglion Cells

Ganglion cells have been reported in the carotid body of various animals: in the rat, rabbit, monotremes (Tachyglossus), hedgehog, cat, pig, sheep, horse, pilot whale, Weddell seal and man. They were found to be present in the carotid body of the sheep, rat and cat (de Kock, 1954), pilot whale (de Kock, 1956), cat, in the periphery of the connective tissue capsule, (Ross, 1959), rabbit, also in the periphery of the connective tissue capsule, (Ross, 1959), rabbit, also in the periphery of the connective tissue capsule, (Biscoe and Stebhens, 1966), pig, between the glomeruli, (Abraham, 1968a), horse, in the capsule and connective tissue septa, (Abraham, 1958, 1968a, 1969), and elsewhere in the carotid body of monotremes (Tachyglossus) (Dowd, 1966) and the hedgehog (Abraham, 1968a). Although ganglion cells have been described in the sheep, cat and rat by de Kock (1954), Abraham (1968a, 1969) did not find them in the sheep or in horned cattle. Gerard and Billingsley (1923) stated that there were no nerve cells of any type in the carotid body of the cat, dog and man but on the other hand Abraham (1969) claimed to have found single nerve cells in the periglandular plexus of carotid body of man. According to Abraham (1968a) the nerve cells and ganglia found in the hedgehog, having only one process, belong to the glossopharyngeal system, and those of the pig and horse possessing two or more processes, belong to the sympathetic system.

INNERVATION OF THE CAROTID BODY

There are two major theoretical views proposed by de Castro (1926) and Meijling (1938) regarding the innervation of the carotid body. According to de Castro, only the glossopharyngeal nerve exclusively supplies the capsular (periglandular) and periglomerular (perilobular) plexuses and the fibres inside the lobules (intra-glomerular plexuses) are the terminations of the medullated fibres which come from the latter. Section of the IX nerve below the ganglion caused degeneration of the fibres supplying the lobules **indicating that they were receptors** (de Castro, 1926). In 1928 he again performed the IX nerve section above the ganglion and found that the fibres supplying the lobules remained unchanged, so he again claimed that they were sensory receptors. De Castro's terminal reticulum concept has had many supports (Riegele, 1928; Sunder-Plassmann, 1933; Rasario, 1937; Hollinshead, 1940b, 1943; Abraham, 1969). The idea of double innervation of the carotid body lobules from sympathetic and parasympathetic sources was later proposed and accepted by many observers (Palumbi, 1940; Abraham, 1953a, 1968a, 1969; Stohr, 1950, 1951, 1957; Adams, 1958).

On the other hand, Meijling (1938), according to Adams (1958), maintained that the specific cells of the carotid body formed a syncytium in which are embedded interstitial cells which act as intermediaries between the afferent fibres and the specific cells; this concept has been supported, according to Adams (1958), by White (1935), Goormaghtigh (1939), Martinez (1939), de Kock (1954) and Clermont (1955).

Nerve Fibre Terminals and Nerve Endings

The various forms of nerve endings have been described as "menisque terminaux" (de Castro, 1929), plates or nerve end plates in the guinea-pig (Engstrom et al., 1957), and fibres only, in the hedgehog (Adams, 1957a; Abraham, 1968a), free nerve endings, tiny loops and bulbs in the cat (Hollinshead, 1939), end bulbs or end rings in the dog (Abraham, 1968a, 1969), plates on end fibres in the sheep (Abraham, 1968a), end systems and end arborizations in cattle (Abraham, 1968a), end arborizations of a variety of forms in the horse (Abraham, 1968a) and end bulbs, end rings or end knots in man (Abraham, 1968a, 1969).

There is controversy as to the localization of the terminal nerve fibres or endings of the carotid body; some consider that they penetrate the cytoplasm (intracytoplasmic) of the carotid body (Riegele, 1928; Boeke, 1932; de Castro, 1951) or of the aortic body (Nonidez, 1935a), whereas many observers have claimed that they did not penetrate the chief cell cytoplasm (pericellular or appositional) (de Castro, 1926, 1929; Riegele, 1928; Sunder-Plassman, 1938; Abraham, 1953a, 1969). The pericellular or appositional nature of nerve fibre terminals or nerve endings has been confirmed by electron microscopical studies (Ross, 1957, 1959; Engstrom et al., 1957; Lever et al., 1959; Garner and Duncan, 1958; Biscoe and Stebbens, 1965, 1966; Al-Lami and Murray, 1968b; de Kock and Dunn, 1964, 1968; Hess, 1968; Dearnaley et al., 1968; Kondo, 1971; Abbott et al., 1972). According to Ross (1957) the end fibres of glossopharyngeal nerve end directly and freely on the surface of the glomus cells. Abraham (1969) reported that all kinds of fibres ramify near their

site of junction with the glomus cell (in close contact with the cells), and nerve end bulbs or end rings are located between or sometimes on the glomus cells of the dog.

The occurrence of nerve fibres and arborizations in the capsular vein of the human carotid body (Abraham, 1969), and in the "capsular artery" of the carotid body of the sheep (Abraham, 1968a, 1969) and the dog (Abraham, 1969) has been reported. Also, the artery of the carotid body and occipital artery in the cat, up to the level of origin of the artery of the carotid body, has been found to be rich in baroreceptor nerve endings (de Castro, 1940).

RESULTS

A. HISTOLOGY OF THE NORMAL CAROTID BODY

Shape, Size and Position

The carotid body of the lamb is an oval, rounded or irregular shaped mass of tissue situated on the craniomedial aspect of the occipital artery or occipitoascending pharyngeal arterial trunk (Plate II, Fig. 1), at or around the origin of the ascending pharyngeal artery (Plate II, Fig. 2), or situated at the angle formed by the origin of the external carotid artery and occipital artery (or occipitoascending pharyngeal arterial trunk). The greater part of the carotid body tissue was compact and capsulated in seven animals (Plate V, Fig. 1) while in the remaining two all the glomic tissue was either scattered around the origin of the ascending pharyngeal artery or widespread around the carotid trifurcation (Plate II, Fig. 3). In some specimens the scattered

glomerular tissue was 0.88 mm to 1.40 mm away from the main compact carotid body tissue. In two out of six specimens studied prior to fluorescent microscopy, the carotid body tissue was scattered around the origin of the ascending pharyngeal artery (Plate XVIII, Fig. 1) or the occipital artery (Plate XIX, Fig. 2).

The sizes of the carotid bodies studied varied widely from 1.25 x 0.54 x 0.80 mm to 1.75 x 0.75 x 1.84 mm (Tables V, VI, VII). The left and right carotid bodies were found to be unequal in size. In all specimens studied the carotid bodies were never related to the internal carotid artery which, in the lambs, was usually patent (Plate XV, Fig. 2).

Capsule and Lobulation

The compact carotid body tissue was surrounded by a collagenous connective tissue capsule which was in part continuous with the adventitia of the ascending pharyngeal artery, the occipital artery, the occipitoascending pharyngeal arterial trunk or the external carotid artery (Plate II, Figs. 1, 2; Plate IX, Fig. 2; Plate XIX, Fig. 2). The capsule was not very distinct, except in one specimen studied prior to fluorescent microscopy, and in it no elastic fibres were demonstrable by the stains and the staining technique employed: orcein, Verhoeff's elastin stain, Gomori's aldehyde fuchsin and Masson's trichrome stain. The scattered carotid body tissue possessed a thin connective tissue capsule. The capsule, particularly that around compact tissue, contained myelinated and nonmyelinated nerve fibres, blood vessels and lymphatics. Strands of connective tissue extended into the carotid body substance thereby dividing the organ into separate

Method of Determining the Size of the Carotid Body

Measurements of the length, breadth and thickness of the carotid body as a whole were carried out on the serial paraffin sections. Serial sections 5μ thick were cut through the entire carotid body and the total number of the serial sections was noted. Every tenth section was mounted on a glass slide and stained with haematoxylin and eosin. The greatest length and greatest breadth of the carotid body was obtained by measuring these dimensions on the mounted serial sections, using the stage micrometer of the microscope. The thickness of the carotid body was calculated by multiplying the section thickness by the total number of serial sections obtained from the entire carotid body.

TABLE V.

SIZE OF THE NORMAL CAROTID BODY

Animal	Whole organ (mm)		Diameter of largest lobule (mm) ⁺
	Left	Right	
1. Lamb	1.62 x 1.35 x 0.70	1.35 x 1.21 x 0.86 0.25 x 0.07 x 0.22	0.32
2. "	0.78 x 1.02 x 1.00*	0.73 x 0.33 x 0.10 0.50 x 0.25 x 0.20	0.10
3. "	0.85 x 0.35 x 1.36	1.21 x 0.57 x 0.80	0.17
4. "	1.25 x 0.54 x 0.80*	1.12 x 0.43 x 0.60*	0.28
5. "	1.20 x 0.85 x 1.20*	1.05 x 0.70 x 1.00*	0.35
6. "	1.00 x 1.00 x 1.42	1.45 x 0.52 x 1.30	0.25
7. "	1.35 x 0.66 x 0.84	1.00 x 0.75 x 1.24	0.24
8. Sheep	1.90 x 0.70 x 1.42	1.30 x 0.80 x 1.64	0.29
9. "	1.30 x 0.45 x 1.03	1.75 x 0.75 x 1.84	0.37

* approximates from the serial frozen sections

+ the largest diameter of a carotid body lobule as measured from a random selection of serial sections

Right carotid body of animal 2 had two portions

Animals 1 to 7 were between six and eight months old; animals 8 and 9 were between one-and-a-half and two years old.

TABLE VI.

SIZE OF THE NORMAL (CONTROL) AND
DENERVATED (AFTER SECTIONING OF THE CAROTID
SINUS NERVE) CAROTID BODY (IN mm)

Animal	Right (control)	Left (denervated)
N 1	1.01 x 0.80 x 1.45	1.00 x 1.00 x 1.50
N 2	1.40 x 0.45 x 0.86	1.61 x 0.50 x 0.92
N 3	1.50 x 1.10 x 1.73	1.25 x 0.79 x 1.20
N 4	1.05 x 0.90 x 1.22	1.15 x 0.80 x 1.34
N 5	1.23 x 1.21 x 0.68	1.19 x 0.60 x 1.01

TABLE VII.

SIZES OF THE NORMAL (CONTROL) AND
SYMPATHECTOMISED CAROTID BODY (IN mm)

Animal	Right (control)	Left (sympathectomized)
G 1	1.16 x 1.17 x 1.95	1.16 x 1.00 x 1.43
G 2	2.00 x 1.05 x 1.25	1.70 x 0.57 x 1.25
G 3	1.92 x 1.15 x 1.48	1.13 x 0.80 x 0.62
	0.30 x 0.90 x 0.60	2.00 x 1.23 x 1.40
G 4	1.15 x 0.95 x 1.50	1.55 x 0.85 x 1.37

The carotid bodies of animal 3 had two portions

The identification of each animal in Tables VI and VII is as in Table II

and distinct lobules (Plate III, Figs. 1,2,3). These collagenous septa provided passage for the blood vessels, lymphatics and nerves.

Fibroblasts and Schwann cells were seen in the connective tissue skeleton of the carotid body. They usually accompanied the nerve trunks to reach the interlobular and intralobular glomic tissue. The nucleus of the fibroblast was smaller and stained much more deeply than that of the Schwann cell and was 6-15 μ long and 1-2.5 μ wide. The Schwann cell exhibited a very pale and scanty cytoplasm around the elongated and flattened nucleus which was 14-17 μ in length and 2-3 μ in width. The Schwann cell nucleus displayed a dense accumulation of chromatin material especially at the periphery of the nucleus.

Ganglion cells were occasionally found in the connective tissue capsule (Plate III, Fig. 2) or in the vicinity of the carotid body among the nerve trunks (Plate XII, Fig. 1). Only in one specimen were they seen within the carotid body lobules. Those within the lobules were very similar to those found in the glossopharyngeal nerve. The ganglion cells were unipolar with an eccentrically placed nucleus. They were up to 32 μ in diameter and their nucleus was 10 μ in diameter. The round to oval nucleus exhibited 1-3 nucleoli in tissue sections impregnated with silver nitrate or silver chloride. Except in two lambs, ganglion cells were not observed in the carotid bodies of lambs whose carotid sinus nerve had been sectioned. These unipolar ganglion cells were presumed to be the sensory ganglion cells of the glossopharyngeal nerve.

Carotid Body Artery

The carotid body artery arose from the ascending pharyngeal artery, occipital artery or occipitoascending pharyngeal arterial trunk. Its diameter at the origin varied from 0.15 mm to 0.22 mm in the specimens examined. It usually divided into two or more branches to supply the carotid body, carotid sinus, and the external carotid and carotid sinus nerves. In some specimens parts of the carotid sinus, external carotid and glossopharyngeal nerves were also supplied by a separate arterial twig from the ascending pharyngeal artery. The diameter of the carotid body artery, outside the carotid body tissue before it divided into smaller arterial branches was 0.08 mm to 0.18 mm. The diameter of the carotid body artery, within the substance of the organ after its division, was 0.07 mm to 0.13 mm.

The carotid body artery had an elastic structure from its origin to the level of the carotid body. The media and intima were 5-15 μ thick, the adventitia was 2.5-12.5 μ , and the total arterial wall thickness of the carotid body artery was 7.5 μ to 20 μ . The number of elastic membranes present at various levels of the artery ranged from 2 to 6 (Plate VIII, Fig. 1). The carotid body artery in the lamb and sheep was richly supplied with nerve fibres some of which also supplied the carotid body tissue. Usually the nerve fibres coursed along the adventitia of the artery before entering the tunica media. Fine nerve branches were seen in the deeper adventitia and in the media of the carotid body artery (Plate VIII, Fig. 2).

Carotid Body Veins

Eight to twelve small veins 0.02 mm to 0.05 mm in diameter emerged from the carotid body capsule and united on the surface of the capsule to form 1 to 3 larger veins (Plate V, Figs. 1,2). The larger veins with diameter ranges from 0.05 mm to 0.08 mm received veins of the same sizes from the carotid sinus, and the common carotid and external carotid arteries (Plate V, Fig. 1). The larger veins were supplied with nerve fibres (Plate VIII, Fig. 3) but it was not possible to identify them in the walls of small vessels.

Carotid Sinus Nerve

The diameter of the carotid sinus nerve varied from 0.50 mm to 0.78 mm in the animals examined. The perineural sheath was usually 0.01 mm to 0.20 mm thick but in some specimens it was up to 0.30 mm thick. The sinus nerve at its mid point contained 3-5 nerve bundles; before it reached the carotid body and carotid sinus it was composed of 5-16 nerve bundles (Plate II, Fig. 3). The diameter of the smallest nerve bundle was 0.06 mm and of the largest was 0.20 mm to 0.30 mm. In all nerve bundles there were both myelinated and nonmyelinated nerve fibres. In the large nerve bundles, there were three different diameters of myelinated nerve fibres, large, medium and small. The large nerve fibres were 8-12 μ in diameter (including myelin sheath), the medium sized fibres were 4-5 μ in diameter and the small nerve fibres were 1 μ to 1.5 μ in diameter. In each nerve bundle the small diameter nerve fibres were numerous and the large diameter nerve fibres were comparatively few, while the number of medium size

nerve fibres was intermediate. The nerve fibres, especially the large diameter nerve fibres, exhibited regular thickenings and narrowings along their course in tissues impregnated with silver solutions. However, tissues fixed in Regaud's fluid and post-chromated for at least 2-3 days, and tissues fixed in modified Karnovsky's fluid and post-fixed in osmium tetroxide solution, did not show these axoplasmic varicosities. Some of the nerve bundles from the carotid sinus nerve by-passed the carotid body to supply the carotid sinus (Plate VII, Fig. 1).

External Carotid Nerve

The external carotid nerve, a branch from the cranial cervical ganglion, was also called the ganglio-glomerular nerve by Eyzaguirre and Uchizono (1961). The diameter of the external carotid nerve was 0.40 mm to 0.81 mm. The perineural sheath of the nerve was 0.05 mm to 0.32 mm thick, and the thickest portion of the sheath was found in the proximal portion of the nerve. It was sub-divided into 5-8 nerve bundles before reaching the carotid trifurcation. These nerve bundles were 0.04 mm to 0.20 mm in diameter and each contained up to five myelinated axons. The external carotid nerve contained mostly unmyelinated fibres 0.50 - 2.00 μ in diameter and very few myelinated nerve fibres 3-8 μ in diameter. The smaller myelinated axons were 3-4 μ and the larger ones up to 8 μ in diameter. The number of myelinated axons in each nerve bundle varied considerably.

TYPES OF CELLS IN THE CAROTID BODY

Chief Cells

The chief (type I) cells form the majority of the carotid body cell groups. The type II cells are smaller cells which surround the type I cell or cell groups. As the term "type II" does not imply any specific function, it is used throughout this study.

The chief cells were of irregular shape with a diameter of 8-13 μ . They possessed a centrally placed round to oval nucleus. The chief cells occurred either singly or in groups of two or five cells and were closely related to sinusoids. The cytoplasm was foamy and slightly granular in appearance. In tissues fixed in formalin, formol saline, formol-acetic alcohol, formol-glycerin, Bouin or Bouin's fluid modified by Davenport (1960), the cytoplasm of the carotid body cells generally exhibited cytoplasmic vacuolation (Plate IV, Fig. 3; Plate X, Fig. 1). However, tissues fixed in Regaud's fluid and postchromated for 2-3 days showed very finely granular cytoplasm without cytoplasmic vacuolations (Plate IV, Figs. 1,2).

There appeared to be two types of chief cell, one with a smaller, deeply staining nucleus and the other with a larger pale nucleus. The smaller "chromophil" cells were 8-10 μ in diameter with nuclei 3-5 μ in diameter. The nucleus of smaller chief cells was rich in chromatin material and was readily stained with most stains. The nuclear membrane was thick and dense. In tissue sections impregnated with silver solutions the nuclei exhibited one to three

nucleoli (Plate VI, Fig. 2; Plate VII, Fig. 3). The larger type of chief cell was 10-13 μ in diameter and the pale, rounded nucleus was 4-7 μ in diameter. The nucleus exhibited chromatin granules and its membrane was thin but distinct.

It was not possible to demonstrate the cytoplasmic processes in tissues fixed in Regaud's fluid or in any other fixatives employed in this experiment. The carotid body cells formed independent cellular elements and did not show any syncytial arrangements. The cell boundaries were sharply outlined in properly fixed tissues and did not show any anastomoses between themselves or cells of other types.

The carotid body cells displayed a slight variation in their staining reactions. Cytoplasmic organelles and fuchsinophil cells could not be identified by the histological techniques employed in this study. The interstitial cells of Meijling (1938) and de Kock (1954) were not observed in the carotid body.

Type II Cells

The type II cells were irregularly shaped cells whose nuclei stained more deeply than those of the chief cells. The nucleus was irregularly triangular in shape and measured 3-6 μ in diameter. The type II cells were closely associated with the type I cells or cell groups. The cytoplasmic processes of the type II cells and their exact relationship to the type I cells could not be identified under the light microscope. The nucleus of the type II cell possessed a dense and distinct nuclear membrane and scattered chromatin material. The type II cells were best observed in the carotid body lobules located near the periphery of the carotid body.

Sinusoids and Arterioles of Carotid Body

Biscoe and Stehbins (1966) and Biscoe (1971) did not use the term sinusoid, instead they described them as blood vessels of the carotid body. According to Bloom and Fawcett (1962), Majno (1965) and Han (1969) sinusoids have intercellular gaps and their basement membranes are discontinuous. However, many observers used the term sinusoid (Hoffman and Birrell, 1958; Garner and Duncan, 1958; Lever and Lewis, 1959; Lever et al., 1959; de Kock, 1960; de Kock and Dunn, 1964, 1968; Al-Lani and Murray, 1968a,b; Hess, 1968; Torrance, 1968; ~~Kondo~~, 1971; and Abbott and Howe, 1972). For convenience in this light microscopical study, all blood vessels within a diameter range of $5\ \mu$ to $30\ \mu$ were categorized as sinusoids.

The diameter of sinusoids in the carotid body ranged from $5\ \mu$ to $16\ \mu$. Type I cells or cell groups were seen very closely associated with the sinusoidal wall. In these situations an intercellular gap of only $0.5\ \mu$ to $1\ \mu$ separated the endothelium and the type I cells. However, some of the type I cells were about $1-3\ \mu$ distant from the sinusoidal wall.

The arterioles of the carotid body measured $8-25\ \mu$ in diameters, and they were lined by 2-5 endothelial cells (Plate IV, Fig. 1).

INNERVATION OF THE CAROTID BODY

Types and Distribution of Nerve Fibres

The carotid body received both myelinated and nonmyelinated fibres through the carotid sinus and external carotid nerves. Some of the fibres (both myelinated and nonmyelinated) either bypassed the carotid body or passed through the substance of the organ to reach the carotid sinus (Plate VII, Fig. 1). Most of the myelinated fibres showed a poor staining reaction for the myelin sheath in tissues fixed in the routine histological fixatives. However, the myelin sheaths of tissues fixed in Regaud's fluid stained well with myelin stains. Also, tissues fixed in modified Karnovsky's fluid or 5% glutaraldehyde solution (phosphate buffered) and subsequently stained with osmium tetroxide and uranyl acetate showed myelin sheaths very well.

The diameter of myelinated fibres located within the interlobular and intralobular substance ranged from $1\ \mu$ to $6\ \mu$. The nerve fibres did not form any nerve plexuses in the capsule or within the carotid body.

Morphology of Nerve Terminals

In the present study no nerve endings which could be regarded as species specific for Ovis aries were seen in the carotid body of sheep. No specific nerve endings were demonstrable in carotid body tissue sections impregnated with silver by various techniques and procedures as described by Rogers (1931), Bodian (1936, 1937), Holmes (1942, 1943), Romanes (1950), Ungewitter (1951), Winkelmann and Schmit (1957), Winkelmann (1959), Abraham (1969) and

Bielschowsky-Gros-Cauna procedure according to Abraham (1969) (Plate VI, Figs. 1,2,3; Plate VII, Fig. 3).

Relationships of Nerve Terminals with Glomus Cells

Nerve fibre terminals were seen very closely associated with the chief cells of the carotid body. They appeared to terminate on or very close to the chief cells or cell groups (Plate VI, Figs. 2,3; Plate VII, Fig. 3). However, it was not possible to identify with certainty the exact mode of contact of the nerve terminals with the chief cells under the ordinary light microscope. Menisci ("menisques terminaux") of de Castro (1929) or the distinct rings or end knots (end spheres) of Abraham (1969) observed in man were not detected in the specimens examined. No nerve end formations or neurofibrils were observed in the cytoplasm of the chief cells (Plate VII, Figs. 2,3; Plate X, Fig. 2; Plate XII, Fig. 3).

Innervation of Carotid Body Blood Vessels

The carotid body blood vessels were supplied with fine nerve fibres about $1\ \mu$ in diameter. Some of the nerve fibres traversed the substance of the carotid body to reach the carotid body artery. Fine nerve fibres ran in the adventitia for a short distance before entering the deeper adventitia. Fine nerve branches in the superficial tunica media were associated with the smooth muscle cells of the carotid body artery (Plate VIII, Fig. 2). The veins draining the carotid body and carotid sinus were also supplied with nerve fibres. These nerve fibres were larger in diameter than were those supplying the carotid body artery. The fibres were seen only within the adventitia of the carotid body veins (Plate VIII, Fig. 3).

Innervation of Internal Carotid Artery

The internal carotid artery was supplied with fine nerve fibres $1\ \mu$ in diameter. The nerve fibres were observed mainly within the adventitia but were occasionally seen entering the superficial layer of the tunica media where they were usually associated with smooth muscle fibres (Plate XV, Fig. 3). It is noteworthy that nerve fibres were found in the media of the regressing internal carotid artery of the lambs.

B. HISTOLOGY OF THE DENERVATED CAROTID BODY (AFTER SECTIONING OF THE CAROTID SINUS NERVE)

In one lamb (N2), the control and the denervated carotid trifurcations were treated according to the modification technique of Nauta and Gyax (1951, 1954) as recommended by Hanlyn (1957). In both control and denervated carotid bodies no nerve fibres were stained. Even the nerve fibres in the large nerve trunks remained unstained.

In the second lamb (N1) the control and denervated carotid trifurcations were treated according to the modification technique of Nauta and Gyax (1951, 1954) as recommended by Guillery et al. (1961). In the control carotid body, the large diameter nerve fibres, especially those about $2.5\ \mu$ in diameter, were well stained. These nerve fibres did not exhibit any marked thickenings or narrowings along their course. Carotid body lobules were richly innervated. Some nerve fibres passed through the organ to supply the carotid sinus. However, in the denervated carotid body it was not possible to identify nerve fibres with certainty (Plate IX,

Fig. 1).

In the remaining three lambs (N3, N4, and N5) the normal and denervated carotid trifurcations were serially sectioned at 12-14 μ thickness to be treated for nervous structures by Romanes' (1950) silver chloride method. A few sections of 5-7 μ thickness were also made from each carotid body to study the cellular structure.

The carotid body cells and the blood vessels did not show any detectable changes one month after sectioning of the carotid sinus nerve (Plate IX, Figs. 1,2; Plate X, Figs. 1,2). Marked degenerative changes were observed in the carotid sinus nerve and its fibres supplying the carotid body, whereas the sympathetic fibres were intact. Large diameter myelinated nerve fibres normally seen in the control carotid bodies (Plate VII, Fig. 2) were absent in the denervated carotid bodies (Plate X, Figs. 2,3). In the denervated specimens the carotid body lobules were apparently devoid of nerve fibres. Fine nerve fibres presumably sympathetic fibres were observed in the denervated carotid bodies in the connective tissue capsule, and in the interlobular connective tissue and in close association with the blood vessels (Plate X, Fig. 3). However, no such fine nerve fibres were observed inside the denervated carotid body lobules (Plate X, Fig. 2).

C. STRUCTURE OF THE CAROTID BODY AFTER SECTIONING OF THE EXTERNAL CAROTID NERVE OR CRANIAL CERVICAL GANGLIONECTOMY

The structure of the carotid body cells did not show any detectable morphological changes after sectioning of the external carotid nerve or cranial cervical ganglionectomy (Plate XI, Figs. 1,2,3). However carotid body veins and sinusoids of the denervated specimens were apparently dilated (Plate XI, Figs. 1,2,3).

The external carotid nerve and its branches to the carotid trifurcation were found to be markedly degenerated. The small diameter nerve fibres usually found in the connective tissue capsule and interlobular tissue of the normal carotid body and in the wall of the carotid body artery were absent in the denervated specimens. The intact nerve fibres, presumably of the carotid sinus nerve were found in the interlobular and intralobular tissue of the denervated carotid bodies (Plate XII, Figs. 2,3). These nerve fibres ended mainly in relation to the carotid body chief cells (Plate XII, Fig. 3). The predominant nerve supply of the carotid body from the carotid sinus nerve was apparent when the carotid bodies, after sympathectomy and after sectioning of the carotid sinus nerve, were compared. After sympathectomy there seemed to be no apparent reduction in the number of nerve fibres in the carotid body (Plate XII, Fig. 2) whereas after sectioning of the carotid sinus nerve a very marked reduction in the number of nerve fibres was seen in the carotid body (Plate X, Figs. 2,3).

DISCUSSION

The carotid body of sheep possessed a thinner capsule compared to laboratory animals such as the guinea-pig, rabbit and cat. The nerve fibres in the capsule did not show any plexus formation which is in contrast to the report of Abraham (1969). The position and distribution of the carotid body tissue varied considerably in different individuals. As similar variations were also recorded in cattle and the goat (Adams, 1958), this probably is the case in ruminants generally.

The artery of the carotid body which supplies the carotid body and carotid sinus is elastic in nature from its origin up to the level of the carotid body. A similar situation has been reported by Muratori (1967) and de Castro and Rubio (1968) in the dog, cat and rabbit. The innervation pattern observed in the artery of the carotid body was similar to those described by Abraham (1969) and de Castro (1940). Also the presence of nerve fibres in the walls of carotid body veins agreed with the reports of Abraham (1968, 1969).

The presence of type I and type II cells of de Kock (1954) were confirmed in the sheep. Although Abraham (1969) did not favour the idea of categorizing carotid body cells into type I and type II, he stressed the differences in the nuclear shape and staining reactions. The "light" and "dark" cells found in many species are also observed in the sheep. The "dark" cell population is comparatively small in the sheep, and apparently is not affected one month after denervation of either the carotid sinus nerve or external carotid nerve.

The cytoplasmic processes of chief cells are not identifiable with certainty under the light microscope. Apparently all glomus cells studied under the light microscope seemed to be devoid of cytoplasmic processes, which agrees with Abraham (1969). Neither neurofibrils nor neurofibrillar networks were observed, which accords with the findings of others (Hammond, 1941; Hollinshead, 1943 and Abraham, 1969). Interstitial cells as such, which were described by de Kock (1951, 1954) but whose existence was denied by Abraham (1969), were not observed in the present study.

Ganglion cells were detected. Such cells had been described by de Kock (1954) although they were not mentioned by Abraham (1969). Ganglion cells were present in both normal and sympathectomized carotid bodies. It has been suggested by Abraham (1968) that these unipolar ganglion cells belong to glossopharyngeal system.

The carotid body of the lamb received both glossopharyngeal (via carotid sinus nerve) and sympathetic (via external carotid nerve) nerve supply. From the present nerve section experiments it is suggested that glossopharyngeal fibres predominate over sympathetic fibres. The large diameter myelinated nerve fibres which totally disappeared (degenerated) after division of the carotid sinus nerve, terminated in relation to the type I cells of the carotid body. These same fibres also supplied the carotid sinus and degenerated after sectioning of the carotid sinus nerve. These fibres could possibly be what Abraham (1968, 1969) called, separately, afferent (sensory) fibres of the carotid body and baroreceptor fibres of the carotid sinus.

The glossopharyngeal nerve fibres which reached the carotid body via the carotid sinus nerve were markedly degenerated after one month chronic denervation. A similar marked degeneration of nerve fibres to the aortic body of the cat were described by Hollinshead (1939) after sectioning of the vagus nerve.

The present study agrees with Abraham (1968, 1969) on the nature of the nerve fibres and nerve terminals. The terminal nerve fibres did not penetrate the chief cell cytoplasm; these seemed to be pericellular or appositional in nature.

No detectable morphological changes were seen in the glomus cells after division of the carotid sinus nerve, the external carotid nerve or cranial cervical ganglionectomy.

The nerve fibres seen in the carotid body artery and veins were predominantly of sympathetic origin as these fibres disappeared markedly in the sympathectomized specimens. However, the possible presence of glossopharyngeal fibres (via carotid sinus nerve) in these blood vessels could not be excluded.

SUMMARY

1. The normal carotid bodies of lambs and sheep were studied histologically to determine the size, shape, position and distribution of carotid body tissue, cell types and innervation. The structures of the artery and veins of the carotid body, the carotid sinus and external carotid nerves were also examined. In the denervated specimens - after sectioning of the carotid sinus and external carotid nerves or cranial cervical ganglion-

ectomy - the structure of the glomus cells, and degenerated and intact nerve fibres were also examined using various normal and degenerated nerve stains.

2. The carotid body was usually of oval shape. Its position varied in different individuals or even in the same individual. Also a widespread distribution of carotid body tissue at the carotid trifurcation was observed.
3. There are two major cell types in the carotid body, the chief or type I and sustentacular or type II cells; the former included both "light" and "dark" cells.
4. The artery of the carotid body was of the elastic type from its origin up to the level of carotid body.
5. The carotid sinus nerve consists mostly of myelinated nerve fibres of diameters 1-12 μ whereas the external carotid nerve consists mainly of fine nonmyelinated fibres of diameters 0.5-2.0 μ .
6. The carotid body cells received both glossopharyngeal (via carotid sinus nerve) and sympathetic (via external carotid nerve) innervation. From the present study it is suggested that the glossopharyngeal fibres predominate in the carotid body.
7. The large diameter myelinated nerve fibres which degenerated after section of the carotid sinus nerve, terminated in close association with the chief or type I cells.
8. The small diameter nerve fibres of the external carotid nerve (sympathetic) terminated in the wall of the artery and veins of the carotid body.

9. The glomus cells did not exhibit any detectable morphological changes after section of the carotid sinus nerve, external carotid nerve or cranial cervical ganglionectomy. However, a marked dilatation of the blood vessels (sinusoids) was seen in sympathectomized specimens.

10. It is suggested that the unipolar ganglion cells of the carotid body found usually at the periphery of the carotid body and occasionally in the glomic tissue are of glossopharyngeal origin.

CHAPTER FIVE

LIGHT MICROSCOPY OF THE CAROTID SINUS

INTRODUCTION

The carotid sinus of various mammalian species has been studied extensively since the discovery of the baroreceptor reflex function of the carotid sinus by Hering in 1924. Although these studies have been conducted in a variety of vertebrates, very few have been conducted in the sheep. Abraham (1958) studied the carotid sinus of sheep and various other vertebrates. However, he made no mention of the carotid sinus of the sheep in particular, except that he stated that the fibres of the carotid sinus nerve of the sheep are markedly thick and varicose and run parallel in the adventitia branching on reaching the media. Later, Abraham (1969) mentioned the innervation of the carotid sinus and the end plate system in the carotid sinus wall.

The present study was undertaken in normal lambs and sheep in an attempt to study:

- (i) the structure and elastic tissue composition of the carotid sinus,
- (ii) the distribution of nerve fibres in the carotid sinus wall, and
- (iii) the morphology of the terminal nerve end system and its relation to the connective tissue and smooth muscle fibres.

The carotid sinuses of 9 lambs (N1 to N5 and G1 to G4) were also studied after chronic denervation (sectioning of the carotid sinus nerve, cranial cervical ganglionectomy, or sectioning of the

external carotid nerve - the sympathetic branch to the carotid trifurcation). The following studies were conducted in the denervated specimens:

- (i) to determine whether there were any resultant morphological changes in the carotid sinus structure,
- (ii) to trace the degenerated nerves (glossopharyngeal and sympathetic fibres) using the modification techniques of Nauta and Gyax (1951, 1954) as recommended by Hamlyn (1957) and Guillery et al. (1961), and
- (iii) to define the nature of persisting nerve fibres (glossopharyngeal or sympathetic), their distribution and mode of termination in the carotid sinus wall using Romanes' (1950) silver chloride method.

LITERATURE REVIEW

In most animals the carotid sinus is a swelling or dilatation of the internal carotid artery at its origin as in man, horse, rabbit, opossum, hedgehog, and guinea-pig. Hering (1924) discovered the baroreceptor reflex function of the carotid sinus, and later studies of Hering (1927), Heymans (1929) and Koch (1931) showed that the carotid sinus and aortic baroreceptors areas are of paramount importance in the reflex control of circulation.

A. COMPARATIVE ANATOMY OF THE CAROTID SINUS

From various comparative anatomical studies on the carotid body and carotid sinus, it is known that in species in which the internal carotid artery is absent such as cattle, sheep, pig and guinea-pig, the carotid sinus is replaced by a swelling at the origin of the occipital artery (de Castro, 1928; Sunder-Plassmann, 1930; Rees 1966, 1967b; Muratori, 1967; Kondo, 1971; Aumonier, 1972). This swelling is generally referred to as the occipital sinus, "occipito-carotid sinus" or "occipito-internal carotid sinus" (Adams, 1958; Muratori, 1967). In the cat and dog, both the internal carotid sinus and the occipital sinus are present (Adams, 1958; Muratori, 1967). According to Adams (1952), in some species such as Varanus varius, the carotid sinus is a complex structure which is quite different from that in other animals. It is a localized duplication of the common carotid and internal carotid arteries, in which the two channels may have accessory communication.

Reviews on the carotid sinus that may be consulted are those of Kuntz (1953), Mitchell (1953, 1956), Adams (1958), and Heymans and Neil (1958). The comparative morphology and histology of the carotid sinus in the following vertebrate species have been studied:

- Mustelus, (Boyd, 1936)
- rat, (Murphy and Hughes, 1965; Rees, 1966, 1967b)
- guinea-pig, (Murphy and Hughes, 1965; Rees, 1966, 1967b, 1968;
Kondo, 1971)

- rabbit, (de Castro, 1928; Addison, 1945; Murphy and Hughes, 1965; Muratori, 1967; Rees, 1966, 1967b, 1968; Rees and Jepson, 1970; Aumonier, 1972)
- cat, (Gerard and Billingsley, 1923; Addison, 1944; Green, 1953, 1954; Boss and Green, 1954b; Eyzaguirre and Uchizono, 1961; Hughes, 1965; Murphy and Hughes, 1965; Muratori, 1967; Rees, 1966, 1967b, 1968; Rees and Jepson, 1970; Aumonier, 1972)
- dog, (Gerard and Billingsley, 1923; de Castro, 1928; Code and Dingle, 1935; Addison, 1939; Hughes, 1965; Murphy and Hughes, 1965; Muratori, 1967; Rees, 1966, 1967b, 1968; Abraham, 1958, 1969; Rees and Jepson, 1970; Bagshaw and Fischer, 1971; Aumonier, 1972).
- sheep, (Waites, 1960; Abraham, 1958, 1969)
- pig, (Muratori, 1967; Abraham, 1958, 1969)
- cattle, (Abraham, 1958)
- mule, (Abraham, 1958)
- horse, (Abraham, 1958, 1969)
- bird, (Chowdhary, 1953; Abraham, 1969)
- Nycticebus coucang, (Adams, 1957c)
- opossum, (Adams, 1955)
- hedgehog, (Adams, 1957a)
- monotremes, (Dowd, 1964, 1966)

Varanus varius, (Adams, 1952)

Varanus monitor, (Chowdhary, 1950)

Vipera berus, (Boyd, 1942)

monkey, (de Castro, 1928; Murphy and Hughes, 1965)

man, (Gerard and Billingsley, 1923; de Castro, 1928;
Rijnders, 1933; Boyd, 1937b; Tchibukmacher, 1938;
Willis and Tange, 1959b; Riisager and Weddell,
1962; Murphy and Hughes, 1965; Hilgenberg, 1958,
1967; Muratori, 1967; Rees, 1966, 1967b, 1968;
Abraham, 1967, 1969).

Specialization of the Carotid Sinus Wall

The structure of the carotid sinus according to many observers is similar to those of the vascular tree elsewhere in the body, although there is some specialization appropriate to its function as a reflexogenic zone of the vascular tree in the higher animals.

The carotid sinus wall as reported by many observers, in general has a thinner wall and thicker tunica media than adjoining vascular structures (Green, 1954; Dowd, 1966; Rees, 1966, 1967b; Bagshaw and Fischer, 1971). According to Bagshaw and Fischer (1971) there is no modification of the whole wall of the carotid sinus. Their measurement of the carotid sinus geometry revealed that there was "significant modification of the tunica media, the adventitia and the ratio of the internal radius to both whole wall thickness or media intima thickness, compared to the internal carotid or common carotid arteries". Most observers have found that the tunica

media is especially thin particularly in the ventro-medial aspect of the sinus (de Castro, 1928; Adams, 1955, 1958; Dowd, 1966, Rees, 1966, 1967b; Muratori, 1967). According to them the tunica media is more elastic in composition than the tunica media elsewhere in the carotid region. According to Rees and Jepson (1970), the tunica media in the carotid sinus wall contains more than twice as much elastic tissue per unit volume as the media in the carotid vessels adjoining the sinus.

In the carotid trifurcation, there exist three classical vessel types, muscular, elastic and mixed (musculo-elastic). Rees (1966, 1968) described the tunica media as predominantly muscular in the internal carotid artery, elastic in the carotid sinus, and mixed in the common carotid and external carotid arteries. According to Rees (1966, 1967b), the specialized tunica media (thinner and more elastic layer) in the rat, rabbit, guinea-pig, cat, dog and human foetus, exhibited clearly marked cranial and caudal limits. He referred to it as the "elastic segment". He also added that the extent of the "elastic segment" varies in different species.

Addison (1939) and Rees (1967b) stated that the transition in structure from the carotid sinus to the adjoining structures, the internal carotid, occipital and ascending pharyngeal arteries, is abrupt whereas that between the junction of the common carotid and external carotid arteries is gradual. According to Muratori (1967), the carotid bulb of the young human subject exhibited clearly three distinguishable parts, a caudal elastic structure, an intermediate hybrid one (mixed structure) and a distal one with muscular structure. He also stated that "the carotid trifurcation is a transitional district of the arterial system between the part with elastic

structure (man) or with mixed structure (mammals) and the part with the muscular structure".

Rat

Rees (1966, 1967b) stated that the composition of the carotid sinus media in the rat is indistinguishable from that of the common carotid and the external carotid arterial walls, but that it is thinner than that of the internal carotid artery.

Rabbit

It has been stated that the carotid sinus dilatation in the rabbit is confined to the origin of the internal carotid artery (Rees, 1966, 1967b; Muratori, 1967). Muratori (1967) described the elastic structure of the carotid sinus, from which the artery of the carotid body takes its origin, as extending to the commencement of the external carotid artery.

Guinea-pig

In the guinea-pig the dilated carotid sinus, according to Rees (1967b), occupies the origin of the occipital artery, and the elastic tissue segment extends for a short distance into the origin of the ascending pharyngeal artery. The arterial wall of this specialized segment has been described as having a thin, elastic type of tunica media (Rees, 1967b; Kondo, 1971).

Cat

Addison (1944) reported that in the cat there is a small out-pouching from which both the internal carotid and the occipital

arteries arise, and that the special elastic structure of the vessel wall is present in the entire outpouching and in the first part of the occipital artery as far as the glomus caroticum. A similar statement was made by Muratori in 1967. Rees (1966, 1967b) stated that this secondary outpouching gave rise to both the occipital and ascending pharyngeal arteries.

Dog

In the dog, according to Addison (1939), the carotid sinus is the dilated beginning of the internal carotid artery at the bifurcation of the common carotid artery into the internal and external carotid arteries. In 1944, he again stated that in addition to the well developed carotid sinus, there is at the beginning of the occipital artery a small dilatation with a special elastic tissue wall. Rees (1966, 1967b) and Muratori (1967) also found that the extent of the "elastic segment" reached the origin of the occipital artery. After studying the properties of the carotid sinus mechanism in anaesthetized dogs, Peterson et al. (1960) concluded that the carotid sinus wall is the most distensible arterial segment known.

Pig

According to Muratori (1967) the common carotid artery in the pig divides into the external carotid artery, the external maxillary artery and a diverticulum "(the occipito-internal carotid sinus)" whose thin elastic tissue wall is richly innervated.

Calf

Muratori (1967) stated that in the calf the common carotid artery divides into the external carotid and external maxillary arteries, and that sometimes it exhibits a slight evagination or a conic diverticulum. The evagination has an elastic structure and possesses a rich supply of baroreceptor fibres. The conic diverticulum ("occipito-internal carotid sinus"), if present, has a mixed structure, except in the area (supplied with nerve endings) from which the artery of carotid body originates.

Man

Rees (1967b) described, in the six month-old human foetus, a dilated "elastic segment" extending from the internal carotid artery into the cranial end of the common carotid artery. Muratori (1967) described the structural composition of the carotid sinus of the human foetus in detail.

From the literature reviewed above, it is evident that, in all the animals studied, rat, guinea-pig, rabbit, cat, dog, calf, pig, horse and man, the carotid sinus is a swelling, evagination or diverticulum. Baroreceptor nerve endings have been found either in one particular area only of the carotid sinus wall where the structural composition is usually purely elastic in nature, or within the entire carotid sinus wall. It seems that the form and extent of the carotid sinus in the ruminant, especially the calf, is variable. Muratori (1967) concluded that "the carotid sinus and its associated arterial areas (commencement of the occipital artery, nutrient artery of the carotid body) in the portions supplied with baroreceptor endings have always an elastic structure".

B. INNERVATION OF THE CAROTID SINUS

From the comparative and gross anatomical studies in various vertebrates it has been found that the carotid sinus, like the carotid body, receives its nerve supply from four sources, the pharyngeal branch (carotid sinus nerve) of the glossopharyngeal nerve, the vagus, and the cranial cervical ganglion and the hypoglossal nerve (Code and Dingle, 1935; Tchibumacher, 1938; Mitchell, 1953, 1956; Adams, 1958; Abraham, 1967, 1969). The contribution from the hypoglossal nerve and its functional significance, according to Adams (1958), seems to be unimportant, and its contribution in many species has been reported to be variable or absent. From various neurophysiological studies it is known that the major nerve contribution is from the glossopharyngeal nerve via the carotid sinus nerve (the nerve of Hering), which is the most important for baroreceptor reflex function of the carotid sinus, whereas the sympathetic and vagal contributions are reported to be of only minor importance (Adams, 1958). Adams (1958) mentioned that small twigs of the glossopharyngeal nerve may reach the carotid sinus through the intercarotid plexus. It has been found that some animals, such as the hedgehog, are exceptionally peculiar in having no special carotid sinus nerve (Adams, 1957a). Various names given to the carotid sinus nerve have been mentioned fully by Adams (1958).

Adams (1958) mentioned that the intercarotid nerve may arise by several rootlets from the glossopharyngeal nerve or even from the nerve to the styloglossus. According to Boyd (1937), 60% of fibres go to the carotid sinus, and the intercarotid nerve is independent and is distinguishable from the intercarotid plexus.

The intercarotid plexus, according to Danielopolu and Manescu cited by Adams (1958), is predominantly parasympathetic, but receives fibres from both the vagus and glossopharyngeal nerves. Adams (1958) stated that "although undoubtedly this plexus has connections with both carotid body and carotid sinus, it is largely continued on the external carotid artery". Furthermore, he mentioned that direct nerve branches particularly from the glossopharyngeal nerve could be traced to the carotid sinus wall. The carotid sinus nerve usually divides, according to most investigators, into two or more branches which supply the carotid body and the carotid sinus (Tchibukmacher, 1938; Eyzaguirre and Uchizono, 1961; Kondo, 1971).

Although the carotid sinus received sympathetic fibres (presumably post ganglionic) from the cranial cervical ganglion, as described by Gerard and Billingsley (1923), Ask-Upmark (1935), Tchibukmacher (1938), Kuntz (1953), Mitchell (1956), Adams (1958), Eyzaguirre and Uchizono (1961), Rees (1966, 1967b, 1968), Biscoe and Sampson (1968), Abraham (1967, 1969) and Eyzaguirre and Lewin (1961), Willis and Tange (1959a) failed to demonstrate adrenergic fibres in the carotid sinus by usual histological techniques. In later studies using the phenolic amine-formaldehyde condensation reaction and electron microscopic examination, Rees (1966, 1967a,b) identified the adrenergic fibres in the sinus wall. Reis and Fuxe (1968), using fluorescence histochemical methods, confirmed the presence of a noradrenaline containing terminal network in the carotid sinus adventitia of the rabbit and cat. Species variation in the sympathetic contribution to the carotid sinus has been reported. Some workers reported that no sympathetic fibres could be traced to the carotid region in monotremes (Ornithorhynchus)

(Dowd, 1966), or in the rat (Reis and Fuxe, 1968). Reis and Fuxe (1968) suggested that sympathetic innervation may not be necessary for baroreceptor function in some mammals such as the rat.

In the adventitia of the carotid sinus of the rabbit, Rees (1967a) found the ultimate terminations of adrenergic nerves upon the smooth muscle cells. Similar findings were reported by Reis and Fuxe in 1967. Rees (1966, 1967b, 1968) stated that the baroreceptor endings were associated with the collagen in the adventitia and with the elastin at the medioadventitial border. From these structural relationships, Rees suggested that stimulation of the baroreceptors by the sympathetic discharge effect might be direct in the adventitia or indirect in the media of rabbit and cat and, furthermore, that the adrenergic innervated smooth muscle cells in these species seemed to have the sole responsibility of increasing the sinus wall tension and baroreceptor discharge independent of the endosinus pressure. Many investigators have claimed that the sympathetic innervation serves to set the sensitivity of the baroreceptor reflexes (Palms, 1943; Floyd and Neil, 1952; Kezdi, 1954; Peterson, 1962; Moncada and Scher, 1963; Koizumi and Sato, 1969; Mills and Sampson, 1969; Sampson and Mills, 1970). It has been proposed that the structural relationship between smooth muscle cells and the elastic laminae seems to be one of the major factors in the sympathetic modulation of the carotid sinus baroreceptor reflexes (Kezdi, 1954; Peterson, 1962; Moncada and Scher, 1963; Rees, 1966, 1967b, 1968). Peterson (1962) also claimed that baroreceptors can be fired independently of the arterial blood pressure by the contraction of the smooth muscle elements lying within the sinus wall.

Two hypotheses about the sympathetic influence on baroreceptor activity are proposed by some observers (Kezdi, 1954; Rees, 1966, 1967b, 1968; Reis and Fuxe, 1968; Sampson and Mills, 1970). One is that the sympathetic fibres might act directly to modify the sensitivity of the baroreceptors, and the other is that sympathetic activation could be mediated by the vasoconstrictor action of noradrenalin on the smooth muscle cells of the carotid sinus and hence modify the tension on the baroreceptors.

C. HISTOLOGY OF THE HUMAN CAROTID SINUS

As elsewhere in the vascular system, the carotid sinus or carotid bulb of man consists of three layers - tunica adventitia, tunica media and tunica intima.

Tunica Adventitia

The tunica adventitia is usually composed of fibrous connective tissue and is characterized by a great number of nerve fibres. Its boundary is marked by the external elastic layer which is conventionally regarded as the outermost layer of the tunica media (Willis and Tange, 1969a).

Willis and Tange (1959a) described it as consisting mainly of collagen fibres which appear as separate lamellae with few elastic fibres in between. Muratori (1967) described, at the elastic portion of the carotid sinus, elastic laminae continuing into the adventitia which became increasingly thick and rich in elastic fibres at the intermediate portion, whereas at the distal part it exhibited an internal thick layer rich in elastic fibres and an external loose

layer of connective tissue.

Early investigators, de Castro (1926, 1928), and Sunder-Plassmann (1930, 1933) confined the baroreceptor nerve endings to the adventitia. Riisager and Weddell (1962) and Abraham (1967) stated that the end fibres terminate in the inner layer of the adventitia near its junction with the tunica media. However, Abraham (1958, 1969) confirmed that the adventitia is the richest of the three layers in nerve fibres, and relatively few nerve fibres are present in the tunica media. Later studies by Rijnders (1933), Boss and Green (1956), Willis and Tange (1959a), Abraham (1958, 1969), Rees (1966, 1967b, 1968), Dropmann (1967) and Aumonier (1972) showed that most arborizations did penetrate the external elastic membrane of the tunica media.

Tunica Media

The outermost layer of the tunica media of the human "carotid bulb" shows regularly arranged numerous layers of elastic fibres. Each layer, according to Willis and Tange (1959a), has numerous interstices through which collagen fibres pass. Muratori (1967) stated that, at the elastic portion of the carotid sinus, a series of elastic membranes are separated from one another by connective tissue and smooth muscle cells, and the latter are inserted by means of small elastic tendons on to the elastic membranes. He also mentioned that small groups of transverse smooth muscle cells grow down from about the middle of the carotid sinus to the elastic portion, and that this elastic portion of the carotid sinus is richly supplied with baroreceptor nerves. Thus Muratori (1967) described the human carotid sinus as having three portions, the

proximal elastic portion, a "hybrid" intermediate portion, and a distal muscular portion. In electron microscopic examinations by Dropmann (1967) and Rees (1967b, 1968), the tunica media was found to consist of four to five broad elastic laminae between which were three to four layers of smooth muscle cells.

Tunica Intima

Muratori (1967) stated that the tunica intima of the human carotid sinus consists of endothelium and sometimes a thin layer of subendothelial connective tissue as in the common carotid artery. Most observers found no nervous structures in the tunica intima.

(i) Characteristics of Nerve Fibres in the Sinus Nerve

De Castro (1951) stated that in the cat carotid sinus nerve there were about 700 myelinated fibres and their sizes and frequencies varied as follows: 3.5% were large fibres 6-8 μ in diameter, 79% were 3-5 μ in diameter and 17.5% were less than 3 μ in diameter. Thus the sinus nerve contains predominantly large nonmyelinated fibres. Douglas and Ritchie (1956) and Douglas and Schumann (1956) also found that the sinus nerve contains both medullated (A fibres) and nonmedullated depressor afferents (C fibres). Fidone and Sato (1969) estimated A and C fibre populations in the carotid sinus nerve of the cat. According to them, in the A fibre (myelinated) population, approximately two-thirds of the fibres are chemoreceptor fibres and one-third are baroreceptor fibres, and among the C fibres (unmyelinated) two-thirds are baroreceptor and one-third chemoreceptor fibres respectively. Some observers believe that this dominance of baroreceptor C fibres is responsible for the powerful

depressor reflex elicited by intense stimulation of the carotid nerve (mediated by unmyelinated afferents) (Douglas and Ritchie, 1956; Douglas and Schumann, 1956; Fidone and Sato, 1969).

According to Eyzaguirre and Uchizono (1961) the carotid nerve of the cat consists of two types of nonmyelinated fibres, one comes from the superior cervical ganglion and the other is presumably of an intracranial source. They also found that the nonmyelinated axons ($0.1-0.3 \mu$) outnumbered the myelinated fibres ($1.0-9.0 \mu$).

Eyzaguirre and Lewin (1961) stated that nonmyelinated C fibres fell into two groups according to their conducting velocities. One group conducts at $0.3-0.4$ m/sec while the other conducts at $1.6-1.8$ m/sec, in the cat. It is suggested by some workers that nonmyelinated C fibres are responsible for the conduction of baroreceptor impulses.

(ii) Distribution of Axons and their Characteristics in the Carotid Sinus of Man

It is now well known that in all mammalian species, the tunica adventitia of the carotid sinus is rich in nerve fibres. Fibres from the glossopharyngeal nerve, the pharyngeal branch of the vagus and the cranial cervical ganglion form a rich plexus in the sinus wall. In this plexus, Abraham (1969) identified two types of fibres, one is thick and the other is thin. Some observers also reported that there was a close association of the nerve branches with the vasa vasorum in the adventitia of the carotid sinus in man. According to Rees (1967b), Willis and Tange (1959a), Dropmann (1967), and Abraham (1967, 1969) the perineural sheaths of the nerve branches may persist until they reach the deeper adventitia and myelin is practically absent when they reach the tunica media.

It has been variously reported that the diameter of axons in man ranges from 1.5-15 μ (Willis and Tange, 1959a), or 6 μ to less than 1 μ in diameter in 18 out of 20 human subjects (Riisager and Weddell, 1962). Distribution curves of axon diameter compiled by Riisager and Weddell (1962) show a sharp peak for the axons in the bundles at the 1.5 μ level (35%) and a more rounded curve for the pre-terminal axons with 40% being between 2 μ and 2.5 μ in diameter. Riisager and Weddell (1962) also stated that sometimes fibres from the carotid sinus nerve accompany each other to reach the deeper layer of adventitia and along their course they divide dichotomously.

Abraham (1969) described the dendritic branches as assuming the typical form of "depressor" fibres - an alternate broadening and narrowing. According to him, this depressor characteristic could be seen in many species other than man, such as birds, dog, pig, calf, but not in the sheep. The thick and thin fibres in the carotid sinus adventitia, like those in the sinus nerve, are thought by some to be of glossopharyngeal and vagal origin, and sympathetic origin respectively (Muratori, 1934; Nonidex, 1935b; Abraham, 1969). According to Abraham (1969) there is a complete absence of any anastomoses between the nerve rami, the terminal branches and the endplates.

(iii) Nerve End Systems in the Carotid Sinus Wall of Man and Animals

Adams (1958) reviewed the innervation of the carotid sinus of man and several vertebrate species. He mentions two neuronal concepts regarding the form and nature of nervous terminations in the wall of the carotid sinus. One, the "orthodox neuronal concept" proposed by de Castro, regards the nerve endings as

distinct and discrete, and classified them as type I and type II according to their shape and end branching systems. The other, the "terminal reticular concept" originally proposed by Sunder-Plassmann and Meijling, maintains that the ultimate meshwork of the nervous element is composed of a continuous syncytium of cells permeated by neurofibrillar reticulum.

The "orthodox neuronal concept" has received much support from later observers (Muratori, 1933; Nonidez, 1936; Abraham, 1953a,b, 1958, 1967, 1969; Hilgenberg, 1958, 1967; Willis and Tange, 1959a; Riisager and Weddell, 1962; Dowd, 1966; Rees, 1967b, 1968). Most authors deny the terminal reticular concept of innervation of the carotid sinus (Willis and Tange, 1959a; Riisager and Weddell, 1962; Abraham, 1953a,b, 1967, 1969; Dowd, 1966; Rees, 1967b, 1968).

It is now generally accepted that the nerve endings are arborizations of stem fibres formed after the sheaths of the axons cease to be apparent. These arborizations, according to Willis and Tange (1959a), occur in circumscribed areas. They described these circumscribed areas as uniaxonic and multiaxonic receptor fields. Riisager and Weddell (1962) stated that even the same parent axon showed endings similar to de Castro's type I and type II. More comprehensive studies of Abraham (1958, 1967, 1969) showed that there are variations in the appearance of endplates in different species. He reaffirmed two forms of end systems in the sinus wall of man and mammals, and denied syncytial arrangement of nerve fibres. One type of end system is constituted by a few, smooth, thick and long myelinated fibres with various sizes of thickenings along their course and bearing small end plates. The other form

of nerve end system is made up of very thick myelinated fibres with few varices and characterized by rich end arborizations bearing a greater number of large end plates.

According to some observers, the end plates are sharply defined against the surrounding connective tissue element in man and some other animals. According to Abraham (1969) the end plates in man and most animals are mostly of ivy leaf shape. The large end plates attach flatly to the inner adventitial surface (Abraham, 1969). According to Willis and Tange (1959a) the end system lies in close relation to the elastic fibres, and the branches of the arborizations run along with the elastic fibres. Riisager and Weddell (1962), however, found the nerve terminals to be closely related to the arteriolar vasa vasorum. Abraham (1969) stated that the end plate system is formed after the nerve terminals in the connective tissue layer of the sinus wall, and that the neurofibrils in the end plates form a network. He also added that in the terminal rami or in the free axons, the neurofibrillar arrangement is more or less parallel to the long axis.

Abraham (1969) stated that the end plates of the carotid sinus of the dog appear in variable form, those of the pig can be clearly distinguished from those of the dog, and in the horse there are no specific end formations. In the calf and sheep particular end system patterns and receptor apparatus characteristic of their own species have been observed (Abraham, 1968, 1969).

RESULTS

A. HISTOLOGY OF THE NORMAL CAROTID SINUS

(a) Structure and Elastic Composition of the Carotid Sinus

The carotid sinus of the sheep was found to be near the origin of the occipital artery or the occipitoascending pharyngeal arterial trunk (Fig. 35). The carotid sinus in some animals exhibited a slight bulge or diverticulum (Plate XIII, Figs. 1,3). The extent of the carotid sinus varied according to the position of the carotid body. When the carotid body was situated on the occipital artery, 3.35 mm distal to the origin, the elastic tissue layers were seen 1-1.3 mm beyond the level of the carotid body. When the carotid body was located at the origin of the ascending pharyngeal artery, the elastic tissue layers were seen 1-2 mm beyond the level of the carotid body artery which, in these situations, usually originated from the ascending pharyngeal artery itself or from the angle between the origins of the ascending pharyngeal and occipital arteries.

Three classical vessel types were found in the carotid trifurcation, mixed (musculo-elastic), elastic and muscular. The structure of the occipital artery, 1-1.5 mm from its origin from the common carotid artery, was of the musculo-elastic (mixed) type while that portion of the artery, 1-1.3 mm beyond the level of the carotid body (when the carotid body was situated on the occipital artery), was of the muscular type. The tunica media was predominantly elastic in the carotid sinus (Plate XIII, Fig. 3), mixed in the external carotid and common carotid arteries, and muscular in the occipital artery (Plate XIII, Fig. 2; Plate XV,

Key to Fig. 35.

The Elastic Tissue Composition of the Carotid Trifurcation.

Abbreviations

- ap - ascending pharyngeal artery
- cb - carotid body supplied by carotid body
artery of elastic type
- cc - common carotid artery
- cl - cranial laryngeal artery
- ec - external carotid artery
- l - lingual artery
- m - muscular branch
- o - occipital artery
- opt - occipitoascending pharyngeal arterial
trunk

The black areas indicate portions of the
artery with elastic structure.

This figure is drawn merely to represent the typical situation when the occipital and ascending pharyngeal arteries arise from a common trunk and when the carotid body is at the origin of the ascending pharyngeal artery.

Fig. 35

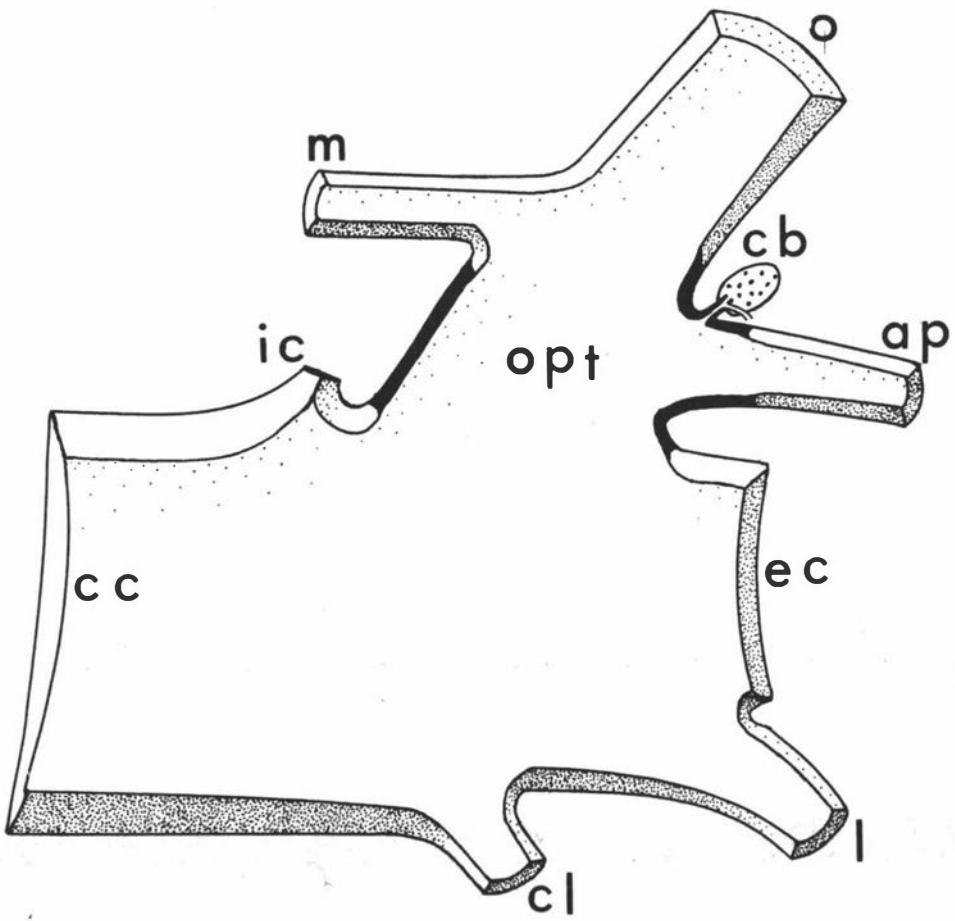


Fig. 1). The transition from musculo-elastic to elastic portions, and from elastic to muscular portions was abrupt (Plate XIII, Fig. 1).

The carotid sinus consisted of three layers - tunica adventitia, tunica media and tunica intima. The arterial wall thickness of the carotid sinus and the common carotid is shown in Tables VIII, IX and X

(i) Tunica Adventitia

The tunica adventitia of the carotid sinus was found to be slightly thicker at the origin of the carotid sinus than at the level of the carotid body. The adventitia was rich in the blood vessels, lymphatics and nerve fibres and consisted mainly of collagen fibres. There were few elastic fibres in the deeper layer of the adventitia. Also, at the origin of the carotid sinus there were elastic fibres in the superficial adventitia. About the middle of the carotid sinus there were practically no elastic fibres in the adventitia. The elastic fibres appeared gradually in the outer layer of the adventitia in the distal portion of the carotid sinus. Small arterioles found in the superficial layer of the adventitia were 1.5-1.7 mm in diameter. The diameters of the largest veins draining the carotid trifurcation were up to 2.4 mm in diameter.

(ii) Tunica Media

The sinus had a comparatively thinner wall and thicker tunica media than did the adjoining blood vessels in the carotid trifurcation (Tables VIII, IX, X). The greatest number of elastic membranes (more than 12) was observed in the wall of the carotid sinus. At the origin of the carotid sinus and at the junction between it and the occipital

Method of Obtaining the Data for Tables VII, IX and X

The entire carotid trifurcation from both sides of one lamb (approximate age, 6-7 months) was fixed in 10% formal saline by immersion. Serial, transverse, paraffin sections of 5 μ were made from each carotid trifurcation and were stained with Mayer's haematoxylin and eosin, Ponceau, and orcein. The vessel wall thickness was measured at three sites:

- (a) That lying opposite to, and at the level of, the origin of the carotid sinus;
- (b) That lying caudal to the carotid sinus;
- (c) That near the origin of the carotid sinus.

Variations in the arterial wall thickness were noted as further measurements: for example in Table VIII, three measurements were taken of the common carotid arterial wall at site (a). Similar repeated measurements were taken for Table IX.

The animal identified as animal 1 in Tables VIII, IX and X was the same animal.

TABLE VIII.

ARTERIAL WALL THICKNESS OF THE NORMAL CAROTID TRIFURCATIONS (IN mm)

Animal	Blood vessel	Thickness of intima	Tunica media		Thickness	Thickness of adventitia	Total thickness of vessel
			No. of internal elastic membranes	Total No. of elastic membranes			
1. Right	a. Common carotid	0.01	2	7	0.42	0.19	0.62
"	"	0.01	2	8	0.43	0.16	0.60
"	"	0.02	2	6	0.41	0.12	0.55
"	b. "	0.01	2	-	0.40	0.21	0.62
"	"	0.01	2	-	0.44	0.18	0.63
"	c. "	0.01	2	-	0.62	0.05	0.68
"	"	0.01	2	-	0.69	0.10	0.80

a = arterial wall lying opposite to/and at the level of the origin of the carotid sinus

b = arterial wall lying caudal to the carotid sinus

c = arterial wall near the origin of the carotid sinus

TABLE IX.

ARTERIAL WALL THICKNESS OF THE NORMAL CAROTID TRIFURCATION (IN mm)

Animal	Blood vessel	Thickness of intima	Tunica Media			Thickness of adventitia	Total thickness of vessel
			No. of internal elastic membranes	Total No. of elastic membranes	Thickness		
1. Right	a. Common carotid	0.01	-	12	0.20	0.08	0.29
"	"	0.01	-	12	0.12	0.10	0.23
"	"	0.01	-	12	0.15	0.11	0.27
"	"	0.01	1	5	0.07	0.12	0.20
"	"	0.01	-	9	0.10	0.06	0.17
1. Left	"	0.01	-	12	0.28	0.10	0.39
"	"	0.01	-	12	0.15	0.07	0.22
"	"	0.01	-	10	0.08	0.05	0.14
"	"	0.01	-	10	0.09	0.05	0.15
"	"	0.01	-	10	0.07	0.15	0.23

TABLE X.

ARTERIAL WALL THICKNESS OF THE NORMAL CAROTID TRIFURCATION (IN mm)

Animal	Blood vessel	Thickness of intima	Tunica media			Thickness of adventitia	Total Thickness of vessel
			No. of internal elastic membranes	Total No. of elastic membranes	Thickness		
1. Left	Carotid sinus at the level of artery of carotid body	0.01	-	10	0.03	0.10	0.14
"	Carotid sinus at its origin	0.01	-	12	0.10	0.14	0.25
1. Right	External carotid	0.02	2	8	0.50	0.13	0.65
1. Left	"	0.02	2	8 approx.	0.33	0.17	0.52
"	"	0.02	2	8 approx.	0.42	0.13	0.57
1. Right	Ascending pharyngeal	0.01	-	5.8	0.04	0.04	0.09

artery (muscular type) the majority of the elastic fibres were arranged circularly while in the remainder of the carotid sinus they were arranged mainly longitudinally. In the lambs the elastic membranes were disposed close to each other, 2-25 μ apart. In the occipital artery (muscular type) of the ewe the elastic membranes are much farther apart than those of the lamb (May, 1965).

(iii) Tunica Intima

The tunica intima of the carotid sinus was thinner than that of the occipital artery (muscular type). It consisted of endothelium and a thin layer of subendothelial connective tissue as in the common carotid or occipital (muscular type) arteries. The subendothelial layer of the occipital artery (muscular type) is more defined in the ewe than in the lamb (May, 1965). A single internal elastic membrane usually separated the intima from the media. In the external carotid, common carotid and occipital (muscular type) arteries double internal elastic membranes usually separated the intima from the media. No nerve fibres were seen in the intima of the carotid sinus.

(b) Occipital Artery (Muscular Type)

The occipital artery beyond the level of the carotid body (when the carotid body was situated on the occipital artery) was of the muscular type. Similarly, the ascending pharyngeal artery beyond the level of the carotid body (when the carotid body was situated at the origin of this artery) was of the muscular type. Compared to the adventitia of the carotid sinus, the adventitia

of the occipital artery (muscular type) contained more elastic membranes. In the adventitia of the occipital artery (muscular type) up to 8 layers of elastic membranes were observed (Plate XV, Fig. 1). Few collagen fibres were seen among or external to these elastic membranes. May (1965) also studied the occipital artery (muscular type).

In the present study the occipital artery of one lamb, from its origin to 10 mm distant, was sectioned serially to study the extent, arrangement and disposition of the elastic tissue and collagen fibres. The tunica media, for 4 mm from the origin of the artery, was mainly of the elastic type, while the remaining 6 mm was mainly of the muscular type. In this specimen the carotid body was located at the origin of the ascending pharyngeal artery. The media exhibited 3-5 weak elastic membranes, and was clearly defined from the adventitia (Plate XV, Fig. 1). The occipital artery (muscular type) possessed double internal elastic membranes separating the media from the intima.

(c) Distribution of Nerve Fibres in the Carotid Sinus Wall

Myelinated and nonmyelinated nerve fibres were seen in the carotid sinus wall especially in the adventitia. The large nerve fibres in the superficial adventitia exhibited regular narrowings and expansions along their course and were 2.5-5 μ in diameter (Plate VII, Fig. 1; Plate XVII, Figs. 1,2). Fine nerve fibres, about 1 μ in diameter, were seen entering the deeper adventitia. Most of these nerve fibres usually branched either in the superficial adventitia or before reaching the medio-adventitial border.

(d) Morphology of the Terminal Nerve End System and its Relation to the Connective Tissue and Smooth Muscle Fibres

Terminal nerve fibres, usually about $0.5\ \mu$ in diameter, approached the medio-adventitial border and ended in relation to the smooth muscle fibres (Plate XVII, Fig. 2). In the deeper part of the adventitia, localised areas of terminal nerve fibres were also observed. Terminal nerve fibres usually ended as diffuse endings bearing no typical end formations. Occasionally terminal nerve fibres were seen in the superficial part of the media between the smooth muscle bundles. However, in the common carotid artery comparatively more fine nerve fibres were seen in the superficial media.

B. DENERVATED CAROTID SINUS (AFTER SECTIONING OF THE CAROTID SINUS NERVE)

In one lamb (N1), the control and the denervated carotid trifurcations were treated according to the modification technique of Nauta and Gyax (1951, 1954) as recommended by Hanlynn (1957) (vide denervated carotid body). In both the control and denervated carotid sinuses the nervous structures were found to be unstained, whereas the reticulin and collagen fibres in the carotid sinus wall were stained deeply (Plate XIV, Fig. 1).

In the second lamb (N2), the control and denervated carotid trifurcations were again treated according to the modification technique of Nauta and Gyax (1951, 1954) as recommended by Guillery et al. (1961) (vide denervated carotid body). In the control carotid sinus, nerve fibres were observed in the

adventitia and in the superficial tunica media (Plate XIV, Fig. 2). Also noted were the nerve fibres supplying the common carotid and external carotid arteries. However, in the denervated carotid sinus no nerve fibres were seen in the carotid sinus wall, the common carotid or external carotid arteries.

In the remaining three lambs (N3, N4 and N5) the carotid trifurcations were serially sectioned and selected sections at the level of the carotid sinus were stained for nervous structures by Romanes' (1950) silver chloride method (vide denervated carotid body). A few sections, 5-7 μ thick, were also prepared from each carotid sinus to study the structural changes.

The carotid sinus of the lambs did not show any detectable structural changes one month after denervation (Plate XVI, Figs. 1,2).

In the denervated carotid sinuses of lambs N3, N4 and N5, there were no large diameter nerve fibres (2.5-5 μ) such as were seen in the controls. A markedly degenerated carotid sinus nerve and its divisions at the carotid trifurcation was observed. However, small diameter nerve fibres about 1 μ in diameter were observed in the adventitia of the carotid sinus and the external carotid and common carotid arteries. Fine nerve fibres were also seen in the adventitia and at the medio-adventitial border of the occipital or ascending pharyngeal arteries. These fibres exhibited a delicate branching system in the deeper part of the adventitia or at the medio-adventitial border of these arteries.

C. STRUCTURE OF THE CAROTID SINUS AFTER SECTIONING OF THE EXTERNAL CAROTID NERVE OR CRANIAL CERVICAL GANGLIONECTOMY

The structure of the carotid sinus did not exhibit any detectable morphological changes after sectioning of the external carotid nerve or cranial cervical ganglionectomy (Plate XVI, Fig. 3). The small veins draining the carotid sinus adventitia were found to be distended (Plate XVI, Fig. 3; Plate XVII, Fig. 3).

The external carotid nerve and its branches to the carotid trifurcation were degenerated. The small diameter nerve fibres usually found in the wall of the normal carotid sinus were absent in the denervated specimens (Plate XVI, Fig. 3). The nerve fibres from the intact carotid sinus nerve were found in the adventitia, in the medio-adventitial border of the denervated carotid sinus (Plate XVI, Fig. 3; Plate XVII, Fig. 3), or in a very few instances in the superficial media.

DISCUSSION

The carotid sinus of sheep exhibits a swelling or dilatation which has been described in the guinea-pig (Rees, 1967b; Kondo, 1971), rabbit (Rees, 1966, 1967b; Muratori, 1967), cat (Addison, 1944; Muratori, 1967; Rees, 1966, 1967b), dog (Addison, 1939, 1944; Rees, 1966, 1967b; Muratori, 1967) and pig, calf and man (Muratori, 1967). The carotid trifurcation of sheep also displayed three classical vessel types - mixed, elastic and muscular as in most species so far studied. The "elastic segment" of Rees (1966, 1967b) could be applied to the carotid sinus of sheep; in addition it was found that the extent of the elastic tissue of the carotid sinus

could be variable according to the position of the carotid body. The transition of vascular walls from the common carotid and external carotid arteries to the occipital (elastic) artery, and from the elastic to the muscular portions of the occipital artery are also abrupt, as Rees (1966, 1967b) reported in laboratory animals and man.

The arterial supply and venous drainage of the carotid sinus, carotid body and associated nerves, the carotid sinus nerve and external carotid nerve, are readily observed in histological sections. Although the carotid body is provided with profuse blood vessels the carotid sinus receives relatively few.

The carotid sinus is not exclusively supplied by nerves from the carotid sinus and external carotid nerves; it occasionally receives nerve supply from the pharyngeal branches of the vagus, and from the hypoglossal nerve (see gross anatomy, chapter III). From the denervation experiments it is apparent that the only major source of nerve supply, as in most species, is from the carotid sinus and external carotid nerves. The fibres of the carotid sinus nerve supply the carotid body and carotid sinus and some fibres, after entering the carotid body, even proceed to supply the carotid sinus. Among these fibres are the large myelinated nerve fibres which display regular thickening and expansions. These fibres degenerate markedly one month after division of the carotid sinus nerve. Their origin, formerly proposed by Abraham (1968, 1969) to be from the glossopharyngeal nerve, is clarified by the present study.

Degenerated nerve staining techniques employed in the present study - modification techniques of Nauta and Gyax (1951, 1954) modified by Guillery et al. (1961) and that of Hamlyn (1957) - are not particularly suitable for selective staining of nerve fibres in a vascular wall with abundant connective tissue. It appeared to be that the technique of Guillery et al. differentiated nervous tissue better than that of Hamlyn. However, the former technique presented certain problems in the removal of clearing agent (cedarwood oil) from the tissue during tissue processing leading to difficulties in subsequent tissue sectioning.

The predominance of myelinated nerve fibres over the nonmyelinated fibres in the carotid sinus of the sheep described in the present study agrees with the findings of de Castro (1951) and Ezyguirre and Uchizono (1961). The majority of the fibres of the external carotid nerve are myelinated as has been described in the cat (Ezyguirre and Uchizono, 1961). Almost all of the small diameter nonmyelinated nerve fibres in the carotid sinus wall degenerate after division of the external carotid nerve or cranial cervical ganglionectomy.

In the carotid sinus wall of the sheep the nerve fibres are particularly localized in areas. These areas are probably comparable to the axonic fields of Riisager and Weddell (1962). It appeared that in the sheep there are no specific types of nerve endings comparable to those of rabbit, guinea-pig, cat, dog and man. However, Abraham (1958, 1969) stated that in the sheep there are particular end system patterns and receptor apparatus characteristic of that species.

The structure of the carotid sinus wall one month after sectioning of the carotid sinus presents no detectable morphological changes. The only structural changes observed after division of the external carotid nerve or cranial cervical ganglionectomy was the dilatation of veins in the carotid sinus adventitia. Fine nerve fibres which degenerated after sympathectomy could be traced to the deeper adventitia. The nerve fibres of the carotid sinus wall could be traced generally to the deeper adventitia. This is in accord with the reports of Rees (1966), Abraham (1967, 1969), and Aumonier (1972). Occasionally some fine nerve fibres could also be traced to the medioadventitial border or superficial media.

SUMMARY

1. The present study was conducted in the normal lambs and sheep and denervated lambs to study the location, structure and elastic tissue composition of the carotid sinus, the distribution of nerve fibres and the morphology of the nerve terminals employing various histological techniques. In the denervated animals the extent of the degenerated nerve fibres and their distribution, and the nature of persisting nerve fibres were observed using Nauta and Gyax (1951, 1954) technique modified by Hamlyn (1957) and Guillery et al. (1961), and Romanes' (1950) silver chloride method.
2. The carotid sinus is a swelling, dilatation or diverticulum at the origin of the occipital artery or the occipitoascending pharyngeal arterial trunk. The extent of the elastic tissue of the carotid sinus varies according to the position of the carotid body.

3. Three classical vessel types, musculoelastic, elastic and muscular, are present in the carotid trifurcation. The carotid sinus is predominantly of the elastic type.
4. The carotid sinus has a comparatively thinner wall and a thicker tunica media than that of the adjoining blood vessels.
5. The tunica adventitia of the carotid sinus wall is rich in myelinated and nonmyelinated fibres. These could be traced to the deeper adventitia, to the medioadventitial border or even up to the superficial media.
6. Terminal nerve fibres usually end as diffuse endings bearing no specific end formations.
7. The carotid sinus wall did not exhibit any detectable morphological changes one month after the sectioning of the carotid sinus nerve; however, a marked dilatation of the veins of the adventitia was observed after sectioning of the external carotid nerve or cranial cervical ganglionectomy.
8. The large diameter myelinated nerve fibres which degenerated after sectioning of the carotid sinus nerve are suggested to be of glossopharyngeal origin; whereas, fine nonmyelinated fibres which could be traced to the medioadventitial border or superficial media are suggested to be of sympathetic origin.

CHAPTER SIX

FLUORESCENCE MICROSCOPICAL STUDIES OF THE

CAROTID BODY AND CAROTID SINUS

INTRODUCTION

According to various biochemical, histochemical and ultrastructural studies, the carotid body of several vertebrates contains catecholamines, dopamine and 5-hydroxytryptamine in variable quantities. The species so far studied have been the bird, rat, Rana temporaria, Syrian hamster, rabbit, cat, dog, horse and man. However, no work relating to the carotid body and carotid sinus of the sheep has previously been done. In the present study, the carotid bodies and carotid sinuses from long-term, unilateral, sympathectomized lambs were investigated histochemically by using the formaldehyde-catecholamine condensation reaction, to determine the localization of catecholamines in the carotid body and carotid sinus, and in the common and external carotid arteries.

LITERATURE REVIEW

Biochemical, pharmacological, histochemical and ultrastructural studies have shown the presence of biogenic amines in the carotid body of various vertebrate species: in the bird (Kobayashi, 1969b), rat (Battaglia, 1966, 1968; Blümcke et al., 1967a, 1967b), Rana temporaria (Banister et al., 1967), Syrian hamster (Chen and Yates, 1968, 1969; Chen et al., 1967, 1968, 1969), rabbit (Lever, and Boyd, 1957; Lever et al., 1959; Fillenz and Woods, 1966; Palkama, 1965; Blümcke, et al., 1967a; Rees, 1967a; Dearnaley et al., 1968a, 1968b), cat (Ross, 1959; Lever et al., 1959; Hayashi, 1966; Chiocchio et al., 1966, 1967, 1971; Hess, 1968; Morita et al., 1969; Zapata et al., 1969a; Tramezzani et al., 1971), dog (Höglund, 1967; Kobayashi, 1968), horse (Höglund, 1967), and man (Neimi and Ojala, 1964; Hamberger et al., 1966).

Electron microscopical studies revealed the presence of osmiophilic granules or electron-dense cored vesicles in all the species so far studied (see the review of ultrastructural studies of the carotid body). These electron-dense cored vesicles are considered by many observers to contain catecholamines (Lever et al., 1959; Ross, 1959; Neimi and Ojala, 1964; Palkama, 1965; Hamberger et al., 1966; Hayashi, 1966, 1968; Battaglia, 1966, 1968; Banister et al., 1968; Chen et al., 1967; Blümcke et al., 1967a, b; Rees, 1967a; Hess, 1968; Chen and Yates, 1969; Kobayashi, 1969b; Morita et al., 1969; Zapata et al., 1969a; Chiocchio et al., 1966, 1971). Some observers (Blümcke et al., 1967a, b) were even tempted to call them "catecholamine bodies". The carotid body tissue of several species exhibits fluorescence which indicates the presence of one or more catecholamines.

According to Blümcke et al. (1967a, b) the catecholamine bodies in rats and rabbits depleted after hypoxia and disintegrated after an increase in CO₂ in the respiratory air. Chen and Yates (1968) and Chen et al. (1969) found that, in Syrian hamsters, reserpine administration depleted catecholamines without disappearance of granules (electron-dense cored vesicles) and hypoxia did not affect ~~catecholamine~~ content, which is contrary to the findings of Blümcke et al. (1967b). Lever et al. (1959) stated that reserpine administration in the rabbit resulted in a general depletion of these granules throughout the glomus, which is again contrary to the finding of Chen and Yates (1968).

The granules (electron-dense cored vesicles) according to many reports contain varying amounts of adrenaline and noradrenaline and the adrenaline and noradrenaline content of the carotid body has been the subject of contradictory reports by different observers. The

major component of the stored catecholamine is noradrenaline in the dog (Kobayashi, 1968), rabbit (Palkama, 1965), and cat (Chiocchio et al., 1971; Hayashi, 1966); whereas in Rana temporaria it is adrenaline (Banister et al., 1967). According to many reports the carotid body cells also contain indolamines, dopamine and 5-hydroxytryptamine.

A. Indolamines, Dopamine and 5-hydroxytryptamine

Lever et al. (1959) stated that the phenolic amines present in the glomus cells of the cat and rabbit, identified by various histochemical methods, appeared to be adrenaline or noradrenaline rather than 5-hydroxytryptamine. However, several later reports stated that carotid body cells also contained indolamines (Chen and Yates, 1969; Chen et al., 1967), dopamines (Fillenz and Woods, 1966; Banister et al., 1967; Dearnaley et al., 1968a, 1968b; Knoche et al., 1969; Morita et al., 1969; Chiocchio et al., 1966, 1967, 1971), and 5-hydroxytryptamine (Hamberger et al., 1966; Morita et al., 1969; Chiocchio et al., 1971).

It appears that the relative amounts of catecholamines, indolamines, dopamines and 5-hydroxytryptamine present in the glomus cells vary in different species. In the Syrian hamster, Chen and Yates (1969) found that the granules contained predominantly catecholamines with relatively small amounts of indolamines and serotonin. However, in the cat, the majority of cells contained dopamine (Chiocchio et al., 1966; Morita et al., 1969). According to Chiocchio et al. (1966) dopamine constituted more than half of the total catecholamine content of the carotid body, while noradrenaline represented 35% and adrenaline 8%. Chiocchio et al. (1967) differentiated three cell types in the carotid body of the cat

according to their distribution, the size of their granules and the nature of their staining reaction with silver nitrate. One type, having large polymorphic granules, was distributed irregularly in the carotid body. It gave a positive reaction with 1-2 min treatment with silver nitrate. The second type, having smaller granules, exhibited no silver nitrate reaction up to 2 min treatment, but gave a positive reaction after treatment for 15 min or more. The third type, which was scarce, contained small round granules and showed a negative reaction even when treated for 30 min or more. They suggested that the first type, which was the most prevalent cell type, contained noradrenaline, the second cell type adrenaline, and the third cell type, which was scarce, 5-hydroxytryptamine. Morita et al. (1969) found that the majority of cells ('dark cell type II') contained dopamine, and the remainder of the glomus cells contained either noradrenaline ('dark cell type I') or adrenaline ('light cell type IV'). This was confirmed in a more recent report by Chiocchio et al. (1971) who described the carotid body cells of the cat as exhibiting an intense fluorescence after formaldehyde treatment, but not all of these cells gave a fluorescence reaction with the trihydroxyindole histochemical method. They concluded "that most of the glomus cells contain norepinephrine or DOPA or a combination of these two compounds while some cells contain only dopamine. A few yellow fluorescence cells were also found after formaldehyde treatment which probably contain 5-hydroxytryptamine".

B. Fluorescence Microscopical Studies

Fluorescence microscopical studies have been done on the carotid body of the white rat (Blümcke et al., 1967b), rat (Battaglia, 1968), rabbit (Fillenz and Woods, 1966; Rees, 1967a), cat (Chiocchio et al., 1971), man (Neimi and Ojala, 1964) and the carotid labyrinth of

Rana temporaria (Banister, 1968). Fluorescence microscopical studies on the carotid sinus have been made in the rabbit (Rees, 1966, 1967a; Reis and Fuxe, 1968), the rat and cat (Reis and Fuxe, 1968).

Blü̈mcke et al. (1967b), using fluorescence microscopy, found that the catecholamines vanished almost completely from the receptor cells after the rats were subjected to 20 min of hypoxia. According to Neimi and Ojala (1964) the green fluorescence cells in man were relatively few in number but were evenly distributed among the alveoli of the lobules and did not show any clear relationship to the capillary spaces of the carotid bodies. They also stated that no fluorescence was seen in the nerve fibres and suggested that the carotid body probably lacked adrenergic parenchymatous innervation. Fillenz and Woods (1966) found that yellow green fluorescence was intense in the cytoplasm of type I cells of the carotid body of the rabbit, while similar but much weaker fluorescence was seen in the nerves. They suggested that amines present in the carotid body cells might be dopamine.

Rees (1966, 1967a) studied the distribution of biogenic amines in the carotid bifurcation region of the rabbit. He stated that glomus cells contained phenolic amines which persisted even up to 21 days after sympathectomy. According to him, the carotid sinus of the rabbit contained adrenergic fibres derived from the superior cervical ganglion.

There has been a controversy for many years on the nature of a possible chemical transmitter substance in the carotid body cells. It has been the subject of various reviews and experiments (Liljestrand, 1954; Liljestrand and Zotterman, 1954; Daly, 1954; Heymans, 1955; Heymans and Neil, 1958; Anichkov and Belen'kii, 1962;

Eyzaguirre et al., 1965; Heymans et al., 1968; Eyzaguirre and Zapata, 1968; Torrance, 1968; Paintal, 1969; Biscoe, 1971; Ballard and Jones, 1972). Various substances which have been proposed as candidates for a chemical mediator are acids (lactic acid, etc.), amino acids (glutamic acid and glutamic dehydrogenase, etc.), ATP and AMP, acetylcholine and catecholamines (Torrance, 1968; Eyzaguirre and Zapata, 1968). Of the theories on chemical mediation, the cholinergic hypothesis (acetylcholine) and the adrenergic hypothesis (catecholamines) seem the most plausible and yet still await confirmation.

RESULTS

Normal Carotid Body

In the lamb, the carotid body lobules were 0.05-0.20 mm in diameter (see histology of the carotid body). Each lobule was observed as a very distinctly outlined area of intense fluorescence (Plate XVIII, Figs. 1,2). The cytoplasm of almost all of the glomus cells exhibited an intense green to yellow-green fluorescence after treatment for one hour with formaldehyde gas. Each glomus cell appeared as a discrete fluorescent unit having a diameter of 6-9 μ . Sometimes discrete masses of individually fluorescing cells were found to be distributed evenly in the sections cut at the periphery of the organ.

The catecholamines were found to be very liable to diffuse out of the cytoplasm of the glomus cells and, when this occurred, (Plate XX, Fig. 2), the fluorescent units coalesced and appeared as diffuse fluorescent masses. However, optimal fluorescence was attained in most of the sections gassed with formaldehyde (paraformal-

dehyde powder subjected to humidity 70%, 80%, 85% and 89% by storing over 34%, 28%, 25% and 21% sulphuric acid respectively) at 80°C for one hour. The diffusion of biogenic amines usually occurred during thawing of the frozen tissue sections on the fluorescence free glass microscope slides and during drying in the desiccator containing phosphorous pentoxide. The intensity of the fluorescence faded gradually and was appreciably lost after 24 hr, while the elastic fibres retained their autofluorescence.

There were no significant fluorescent products in the interlobular spaces or in the capsule of the carotid body. Even the largest nerve fibres (the glossopharyngeal fibres) produced very faint fluorescence or none at all. However, a diffuse fluorescent network was seen along the artery of the carotid body in thinner frozen tissue sections.

(a) Normal Common Carotid and External Carotid Arteries and Carotid Sinus

In the common carotid and external carotid arteries beaded fluorescent fibres, presumed to be sympathetic nerve fibres, were seen in the adventitia and also at the medio-adventitial border (Plate XXI, Figs. 1,3). Especially at the medio-adventitial border, there were non-specific fluorescent elastic fibres, but these autofluorescent elastic fibres could be easily distinguished by the nature of their fluorescence (Plate XXI, Fig. 3). If diffusion of biogenic amines had occurred, it was not possible to distinguish the strands of connective tissue fibres from the sympathetic nerve fibres.

From the present study of frozen serial sections of the carotid sinus, it was found that the carotid sinus of the lamb contained a few beaded fluorescent fibres in the outermost layer of the adventitia (Plate XXI, Fig. 1). It was not possible to demonstrate the presence of fluorescent nerve fibres in the media of the carotid sinus itself.

(b) Denervated Carotid Body and Carotid Sinus

The carotid body cells from animals one month and 6 weeks after cranial cervical ganglionectomy, and 8 weeks after sectioning of the external carotid nerve, were still found to be as fluorescent as the contralateral normal carotid body cells of the same individuals (Plate XIX, Figs. 1,2,3; Plate XX, Fig. 1). The intensities of the discrete fluorescent cell units in the normal and the denervated carotid bodies were found to be the same. However, the fluorescent plexus usually seen along the carotid body artery in the normal carotid bodies, was absent in all the denervated carotid bodies. Moreover, the beaded fluorescent fibres usually seen in the adventitia and at the medio-adventitial border of the common and external carotid arteries were virtually absent in the denervated arteries of the same individuals. Furthermore, the beaded fluorescent strands usually found in the outermost layer of the adventitia of the normal carotid sinus, were invariably absent in the denervated carotid sinuses of all the experimental animals (Plate XXI, Fig. 2).

(c) Ungassed Control Sections of Normal Carotid Body, Carotid Sinus, and Common and External Carotid Arteries

In the ungassed control sections of normal carotid bodies, fluorescent glomus cell units were absent (Plate XX, Fig. 3) and

no fluorescent plexus was seen along the carotid body artery near its point of entry. The beaded fluorescent fibres seen in the formaldehyde gassed sections in the outermost layer of the adventitia of the carotid sinus, and those in the adventitia and at the medio-adventitial border of the common carotid and external carotid arteries, were lacking in the ungassed normal control sections. These results confirmed that true fluorescence was obtained from the formaldehyde condensation products.

DISCUSSION

The histochemical reaction involved in the present study is a condensation of catecholamines with formaldehyde gas to form a 3,4-dihydroisoquinoline and 2,4-dihydro-norharmans which, when excited with ultraviolet light, fluoresce strongly at a wavelength of 480 nm (Corrodi and Hillarp, 1963, 1964), or 390 nm (Falck, 1962; Falck et al., 1962; Corrodi et al., 1962). Only primary catecholamines such as noradrenaline, dopamine and 5-hydroxytryptamine are converted into a fluorescing product after treatment for one hour with formaldehyde, whereas secondary catecholamines, such as adrenaline, are not (Carlsson et al., 1964). Noradrenaline and dopamine give green or yellow-green fluorescence (Spriggs et al., 1966) but, having identical activation and emission spectra (Corrodi and Jonsson, 1965), can not be separately distinguished under the fluorescence microscope. The fluorescence of 5-hydroxytryptamine (serotonin) is yellow. The secondary catecholamines such as adrenaline also give fluorescence products, but only after 3 or more hours treatment with formaldehyde gas. Angelakos and King (1967) and Chiochio et al. (1971) used trihydroxyindole fluorescence products (blue to blue-green fluorescence, 500-520 nm) to differentiate adrenaline from other

catecholamines in the nerve endings.

In the present study it was not possible to make a quantitative estimation of the different biogenic amines present in the carotid body of the lamb. However, from the intense green to yellow-green fluorescence obtained with the formaldehyde gas condensation reaction, it is suggested that the carotid body cells of the lamb are rich in catecholamines. As 5-hydroxytryptamine gives a yellow fluorescence, and secondary amines such as adrenaline give fluorescent products only after 3 or more hours treatment with formaldehyde gas (Carlsson et al., 1964), the intense fluorescence exhibited by the glomus cells in this study is likely to have been produced mainly by noradrenaline and dopamine. It was not possible to differentiate these two amines because of their identical activation and emission spectra, nor was it possible to determine that the carotid body cells contained exclusively noradrenaline or dopamine. The persistence of intense fluorescent carotid body cells even up to 8 weeks after denervation suggested that sympathetic denervation did not affect the catecholamines detectable by the formaldehyde condensation reaction and that the noradrenaline and dopamine content remained the same after long-term sympathetic denervation.

Fluorescence other than that produced by catecholamines may result from formaldehyde gas reaction with other proteins and auto-fluorescence of nerve itself. Also, some tissues may not be influenced by formaldehyde (Norberg and Hamberger, 1964). In the lambs, the non-specific fluorescence was very intense in the internal elastic membrane and the elastic fibres of the common and external carotid arteries, whereas in the collagen fibres in the adventitia of these arteries the fluorescence was weak. Similar auto-

fluorescence was seen near the intimal surface of the gingival artery from a seven-week-old infant, "non-specific intimal fluorescence or inner ring", by Frewin et al. (1971), and in the cerebral artery of the rat (Iwayama et al., 1970). Neimi and Ojala (1964) reported the non-specific fluorescence of connective tissue fibres in the human carotid body. They also reported that no fluorescence was seen in the nerve fibres. Rees (1967a), likewise, found auto-fluorescent elastic fibres in the common and external carotid arteries of the rabbit.

The present findings on the carotid body in the lambs agree with those of Fillenz and Woods (1966), and Rees (1967a) in the rabbit, and Chiocchio et al. (1971) in the cat. They also agree with the finding by Neimi and Ojala (1964) in man, that the nerve fibres (possibly glossopharyngeal fibres) exhibit no fluorescence. However, Neimi and Ojala made no mention of beaded fluorescent fibres such as have been found along the carotid body artery in the lamb. The present findings also support the fact that the carotid body cells contain catecholamines, especially noradrenaline or dopamine or both (Battaglia, 1968; Chen and Yates, 1969; Chen et al., 1967; Chiocchio et al., 1966, 1971; Dearnaley et al., 1968a, 1968b; Fillenz and Woods, 1966; Hamberger et al., 1966; Hayashi, 1966; Hoglund, 1967; Kobayashi, 1968, 1969; Lever and Boyd, 1957; Lever et al., 1959; Morita et al., 1969; Palkama, 1965 and Zapata et al., 1969a). They also agree with those of Rees (1966, 1967a) and Reis and Fuxe (1968) on the carotid sinus, and the common and external carotid arteries (Rees, 1967a). The nature of the fluorescence observed by Rees (1966, 1967a) and Reis and Fuxe (1968) in the rabbit and cat was comparable to that of the lambs used in the present study.

SUMMARY

1. The distribution of catecholamines in the carotid body and carotid sinus was studied histochemically by using a formaldehyde-catecholamine condensation reaction. Studies were made after cranial cervical ganglionectomy or after sectioning the external carotid nerve.
2. Both the normal and sympathetically denervated carotid body cells exhibit intense fluorescence, and the intensity of the fluorescence remains the same up to 8 weeks after sympathectomy.
3. It is suggested that the normal carotid body cells contain catecholamines consisting mainly of noradrenaline and dopamine, which are not affected by chronic sympathetic denervation.
4. Fluorescent nerve fibres were seen on the outermost layer of the adventitia of the normal carotid sinus, along the carotid body artery, and in the adventitia and the medio-adventitial border of the common carotid and external carotid arteries. They were not present in the denervated specimens.
5. It is concluded that the carotid sinus, carotid body artery and the common carotid and external carotid arteries of the lamb receive sympathetic adrenergic innervation.

CHAPTER SEVEN

ULTRASTRUCTURE OF THE CAROTID BODY AND CAROTID SINUS

INTRODUCTION

The ultrastructure of the carotid body and carotid sinus of various vertebrates including man has been studied extensively, the most commonly used laboratory animals for electron microscopical studies being the cat and rabbit. However, there is no reference in the literature to the ultrastructure of either the carotid body or carotid sinus of the sheep, one of the commonly used experimental animals. The following experiments were carried out to study the ultrastructure of the normal and long-term denervated carotid body and carotid sinus in lambs.

In the normal carotid bodies, studies were made for:

- (i) the types of carotid body cells,
- (ii) the blood vessels and their relation to the glomic cells, and
- (iii) the terminal axons, nerve endings and their relationships to the glomic cells and the blood vessels.

In the denervated carotid bodies (after sectioning of the carotid sinus nerve, cranial cervical ganglionectomy or sectioning of the external carotid nerve) the following studies were conducted:

- (i) the nature of morphological changes in the glomic cells, and
- (ii) the changes in the terminal axons and the nerve endings.

Studies were also made:

- (i) in the normal carotid sinus for the structure and composition of the vascular wall, and
- (ii) in the denervated carotid sinus for structural changes especially in the terminal nerve fibres and nerve endings.

LITERATURE REVIEW

The carotid body of a variety of vertebrates has been studied extensively by electron microscopy, including the "amphibian" (Ishii and Oosaki, 1969), toad (Ishii and Oosaki, 1966), bird (Kobayashi, 1969a), guinea-pig (Engstrom et al., 1957; Kondo, 1971), rat (Hoffman and Birrell, 1958; Battaglia, 1966, 1968; Blumcke et al., 1967a,b), mouse (Duncan and Garner, 1957; Garner and Duncan, 1958; Kobayashi and Uehara, 1970), rabbit (Lever and Boyd, 1957; Lever et al., 1959; Palkama, 1965; Palkama and Hopsu, 1965; Biscoe and Stehbens, 1966; Blumcke et al., 1967a; Dearnaley et al., 1968), Syrian hamsters (Chen and Yates, 1968, 1969; Chen et al., 1969), cat (Ross, 1957a, 1959; Duncan and Garner, 1957; Garner and Duncan, 1958; Lever et al., 1959; Eyzaguirre and Uchizono, 1961; de Kock and Dunn, 1964, 1966, 1968; Biscoe and Stehbens, 1965, 1966, 1967; Biscoe et al., 1969, 1970; Molyneux and Scott, 1966; Hayashi, 1966; Duncan and Yates, 1967; Hess, 1968; de Castro and Rubio, 1968; Al-Lami and Murray, 1967, 1968a; Lall, 1969; Morita et al., 1969; Zapata et al., 1969a,b; Abbott et al., 1972; Ballard and Jones, 1972), dog (Hoglund, 1967; Kobayashi, 1968), horse

(Hoglund, 1967), Weddell seal (Morita et al., 1970), man (Feria-Velasco and Zavala, 1967; Kraus and Martinek, 1967, 1968; Grimley and Glenner, 1966a,b, 1967, 1968; Abraham, 1968b) and monkey (Kraus and Martinek, 1967, 1968; Al-Lami and Murray, 1968b).

CELL TYPES

The type I and type II cells of the carotid body as seen under light microscopy in various animals have been confirmed by electron microscopical studies in the mouse (Garner and Duncan, 1958), guinea-pig (Kondo, 1971), Syrian hamster (Chen and Yates, 1969), rabbit (Lever et al., 1968), cat (Garner and Duncan, 1958; Ross, 1959; Lever et al., 1959; Eyzaguirre and Uchizono, 1961; Biscoe and Stehbens, 1965, 1966, 1967; de Kock and Dunn, 1964, 1968; Duncan and Yates, 1967; Al-Lami and Murray, 1968a,b; Hess, 1968; de Castro and Rubio, 1968; Morita et al., 1969; Abbott et al., 1972), horse and dog (Hoglund, 1967) and Weddell seal (Morita et al., 1970). Abbott and Howe (1972) also found two types of cells, type I and type II, in the aortic body tissue of the cat. Sometimes the cell types are not mentioned, as in the guinea-pig (Engstrom et al., 1957), mouse and cat (Duncan and Garner, 1957). Studies have also revealed the presence of ganglion cells in the rat (Hoffman and Birrell, 1958), cat (Ross, 1959; Biscoe and Stehbens, 1966; Al-Lami and Murray, 1968a; Hess, 1968), dog (Kobayashi, 1968), rabbit (Biscoe and Stehbens, 1966) and Weddell seal (Morita et al., 1970), mast cells in the cat and rabbit (Lever et al., 1959), fibroblasts in the cat (Hess, 1968) and histiocytes in the cat (de Castro and Rubio, 1968). Unidentified cells have been reported to be associated with clumps of type I and type II cells in the cat and rabbit (Biscoe and Stehbens,

1966), and one particular type of cell which is quite distinct from the type I and type II cells, in the cat (de Castro and Rubio, 1968).

A. CHIEF OR TYPE I CELLS

The chief (type I) cells have been described in detail by many observers (Garner and Duncan, 1958; Ross, 1959; Lever et al., 1959; Biscoe and Stehbens, 1966; de Castro and Rubio, 1968; Hess, 1968; Al-Lami and Murray, 1968a,b; Morita et al., 1969, 1970; Kondo, 1971). The majority of cells in the carotid body in various species are the chief cells. According to Al-Lami and Murray (1968a) the type I and type II cell ratio is ten to one. All authors agree that most of the chief cells occur in groups invested by type II cells. According to de Castro and Rubio (1968) the minimum distance which separates the chief cell from the blood varies between 1 and 3 μ , even though it is ensheathed by the sustentacular cell processes, and the greatest distance between the blood and a chief cell can be as much as 15-20 μ . Kondo (1971) reported that mitotic chief cells are rarely found, and that they are considerably enlarged and rounded and contain numerous dense granular vesicles throughout the cytoplasm.

Types of Chief Cells

The light and dark cells as seen under the light microscope have been confirmed by ultrastructural studies in the rabbit (Lever and Boyd, 1957; Lever et al., 1959; Palkama and Hopsu, 1965), cat (Hayashi, 1966; de Castro and Rubio, 1968; Morita

et al., 1969; Abbott et al., 1972), dog and horse (Hoglund, 1967), Weddell seal (Morita et al., 1970), monkey (Kraus and Martinek, 1967) and man (Feria-Velasco et al., 1966; Grimley and Glenner, 1966b, 1967; Kraus and Martinek, 1967). However, a number of observers did not categorize the type I cells into light or dark cells (Duncan and Garner, 1957; Garner and Duncan, 1958; Engstrom et al., 1957; Hoffman and Birrell, 1958; Ross, 1959; de Kock and Dunn, 1964, 1968; Biscoe and Stehbens, 1966; Duncan and Yates, 1967; Hess, 1968; Al-Lami and Murray, 1968a; Dearnaley et al., 1968; Kondo, 1971), but some of them indicated that there is a wide range of appearance of the normal glomus cell (Lever and Boyd, 1957; Lever et al., 1959; Duncan and Garner, 1957; Garner and Duncan, 1958; Ross, 1959). Morita et al. (1969) even distinguished four types of chief cell, "Type I", "Type II", "Type III", and "Type IV or light cell", on the basis of the electron density of their cytoplasm as well as on the morphological features of the osmiophilic granules they contained. Kraus and Martinek (1967) stated that the light and dark cells were morphologically different functional stages of the chemoreceptor cells. Kobayashi (1968) classified the glomus cells into chromaffin and nonchromaffin cells on the basis of their reaction to potassium dichromate. He stated that chromaffin cells were less frequent and contained dense osmiophilic granules. However, Biscoe (1971) stated that there was no entirely convincing morphological evidence to support the claim that there are two varieties of type I cell, light and dark, one with many vesicles and the other with few or no electron-dense vesicles.

Light Cells

The cytoplasm of the light or clear cell, according to Lever and Boyd (1957), Lever et al. (1959), de Castro (1968), and Abbott et al. (1972), is less dense or clearer than that of the dark cell. It has been reported that light cells contain grossly vacuolated and distended mitochondria (Lever and Boyd, 1957; Lever et al., 1959), or they contain many vesicles or vacuoles and fewer mitochondria (or none at all) than the dark cells (de Castro and Rubio, 1968). They have been described as having fewer osmiophilic granules in the cytoplasm (Lever and Boyd, 1957; Lever et al., 1959). According to Morita et al. (1969) these cells, their "Type IV", are difficult to find in the cat, and in their cytoplasm a small number of granules, $120 \text{ nm} \pm 3$ in diameter, are uniformly distributed. They suggested that these cells might be adrenaline-containing cells or might be a functional state of their "Type II" cell. However, according to Abbott et al. (1972) "clear Type I cells" are more common than the "dense Type I cells". According to Hayashi (1966), more mitochondria were found in the "pale" cells than in the "dark" cells.

Dark Cells

The "dark" cell contains a background cytoplasm of noticeable electron density (Lever and Boyd, 1957; Lever et al., 1959; Grimley and Glennær, 1966b; Morita et al., 1969) in which lie compact mitochondria with a content of internal cristae, filaments and numerous osmiophilic granules $0.05\text{-}0.15 \mu$ in diameter (Lever and Boyd, 1957; Lever et al., 1959). Morita

et al. (1969) classified the dark cells into three types: "Type I", "Type II", and "Type III". "Type I" cells did not appear very often, "Type II" cells were most frequent, and "Type III" cells were occasionally seen, and they had cytoplasmic granules with diameters of 170-400nm, $130.1 \text{ nm} \pm 3.5$ and $93 \text{ nm} \pm 2.4$ respectively. Moreover they considered that "Type I", "Type II" and "Type III" cells contain noradrenaline, dopamine and "specific amines" respectively. Abbott et al. (1972) stated "that some of these cells (dense Type I cells) have very few granules and in some respects are similar in appearance to the Type II cells, but may be distinguished from the latter by their topography and a different arrangement of the endoplasmic reticulum".

The chief cell cytoplasm in most of the animals studied exhibits a finely granular cytoplasm with a rounded and centrally placed nucleus. The cytoplasm has been reported to be rich in organelles and inclusions: mitochondria (Ross, 1957, 1959; Hoffman and Birrell, 1958; Hess, 1968; Eyzaguirre and Uchizono, 1961; Biscoe and Stehbens, 1966; Battaglia, 1968; Al-Lami and Murray, 1968a,b; Zapata et al., 1969b; Kondo, 1971), endoplasmic reticulum (Ross, 1957a, 1959; Garner and Duncan, 1958; Hoffman and Birrell, 1958; Lever et al., 1959; Biscoe and Stehbens, 1966; Grimley and Glenner, 1966b; Kraus and Martinek, 1967, 1968; Battaglia, 1968; Kondo, 1971), Golgi complex (Ross, 1969; Garner and Duncan, 1958; Lever et al., 1959; Biscoe and Stehbens, 1966; Battaglia, 1968; Kraus and Martinek, 1968; Hess, 1968; Grimley and Glenner, 1966b; Zapata et al., 1969b; Kondo, 1971), centriole or centrioles (Hess, 1968; Biscoe and Stehbens, 1966; Kondo, 1971), cilium

or cilia (Biscoe and Stehbens, 1966; Kraus and Martinek, 1967; Hess, 1968; Battaglia, 1968; Kondo, 1971), Nissl body (Grinley and Glenner, 1966b; Hess, 1968; Zapata et al., 1969b), ribosomes (Battaglia, 1968; Kondo, 1971), microtubules (Hess, 1968; Biscoe and Stehbens, 1966), filaments (Kondo, 1971), lysosomes (Biscoe and Stehbens, 1966; Al-Lami and Murray, 1968a,b; Kondo, 1971), vacuoles (Hess, 1968), clear corpuscles (de Castro and Rubio, 1968), lipid body (Ross, 1959; Lever et al., 1959; Al-Lami and Murray, 1968a; Hess, 1968), multivesicular bodies (Kondo, 1971), unspecified intracellular inclusion bodies (Ross, 1959; de Kock and Dunn, 1964; Kondo, 1971) and cytoplasmic vesicles (Ross, 1957).

The glomus cells have been claimed to have complex cytoplasmic processes (Garner and Duncan, 1958; Lever et al., 1959; de Kock and Dunn, 1964, 1968; Biscoe and Stehbens, 1966; Molyneux and Scott, 1966; Grinley and Glenner, 1966b; Duncan and Yates, 1967; de Castro and Rubio, 1968; Hess, 1968; Al-Lami and Murray, 1968a; Zapata et al., 1969b; Morita et al., 1970; Kondo, 1971). Up to five cytoplasmic processes have been reported by de Kock and Dunn (1964). The nature of the cytoplasmic processes has been variously described as interlocking (Garner and Duncan, 1958; Grinley and Glenner, 1966b), dendritic (Hoffman and Birrell, 1958), dovetailing or interdigitated (Duncan and Garner, 1957; Lever et al., 1959), and finger-like (de Kock and Dunn, 1964; Biscoe and Stehbens, 1966). These cytoplasmic processes are said to be directed toward the cell bodies and extensions of other neighbouring chief cells (Lever et al., 1959), and they are not oriented toward the

blood vessels or nerve fibres (de Kock and Dunn, 1964) but may extend for a long distance around the blood sinusoids (Hess, 1968). Therefore each cell-group or cell-nest is separated from the adjoining one by connective tissue and the type II cell cytoplasmic process or processes (Hess, 1968), and from the blood sinusoids by the type II cell cytoplasmic process, interstitial space, basement membrane and the endothelial cells (de Kock and Dunn, 1964). Non-myelinated axons ensheathed by Schwann cells (Ross, 1959) and myelinated fibres (Lever et al., 1959) may occupy these interstitial spaces. According to de Kock and Dunn (1964) up to six layers of collagenous bundles can be found around the cell-groups. The cytoplasmic membrane of the chief cells is completely enveloped by the type II cell sheaths (de Kock and Dunn, 1964, 1968; Biscoe and Stehbens, 1966), or less completely enveloped (Duncan and Yates, 1967; Al-Lami and Murray, 1968a; Kondo, 1971). The unenveloped portion of the cytoplasmic membrane of the chief cell is in direct contact with the basement membrane or perisinusoidal space surrounding each glomus cluster (Ross, 1959; Duncan and Yates, 1967; Al-Lami and Murray, 1968a; Kondo, 1971), or in contact with the plasma membranes of terminal axons or of the nerve endings (Biscoe and Stehbens, 1966; Al-Lami and Murray, 1968a; Kondo, 1971).

Mitochondria

The mitochondria, according to Ross (1959), Battaglia (1968), and Kondo (1971) are small, numerous, and round to oval or elongated in shape. They are stated by Ross (1959) to be uniformly distributed in the cytoplasm, and small (200-400 nm), and by Biscoe and Stehbens (1966) to be 1.3μ long and $0.2-0.35 \mu$ wide. Kondo (1971) reported

that the chief cell cytoplasmic processes were elongated in shape, and were oriented parallel to the long axis of the processes. According to Al-Lami and Murray (1968a) they were exceptionally dense after single fixation with glutaraldehyde and osmic acid. It has been stated that cristae were closely packed (Ross, 1959), uniform and parallel to each other and embedded in the dense matrix (Battaglia, 1966, 1968). A few branching forms have been reported by Ross (1959) and Biscoe and Stehbens (1966).

Endoplasmic Reticulum

The endoplasmic reticulum of the chief cells has been described as tubular (Garner and Duncan, 1958), simple in form (Lever et al., 1959) consisting of small rough-walled sacs and tubules (Lever et al., 1959) or flattened elongated sacs (Biscoe and Stehbens, 1966). According to Ross (1959) they are usually located at the opposite pole of the nucleus and the width of their profiles varies from 20-40 nm. It has been reported that they are in parallel arrangements (Ross, 1959; Biscoe and Stehbens, 1966; Chen and Yates, 1969) except "in the cells containing compact mitochondria and few or no osmiophile granules some of the endoplasmic reticulum is arranged in bilaminar sheets" (Lever et al., 1959). The size of the dense granules associated with the membranes of the endoplasmic reticulum was measured as 10-15 nm by Ross (1959) and 16-19 nm by Biscoe and Stehbens (1966). According to Garner and Duncan (1958) they are usually sensitive to fixation and produce granules of high electron density in poorly fixed tissues.

Golgi Complex

The Golgi complex has been reported to be occasionally observed in the juxtannuclear or perinuclear region (Ross, 1959; Chen and Yates, 1969; Kondo, 1971) or to be poorly developed (Hayashi, 1966; Kondo, 1971). Abbott et al. (1972) stated that the Golgi complex and endoplasmic reticulum are a common feature of type I cells. It has been described as consisting of a compact collection of Golgi membranes (Lever et al., 1959) or as systems of narrow, flattened tubules and small (20-40 nm) vesicles in close association (Ross, 1959). Electron-opaque cored vesicles have been found to be fused with or budded from sacs of the Golgi apparatus (Biscoe and Stehbens, 1966). Kraus and Martinek (1968) stated that the typical primary granules arising from the vesicles of the Golgi complex are in direct connection with the ergastoplasmic tubules.

Centrioles, Cilia and Nissl Body

Kondo (1971) stated that centrioles are located near the nucleus and are gathered in a cytocentrum, and Biscoe and Stehbens (1966) found them to be continuous with a cilium. According to Hess (1968) each glomus cell has a single cilium extending from its interior in relation to a single centriole, but Biscoe and Stehbens (1966) found several cilia extending beyond the "normal cell margin" and lying parallel to the surface of the chief cell where they were covered by type II cells. Cilia have been reported as short (Kondo, 1971), and having an overall diameter of 220 nm and containing circumferentially arranged fibrils each 250 nm wide (Biscoe and Stehbens, 1966). Hess (1968) stated that a Nissl body consisting of double membranes was located near the periphery of each glomus cell.

Free Ribosomes, Microtubules, Filaments, Lysosomes and Lipids

Kondo (1971) reported that the chief cell cytoplasm contains free ribosomes, and that filaments and microtubules are oriented parallel to the long axis of the chief cell cytoplasmic processes. Microtubules have also been reported to be present (Hess, 1968), and located particularly in the centrosomal regions with a diameter of 17-25 nm (Biscoe and Stehbens, 1966). Lysosomes have been reported in the glomus cell (Biscoe and Stehbens, 1966; Al-Lami and Murray, 1968a; Kondo, 1971). They have been described as membrane bound bodies having a diameter of 0.3-0.7 μ (Biscoe and Stehbens, 1966) or 0.8-1.5 μ (Al-Lami and Murray, 1968a). Lipid bodies have been reported to be occasionally found (Ross, 1959; Lever et al., 1959; Al-Lami and Murray, 1968a; Hess, 1968). It has been stated that they are about the same size as lysosomes (Al-Lami and Murray, 1968a) and that they are found more in the sustentacular cells than in the chief cells (Ross, 1959).

Cytoplasmic Vesicles

Cytoplasmic vesicles of various dimensions have been reported in the chief cells by many observers (Ross, 1957, 1959; Engström et al., 1957; Duncan and Garner, 1957; Garner and Duncan, 1958; Lever and Boyd, 1957; Lever et al., 1959; Eyzaguirre and Uchizono, 1961; Biscoe and Stehbens, 1966; Molyneux and Scott, 1966; Blümcke et al., 1967a,b; Kraus and Martinek, 1967, 1968; Duncan and Yates, 1967; Höglund, 1967; Al-Lami and Murray, 1968a,b; Dearnaley et al., 1968; Kobayashi, 1968; Zapata et al., 1969b; Chen and Yates, 1969; Morita et al., 1969, 1970; Kobayashi and Uehara, 1970; Kondo, 1971). Many observers have been tempted to

group them according to their sizes and staining reactions. Morita et al. (1969) even classified the chief cells into four types on the basis of their cytoplasmic density as well as on the morphological features of their osmiophilic granules. Feria-Velasco and Zavala (1967) described two types of granular cells, differing only in sizes of their granules, surrounding type I cells. The most characteristic feature of the chief cell, according to many observers, is the presence of membrane-bound granules (cored vesicles) or osmiophilic granules in the species so far studied: rat, rabbit guinea-pig, Syrian hamsters, cat, dog, horse, Weddell seal, monkey and man.

The sizes of the small and large vesicles, dense granules, and osmiophilic granules or high electron density dark-cored vesicles in various animals have been reported as follows:

Small vesicles

mouse	30-40 nm	(Kobayashi and Uehara, 1970)
rat	20-50 nm	(Hoffman and Birrell, 1958)
cat	20-40 nm	(Ross, 1959)
cat	93 ± 2.4 nm	(Morita <u>et al.</u> , 1969)

Large vesicles

cat	60-120 nm	(Ross, 1959)
cat, rabbit	40-120 nm	(Biscoe and Stehbens, 1966)
cat	170-400 nm	(Morita <u>et al.</u> , 1969)

Dense granules

guinea-pig	4-5 nm	(Engström <u>et al.</u> , 1957)
cat, rabbit	16-19 nm	(Biscoe and Stehbens, 1966)

Osmiophilic granules (dark-cored vesicles)

Syrian hamster	50-200 nm	(Chen and Yates, 1969)
guinea-pig	70-200 nm	(Kondo, 1971)
	av. 100 nm	
mouse	80-90 nm	(Kobayashi and Uehara, 1970)
rabbit	60-200 nm	(Dearnaley <u>et al.</u> , 1968)
cat,	50-100 nm	(Lever and Boyd, 1957;
rabbit		Lever <u>et al.</u> , 1959)
cat, rabbit	35-190 nm	(Biscoe and Stehbens, 1966)
cat	60-80 nm	(Ross, 1959)
cat	50-150 nm	(Hess, 1968)
cat	40-130 nm	(Al-Lani and Murray, 1968a)
cat	50-150 nm	(Zapata <u>et al.</u> , 1969b)
cat	130±3.5 nm	(Morita <u>et al.</u> , 1969)
man	100-200 nm	(Grinley and Glenner, 1966b)

Ross (1959) and Morita et al. (1969) and many others reported that most of the chief cells contain a sparse or scattered population of high electron density dark-cored vesicles. According to Lever and Boyd (1957) and Lever et al. (1959), the population of osmiophilic granules is higher in the dark cells than in the light cells. Although many studies have indicated that these granules are widely distributed in the chief cell cytoplasm, they are particularly dense beneath the cell membrane (Morita et al., 1969; Kondo, 1971) and are sometimes crowded at one pole of the cell or even found opening

on to the chief cell surface (Kondo, 1971). Kondo (1971) also reported that these granules are present in the chief cell processes but are absent in the axons.

Duncan and Yates (1967) regarded the high electron density droplets as an effect of fixation on a highly labile cytoplasm. In 1967, they reported that granules were faint after fixation with Dalton's fluid, very dense but small after fixation with osmic acid, devoid of a dense central core after 3% $KMnO_4$ fixation, and very dense after perfusion with formalin and glutaraldehyde. However, Biscoe and Stehbens (1966) and Hess (1968) found that granules were depleted in osmium fixed materials. The dark-cored vesicles, according to Duncan and Yates (1967), did not disappear but rather increased in number under anoxia. According to Molyneaux and Scott (1966) the granules become dispersed and approximate the plasma membrane after hypoxia.

Multivesicular Bodies, Vacuoles, Inclusion Bodies, Clear Corpuscles, and "Lamellate Bodies"

Multivesicular bodies were reported in the chief cell cytoplasm by Kondo (1971). Large vacuoles, 0.2-0.3 μ in diameter, containing small vesicles 20-30 nm in diameter have been reported by Hess (1968). The inclusion bodies of Kondo (1971) are about 0.4 μ in diameter, each having a central dense particle 0.3 μ in diameter, surrounded by 2-3 concentric lamellae. According to de Castro and Rubio (1968) clear corpuscles, 0.7-1.2 μ in diameter, are more frequent in animals subjected to hypoxia or hypercapnia. Abbott et al. (1972) have been the first to describe "lamellate bodies" measuring up to 1 μ m in length. They stated that these "lamellate bodies" are

"composed of a system of closely aligned, parallel canals or sacs, were occasionally found. ---- Continuity between lamellate bodies and the endoplasmic reticulum was sometimes observed".

Nucleus

The chief cells have been described as having a centrally placed, oval or rounded nucleus with a single nucleolus (Hoffman and Birrell, 1958; Ross, 1959; Al-Lami and Murray, 1968a; Kondo, 1971). Ross (1959) described them as having a dense periphery and a fine granular karyoplasm. Nuclear pores have been reported by Hoffman and Birrell (1958), Hayashi (1966) and Al-Lami and Murray (1968a), but Ross (1959) found none. The pores are about 80-100 nm wide according to Al-Lami and Murray (1968a). Lever et al. (1959) stated that the outer lamina of the nuclear membrane is more sacculated toward the cytoplasm in the cat than in the rabbit.

Modifications of the Chief Cell Plasma Membrane

Where two chief cells are opposed to each other, membrane thickenings (Dearnaley et al., 1968), desmosomes (Hess, 1968), tight junctions as well as desmosomes (Al-Lami and Murray, 1968b), junctional complexes similar to zonula adhaerens (Biscoe and Stehbens, 1966) and junctional specializations of the cell membranes of the type called fascia adhaerens have been reported by Kondo (1971). On the other hand, many observers made no mention of such a modification of chief cell plasma membranes (Duncan and Garner, 1957; Hoffman and Birrell, 1958; Ross, 1959; de Kock and Dunn, 1964).

Most observers did not report any specializations in the plasma membranes of chief cells contiguous with or enclosed by the sustentacular or type II cells, but Kondo (1971) reported "occasional junctional specializations of cell membranes with an accumulation of dense material in the subjacent cytoplasm on one or both sides". It has been reported that a gap only about 15 nm wide separates adjacent chief cell plasma membranes (Kondo, 1971).

At the sites of contact between the axon terminals and the chief cell there is no specialization of the adjoining surfaces nor is there any accumulation of synaptic vesicles or of mitochondria (Ross, 1959; de Kock and Dunn, 1964). Lever et al. (1959) however, made no mention of local specialization on the type I cell membrane although they described specialization in the axoplasm. This will be reviewed in detail in connection with the nerve endings.

(B) SUSTENTACULAR OR TYPE II CELLS

The cytoplasm of the sustentacular or type II cell has been stated to be less dense (Ross, 1959; Lever et al., 1959) or denser (de Castro and Rubio, 1968) than that of the chief cells, or the cytoplasmic density varies even in the same cell (Kondo, 1971). The cytoplasm has been described by many observers as containing mitochondria, endoplasmic reticulum, Golgi complex, cilia, ribosomes, microtubules, filaments or fibrils, lipid bodies, vesicles and vacuoles. Ross (1959) reported that 3-4 cytoplasmic processes which may be wide (300-500 nm) or narrow (15-30 nm), arise from any one sustentacular cell. According to him, they may embrace a whole glomus cell, parts of glomus cells, other sustentacular cell processes or a combination of these. The cytoplasmic processes

have been described as possessing vacuoles (de Kock and Dunn, 1964), microtubules 15 nm in diameter and fine fibrils about 5-15 nm in diameter (Biscoe and Stehbens, 1966) and a small amount of mitochondria and filaments in a very clear matrix (Kondo, 1971). These cytoplasmic processes, according to Kondo (1971) are applied to the chief cells without any membrane specializations.

Mitochondria, Endoplasmic Reticulum and Golgi Complex

The mitochondria, according to various reports, are small and are about 200-300 nm (Ross, 1959), and relatively few of them have been observed in the sustentacular cell cytoplasm (Lever et al., 1959; de Castro and Rubio, 1968). They have been described as having sparse cristae (Ross, 1959).

Dearnaley et al. (1968) stated that the sustentacular cells are characterized by an abundance of rough endoplasmic reticulum but, according to some workers, the endoplasmic reticulum is inconspicuous (Lever et al., 1959) and is not well developed (Kondo, 1971). The elongated or folded membrane profiles of Ross (1959) studded with small dense granules (10-15 nm in size), are probably the rough surfaced endoplasmic reticulum.

The size of the vesicles of the Golgi complex have been reported to be as large as 0.8 μ in diameter (Biscoe and Stehbens, 1966) and not well developed (Kondo, 1971).

Cilia, Ribosomes, Microtubules, Fibrils and Filaments

Cilia have been observed in the type II cell cytoplasm by Biscoe and Stehbens (1966) and Hess (1968). According to Biscoe and Stehbens (1966) the cilia of the 9 + 0 fibril pattern projected from the endothelial aspect of the type II cells.

Ribosomes, according to Kondo (1971), were not so well developed. Polyribosomes have been reported in the type II cell cytoplasm.

Microtubules, filaments and fibrils were reported to be conspicuous and rich in the type II cell cytoplasm by Al-Lami and Murray (1968) and Kondo (1971).

Lipid Bodies, Vacuoles and Vesicles

Ross (1959) reported the presence of osmiophilic lipid bodies in the sustentacular cell cytoplasm. Small vacuoles have been observed by de Castro and Rubio (1968). Also reported have been a few dark-cored vesicles (Al-Lami and Murray, 1968a) and a few light-cored vesicles (Ross, 1959).

Nucleus

The sustentacular cells have been described as having an ovoid (Kondo, 1971) and flattened or elongated nucleus (Ross, 1959; Lever et al., 1959), with a finely granular karyoplasm (Ross, 1959). Most of the observers stated that the sustentacular cell nucleus has a denser periphery than that of chief cells.

Cell Membrane Modifications

Biscoe and Stehbens (1966) found that dense zones up to 0.1μ long and 30 nm wide were present along the type II cell plasma membrane adjoining the basement membrane, and similar dense zones have been described by Al-Lami and Murray (1968a,b). Junctional specializations of cell membranes between two adjacent type II cells or between them and chief cells have been reported by Kondo (1971).

"Another Type of Cell" in the Carotid Body

According to de Castro and Rubio (1968) "there is another type of cell in the carotid body These cells are almost as large as the type I cells though they are much less numerous". They described the characteristics of these cells as a dense cytoplasm with osmiophilic granules, smaller mitochondria found only in the cell body, an irregular nucleus with large electron-dense granules, and cytoplasmic vacuoles.

(C) BLOOD VESSELS OF THE CAROTID BODY

De Castro and Rubio (1968) stated that in each carotid body lobule there are two distinct types of capillaries, the wide and tortuous type I capillaries with a diameter of $14-28\mu$, and the narrower and less numerous type II capillaries, with a diameter of $6-12\mu$, which bridge between the type I capillaries. Biscoe and Stehbens (1965) stated that blood vessels were numerous and sinusoidal, and were always lined by at least three endothelial cells. Association of pericytes and smooth muscle fibres with the vessel walls has been reported (Hoffman and Birrell, 1958;

Lever et al., 1959; Biscoe and Stehbens, 1965, 1966). The endothelial cells have been reported to be devoid of fenestrations (Garner and Duncan, 1958; de Kock and Dunn, 1964) but later observers emphasized their presence (Biscoe and Stehbens, 1965, 1966; Al-Lami and Murray, 1968a,b). Fenestrations, according to Biscoe and Stehbens (1965, 1966) and Al-Lami and Murray (1968a,b) are about 50-70 nm and 60 nm wide respectively, and are covered by diaphragms 10 nm thick (Al-Lami and Murray, 1968a). Moreover Biscoe and Stehbens (1965, 1966) stated that dense-walled or coated vesicles and caveolae are present in the endothelium. The endothelium was described as having numerous endothelial folds in the cat and mouse (Duncan and Garner, 1957).

Hoffman and Birrell (1958) detected a solitary ganglion cell lying adjacent to the sinusoid and Engström et al. (1957) even detected bud-shaped nerve endings beneath the innermost layer of the endothelium of small capillaries. In contrast to these reports Lever et al. (1959) stated that there are no nerve terminals in relation to the vessel wall.

According to Abraham (1968b), microvilli and cilia, especially of the endothelial cells, may play a role in the regulation of blood flow.

(D) NERVE FIBRES, NERVE ENDINGS AND THEIR RELATIONSHIP TO THE CHIEF CELLS

Most nerve fibres in the interstitial stroma (interglomerular tissue) are unmyelinated but a few myelinated fibres have also been reported (Ross, 1959; Eyzaguirre and Uchizono, 1961; Biscoe

and Stehbens, 1966; Kondo, 1971; Abbott et al., 1972). The axons, having a wide range of diameters, have been described by many workers as follows:

<u>Species</u>	<u>Axon diameter</u>	
cat (large axon)	0.2 μ or larger	(de Kock and Dunn, 1968)
cat (small axon)	0.2 μ or around	(de Kock and Dunn, 1968)
cat	0.2-0.4 μ	(Ross, 1959)
cat (nonmyelinated axon)	0.4-1.2 μ	(Dearnaley <u>et al.</u> , 1968)
guinea-pig	0.07-0.2 μ	(Kondo, 1971)

Axons of the following diameter ranges have been reported to be expanded or dilated to form the biggest nerve endings or synaptic bags or bulbous synaptic terminals in the carotid body:

<u>Species</u>	<u>Diameter of Axon</u>	<u>Diameter of Endings</u>
cat, rabbit	0.2-0.5 μ axon	0.5-2.0 μ endings (Biscoe and Stehbens, 1966)
cat	axon terminal	0.4-0.5 μ endings (Ross, 1959)
cat	axon terminal	3-6 μ endings (de Castro and Rubio, 1968)
cat	axon terminal	1-2 μ endings (Zapata <u>et al.</u> , 1969b)
cat	0.5 μ axon	1-2 μ endings (Hess, 1968)
cat	axon	1-3 μ endings (Dearnaley <u>et al.</u> , 1968)
cat	0.2 μ and larger axon	synaptic bags (de Kock and Dunn, 1968)
cat	axons	1.5-6.0 μ endings "synaptic" terminals (Abbott <u>et al.</u> , 1972)
guinea-pig	0.5 μ axon	2 μ endings (Kondo, 1972)

According to de Kock and Dunn (1968) the small diameter nerve fibres ($0.2\ \mu$ and around) do not show any enlargement but contain well defined microtubules around 20 nm in diameter. Kondo (1971) stated that the smallest fibres having a diameter of 70-200 nm are found particularly near the venules and possess few neurotubules in a relatively dense matrix of axoplasm. According to de Kock and Dunn (1968) the nerve fibres end in one of the following three ways:

- (i) as small nerve endings within mesaxonic infoldings of type II cells,
- (ii) as large synaptic bags in close apposition to the type I cells, and
- (iii) as small nerve endings in the complex folded membrane system.

The axons of the carotid body, according to many observers contained mitochondria (Dearnaley et al., 1968), neural filaments and fibres (Hess, 1968).

All ultrastructural studies of the carotid body indicate that the terminal axons or their expansions and the nerve endings are located on the surface of the glomus cell, between adjacent glomus cells, between the glomus cells and the blood vessels, or in relation to the type II cell sheaths. None of the ultrastructural studies so far carried out on the carotid body demonstrates that the terminal axons or the nerve endings are intracytoplasmic. Many observers have found them lying in contact or in the groove of the plasma membrane of the chief cells (Engström et al., 1957; Garner and Duncan, 1958; Ross, 1957a, 1959; Hoffman and Birrell,

1958; de Kock and Dunn, 1964; Biscoe and Stehbens, 1965, 1966; Al-Lami and Murray, 1967, 1968a,b; Morita et al., 1970; Kondo, 1971).

According to Al-Lami and Murray (1968a,b) and Molyneux and Scott (1966) there are two classes of nerve endings, but Kondo (1971) described three types of nerve endings and one type of terminal expansion or synaptic bag. Kondo (1971) described a rare nerve ending which lies in the cytoplasm of the sustentacular cell and contains small cored vesicles 50 nm in diameter, and a less frequent form of nerve ending having a dense accumulation of mitochondria, few glycogen particles and vesicles of varying sizes. He proposed that the former type of ending is "adrenergic" and the latter a "presumptive afferent ending". He also stated that none of them is in direct contact with the chief cells.

The nerve endings in the Schwann cells, according to Biscoe and Stehbens (1966) contained mitochondria 0.1-0.13 μ in diameter, electron opaque cored vesicles 65-100 nm in size, and microvesicles 50 nm in diameter. The nerve endings according to various reports contain mitochondria (Biscoe and Stehbens, 1965, 1966; Höglund, 1967; Al-Lami and Murray, 1965a,b; Kondo, 1971; Abbott et al., 1972), synaptic vesicles (Biscoe and Stehbens, 1965, 1966; Grimley and Glenner, 1966b; Höglund, 1967; Al-Lami and Murray, 1968a,b; Kondo, 1971; Abbott et al., 1972), occasional vesicles with central dense cores (Biscoe and Stehbens, 1965, 1966; Abbott et al., 1972), dense particles (Biscoe and Stehbens, 1965), glycogen granules (Biscoe and Stehbens, 1966; Al-Lami and Murray, 1968a; Kondo, 1971; Abbott et al., 1972), and fibrils and microtubules (Biscoe and Stehbens, 1966). According to Al-Lami and Murray (1968a)

ribosomes are absent in the nerve endings. The dimensions of the constituents of the nerve endings given by various observers are as follows:

mitochondria	100-180 nm in diameter	(Biscoe and Stehbens, 1966)
	150-250 nm " "	(Kondo, 1971)
vesicles	50 nm " "	(Biscoe and Stehbens, 1965)
	50-100 nm " "	(" " " , 1966)
	50-70nm " "	(Zapata <u>et al.</u> , 1969b)
electron opaque cored vesicles	100 nm " "	(Biscoe and Stehbens, 1965)
	40-850 nm " "	(" " " , 1966)
glycogen granules	10 nm " "	(" " " , 1966)
fibrils	10 nm " "	(" " " , 1966)
microtubules	25 nm " "	(" " " , 1966)

The terminal axon expansions (synaptic bags or synaptic terminals) have been reported as containing the following:

mitochondria	(Molyneux and Scott, 1966; Dearnaley <u>et al.</u> , 1968; Hess, 1968; de Kock and Dunn, 1968; Kondo, 1971; Abbott <u>et al.</u> , 1972).	
clear vesicles	50 nm in diameter	(Dearnaley <u>et al.</u> , 1968)
	50-60 nm " "	(Hess, 1968)
	40-60 nm " "	(de Kock and Dunn, 1968)
	60-150 nm " "	(" " " , 1968)
	15-30 nm " "	(de Castro and Rubio, 1968)
	up to 50 nm " "	(Abbott <u>et al.</u> , 1972)
osmium-dense cored vesicles	rare	(de Kock and Dunn, 1968)
	50-90 nm " "	(Abbott <u>et al.</u> , 1972)

dense bodies	150-250 nm in diameter	(Kondo, 1971)
glycogen granules	10-15 nm " "	(Abbott <u>et al.</u> , 1972)

The distance between the plasma membranes of the axon or nerve ending or synaptic terminal and that of the chief cell at the region of synaptic contact have been stated to be as follows:

axon-chief cell	30 nm wide	(Lever <u>et al.</u> , 1959)
axon- " "	8-17 nm "	(Biscoe and Stehbens, 1965)
axon- " "	5-10 nm "	(" " " , 1966)
endings- " "	10-20 nm "	(" " " , 1966)
endings- " "	20 nm "	(Kondo, 1971)
axon terminals- chief cell	30 nm "	(Hess, 1968)
axon terminals- chief cell	8-10 nm "	(de Castro and Rubio, 1968)
axon terminals- chief cell	30 nm "	(Zapata <u>et al.</u> , 1969b)
axon terminals- chief cell	30 nm "	(Abbott <u>et al.</u> , 1972)
	(some 15-20 nm)	

Axons, Axon Terminals, Endings and their Association with the Chief Cells

According to some observers the junction between the axon and glomus cell has no specializations whatsoever on either side (Ross, 1959; Garner and Duncan, 1958; de Kock and Dunn, 1964), but Lever et al. (1959) found specialization within the axoplasm. Many

observers reported that the structural modifications were either on the axon side or on both axon and glomus cell sides, (Biscoe and Stehbens, 1965, 1966; Duncan and Yates, 1967; Al-Lami and Murray, 1968a,b; Hess, 1968; de Kock and Dunn, 1968; de Castro and Rubio, 1968; Dearnaley et al., 1968; Kondo, 1971; Abbott et al., 1972). The structural modifications may be found (i) on the plasma membranes of axon terminals, nerve endings or glomus cells, (ii) within the axoplasm or in the glomus cell cytoplasm adjacent to the specialized structural contacts.

The structural modifications on the plasma membranes at the synaptic contacts (axon-glomus cell contacts) were reported as electron-dense zones 0.2-0.5 μ in length (Biscoe and Stehbens, 1965), 20 nm wide (Al-Lami and Murray, 1968a), opaque zones (Biscoe and Stehbens, 1966; Kondo, 1971), membrane thickenings (Hess, 1968; Abbott et al., 1972) and desmosomes (Hess, 1968; Battaglia, 1968; Kobayashi and Uehara, 1970). The specializations within the axoplasm or chief cell cytoplasm subjacent to the synaptic contacts have been reported as being a dense accumulation of vesicles with or without electron dense zones (Molyneux and Scott, 1966; Biscoe and Stehbens, 1965, 1966; de Castro and Rubio, 1968; Kobayashi, 1968, 1969a; Kobayashi and Uehara, 1970; Kondo, 1971; Abbott et al., 1972). The electron dense zones according to Biscoe and Stehbens (1965, 1966), extended about 50 nm into the axoplasm from the synaptic contacts, and the related intra cytoplasmic dense zones on the glomus cell side were as much as 80 nm wide (Biscoe and Stehbens, 1966).

Synaptic complexes were apparently afferent in the mouse as reported by Kobayashi and Uehara (1970) on the basis of the localization of small-cored vesicles. According to Al-Lami and Murray (1968b) the nerve endings in the carotid body may be entirely afferent in function. Axo-axonic synapses were also described by Kobayashi (1969b) in the carotid body of the bird, where he found synaptic vesicles on both sides of these synapses. However, according to some researchers, glomus cells received efferent innervation in the dog (Kobayashi, 1968) and in man (Abraham, 1968b). The basket-endings of the carotid body of the cat according to Al-Lami and Murray (1968a) were both afferent and efferent endings. Kondo (1971) also described adrenergic and afferent endings in the carotid body of the guinea-pig.

Nerve Endings as Chemoreceptors

Biscoe and Taylor (1963) proposed that the fine nerve endings in the carotid body of the cat were involved in chemoreception. In 1971, Biscoe postulated that the nerve endings themselves could be the transducer element and suggested that such nerve endings could be under the endothelium or surrounded by type II cells. He concluded that "the evidence now suggests that the type I cells are not receptors The sensors are small nonmyelinated nerve terminals enclosed in the type II cells".

E. NERVE SECTION EXPERIMENTS ON THE CAROTID BODY AND CAROTID SINUS

Reviews and reports of nerve section experiments on the carotid body have been written by de Castro (1926, 1928), Meijling (1938), Lever et al. (1959), de Kock and Dunn (1968), de Castro and Rubio (1968), Hess (1968), Biscoe and Stehbens (1967), Biscoe et al. (1969, 1970), Biscoe (1971), and Abbott et al. (1972). Denervation experiments on the carotid sinus were performed by Rees (1966, 1967, 1968).

(a) Carotid Body After Sectioning of Carotid Sinus Nerve

De Castro (1926) sectioned the glossopharyngeal nerve below the ganglion and found degeneration of nerve endings which were related to the glomus cells, and therefore suggested that these were effectors. In 1928 he performed intracranial sectioning of both glossopharyngeal and vagal nerve roots. He reported that the nerve endings were still intact even after 12 days post operation, and then claimed that the glomus cells were receptors. However, according to Meijling (1938), the neurofibrillar reticulum within the glomus cells remains unchanged after the carotid sinus nerve or all the nerves in the intercarotid triangle of the horse are sectioned.

Hess (1968) sectioned the glossopharyngeal nerve of the cat. He found changes in the synapses as early as one day post operation, and virtually no synapses were seen on the glomus cells at 3 days post operation, and at 7 days no nerve fibres or synapses around the glomus cells were seen. He also stated that "at 3 days up to 7 days from denervation no striking changes are seen in the chief

cells, perhaps the lipid bodies are seen more frequently than in the normal glomus cells". He also found changes in the cytoplasm of the capsule cell and changes in the nature of the cytoplasmic envelopment of the capsule cell around the glomus cells. De Kock and Dunn (1968) have described the folded membrane systems of type II cells as undergoing signs of severe membrane degeneration within 48 hours of carotid sinus nerve section; however, they did not find the small nerve fibres enclosed by these membrane systems to be affected. De Castro and Rubio (1968) stated that, when the carotid sinus nerve was sectioned in the cat, after 48 hours degenerative changes had developed only in the nerve terminals in contact with type I cells. However, when the vagal and glossopharyngeal roots were sectioned intracranially, they were unable to detect any changes in the nerve endings even after 30 days.

Delayed degeneration of glossopharyngeal fibres to the carotid body was suggested by Biscoe and Stehbens (1967), Biscoe et al. (1969, 1970) and Biscoe (1971). It was reported that the degeneration was neither uniform nor complete even after three months post operation (Biscoe and Stehbens, 1967; Biscoe et al., 1969). They stated that irregular spaces or vacuoles appeared within the type II cells. Biscoe et al. (1969, 1970) described the nerve endings on the glomus cells as efferent and hence their cell bodies were probably in the brain stem. Abbott et al. (1972) examined the carotid bodies of cats 3 hours to 3 weeks after sectioning of the carotid sinus nerve. They found that most of the myelinated fibres and many of the nonmyelinated fibres underwent degenerative changes. According to them the initial stages in

degeneration of the "synaptic" terminals could be detected within 3 hours of the carotid sinus nerve division, and beyond 10 days after operation no normal synaptic terminals were seen. They also reported that the type I glomus cells appeared to hypertrophy and produced new branched processes which filled in the spaces left by the degenerated neural elements.

(b) Carotid Body After Sympathectomy

One week after the unilateral excision of the cranial cervical ganglion and upper sympathetic chain of the rabbit, Lever et al. (1959) found no changes either in the glomus cells or in the nerve terminals associated with them. Hess (1968) did not find any changes in the synaptic terminals one week after severance of the sympathetic fibres to the carotid body of the cat. However, 2-3 weeks after the excision of the cranial cervical ganglion and sympathetic fibres to the carotid body of the cat, Biscoe and Stehbens (1967) found degenerative changes in the nerve fibres within Schwann cells under the endothelium. They therefore suggested that these nerve endings were sympathetic in origin.

(c) Ultrastructure of Normal Carotid Sinus

Various ultrastructural studies on the carotid sinus have been undertaken in the rabbit (Rees, 1966, 1967a,b, 1968; Dropmann, 1967) and man (Abraham, 1967, 1969). Ultrastructural studies on the carotid sinus of sheep or any other ruminants are not available in the literature.

Rees (1967b) described the carotid sinus adventitia as having two types of nerves "(category 1 and category 2)" in the deeper layer. He observed myelinated together with "premyelinated" axons of diameters 0.6-8.0 μ (thickness of myelin sheath not included) in the superficial adventitia. In the deeper layer he did not find any myelin sheath and suggested that the nerve fibres are "premyelinated" or nonmyelinated. He also stated that the "category 1" nerves (0.1-1.1 μ in diameter) are characterized by having numerous vesicles (30-50 nm in diameter) and a small number of mitochondria. According to him they are exclusively myelinated and are associated with isolated adventitial smooth muscle cells. He described the "category 2" nerves as having a diameter range of 0.2-4.5 μ , numerous mitochondria, concentric osmiophilic lamellae, membrane free granules, and inconspicuous vesicles 50-250 nm in diameter. He stated that they may be either nonmyelinated or "premyelinated" and are also associated with the adventitial smooth muscle cells. Rees (loc. cit.) observed no nerves in the tunica media or in the intima.

Dropmann (1967) observed ovoid shaped lamellar bodies ranging from 0.2-3.0 μ in diameter in the third or fourth muscle layer of the media in close connection with the elastic laminae. However, Rees (1967b) regarded these lamellar bodies as simple whorl-shaped membranous neurites in the deeper layer of the adventitia.

(d) Ultrastructure of Denervated Carotid Sinus

Rees (1966, 1967b) is probably the only one who performed denervation experiments on rabbits and studied the carotid sinus

microscopically and ultrastructurally. He performed unilateral cranial cervical ganglionectomy and unilateral carotid sinus nerve section, or both. After sectioning of the carotid sinus nerve he observed no major nerve bundles of normal appearance in the carotid sinus wall, and the nerves containing dense-cored vesicles ("category 1 nerves") still remained in the deeper part of the adventitia. After sympathectomy he did not observe any "category 1 nerves" in the carotid sinus wall or any visible changes in the composition of large sheathed nerve bundles situated in the superficial adventitia. He concluded that the "category 1 nerves" were adrenergic nerves which ultimately ended in relation to the adventitial muscle surface. The deep adventitial neurites ("category 2") were derived from the glossopharyngeal nerve and they most likely represented the sensory (baroreceptor) nerve component of the sinus wall (Rees, 1967b).

RESULTS

A. FIXATION AND STAINING

Carotid bodies and carotid sinuses removed from anaesthetized animals prior to subsequent immersion in the modified Karnovsky's fixative at 4°C were poorly fixed. In these specimens, the organelles of the carotid body cells, especially the mitochondria, were abnormally distended and the glomus cytoplasm was excessively vacuolated. Also, the cytoplasm of fibroblasts, axons and smooth muscle cells in the carotid sinuses were vacuolated.

Carotid bodies and carotid sinuses from anaesthetized animals infused in situ with either modified Karnovsky's fluid

or 5% glutaraldehyde, phosphate buffered, pH 7.2-7.4, were satisfactorily fixed. Infusion of 5% glutaraldehyde only, phosphate buffered, pH 7.2-7.4, through both common carotid arteries appeared to be equally as effective in fixing the carotid body and the carotid sinus as when 2% paraformaldehyde was incorporated.

Brief washing of the tissue blocks in distilled water before dehydration through an ethanol series, including 75% ethanol in which 1% uranyl nitrate was incorporated, gave better differentiation and contrast. Subsequent staining of the tissue sections from these tissue blocks with 1% uranyl nitrate did not further improve the contrast or the differentiation of the cellular components. Seven to ten minutes staining of thin section on the grid with 1% lead citrate alone was found to be sufficient for the carotid body and carotid sinus.

B. ULTRASTRUCTURE OF THE CAROTID BODY

1. NORMAL CAROTID BODY

The parenchyma of the carotid body of the lamb was found to be composed of two major types of cells, the chief or type I and sustentacular or type II cells. The carotid body cells were found in groups among the blood vessels (sinusoids). Myelinated and non myelinated nerve fibres were numerous especially at the periphery of the carotid body tissue (Plate XXIV, Fig. 1). Mast cells were occasionally found but they were fewer in the carotid body than in the carotid sinus. Although ganglion cells were observed frequently in the carotid body under light microscopy, they were rarely seen under electron microscopy.

(a) Chief or Type I Cells

The large parenchymal cells of the carotid body which contained electron dense-cored vesicles are the chief or type I cells. These osmiophilic, electron dense-cored vesicles were present in all the carotid bodies examined by electron microscopy, the fixatives being either modified Karnovsky's fluid or in 5% glutaraldehyde (phosphate buffered, pH 7.2-7.4) solution (Plate XXII, Fig. 2). The classical "light" and "dark" cells found in many species were not able to be identified with certainty in the lamb. It was also not possible to classify the carotid body type I cells into several sub types as was done by Morita et al. (1969) in the cat.

The chief or type I cells were generally rounded to polygonal in shape, having oval to rounded nuclei. They measured 7-14 μ in diameter. The type I cells or cell groups were partially enclosed by the cytoplasmic extensions of fibroblasts and type II cells (Plate XXII, Fig. 3). The centrally placed nucleus usually exhibited a single and prominent nucleolus. The nucleus measured 4.8-7 μ in diameter.

The adjacent chief cells were generally approximately 0.3 μ apart. On some occasions a distance of 1.19 μ - 2 μ was noted when the adjacent chief cells were separated by three or more layers of cytoplasmic processes of fibroblasts. The membrane thickenings and specializations such as desmosomes, zonula adhaerens or fascia adhaerens were not observed on the opposed membranes of the chief or type I cells.

The chief cell cytoplasm exhibited numerous cytoplasmic organelles and inclusions. Mitochondria were abundant throughout the cytoplasm. They were usually round to oval in shape and were 720 nm long and 160 nm wide. Cristae mitochondriales were generally of equal size and parallel in their orientation (Plate XXII, Fig. 1). In the cytoplasmic processes of the chief cells they were oriented parallel to the long axes of the processes.

Numerous free ribosomes 10-21 nm in diameter, and granular endoplasmic reticulum were observed in the cytoplasm. The endoplasmic reticulum was composed of cisternae of various sizes, 21 to 63 nm in diameter. Some of these cisternae were 105 nm apart from each other. The granules on these tubular systems were of the same size as those found free in the cytoplasm. Centrioles were located near the nucleus. Also distributed throughout the cytoplasm were the microtubules and filaments which were also present in the chief cell processes.

Golgi complexes were located occasionally around the nucleus. Cytoplasmic vesicles 17-45 nm in diameter were always present and sometimes tubular systems of the Golgi complexes were closely associated with them. Also noted in the cytoplasm were clear vesicles 350-400 nm in length and 100-300 nm in width.

The most characteristic feature of the chief cell was the presence of the osmiophilic electron dense-cored vesicles which were bounded by distinct membranes (Plate XXIII, Fig. 1; Plate XXIV, Fig. 2). They were distributed throughout the cytoplasm and their diameters ranged from 63-160 nm. The electron dense cores of these vesicles were separated from the outermost membranes by a uniform distance of 21 nm.

There were two types of nerve endings - the large and small, in the carotid body. The large nerve endings (Plate XXIV, Fig. 3) were seen associated with the type I cells while the smaller nerve endings and nonmyelinated axons were related to the blood vessel (Plate XXVIII, Fig. 2). The type I cell membranes did not exhibit any electron-dense zones at the glomic cell and nerve ending contacts. Sometimes very fine nonmyelinated axons were seen in the small grooves of the type I cell membrane.

(b) Sustentacular or Type II Cells

The sustentacular or type II cells were irregularly shaped and were best observed at the periphery of the carotid body lobules. They were 4-6 μ in diameter and possessed extensive cytoplasmic processes which wrapped around the type I cell or cell groups (Plate XXII, Fig. 2). These cells possessed a flattened or ovoid nucleus with a finely granular karyoplasm.

The cytoplasm of type II cells contained mitochondria, endoplasmic reticulum, Golgi complexes, few cytoplasmic vesicles, microtubules and filaments. No electron dense-cored vesicles were observed in their cytoplasm. The type II cells exhibited relatively few mitochondria, and their granular endoplasmic reticulum was not as prominent as in the type I cells.

The cytoplasmic processes of the type II cells were long and complex. They enveloped the type I cell almost completely or only partially. In some cases, by doing so, their cytoplasmic processes intervened between the type I cell or cells and the blood vessels (Plate XXII, Figs. 1, 3). Therefore in these situations the sinusoidal walls were separated by varying

numbers of cytoplasmic processes of type II cells, fibroblasts and collagen fibres from the type I cell or cells.

(c) Nerve Fibres

The carotid body capsule contained numerous myelinated and nonmyelinated fibres. The smallest diameter myelinated fibres were 1.8μ in diameter whereas the largest ones were up to 3.5μ in diameter. Bundles of myelinated fibres were ensheathed by cytoplasmic processes of fibroblasts. Usually collagen fibres were ensheathed by cytoplasmic processes of fibroblasts. Usually collagen fibres intervened between the nerve fibres, between nerve bundles, and between them and the adjacent glomic tissue (Plate XXII, Figs. 2, 3). Numerous, small mitochondria, very few vesicles, and neural filaments and microtubules were seen in the axoplasm of nerve fibres.

(d) Nerve Endings

There were two types of nerve endings - large and small - in the carotid body of the lamb. The large nerve endings were 2 thick and approximately 8μ long (Plate XXIV, Fig. 3). They contained small mitochondria, densely packed electron dense-cored vesicles 110 nm in diameter, clear vesicles up to 1μ in diameter, and small, dense granules of 36 nm in diameter. The axoplasm was very susceptible to fixation artifacts, especially when the tissues were fixed by imersion as compared to those fixed in situ by infusion.

(e) Blood Vessels

Blood vessels were numerous in the carotid body tissue and were lined by one to three endothelial cells (Plate XXII, Fig. 1; Plate XXV, Fig. 3). The endothelial cells projected cytoplasmic folds, 70-95 nm wide and 460-720 nm long, into the blood vascular lumen. Occasionally, branched cytoplasmic folds were observed. The endothelial cells were fenestrated and their fenestrae were 40-80 nm wide.

The distance between the chief cell (type I) and blood vessel (sinusoid), in situations where fibroblast or type II cell processes intervened, was about 0.4μ . It was generally found that cytoplasmic extensions of fibroblasts either surrounded the blood vessel or ensheathed groups of type I and type II cells.

2. DENERVATED CAROTID BODY

(a) Carotid Body After Sectioning of the Carotid Sinus Nerve

From two weeks after sectioning of the carotid sinus nerve the myelinated nerve fibres in the capsule and in the interlobular connective tissue of the carotid body exhibited marked degenerative changes. The degenerated nerve fibres were not identifiable with certainty in the carotid bodies after five weeks to eight weeks denervation.

Neither the type I nor the type II cells showed detectable cellular changes either after sectioning of the carotid sinus nerve or after sympathectomy. In this, the present study agrees with those of Lever et al. (1959), de Kock and Dunn (1968) and de Castro and Rubio (1968).

Nerve endings of the large type which were usually associated with the type I cells, as well as the large diameter myelinated nerve fibres of the carotid body degenerated after sectioning of the carotid sinus nerve (Plate XXV, Fig. 2). As the nonmyelinated nerve fibres (Plate XXV, Fig. 1) still remained intact these large nerve endings and large myelinated nerve fibres are suggested to be of the glossopharyngeal origin.

(b) Carotid Body After Sectioning of the External Carotid Nerve or Cranial Cervical Ganglionectomy

There were no detectable morphological changes in the type I and type II cells of the carotid body after sectioning of the external carotid nerve or cranial cervical ganglionectomy. However, degeneration was seen in the small nonmyelinated nerve fibre terminals (Plate XXV, Fig. 3), and also in the small nerve endings especially those near to or in contact with the blood vessels of the carotid body. As the large diameter myelinated nerve fibres and the large nerve endings still remained intact, the small nonmyelinated nerve fibre terminals and the small nerve endings which are related to the blood vessels are suggested to be of sympathetic origin.

C. ULTRASTRUCTURE OF THE CAROTID SINUS

1. NORMAL CAROTID SINUS

The fine structure of the individual vascular wall components was found to be similar in the common carotid artery, carotid sinus, and the occipital (muscular portion) and external carotid arteries. The carotid sinus wall is composed of endothelium,

tunica media **and** tunica adventitia. The individual components of the carotid sinus wall are endothelium, smooth muscle cells, fibrocytes, occasional mast cells, collagen and elastic fibres.

(a) Tunica Intima

A single layer of flattened endothelial cells lined the lumen of the carotid sinus. The intima was normally $1.5-2.5\mu$ thick and was separated from the internal elastic lamina by an ill-defined layer $0.3-1.0\mu$ thick. The endothelial cell processes narrowed gradually before coming in contact with the adjacent endothelial cell processes. No intercellular gaps or pores were observed. The endothelial cells possessed rich organelles and inclusions. The endothelial cells presented complex endothelial folds.

(b) Tunica Media

The tunica media of the carotid sinus wall consisted of elastic membranes (Plate XXVI, Fig. 1) alternated with one to three layers of smooth muscle cells (Plate XXVII, Fig. 3). In a few situations smooth muscle cells were absent between one or two elastic laminae. The number of elastic laminae in the media of the carotid sinus varied from 3 to 12. The smooth muscle cells, especially their cytoplasmic processes, were closely related to the elastic membranes. A distance of 0.16μ to 0.78μ generally separated the smooth muscle cells and the elastic membranes.

The slender smooth muscle cells of the media were $3-4\mu$ wide across their nuclei while their cytoplasmic processes were considerably narrower. The processes formed cytoplasmic contacts with adjacent smooth muscle cells (Plate XXVII, Fig. 3). Adjacent cell bodies also exhibited cytoplasmic contacts which were

0.7-2.14 μ long, whereas the cytoplasmic contacts between processes or between the processes and the membranes of the cell bodies could be as small as 0.07-0.1 μ in length.

(c) Tunica Adventitia

The tunica adventitia of the carotid sinus consisted of a few isolated smooth muscle cells, fibrocytes and collagen fibres. Fibrocytes showed long cytoplasmic extensions (Plate XXVI, Fig. 2) similar to those found in the carotid body. The present findings agree with those of Rees (1968).

(d) Nerves of the Carotid Sinus

In the electron micrographs of the normal carotid sinus of lambs, no nerve fibres were detected either in the media or in the tunica media. The tunica adventitia was rich in myelinated and nonmyelinated nerves (Plate XXVI, Fig.3; Plate XXVII, Fig. 2).

(i) Nerves in the Superficial Adventitia

In the superficial part of the carotid sinus adventitia, both myelinated and nonmyelinated axon bundles (Plate XXVIII, Fig. 1) were observed. Almost all of the nerves occurred as bundles or trunks. The nerve terminals possessed very indistinct perineural sheaths and few electron dense-cored vesicles.

(ii) Nerves Near the Medioadventitial Border

Near the medioadventitial border of the carotid sinus wall, only single nerve fibres were observed. All the nerves at this level were nonmyelinated and possessed distinct perineural sheaths. The nerve terminals contained dense-cored vesicles and mitochondria (Plate XXVII, Fig. 1).

2. DENERVATED CAROTID SINUS

(a) Carotid Sinus After Sectioning of the Carotid Sinus Nerve

Two weeks after sectioning of the carotid sinus nerve marked degenerative changes were observed in the large myelinated nerve fibres of the carotid sinus. These changes were almost complete five to eight weeks after sectioning of the carotid sinus nerve. The number of myelinated nerve fibres in the carotid sinus adventitia were markedly reduced while some nonmyelinated nerve fibres were occasionally seen. Those fine nonmyelinated nerve fibres (Plate XXVIII, Fig. 2) which persisted could be compared to those small nerve fibres of de Kock and Dunn (1968) and Biscoe and Stehbens (1967). These small fibres could be either persisting carotid sinus nerve fibres or the fibres of the external carotid nerve (sympathetic). The nonmyelinated nerve terminals possessing distinct perineural sheaths and possessing dense-cored vesicles were usually found to be degenerated after sectioning of the external carotid nerve. However, the nerve terminals possessing indistinct perineural sheaths and few electron dense-cored vesicles degenerated after sectioning of the carotid sinus nerve. From the present study it is suggested that these nerve terminals were derived from the glossopharyngeal nerve via the carotid sinus nerve.

(b) Carotid Sinus After Sectioning of the External Carotid Nerve or Cranial Cervical Ganglionectomy

The nonmyelinated sheathed nerve terminals at the medio-adventitial border of the carotid sinus were usually degenerated after sectioning of the external carotid nerve or after cranial

cervical ganglionectomy. However, the large myelinated nerve fibres (Plate XXVIII, Fig. 3) and, the nerve terminals possessing indistinct perineural sheaths and few electron dense-cored vesicles still remained in the carotid sinus adventitia. It is suggested that the degenerated nonmyelinated sheathed nerve terminals belonged to the sympathetic system.

D. OCCIPITAL ARTERY (MUSCULAR PORTION)

The elastic membranes in the media of the occipital artery (muscular portion) were $0.2-3.0\mu$ in diameter. They were closely related to the collagen fibres and fibroblasts. The collagen fibres were 6.0 nm thick. In the adventitia, myelinated nerve fibres 1.4 to 5.3μ in diameter and a number of nonmyelinated fibres were seen. The myelin sheaths were 0.4 to 0.5μ thick. The axoplasm of the myelinated fibres contained mitochondria and vesicles of various sizes.

E. COMMON CAROTID ARTERY

The elastic membranes in the media of the common carotid artery were $2.3-3.8\mu$ in diameter. Collagen fibres usually intervened between the smooth muscle cells and the elastic membranes. A minimum distance of 2.3μ was found between the smooth muscle cells and the elastic membranes. There were 2-3 layers of smooth muscle cells in each cell group interposed between the elastic membranes. The smooth muscle cells measured $2.4-4.5\mu$ in diameter and their nuclei $0.7-1.5\mu$ in diameter. Adjacent smooth muscle cells were $0.1-1.0\mu$ apart from each other. The rough surface endoplasmic reticulum was especially

prominent in the smooth muscle cells. Numerous myelinated and nonmyelinated nerve fibres were seen in the adventitia.

DISCUSSION

The ultrastructure of the carotid body and carotid sinus of the lamb can be compared to those of laboratory animals such as the rat, mouse, guinea-pig, rabbit and cat (see Literature Review, p.147).

The type I and type II cells of the carotid body as seen under light microscopy in all laboratory animals were also demonstrated by electron microscopy in the lambs. Although mast cells have been described by Lever et al. (1959) in the rabbit and cat, they were not seen in the lamb carotid body under the electron microscope. Ganglion cells have been described in the rat (Hoffman and Birrell, 1958), cat (Ross, 1959; Biscoe and Stehbens, 1966; Al-Lami and Murray, 1968 a; Hess, 1968), rabbit (Biscoe and Stehbens, 1966), dog (Kobayashi, 1968) and Weddell seal (Morita et al., 1970). However, in the lamb ganglion cells were not seen under the electron microscope although they were demonstrated histologically.

According to de Castro and Rubio (1968) the minimum distance which separates the type I cell from the blood varies between 1 and 3μ in the cat. In the present study the distance between the type I cell and the blood vessel in some situations was about 0.4μ .

Many observers classified type I cells into two or more cell types. However, in the lamb it was not possible to classify type I cells according to their cytoplasmic density, or the morphological features of the osmiophilic granules. It was found that all of the type I cells contained osmiophilic vesicles. The present study supports the statement of Biscoe (1971) that there is no entirely convincing morphological evidence to support the claim that there are two varieties of type I cell, light and dark, one with many vesicles and the other with few or no electron-dense vesicles.

The type I cells of many laboratory animals and man have been reported to have a cilium or cilia (Biscoe and Stehbins, 1966; Kraus and Martinek, 1967; Hess, 1968; Battaglia, 1968; Kondo, 1971) and a Nissl body (Grimley and Glenner, 1966 b; Hess, 1968; Zapata et al., 1969 b). They were not seen in the present study of the lambs.

As the glomus cells (type I) are equipped with numerous cytoplasmic organelles, especially abundant mitochondria, endoplasmic reticulum, well developed Golgi complexes and various types of cytoplasmic vesicles, they should be regarded as metabolically very active cells supplemented with abundant nerve terminals and nerve endings. The greatest interest lies in the nature and content of the dark-cored osmiophilic vesicles of the type I cells. From the fluorescent microscopical studies they are suggested to be rich in biogenic amines especially noradrenaline and dopamine which did not disappear after chronic sympathetic denervation. The size of the osmiophilic dark-cored vesicles of the lamb carotid body was found to be the same as those of the

Syrian hamster (Chen and Yates, 1969), guinea-pig (Kondo, 1971), mouse (Kobayashi and Uehara, 1970), rabbit (Dearnaley et al., 1968; Biscoe and Stehbens, 1966), cat (Lever and Boyd, 1957; Biscoe and Stehbens, 1966; Ross, 1959; Hess, 1968; Al-Lami and Murray, 1968 a; Zapata et al., 1969 b; Morita et al., 1969) and man (Grimley and Glenner, 1966 b). These electron dense-cored vesicles were always seen in the osmium fixed carotid bodies obtained from animals perfused by modified Karnovsky's fluid or 5% glutaraldehyde (phosphate buffered, pH 7.2-7.4). Duncan and Yates (1967) reported that granules were very dense but small after fixation with osmic acid; however, Biscoe and Stehbens (1966) and Hess (1968) found that these vesicles were depleted in osmium fixed materials.

The present study agrees with the statement of de Kock and Dunn (1968) that the nerve fibres end in one of three ways - (i) as small nerve endings within mesaxonic infoldings of type II cells, (ii) as large synaptic bags in close apposition to the type I cells, and (iii) as small nerve endings in the complex folded membrane system. The present study also demonstrated that the terminal axons and the nerve endings are located on the surface of the type I cell, between adjacent type I cells, between the glomus cells and the blood vessels, or in relation to the type II cell sheaths.

Although delayed degeneration of the glossopharyngeal nerve fibres to the carotid body was suggested by Biscoe and Stehbens (1967), Biscoe et al. (1969, 1970) and Biscoe (1971), many observers described nerve degeneration from as early as 3 hours (Abbott et al., 1972), 2 days (de Castro and Rubio, 1968;

de Kock and Dunn, 1968), and 3 days (Hess, 1968). According to Hess (loc. cit.) no nerve fibres or synapses around the glomus cells are seen at 7 days after sectioning of the carotid sinus nerve. Beyond ten days after operation no normal synaptic terminals were seen by Abbott et al. (1972). In the present study in lambs, degenerative nerve terminals and nerve endings were not identifiable with certainty in the carotid bodies after 5 weeks to 8 weeks from nerve sectioning.

After sectioning of the carotid sinus nerve, Hess (1968) found more lipid bodies than in the normal glomus cells, and changes in the capsule cell cytoplasm, whereas Biscoe and Stehbens (1967) and Biscoe et al. (1969) stated that irregular spaces or vacuoles appeared within the type II cells. In contrast, in the lamb, neither the type I nor the type II cells showed detectable cellular changes either after sectioning of the carotid sinus nerve or after sympathectomy.

The carotid sinus ultrastructure in the lamb presented no marked morphological differences from that of the laboratory animals so far studied. It was found that the endothelial cells of the tunica intima in the lamb had elaborate endothelial folds and occasionally were branched.

The scattered carotid body tissue was studied by light microscopy and was found to consist of cells similar to those observed in the carotid body. Its nerve supply was found to be mainly from the carotid sinus nerve (Plate II, Fig. 3). However, in the present study the ultrastructure of the scattered carotid body tissue was not examined.

SUMMARY

1. Ultrastructural studies were made on the normal and long-term denervated carotid body and carotid sinus in lambs.
2. The normal carotid body of the lamb was composed of two major cell types, the chief or type I and sustentacular or type II cells. The type I cells were characterized by the presence of numerous dark-cored osmiophilic vesicles and mitochondria. The type II cells were irregular shaped cells with few osmiophilic vesicles or mitochondria, and extensive cytoplasmic processes.
3. Two types of nerve endings - the large and small - were observed in the normal carotid body. The large nerve endings were seen associated with the type I cells while the smaller nerve endings were related to the blood vessels.
4. The blood vessels were numerous in the carotid body and were lined by one to three endothelial cells.
5. After sectioning of the carotid sinus nerve most of the large diameter myelinated nerve fibres and the large nerve endings degenerated, and therefore it is suggested that they are derived from the glossopharyngeal nerve. After sympathectomy, however, the small nerve endings which were related to the blood vessels degenerated, and they are suggested to be derived from the sympathetic system.

6. Ultrastructure of the individual vascular wall components were similar in the common carotid artery, carotid sinus, and occipital (muscular) and external carotid arteries.
7. The vascular layers of the ovine carotid sinus appeared to be comparable to those of the laboratory animals.
8. No nerve fibres were detected in either the tunica media or tunica intima of the carotid sinus.
9. The nerve terminals in the superficial adventitia which possessed indistinct perineural sheaths and few electron dense-cored vesicles degenerated after sectioning of the carotid sinus. It is suggested that they are derived from the glossopharyngeal nerve. After sympathectomy the nerve terminals near or at the medioadventitial border were found to be degenerated. These nerve terminals, which contained numerous dense-cored vesicles and mitochondria, are suggested to be sympathetic in origin.
10. The ultrastructure of the occipital (muscular) artery and the common carotid artery is also briefly described.

CHAPTER EIGHT

GENERAL CONCLUSIONS AND COMMENTS

In the present study of the carotid body and carotid sinus of lambs and adult sheep, the results obtained from the gross anatomical, histological, fluorescent microscopical and ultrastructural studies have been discussed separately in their respective chapters of the thesis. From these studies it is evident that the carotid body and carotid sinus of lambs and adult sheep are similar to those of the laboratory animals so far described by others. The present experiments have shown that both the carotid body and carotid sinus in the ovine species receives glossopharyngeal and sympathetic innervation. The results obtained from the normal carotid body and carotid sinus were supported by the nerve degeneration results from the nerve section experiments.

The times allowed for nerve degeneration were thought to be sufficient in both the histological and ultrastructural nerve degeneration studies; however, in the case of ultrastructural studies it is suggested that the post operative period should be as short as possible in order to observe the early degenerative changes in the terminal nerve fibres and nerve endings. In the present study, the degenerative changes were almost complete at 2 weeks to 2 months after nerve transection.

For both histological and ultrastructural studies on the carotid body and carotid sinus fixation of the organs in situ is recommended. In situ fixation prevented the cytoplasmic vacuolations and mitochondrial swelling in the carotid body cells and carotid sinus smooth muscle cells. Nerve endings in both the carotid body and the carotid sinus are highly susceptible to fixation artifacts.

The optimum compositions of the fixative fluids employed in the gross anatomical dissections for better differentiation of the nervous tissue from the connective tissue and surrounding structures have been described.

Various tissue fixatives and nerve staining techniques were employed on the carotid body and carotid sinus of lambs and sheep. For histological studies on the carotid body fixation with Regaud's fluid is recommended as it invariably preserved the glomic cell cytoplasm and its organelles. Tissues fixed in 10% formalin, formol-acetic alcohol or formol-sucrose ammonium hydroxide are suitable for frozen sections which are subsequently to be stained with Winkelmann's (1959) nerve stain. For this stain, thorough washing of the tissue blocks and sections is necessary to prevent the formation of precipitates in the potassium carbonate solution. Tissues fixed in the above fixatives and in Bouin's fluid or Bouin's fluid as modified by Davenport (1960) are suitable for most nerve stains, especially Romanes' silver chloride (1950) stain. Thin frozen tissue sections can also be stained satisfactorily with Romanes' silver chloride stain. Tissues fixed in Bouin's fluid or in Bouin's fluid as modified by Davenport (1960) need shorter silver reduction time in both the gold chloride and oxalic acid solutions.

PLATES

Key to Plate I.

Gross Innervation of the Carotid Trifurcation

- Fig. 1. Two carotid sinus nerve filaments join together before reaching the carotid trifurcation. A communicating branch between the glossopharyngeal nerve and the dorsal branch of the pharyngeal rami of the vagus is prominent. Left carotid trifurcation, lateral view.
- Fig. 2. Two carotid sinus nerve filaments as in Fig. 1. One of the filaments communicates with the vagus. A communicating branch between the glossopharyngeal nerve and the dorsal branch of the pharyngeal rami of the vagus is illustrated. Left carotid trifurcation, lateral view.
- Fig. 3. Two carotid sinus nerve filaments lie lateral to the pharyngeal rami of the vagus while the cervical sympathetic trunk and external carotid nerve lie medial to them. The external carotid nerve communicates with one carotid sinus nerve filament. Right carotid trifurcation, lateral view.

Key to Plate II.

Position of the Carotid Body

- Fig. 1. The carotid body is situated on the occipitoascending pharyngeal arterial trunk. Formol-acetic alcohol, H & E, X50.
- Fig. 2. The carotid body is located around the origin of the ascending pharyngeal artery. Formol-acetic alcohol, H & E, X50.
- Fig. 3. Scattered carotid body tissues on the occipitoascending pharyngeal arterial trunk. Divisions of the carotid sinus nerve are also to be seen. Formol-saline, H & E, X50.

PLATE I.

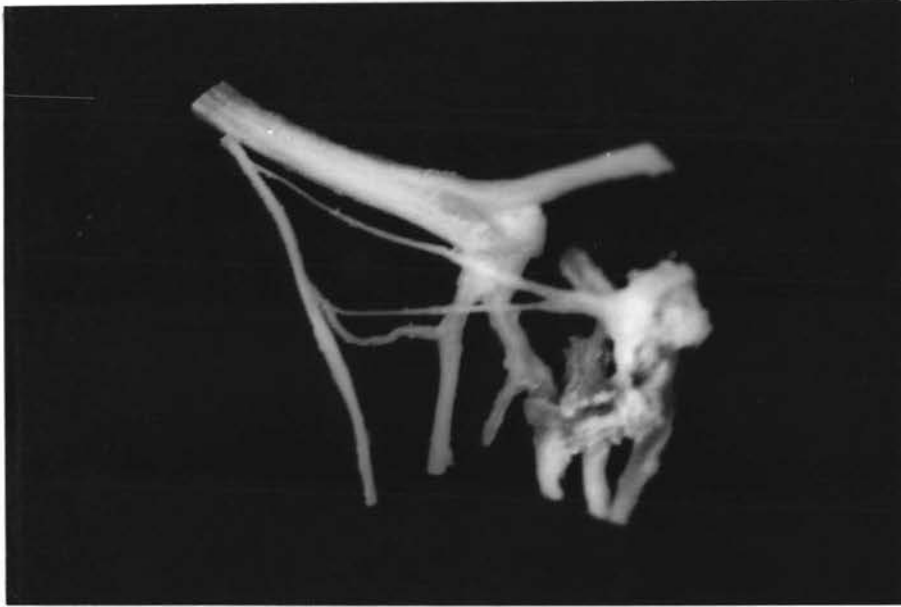

Fig. 1.

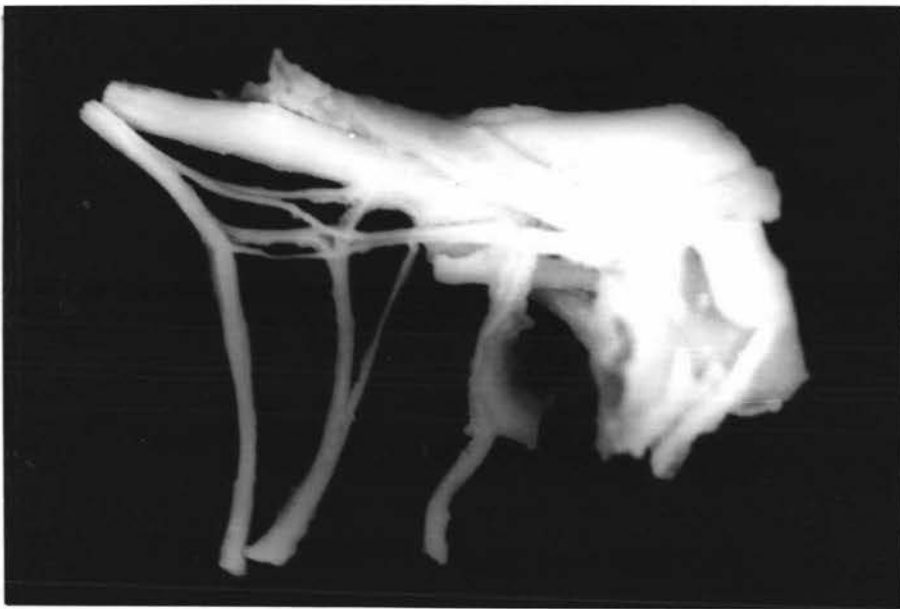

Fig. 2.

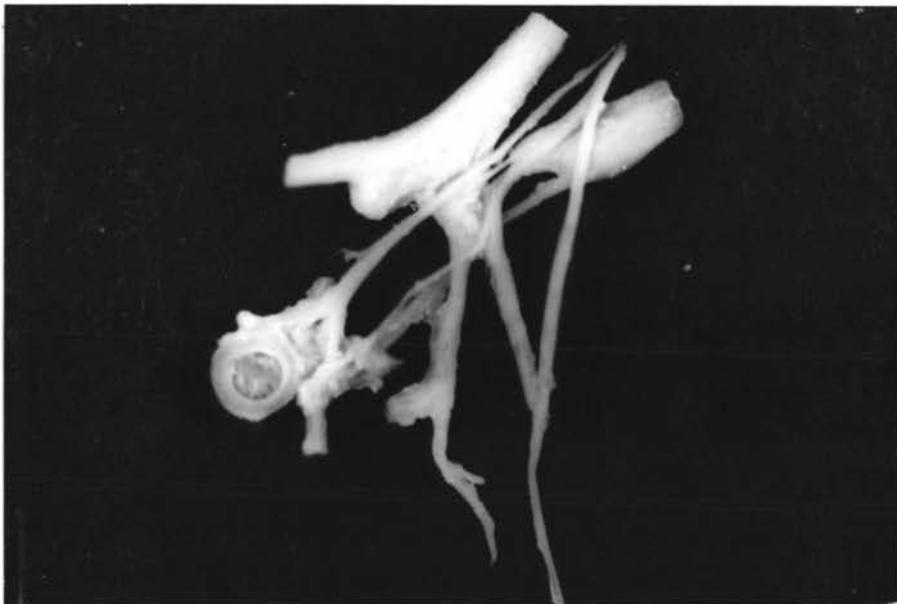

Fig. 3.

PLATE II.

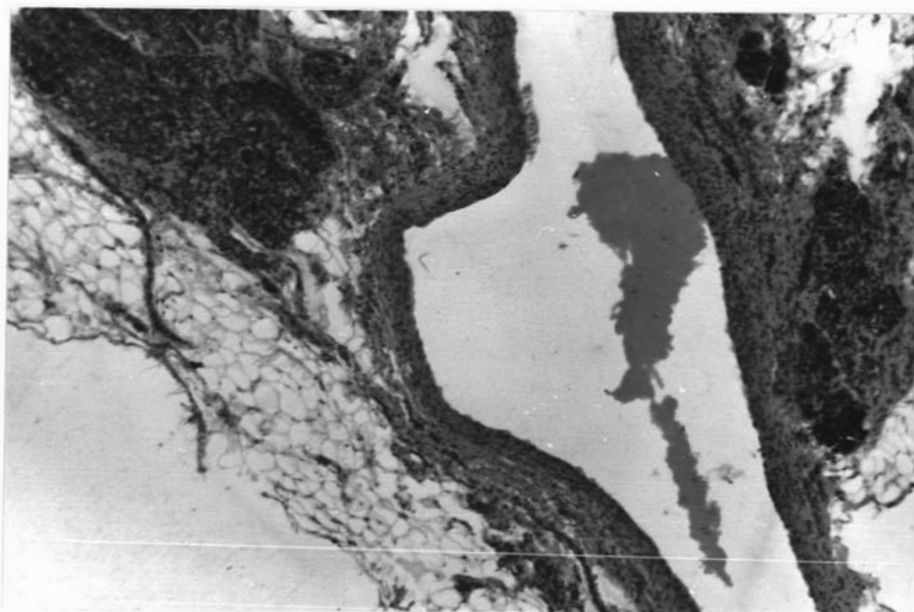

Fig.1.

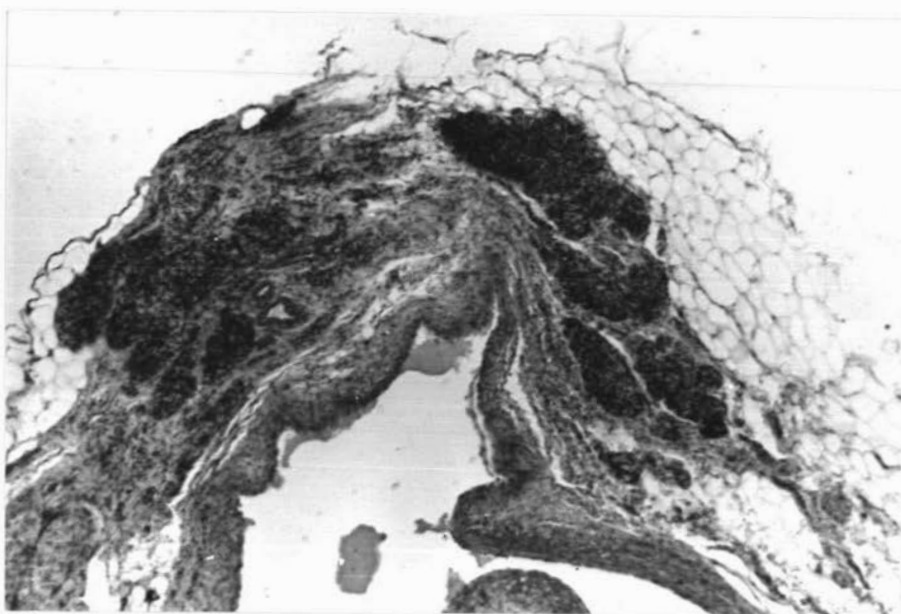


Fig.2.

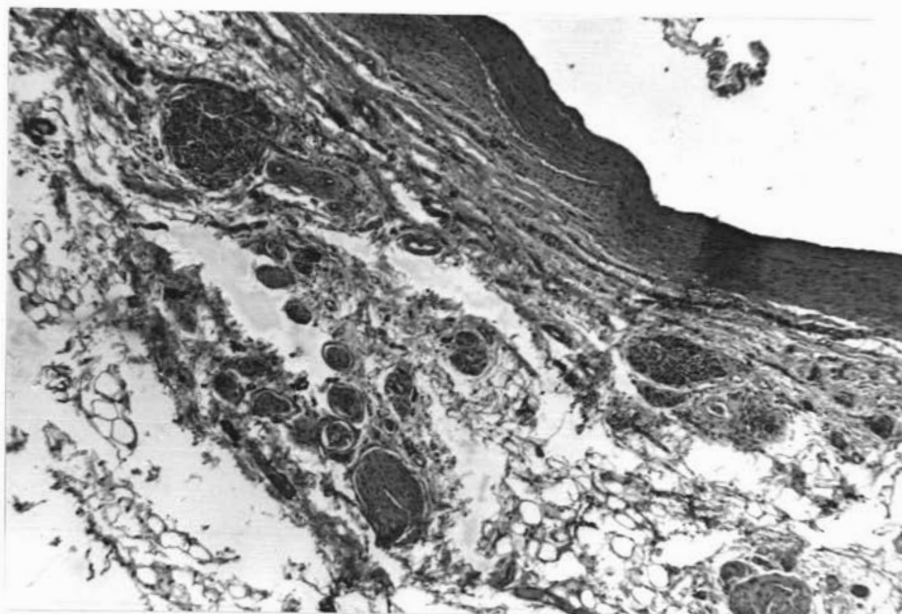


Fig.3.

Key to Plate III.

Structure of the Normal Carotid Body

- Fig. 1. Distinct lobulation of the carotid body is illustrated. Nerve trunks (on the top and on the right hand side) and blood vessels (left hand side) are also to be seen. Regaud's fluid, H & E, X74.
- Fig. 2. Upper portion of the carotid body from (Fig. 1.). Ganglion cells are seen in the nerve trunks which are located in the capsule. Regaud's fluid, H & E, X190.
- Fig. 3. Carotid body showing less distinct interlobular connective tissue. Regaud's fluid, Picro-ponceau, X190.

Key to Plate IV.

Structure of the Normal Carotid Body Lobules

- Fig. 1. Carotid body tissue showing different cell types. Small and large chief cells are to be noted. Regaud's fluid, Picro-ponceau, X470.
- Fig. 2. Carotid body lobules exhibiting large and small chief cells. A blood vessel is seen on the right. Regaud's fluid, H & E, X1050.
- Fig. 3. Carotid body lobule and the interlobular connective tissue and blood vessels. Large and rounded chief cells (type I) with foamy cytoplasm, and small and irregular sustentacular (type II) cells are demonstrated. Formol-saline, H & E, X1050.

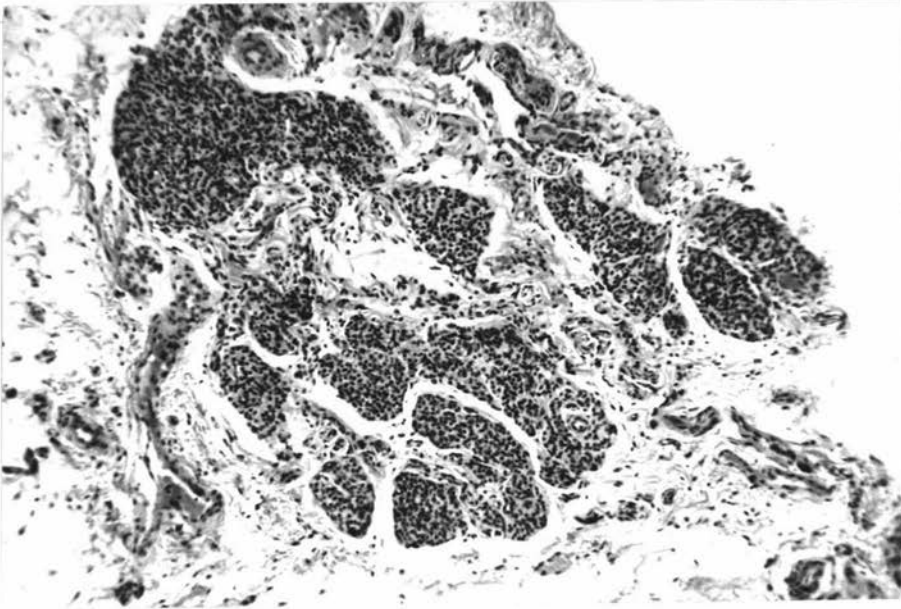


Fig.1.

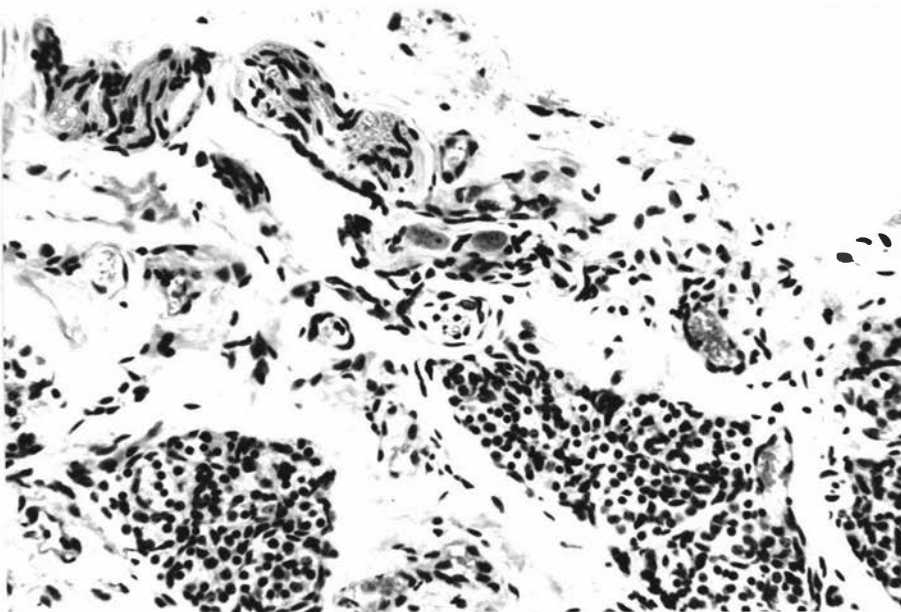


Fig.2.

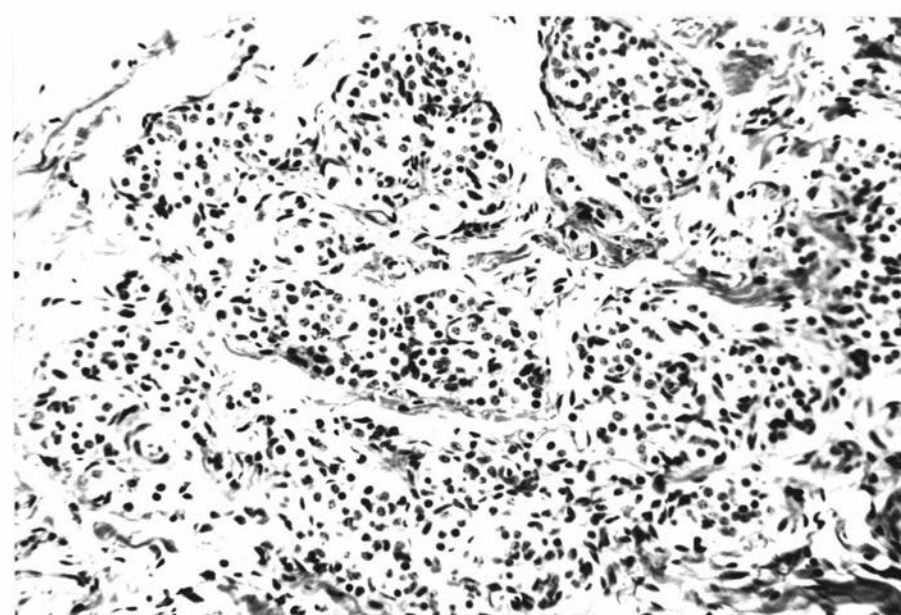


Fig.3.

PLATE IV.

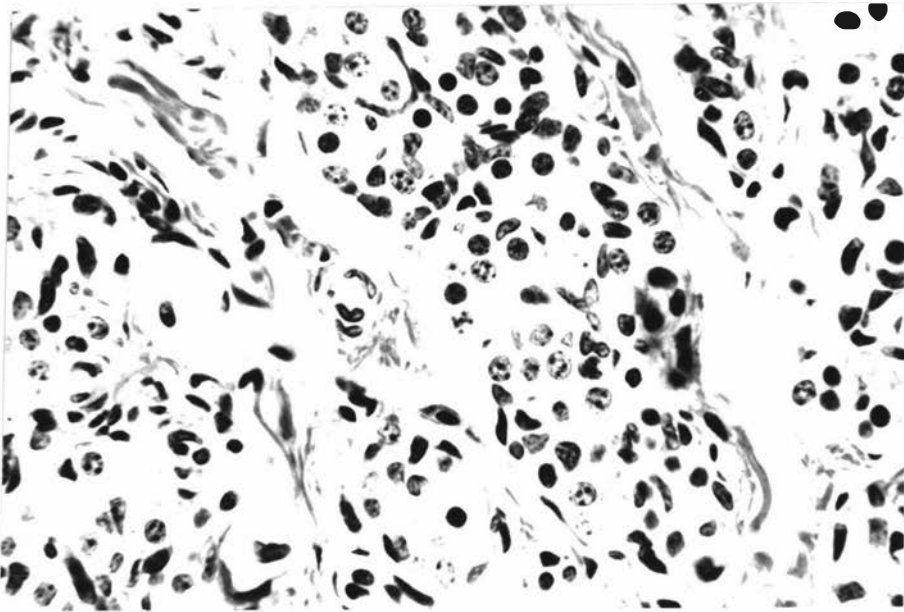


Fig.1.

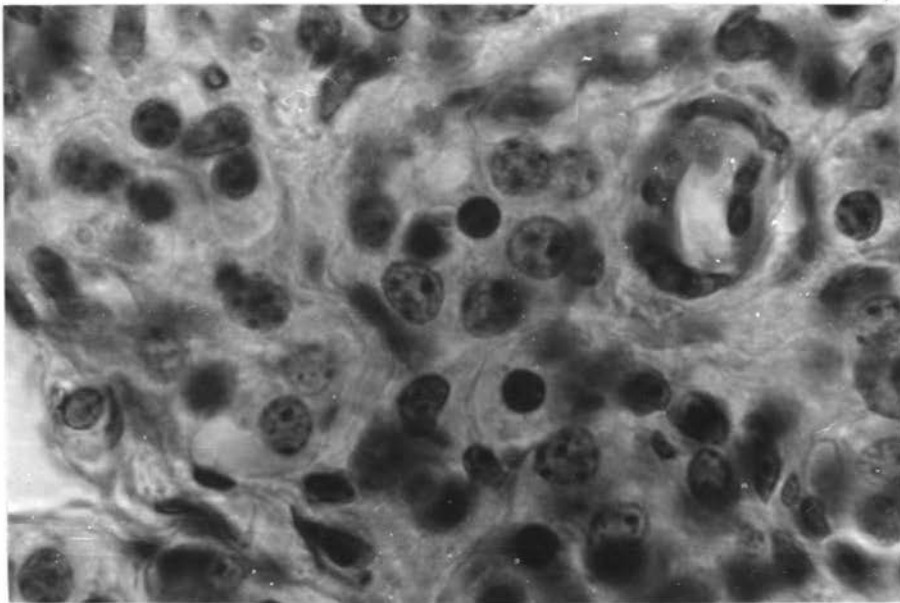


Fig.2.

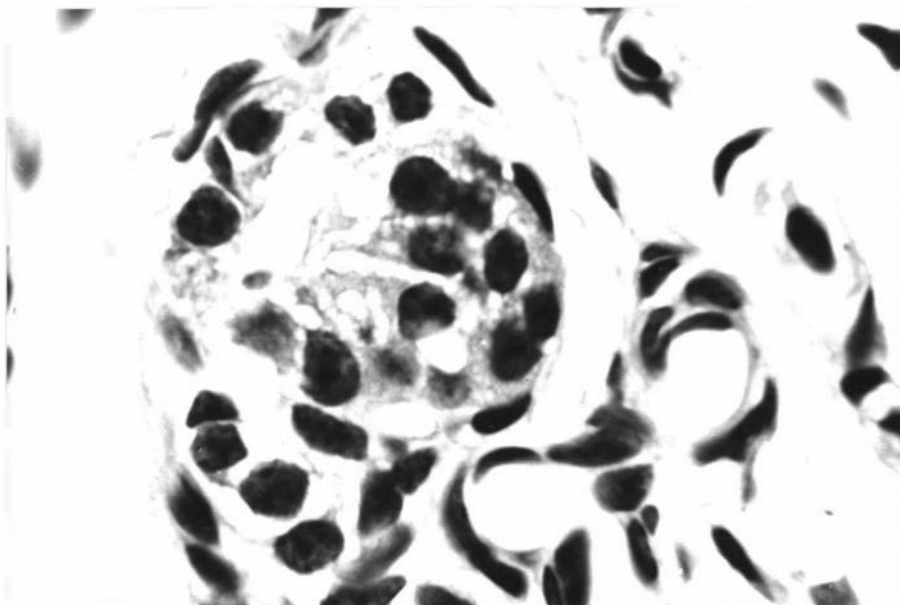


Fig.3.

Key to Plate V.

Innervation of the Normal Carotid Body

- Fig. 1. Most of the large diameter nerve fibres are demonstrated. Entry of nerve fibres through the capsule at various points of the organ is noted. Bouin's fluid, Romanes' silver chloride, X74.
- Fig. 2. Carotid body from Fig. 1, left hand side upper portion. One large carotid body vein emerges from the thin capsule. Some nerve fibres are seen associated with this emergent vein. X190.
- Fig. 3. Nerve fibres of the carotid body. Small and large (regularly beaded) nerve fibres are seen at the periphery of the carotid body. Formol-saline, Romanes' silver chloride, X190.

Key to Plate VI.

Innervation of the Normal Carotid Body Lobules

- Fig. 1. Large diameter nerve fibres are seen in the interlobular tissue of the organ. Formalin, Holmes' silver, X470.
- Fig. 2. A large diameter nerve fibre is seen on the upper left hand side, and a small and long nerve fibre ends in relation to the glomic cell. Formol-saline, Romanes' silver chloride, X470.
- Fig. 3. Innervation of accessory glomic tissue. Large diameter nerve fibres supplying isolated glomic tissue. Formol-saline, Romanes' silver chloride, X470.

PLATE V.

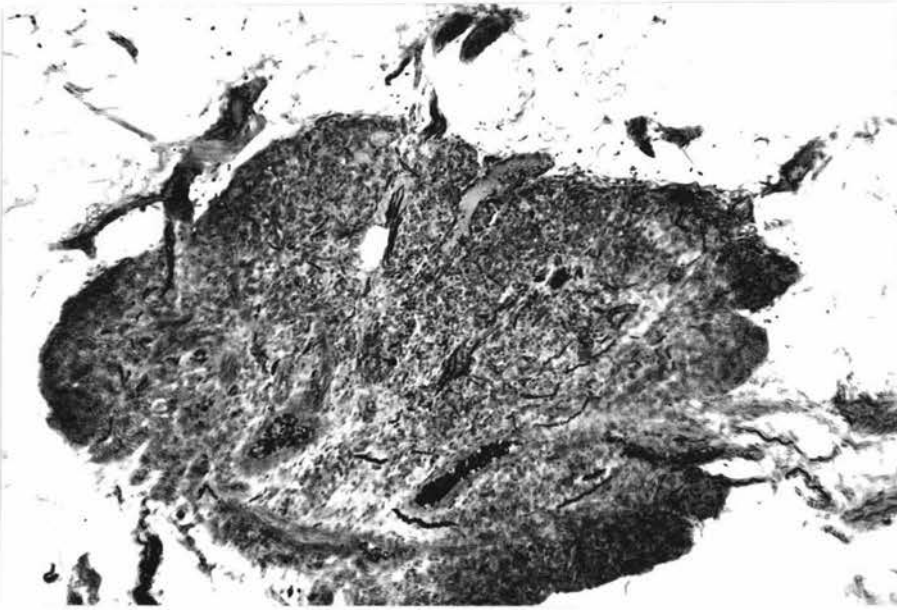

Fig.1.

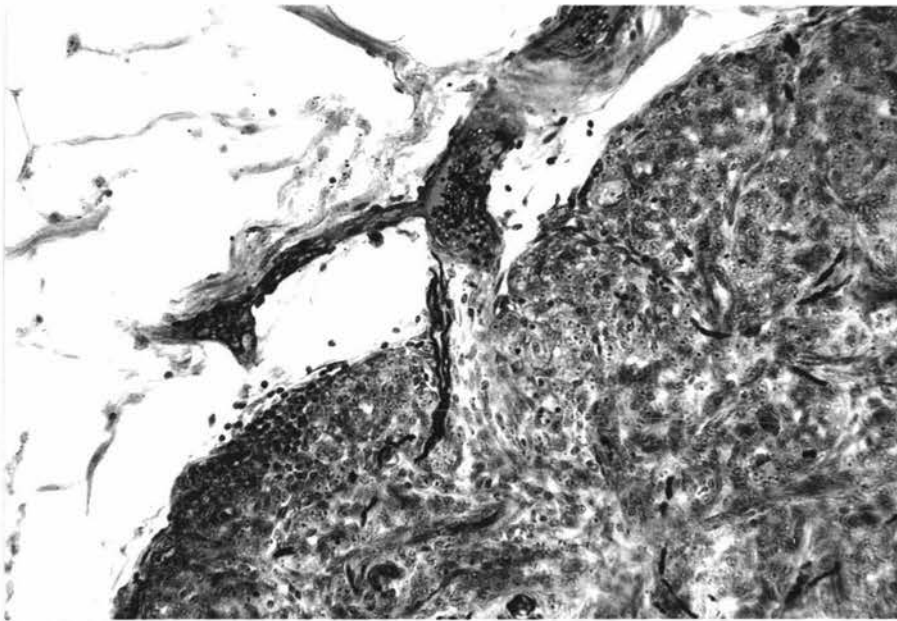


Fig.2.

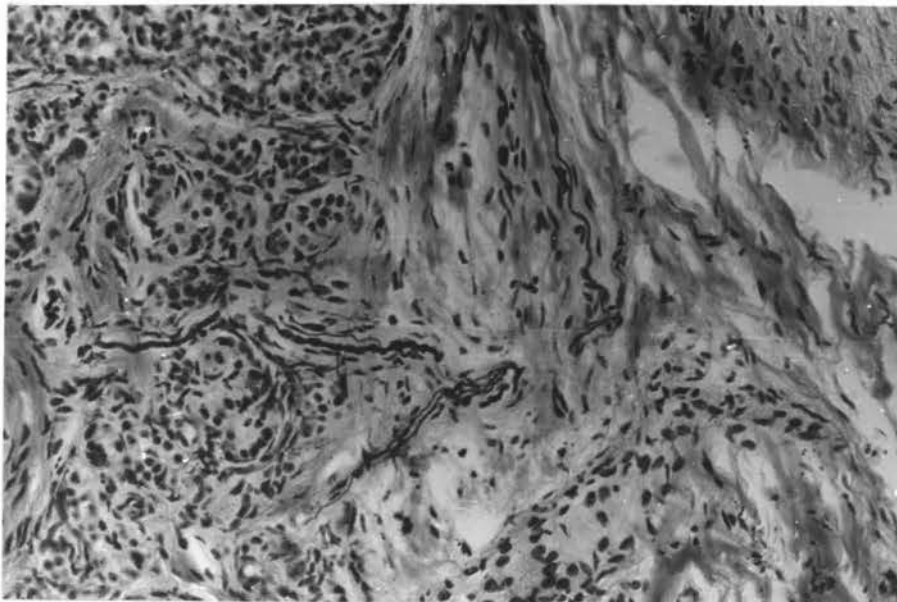


Fig.3.

PLATE VII.

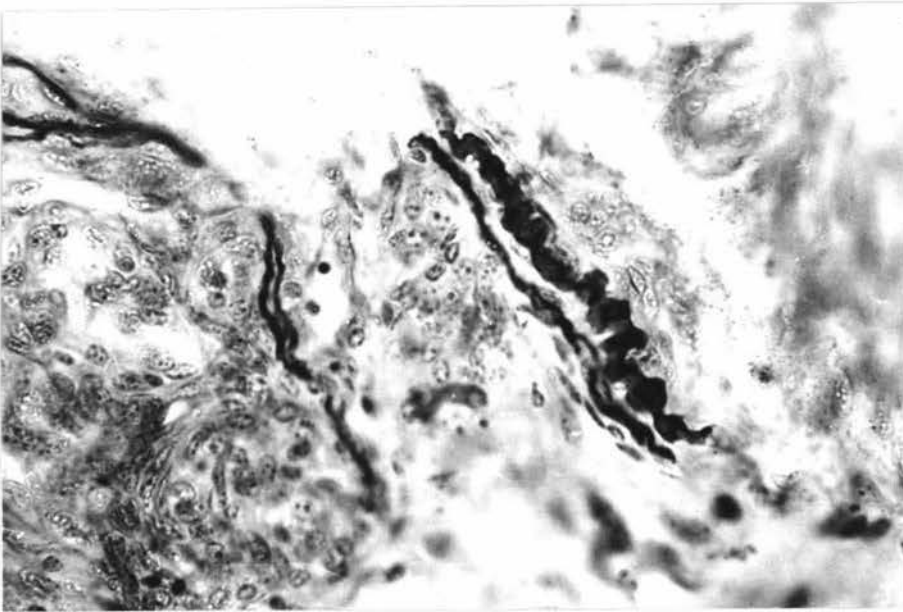


Fig.1.

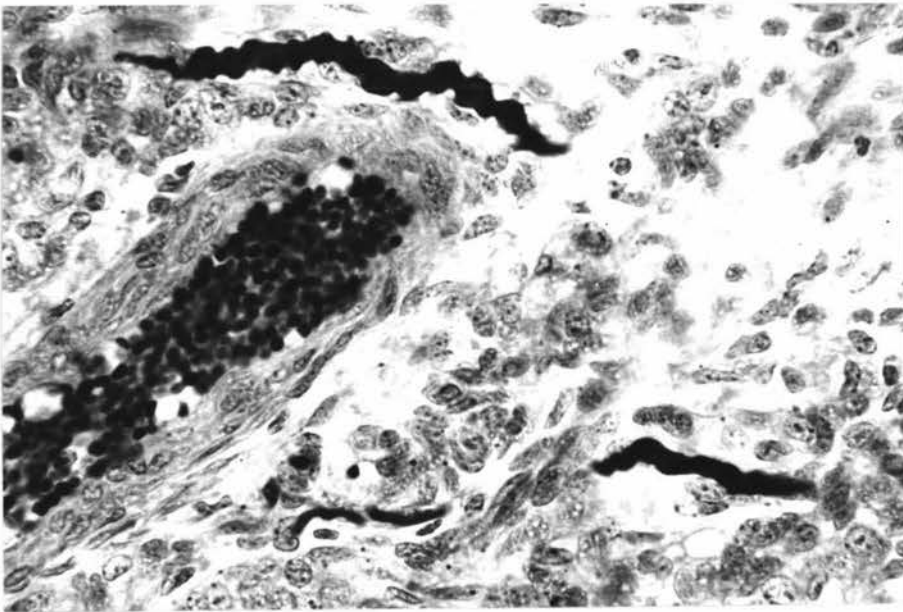


Fig.2.

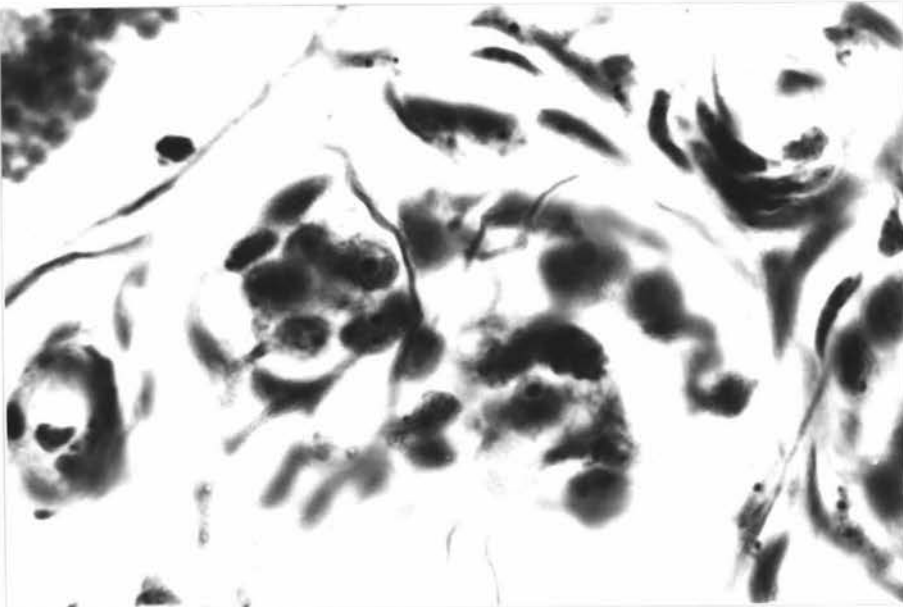


Fig.3.

Key to Plate VII.

Relationships of Nerve Fibres to the Carotid Body Cells

- Fig. 1. A large (regularly beaded) and small diameter nerve fibres passing from the carotid body to the carotid sinus. Formol-saline, Ungewitter's urea-silver nitrate, X470.
- Fig. 2. Relationship of the large diameter (beaded) nerve fibres to the carotid body cells. A small blood vessel is seen on the right hand side. Bouin's fluid, Romanes' silver chloride, X470.
- Fig. 3. Relationship of the small diameter nerve fibres to the glomic cells. Fibres end very close to the chief cells. Formol-saline, Romanes' silver chloride, X1050.

Key to Plate VIII.

Structure of the Carotid Body Artery and Vein

- Fig. 1. Elastic tissue of the artery of the carotid body. The artery in the carotid body substance exhibits 2-6 layers of elastic fibres, and a thin adventitia. Formol-saline, Orcein-ponceau, X470.
- Fig. 2. Innervation of the artery of the carotid body. A fine nerve fibre is seen in the arterial wall. Formol-saline, Romanes' silver chloride, X470.
- Fig. 3. Innervation of the vein of the carotid body. Comparatively thick nerve fibres are demonstrated in the vascular wall. Bouin's fluid, Holmes' silver, X470.

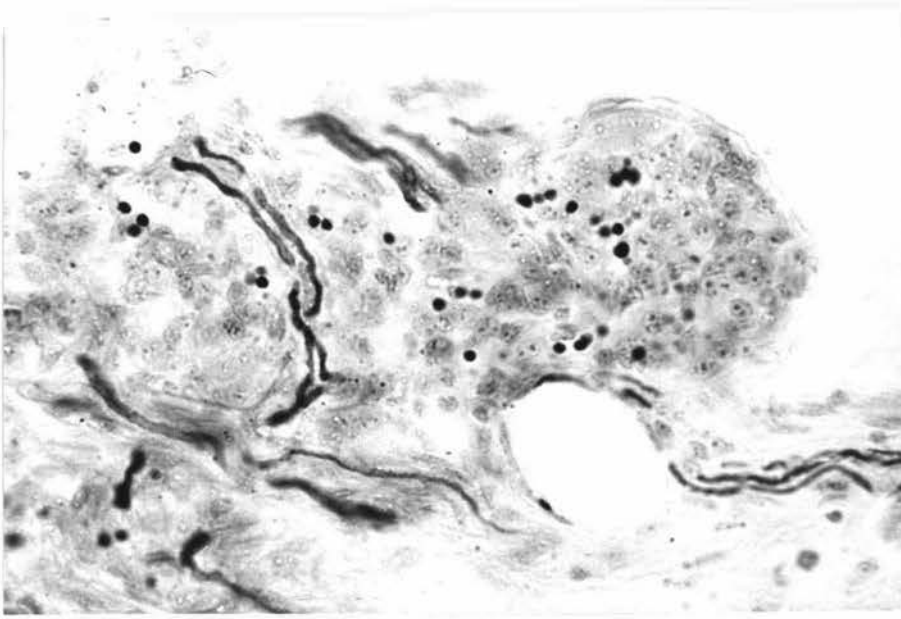


Fig.1.

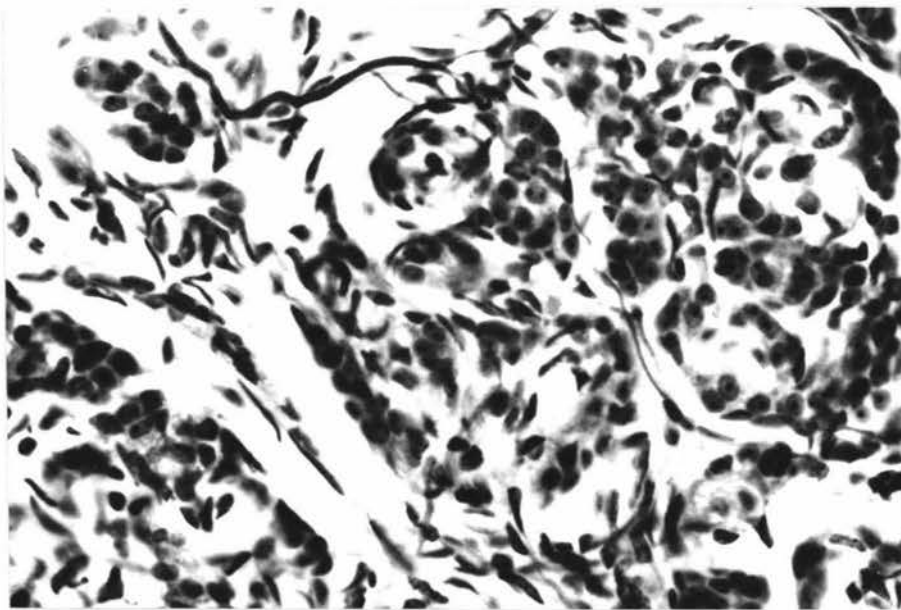


Fig.2.

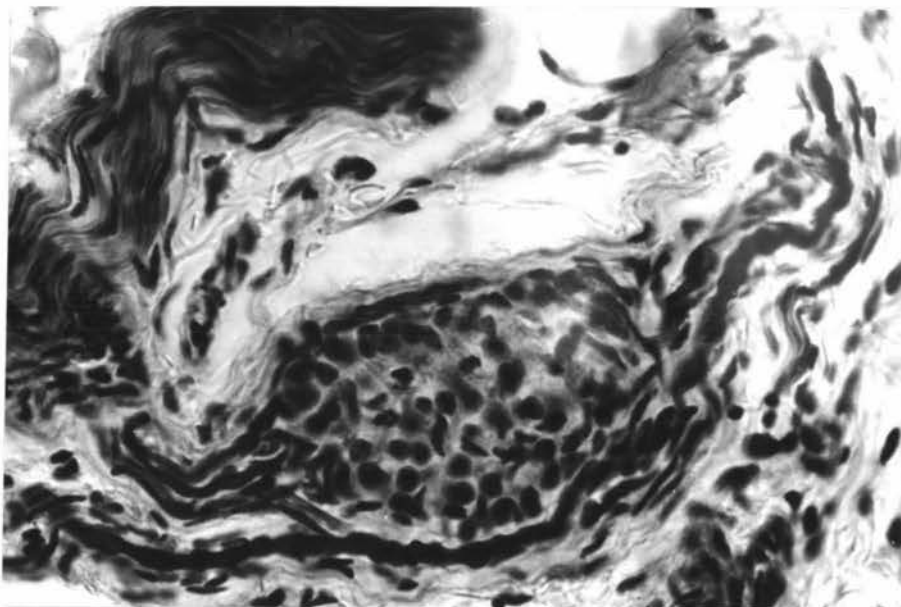


Fig.3.

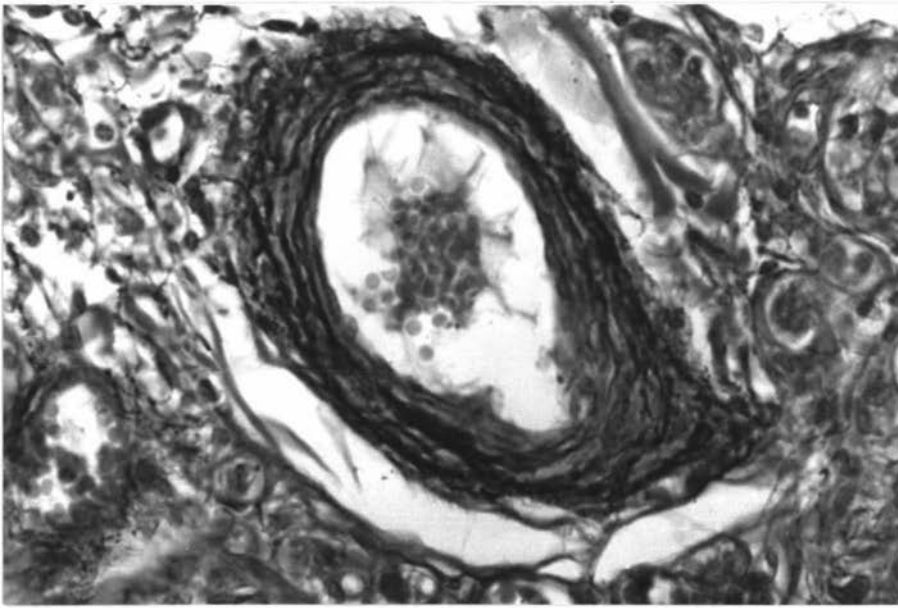


Fig.1.

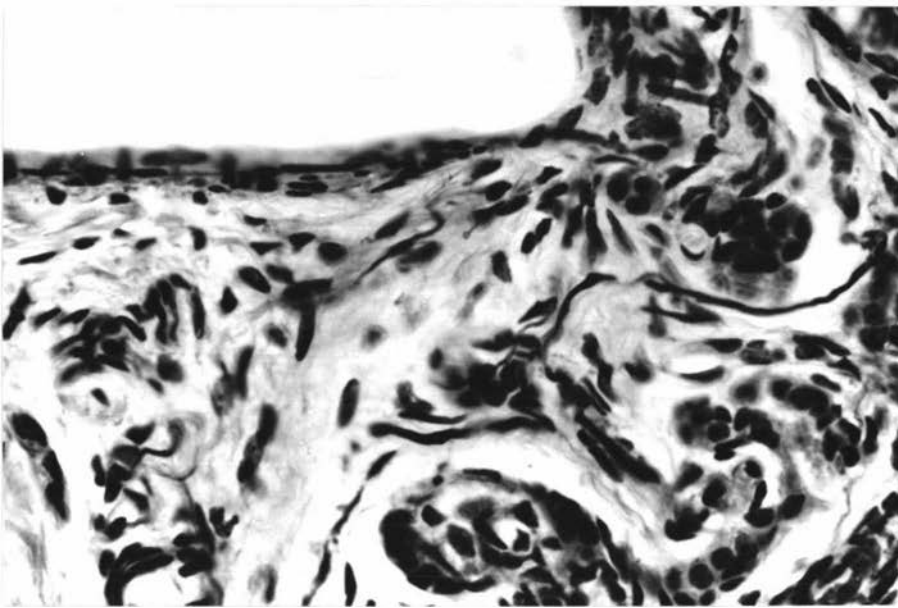


Fig.2.

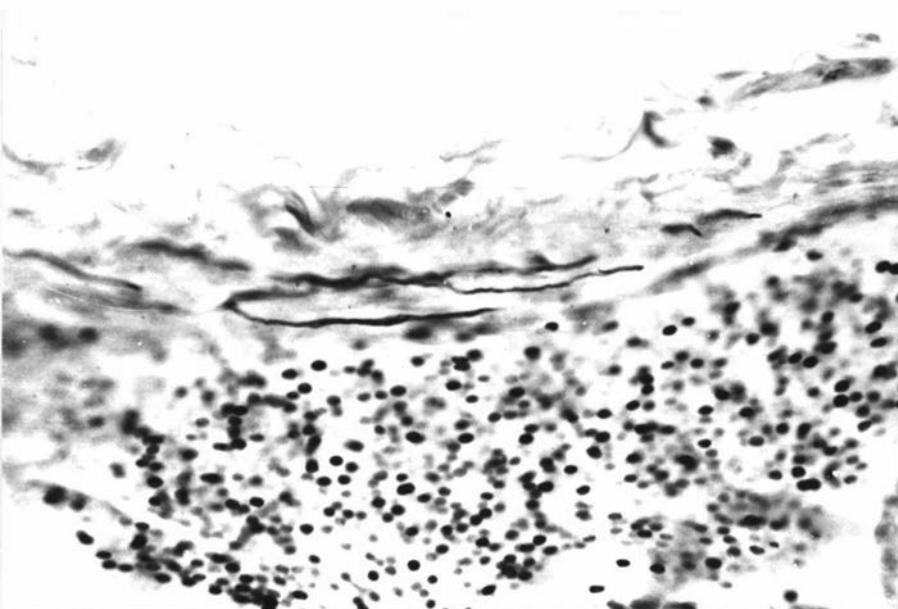


Fig.3.

Key to Plate IX.

Structure of the Denervated Carotid Body

- Fig. 1. Carotid body after sectioning of the carotid sinus nerve. No degenerated nerves are demonstrable. Hanly'n's (1957) method, X190. **Perfused**
- Fig. 2. Carotid body (on the right) and carotid sinus (on the left) after sectioning of the carotid sinus nerve. No detectable morphological changes are observed, except proliferation of the connective tissues of the carotid body. Formol-saline, H & E, X190.
- Fig. 3. Carotid body after sectioning of the carotid sinus nerve. Proliferation of the interlobular connective tissues is prominent. Formol-saline, H & E, X190.

Key to Plate X.

Structure of the Denervated Carotid Body

- Fig. 1. Carotid body after sectioning of the carotid sinus nerve. Chief (type I) cells are seen at the centre. Vacuolation of the cytoplasm is probably due to formol-saline fixation. H & E, X1050.
- Fig. 2. The carotid body (Fig. 1) is practically devoid of nerve fibres after division of the carotid sinus nerve; however, the morphology of the chief cell nuclei remains unchanged. Formol-saline, Romanes' silver chloride, X1050.
- Fig. 3. Carotid body after sectioning of the carotid sinus nerve. Except for a fine nerve fibre in the interlobular connective tissue, which apparently supplies the carotid body blood vessel, there are virtually no nerve fibres in the carotid body. Formol-saline, Romanes' silver chloride, X190.

PLATE IX.



Fig.1.

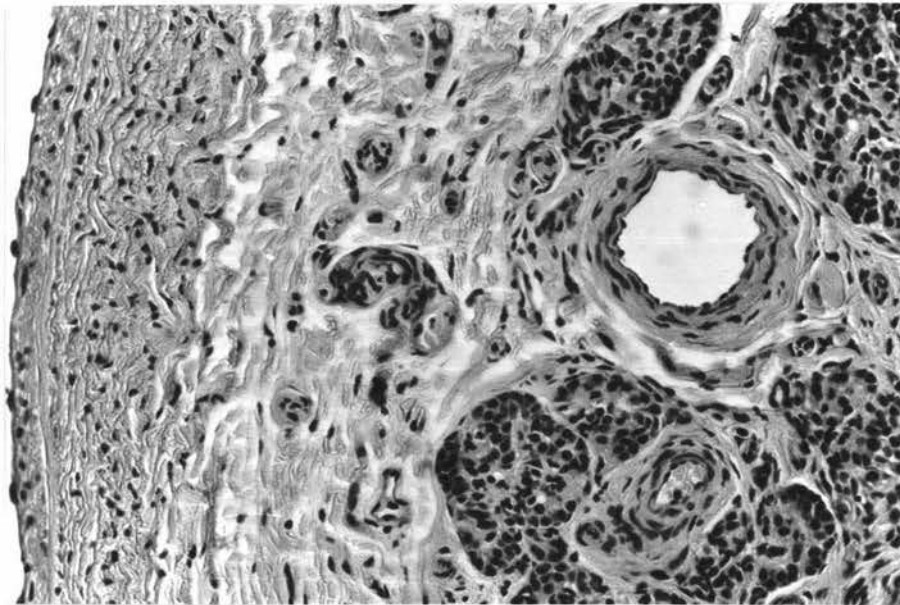


Fig.2.

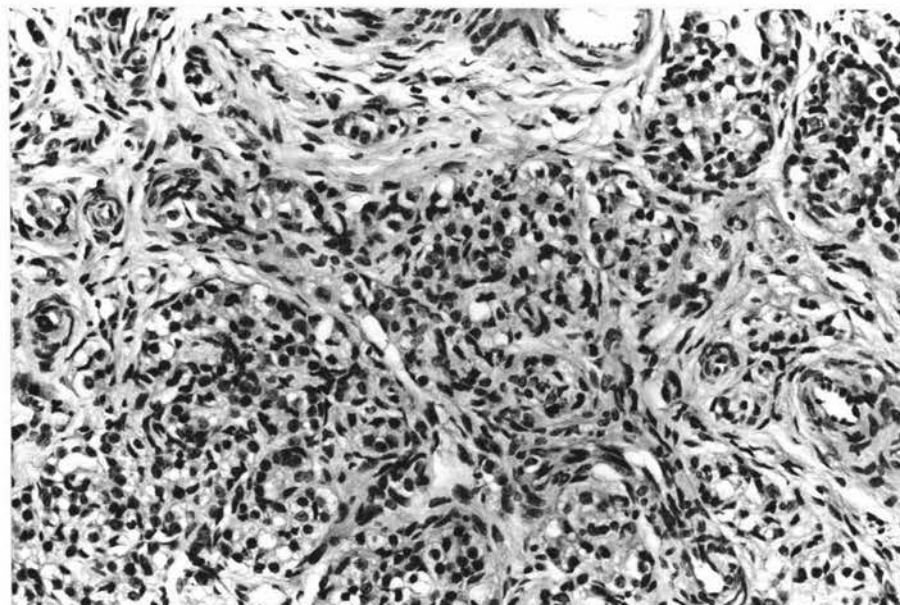


Fig.3.

PLATE X.

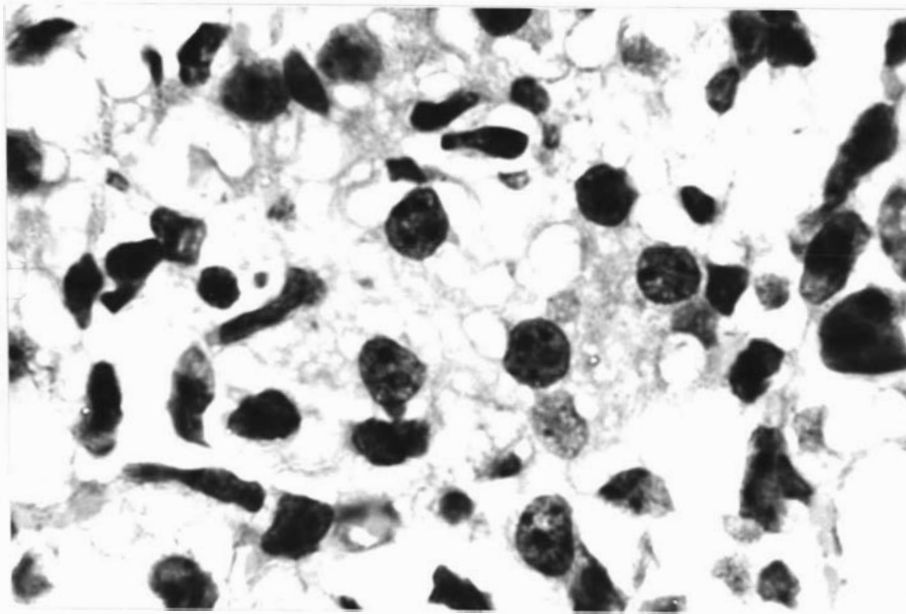


Fig.1.

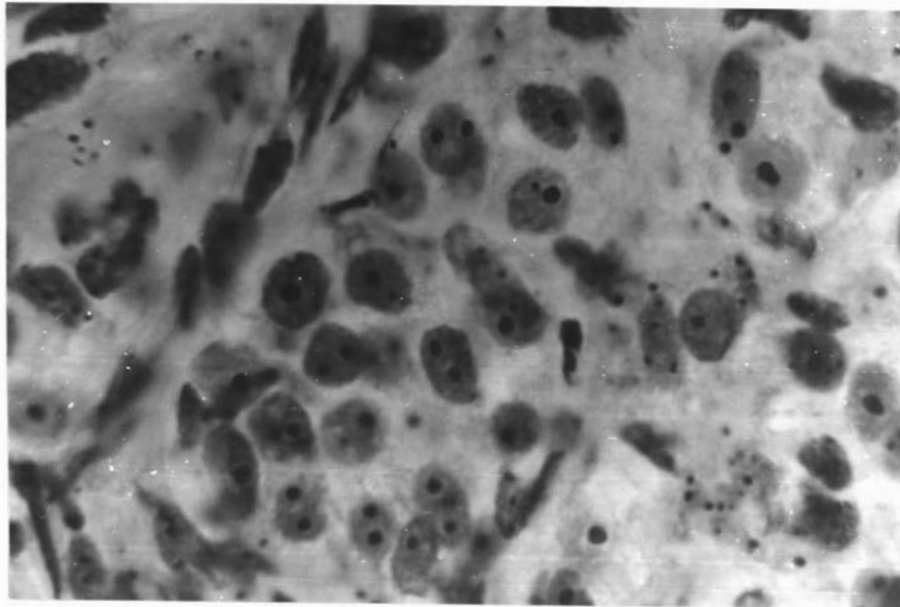


Fig.2.

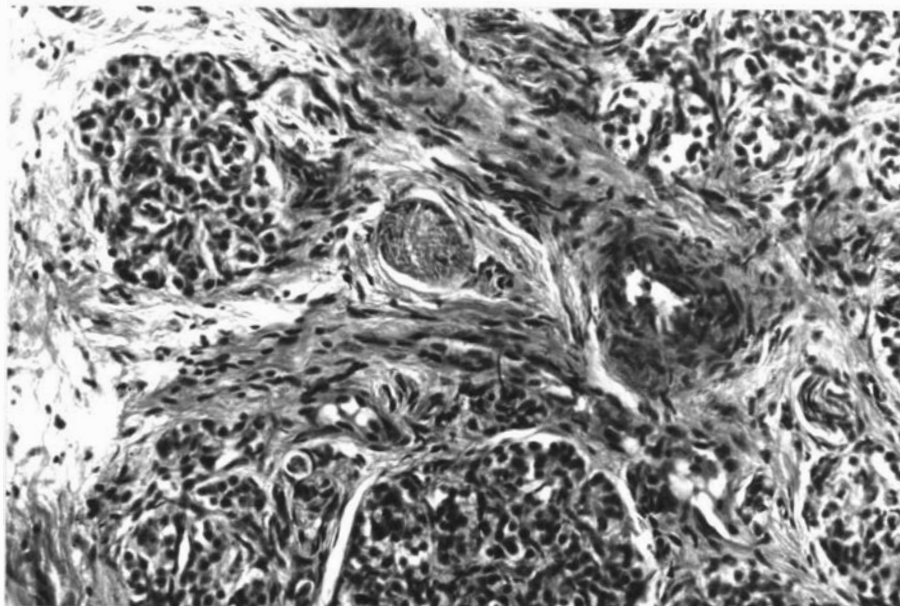


Fig.3.

Key to Plate XI.

Structure of the Sympathectomized Carotid Body

- Fig. 1. Carotid body after cranial cervical ganglionectomy. Dilated carotid body blood vessels are observed. Formol-saline, Picro-ponceau, X190.
- Fig. 2. Marked dilatations of the carotid body blood vessels and sinusoids after sectioning of the external carotid nerve. Formol-saline, H & E, X470.
- Fig. 3. No detectable morphological changes are apparent in the carotid body chief cells. Prominent and distended sinusoids are demonstrated. Formol-saline, H & E, X1050.

Key to Plate XII.

Innervation of the Sympathectomized Carotid Body

- Fig. 1. Intact unipolar ganglion cells in the nerve trunks of the carotid body after cranial cervical ganglionectomy. Formol-saline, Romanes' silver chloride, X470.
- Fig. 2. Intact nerve fibres of the carotid body after cranial cervical ganglionectomy. The predominance of glossopharyngeal fibres is demonstrated. Romanes' silver chloride, X190.
- Fig. 3. Innervation of the carotid body chief (type I) cells after sectioning of the external carotid nerve. The nerve fibres usually terminate in close relationship to the chief (type I) cells. Formol-saline, Romanes' silver chloride, X1050.

PLATE XI

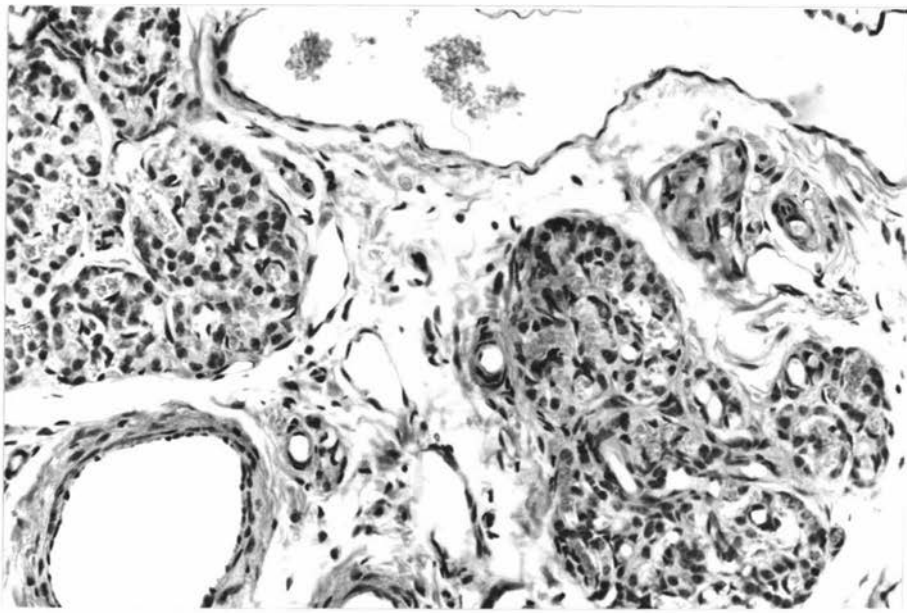


Fig.1.

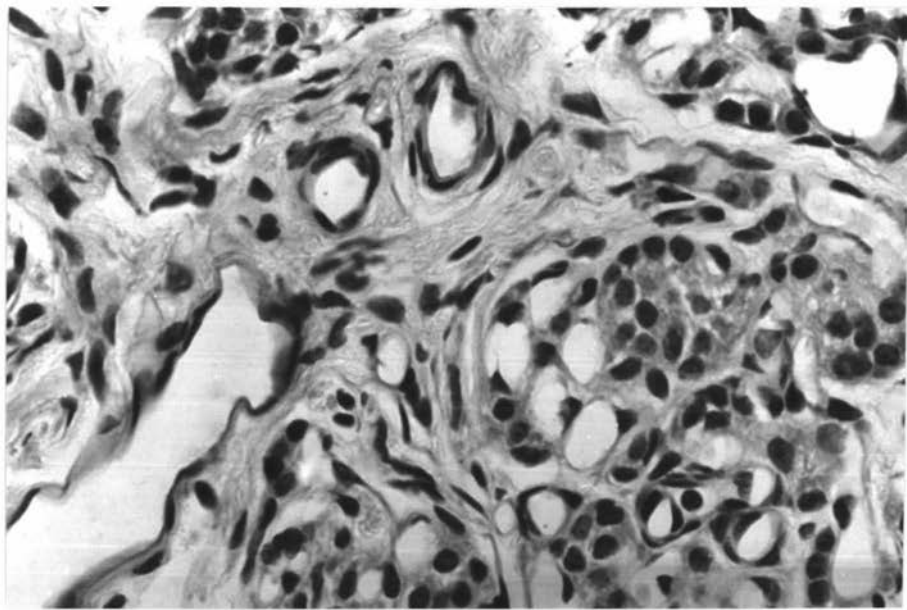


Fig.2.

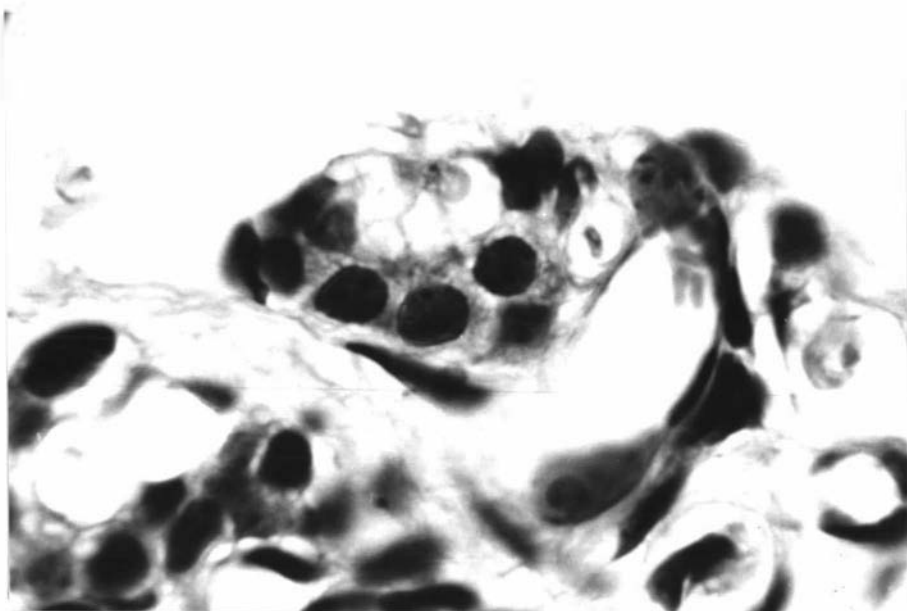


Fig.3.

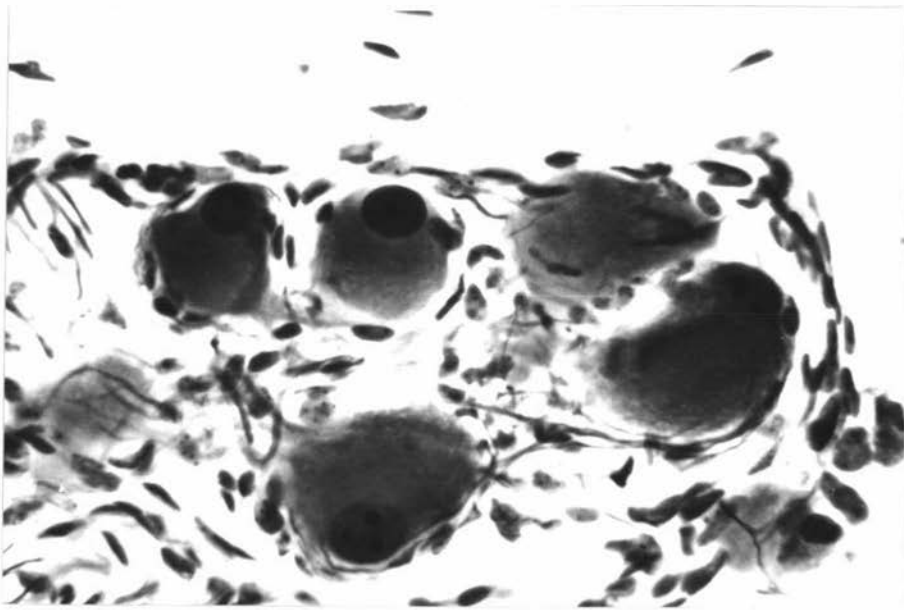


Fig.1.

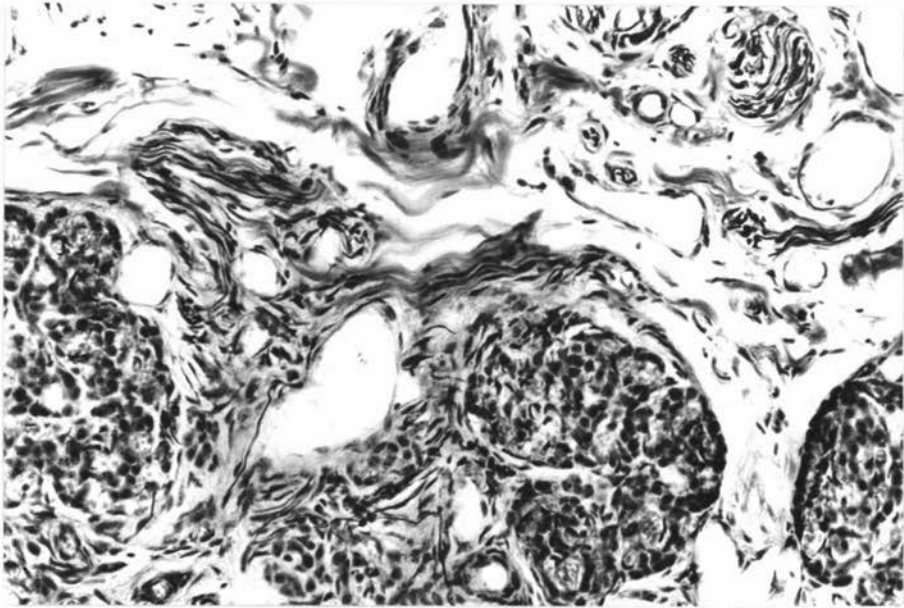


Fig.2.

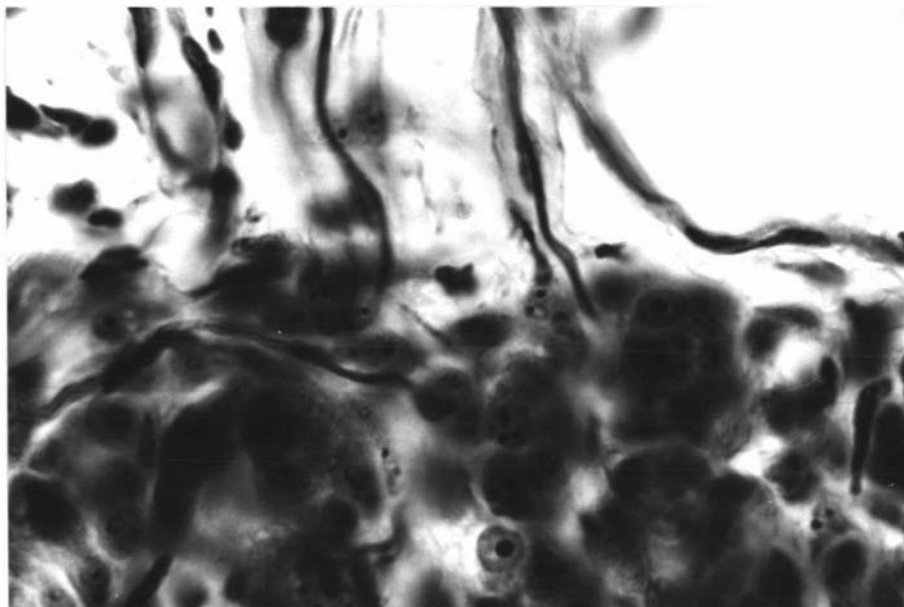


Fig.3.

Key to Plate XIII.

Structure of the Normal Carotid Sinus

Fig. 1. Junction of the carotid sinus (left hand side) and the common carotid artery (right hand side). The transition is abrupt where the circular elastic fibres of the carotid sinus and the smooth muscle fibres of the common carotid artery are distinctly separated. However, the longitudinal elastic fibres of the carotid sinus proceed into the common carotid adventitia. Formalin, H & E, X50.

Fig. 2. Junction between the elastic portion (carotid sinus) and the muscular portion of the occipital artery. At the beginning of the muscular portion of the occipital artery, the smooth muscle fibres appear between the elastic fibres. H & E, X190. **Formalin**

Fig. 3. Elastic tissue of the carotid sinus. Numerous layers of elastic fibres of the carotid diverticulum are demonstrated. The carotid sinus is predominantly of the elastic type. Verhoeff's elastin stain, X74. **Formalin**

PLATE XIII.

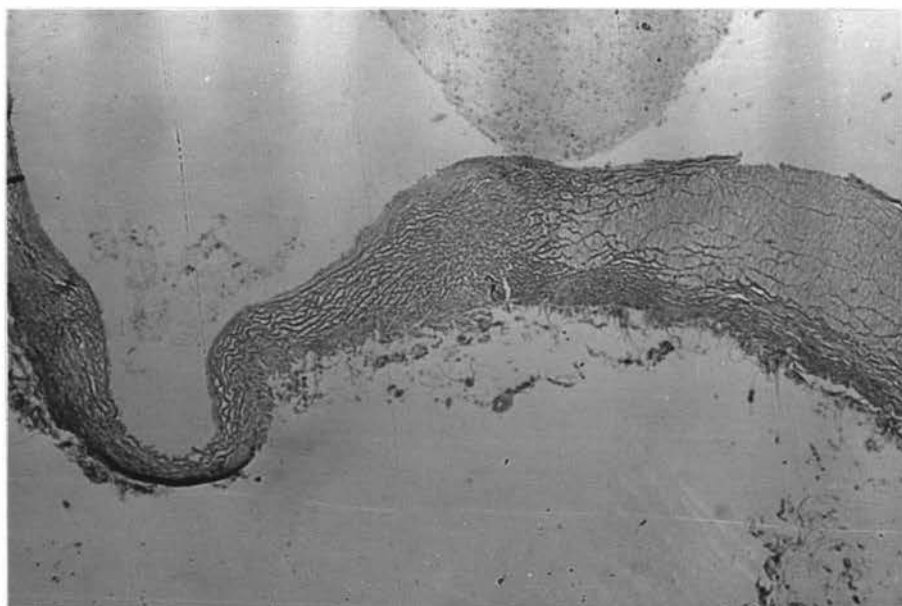


Fig.1.

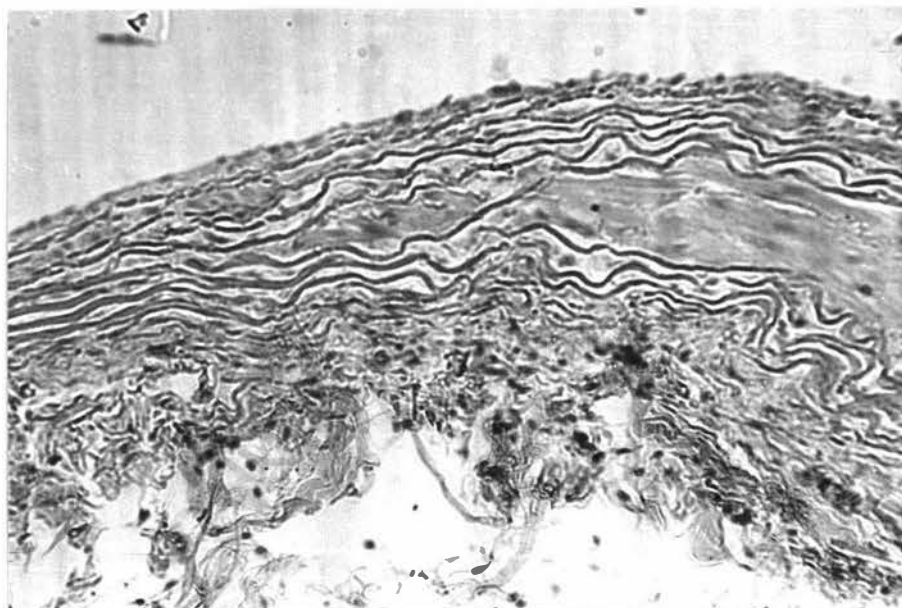


Fig.2.

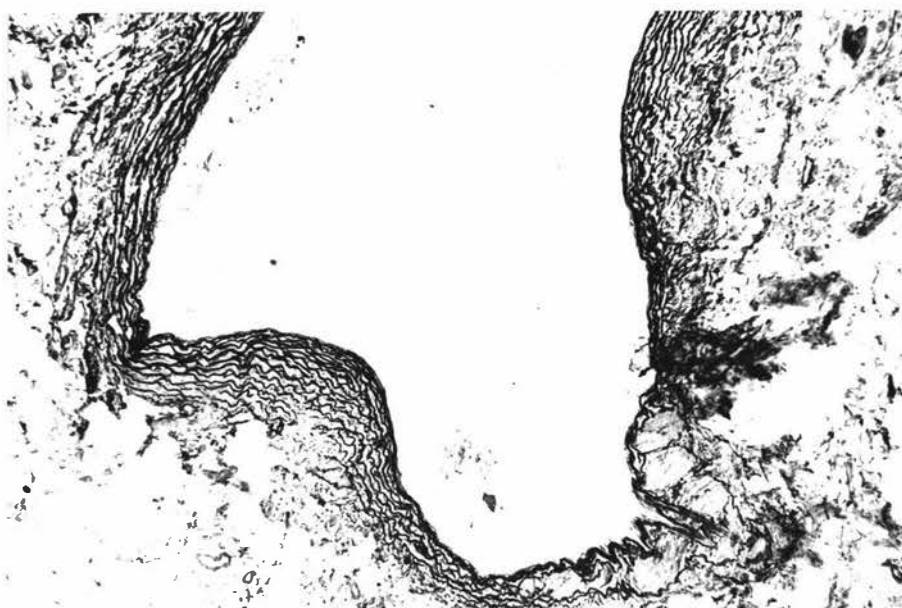


Fig.3.

Key to Plate XIV.

Structure of the Denervated Carotid Sinus and Occipital Artery

- Fig. 1. Carotid sinus after sectioning of the carotid sinus nerve. Degenerated nerves are stained by Hamlyn's (1957) method. This method is not suitable for staining nerve fibres in the vascular wall. X74. Frozen
- Fig. 2. Control carotid sinus stained by the method of Guillery et al. (1961). Normal nerve fibres are seen on the bottom right hand side. This illustrates that this method in the carotid sinus, stains normal nerve fibres and is thus unsuitable as a specific stain for degenerated nerve fibres. X190. Perfused neutral formal saline
- Fig. 3. Nerves in the wall of the occipital artery (muscular type) after sectioning of the external carotid nerve. Frozen section, formol-saline, Romanes' silver chloride. X 470

Key to Plate XV.

Structure of the Occipital and Internal Carotid Arteries

- Fig. 1. Occipital artery (muscular portion). Thick tunica media with few elastic fibres and a thinner tunica adventitia with elastin and collagen fibres. Formol-saline, H & E, X74.
- Fig. 2. Patent internal carotid artery. A very thick tunica adventitia and a thinner tunica media. Elastic fibres are seen in the medioadventitial border. Bouin's fluid, Orcein, X74.
- Fig. 3. Nerve structures in the wall of the internal carotid artery. Formol-saline, Romanes' silver chloride, X470.

PLATE XIV.

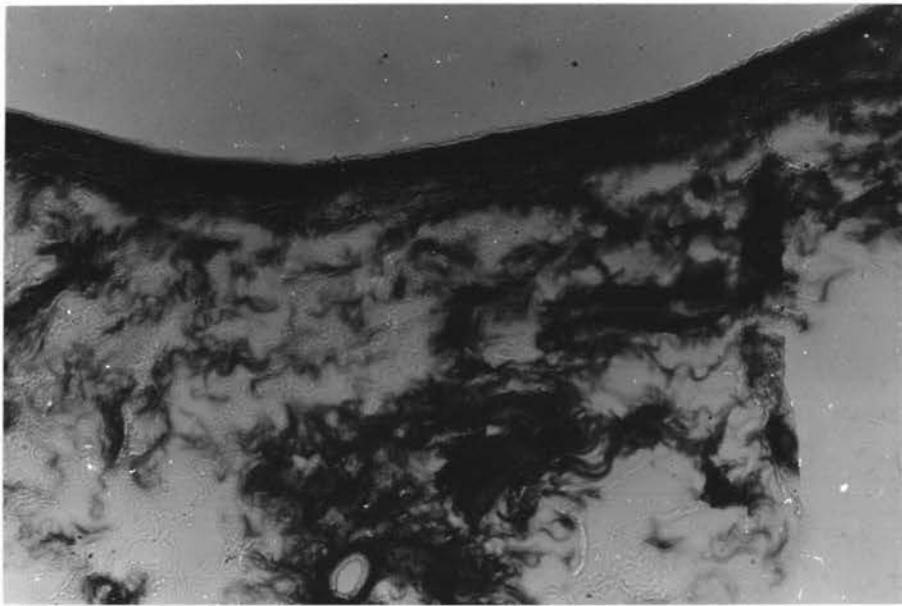


Fig.1.

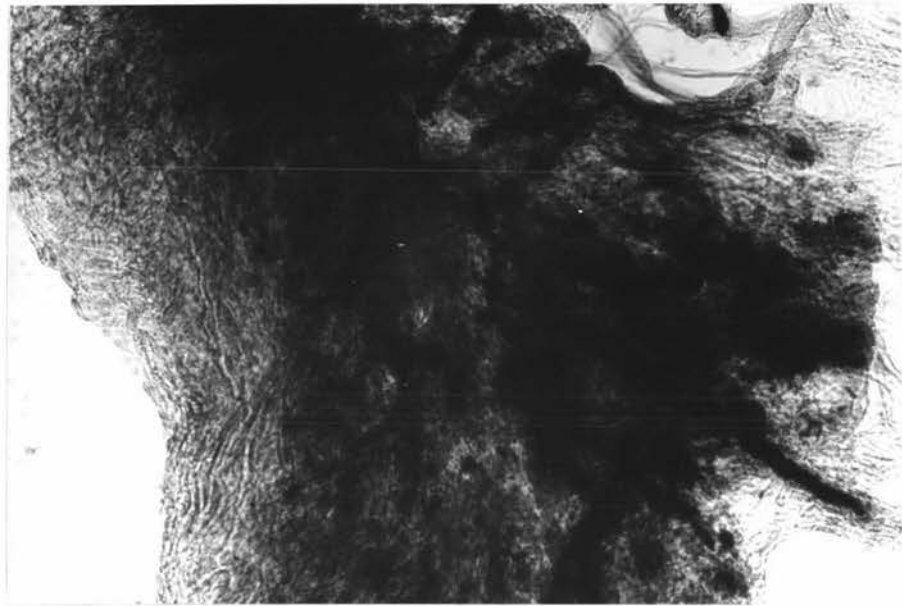


Fig.2.

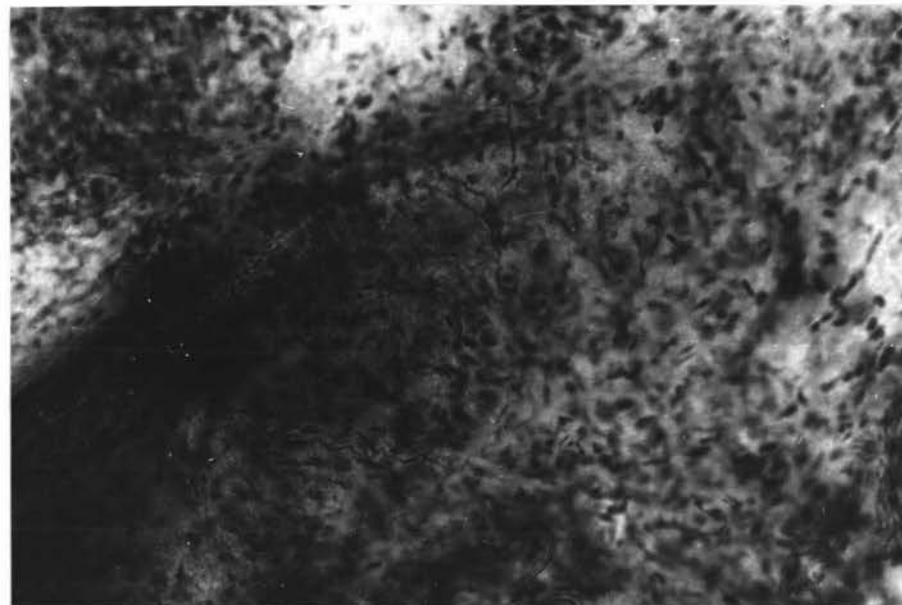


Fig.3.

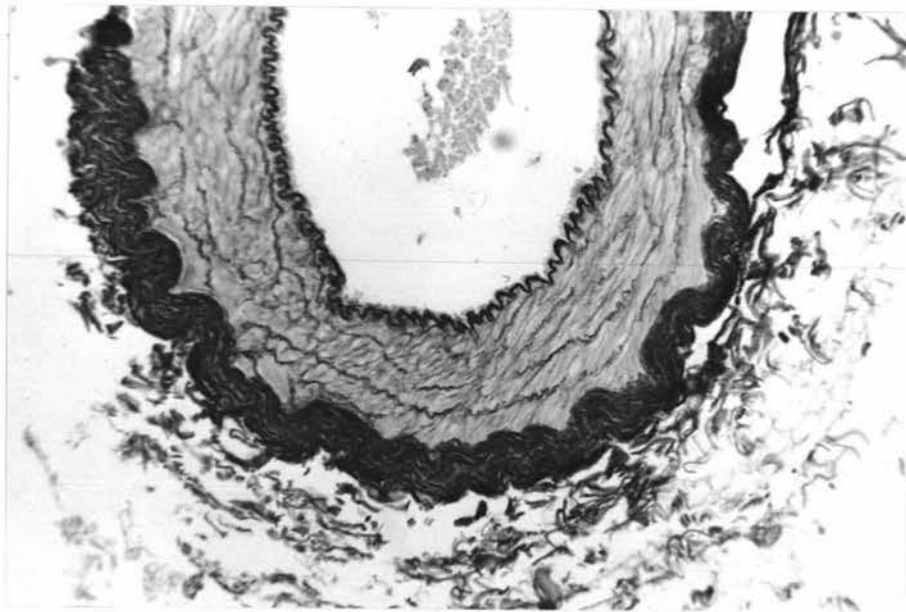


Fig.1.

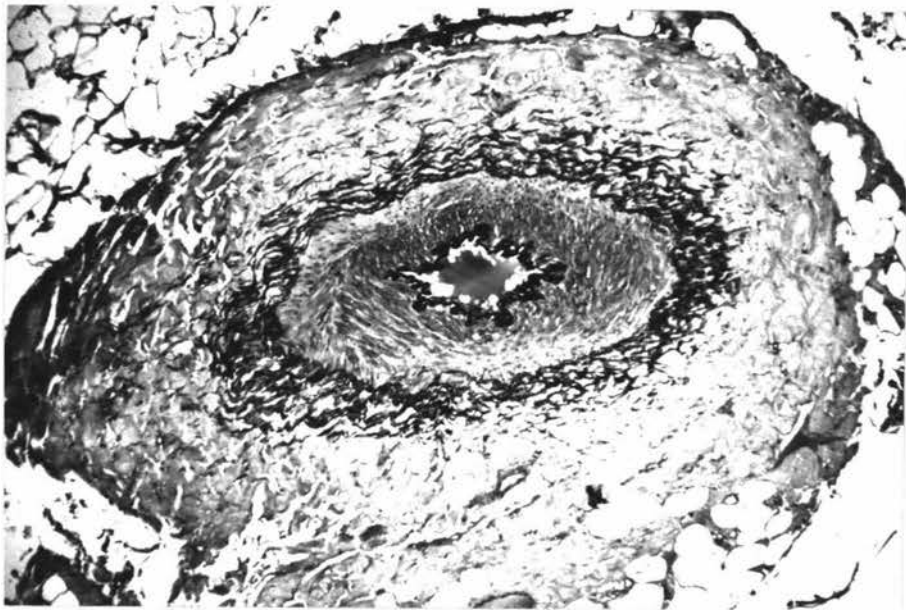


Fig.2.

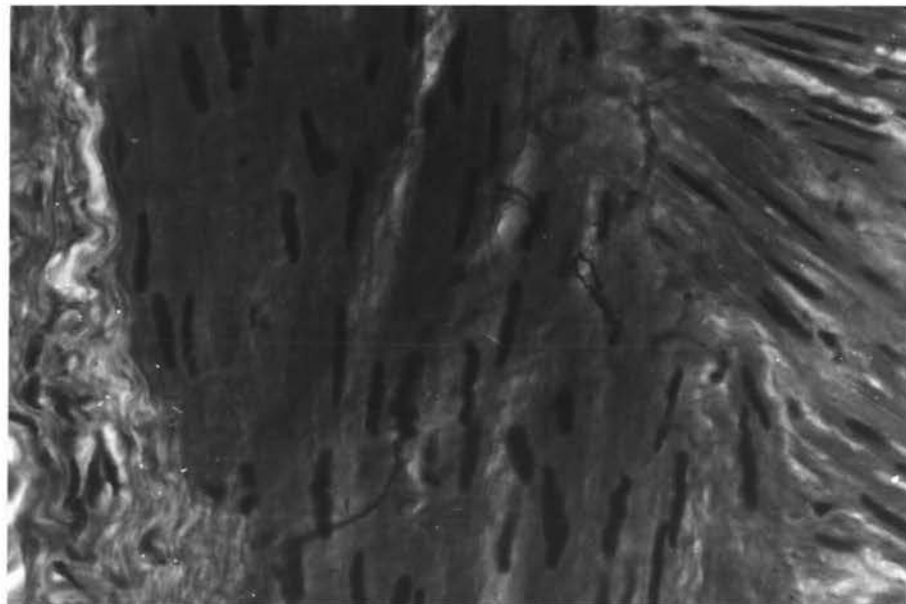


Fig.3.

Key to Plate XVI.

Structure of the Denervated Carotid Sinus

- Fig. 1. Carotid sinus after sectioning of the carotid sinus nerve. No detectable morphological changes are seen. Formol-saline, H & E, X190.
- Fig. 2. Carotid sinus after division of the carotid sinus nerve. The sinus wall is apparently normal. Formol-saline, Gomori's aldehyde fuchsin, X190.
- Fig. 3. Carotid sinus after cranial cervical ganglionectomy. Intact nerve fibres of glossopharyngeal origin are seen, on the left hand side, approaching the adventitia. Dilated vessels in the adventitia are demonstrated. Formol-saline, Romanes' silver chloride, X470.

Figs 1 and 2 are from the same animal. Fig 3 from a different animal.

Key to Plate XVII.

Structure of the Normal and Sympathectomized Carotid Sinus

- Fig. 1. Normal carotid sinus. The nerve fibres of the carotid sinus nerve (lower right hand side) are seen coursing in the adventitia. Fibres can be traced up to medioadventitial border. These fibres are markedly degenerated one month after sectioning of the carotid sinus nerve. Romanes' silver chloride, X190.
- Fig. 2. Normal carotid sinus. The terminal nerve fibres of the carotid sinus nerve are seen in the deeper adventitia and in the superficial media. Romanes' silver chloride, X470.
- Fig. 3. Carotid sinus one month after cranial cervical ganglionectomy. The intact nerve fibres of the carotid sinus nerve are seen in the superficial and deeper adventitia. Dilated blood vessels are observed in the adventitia. Romanes' silver chloride, X470.

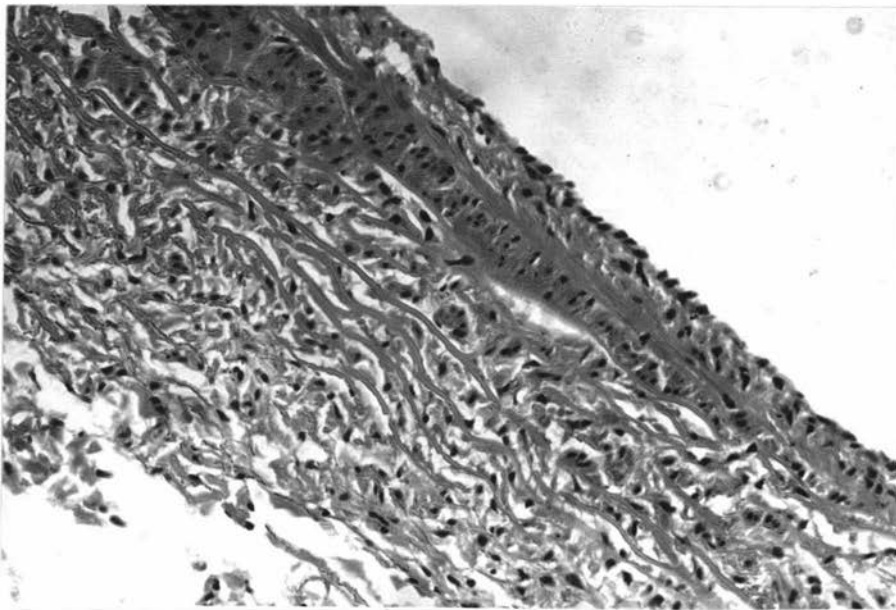


Fig. 1.

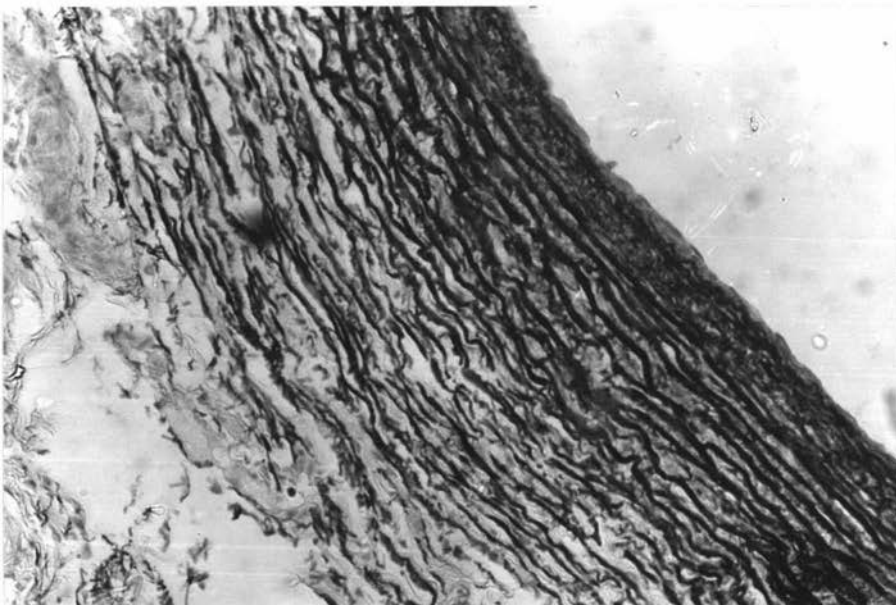


Fig. 2.

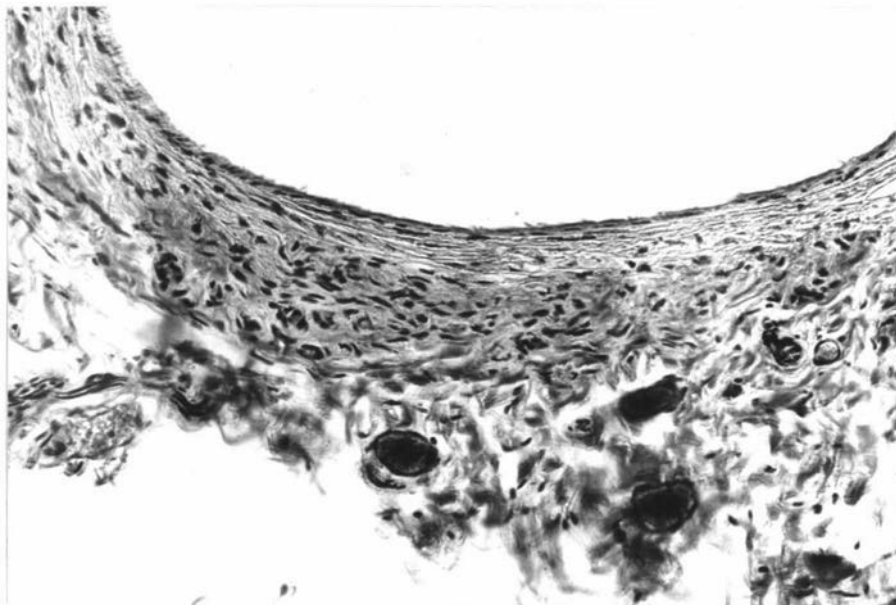


Fig. 3.

PLATE XVII.

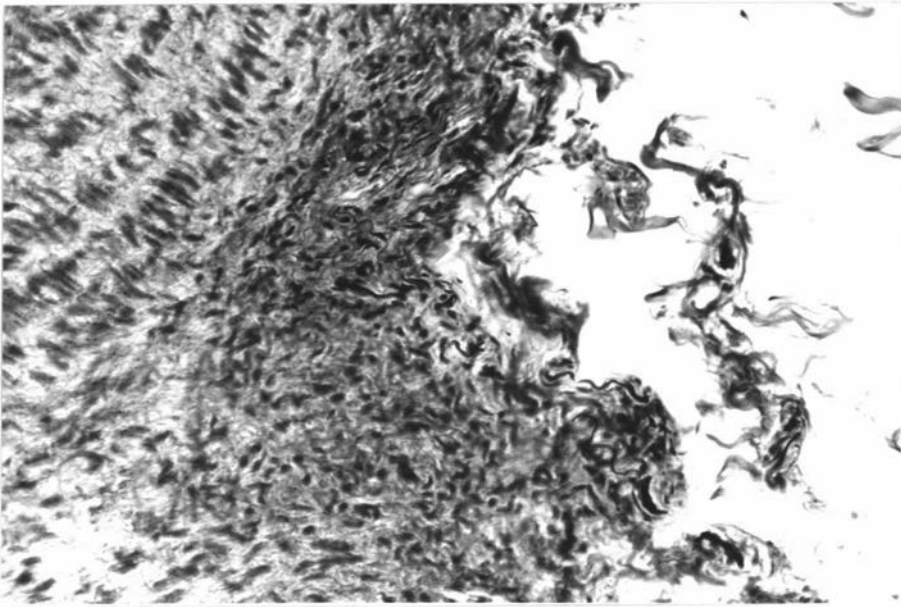


Fig. 1.

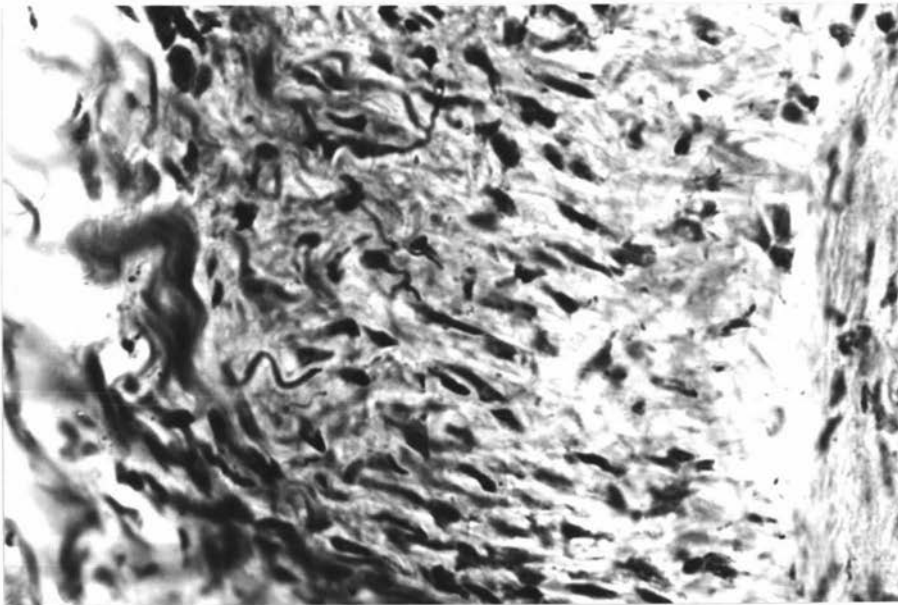


Fig. 2.

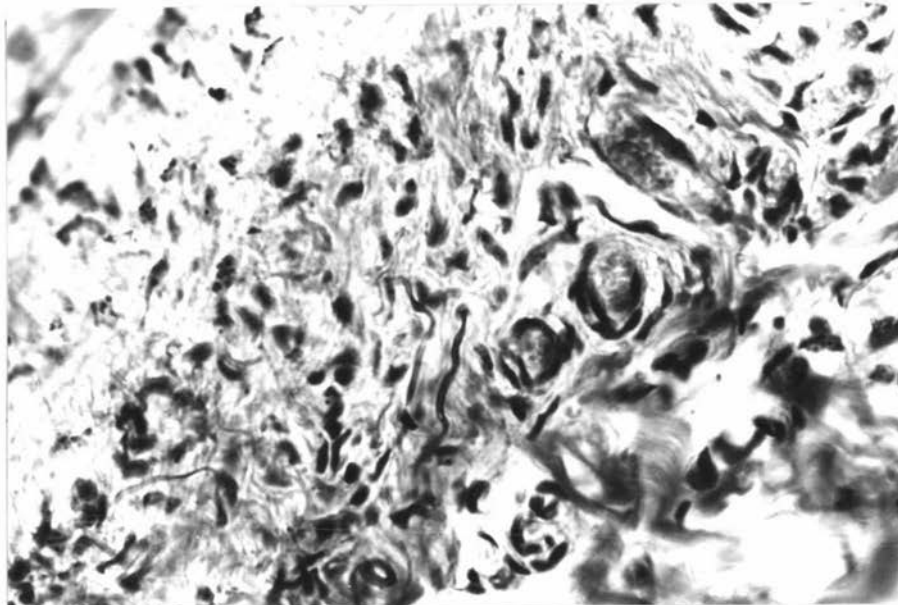


Fig. 3.

Key to Plate XVIII.

Fluorescent Microscopy of the Carotid Body

- Fig. 1. Normal carotid body tissue. Frozen section, neutral formol-saline, H & E, X50.
- Fig. 2. Normal carotid body tissue (Fig. 1). Discrete fluorescent units of the carotid body lobules are demonstrated. X50.
- Fig. 3. Diffuse carotid body tissue (after sympathectomy). Frozen section, neutral formol-saline, H & E, X50.

Key to Plate XIX.

Fluorescent Microscopy of the Sympathectomized Carotid Body

- Fig. 1. Carotid body after sympathectomy (from Fig. 3, Plate XVIII). Fluorescent units are still seen one month after denervation. X50.
- Fig. 2. Carotid body after sectioning of the external carotid nerve. Frozen section, neutral formol-saline, H & E, X50.
- Fig. 3. Sympathectomized carotid body (from Fig. 2). Fluorescing carotid body lobules are still observed. X 50

References back to previous figures mean that the illustrations are from serial sections of the same carotid body.

PLATE XVIII.

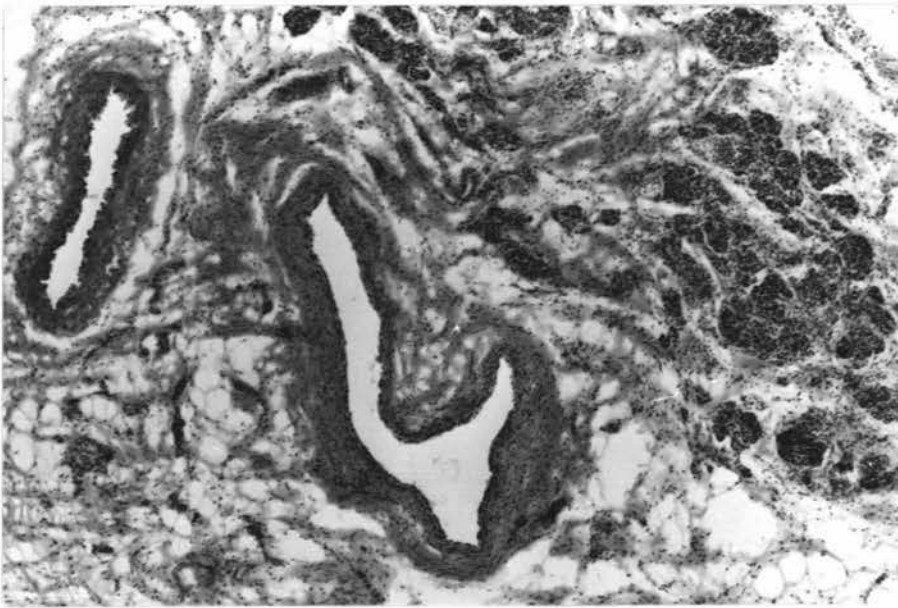


Fig. 1.

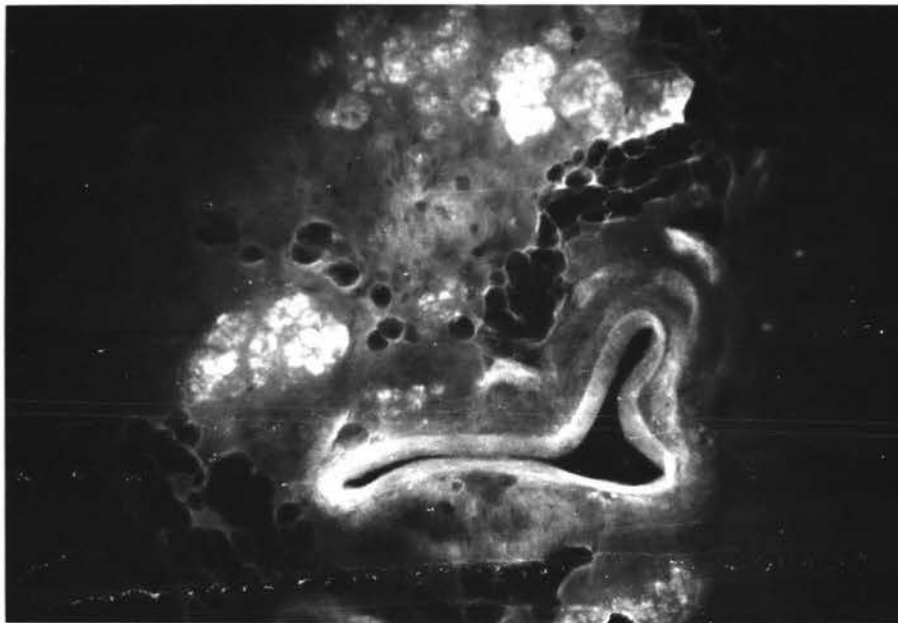


Fig. 2.

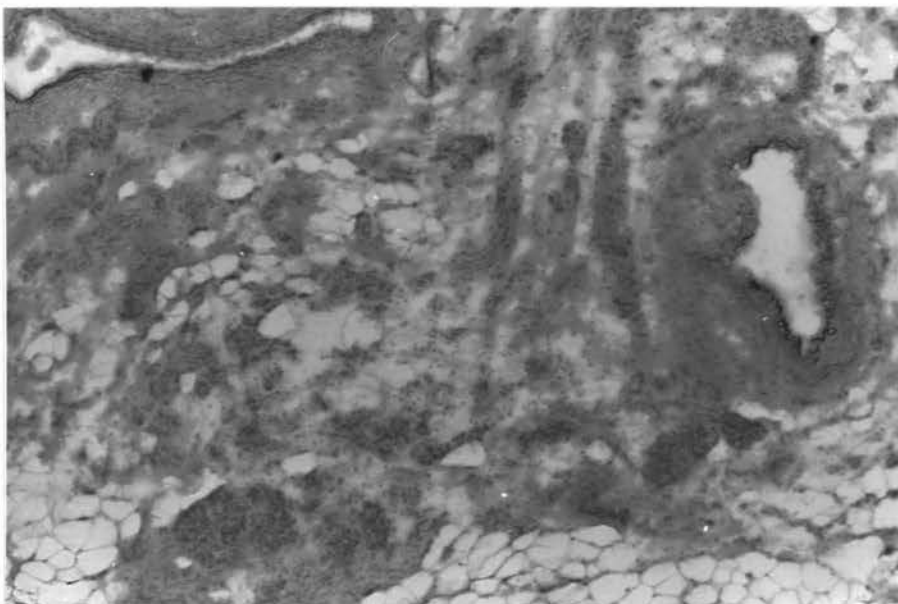


Fig. 3.

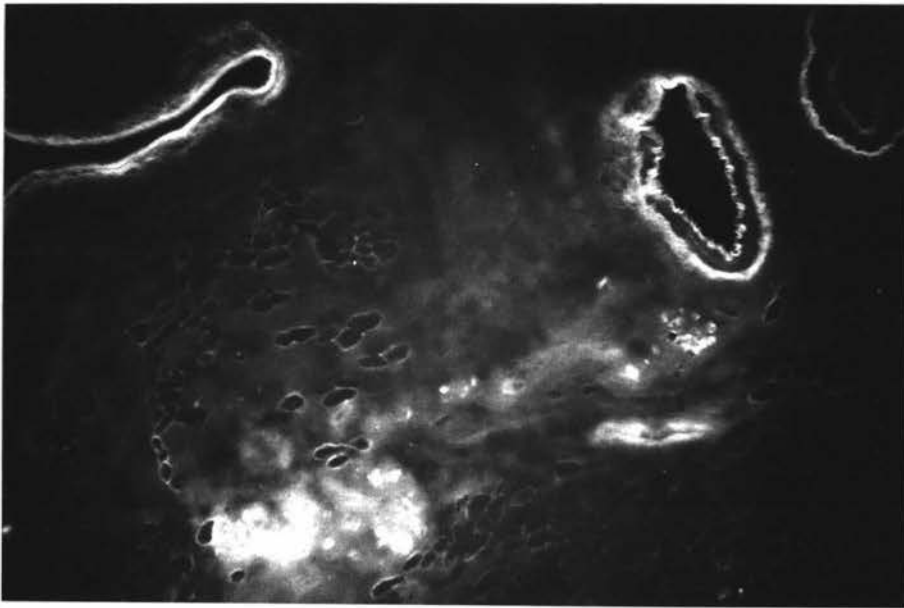


Fig. 1.

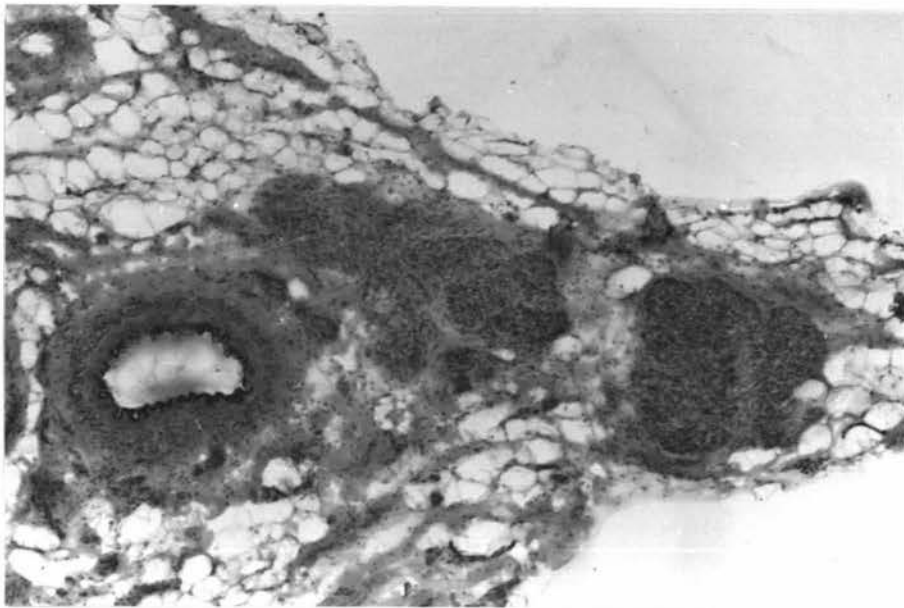


Fig. 2.

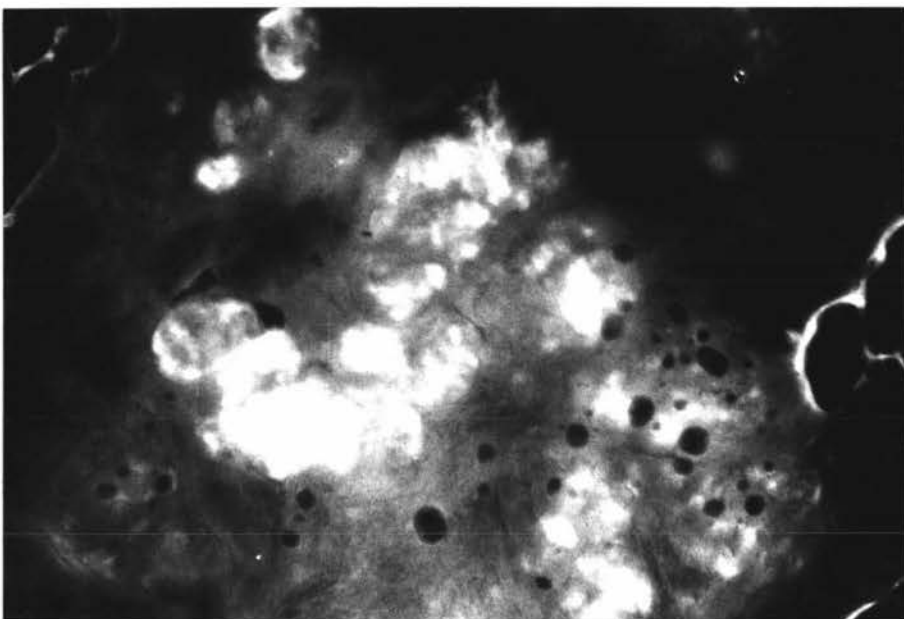


Fig. 3.

Key to Plate XX.

Fluorescent Microscopy of the Carotid Body

- Fig. 1. Carotid body after sympathectomy. Carotid body lobules fluoresce brightly 8 weeks after chronic denervation. x50
- Fig. 2. Normal carotid body. Diffusion of catecholamines leading to a diffuse fluorescing mass. x 50
- Fig. 3. Normal carotid body (at the centre). Ungassed (formaldehyde) control preparation of the carotid body is devoid of fluorescing units. x 50

Key to Plate XXI.

Fluorescent Microscopy of the Carotid Sinus and Common Carotid Artery

- Fig. 1. Normal carotid sinus. Usually, small fluorescing nerve fibres are observed in the adventitia of the carotid sinus especially near the junction of the carotid sinus and the common carotid artery. A slight diffusion of amines has taken place. The carotid sinus diverticulum is illustrated. x 50
- Fig. 2. Denervated carotid sinus. After sympathectomy no fluorescing fibres are seen either in the carotid sinus adventitia or in the common carotid artery. Bulging of the carotid sinus is noted. x 50
- Fig. 3. Normal common carotid artery. Autofluorescing internal and external elastic membranes, and elastin in the media are demonstrated. Fluorescing nerve fibres are seen only in the adventitia. x 50

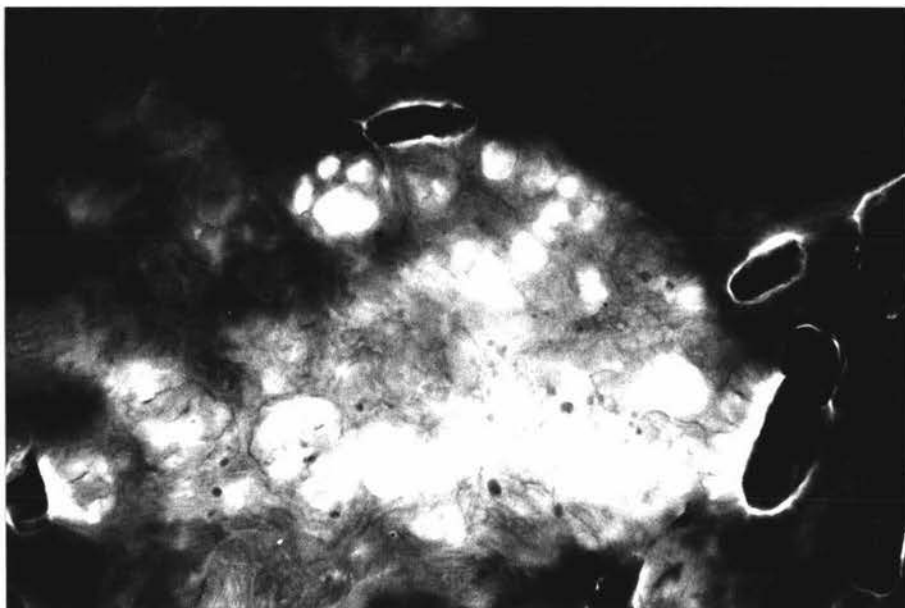


Fig. 1.

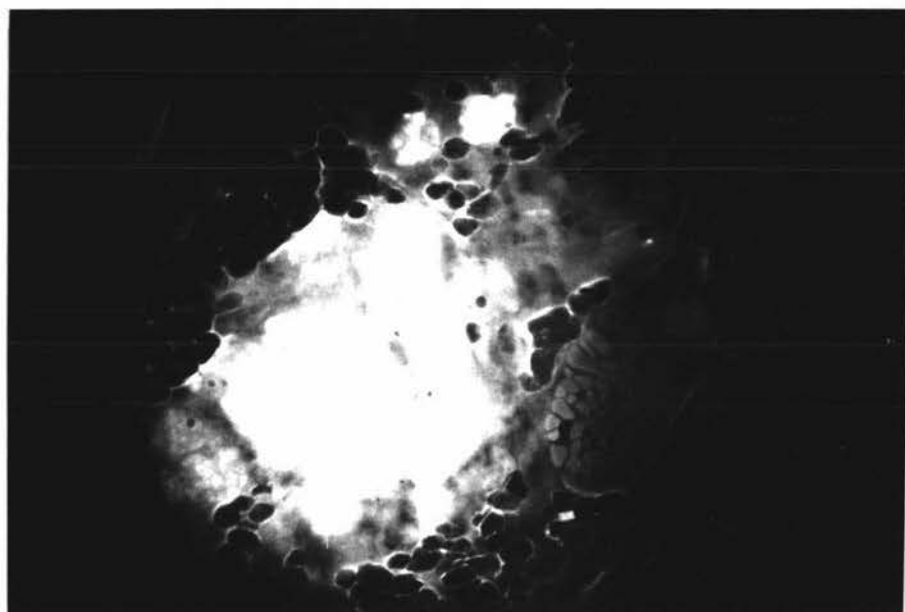


Fig. 2.

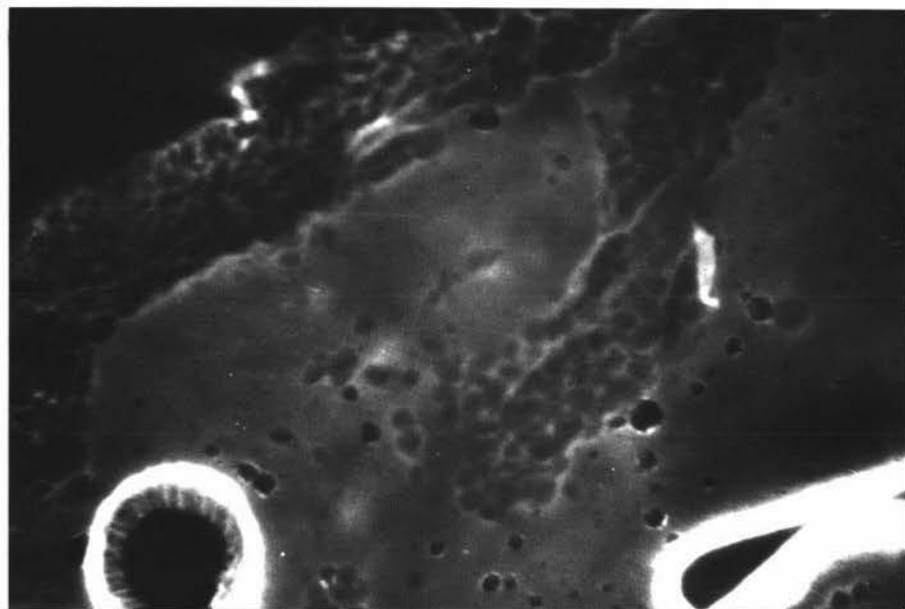


Fig. 3.

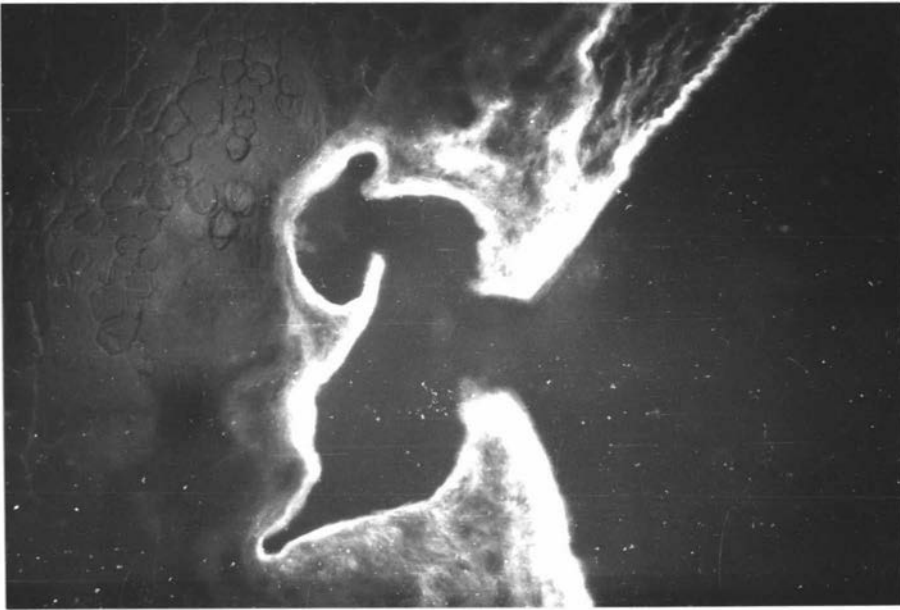


Fig. 1.

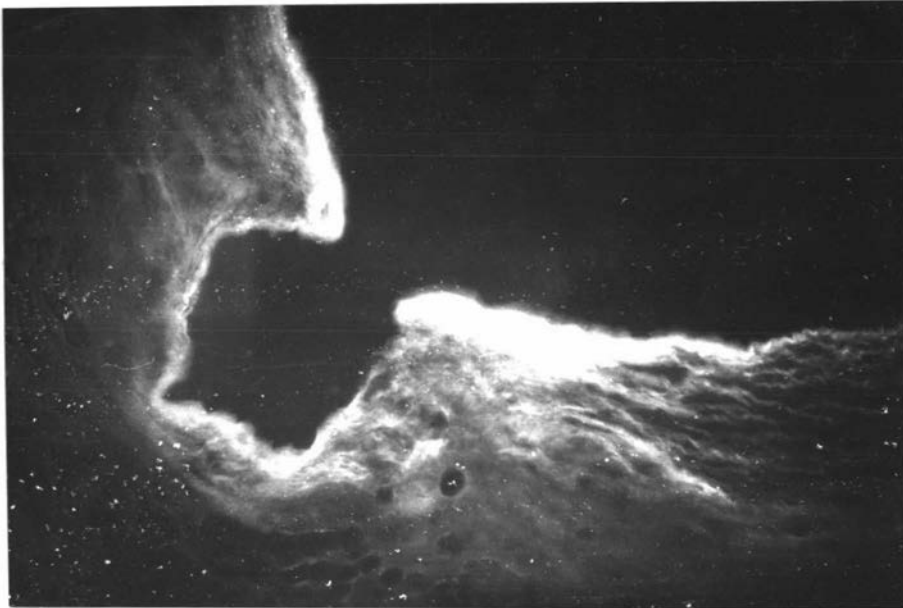


Fig. 2.

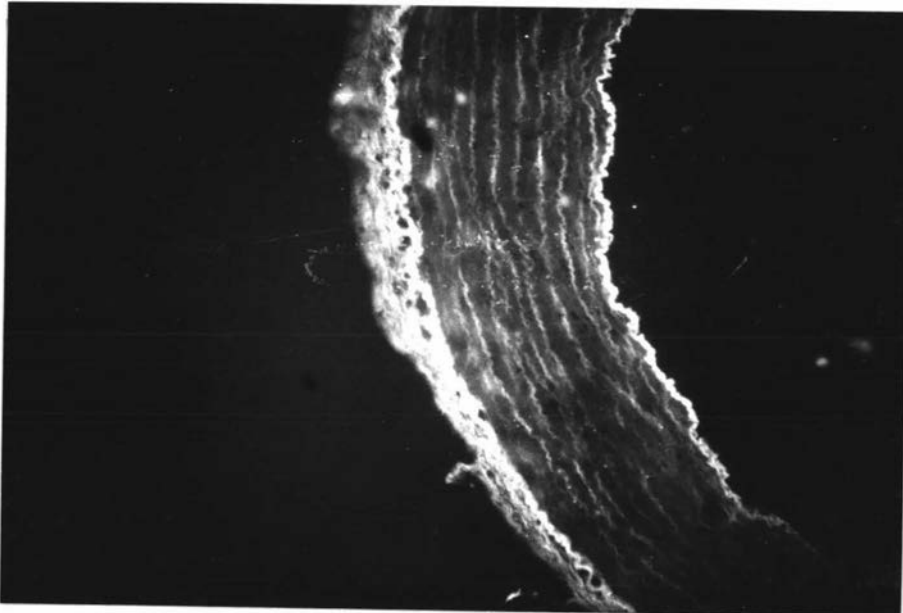


Fig. 3.

Key to Plate XXII.

Ultrastructure of the Normal Carotid Body

Fig. 1. Carotid body cells and a blood vessel. Glomus cells of type I and type II can be seen. Pericytes may be observed. Glutaraldehyde fixation. X3750 **Perfused**

Fig. 2. A type II cell located between type I cells and a blood vessel. The type II cell exhibits a different nuclear chromatin pattern and extensive cytoplasmic process around type I cells. Glutaraldehyde fixation. X7000 **Perfused**

Fig. 3. A type I cell enveloped by the cytoplasmic processes of a type II cell and a fibroblast. Electron dense-cored vesicles are numerous. The cytoplasm is vacuolated due to fixation of the tissue by immersion in modified Karnovsky's fluid. X8100.

Key to Plate XXIII.

Ultrastructure of the Normal Carotid Body

Fig. 1. A type I glomus cell showing electron dense-cored vesicles, mitochondria, rough surfaced endoplasmic reticulum, and cytoplasmic granules. Nuclear pores may also be seen. Glutaraldehyde fixation. X26400.

Fig. 2. A type I glomus cell related to a fibroblast and a myelinated nerve fibre. Small terminal nerve fibres can also be seen. Glutaraldehyde fixation. X6660.

Fig. 3. Large diameter nerve fibres in the **carotid** body. Note the neurotubules, fibrils and mitochondria. Glutaraldehyde fixation. X10950.

All perfused

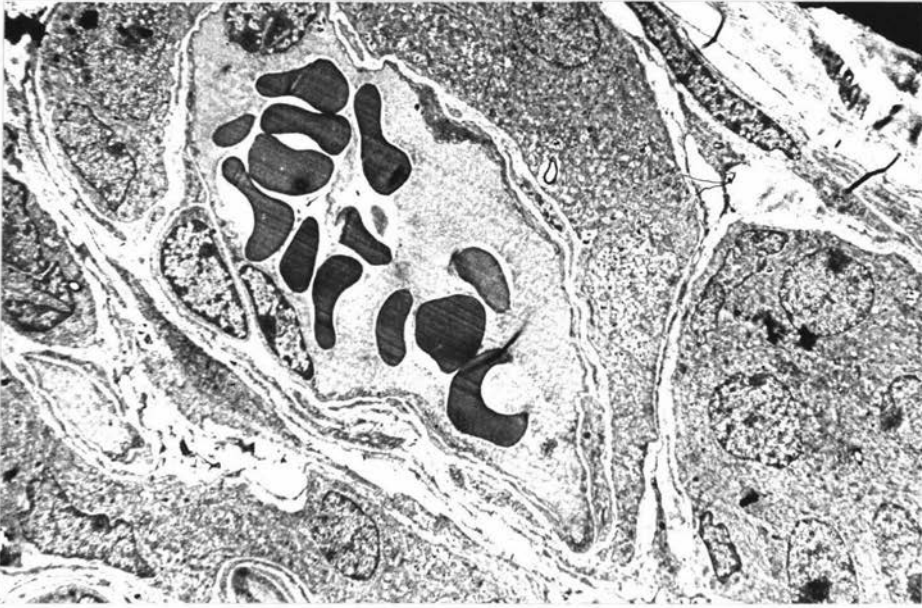


Fig. 1.

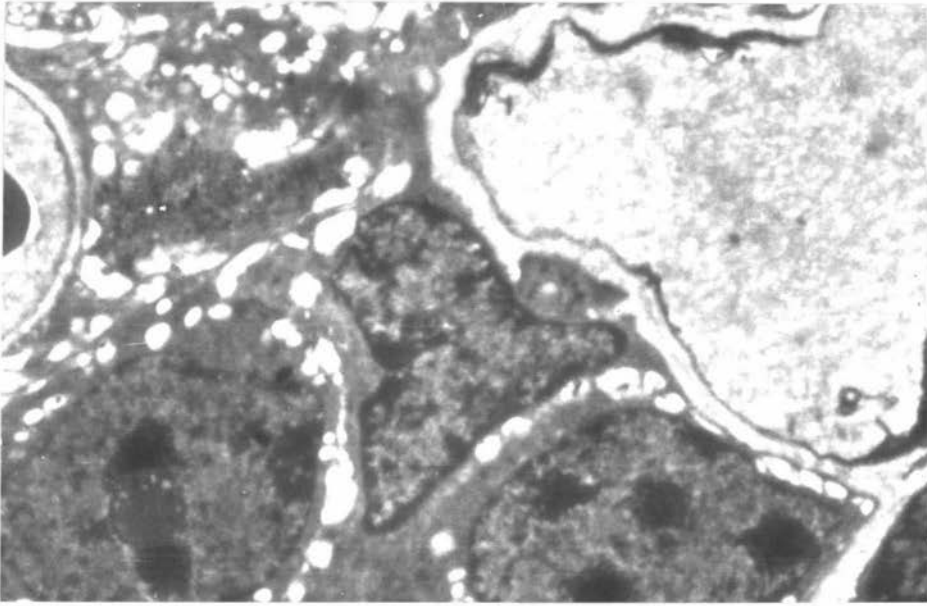


Fig. 2.

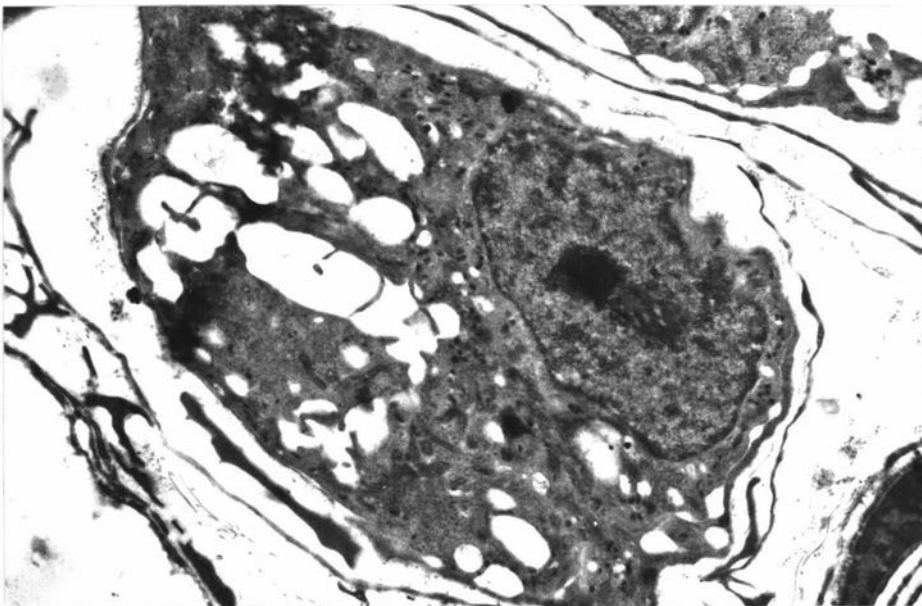


Fig. 3.

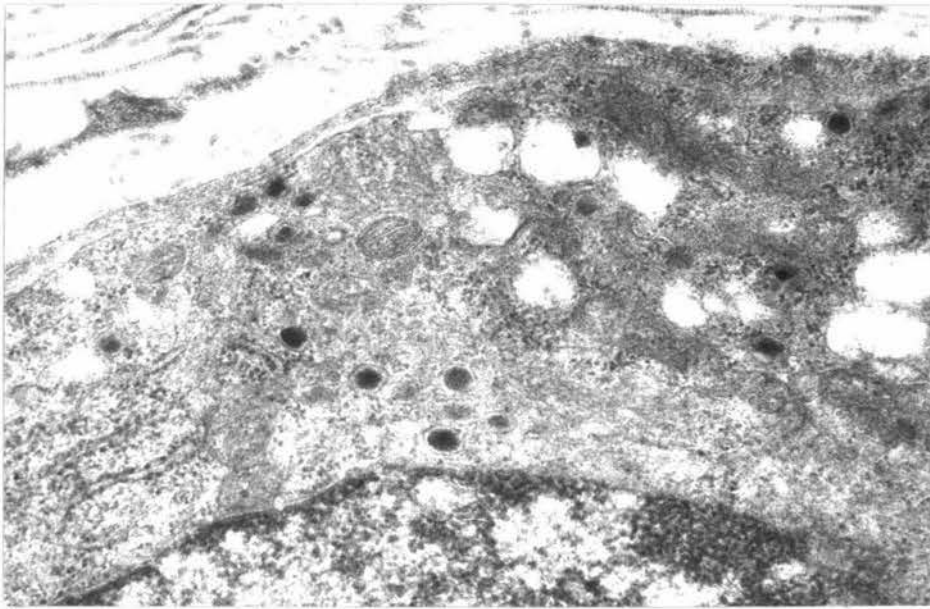


Fig. 1.

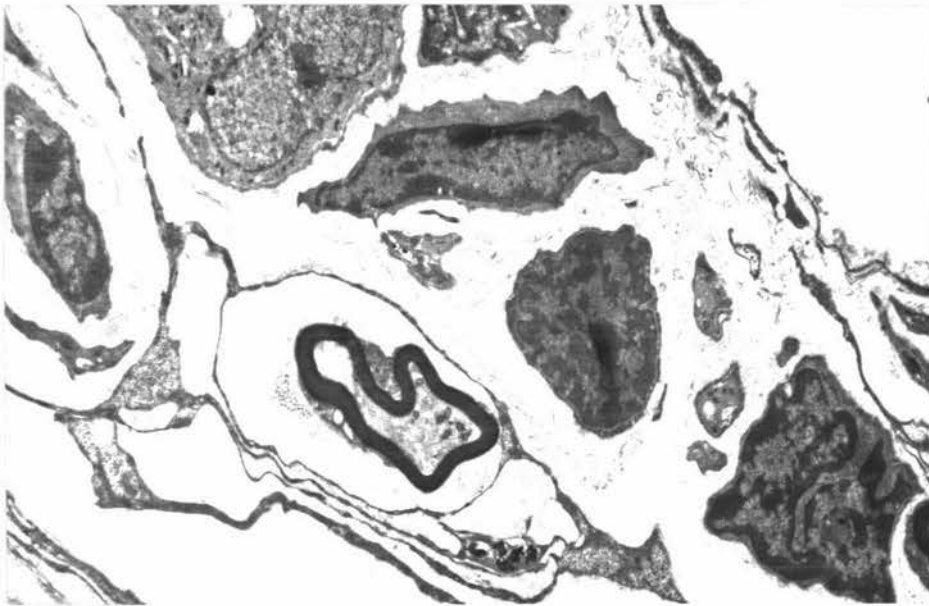


Fig. 2.

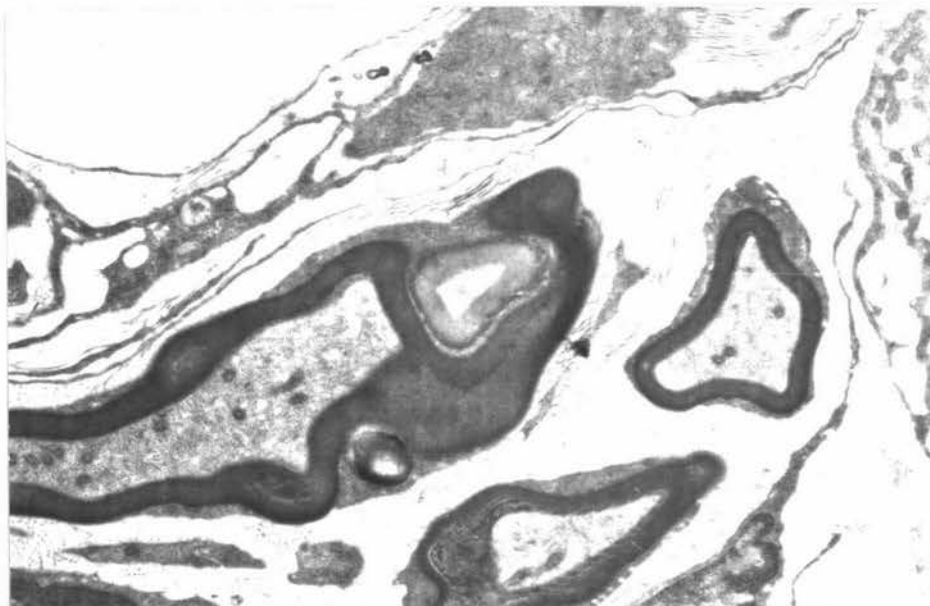


Fig. 3.

Key to Plate XXIV.Ultrastructure of the Normal **Carotid Body**

- Fig. 1. A nerve bundle of the normal carotid body in a connective tissue sheath. It contains two myelinated nerves and a small myelinated axon. A Schwann cell nucleus is illustrated. Modified Karnovsky's fluid. X10080.
- Fig. 2. An extensive type II cell sheath enveloping a type I cell almost completely. A fibroblast, a small nerve ending and a myelinated nerve fibre are also observed. Glutaraldehyde fixation. X10200.
- Fig. 3. A large type of nerve ending of the carotid body. Numerous electron dense-cored vesicles, mitochondria and clear vesicles are visible. Modified Karnovsky's fluid. X21300.

All perfusedKey to Plate XXV.

Ultrastructure of the Denervated Carotid Body

- Fig. 1. Persisting nonmyelinated nerve fibre bundles in the carotid body 8 weeks after sectioning of the carotid sinus nerve. Glutaraldehyde fixation. X8190.
- Fig. 2. Type I glomus cells and the related large diameter nerve fibres 3 weeks after sectioning of the carotid sinus nerve. The nerves fibres are degenerated. Glutaraldehyde fixation. X7700.
- Fig. 3. Marked degeneration of the nerve endings related to the blood vessels 8 weeks after cranial cervical ganglionectomy. Glutaraldehyde fixation. X7840.

All perfused

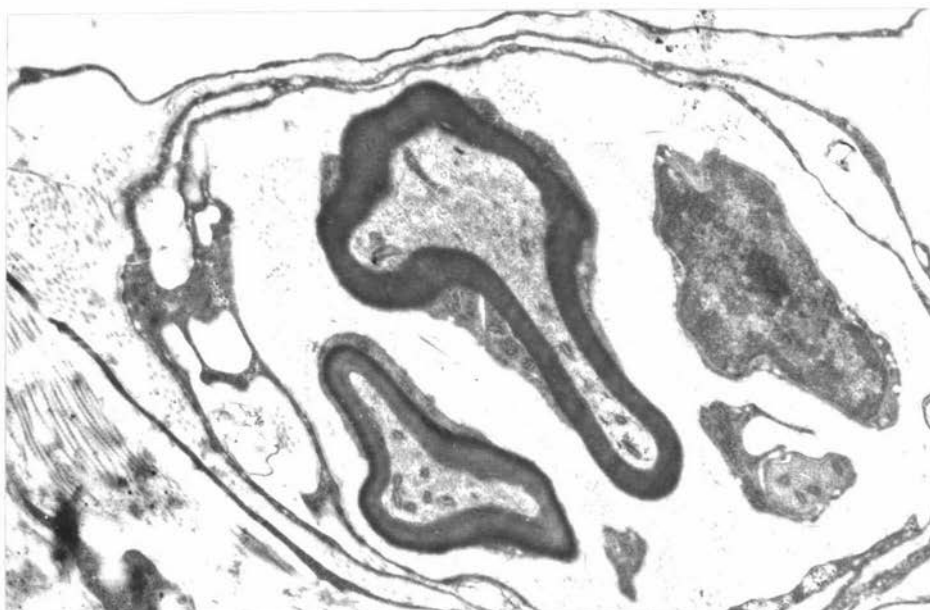


Fig. 1.

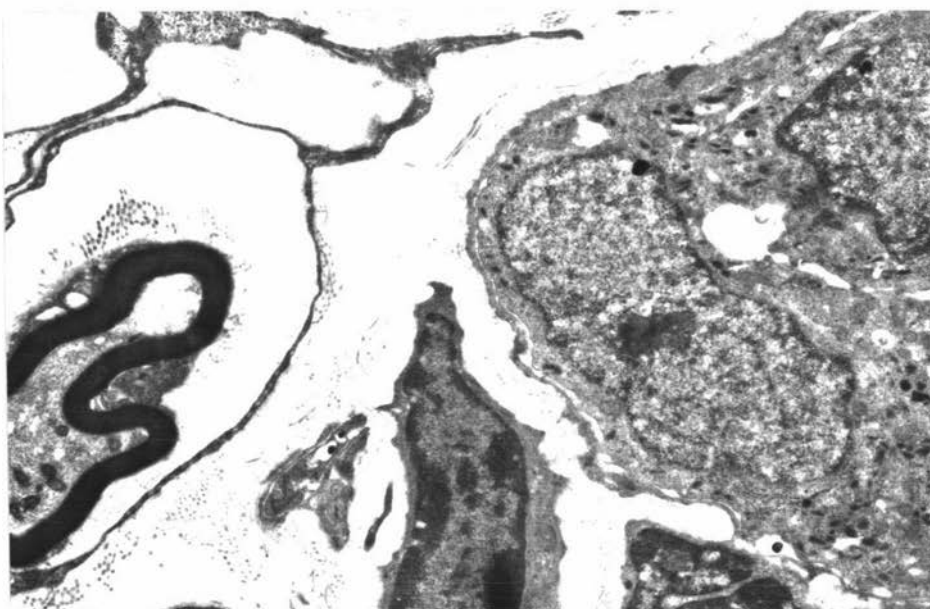


Fig. 2.

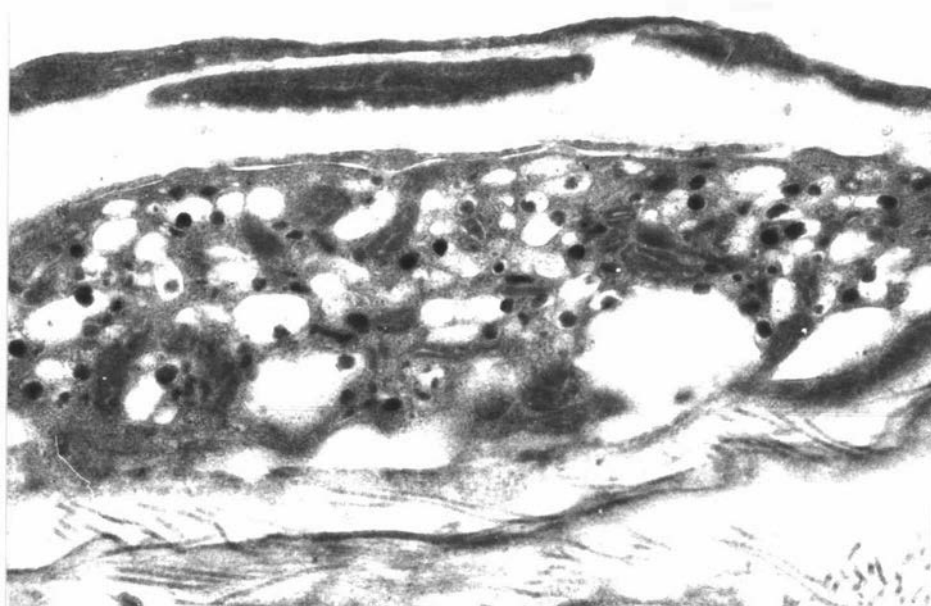


Fig. 3.

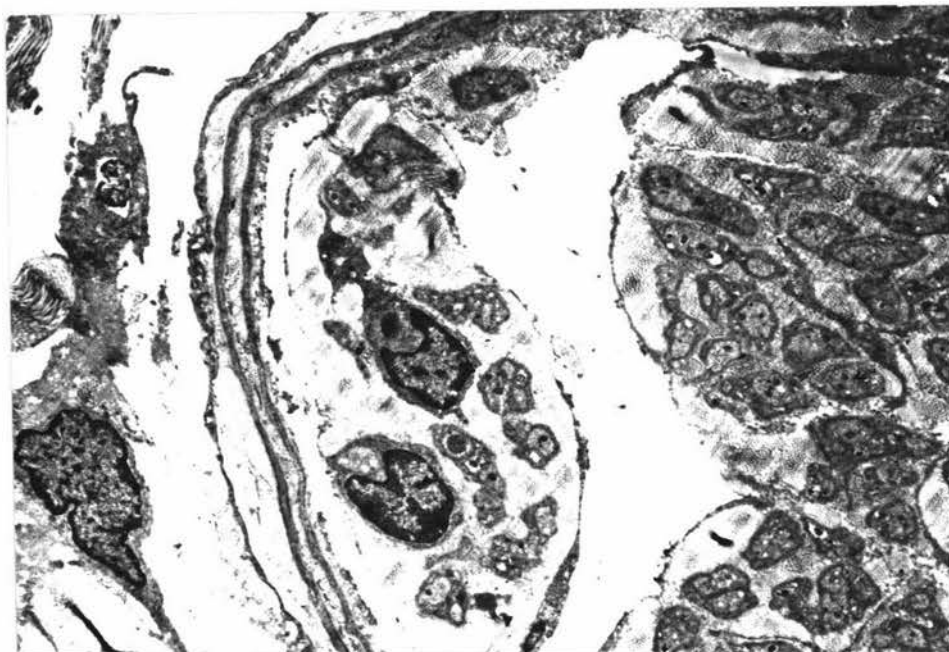


PLATE XXV.

Fig. 1.

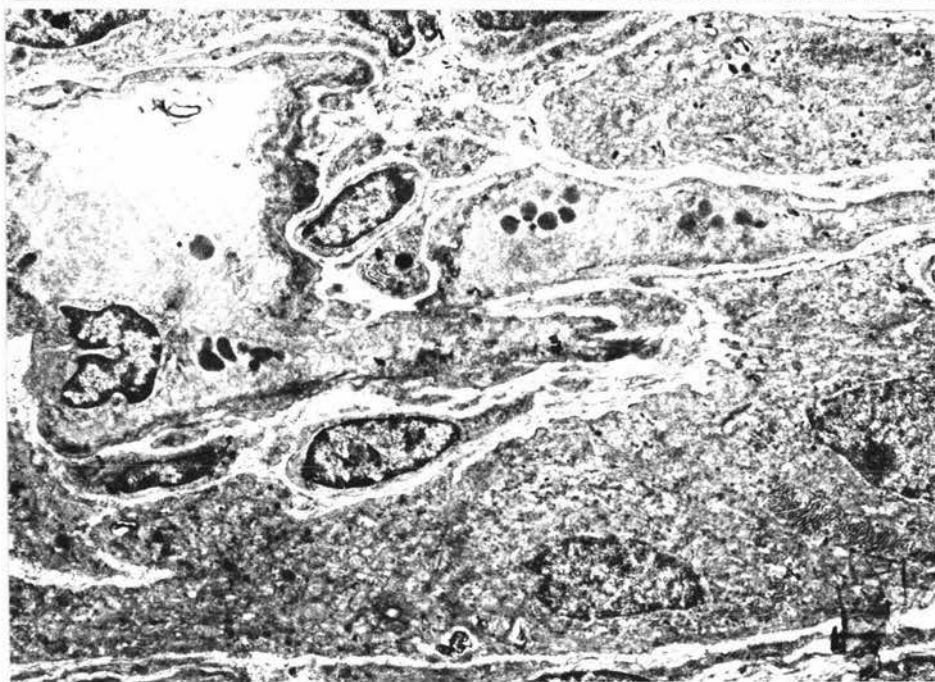


Fig. 2.

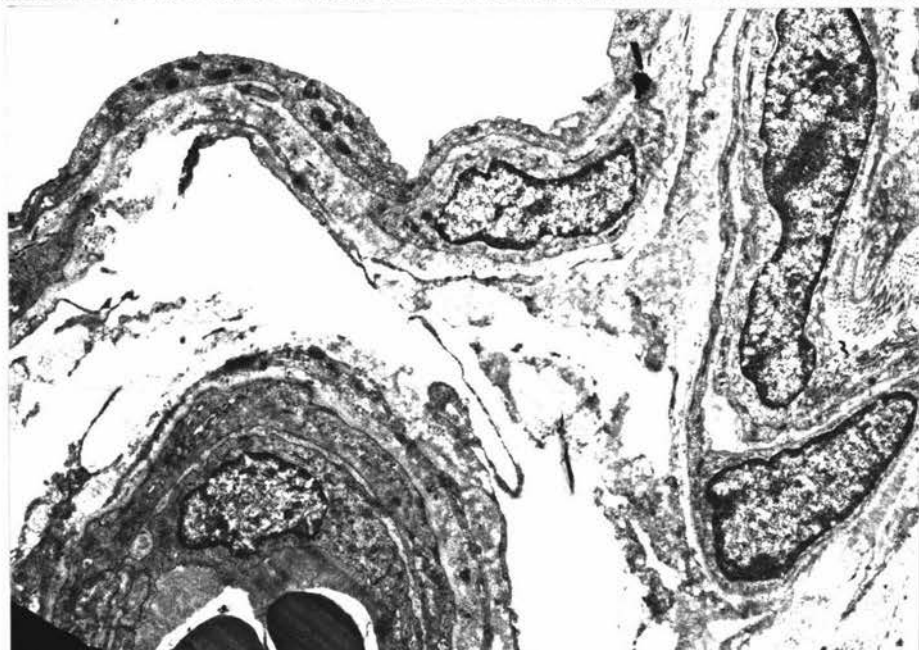


Fig. 3.

Key to Plate XXVI.

Ultrastructure of the Normal Carotid Sinus

- Fig. 1. An elastic membrane in the media of the carotid sinus which is related to collagen fibres and fibrocytes. Glutaraldehyde fixation. X13170.
- Fig. 2. An extensive cytoplasmic process of a fibrocyte separating layers of alternating collagen fibres which are cut longitudinally and transversely. Glutaraldehyde fixation. X21380.
- Fig. 3. A large diameter myelinated nerve fibre in the adventitia of the carotid sinus. Glutaraldehyde fixation. X8175.

All perfused

Key to Plate XXVII.

Ultrastructure of the Normal and Denervated Carotid Sinus

- Fig. 1. Nonmyelinated nerve fibres near the medio-adventitial border of the normal carotid sinus. Glutaraldehyde fixation. X7500.
- Fig. 2. Persisting nonmyelinated nerve fibres in the adventitia of the carotid sinus 8 weeks after transection of the carotid sinus nerve. Note also the small terminal nerve fibres. Glutaraldehyde fixation. X8400.
- Fig. 3. Rows of smooth muscle cells between two elastic membranes of the carotid sinus media 8 weeks after transection of the carotid sinus nerve. Adjacent smooth muscle cells exhibit cytoplasmic contacts. X7650.

All perfused

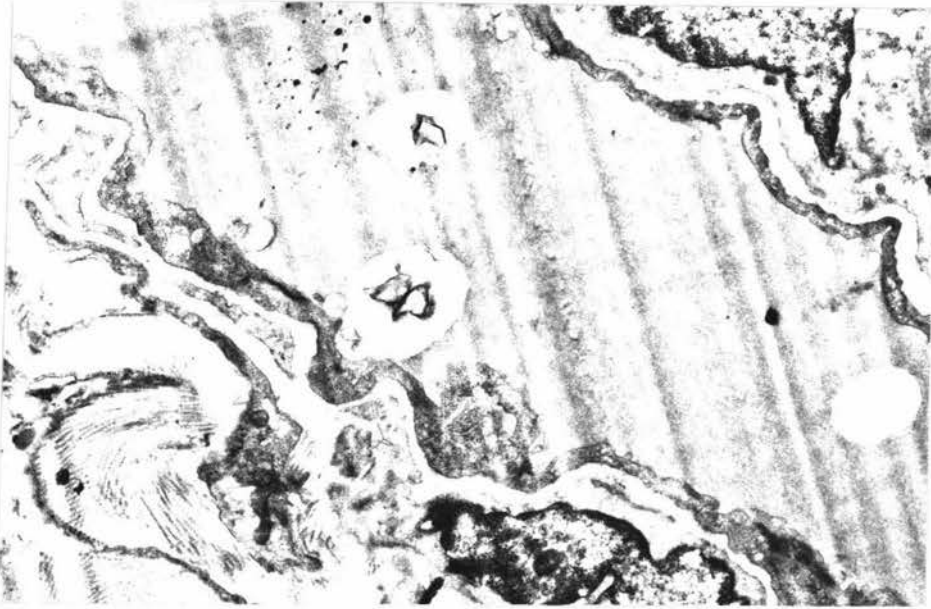


Fig. 1.

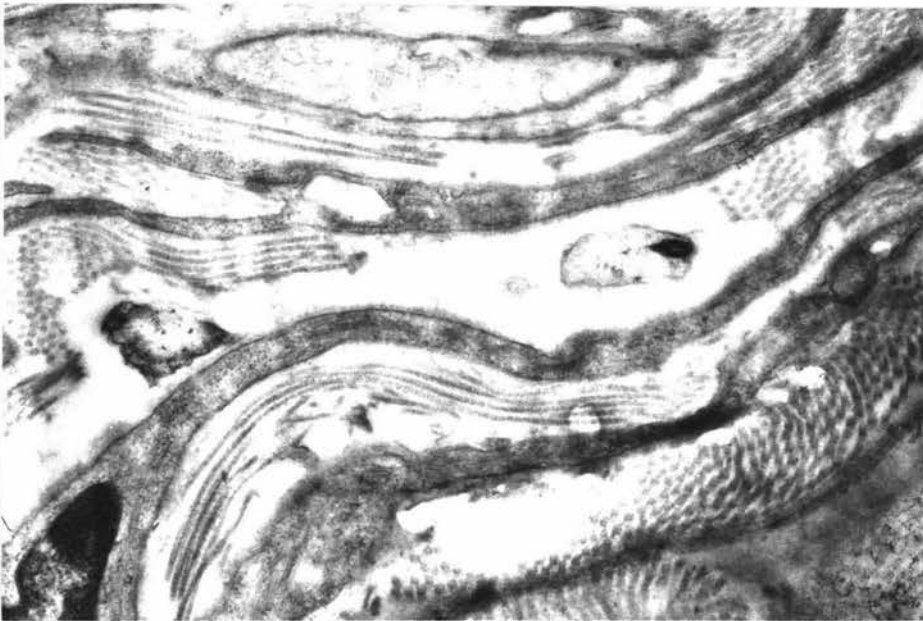


Fig. 2.

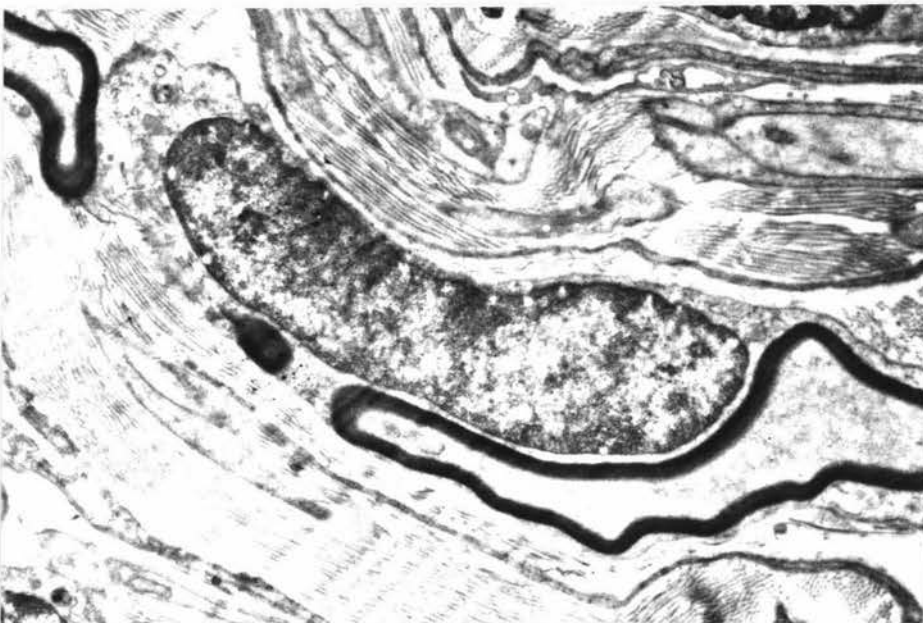

Fig. 3.

Key to Plate XXVIII.

Ultrastructure of the Normal and Denervated Carotid Sinus

- Fig. 1. Normal carotid sinus adventitia. Nonmyelinated nerve fibres and their relations to the fibroblast and connective tissue fibres. Glutaraldehyde fixation. X9610.
- Fig. 2. Carotid sinus 8 weeks after sectioning of the carotid sinus nerve. Persisting small nonmyelinated nerve fibres are found to be related to the blood vessels. Glutaraldehyde fixation. X8000.
- Fig. 3. Carotid sinus 5 weeks after cranial cervical ganglionectomy. Persisting myelinated nerve fibres are observed. Modified Karnovsky's fluid. X9000.

All perfused

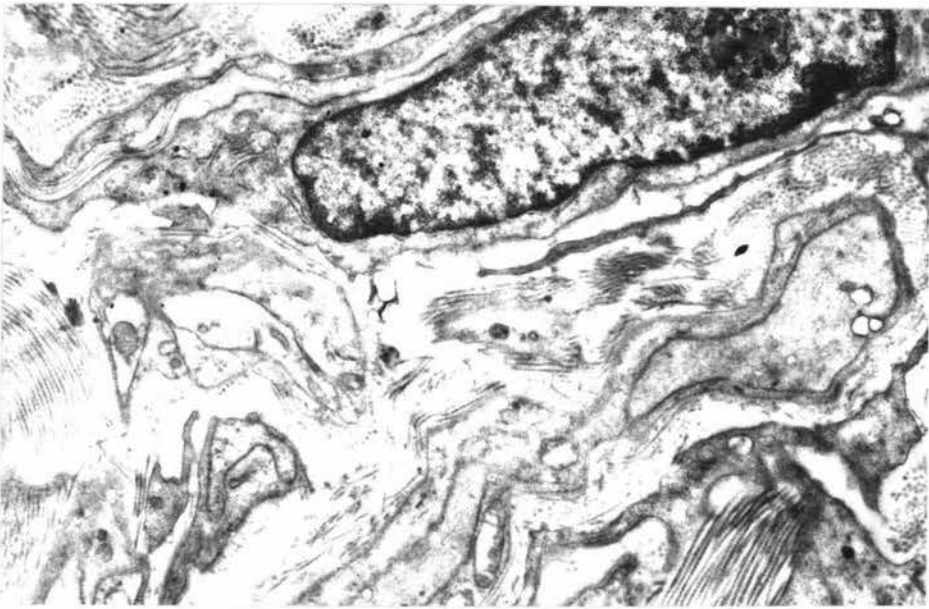


Fig. 1.

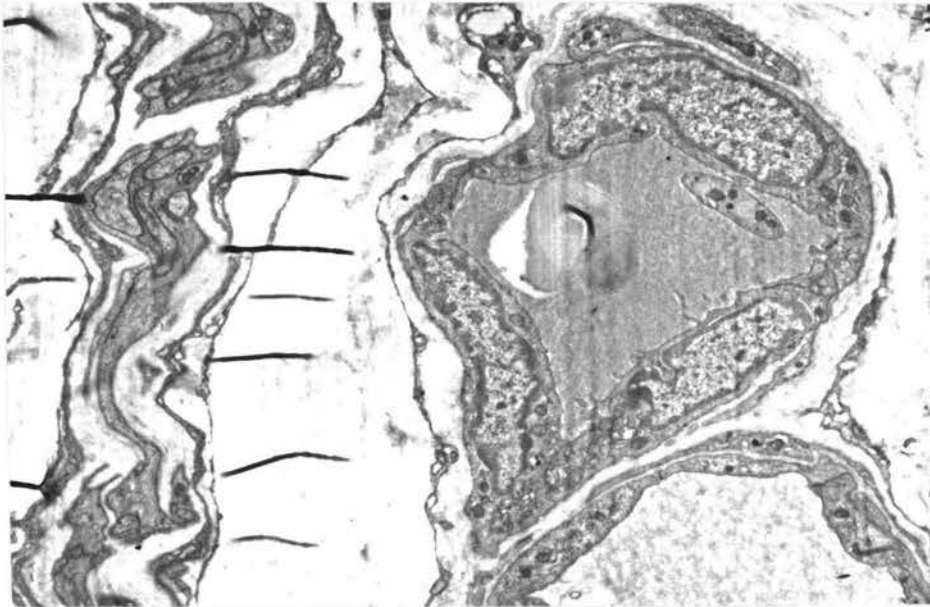

Fig. 2.

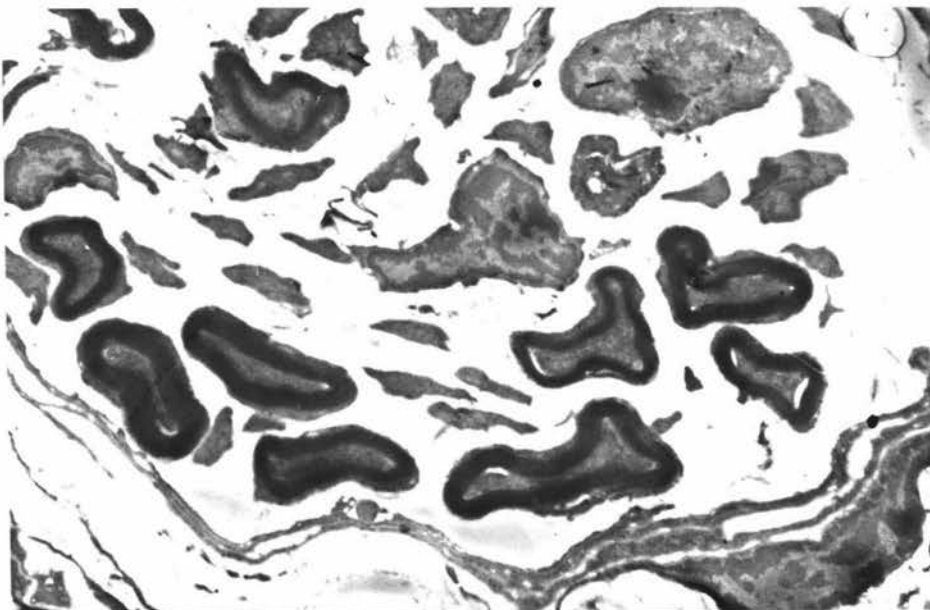


Fig. 3.

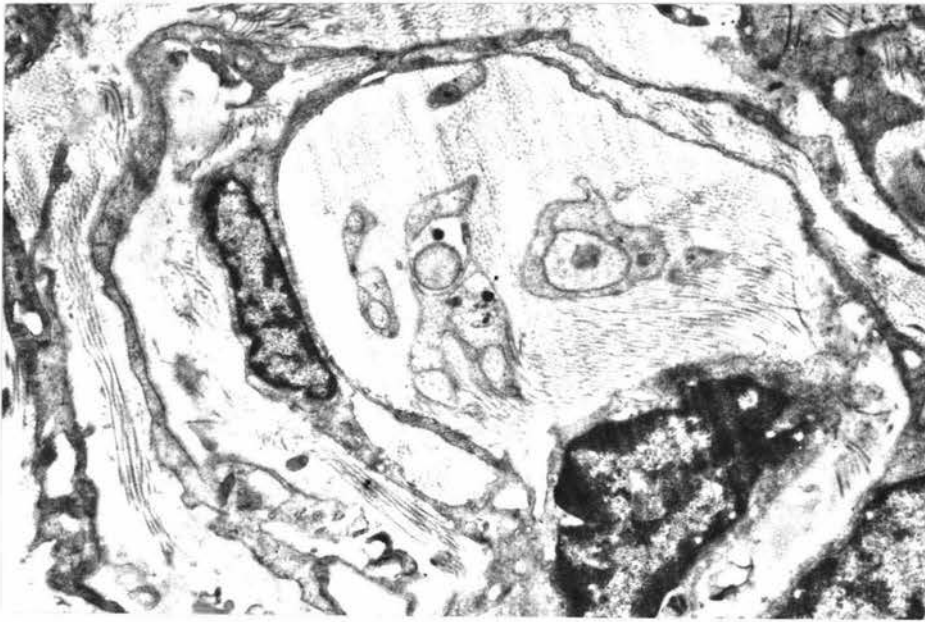

Fig. 1.

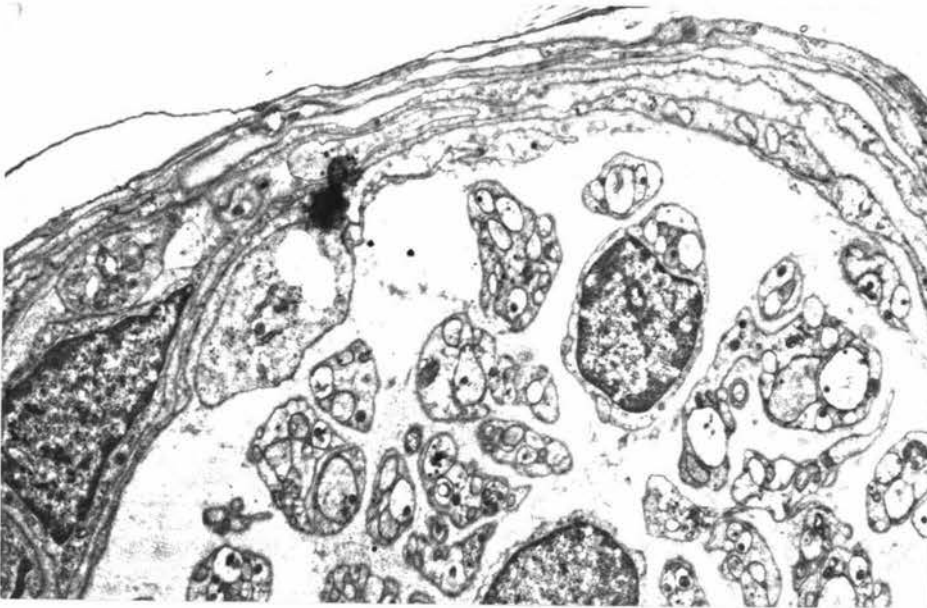


Fig. 2.

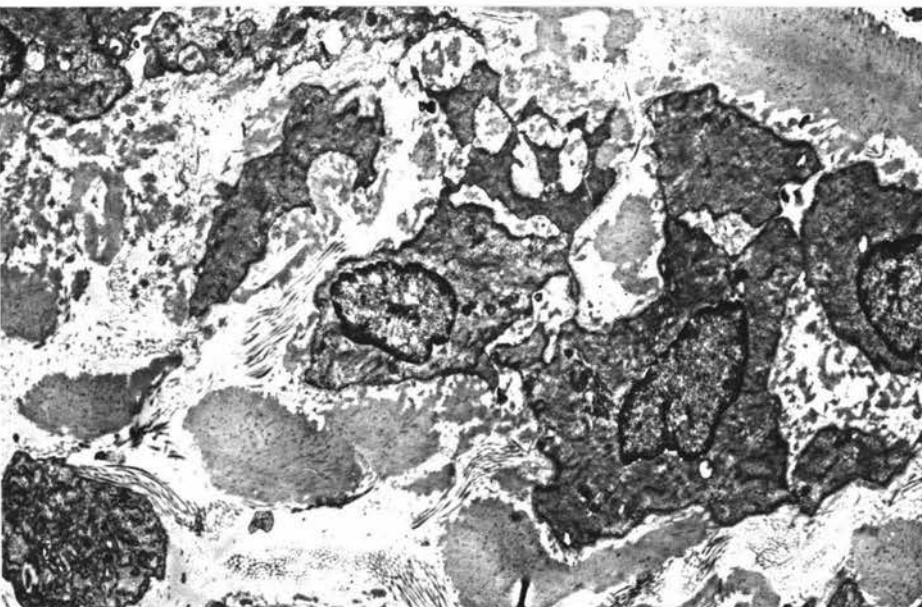


Fig. 3.

BIBLIOGRAPHY

- ABBOTT, C.P., DE BURGH DALY, M. AND HOWE, A. (1972). Early ultrastructural changes in the carotid body after degenerative section of the carotid sinus nerve in cat. *Acta anat.*, 83: 161-185.
- ABBOTT, C.P. AND HOWE, A. (1972). Ultrastructure of the aortic body tissue in the cat. *Acta anat.*, 81: 609-619.
- ABRAHAM, A. (1943). Idegvegtetek az arteria renalis fala'ban (Nerve end organs in the wall of the renal artery). *Allattani Közl.*, 40: 242. (Cited by Abraham, 1969.)
- _____ (1953a). Die Innervation der Blutgefasse. *Acta biol. Acad. sci. hung.*, 4: 69-160. (Cited by Adams, 1958.)
- _____ (1953b). Blood pressure and peripheral nervous system. *Acta. biol. Acad. sci. hung.*, 4: 307-365.
- _____ (1958). The microscopical innervation of the reflexogenic areas in the mammal's arterial system. 15th Int. Congr. Zool. London., 27: 917-919.
- _____ (1967). The structure of baroreceptors in pathological conditions in man. In Baroreceptors and Hypertension. Ed. P. Kezdi, Pergamon, Oxford and London, pp. 273-291.
- _____ (1968a). Species characteristics in the structure of the nervous system in the carotid body. In Arterial Chemoreceptors. Ed. R.W. Torrance, Blackwell, Oxford and Edinburgh, pp. 57-63.
- _____ (1968b). Electron microscopic investigations on the human carotid body: preliminary communication. *Z. mikr.-anat. Forsch.*, 79: 309-315. (Abstract in *Excerpta med.*, 23: 4269A, 1969.)
- _____ (1969). Microscopic Innervation of the Heart and Blood Vessels in Vertebrates Including Man. Pergamon, Oxford and London.

- ACHARI, N.K. (1969). A lateral approach to the carotid sinus nerve in the cat. *J. Physiol., Lond.*, 204: 15p.
- ADAMS, W.E. (1952). The carotid sinus complex and epithelial body of Varanus varius. *Anat. Rec.*, 113: 1-27.
- _____ (1955). The carotid sinus complex, "parathyroid" III and thymo-parathyroid bodies, with special reference to the Australian opossum, Trichosurus vulpecula. *Ann. J. Anat.*, 97: 1-57.
- _____ (1957a). The carotid sinus complex in the hedgehog, Erinaceus europaeus. *J. Anat., Lond.*, 91: 207-227.
- _____ (1957b). On the possible homologies of the occipital artery in mammals, with some remarks on the phylogeny and certain anomalies of the subclavian and carotid arteries. *Acta anat.*, 29: 90-113.
- _____ (1957c). The extracranial carotid rete and carotid fork in Nycticebus coucang. *Ann. Zool., Agra*, 2: 21-38.
- _____ (1958). The Comparative Morphology of the Carotid Body and Carotid Sinus. Thomas, Springfield, Ill.
- ADDISON, W.H.F. (1939). On the histology of the mammalian carotid sinus. *Biol. Bull. mar. biol. Lab., Woods Hole*, 77: 314.
- _____ (1944). The extent of the carotid pressoreceptor area in the cat as indicated by its special elastic-tissue wall. *Anat. Rec.*, 88: 418-419.
- _____ (1945). The arterial relations of the glomus caroticum in the rabbit. *Anat. Rec.*, 91: 264.
- ADDISON, W.H.F. AND COMROE, J.H. JR. (1937). The vascular relations of the glomus caroticum in the dog. *Anat. Rec.*, 67: suppl 3, p. 2.

- AL-LAMI, F. AND MURRAY, R.G. (1968a). Fine structure of the carotid body of normal and anoxic cats. *Anat. Rec.*, 160: 697-718.
- _____ (1968b). Fine structure of the carotid body of Macaca mulata monkey. *J. Ultrastruct. Res.*, 24: 465-478.
- ANGELAKOS, E.T. AND KING, M.P. (1967). Demonstration of nerve terminals containing adrenaline by a new histochemical technique. *Nature, Lond.*, 213: 391-392.
- ANICHKOV, S.V. AND BELEN'KII, M.L. (1962). Pharmacology of the Carotid Body Chemoreceptors. Translated by R. Crawford, Pergamon, Oxford and London.
- ARGAUD, R. AND DE BOISSEZON, P. (1938). Remarques sur la pseudo-chromaffinité du corpuscule carotidien. *Ref. franc. Endocr.*, 16: 305-316. (Cited by Adams, 1958.)
- ASK-UPMARK, E. (1935). The Carotid Sinus and the Cerebral Circulation. An anatomical, experimental, and clinical investigation including some observations on rete mirabile caroticum. Berlingska Boktryckeriet, Lund. 374 pp. (*Acta psychiat., Kbh.*, Suppl. 6: 1-374, 1935.) (Cited by Adams, 1958.)
- APPLETON, A.B. AND WAITES, G.M.H. (1957). A surgical approach to the superior cervical ganglion and related structures in the sheep. *J. Physiol., Lond.*, 135: 52-57.
- AUMONIER, F.J. (1972). Histological observations on the distribution of baroreceptors in the carotid and aortic regions of the rabbit, cat and dog. *Acta anat.*, 82: 1-16.
- BAGSHAW, R.J. AND FISCHER, G.M. (1971). Morphology of the carotid sinus in the dog. *J. app. Physiol.*, 31: 198.

- BAGSHAW, R.G. AND PETERSON, L.H. (1972). Sympathetic control of the mechanical properties of the canine carotid sinus. *Am. J. Physiol.*, 222: 1462-1468.
- BALANKURA, K. (1954). Observations on the development of the intra-cranial rete in the sheep. *J. Anat., Lond.*, 88: 572.
- BALDWIN, B.A. AND BELL, F.R. (1963). The anatomy of the cerebral circulation of the sheep and ox. The dynamic distribution of the blood supplied by the carotid and vertebral arteries to cranial regions. *J. Anat., Lond.*, 97: 203-215.
- BALLARD, K.J. AND JONES, J.V. (1972). Demonstration of choline acetyltransferase activity in the carotid body of the cat. *J. Physiol., Lond.*, 227: 87-94.
- BANISTER, JEAN (1968). Catecholamines in the carotid labyrinth of Rana temporaria. In Arterial Chemoreceptors. Ed. R.W. Torrance, Blackwell, Oxford and Edinburgh, pp. 193-194.
- BANISTER, R.J., PORTIG, P.G. AND VOGT, M. (1967). The content and localization of catecholamines in the carotid labyrinths and aortic arches of Rana temporaria. *J. Physiol., Lond.*, 192: 529-538.
- BATTAGLIA, G. (1966). Ultrastructural observations on the carotid body of the rat. *Boll. Soc. ital. Biol. sper.*, 42/22: 1581-1584. (Abstract in *Excerpta med.*, sect. I., 22: 5094A: 1968.)
- _____ (1968). Ultrastructural investigations on the carotid body of rat. *Arch. Ital. Anat. Embryol.*, 73: 155-157. (Abstract in *Excerpta med.*, 22: 5094A: 1968.)
- BATTEN, E.H. (1960a). Placodal contributions to the glossopharyngeal nerve and the developing carotid body. *J. Anat., Lond.*, 94: 290-291 P.

- _____ (1960b). The placodal relations of the glossopharyngeal nerve in the sheep: a contribution to the early development of the carotid body. *J. comp. Neurol.*, 114: 11-38.
- BISCOE, T.J. (1971). Carotid body: Structure and function. *Physiol. Rev.*, 51: 437-495.
- BISCOE, T.J., LALL, A. AND SAMPSON, S.R. (1969). On the nerve endings associated with the carotid body glomus cells of the cat. *J. Physiol., Lond.*, 200: 131-132 P.
- _____ (1970). Electron microscopic and electrophysiological studies on the carotid body following intracranial section of the glossopharyngeal nerve. *J. Physiol., Lond.*, 208: 133-152.
- BISCOE, T.J. AND SAMPSON, S.R. (1968). Rhythmical and non-rhythmical spontaneous activity recorded from the central cut end of the carotid sinus nerve. *J. Physiol., Lond.*, 196: 327-338.
- BISCOE, T.J. AND STEHBENS, W.E. (1965). Electron microscopic observations on the carotid body. *Nature, Lond.*, 208: 708-709.
- _____ (1966). Ultrastructure of the carotid body. *J. Cell Biol.*, 30: 563-578.
- _____ (1967). Ultrastructure of the denervated carotid. *Q. J. exp. Physiol.*, 52: 31-36.
- BISCOE T.J. and TAYLOR A. (1963). The discharge pattern recorded in chemoreceptor afferent fibres from the cat carotid body with normal circulation and during perfusion. *J. Physiol., Lond.*, 168: 332-344.

- BLOOM, F. (1943). Structure and histogenesis of tumours of the aortic bodies in dogs with a consideration of the morphology of the aortic and carotid bodies. *Archs Path.*, 36: 1-12.
- BLOOM, W. AND FAWCETT, D.W. (1962). A textbook of Histology. 8th ed., Saunders, Philadelphia and London.
- BLÜMCKE, S., NIEDORF, H.R. AND RODE, J. (1967a). The glomus caroticum after an increase in the CO₂ of the respiratory air. *Z. Zellforsch.*, 81: 557-570. (Abstract in *Excerpta med.*, 22: 2105A: 1968.)
- BLÜMCKE, S., RODE, J. AND NIEDORF, H.R. (1967b). The carotid body after oxygen deficiency. *Z. Zellforsch.*, 80: 52-77. (Abstract in *Excerpta med.*, 22: 274A: 1968.)
- BODIAN, D. (1936). A new method for staining nerve fibres and nerve endings in mounted paraffin sections. *Anat. Rec.*, 65: 89-97.
- _____ (1937). The staining of paraffin sections of nervous tissues with activated protargol. The role of fixatives. *Anat. Rec.*, 69: 153-162.
- BOEKE, J. (1932). Cytology and Cellular Pathology of the Nervous System. Ed. W. Penfield. Hoeber, New York, Vol. 1/6 - Nerve endings, motor and sensory, pp. 241-315.
- DE BOISSEZON, P. (1942). La Zone Reflexogene Carotidienne. Etude Anatomique et Histophysiologique. Toulouse: Librairie Marqueste. (Cited by Adams, 1948.)
- BOSS, J. AND GREEN, J.H. (1954a). Nervous structures in the recently described baroreceptor areas of the right common carotid artery in the cat. *J. Physiol.*, Lond., 124: 43 P.
- _____ (1954b). The modification of the arterial wall in baroreceptor areas. *J. Physiol.*, Lond., 125: 42 P.

- _____ (1956). The histology of the common carotid baroreceptor areas of the cat. *Circulation Res.*, 4: 12-17.
- BOYD, J.D. (1933). The development and significance of the amphibian carotid body. *J. Anat., Lond.*, 68: 154-155.
- _____ (1936). Nerve supply to the branchial arch arteries of vertebrates. *J. Anat., Lond.*, 71: 157-158.
- _____ (1937a). The development of the human carotid body. *Contr. Embryol. Carneg. Inst.*, 26: 1-31.
- _____ (1937b). Observations on the human carotid sinus and its nerve supply. *Anat. Anz.*, 84: 386-399.
- _____ (1942). The nerve supply of the branchial arch arteries in *Vipera berus*. *J. Anat., Lond.*, 76: 248-257.
- BURTON, A.C. (1954). Relation of structure to function of the tissues of the wall of the blood vessels. *Physiol. Rev.*, 34: 619-642.
- CARLSSON, A., FALCK, B., FUXE, K. AND HILLARP, N-Å. (1964). Cellular localization of monoamines in the spinal cord. *Acta physiol. scand.*, 60: 112-119.
- DE CASTRO, F. (1926). Sur la structure et l'innervation de la glande intercarotidienne (glomus caroticum) de l'homme et des mammifères, et sur un nouveau système d'innervation autonome du nerf glossopharyngien. *Etudes anatomiques et expérimentales. Trab. Lab. Invest. biol. Univ. Madr.*, 24: 365-432. (Cited by Adams, 1958.)
- _____ (1928). Sur la structure et l'innervation du sinus carotidien de l'homme et des mammifères. Nouveaux faits sur l'innervation et la fonction du glomus caroticum. *Etudes anatomiques et physiologiques. Trab. Lab. Invest. biol. Univ. Madr.*, 25: 331-380. (Cited by Adams, 1958.)

- _____ (1929). Über die Struktur und Innervation des Glomus caroticum beim Menschen und bei den Säugetieren. Anatomisch-experimentelle Untersuchungen. Z. ges. Anat. 1. Z. Anat. EntwGesch., 89: 250-265. (Cited by Adams, 1958.)
- _____ (1940). Neuvas observaciones sobre la inervacion de la region carotidea. Los quimio y preso-receptores. Trab. Inst. Cajal Invest. biol., 32: 297-384. (Cited by Adams, 1958.)
- _____ (1951). Sur la structure de la synapse dans les chemorecepteurs: leur mécanisme d'excitation et rôle dans la circulation sanguine locale. Acta physiol. scand., 22: 14-43. (Cited by Adams, 1958.)
- DE CASTRO, F. AND RUBIO, M. (1968). The anatomy and innervation of the blood vessels of the carotid body and the role of chemoreceptive reactions in the auto-regulation of the blood flow. In Arterial Chemoreceptors. Ed. R.W. Torrance, Blackwell, Oxford and Edinburgh, pp 267-277.
- CELESTINO DA COSTA, A. (1935). Paraganglia and carotid body. J. Anat., Lond., 69: 479-483.
- CHAUVEAU, A. (1891). The Comparative Anatomy of the Domesticated Animals. 2nd. English ed. Translated by G. Fleming, Churchill, London.
- CHEN, I-LI AND YATES, R.D. (1968). An electron microscopic cytochemical study of the effects of hypoxia and reserpine on the glomus cells of the carotid body. Anat. Rec., 160: 330.
- _____ (1969). Electron microscopic radio-autographic studies of the carotid body following injections of labelled biogenic amine precursors. J. Cell Biol., 42: 794-803.

CHEN, I-LI, YATES, R.D. AND DUNCAN, D. (1967). Electron microscope localization of biogenic amines in the carotid body. *J. Cell Biol.*, 35: 22A.

_____ (1968). The effects of nerve stimulation or nerve transection on the glomus cells of the carotid body. *J. Cell Biol.*, 39: 24A.

_____ (1969). The effects of reserpine and hypoxia on the amine-storing granules of the hamster carotid body. *J. Cell Biol.*, 42: 804-816.

CHIOCCHIO, S.A., BISCARDI, A.M. AND TRAMEZZANI, J.H. (1966). Catecholamine in the carotid body of the cat. *Nature, Lond.*, 212: 834-835.

_____ (1967). 5-hydroxytryptamine in the carotid body of the cat. *Science*, 158: 790-791.

CHIOCCHIO, S.A., KING, M.P., CARBALLO, L. AND ANGELAKOS, R.T. (1971). Monoamines in the carotid body cells of the cat. *J. Histochem. Cytochem.*, 19: 620-626.

CHOWDHARY, D.S. (1950). A note on the carotid body and carotid sinus of Varanus monitor. *Anat. Rec.*, 107: 235-241.

_____ (1951). The carotid labyrinth of Rana tigrina. *Nature, Lond.*, 167: 1074.

_____ (1953). A Comparative Study of the Carotid Body and Carotid Sinus of Vertebrates. II. The carotid body and "carotid sinus" of the fowl (Gallus domesticus). Doctorate Thesis, Edinburgh, 58 pp.

CHUNGCHAROEN, D., DALY, M. DE BURGH AND SCHWEITZER, A. (1952a). The blood supply of the carotid body. *J. Physiol., Lond.*, 117: 11-12 P.

(1952b).

The blood supply of the carotid body in cats, dogs and rabbits. *J. Physiol., Lond.*, 117: 347-358.

(1952c)

The blood supply of the superior cervical sympathetic and the nodose ganglia in cats, dogs and rabbits. *J. Physiol., Lond.*, 118: 528-536.

CLERMONT, D. (1955). Le corpuscule carotidien. *Toulouse med.*, 56: 129-150. (Cited by Adams, 1958.)

CODE, C.F. AND DINGLE, W.T. (1935). The carotid sinus nerve. *Proc. Mayo Clin.*, 10: 129-132.

CODE, C.F., DINGLE, W.T. AND MOORHOUSE, V.H.K. (1936). The cardiovascular carotid sinus reflex. *Am. J. Physiol.*, 115: 249-260.

COMROE, J.H. JR. AND SCHMIDT, C.F. (1938). The part played by reflexes from the carotid body in the chemical regulation of respiration in the dog. *Am. J. Physiol.*, 121: 75-97.

CORRODI, H., FALCK, B. AND HILLARP, N-Å. (1962). Sensitive fluorescence methods for histochemical demonstrations of catecholamines at the cellular level. Paper read at Scandinavian pharmacological meeting, Göteborg. (Cited by Carlsson et al., 1964.)

CORRODI, H. AND HILLARP, N-Å. (1963). Fluoreszenzmethoden zur histochemischen Sichtbarmachung von Monoaminen.
1. Identifizierung der fluoreszierenden Produkte aus Modellversuchen mit 6,7-Dimethoxyisochinolinderivaten und Formaldehyd. *Helv. Chim. Acta*, 46: 2425-2430. (Abstract in *Excerpta med.*, 45: 49762A: 1964.)

(1964). Fluoreszenzmethoden zur

histochemischen Sichtbarmachung von Monoaminen.

2. Identifizierung des fluoreszierenden Produktes aus Dopamin und Formaldehyd. *Helv. Chim. Acta*, 47: 911-918. (Cited by Spriggs et al., 1966.)

- CORRODI, H. AND JONSSON, G. (1965). Fluoreszenzmethoden zur histochemischen Sichtbarmachung von Monoaminen. 5. Identifizierung des fluoreszierenden Produktes aus Modellversuchen mit 5-Methoxytryptamin und Formaldehyd. Fluorescence methods for the histochemical identification of monoamines. 5. Identification of the fluorescing products from model experiments with 5-methoxytryptamine and formaldehyde. *Acta Histochem.*, 22: 248-258. (Abstract in *Excerpta med.*, 47: 55180A: 1966.)
- CROSS, K.W., DAWES, G.S. AND MOTT, J.C. (1959). Anoxia, O₂ consumption and cardiac output in new-born lambs and adult sheep. *J. Physiol., Lond.*, 146: 316-343.
- CROSS, K.W. AND MALCOLM, J.J. (1952). Evidence of carotid body and sinus activity in newborn and foetal animals. *J. Physiol., Lond.*, 118: 10-11 P.
- CULLING, C.F.A. (1963). Handbook of Histopathological Techniques. 2nd ed., Butterworth, London.
- DALY, M. DE BURGH (1954). VI. The problem of transmission at chemoreceptors. Acetylcholine and transmission at chemoreceptors. *Pharmac. Rev.*, 6: 79-80.
- DALY, M. DE BURGH, LAMBERTSEN, C.J. AND SCHWBITZER, A. (1952). Observations on carotid body blood flow in the cat. *J. Physiol., Lond.*, 117: 12 P.
-
- (1954).
Observations on the volume of blood flow and oxygen utilization of the carotid body in the cat. *J. Physiol., Lond.*, 125: 67-89.
- DANIEL, P.M., DAWES, J.D.K. AND PRICHARD, MARJORIE M.L. (1953). Studies of the carotid rete and its associated arteries. *Phil. Trans. R. Soc., Lond., B.*, 237: 173-208.
- DAVENPORT, H.A. (1960). Histological and Histochemical Techniques. Saunders, Philadelphia and London.

DEARNALEY, D.P., FILLENZ, M. AND WOODS, R.I. (1968a). The identification of dopamine in the carotid body of the rabbit. In Arterial Chemoreceptors. Ed. R.W. Torrance, Blackwell, Oxford and Edinburgh, pp. 189-192.

_____ (1968b). The identification of dopamine in the rabbit's carotid body. Proc. R. Soc., Lond., Ser. B., 170: 195-203.

DOUGHTERY, R.W., HABEL, R.E. AND BOND, H.E. (1958). Oesophageal innervation and the eructation reflex in sheep. Am. J. vet. Res., 19: 115-123.

DOUGLAS, W.W. (1954). VI. The problem of transmission at chemoreceptors. Is there chemical transmission at chemoreceptors? Pharmac. Rev., 6: 81-83.

DOUGLAS, W.W. AND RITCHIE, J.M. (1956). Cardiovascular reflexes produced by electrical excitation of non-medullated afferents in the vagus, carotid sinus and aortic nerves. J. Physiol., Lond., 134: 167-178.

DOUGLAS, W.W. AND SCHUMANN, W. (1956). A study of the depressor and pressor components of the cat's carotid sinus and aortic nerves using electrical stimuli of different intensities and frequencies. J. Physiol., Lond., 132: 173-186.

DOWD, D.A. (1964). The carotid body - carotid sinus complex in monotremes. Proceedings of the anatomical Society of Australia and New Zealand, J. Anat., Lond., 98: 494.

_____ (1966). The carotid body - carotid sinus complex in monotremes. Acta anat., 65: 353-380.

DROPMANN, KLAUS (1967). Electron microscopic findings in the carotid sinus of rabbits. In Baroreceptors and Hypertension. Ed. P. Kezdi, Pergamon, Oxford and London, pp. 267-272.

- DUNCAN, D. AND GARNER, C.M. (1957). An electron microscopic study of the carotid body. *Anat. Rec.*, 127: 285-286.
- DUNCAN, D. AND YATES, R. (1967). Ultrastructure of the carotid body of the cat as revealed by various fixatives and the use of reserpine. *Anat. Rec.*, 157: 667-682.
- EALLES, NELLIE B. (1926). The anatomy of the head of a foetal African elephant, *Elephas africanus* (*Loxodonta africana*). *Trans. R. Soc. Edin.*, 54: 491-551.
- ENGSTRÖM, H., HAMBERGER, C-A., HOLMER, M. AND RIGNELL, N.S. (1957). The carotid body. *Acta otolaryng.*, 48: 379-389.
- EVANS, D.H.L. AND MURRAY, J.G. (1954). Histological and functional studies on the fibre composition of the vagus nerve of the rabbit. *J. Anat., Lond.*, 88: 320-336.
- EYZAGUIRRE, C., KOYANO, H. AND TAYLOR, J.R. (1965). Presence of acetylcholine and transmitter release from carotid body chemoreceptors. *J. Physiol., Lond.*, 178: 463-476.
- EYZAGUIRRE, C. AND LEWIN, J. (1961). The effect of sympathetic stimulation on the carotid nerve activity. *J. Physiol., Lond.*, 159: 251-267.
- EYZAGUIRRE, C. AND UCHIZONO, K. (1961). Observations on the fibre content of nerves reaching the carotid body of the cat. *J. Physiol., Lond.*, 159: 268-281.
- EYZAGUIRRE, C. AND ZAPATA, P. (1968). A discussion of possible transmitter or generator substances in carotid body chemoreceptors. In *Arterial Chemoreceptors*. Ed. R.W. Torrance, Blackwell, Oxford and Edinburgh, pp. 213-251.
- FALCK, B. (1962). Observations on the possibilities of the cellular localization of monoamines by a fluorescence method. *Acta physiol. scand.*, 56: suppl. 197, 1.
- FALCK, B., HILLARP, N-Å., THIEME, G. AND TORP, A. (1962). Fluorescence of catecholamines and related compounds condensed with formaldehyde. *J. Histochem. Cytochem.*, 10: 348-354.

- FERIA-VELASCO, A., GONZALEZ, A.A. AND ZAVALA, Y. (1966). The submicroscopic structure of the normal carotid body in man. *Arch. mex. Anat.*, 1:33. (Cited by Feria-Velasco and Zavala, 1967.)
- FERIA-VELASCO, A. AND ZAVALA, B.J. (1967). Comparative ultrastructural study of two chemodectomas and normal chemoreceptors in the human. *Anat. Rec.*, 157: 243.
- FIDONE, S.J. AND SATO, A. (1969). A study of chemoreceptor and baroreceptor A and C⁻ fibres in the cat carotid nerve. *J. Physiol., Lond.*, 205: 527-548.
- FILLENZ, M. AND WOODS, R.I. (1966). Some observations on the rabbit carotid body. *J. Physiol., Lond.*, 186: 39-40 P.
- FLOYD, W.F. AND NEIL, E. (1952). The influence of sympathetic innervation of the carotid bifurcation on the chemoreceptor and baroreceptor activity in the cat. *Archs int. Pharmacodyn. Ther.*, 92: 230-239.
- FOOT, N.C. (1932). Two simple methods for the silver impregnation of nerve fibres in paraffin sections of central and peripheral nervous system. *Am. J. Path.*, 8: 769-775.
- FREWIN, D.B., HUME, W.R., WATERSON, J.G. AND WHELAN, R.F. (1972). The histochemical localization of sympathetic nerve endings in human gingival blood vessels. *Aust. J. exp. Biol. med. Sci.*, 49: 573-580.
- FUNKE, J. (1904). The carotid body: anatomy, histology, embryology and tumours arising from it. *Am. Med.*, 8: 109-115.
- GARNER, C.M. AND DUNCAN, D. (1958). Observations on the fine structure of the carotid body. *Anat. Rec.*, 130: 691-700.
- GERARD, MARGARET W. AND BILLINGSLEY, P.R. (1923). The innervation of the carotid body. *Anat. Rec.*, 25: 391-400.
- GOMEZ, L.P. (1908). The anatomy and the pathology of the carotid gland. *Am. J. med. Sci.*, 136: 98-110.

- GOMORI, G. (1950). Aldehyde-fuchsin - A new stain for elastic tissue. *Am. J. clin. Path.*, 20: 665-666.
- GOORMAGHTIGH, N. (1939). La structure glomique du glomus carotidien. *Acta brev. neerl.*, 9: 208-209. (Cited by Adams, 1958.)
- GORDON, H. AND SWEETS, H.H. JR. (1936). A simple method for silver impregnation of reticulum. *Am. J. Path.*, 12: 545-551.
- GREEN, J.H. (1953). A new baroreceptor area in the cat. *J. Physiol., Lond.*, 122: 70 P.
- _____ (1954). Further baroreceptor areas associated with the right common carotid artery in the cat. *J. Physiol., Lond.*, 123: 41 P.
- GRIMLEY, P.M. AND GLENNER, G.G. (1966a). Comparative fine structures of the human carotid body and related tumours. Sixth International Congress for electron microscopy, Kyoto, Japan. Vol. II. Maruzen Co., Ltd. Tokyo, Japan. (Cited by Grimley and Glenner, 1967.)
- _____ (1966b). Fine structure of the human carotid body. *J. Cell Biol.*, 31: 43A.
- _____ (1967). Histology and ultra-structure of the carotid body paragangliomas: comparison with the normal gland. *Cancer*, 20: 1473-1478.
- _____ (1968). Ultrastructure of the human carotid body. A perspective on the mode of chemoreception. *Circulation*, 37: 648-665.
- GUILLERY, R.W., SHIRRA, B. AND WEBSTER, K.E. (1961). Differential impregnation of degenerating nerve fibres in paraffin-embedded material. *Stain Technol.*, 36: 9-13.
- GURR, E. (1956). A Practical Manual of Medical and Biological Staining Techniques. Interscience, New York.

- HAM, A.W. (1969). Histology. 6th ed. Lippincott, Philadelphia and Montreal.
- HAMBERGER, B., RITZEN, M. AND WERSÄLL, J. (1966). Demonstration of catecholamines and 5-hydroxy-tryptamine in the human carotid body. *J. Pharmac. exp. Therap.*, 152: 197-201.
- HAMLIN, L.H. (1957). Application of the Nauta-Gygax technique for degenerating axons to mounted sections. *Stain Technol.*, 32: 123-126.
- HAMMOND, W.S. (1941). The development of the aortic arch bodies in the cat. *Am. J. Anat.*, 69: 265-293.
- HAYASHI, A. (1966). Studies of the carotid body and carotid sinus: fine structure of the carotid body. *J. Jap. Soc. internal. Med.* 55: 84-92. (Abstract in *Excerpta med.*, 21: 808A: 1967.)
- HERING, H.E. (1924). Der Sinus caroticus an der Ursprungsstelle der Caroticus interna als Ausgangsort eines hemmenden Herzreflexes und eines depressorischen Gefäßreflexes. *Münch. med. Wschr.*, 71: 701-704. (Cited by Adams, 1958.)
- _____ (1927). Die Karotissinusreflexe auf Herz und Gefäße vom normal-physiologischen, pathologisch-physiologischen Standpunkt. Steinkopff, Dresden. (Cited by Adams, 1958.)
- HESS, A. (1968). Electron microscopic observations of normal and experimental cat carotid bodies. In Arterial Chemoreceptors. Ed. R.W. Torrance, Blackwell, Oxford and Edinburgh, pp. 51-56.
- HEYMANS, C. (1929). *C.R. Soc. Biol. Paris*, 100: 196. (Cited by C. Heymans and E. Neil, 1958.)
- _____ (1955). Action of drugs on carotid body and sinus. *Pharmac. Rev.*, 7: 119-142.
- HEYMANS, C. AND NEIL, E. (1958). Reflexogenic Areas of the Cardiovascular System. Churchill, London.

- HEYMANS, C., DE SCHAPEDRYVER, A. AND DE VLEESCHHOUWER, G. (1968). Catecholamines and chemoreceptors. In Arterial Chemoreceptors. Ed. R.W. Torrance, Blackwell, Oxford and Edinburgh, pp. 263-266.
- HILGENBERG, F. (1958). Neurohistologische Studien über die Pressorezeptoren des Carotissinus bei Hypertoniker. *Acta Neurovegetativa*, 19: 1-14. (Cited by Hilgenberg, 1967.)
- _____ (1967). Neurohistologic studies of the carotid sinus baroreceptors in hypertension. In Baroreceptors and Hypertension. Ed. P. Kezdi, Pergamon, Oxford and London, pp. 293-297.
- HOFFMAN, H. AND BIRRELL, J.H.W. (1958). The carotid body in normal and anoxic states: an electron microscopic study. *Acta anat.*, 32: 297-311.
- HÖGLUND, R. (1967). An ultrastructural study of the carotid body of horse and dog. *Z. Zellforsch.*, 76: 568-576. (Abstract in *Excerpta med.*, 21: 3602A: 1967.)
- HOLLINSHEAD, W.H. (1939). The origin of the nerve fibres to the glomus aorticum of the cat. *J. comp. Neurol.*, 71: 417-426.
- _____ (1940a). Chromaffin tissue and paraganglia. *Quart. Rev. Biol.*, 15: 156-171.
- _____ (1940b). The innervation of the supracardial bodies in the cat. *J. comp. Neurol.*, 73: 37-48.
- _____ (1942a). A comparative study of the glomus coccygeum and the carotid body. *Anat. Rec.*, 84: 1-16.
- _____ (1942b). On the cytology of the carotid body of the cat. *Anat. Rec.*, 82: 486.
- _____ (1943). A cytological study of the carotid of the cat. *Am. J. Anat.*, 73: 185-213.
- _____ (1945). Effects of anoxia upon carotid body morphology. *Anat. Rec.*, 92: 255-261.

- _____ (1947). Chemoreceptors in the abdomen.
J. comp. Neurol., 74: 269-283.
- HOLLINSHEAD, W.H. AND SAWYER, C.H. (1945). Mechanisms of carotid body stimulation. Am. J. Physiol., 144: 79-86.
- HOLMES, W. (1942). A new method for the impregnation of nerve axons in mounted paraffin sections. J. Path. Bact., 54: 132-136.
- _____ (1943). Silver staining of nerve axons in paraffin sections. Anat. Rec., 86: 157-187.
- HUGHES, T. (1965). The microcirculation of baroreceptor areas. J. Anat., Lond., 99: 920-921 P.
- HUMASON, G.L. (1967). Animal Tissue Techniques. 2nd. ed., Freeman, San Francisco and London.
- HWANG, K., GROSSMAN, M.I. AND IVY, A.C. (1948). Nervous control of the cervical portion of the esophagus. Am. J. Physiol., 154: 343-357.
- ISHII, K. AND OOSAKI, T. (1966). Electron microscopy of the chemoreceptor cells of the carotid labyrinth of the toad. Nature, Lond., 212: 1499-1500.
- _____ (1969). Fine structure of the chemoreceptor cells in the amphibian carotid labyrinth. J. Anat., Lond., 104: 263-280.
- IWAYAMA, T., FURNESS, J.B. AND BURNSTOCK, G. (1970). Dual adrenergic and cholergic innervation of the cerebral arteries of the rat. Circulation Res., 26: 635-646.
- JONES, D.R. AND PURVES, M.J. (1969). Arterial chemoreceptors and the diving response in the duck. J. Physiol., Lond., 203: 41-42 P.
- _____ (1970). The carotid body in the duck and the consequences of its denervation upon the cardiac responses to immersion. J. Physiol., Lond., 211: 279-294.

- KARNAUCHOW, P.N. (1965). The carotid body: pathologist's view. *Can. med. Assoc. J.*, 92: 1298-1301.
- KARNOVSKY, M.J. (1965). A formaldehyde-glutaraldehyde fixative of high molarity for use in electron microscopy. *J. Cell Biol.*, 27: 137A.
- KEEN, W.W. AND FUNKE, J. (1906). Tumors of the carotid gland. *J. Am. med. Ass.*, 47: 469-479, 566-570.
- KEZDI, P. (1954). Control by the superior cervical ganglion of the state of contraction and pulsatile expansion of the carotid sinus wall. *Circulation Res.*, 2: 367-371.
- INOUCHE, H., ALFES, H., MÖLLMANN, H. AND REISCH, J. (1969). On the biogenic amines in the carotid body: identification of dopamine by mass spectrometry. *Experientia*, 25: 515-516.
- KOBAYASHI, S. (1968). Fine structure of the carotid body of the dog. *Archs. Histol. Jap.*, 30: 95-120. (Abstract in *Excerpta med.*, 23: 2080A: 1969.)
- _____ (1969a). On the fine structure of the carotid body of the bird, *Uroloncha domestica*. *Archs. Histol. Jap.*, 31: 9-19. (Abstract in *Excerpta med.*, 25: 247A: 1971.)
- _____ (1969b). Catecholamines in the avian carotid body. *Experientia*, 25: 1075-1076. (Cited by Biscoe, 1971.)
- KOBAYASHI, S., AND UEHARA, M. (1970). Occurrence of afferent synaptic complexes in the carotid body of the mouse. *Archs. Histol. Jap.*, 32: 193-201. (Abstract in *Excerpta med.*, 25: 1675A: 1971.)
- KOCH, E. (1931). Ergebnisse der Krieslaufforschung. Ed. B. Kisch. Steinkopff, Dresden and Leipzig: Bd. I - Die reflektorische Selbststeuerung des Krieslaufes. (Cited by Adams, 1958.)
- DE KOCK, L.L. (1951). Histology of the carotid body. *Nature, Lond.*, 167: 611-612.

- _____ (1954). The intra-glomerular tissues of the carotid body. *Acta anat.*, 21: 101-116.
- _____ (1956). The carotid body of the pilot-whale, *Globicephala melacna*. *Nature, Lond.*, 177: 1084-1085.
- _____ (1958). On the carotid body of certain birds. *Acta anat.*, 35: 161-178.
- _____ (1959). The carotid body system of the higher vertebrates. *Acta anat.*, 37: 265-279.
- _____ (1960). The sinusoids of the carotid body tissue as part of the reticulo-endothelial system. *Acta anat.*, 42: 213-226.
- DE KOCK, L.L. AND DUNN, A.E.G. (1964). Ultra-structure of carotid body tissue as seen in serial sections. *Nature, Lond.*, 202: 821-822.
- _____ (1966). An electron microscopic study of the carotid body. *Acta anat.*, 64: 163-178.
- _____ (1968). Electron-microscopic investigation of the nerve endings in the carotid body. In *Arterial Chemoreceptors*. Ed. R.W. Torrance, Blackwell, Oxford and Edinburgh, pp. 179-187.
- KOIZUMI, K. AND SATO, A. (1969). Influence of sympathetic innervation on carotid sinus baroreceptor activity. *Am. J. Physiol.*, 216: 321-329.
- KONDO, HISATAKE (1971). An electron microscopic study on innervation of the carotid body of guinea-pig. *J. Ultrastruct. Res.*, 37: 544-562.
- KRAUS, R. (1966). Cytology and cytochemistry of the chemoreceptor cells in man. *Folia Morphol.*, 14: 404-412.
- KRAUS, R. AND MARTINEK, J. (1967). A contribution to the cytology of the carotid body. *Folia Morphol.*, 15: 392-395.
(Abstract in *Excerpta med.*, 22: 2106A: 1968.)

- _____ (1968). Secretory manifestations of the glomus cells. *Folia Morphol., Praha*, 16: 388-390. (Abstract in *Excerpta med.*, 23: 382A: 1969.)
- KUNTZ, A. (1953). *The Autonomic Nervous System*. 4th ed., Lea and Febiger, Philadelphia.
- KUSHIRO, T. (1949). (Histological observation on the human carotid bodies.) *No Shinkei*, 1: 373-377. (In Japanese) (Cited by Adams, 1958.)
- LALL, A. (1969). Identification of Efferent Nerve Endings on the Type I Cell of the Carotid Body of the Cat. An Ultrastructural Study. Ph.D. Dissertation, University of California. (Cited by Biscoe, 1971.)
- LATTES, RAFFAELE (1950). Nonchromaffin paraganglioma of ganglion nodosum, carotid body, and aortic-arch bodies. *Cancer*, 3: 667.
- LEVER, J.D. AND BOYD, J.D. (1957). Osmiophile granules in the glomus cells of the rabbit carotid body. *Nature, Lond.*, 179: 1082-1083.
- LEVER, J.D., BOYD, J.D. AND LEWIS, P.R. (1957). The fine structure of the carotid body glomus cell in the rabbit. *J. Anat., Lond.*, 91: 594 P.
- LEVER, J.D., LEWIS, P.R. AND BOYD, J.D. (1959). Observations on the fine structure and histochemistry of the carotid body in the cat and rabbit. *J. Anat., Lond.*, 93: 478-490.
- LILJESTRAND, G. (1954). VI. The problem of transmission at chemoreceptors. *Transmission at chemoreceptors. Pharmac. Rev.*, 6: 73-78.
- LILJESTRAND, G. AND ZOTTERMAN, Y. (1954). The effect of certain choline esters on the chemoreceptor activity in the carotid body. *Acta physiol. scand.*, 31: 203-214.

- LILLIE, R.D. (1951). The allochrome procedure: A differential method segregating the connective tissues: collagen, reticulum and basement membranes into two groups. *Am. J. clin. Path.*, 21: 484-488.
- _____ (1954). Histopathologic Technic and Practical Histochemistry. McGraw-Hill, New York and Lond., pp. 357-358.
- MCCLOSKEY, D.I. (1970). Autoregulation of blood flow in the denervated carotid body of the cat. *J. Physiol.*, Lond., 40 P.
- MCCREA, E. D'ARCY (1924). The abdominal distribution of the vagus. *J. Anat.*, Lond., 59: 18-40.
- MAJNO, G. (1965). Ultrastructure of the vascular membrane. In Handbook of Physiology. Circulation. Ed. W.F. Hamilton and P. Dow, *Am. Physiol. Soc.*, Washington, D.C. Sect. 2 vol., III, pp. 2293-2375.
- MARTINEZ, G.M. (1939). Contribucion a la histologia normal y patologica del glomo carotideo. *Bol. Soc. Biol. Concepcion*, 13: 107-131.
- MASSON, P. (1929). Some histological methods. Trichrome stainings and their preliminary technique. *J. tech. meth. Bull. int. Ass. med. Mus.* 12: 75.
- MAY, N.D.S. (1964). The Anatomy of the Sheep. 2nd ed. University of Queensland Press, Brisbane.
- _____ (1965). The Anatomy of the Head and Neck of the Sheep with Special Consideration of the Vascular System and the Effects of Experimental Occlusions. Ph.D. Thesis, University of Queensland.
- _____ (1968). Experimental studies of the collateral circulation in the head and neck of sheep (Ovis aries). *J. Anat.*, Lond., 103: 171-181.

- MAZZELLA, H. AND MULLIN, R.G. (1956). Effects of removal of the superior sympathetic ganglion on carotid sinus. *Arch. int. Pharmacodyn.*, 107: 54-61. (Cited by Adams, 1958.)
- MEIJLING, H.A. (1938). Bau und Innervation von Glomus caroticum und Sinus caroticus. Eine Untersuchung unter Benutzung spezifischer Nervenfarbungs - methoden. *Acta neerl. morph.*, 1: 193-288. (Cited by Adams, 1958.)
- MILLS, E. AND SAMPSON, S.R. (1969). Respiratory responses to electrical stimulation of the cervical sympathetic nerves in decerebrate, unanaesthetized cats. *J. Physiol., Lond.*, 202: 271-282.
- MITCHELL, G.A.G. (1953). Anatomy of the Autonomic Nervous System. Livingstone, Edinburgh and London.
- _____ (1956). Cardiovascular Innervation. Livingstone, Edinburgh and London.
- MIZERES, N.J. (1955). The anatomy of the autonomic nervous system in the dog. *Am. J. Anat.*, 96: 285-318.
- MOLYNEUX, G.S. AND SCOTT, MARY J. (1966). The cytology of the carotid body in normal and hypoxic states. *J. Anat., Lond.*, 100: 942.
- MONCADA, A. AND SCHER, A.M. (1963). Reflex control of the sensitivity of the carotid baroreceptors. *Circulation Res.*, 28: 771.
- MORITA, E., CHIOCCHIO, R. AND TRAMEZZANI, J.H. (1969). Four types of main cells in the carotid body of the cat. *J. Ultrastruct. Res.*, 28: 399-410.
- _____ (1970). The carotid body of the Weddell seal (Leptonychotes weddelli). *Anat. Rec.*, 167: 309-328.

- MURATORI, G. (1933). Ricerche istologiche sull'innervazione del glomo carotico. *Archo ital. Anat. Embriol.*, 30: 573-602. (Cited by Adams, 1958.)
- _____ (1943). Ricerche anatomiche sulla vascolarizzazione sanguigna del glomo carotico. *Arch. Ist. biochim. ital.*, 15: 145-169. (Cited by Adams, 1958.)
- _____ (1967). Histological observations on the structure of the carotid sinus in man and mammals. In Baroreceptors and Hypertension, Ed. P. Kezdi, Pergamon, Oxford and London, pp. 253-265.
- MURPHY, M. AND HUGHES, T. (1965). A comparative study of the carotid sinus complex. *J. Anat., Lond.*, 99: 919-920 P.
- NAUTA, W.J.H. AND GYGAX, P.A. (1951). Silver impregnation of degenerating axon terminals in the central nervous system: (1) technic. (2) chemical notes. *Stain Technol.*, 26: 5-11.
- _____ (1954). Silver impregnation of degenerating axons in the central nervous system: A modified technic. *Stain Technol.*, 29: 91-93.
- NEIMI, M. AND GJALA, K. (1964). Cytochemical demonstration of catecholamines in the human carotid body. *Nature, Lond.*, 203: 539-540.
- NOMINA ANATOMICA VETERINARIA (1968). World Association of Veterinary Anatomists. Vienna, Austria.
- NONIDEZ, J.F. (1935a). The aortic (depressor) nerve and its associated epithelioid body, the glomus aorticum. *Am. J. Anat.*, 57: 259-301.
- _____ (1935b). The presence of depressor nerves in the aorta and carotid of birds. *Anat. Rec.*, 62: 47-73.
- _____ (1936). The nervous "terminal reticulum". A critique. I. Observations on the innervation of the blood vessels. *Anat. Anz.*, 82: 348-366. (Cited by Adams, 1958.)

- NORBERG, K.-A., AND HAMBERGER, B. (1964). The sympathetic adrenergic neuron. *Acta physiol. scand.*, 63: suppl. 238.
- OSTERMANN, E. (1952). Mikroskopische Untersuchungen über die Carotisdrüse des Rindes. Inaug. Diss., Mainz.
(Cited by Adams, 1958.)
- PAGTAKHAN, R.D., FARIDY, E.E. AND CHERNICK, V. (1971). Interaction between arterial PO_2 and PCO_2 in the initiation of respiration of foetal sheep. *J. appl. Physiol.*, 30: 382.
- PAINTAL, A.S. (1969). Further evidence that acetylcholine is not a transmitter at chemoreceptors. *J. Physiol., Lond.*, 204: 94 P.
- PALKAMA, A. (1965). Histochemistry and electron microscopy of the carotid body. *Annls Med. exp. Biol. Fenn.*, 43: 260-266. (Abstract in *Excerpta med.*, 20: 4346A: 1966.)
- PALKAMA, A. AND HOPUSU, V.K. (1965). The presence of a carotid body-like tissue between the right subclavian and common carotid arteries. *Annls Med. exp. Fenn.*, 43: 169-173. (Abstract in *Excerpta med., Sect. I., Anatomy*, 20: 3368A: 1966.)
- PALM, F. (1943). Zur Funktion der branchiogenen Reflexzonen für Chemo- und Pressorezeption. *Z. ges. exp. Med.*, 113: 415-461. (Cited by Rees, 1967a.)
- PALUMBI, G. (1940). La fine vascolarizzazione ed innervazione del glomo carotideo dei mammiferi. *Comment. pontif. Acad. Sci.*, 4: 289-320. (Cited by Adams, 1958.)
- PATTERSON, E.L. (1950). Sources of arterial blood supply to the superior and middle cervical sympathetic ganglia and the ganglion intermediaire. *J. Anat., Lond.*, 84: 329-341.

- PERMAN, - (1916). Arkiv f. Zool. Stockholm, vol. X, No.11.
(Cited by McCrea, 1924.)
- PETERSON, L.H. (1962). Properties and behaviour of living vascular wall of blood vessels. *Physiol. Rev.*, 42: suppl. 5, p. 309.
- PETERSON, L.H., FEIGL, E. AND GOURAS, P. (1960). Properties of the carotid sinus mechanism. *Fedn. Proc. Fedn. Am. Socs exp. Biol.*, 19: 40.
- PFÖRTNER, - (1869). Untersuchungen über das Ganglion intercaroticum und die Nebenniere. *Z. rat. Med.*, Ser. III, 34: 240-256. (Cited by Adams, 1958.)
- PICK, J. (1959). The discovery of the carotid body. *J. Hist. Med. Sci.*, 14: 61-73.
- POPESKO, P. (1970). Atlas of Topographical Anatomy of the Domestic Animals. Translation by R. Getty, Saunders, Philadelphia and London.
- PRYSE-DAVIES, J., DAWSON, I.M.P. AND WESTBURY, G. (1964). Some morphologic, histochemical and chemical observations on chemodectomas and the normal carotid body, including a study of chromaffin reaction and possible ganglion cell elements. *Cancer*, 17: 185-202.
- PURVES, M.J. (1969a). Changes in oxygen consumption of the carotid body of the cat. *J. Physiol., Lond.*, 200: 132-133 P.
- _____ (1969b). Carotid body blood flow and oxygen usage in the cat. *J. Physiol., Lond.*, 202: 1P.
- _____ (1970). The role of the cervical sympathetic nerve in the regulation of oxygen consumption of the carotid body of the cat. *J. Physiol., Lond.*, 209: 417-421.

- RASARIO, G.M. (1937). *Richerche isto-patologiche sul glomo carotideo*. *Minerva Med.*, Torino, 28: 4-13. (Cited by Adams, 1958.)
- REES, P.M. (1966). *Morphological Basis for the Carotid Sinus Baroreceptor Reflex*. Ph.D. Thesis, University of Wales, Cardiff, U.K.
- _____ (1967a). The distribution of biogenic amines in the carotid bifurcation region. *J. Physiol., Lond.*, 193: 245-253.
- _____ (1967b). Observations on the fine structure and distribution of presumptive baroreceptor nerves. *J. comp. Neurol.*, 131: 517-548.
- _____ (1968). Electron microscopical observations on the architecture of the carotid arterial walls, with special reference to the sinus portion. *J. Anat., Lond.*, 103: 35-47.
- REES, P.M. AND JEPSON, P. (1970). Measurement of arterial geometry and wall composition in the carotid sinus baroreceptor area. *Circulation Res.*, 26: 461-467.
- REIS, D.J. AND FUXE, K. (1968). Adrenergic innervation of the carotid sinus. *Am. J. Physiol.*, 215: 1054-1057.
- REYNOLDS, E.S. (1963). The use of lead citrate of high pH as an electron-opaque stain in electron microscopy. *J. Cell Biol.*, 17: 208-212.
- RIEGELE, L. (1928). *Die Nerven des Glomus caroticum beim Menschen mit kurzer Übersicht über den histologischen Aufbau des Organs*. *Z. ges. Anat. 1. Z. Anat. EntwGesch.*, 86: 142-167. (Cited by Adams, 1958.)
- RIISAGER, M. AND WEDDELL, G. (1962). Nerve terminations in the human carotid sinus, variation in structure in the age group 52-80 years. *J. Anat., Lond.*, 96: 25-38.

- RIJNDERS, H. (1933). Über das Nervenmaterial in der Wand des Bulbus caroticus. *Acta brev. neerl. physiol.*, 3: 22-24. (Cited by Adams, 1958.)
- ROGERS, D.C. (1965). The development of rat carotid body. *J. Anat., Lond.*, 99: 89-101.
- ROGERS, W.M. (1931). New silver methods for paraffin sections. *Anat. Rec.*, 49: 81-87.
- ROMANES, G.J. (1950). The staining of nerve fibres in paraffin sections with silver. *J. Anat., Lond.*, 84: 104-115.
- ROMEIS, B. (1948). *Mikroskopische Technik*. Leibniz, München. (Cited by Humason, 1967.)
- ROSS, L.L. (1957a). An electron microscopic study of carotid body chemoreceptors. *Anat. Rec.*, 127: 481A.
- _____ (1957b). A cytological and histochemical study of the carotid body of the cat. *Anat. Rec.*, 129: 433-455.
- _____ (1959). Electron microscopic observations of the carotid body of the cat. *J. biophys. biochem. Cytol.*, 6: 253-262.
- ROSS, L.L. AND HUNT, T.E. (1954). Histochemical study of the carotid body of the rat and cat. *Anat. Rec.*, 118: 436.
- SAMARASINGHE, D.D. (1965). The innervation of the cerebral arteries in the rat: an electron microscope study. *J. Anat., Lond.*, 99: 815-828.
- SAMPSON, S.R. AND MILLS, E. (1970). Effects of sympathetic stimulation on discharges of carotid sinus baroreceptors. *Am. J. Physiol.*, 218: 1650-1653.
- SATO, S. (1932). (Morphologische Untersuchungen über die Carotis-Drüsen bei Wirbeltieren und beim Menschen.) *Igaku Kenkyuu, Fukuoka*, 6: 707-811. (In Japanese: abstract in *Jap. J. med. Sci., I. Anat.*, 5/ii: abstracts pp. 82-83: 1934.) (Cited by Adams, 1958.)

- SCHAFER, E.S., SIR (1929). The Essentials of Histology. Descriptive and Practical for the Use of Students. Longmans Green, London.
- SCHAFER, A. (1892). Beiträge zur Histologie der Glandula carotica. Arch. mikr. Anat., 40: 287-320. (Cited by Adams, 1958.)
- SCHMIDT, C.F. AND COMROE, J.H., JR. (1940). Functions of the carotid and aortic bodies. Physiol. Rev., 20: 115-157.
- SMITH, CHRISTIANNA (1924). The origin and development of the carotid body. Am. J. Anat., 34: 87-131.
- SPRIGGS, T.L.B., LEVER, J.D., REES, P.M. AND GRAHAM, J.D.P. (1966). Controlled formaldehyde-catecholamine condensation in cryostat sections to show adrenergic nerves by fluorescence. Stain Technol., 41: 323-327.
- STILLING, H. (1892). Du Ganglion Intercarotidien. Inaug. Diss., Lausanne. Trav. Fac. Univ. Lausanne, pp. 321-331. (Cited by Adams, 1958.)
- STÖHR, P., JR. (1950). Innervation der Blutgefäße. Nauheimer Fortbildungs-Lehrgänge, 15: 1-4. (Cited by Adams, 1958.)
- _____ (1951). Lehrbuch der Histologie und der mikroskopischen Anatomie des Menschen. Springer, Berlin, Göttingen and Heidelberg. (Cited by Adams, 1958.)
- _____ (1957). Mollendorffs Handbuch der mikroskopischen Anatomie des Menschen. Ed. W. Bergmann. Springer, Berlin, Göttingen and Heidelberg. Bd. IV/5 - Mikroskopische Anatomie des vegetativen Nervensystems. (Cited by Adams, 1958.)
- STORY, H. ELIZABETH (1951). The carotid arteries in the Procyonidae. Fieldiana, Zool., 32: 475-557.

- SUNDER-PLASSMANN, P. (1930). Untersuchungen über den Bulbus carotidis bei Mensch und Tier im Hinblick auf die "Sinusreflexe" nach H.E. Hering; ein Vergleich mit anderen Gefäßstrecken; die Histopathologie des Bulbus carotidis; das Glomus caroticum. Z. ges. Anat. 1. Z. Anat. EntwGesch., 23: 567-622.
- _____ (1933). Der Nervenapparat des Sinus caroticus und des Glomus caroticum vom Menschen der verschiedenen Altersstufen und Foetus humanus von verschiedenen Tieren und von Kaninchen vor und nach Durchschneidung des Sinusnerven. Verh. dtsh. Ges. Krieslaufforsch., 1933: 69-78. (Cited by Adams, 1958.)
- TAYEB, M.A.F. (1951). A study on the blood supply of the camel's head. Br. vet. J., 107: 147-155.
- TCHIBUKMACHER, N.B. (1938). Surgical anatomy of carotid sinus nerve and intercarotid ganglion. Surg. Gynec. Obstet., 67: 740-745.
- TORRANCE, R.W. (1968). Prolegomena. In Arterial Chemoreceptors. Ed. R.W. Torrance, Blackwell, Oxford and Edinburgh, pp. 1-40.
- TRAMEZZANI, J.H., MORITA, E. AND CHIOCCHIO, S.R. (1971). The carotid body as a neuroendocrine organ involved in the control of erythropoiesis. Proc. Nat. Acad. Sci., 68: 52-55.
- UNGEWITTER, L.H. (1951). A urea silver nitrate method for nerve fibres and nerve endings. Stain Technol., 26: 73-76.
- VAUGHAN, I. (1895). Ed. Strangeways' Veterinary Anatomy. 5th ed. Bell and Bradfute, Edinburgh.
- WAITES, G.M.H. (1960). The influence of the occipito-vertebral anastomoses on the carotid sinus reflex of the sheep. Q. J. exp. Physiol., 45: 243- 251.

- WATSON, M. (1874). Contributions to the anatomy of the Indian elephant, Part IV. Muscles and blood vessels of the face and head. *J. Anat., Lond.*, 9: 118-133.
- WATZKA, M. (1943). Handbuch der mikroskopischen Anatomie des Menschen. Ed. W. von Möllendorff. Springer-Verlag, Verlin. VI/4 Die Paraganglien, pp. 262-308. (Cited by Adams, 1958.)
- WHITE, E.G. (1935). Die Struktur des Glomus caroticum, seine Beziehung zum Nervensystem. *Beitr. path. Anat.*, 96: 177-227. (Cited by Adams, 1958.)
- WILLIS, A.G. AND BIRRELL, J.W.H. (1955). The structure of a carotid body tumour. *Acta anat.*, 25: 220-265.
- WILLIS, A.G. AND TANGE, J.D. (1959a). Studies on the innervation of the carotid sinus of man. *Am. J. Anat.*, 104: 87-114.
- _____ (1959b). The argentophil cells of the human carotid body. *Am. J. Anat.*, 105: 141-163.
- WINDER, C.V. (1937). On the mechanism of stimulation of carotid gland chemoreceptors. *Am. J. Physiol.*, 118: 389-398.
- WINKELMANN, R.K. (1959). A hydroxyl-dependent silver method for nerve axoplasm. *J. Stain Technol.*, 34: 193-195.
- WINKELMANN, R.K. AND SCHMIT, R.W. (1957). A simple silver method for nerve axoplasm. *Staff Meet., Mayo Clin.*, 32: 217-222.
- WITTER, R.L. (1950). A comparative study of the gross and microscopic anatomy of the carotid body in six species. *Mich. St. Univ. Vet.*, 20: 12-18.
- ZAPATA, P., HESS, A., BLISS, E.L. AND EYZAGUIRRE, C. (1969a). Chemical, electron microscopic and physiological observations on the role of catecholamines in the carotid body. *Brain Res.*, 14: 473-496.

ZAPATA, P., HESS, A. AND EYZAGUIRRE, C. (1969b). Reinnervation of the carotid body and carotid sinus with superior laryngeal nerve fibers. *J. Neurophysiol.*, 32: 215-228.