

Copyright is owned by the Author of the thesis. Permission is given for a copy to be downloaded by an individual for the purpose of research and private study only. The thesis may not be reproduced elsewhere without the permission of the Author.

A STUDY OF FOOT ABSCESS
IN SHEEP

A THESIS PRESENTED IN PARTIAL FULFILMENT
OF THE REQUIREMENTS FOR THE DEGREE OF
DOCTOR OF PHILOSOPHY AT MASSEY UNIVERSITY

DAVID MICHAEL WEST
1981

ABSTRACT

A study was made of various aspects of 53 naturally occurring cases of foot abscess in sheep. Radiographic techniques were used to follow the progress of the lesion and from this, and a study of the anatomy of the digits, it was concluded that foot abscess of sheep could be defined as an infection of the distal interphalangeal joint. For this reason the term 'foot abscess' was considered to be preferable to the term 'infective bulbar necrosis' (Roberts *et al.*, 1968).

Support was given to the contention of Roberts *et al.* (1968) that *Fusobacterium necrophorum* and *Corynebacterium pyogenes* are the causative organisms of foot abscess. Both organisms were frequently isolated from naturally occurring cases, and an identical condition was reproduced in seven sheep by inoculating a mixture of *F. necrophorum* and *C. pyogenes* organisms into the distal interphalangeal joint. It appeared likely that relatively greater numbers of either organism in pure culture were required to reproduce foot abscess by this means, than by using a mixture of the two organisms.

To help evaluate the significance of foot abscess to New Zealand sheep farmers, a postal survey of New Zealand Romney sheep breeders was conducted. Foot abscess was reported to occur in 270 (77 percent) of the 351 respondents' flocks, but the incidence of foot abscess within a flock was low. Foot abscess was considered an important disease by sheep farmers because of the unexpected nature of outbreaks at critical times in the farming calendar, and the unsatisfactory nature of treatment and prevention. The *F. necrophorum* vaccine was

used by a third of the farmers that reported having cases of foot abscess in their flocks and many farmers were either dissatisfied with, or unsure of its effectiveness.

The attack rate of foot abscess was reported to be higher for rams than for ewes. A possible explanation for this was advanced following the investigation of an outbreak of ovine interdigital dermatitis and foot abscess affecting 100 individuals out of 300 young rams on a Perendale stud property.

From a study of the anatomy of the digits it was concluded that the distal interphalangeal joint of sheep was vulnerable to infection or trauma on the interdigital aspect where the joint capsule protruded above the coronary border of the hoof as the dorsal and volar pouches. Foot abscess was reproduced in 39 digits of 20 sheep, following interdigital tissue damage by the application of liquid nitrogen to the interdigital skin, combined with the exposure of the feet to wet, faeces-contaminated conditions. It was suggested that this simulated what happens in natural outbreaks of ovine interdigital dermatitis and foot abscess.

Ovine interdigital dermatitis responded readily to the combined therapeutic measures of dry surroundings, formalin foot bathing and selected antibiotic therapy. In contrast, once infection became established in the distal interphalangeal joint (foot abscess), the above treatment was no longer effective. Permanent joint damage with deformity was inevitable, but the effects of this was reduced if the axial collateral ligaments remained intact. The foot healed sufficiently to allow for adequate locomotion after a period of about two months. It was possible, using radiographic techniques to assess if the distal interphalangeal joint was infected, the approximate duration of the joint infection, and the likely degree of permanent damage and deformity.

ACKNOWLEDGEMENTS

I wish to thank my supervisors for their help, interest and encouragement during this work. In particular I thank Professor A.N. Brueère for giving me the opportunity to undertake this study and for his enthusiasm and optimism that the project would reach this stage. I am grateful also, for the guidance of Dr B.S. Cooper and his helpful advice in the preparation of this manuscript.

I gratefully acknowledge the competent technical assistance of Lynne Cullinane who performed the microbiological examinations and provided the bacterial cultures.

My thanks go to the many people in the Veterinary Faculty who have assisted with discussion and technical advice, particularly Dr R. Marshall and Dr R. Wyburn.

I wish also to thank Tom Law who photographed and printed most of the figures in the thesis, and the staff of the Veterinary Hospital, particularly Cedric Barnett, for technical assistance and care of the sheep.

I am grateful to Val Darroch, Veronica Lobb and Alison Cleaver for typing and Karen Armitage for assistance in the preparation of this manuscript.

TABLE OF CONTENTS

	Page
Abstract	
Acknowledgements	
List of tables	
List of figures	
 <u>CHAPTER 1</u>	
Review of the literature	1
 <u>CHAPTER 2</u>	
A survey of New Zealand Romney sheep breeders, concerning some aspects of foot abscess	22
 <u>CHAPTER 3</u>	
Anatomical considerations of the distal interphalangeal joint of sheep	38
 <u>CHAPTER 4</u>	
A study of naturally occurring cases of ovine foot abscess	52
 <u>CHAPTER 5</u>	
Investigation of a flock outbreak of dermatitis, necrosis and erosion of the interdigital skin, resulting in some cases of foot abscess.	81
 <u>CHAPTER 6</u>	
The experimental reproduction of foot abscess by the inoculation of bacterial cultures into the distal interphalangeal joint of sheep	101
 <u>CHAPTER 7</u>	
The experimental reproduction of foot abscess by damaging the interdigital tissues of sheep	133
 <u>CHAPTER 8</u>	
Summary and conclusions	168
 <u>REFERENCES</u>	172

LIST OF TABLES

<u>Table</u>		<u>Page</u>
2.I	The percentage of respondents reporting foot abscess cases	27
2.II	The percentage of respondents reporting the occurrence of foot abscess in different classes of sheep	28
2.III	The seasonal occurrence of foot abscess	28
2.IV	Factors considered by respondents to predispose to foot abscess	29
2.V	Treatment of foot abscess cases	30
2.VI	Prognosis of foot abscess cases	31
2.VII	The effectiveness of <i>Fusobacterium necrophorum</i> vaccine	32
4.1	The number of sheep with foot abscess, admitted to the Veterinary Hospital during the years 1974 to 1978, according to season	60
4.II	The breed and age of sheep with foot abscess admitted to the Veterinary Hospital	60
4.III	The distribution of the digit affected with foot abscess amongst sheep admitted to the Veterinary Hospital	61
4.IV	Isolations of <i>Fusobacterium necrophorum</i> and <i>Corynebacterium pyogenes</i> from sheep with foot abscess	65
5.I	The occurrence of new cases of lameness in relation to the daily rainfall and management procedures	85
5.II	The occurrence of lameness associated with necrosis and erosion of the interdigital skin	87
6.I	The reaction to the inoculation of <i>Fusobacterium necrophorum</i> organisms into the distal interphalangeal joint of sheep	107

<u>Table</u>		<u>Page</u>
6.II	The reaction to the inoculation of <i>Corynebacterium pyogenes</i> organisms into the distal interphalangeal joint of sheep.	114
6.III	The reaction to the inoculation of a mixture of <i>Fusobacterium necrophorum</i> and <i>Corynebacterium pyogenes</i> organisms into the distal interphalangeal joint of sheep.	123
7.I	The schedules of treatments used to assess methods of interdigital tissue damage	139
7.II	The digits that developed infection in the distal interphalangeal joint following liquid nitrogen treatment	142
7.III	The site of application of liquid nitrogen	154
7.IV	Schedules of treatments used to reproduce foot abscess	154
7.V	Reproduction of foot abscess following liquid nitrogen damage to the interdigital tissues.	157.

LIST OF FIGURES

<u>Figure</u>		<u>Page</u>
2.1	Foot abscess survey	25
2.2	'Veterinary regions' of the New Zealand Ministry of Agriculture and Fisheries	26
3.1a	The digit of a Romney ewe, radiographed immediately following the injection of 0.75ml of meglumine lothalamate into the dorsal pouch of the distal inter- phalangeal joint	43
3.1b and c	The digit of a Romney ewe, radio- graphed immediately following the injection of 0.5ml of meglumine lothalamate into b) the volar pouch and c) the dorsal pouch of the distal interphalangeal joint.	44
3.2a b and c	The serial dissection of the axial aspect of a sheeps digit, following the injection of latex into the distal interphalangeal joint	45
3.3	Dissection of the axial aspect of the left fore lateral digit of a Romney ewe.	46
3.4	Sesamoidean ligaments of the distal interphalangeal joint of sheep (abaxial aspect)	47
3.5	Sesamoidean ligaments of the distal interphalangeal joint of sheep (volar aspect)	48
3.6	Dorsal and collateral ligaments of the distal interphalangeal joint of sheep	49
4.1a and b	The two positions of the foot and the direction of the X-ray beam during radiology	56
4.2a and b	The left fore foot of a Perendale ram which had developed foot abscess in the lateral digit, presumably as a consequence of overparing of the hoof by the owner	58-

<u>Figure</u>		<u>Page</u>
4.3a b and c	The left fore foot of a Perendale ram with foot abscess of the lateral digit. Seven days previously pus had been observed imprisoned in the lamellar region of the toe.	59
4.4a and b	The right hind foot of a Perendale ram affected with foot abscess in the lateral digit	66
4.5a and b	The left hind foot of a Cheviot ram with foot abscess of the lateral digit	67
4.6	The left hind foot of a Perendale ram with foot abscess of the lateral digit.	68
4.7	The left hind foot of a Perendale ram with foot abscess of the lateral digit.	69
4.8	The left hind foot of a Perendale ram, photographed 16 days after foot abscess was first noticed.	70
4.9a and b	The left fore foot of a Cheviot ram, photographed 14 days after foot abscess was first noticed	71
4.10a b and c	Radiographs of the left hind foot of a Perendale ram with foot abscess of the lateral digit	72
4.11	Radiograph of the left hind foot of a Perendale ram with foot abscess of the lateral digit	73
4.12a b c and d	Radiographs of the left hind foot of a Perendale ram with foot abscess of the medial digit	74
4.13a b c and d	Radiographs of the left hind foot of a Cheviot ram with foot abscess of the lateral digit	75
5.1 a and b	Ram hoggets grouped together	89
5.2 a b c d e f g h and i	Photographs of the interdigital space of Perendale ram hoggets affected with ovine interdigital dermatitis	90, 91, 92
5.3	Radiograph of a sheep's foot affected with ovine interdigital dermatitis	93

<u>Figure</u>		<u>Page</u>
5.4a b c and d	Radiographs of the feet of four sheep in which the infection associated with ovine interdigital dermatitis had invaded the deeper tissues of the foot	94
6.1a b c and d	The right hind foot of sheep number 4 following the inoculation of approximately 10^{10} <i>Fusobacterium necrophorum</i> organisms into the distal interphalangeal joint of the medial digit	110
6.2a and b	The right hind foot of sheep number 5 a) 17 days and b) 14 days after the inoculation of approximately 10^{10} <i>Fusobacterium necrophorum</i> organisms into the distal interphalangeal joint of the medial digit	111
6.3a b c and d	Radiographs of the right hind foot of sheep number 4 following the inoculation of approximately 10^{10} <i>Fusobacterium necrophorum</i> organisms into the distal interphalangeal joint of the medial digit	112
6.4a and b	The left hind foot of a) sheep number P.1 and b) sheep number P.2, seven days after the inoculation of approximately 6×10^8 <i>Corynebacterium pyogenes</i> organisms into the distal interphalangeal joint of the medial digit.	117
6.5	Radiograph of the left hind foot of sheep number P.1, nine days after the inoculation of approximately 6×10^8 <i>Corynebacterium pyogenes</i> organisms into the distal interphalangeal joint of the medial digit.	118
6.6	Radiograph of the left fore foot of sheep number 9, 19 days after the inoculation of approximately 4×10^7 <i>Corynebacterium pyogenes</i> organisms into the distal interphalangeal joint of the lateral digit.	119
6.7a b and c	The left fore foot of sheep number 11 following the inoculation of approximately 2×10^9 <i>Corynebacterium pyogenes</i> organisms into the medial digit.	120

<u>Figure</u>		<u>Page</u>
6.8a b c and d	Radiographs of the left hind foot of sheep number 10 following the inoculation of approximately 2×10^9 <i>Corynebacterium pyogens</i> organisms into the distal interphalangeal joint of the medial digit.	121
6.9a b c d e and f	Gross changes of the left hind foot of sheep number P.5, following the inoculation of <i>Fusobacterium necrophorum</i> and <i>Corynebacterium pyogenes</i> organisms into the distal interphalangeal joint of the lateral digit.	125
6.10a b c d e and f	Gross changes of the left hind foot of sheep number P.6, following the inoculation of <i>Fusobacterium necrophorum</i> and <i>Corynebacterium pyogenes</i> organisms into the distal interphalangeal joint of the medial digit.	126
6.11a b c d e and f	Radiographically visible changes of the left hind foot of sheep number P.5, following the inoculation of <i>Fusobacterium necrophorum</i> and <i>Corynebacterium pyogenes</i> organisms into the distal interphalangeal joint of the lateral digit.	127
6.12a b c d e and f	Radiographically visible changes of the left hind foot of sheep number P.6, following the inoculation of <i>Fusobacterium necrophorum</i> and <i>Corynebacterium pyogenes</i> organisms into the distal interphalangeal joint of the medial digit.	128
7.1	A section of the pen which was covered to a depth of 3 cm with a slurry of wet faeces	137
7.2a b and c	The application of liquid nitrogen to the interdigital space of sheep	138
7.3	The interdigital space three days after liquid nitrogen had been applied to the interdigital skin.	144
7.4a and b	The interdigital space of two sheep, eight days after liquid nitrogen had been applied to the interdigital skin.	145

7.5a b and c	The right fore foot of the sheep number 2, following the application of liquid nitrogen to the interdigital skin.	146
7.6a b and c	Radiographs of the feet of sheep, 27 days after liquid nitrogen had been applied to the interdigital skin	147
7.7	The site of application of the liquid nitrogen	152
7.8a b and c	The right fore foot of sheep number 7, after the application of liquid nitrogen to the interdigital skin.	159
7.9a b and c	The right hind foot of sheep number 7, after the application of liquid nitrogen to the interdigital skin.	160
7.10a b and c	The right hind foot of sheep number 6, after the applications of liquid nitrogen to the interdigital skin	161
7.11a b and c	The left hind foot of sheep number 16, after the application of liquid nitrogen to the interdigital skin.	162
7.12a and b	The left hind foot of sheep number 15, after the application of liquid nitrogen to the interdigital skin .	163

CHAPTER 1

REVIEW OF THE LITERATURE

DEFINITION

DIFFERENTIAL DIAGNOSIS

ECONOMIC IMPORTANCE, INCIDENCE AND PREVALENCE

AETIOLOGY

1. The causative organisms
2. Predisposing factors

TREATMENT

PROGNOSIS

PREVENTION

DEFINITION

Foot abscess is an acute purulent infection usually involving one digit of the foot (Gregory, 1939). Infection is presumed to start in the interdigital space (Gregory, 1939; Roberts, Graham, Egerton and Parsonson, 1968), and extend into the deeper structures of the digit to involve the tendons and ligaments of the joints (Murnane, 1933). The soft tissues just above the coronet on the abaxial aspect become distended with pus, and pressure on this area expresses pus from the original lesion in the interdigital space (Gregory, 1939). In the latter stages pus and sometimes necrotic material such as portions of ligaments are discharged from the sinuses at either the coronet or the interdigital space. The development of excessive granulation tissue is frequently encountered particularly in the interdigital space. Eventually the bacterial infection subsides but with resolution considerable fibrosis may occur, and the digit remains swollen and restricted in movement (Egerton and Graham, 1969).

Historical

Much of the literature on diseases of sheep's feet has been devoted to footrot. The condition was shown by Beveridge (1941) and Roberts and Egerton (1969) to be caused by the specific transmitting agent *Bacteroides nodosus* (*B. nodosus*) in association with other organisms particularly *Fusobacterium necrophorum* (*F. necrophorum*).

Murnane (1933) described two types of 'footrot', one of which was the common subacute form which frequently passed to a chronic state, and the other was the less common, acute or malignant type. Gregory (1939) advanced the view that from both the clinical and bacteriological points of view these two conditions were distinct entities. For the less common acute type, Gregory (1939) proposed the name 'digital suppuration' which was descriptive of the extensive pyogenic processes usually involving one digit only. In most of the

cases he studied, the organism of importance was *F. necrophorum* although *Escherichia coli* (*E. coli*) and *Corynebacterium pyogenes* (*C. pyogenes*) were sometimes cultured and sometimes observed in smears of exudate.

The term foot abscess gradually took the place of digital suppuration, but this description included lesions of both the lamellar and bulbar regions of the foot (Deane, Davis, Epling and Jensen, 1955). The observations of Roberts, Graham, Egerton and Parsonson (1968) suggested that these were two separate conditions, viz. 'toe abscess' affecting the lamellae and 'heel abscess' affecting the bulbar soft tissues. The most common and important form, 'heel abscess' they renamed infective bulbar necrosis and found that it occurred most often in the hind feet of lambing ewes and rams during cool, wet periods. Their experiments suggested that it was probably a true mixed infection involving the inter-related action of *F. necrophorum* and *C. pyogenes*.

In contrast to Murnane (1933), Gregory (1939) and Beveridge (1941); Roberts *et al.* (1968) considered the bulbar soft tissue to be the major site of the infection and their clinical description did not include lesions of either joints or ligaments.

DIFFERENTIAL DIAGNOSIS

Toe abscess (lamellar suppuration)

Confusion has arisen because toe abscess, like foot abscess, is an acute suppurative condition commonly affecting only one digit.

Toe abscess is a less common condition that occurs mainly at the toe in the front feet. Exposure of the sensitive lamellae often due to breakage of overgrown horn or separation of the wall following laminitis (Egerton and Graham, 1969) may result in opportunist infection. In the majority of cases the earliest sign of infection is an acute

lameness, so painful that the animal refuses to bear any weight on the leg. Examination may fail to reveal any obvious lesion but generally one claw is found to be hot and pressure applied to the wall causes the animal to flinch. Careful paring away of the horn at the toe reveals the presence of imprisoned pus. If the original site of injury on the plantar surface becomes sealed by mud, faeces or exudate, infection can track upwards and produce a sinus above the coronet.

Foot abscess, footrot and toe abscess can occur simultaneously in a flock, in the same sheep, and even in the same foot (Belschner, 1939).

Footrot

"Footrot is a contagious disease of the sheep's foot characterised by separation of a large portion of the hoof from the soft tissues due to a spreading infection immediately beneath the horn" (Eeveridge, 1941).

The infection commences in the interdigital skin, and horn separation is often seen first in the angle of the heels, but later extends forwards under the plantar surface and walls. In uncomplicated cases there is little suppuration. Both digits of the foot are invariably affected, each sheep often having more than one, but rarely all four feet involved. Footrot is a flock disease and under suitable environmental conditions may spread rapidly until over 90 percent of the flock becomes infected. Footrot can be differentiated from foot abscess because of the separation of the horn, the minimal swelling and suppuration, the characteristic odour, the general bilateral involvement of the digits, and under suitable conditions, the rapid spread of the infection to involve other sheep in the flock. Confirmation of footrot is dependant on demonstrating the presence of *B. nodosus*.

Scald

This term has been used in the past to describe any interdigital dermatitis. Interdigital dermatitis caused by *F. necrophorum* is now called ovine interdigital dermatitis (Parsonson, Egerton and Roberts, 1967), and interdigital dermatitis that is restricted to the interdigital integument, and caused by strains of *B. nodosus* is now called benign or non-progressive footrot (Thomas, 1962; Egerton, Roberts and Parsonson, 1969).

Murnane (1933) referred to a condition in sheep running on wet or swampy country which closely resembled the early stages of footrot. It readily responded to formalin footbathing and sometimes cleared up spontaneously, especially under drier conditions. Engel (1933) and Snowdon (1953) observed a similar condition that developed in footrot-free flocks after heavy frosts. In Britain this condition has also been referred to as 'Scad' (Anon., 1969). The picture was somewhat confused by Thomas (1962) who made a very worthy study of non-progressive footrot and the organism that caused it, but described the disease as 'scald'. Finally, Parsonson *et al.* (1967) studied 'scald' in six footrot-free flocks in South Eastern Australia. They showed the disease to be an acute necrotising infection restricted mainly to the posterior interdigital skin and associated with epidermal invasion by *F. necrophorum*. Experimental infection with *F. necrophorum* was dependent on prior skin damage induced, either by prolonged water maceration, or by scarifying the interdigital skin (Parsonson *et al.*, 1967; Egerton *et al.*, 1969). Numerous diphtheroid bacteria including *C. pyogenes* were found at the skin surface by Parsonson *et al.* (1967) and they suggested that these would assist the establishment and invasion of *F. necrophorum* by using oxygen, decreasing the Eh, and producing catalase. This newly defined condition was named ovine interdigital dermatitis.

Ovine interdigital dermatitis and foot abscess have been observed to occur within a flock at the same time (Roberts *et al.*, 1968), and it was suggested by Egerton, Roberts, Graham and Parsonon (1966) that ovine interdigital dermatitis precedes and predisposes to foot abscess. Only during the transitional stage should clinical differentiation pose any difficulties; at other times the confinement of ovine interdigital dermatitis to the interdigital space differentiates it from foot abscess.

Other conditions

The following conditions should be mentioned under differential diagnosis, because they cause lameness in sheep, but it is unlikely that they would be confused with foot abscess because they all have specific characteristic features.

Foot and Mouth Disease

This virus infection affects all cloven-hooved animals and characteristically produces vesicles on the coronet and in the interdigital space. Following rupture the vesicles may be invaded by environmental organisms including *F. necrophorum*. Separation of the hooves starts first at the coronet and the high morbidity and other systemic effects differentiate it from foot abscess.

Contagious pustular dermatitis

This virus disease is a proliferative dermatitis affecting mainly lambs. Scabs tend to build up and coalesce about the lips and coronet and sometimes in the interdigital space. Secondary infection of these lesions with *F. necrophorum* from the environment commonly occurs. The age group affected, the characteristic sites and proliferative nature of the lesion, and the high morbidity differentiate it from foot abscess.

'Strawberry footrot'

Dermatophilus congolensis infection appears in the form of multiple raised scabs between the coronet and the knee or hock. Characteristic filaments and coccoid forms of

D. congolensis may be seen in stained smears made from the underside of scab material.

Suppurative cellulitis

In suppurative cellulitis there is patchy dermatitis due to *F. necrophorum* infection of the lower limbs, particularly that part on the posterior aspect of the limb between the hock and the pastern. The site affected differentiates it from foot abscess.

Post-dipping lameness

Dipping sheep in dips contaminated with *Erysipelothrix insidiosa* organisms can lead to infection of skin wounds with subsequent spread to the laminae. There is no tendency for abscess formation as occurs in foot abscess.

FOOT ABSCESS

ECONOMIC IMPORTANCE, INCIDENCE AND PREVALENCE

Although there has not been an evaluation of the economic importance of foot abscess to the sheep industry, second to footrot, it has always been considered the most common and most important infection of the ovine foot (Roberts *et al.*, 1968). Much of this importance undoubtedly arises because foot abscess occurs more frequently in ewes close to lambing (Roberts *et al.*, 1968) and in rams (Thomas, 1962) than in other classes of sheep. Production losses may therefore arise if sheep breeding programmes are disrupted by rams developing foot abscess close to the period of mating or if ewes develop pregnancy toxaemia as a consequence of the severe lameness associated with foot abscess.

In Australia, Gregory (1939) considered that foot abscess occurred sporadically in most flocks but outbreaks involving up to ten percent of a flock have been reported (Belschner, 1939). These outbreaks were usually observed after periods of rainfall during autumn, winter and spring (Roberts *et al.*, 1968).

In New Zealand Clark (1966) reported from a limited postal survey of 36 farms in the Malvern and Oxford counties that foot abscess occurred on 19 (52.7 percent) properties and where present, the incidence ranged from 0.01 percent to 20 per cent with an average of 1.71 percent.

Williamson (1953) reported treating 75 sheep with foot abscess in the Waimate region of the South Island, over a 16 month period, but did not state the population that these were derived from.

Foot abscess was observed by Roberts *et al.* (1968) to be more prevalent in ewes in late pregnancy than in dry ewes. In four flocks of pregnant ewes examined the prevalence ranged from four to seven percent whereas in dry ewes examined simultaneously in the same district it was not more than one percent.

Thus it appears that predisposing factors such as climatic influences and pregnancy may have a profound effect on the prevalence of foot abscess.

AETIOLOGY

Research into the aetiology of foot abscess falls into two categories: -

1. the causative organisms, and
2. the predisposing factors

1. The causative organisms

The identification of the important microorganisms in a site such as the ovine foot is confused by the area under examination being in contact with soil and faeces, and consequently contaminated with numerous organisms both pathogenic and non-pathogenic.

The only published authoratative study on the aetiology of ovine foot abscess was conducted by Roberts *et al.* (1968)

who considered that *F. necrophorum* in association with *C. pyogenes* were the causative organisms.

It is intended here to first discuss the role of these two individual organisms.

Fusobacterium necrophorum

Fusobacterium necrophorum is described in the 8th edition of Bergey's Manual of Determinative Bacteriology as a gram-negative, non-spore-forming, non-motile, strictly anaerobic, pleomorphic bacterium in the family *Bacteroidaceae*. Over 20 different binomials have been used at various times to refer to this organism (Barbara Langworth, 1977) but *F. necrophorum* is now the accepted terminology.

Fusobacterium necrophorum has been isolated from the alimentary tract of man and other animals and from necrotic lesions and abscesses, but in particular from bovine liver abscesses, foot rot of cattle, sheep and pigs, and abscesses of the foot (Simon and Stovel, 1969). The organism can also survive in soil for relatively long periods (Garcia, Neil and McKay, 1971). Using the fluorescent antibody technique Gacia *et al.* (1971) could detect the presence of *F. necrophorum* in damp soil for as long as eight weeks under aerobic conditions and up to eleven months under anaerobic conditions.

Studies of the pathogenic mechanism of, and immune response to, *F. necrophorum* have been reported relatively recently by many investigators (Roberts, 1967a and b; Roberts, 1970; Alexander, Garcia and McKay, 1973; Gacia, Dorward, Alexander, Magwood and McKay, 1974; Gacia, Charlton and McKay, 1975; Abe, Lennard and Holland, 1976; Abe, Majeski and Lennard, 1976; Cameron and Fuls, 1977; Fales, Warner and Teresa, 1977; Coyle-Dennis and Lauerman, 1978; Coyle-Dennis and Lauerman, 1979). Much of this research has centred on the role of toxins produced by *F. necrophorum* and the

possible use of toxoids in vaccine composition. Both endotoxins (Gacia *et al.*, 1975) and exotoxins (Roberts, 1967a; Coyle-Dennis and Lauerma, 1979) contribute to the pathogenicity of *F. necrophorum*. Roberts (1967a) using *in vivo* methods demonstrated the importance of leucocidal exotoxin produced by *F. necrophorum*. In experimental injections to the dermis of rabbits, sheep and guinea pigs, the leucocidal exotoxin inhibited leucocytes from leaving blood vessels within the inoculated area, and leucocytes outside the area were arrested and destroyed at the periphery. Buxton and Fraser (1977) considered that the migration of leucocytes into an area of inflammation was a most important initial response of the host to microbial infection, which concentrated cells with phagocytic properties into a focus of infection. In the presence of the leucocidal exotoxin produced by *F. necrophorum* this defence mechanism was severely limited in effectiveness. Roberts (1967a) suggested that in mixed infections the leucocidal exotoxin would protect other organisms as well as *F. necrophorum* from phagocytosis.

More recently other leucocidal exotoxins have been identified (Fales *et al.*, 1977; Coyle-Dennis and Lauerma, 1978) and a correlation established between the virulence of *F. necrophorum* isolates and their leucocidal exotoxin production (Coyle-Dennis and Lauerma, 1979).

In natural foot infections, *F. necrophorum* frequently acts co-operatively with other bacteria (Berg and Loan, 1975; Egerton *et al.*, 1969; Roberts and Egerton, 1969; and Roberts, 1969).

Roberts *et al.* (1968) considered *F. necrophorum* to be the primary pathogen in ovine foot abscess but also frequently isolated *C. pyogenes*. Roberts (1967a and b) determined the association between *F. necrophorum* and *C. pyogenes*. *Fusobacterium necrophorum* was the more invasive

and destructive organism and produced a leucocidal toxin that protected both *C. pyogenes* and itself from phagocytosis. On the other hand *C. pyogenes* produced a factor which stimulated the growth and invasiveness of *F. necrophorum*.

Parsonson *et al.* (1967) working with ovine interdigital dermatitis, isolated gram negative rods, filamentous forms, gram negative cocci and diptheroids (including *C. pyogenes*) from about 500 cases of ovine interdigital dermatitis. They were able to reproduce the disease by placing *F. necrophorum* soaked pads on scarified interdigital skin. Because of the known interrelationship between *F. necrophorum* and *C. pyogenes*, ovine interdigital dermatitis has been defined as being caused by *F. necrophorum* in association with *C. pyogenes* (Egerton and Graham, 1969).

Egerton, Roberts and Parsonson (1969), and Roberts and Egerton (1969) emphasised the role played by *F. necrophorum* in ovine footrot. Although *B. nodosus* acts as the essential transmitting agent of footrot, by itself it was found incapable of causing the disease. Some prior invasion by *F. necrophorum* was necessary before *B. nodosus* could invade the interdigital skin of sheep's feet. Once *B. nodosus* infection was established, deeper penetration by *F. necrophorum* organisms was observed histologically. This increase of invasiveness was attributed to the production of a nutrient factor by *B. nodosus* which Roberts and Egerton (1969) had demonstrated both *in vitro* and *in vivo*.

Berg and Loan (1975) working with footrot of cattle (interdigital necrobacillosis: Greenough, MacCallum and Weaver, 1972) isolated *F. necrophorum* and *Bacteroides melaninogenicus* (*B. melaninogenicus*) as well as other organisms from all eight cases examined. In experimental infections with pure and mixed cultures they obtained the most severe lesions with a dual inoculum of

F. necrophorum and *B. melaninogenicus* and concluded that those two were the aetiological agents of footrot in cattle.

It may be concluded that although the pathogenesis of these various foot conditions of sheep and cattle is complex, a common factor appears to be an initial infection with *F. necrophorum*. In these infections the pathogenesis of *F. necrophorum* appears to involve the following series of events. Initially there is a break in the surface epithelium by which *F. necrophorum* gains entry. As the bacteria proliferate, an exotoxin is produced which arrests and destroys the invading leucocytes thus inhibiting phagocytosis and permitting itself and other bacteria to become established and grow. Necrosis of the local tissues ensues as toxins are produced. Other bacteria that act in association with *F. necrophorum* such as *B. nodosus* and *C. pyogenes* produce factors which stimulate the growth and invasiveness of *F. necrophorum* thereby increasing the tissue destruction.

Corynebacterium pyogenes

Corynebacterium pyogenes is described in the 8th edition of Bergey's Manual of Determinative Bacteriology as a non-motile, non-spore-forming, non-capsulated, gram-positive rod. The organism has been frequently isolated from acute suppurative lesions in cattle, sheep and pigs and from mastitis in cattle (Blood and Henderson, 1974), but can also be isolated from normal animals and is presumed to be a parasite on mucous surfaces of warm-blooded animals (Buxton and Fraser, 1977).

Gardner (1961) described a condition of severe lameness in two flocks of sheep, characterized by sinus formation in the interdigital space only, and not at the coronet region as in typical foot abscess. *C. pyogenes* was isolated from the purulent interdigital lesion.

Corynebacterium pyogenes produces a filterable haemolytic toxin when grown in cooked meat media or in milk (Buxton and Fraser, 1977). This toxin is fatal to rabbits and mice when inoculated intravenously and causes necrosis when injected into the skin of guinea pigs.

In sheep *C. pyogenes* and *F. necrophorum* are frequently isolated from the same lesion (Parsonson *et al.*, 1967; Roberts *et al.*, 1968; and Egerton *et al.*, 1969), and have been shown by Roberts (1967a and b) to act co-operatively.

The role of *C. pyogenes* in this association was clarified by Roberts (1967b). He demonstrated that filtrates from *C. pyogenes* stimulated the growth of *F. necrophorum* organisms in the dermis of rabbits and sheep. The factor in the filtrate of *C. pyogenes* was a heat-labile undialysable macromolecule. The affect of this agent in stimulating the growth of *F. necrophorum* was considered important in the pathogenesis of ovine interdigital dermatitis (Parsonson *et al.*, 1967), ovine foot abscess (Roberts *et al.*, 1968) and ovine footrot (Roberts and Egerton, 1969).

Experimental reproduction of foot abscess

It was suggested by Egerton, Roberts, Graham and Parsonson (1966) that foot abscess arises from ovine interdigital dermatitis and this is supported by their subsequent observations (Roberts *et al.*, 1968) that both conditions were present in flocks at the same time and that in several instances foot abscess had been preceded by ovine interdigital dermatitis. Although ovine interdigital dermatitis can be reproduced experimentally by either scarifying or macerating the interdigital skin in the presence of *F. necrophorum* organisms (Parsonson *et al.*, 1967; Graham and Egerton, 1968) it has not been possible to reproduce foot abscess by this means.

The only report of experimental reproduction of foot abscess was by Roberts *et al.* (1968). Cultures containing about 2×10^8 *F. necrophorum* organisms per ml or 10^9 *C. pyogenes* organisms per ml and a mixture of the two in volumes of 0.2 ml, were injected into the medial digital cushion of three sheep. Within seven days the heels of all the injected digits were swollen. Purulent material discharged at the site of injection in two out of three digits given pure *C. pyogenes* but not in those given pure *F. necrophorum*. Two of the three digits that received the mixed inoculum discharged pus both at the injection site and through the interdigital skin. The lesions in these two feet were considered similar to naturally occurring cases of foot abscess, although no confirmatory tests such as radiology were performed.

The deposition of relatively large numbers of a mixture of *F. necrophorum* and *C. pyogenes* organisms into the deeper tissues of the foot does not explain how, in naturally occurring cases, the bacteria reach the area and multiply sufficiently to cause foot abscess.

The role of *Fusobacterium necrophorum* and *Corynebacterium pyogenes* in ovine foot abscess

The first person to differentiate foot abscess from other ovine foot conditions was Gregory (1939). He found that exudates expressed from sinuses contained numerous filaments of *F. necrophorum* and smaller numbers of other species, particularly *E. coli* and *C. pyogenes*. Because of the predominance of *F. necrophorum* and its ability to induce a similar exudation when injected into the tissues of sheep, Gregory concluded that *F. necrophorum* was the main causative organism, a view with which Belschner (1939) concurred.

Roberts *et al.* (1968) considered that foot abscess was a mixed infection with *F. necrophorum* and *C. pyogenes*. This opinion was formed following observations made on

approximately 1000 cases of foot abscess in South Eastern Australia. In gram-stained smears of exudate from early cases of foot abscess a filamentous organism morphologically typical of *F. necrophorum* was seen most frequently, but a moderate number of diptheroids were also present, and in older cases the diptheroids predominated. *Fusobacterium necrophorum* predominated in anaerobic cultures made from exudates. Aerobic cultures of exudates from early cases contained *C. pyogenes* almost exclusively. In later cases *C. pyogenes* was still present but other bacteria were also isolated, particularly streptococci.

In histological sections made from the infected soft tissues of the foot, filamentous organisms morphologically resembling *F. necrophorum* were more numerous and stained more intensely at the periphery of the lesion. In contrast diptheroid organisms were present mainly in the centre of the lesion, and in diminishing numbers towards the periphery.

It was concluded by Roberts *et al.* (1968) that *F. necrophorum* was the organism penetrating tissue at the forefront of the necrotising process and that *C. pyogenes* was the diptheroid organism proliferating in the centre of the necrotic lesion. Earlier work by Roberts (1967a and b) had determined the association between these two organisms and the importance of factors produced by each which assisted the effectiveness of the other.

Further evidence for the combined role of *F. necrophorum* and *C. pyogenes* in the aetiology of foot abscess was provided from the experimental reproduction of a similar condition in two of three sheep (Roberts *et al.*, 1968) in which a combined inoculum was injected into the digital cushion. On the other hand pure cultures of each organism used on their own, although containing twice as many bacteria as the combined inoculum, failed to reproduce foot abscess.

In conclusion there is much circumstantial evidence that *F. necrophorum* and *C. pyogenes* are the aetiologically important organisms in ovine foot abscess but the possibility of other organisms playing an essential or supporting role cannot be dismissed.

2. Presdisposing factors to Foot Abscess

Environmental Factors

The role of the environment in predisposing sheep to foot infections was described in general terms by Murnane (1933) and Beveridge (1934). Both workers associated infections of the interdigital skin with wet pastures although by itself moisture was not considered sufficient to cause infection without the presence of specific infecting agents. Murnane, (1933) kept sheep standing in water for periods of up to 3 months without development of footrot.

Beveridge (1941) showed that normal healthy skin was relatively resistant to infection and he believed water maceration to be an important predisposing cause. Experimentally, interdigital skin damage sufficient to permit invasion by *F. necrophorum* organisms has been provided by maceration from continuous exposure to water for 3 to 4 days (Graham and Egerton 1968; Egerton *et al.*, 1969).

Beveridge (1934) considered that any physical damage to the interdigital space might predispose to foot infections. As possible examples of physical damage both Beveridge (1934) and Roberts *et al.* (1968) referred to sheep walking on stones, stubble or thistles, friction between the digits, or penetration from barley grass seeds. Physical damage to the interdigital space has been simulated experimentally by either scarifying or incising the interdigital space (Parsonson *et al.*, 1967; Egerton *et al.*, 1969). This successfully predisposed the interdigital skin to infection by *F. necrophorum* organisms.

Graham and Egerton (1968) emphasised the importance of warmth in the transmission of ovine foot rot but tissue damage due to cold temperatures has been suggested as contributing to the invasion by *F. necrophorum* organisms of the interdigital space (Parsonson *et al.*, 1967; Roberts *et al.*, 1968; anon., 1969). Parsonson *et al.* (1967) observed a higher prevalence of ovine interdigital dermatitis during winter than during summer and Roberts *et al.*, (1968) observed a similar increase in the prevalence of foot abscess during winter. However the district under observation by both Parsonson *et al.* (1967) and Roberts *et al.* (1968) had a predominantly winter rainfall and it is possible that the prevalence of both ovine interdigital dermatitis and foot abscess was increased by the wet underfoot conditions rather than the cold temperatures during winter.

Penetration of the interdigital space by *Strongyloides* larvae

Beveridge (1934) noted that *Strongyloides papillosus* larvae develop under conditions favourable for the spread of ovine footrot and that when larvae of this parasite were applied to the interdigital skin, an appreciable degree of damage occurred. He also noted that footrot was more easily reproduced when *Strongyloides* larvae were applied to the interdigital space in conjunction with 'infective material' than when 'infective material' only was applied. This observation has been recently confirmed by Cross (1978). The presence of *Strongyloides papillosus* larvae under experimental conditions increased the number of feet which developed footrot from one out of sixty in the control group, to five out of fourteen in the treated group. However damage to the interdigital skin by *Strongyloides* larvae was not considered essential to the transmission of ovine foot rot (Roberts and Egerton, 1969).

Experimentally *Strongyloides papillosus* larvae have been observed in a limited number of cases to assist the penetration of *F. necrophorum* organisms into the deeper tissues of the foot (Mantovani, Restani, Ricci-Bitti, Sanquinetti and Biavati, 1974), but the role of *Strongyloides* larvae in predisposing sheep's feet to foot abscess is not known.

The misuse of formalin

Formalin has been routinely used as a treatment for foot rot in sheep for many years, and when used in the recommended manner, formalin foot bathing is both safe and effective.

The first report of severe injury to sheep's feet following treatment with formalin was by Pryor (1959) who described the occurrence of lameness in two flocks. In one flock, 100 merino sheep had been treated with 10 per cent formalin for about 30 minutes three times a week. After 4 weeks most of the flock had severe keratinisation of the interdigital skin. Similar lesions were observed in a second flock that had been treated with 20 percent formalin for 20 to 30 minutes once a week, and were also walked through the foot bath, usually twice a week. In addition some of the sheep in the second flock had interdigital ulcers and sinuses to deeper structures.

Annie Littlejohn (1972) observed hyperkeratinisation of the interdigital skin of sheep's feet which had been exposed to 10 percent formalin for as short a time as one minute twice weekly. She also described the development of a pyogenic infection of the distal interphalangeal joint of an individual sheep that had been exposed repeatedly to 30 percent formalin solution.

Hooper and Jones (1972) described devastating injury to the feet of a flock of 250 sheep following foot bathing of the flock on alternate days for 5 weeks in a formalin solution of unknown concentration. Over 70 percent of the sheep became acutely lame and many were affected in more than one foot with pyogenic infections involving the distal interphalangeal joint. *Fusobacterium necrophorum*, *C. pyogenes* and *B. nodosus* were present in the pus from the distal interphalangeal joint of affected sheep. The suggested pathogenesis was that primary damage to the interdigital skin resulted from the misuse of formalin, and that this permitted the entry of the pathogenic organisms responsible for the purulent and necrotic lesions in the distal interphalangeal joint. The condition was termed corono-pedal abscessation by Hooper and Jones (1972) but their description is similar to that of foot abscess in New Zealand (Chapter 4).

Other predisposing factors

Foot abscess was observed more often in ewes close to lambing than in dry sheep (Roberts *et al.*, 1968) and in lambing ewes the infection was largely confined to the hind feet. Roberts *et al.* (1968) postulated that this might be due to vascular stasis in the interdigital area assisting the deeper invasion by the strict anaerobe *F. necrophorum*. It was suggested that the vascular stasis could arise from interference to the blood supply to the hind feet, brought about either by the developing foetus pressing on the posterior vascular trunks, or as the result of the increased weight on the hind feet in late pregnancy.

TREATMENT

There have been no reports of controlled trials to assess the relative value of different treatments for foot abscess. Most recommendations have been based therefore on first principles of therapy and have consisted of such things as drainage of

abscesses, cleansing the affected area with disinfectant and dressing the foot, (Murnane, 1933; Gregory, 1939).

Williamson (1953) tried a number of different treatments for foot abscess. He obtained the most success with a combination of sulphamezathine given systemically and draining and dressing the abscessed digit. The salve used consisted of copper sulphate 1 part; cod liver oil 4 parts; glycerine 3 parts and cera emulsificans 10 percent.

Both of the bacteria considered to be the main pathogens in foot abscess, namely *F. necrophorum* and *C. pyogenes*, show *in vitro* sensitivity to penicillin (Buxton and Fraser, 1977; Simon, 1977). Egerton and Graham (1969) however found that a mixture of penicillin and streptomycin did not accelerate healing in a series of foot abscess cases treated by them.

Treatment of foot abscess remains largely empirical.

PROGNOSIS

Murnane (1933) and Gregory (1939) recognised the importance of initiating therapy early in cases of foot abscess, before the occurrence of permanent damage and deformity to ligaments and tendons within the digit. Roberts *et al.* (1968) and Egerton and Graham (1969) also found established cases of foot abscess difficult to treat. They found that providing complete drainage was impossible without further damaging the affected digit, and that healing was incomplete and slow, often taking up to three months.

PREVENTION

It was recognised by Gregory (1939) that because of the sporadic nature of foot abscess, and the difficulty in predicting an outbreak, preventive measures would be difficult to apply. He suggested attention should be paid to routine foot trimming and the foot bathing of sheep in

antiseptic solutions during times of high rainfall. Egerton and Graham (1969) recommended the weekly foot bathing of all sheep in 5 percent formalin during periods of high risk such as the period before lambing.

The other preventive measure used has been vaccination of sheep with *F. necrophorum* vaccines. Attempts to immunise animals against infection by *F. necrophorum* have been disappointing (Simon and Stovell, 1969). Although circulating serum antibodies are detectable after immunisation with various vaccines, the protection afforded against infection is meagre (Roberts, 1970; Alexander *et al.*, 1973; Warner Fales and Teresa, 1974; Gacia *et al.*, 1974). Immunisation is further complicated by the lack of information regarding antigens necessary for protection and whether or not these are associated with the main exotoxins and endotoxins possessed by *F. necrophorum* (Roberts, 1970; Garcia Alexander and McKay, 1975; Garcia, Charlton and McKay, 1975).

Cameron and Fuls (1977) using a combined bacterin failed to immunise rabbits against a mixed infection of *F. necrophorum* and *C. pyogenes*. They concluded that although it was possible to induce a low level of immunity by conventional immunisation methods, it was doubtful if effective vaccines could be produced.

Assessment of the effectiveness of vaccines in preventing the occurrence of foot abscess is hampered by both the unpredictability of outbreaks of foot abscess (Gregory 1939), and the problems of experimental reproduction of foot abscess.

CHAPTER 2

A SURVEY OF NEW ZEALAND ROMNEY SHEEP BREEDERS, CONCERNING SOME ASPECTS OF FOOT ABSCESS

INTRODUCTION

METHODS

RESULTS

Occurrence

Class of sheep affected

Seasonal occurrence

Predisposing factors

Treatment

Prognosis

The use of *Fusobacterium necrophorum* vaccine

DISCUSSION

CONCLUSIONS

INTRODUCTION

Unfortunately, little is known about the importance of ovine foot abscess in New Zealand, its effect on production or how it interferes with farming practice. The only report available was a limited postal survey conducted by Clark (1966), which in part dealt with foot abscess, and was sent to 36 members of the Malvern Farmers Veterinary Club. Therefore it was considered necessary to conduct a New Zealand survey on a wider scale to help evaluate the significance of foot abscess, by determining the occurrence and severity of the problem and by recording what measures were adopted for treatment, and their apparent effectiveness.

The survey was conducted through the New Zealand Romney Sheep Breeders Association for two reasons. Firstly, the Association has an efficient organisation and the Romney breed is numerically the largest in New Zealand, comprising 70 percent of the national flock. Secondly, it was considered that stud breeders would have better stock records than commercial farmers, and possibly be more concerned about disease and therefore more likely to respond to a postal survey.

Postal surveys can be criticized, because to be of much value they require a high response rate and in addition they rely on the opinions and attitudes of the respondents. Furthermore the respondents as a group may be biased in favour of people who have recently experienced a problem with the disease under survey. Despite these shortcomings, useful information can be obtained, but every effort should be made to ensure a high response rate and care must be exercised in interpretation of the results.

In order to encourage as many replies as possible, the format of the survey was kept simple and limited to one page (Fig. 2.1). Farmers were invited to submit their personal comments about aspects of foot abscess, in addition to answering specific questions.

METHODS

During the winter of 1974, a questionnaire was posted to each of the 883 members of the New Zealand Romney Sheep Breeders Association: included was a stamped and addressed envelope for the reply. Because of the possible confusion that could arise in asking farmers to distinguish foot abscess from other foot conditions, a description of foot abscess together with a photograph of an affected foot, were included with the questionnaire (Fig. 2.1).

The replies to the questionnaire were analysed in groups according to the six 'veterinary regions' serviced by the Ministry of Agriculture and Fisheries (Fig. 2.2).

Because of the marked difference in incidence of foot abscess with class of sheep, the variable composition of the flocks surveyed and the apparently low incidence of foot abscess within flocks, it was considered misleading to compare property incidences. Instead, the number of sheep observed with foot abscess on each property was recorded.

Statistical analysis

The distribution and frequencies of observations reported, were subjected to analysis using the chi-squared test. In every case, Yates' correction factor was applied and expected values were always greater than five. The probability of differences occurring by chance (P), were read off tables for chi-squared, using the appropriate degrees of freedom.

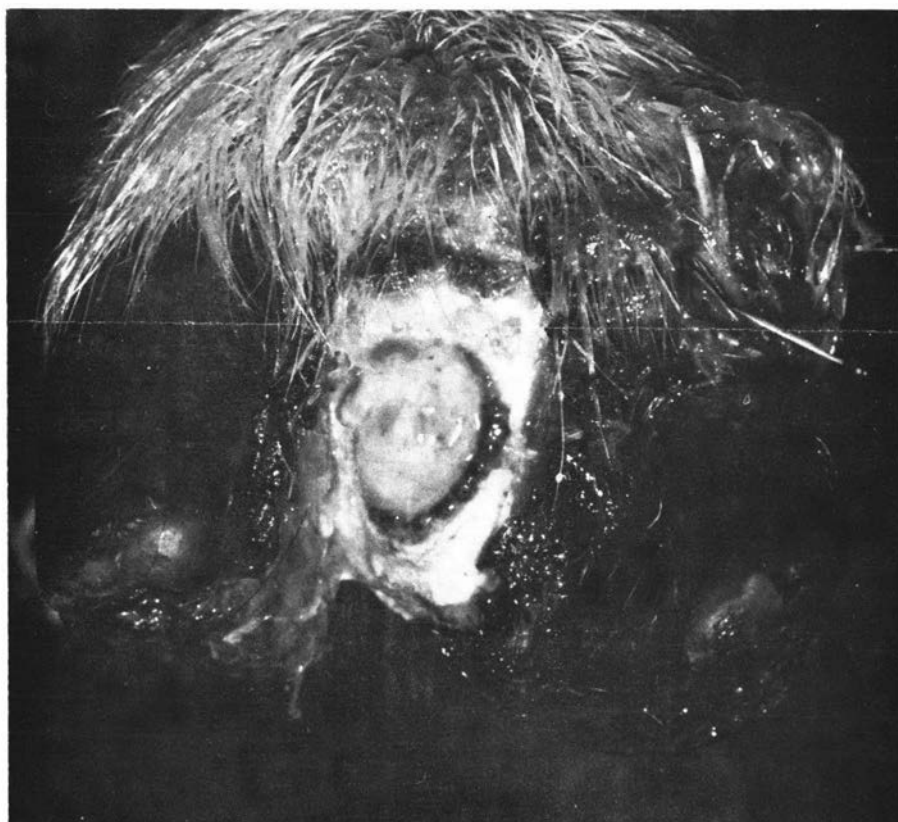FIGURE 2.1

FOOT ABSCESS SURVEY

D.M. West, B.V.Sc.

Lecturer

Department of Veterinary Clinical Sciences



Massey University

Palmerston North

This survey is conducted in conjunction with studies towards a Ph.D. degree at Massey University. The aim of the survey is to ascertain the incidence of **Foot Abscess** in sheep in New Zealand and collect some data on predisposing causes and the outcome of the infection.

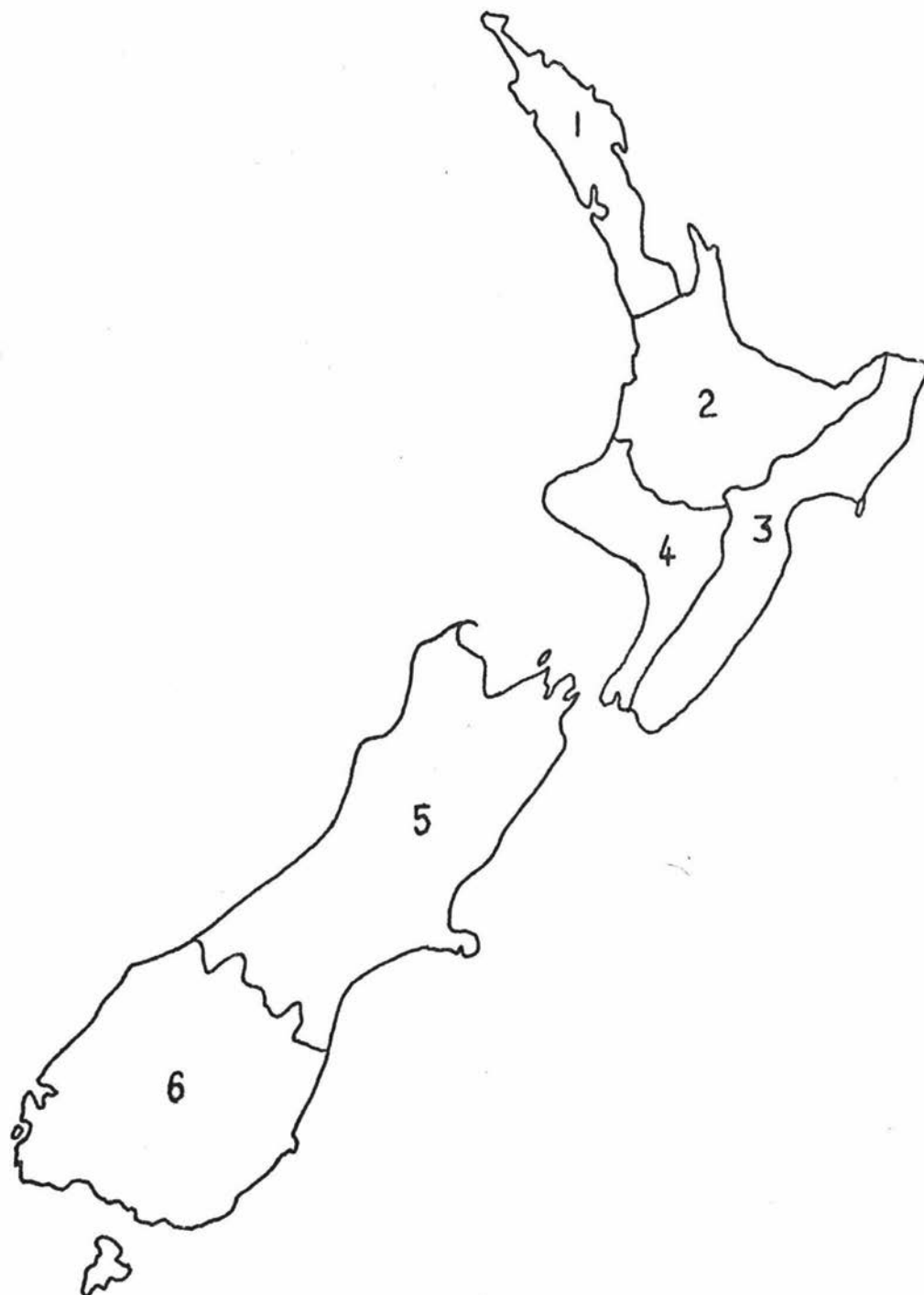
Foot Abscess must be distinguished from Foot Rot. With Foot Abscess there is heat, pain and swelling of one digit of the foot and the abscess discharges either between the digits or at the coronet. The horny layers of the hoof are not affected. Please fill in the form and return it in the enclosed envelope. If you do not have any foot abscess please answer (none) for question 2 and return also, as this information is useful.

1. What is the total number of sheep on your farm?
2. What is the average number that become affected with foot abscess in any one year?
3. What is the greatest number that have become affected with foot abscess in any one year?
4. What class of sheep is more commonly affected?
 - Dry ewes
 - Ewes in lamb
 - Rams
 - Ewe hoggets
 - Ram hoggets
5. What predisposing causes do you associate with foot abscess?
 - none
 - heavy sheep
 - flushes of feed
 - cold environmental temperatures
 - excessively wet conditions
 - when the sheep are on crops
 - any other factors — name them
6. At what time of the year do the majority of the cases of foot abscess occur?
7. How do you treat foot abscess?
8. After treatment, how long do they take to recover?
9. What percentage don't recover and are permanently lame?
10. Have you ever used the foot abscess vaccine?
11. Do you find it effective?

Your assistance with this survey would be greatly appreciated and you will be informed of the results when they are collated. It would also be of assistance if farmers within 50 miles of

FIGURE 2.2

'Veterinary regions' of the New Zealand Ministry of
Agriculture and Fisheries



RESULTS

Distribution of replies

Of the 883 farmers who received the questionnaire, 351 (40 percent) replied. The proportion of farmers who replied from each area was the same except for areas 5 and 6. More replies were received from area 5 and less from area 6 than would have been expected from the number of farmers surveyed in these areas. However, there was no reported difference in the prevalence or severity of foot abscess between areas 5 and 6 and had they been analysed together as one geographical area (the South Island), the proportion of respondents would have been the same as for areas 1 to 4 inclusive.

Occurrence

Foot abscess occurred in 270 (77 percent) of the 351 stud breeders' flocks. The incidence of foot abscess within flocks however was low (Table 2.I), although no property incidences were analyzed for the reasons given under methods. Only two percent of farmers reported having more than 50 sheep affected annually. The problem was distributed fairly evenly throughout New Zealand.

TABLE 2.I

The percentage of respondents reporting foot abscess cases

M.A.F. 'veterinary region'	Percentage of replies, grouped according to annual number of cases		
	Nil	1-20	> 20
1	40	50	10
2	32	58	10
3	21	66	13
4	28	67	5
5	11	70	19
6	22	66	12
TOTAL	23	66	11

Class of Sheep Affected

Foot abscess was reported much more commonly in rams, ram hoggets and in-lamb ewes, than in other classes of sheep (Table 2.II).

TABLE 2.II

The percentage of respondents reporting the occurrence of foot abscess in different classes of sheep

<u>Class of sheep</u>	<u>Percentage of total replies</u>
Rams	34
In-lamb ewes	30
Ram hoggets	30
Dry ewes	3
Ewe hoggets	2
Any class of sheep	1
TOTAL	100

Seasonal Occurrence

Farmers considered that foot abscess occurred throughout the year but there was a lower prevalence during summer (Table 2.III). The difference in prevalence between seasons was highly significant. ($p. < 0.001$).

TABLE 2.III

The seasonal occurrence of foot abscess

<u>Season</u>	<u>Percentage of total replies</u>
Summer	9
Autumn	36
Winter	24
Spring	31
TOTAL	100

Predisposing Factors

Farmers associated the occurrence of foot abscess with a number of predisposing factors; in particular, flushes of feed, excessively wet conditions, heavy sheep, and grazing sheep on crops (Table 2.IV). In addition some farmers made suggestions of other factors that could predispose to foot abscess. These included; sheep on a rising plane of nutrition before mating in autumn, yarding sheep in muddy yards, ewes heavy in lamb, in association with 'scald', and as a sequel to formalin foot bathing (Table 2.IV).

TABLE 2.IV

Factors considered by respondents to predispose to
foot abscess

<u>Predisposing factor</u>	<u>Percentage of total replies</u>
Flushes of feed	26
Excessively wet conditions	25
Heavy sheep	17
When sheep are on crops	10
Cold environmental temperatures	2
None	10
Additional factors suggested as important by farmers;	
Sheep on a rising plane of nutrition before mating	5
Yarding sheep in muddy yards	2
Associated with 'scald'	1
Ewes heavy in lamb	1
As a sequel to formalin foot bathing	1
TOTAL	100

Treatment

Seventy-eight percent of farmers replying to the questionnaire treated foot abscess cases with injectable antibiotics (mainly penicillin), either alone, or in combination with local treatments such as drainage, irrigation or poulticing (Table 2.V).

TABLE 2.VTreatment of foot abscess cases

Treatment	Percentage of total replies
Injectable antibiotics (mainly penicillin)	54
Local treatments to the foot	6
Combined injectable antibiotics and local treatments	24
Did not attempt treatment	16
TOTAL	100

Prognosis

Most infections appeared to require an extended period to heal and a number did not recover completely, leaving the foot misshapen (Table 2.VI).

For 15 percent of the respondents, the prognosis seemed to depend on the time of instituting treatment in relation to the disease process. If treatment was instituted early, the recovery time was shorter and the chances of complete recovery without deformity greater, than if treatment was instituted when foot abscess was well established.

TABLE 2.VI

Prognosis of foot abscess cases

Recovery period	Percentage of total replies
1-6 days	9
1-6 days if treated early	15
weeks	35
months	38
never recover	3
TOTAL	100
<u>Satisfactory recovery</u>	
Nil	19
0-25 percent	25
26-75 percent	14
76-100 percent	7
most, but foot misshapen	13
Do not know	22
TOTAL	100

The use of *Fusobacterium necrophorum* vaccine

Only a third of the farmers that reported having cases of foot abscess in their flocks, made use of *F. necrophorum* vaccine. Of these farmers, 50 percent considered the vaccine to be either not effective, or only partially effective (Table 2.VII).

TABLE 2.VII

The effectiveness of *Fusobacterium necrophorum* vaccine

Effectiveness	Percentage of respondents using the vaccine
Effective	42
Partially effective	33
Not effective	17
Do not know	8
TOTAL	100

DISCUSSION

The data from this postal survey must be interpreted with caution but nevertheless it is considered to be a valid indicator of national statistics for the following reasons.

- a) Forty percent of those surveyed replied, a good response rate for surveys of this kind and one which compares more than favourably with a similar type of survey (Cooper, 1967), in which only 16 percent replied.
- b) The respondents were distributed fairly evenly, relative to the population surveyed.
- c) The choice of pedigree farmers, although limiting the survey to a small population of farmers, had the advantage of more accurate answers and a more even representation of rams compared to ewes than if commercial sheep farms had been surveyed.
- d) The results of the survey are similar to the author's personal observations on a variety of sheep farms in the lower North Island, and to veterinary opinion communicated from other areas of New Zealand.

Although foot abscess occurred in more than three-quarters of the respondents' flocks, the number of affected sheep within a flock was low. Thus, foot abscess occurred sporadically in most flocks and this is comparable with observations made in Australian commercial flocks (Gregory, 1939; Belschner, 1939; Roberts *et al.*, 1968). Belschner (1939) considered an annual incidence of foot abscess of 10 percent to be high and Roberts *et al.* (1968) observed a prevalence of foot abscess ranging from 4 to 7 percent in four flocks of ewes during an outbreak of lameness. In New Zealand Clark (1966) reported from a postal survey of 36 farms in the Malvern and Oxford counties that foot

abscess occurred on 19 (52.7 percent) properties and where present, the incidence ranged from 0.01 percent to 20 percent with an average of 1.71 percent.

Within Australia, foot abscess was most commonly seen affecting adult sheep particularly lambing ewes (Roberts *et al.*, 1968) and sometimes rams (Thomas, 1962). In the survey of pedigree flocks reported here, rams, ram hoggets, and in-lamb ewes were the class of sheep most commonly affected with foot abscess. In New Zealand sheep flocks the proportion of adult ewes to adult rams is about 50 to 1 (New Zealand Meat and Wool Boards Economic Service, 1979). This ratio would be slightly lower in stud flocks, but would seldom be below 30 ewes to a ram. When one considers this big disparity in numbers of ewes to rams and the relative frequency with which foot abscess was noticed in rams and ewes, it is apparent that the attack rate of foot abscess is much higher for rams than for ewes. This difference in attack rate favouring the rams is also evident if the percentage of respondents noticing foot abscess in ram hoggets (30 percent) is compared with respondents noticing foot abscess in ewe hoggets (2 percent). Approximately equal numbers of ram and ewe hoggets are retained on stud farms and although grazed separately, the two groups are managed similarly. No explanation for the difference in attack rate between rams and ewes could be suggested from replies in the survey. A possible explanation is advanced in Chapter 5 of this thesis.

Predisposing factors such as excessively wet underfoot conditions (Gregory, 1939; Roberts *et al.*, 1968), muddy yards (Egerton and Graham, 1969), heavy sheep on good pasture (Egerton and Graham, 1969), or grazing sheep on crops (Gardner, 1961), have all been considered to have a

profound effect on the prevalence of foot abscess, and this is substantiated in this survey. Cold environmental temperature was not considered a particularly important predisposing cause by New Zealand farmers and in addition, the winter prevalence of foot abscess was not observed to be higher than that during autumn and spring. This is at variance with the suggestion by Parsonson *et al.* (1967) and Roberts *et al.* (1968) that tissue damage due to cold temperatures might contribute to the invasion of the inter-digital skin by *F. necrophorum* organisms and thus predispose to foot abscess. The higher prevalence of foot abscess during winter, observed by the Australian workers may have been influenced more by the predominantly winter rainfall of the district under observation, rather than the colder temperature. Similarly the reduced prevalence of foot abscess during the summer observed by New Zealand sheep farmers, may be caused by the dry conditions rather than the higher temperature.

Murnane (1933) and Gregory (1939) recognised the importance of initiating therapy for foot abscess early in the disease process, if healing without permanent deformity was to take place. This was also appreciated by sheep farmers replying to this survey. Despite the poor prognosis, treatment was usually attempted. The injectable antibiotic most often used was penicillin which is available to farmers from a number of retail outlets and is frequently used by farmers to treat or help prevent a variety of other bacterial infections. The two organisms considered to be the main pathogens in foot abscess; namely *F. necrophorum* and *C. pyogenes*, show *in vitro* sensitivity to penicillin (Buxton and Fraser, 1977; Simon, 1977), so there is sound rationale for the use of penicillin, even though its effectiveness has not been fully evaluated.

Local treatment of the affected foot, such as draining and irrigating abscesses using antiseptic solutions and bandaging the foot were recommended as long ago as 1933, by Murnane, and these procedures are still commonly used by New Zealand

sheep farmers today.

Although various *F. necrophorum* vaccines have been used experimentally (Roberts, 1970; Alexander *et al.*, 1973; Garcia *et al.*, 1974), and even marketed commercially, worthwhile protection against infection has not been demonstrated. It was not surprising therefore to receive reports that the vaccine has only limited use in New Zealand flocks and many farmers were dissatisfied with, or unsure of, its effectiveness. Evaluation of field use of vaccines is difficult, especially if the disease concerned occurs sporadically, and it is considered significant that as many as 17 percent of vaccine users considered the vaccine to be ineffective.

Foot abscess may be classed as a 'nuisance-value' disease and as such, often receives far less attention than is warranted. If the collected losses arising from such a disease could be costed, they would amount to a substantial sum. For instance rams which become affected with foot abscess close to the mating period may be rendered unfit for further use in that season because of the prolonged recovery time. In stud flocks in particular, this causes disruption of the breeding programme. In addition, ewes affected with foot abscess close to lambing frequently develop pregnancy toxæmia as an indirect consequence of the severe lameness, and this further increases the production losses. Ram hoggets in stud flocks, also appear to be at risk from outbreaks of foot abscess. Thus, although the incidence and prevalence of foot abscess usually appears to be low, it is nevertheless a significant disease because of the unexpected nature of outbreaks at critical times in the farming calendar, and the difficulties sheep farmers face with treatment and prevention.

CONCLUSIONS

- (1) Foot abscess occurs sporadically in most sheep flocks and it is considered important by farmers because of the unexpected nature of outbreaks at critical times in the farming calendar, and the unsatisfactory nature of treatment and prevention.
- (2) The attack rate of foot abscess is higher for rams than for ewes.
- (3) Foot abscess occurs throughout the year but is less prevalent during summer.
- (4) Predisposing factors such as wet muddy underfoot conditions and heavy well fed sheep have a positive effect on the prevalence of foot abscess.
- (5) Cold environmental temperatures are not considered to be important in the predisposition to foot abscess in New Zealand.
- (6) Treatment of foot abscess is largely empirical and to be effective has to be initiated early in the disease process. The prognosis for complete recovery is poor.
- (7) Although *F. necrophorum* vaccine is used on some New Zealand farms, it has not been entirely satisfactory.

CHAPTER 3

ANATOMICAL CONSIDERATIONS OF THE DISTAL INTERPHALANGEAL JOINT OF SHEEP

INTRODUCTION

MATERIALS AND METHODS

Dissection of major structural components of the distal interphalangeal joint.

Radiography, following the injection of radio-opaque contrast material into the distal interphalangeal joint.

Dissection, following the injection of latex into the distal interphalangeal joint

OBSERVATIONS

Bones

Joint capsule

Ligaments

Volar or sesamoidean ligaments

Dorsal ligament

Collateral ligaments

DISCUSSION

CONCLUSIONS

INTRODUCTION

From a full clinical and radiographic examination of naturally occurring cases of foot abscess, described in Chapter 4 of this thesis, it was noted that the distal interphalangeal joint was invariably involved in the disease process and appeared to be the centre of infection. This anatomical study was undertaken to determine the most likely routes of infection into the distal interphalangeal joint from superficial infections such as ovine interdigital dermatitis.

Much of the literature on the anatomy of the distal interphalangeal joint has been devoted to cattle (Sisson and Grossman, 1966; Nickel, Schummer and Seiferle, 1968; Greenough *et al.*, 1972). Barone (1968) and May (1970) have made comments on the sheep, but these descriptions are either largely comparative or have omissions. It was therefore necessary to make original observations on the extent and ligamentous attachments of the capsule of the distal interphalangeal joint of the sheep.

MATERIALS AND METHODS

Dissection of major structural components of the distal interphalangeal joint.

The feet of ten, clinically normal, mixed aged Romney ewes were dissected to reveal the structure of the distal interphalangeal joint. Particular attention was paid to the position of the joint capsule relative to the interdigital integument and coronet, and the exact siting of major ligaments and tendon insertions.

Radiography following the injection of radio-opaque contrast material into the distal interphalangeal joint.

To delineate the outline of the distal interphalangeal joint, meglumine lothalamate¹ was injected into the joint of 10 sheep and the feet radiographed, using a portable Watson-Victor type 60 X-ray generator with exposure factors of 55 kilovolts and 30 milliamps for 0.1 of a second. The sheep were first anaesthetised with pentobarbitone sodium², before a 25 gauge 2.5cm needle was inserted into either the dorsal or volar pouch of the joint capsule. Joint fluid was withdrawn to confirm the needle position. Between 0.5 and 0.75 ml of contrast medium could be easily injected into the joint space, but greater volumes resulted in a build-up of pressure, preventing further injection.

To assist with interpretation of the X-ray plates, the other digit of the foot had been amputated at a level above the proximal interphalangeal joint a few days previously.

Dissection following the injection of latex into the distal interphalangeal joint.

Using a similar technique to that described above, latex³ to which a few drops of meglumine lothalamate had been added was injected into the distal interphalangeal joint of all the digits of an anaesthetised Romney ewe. The feet were radiographed after injection to confirm needle positioning and the sheep was then destroyed. The lower legs were removed and stored at 4°C for seven days during which time it was anticipated that the latex should solidify. The feet were then dissected in the standard manner.

¹ Conray 280, May and Baker, England

² Nembutal, Abbott Laboratories, Sydney, Australia

³ Latex. Batavian Rubber Co Ltd., Featherston, New Zealand.

OBSERVATIONS

There were no significant differences in the structure of the distal interphalangeal joint between the fore and hind feet. The medial and lateral digits of each foot differed only by being mirror images.

Bones

The distal interphalangeal joint of each digit was formed by the articulation of three bones; the distal phalanx, the middle phalanx and the distal sesamoid (Fig. 3.4).

Joint capsule

The joint capsule extended proximally above the level of the coronary border of the hoof in two places, forming the dorsal and volar pouches (Fig. 3.1a, b and c; and Fig. 3.2a, b and c). Less protection was afforded by the hoof on the axial aspect of the digit as the axial hoof wall is approximately half the height of the abaxial hoof wall.

Ligaments

The ligaments of the distal interphalangeal joint could be considered in three groups;

1. the volar or sesamoidean
2. the dorsal
3. the collateral

1. The volar or sesamoidean ligaments

The volar or sesamoidean ligaments joined the distal sesamoid bone to the other phalanges.

There were proximal and distal sesamoidean ligaments.

Proximally there was a collateral ligament attaching the abaxial aspect of the distal end of the proximal phalanx to the sesamoid bone, and an impar ligament attaching the middle phalanx to the sesamoid bone (Fig. 3.4 and Fig. 3.5). No axial proximal collateral ligament was observed, which is contrary to the statement of Barone (1968) who described it as yellow and elastic.

Distally there were three short ligaments joining the sesamoid bone to the distal phalanx; axial and abaxial collateral ligaments and an impar ligament (Fig. 3.4 and Fig. 3.5).

Also present was the interdigital ligament bridging the distal sesamoids of the two digits, which also contained some fibres derived from the middle phalanges. This may act functionally as a continuation of each proximal collateral sesamoidean ligament (Fig. 3.5).

2. The dorsal ligament

The sheet-like dorsal ligament lay over the dorsal pouch of the joint capsule and from its attachment proximally on the middle phalanx it fanned distally to attach to the distal phalanx (Fig. 3.6). The dorsal ligament was more prominent and thicker, on the axial aspect.

3. The collateral ligaments

The collateral ligaments joined the distal phalanx to the other two phalanges. The collateral ligaments consisted of common and proper parts.

The common collateral ligaments were located axially and abaxially. They linked the proximal and distal phalanges (Fig. 3.3 and Fig. 3.6) and were therefore common to both the proximal and distal interphalangeal joints. The axial common collateral ligament was much wider (5mm) than the abaxial common collateral ligament (2mm).

The proper collateral ligaments were also located axially and abaxially but linked the middle and distal phalanges (Fig. 3.6).

FIGURE 3.1a

The digit of a Romney ewe, radiographed immediately following the injection of 0.75 ml of meglumine lothalamate into the dorsal pouch of the distal interphalangeal joint.

D - dorsal pouch

V - volar pouch

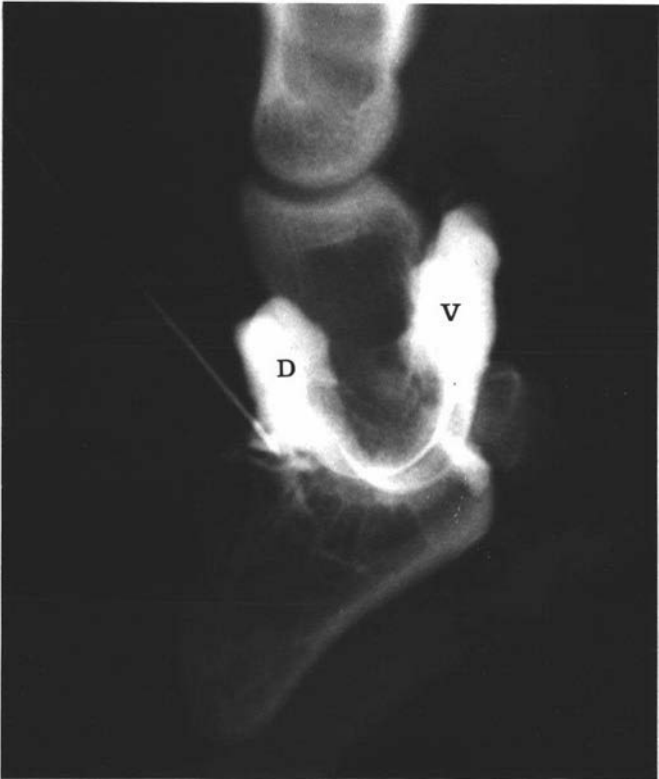


FIGURE 3.1b and c

The digit of a Romney ewe, radiographed immediately following the injection of 0.5 ml of meglumine iothalamate into b/ the volar pouch and c/ the dorsal pouch of the distal interphalangeal joint.

b/ D - dorsal pouch
 V - volar pouch

The broken line indicates the appropriate level of the axial coronary border.

c/ D - dorsal pouch
 V - volar pouch

The broken line indicates the approximate level of the abaxial coronary border.

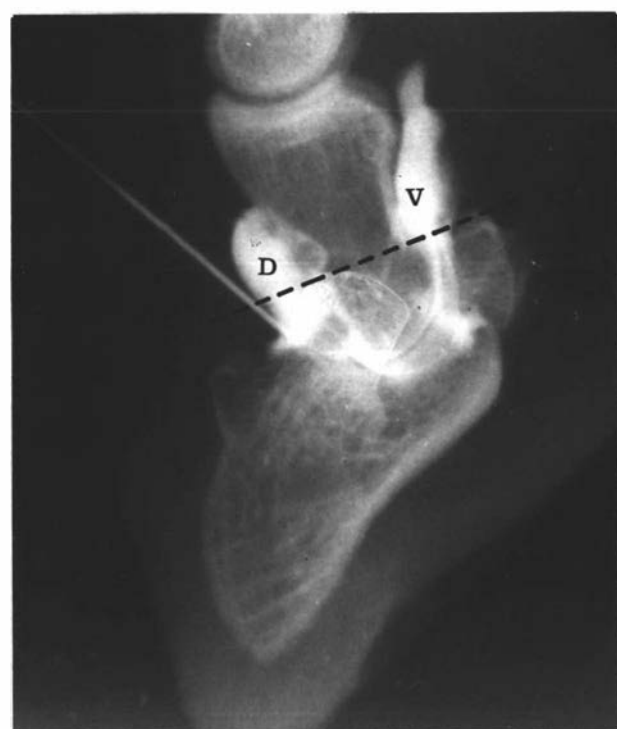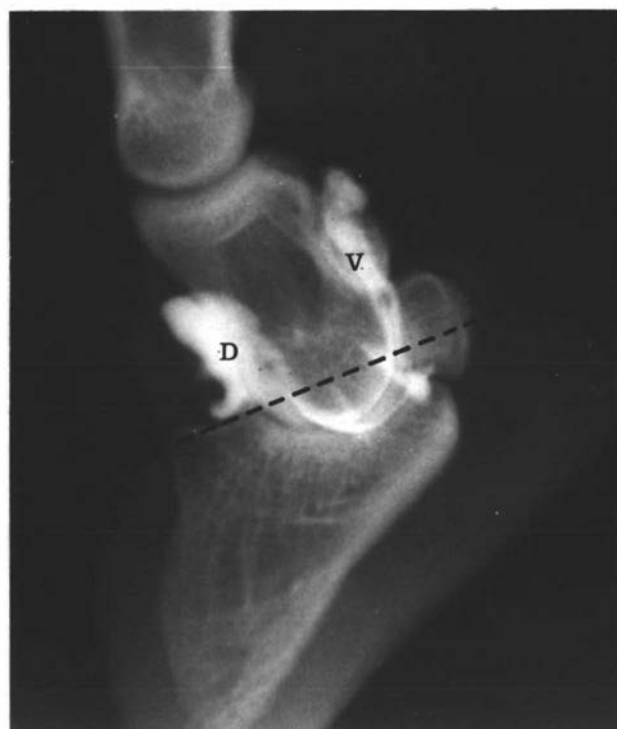


FIGURE 3.2a, b and c

The serial dissection of the axial aspect of a sheeps digit, following the injection of latex into the distal interphalangeal joint.

a/ D - dorsal pouch of the distal interphalangeal joint

E - extensor tendon

F - flexor tendon

G - dorsal ligament

L - axial common collateral ligament

b/ V - volar pouch of the distal interphalangeal joint. The broken line indicates the approximate level of the axial coronary border.

c/ H - axial collateral ligament of the proximal interphalangeal joint.

L - axial common collateral ligament (reflected).

M - axial proper collateral ligament

P - proximal interphalangeal joint.

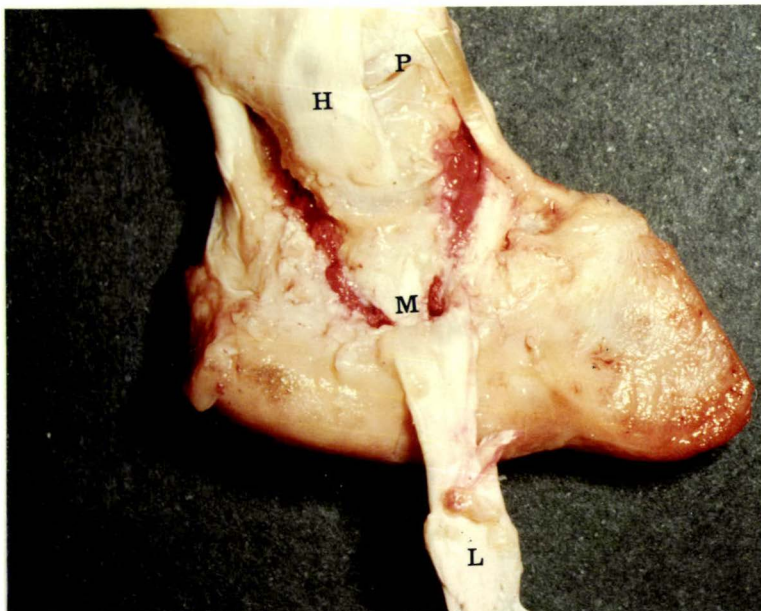
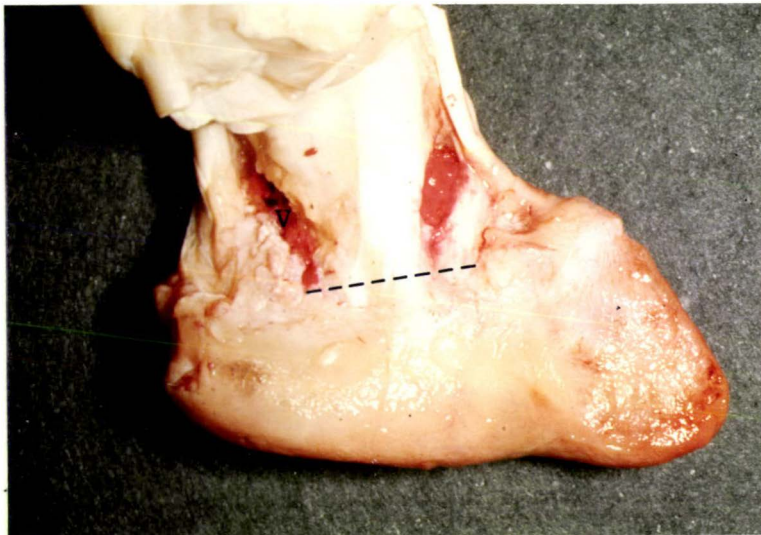
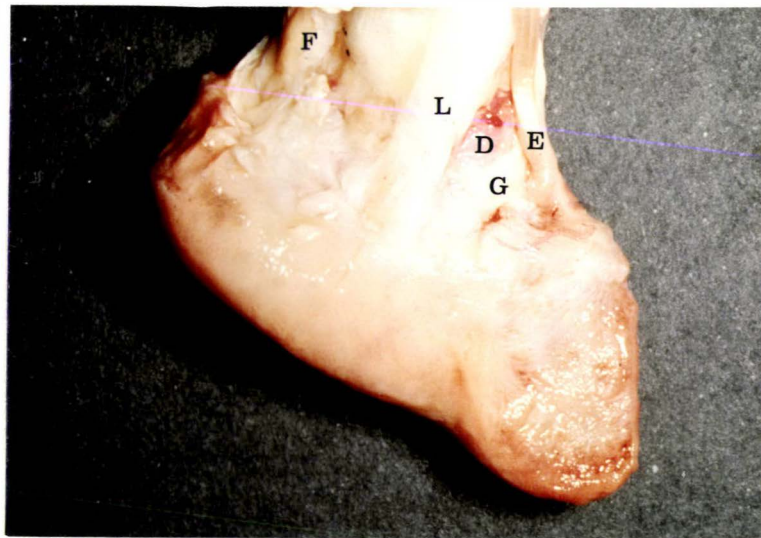


FIGURE 3.3

Dissection of the axial aspect of the left fore lateral digit of a Romney ewe.

- E - extensor tendon
- F - flexor tendon
- L - axial common collateral ligament of the distal interphalangeal joint
- H - axial collateral ligament of the proximal interphalangeal joint
- I - interdigital ligament (transected).

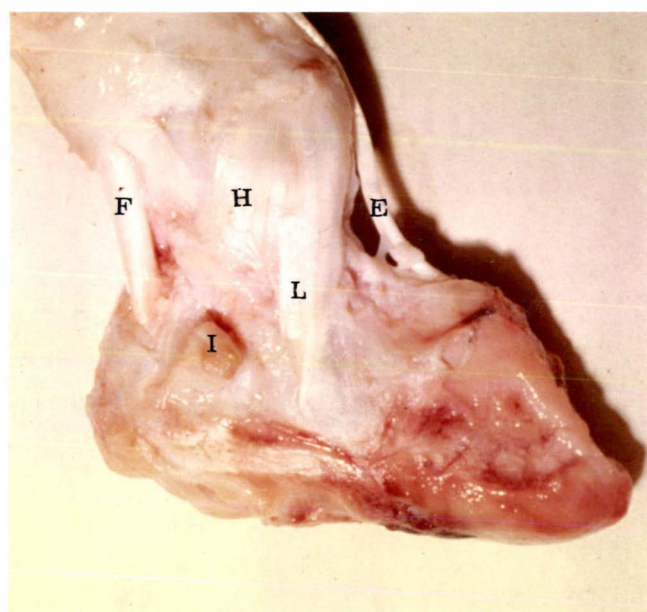


FIGURE 3.4
SESAMOIDEAN LIGAMENTS OF THE DISTAL
INTERPHALANGEAL JOINT OF
SHEEP (abaxial aspect)

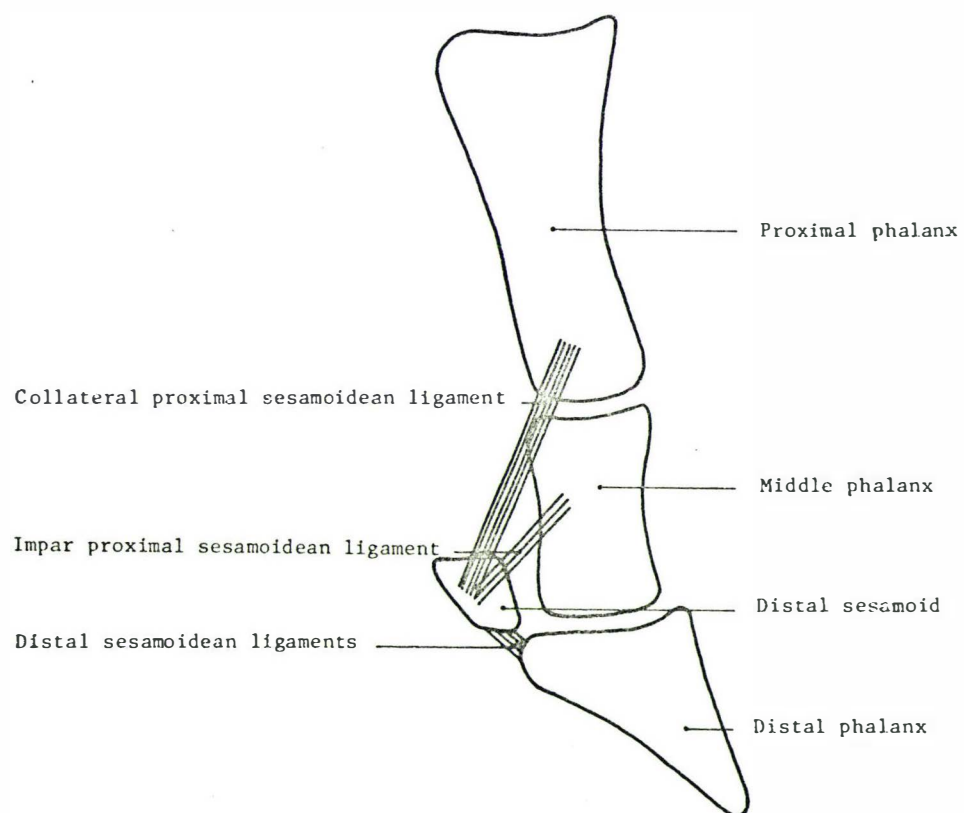


FIGURE 3.5
SESAMOIDEAN LIGAMENTS OF THE
DISTAL INTERPHALANGEAL JOINT OF SHEEP
(volar aspect)

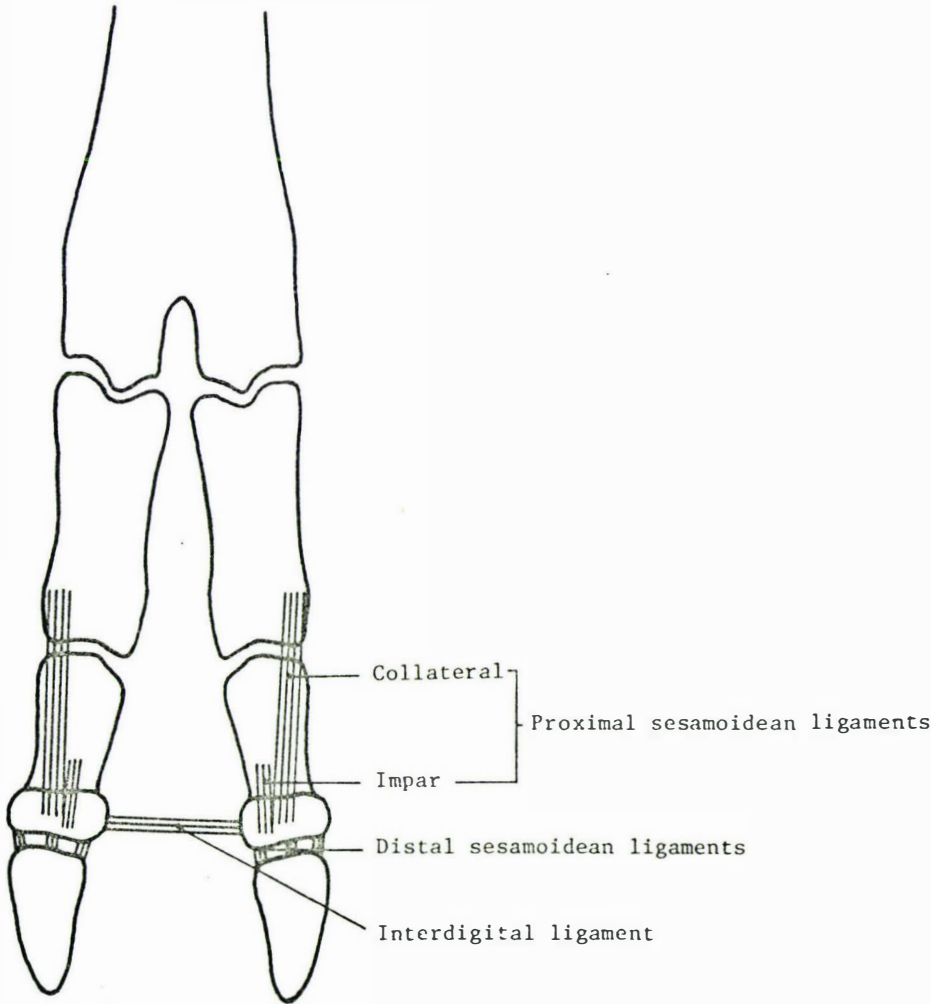
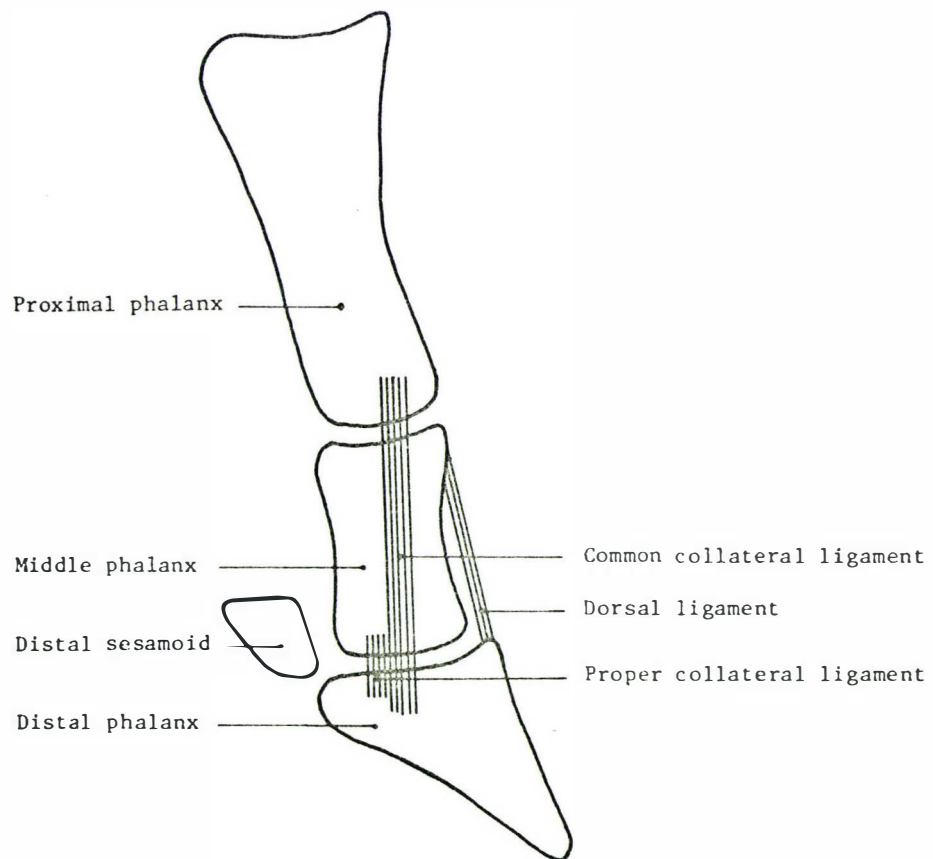


FIGURE 3.6

DORSAL AND COLLATERAL LIGAMENTS OF THE
DISTAL INTERPHALANGEAL JOINT OF SHEEP

(axial aspect)



DISCUSSION

It was evident that the distal interphalangeal joint was most vulnerable to infection or trauma on the axial or interdigital aspect, where the joint capsule protruded above the coronary border as the dorsal and volar pouches. At these two sites, the joint capsule was protected only by the interdigital skin layer and a minimal amount of subcutaneous tissue. It is considered that this is the most likely route of infection in cases of foot abscess.

The anatomy of the distal interphalangeal joint of sheep differed from that of cattle principally in the structure preventing splaying of the digits. In cattle there are cruciate ligaments which link the second phalanx of one digit with the distal sesamoid of the other digit (Greenough *et al.*, 1972) thus limiting the separation of the digits. In sheep, this function is performed by the relatively weak interdigital ligament, which it is suggested acts functionally as a continuation of each proximal collateral sesamoidean ligament (Fig. 3.5).

Another important structure that prevents splaying of the digits in both sheep and cattle is the axial common collateral ligament. This ligament was thicker than the abaxial collateral ligament, presumably because forces abducting the joint are greater. In some cases of foot abscess there is marked abduction and even luxation of the distal phalanx caused by rupture of the axial collateral ligaments and the interdigital ligament (Chapter 4). Permanent instability of the joint then ensues.

CONCLUSIONS

1. The distal interphalangeal joint of sheep is most vulnerable to infection or trauma on the axial, or interdigital, aspect where the joint capsule protrudes above the coronary border as the dorsal and volar pouches. It is considered that this is the most likely route of infection in cases of foot abscess.
2. In sheep the interdigital ligament and each proximal collateral sesamoidean ligament help limit separation of the two digits; a role performed in cattle by the cruciate ligaments.
3. The axial common collateral ligament is thicker than the abaxial ligament, presumably because forces abducting the distal interphalangeal joint are greater than those adducting it.

CHAPTER 4

A STUDY OF NATURALLY OCCURRING CASES OF OVINE FOOT ABSCESS

INTRODUCTION

METHODS

- Photography
- Radiology
- Bacteriology
- Treatment
- Statistics

OBSERVATIONS

- History
- Seasonal occurrence
- Breed
- Sex
- Age
- Distribution of affected digit
- Description
- Prognosis
- Radiography
- Bacteriology

DISCUSSION

CONCLUSIONS

INTRODUCTION

It was necessary initially to study naturally occurring cases of ovine foot abscess, to define the features of the disease in New Zealand, to follow the development of infected cases, to observe the effects of treatment and to establish whether or not the New Zealand disease was identical to the conditions reported overseas.

Much of the earlier confusion about suppurative conditions of the ovine foot had been removed by the Australian workers (Roberts *et al.*, 1968) who differentiated between lamellar suppuration (toe abscess) and foot abscess. This helped to define the more common foot abscess but their description differed from previous observations in that they considered the bulbar soft tissue of the foot was the centre of the infection and they made no mention of the infection involving the distal interphalangeal joint. However, joint involvement had been observed by previous Australian workers (Munane, 1933; Gregory, 1939; Beveridge, 1941). Furthermore, Roberts *et al.* (1968) considered foot abscess to be a necrotising, rather than a suppurative infection and for these reasons suggested the term 'Infective Bulbar Necrosis'.

This study of naturally occurring cases was undertaken to define ovine foot abscess in New Zealand and to establish whether or not the New Zealand cases differed from the description given by Roberts *et al.* (1968).

METHODS

Sheep farmers serviced by the Massey University Veterinary Clinic were asked to refer suspected cases of foot abscess to the clinic. Many of these farmers had ram-breeding flocks.

Between June 1974 and June 1978, lame sheep were admitted to the Massey University Veterinary Hospital where they were examined in detail and records made of the development of the lesion. In particular, note was taken of the degree of lameness, swelling and digital displacement, and the presence of any sinus tracts and the type of material discharging from them.

In addition, approximately 120 individual cases of foot abscess were observed on a number of farms in the region, but for various reasons the affected sheep could not be returned to Massey University for detailed examination. An analysis of these cases has not been included in this study.

Photography

Colour, and black and white photographs of the affected feet were taken regularly, using a 35mm camera. In most cases 2 views of the foot were required; an anterior view and a distal view.

Radiology

The affected feet were radiographed at approximately weekly intervals using a portable Watson-Victor type 60 X-ray generator with exposure factors of 55 kilovolts and 30 milliamps for 0.1 of a second. Two views of the affected foot were taken; an anterior and an oblique (Fig. 4.1). Both of these views were consistently taken from the anterior-posterior direction and all radiographs presented in this thesis conform to conventional radiological presentation; that is, they are presented as if the animal is facing the viewer. Therefore, if the left fore foot is

radiographed, the lateral digit will always be on the viewers right and the medial digit on the viewers left.

The lateral view was considered unsatisfactory because the image of the one unaffected digit lay over the other digit.

Bacteriology

Swabs of discharge from sinuses at either the coronet or the interdigital space were cultured aerobically and anaerobically on five percent sheep blood agar plates.

Treatment

The lame sheep, referred to the Veterinary Hospital remained the property of the client and therefore it was impractical to conduct a controlled treatment trial. In addition, the sheep were not all at the same stage in the disease process when they were admitted to the Hospital. For these reasons, treatment based on first principles was instituted when considered necessary. In instances where pus had accumulated in the affected digit, this was expressed and sinus tracts irrigated with chlorhexidine¹ antiseptic. The foot was then bandaged in an endeavour to prevent further contamination and to reduce the splaying of the affected digit. A mixture of penicillin and streptomycin² at dose rates ranging from 50 to 70 mg/kg of each, was administered by the subcutaneous route in the neck region. This was given daily for as long as the acute swelling and pain remained.

Statistics

The distribution and frequencies of observations, were subjected to analysis using the chi-squared test. In every case Yates' correction factor was applied and expected values were always greater than five. The probability of differences occurring by chance (P), were read off tables for chi-squared, using the appropriate degrees of freedom.

1 Hibitane I.C.I. Tasman, Upper Hutt, New Zealand

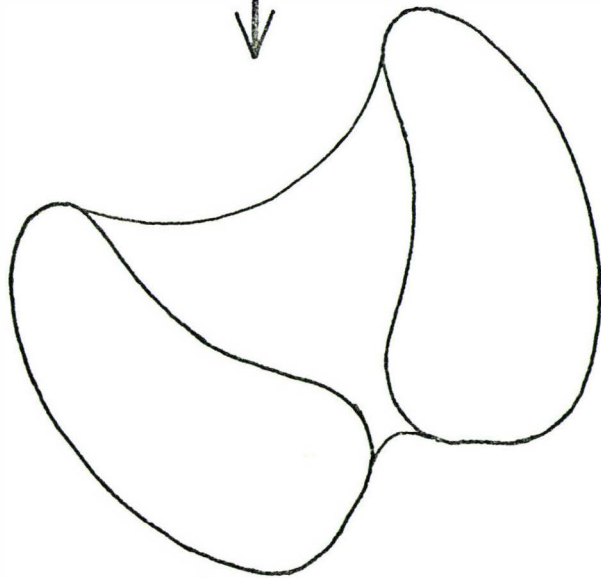
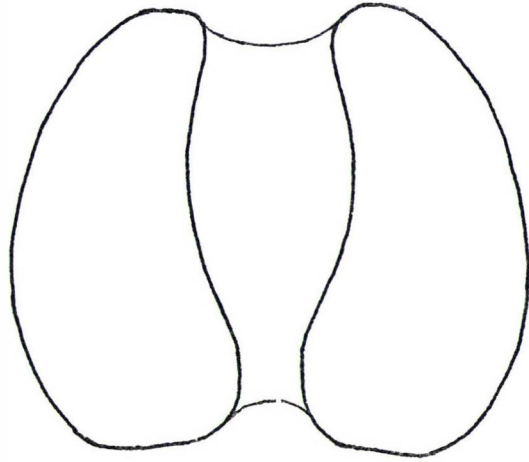
2 Streptopen, Glaxo, Palmerston North, New Zealand.

FIGURE 4.1a and b

The two positions of the foot and the direction of the X-ray beam during radiology.

a) Anterior

b) Oblique



OBSERVATIONS

Over the four year period, 53 sheep with foot abscess having 57 affected digits, were admitted to the Veterinary Hospital for detailed examination.

History

In most cases there was no history of previous lameness and foot abscess had already developed by the time the condition was first observed by the owner. In 22 cases, other sheep in the flock were concurrently affected with ovine interdigital dermatitis and in 7 instances ovine interdigital dermatitis had been observed to be affecting the foot a few days before the development of foot abscess (Chapter 5). In two sheep, lamellar suppuration had preceded foot abscess. In one of these (Fig. 4.2 a and b) the owner had cut into the abaxial wall of the affected digit in an attempt to drain the imprisoned pus in the lamellar region. In so doing, he had damaged the 3rd phalanx and probably aided the infection reaching the distal interphalangeal joint.

In the other instance of lamellar suppuration preceding foot abscess, the wall of the foot had been conservatively pared at the time that lamellar suppuration was first diagnosed. Four days later the digit was extremely swollen (Fig. 4.3 a and b) and the distal interphalangeal joint infected (Fig. 4.3c). In this case the most likely route of infection into the distal interphalangeal joint was from the infection in the lamellar region tracking upwards.

FIGURE 4.2 a and b

The left fore foot of a Perendale ram which had developed foot abscess in the lateral digit, presumably as a consequence of overparing of the hoof by the owner.

- a) The defect in the abaxial wall (arrowed) is clearly visible.

G - granulation tissue

T - sinus tracts

- b) Radiograph of the foot

E - erosion of bone

W - widening of the joint space

P - proliferation of bone

The bone which had proliferated adjacent to the distal phalanx at the point of the original paring, eventually became detached and was removed via the defect in the abaxial wall.

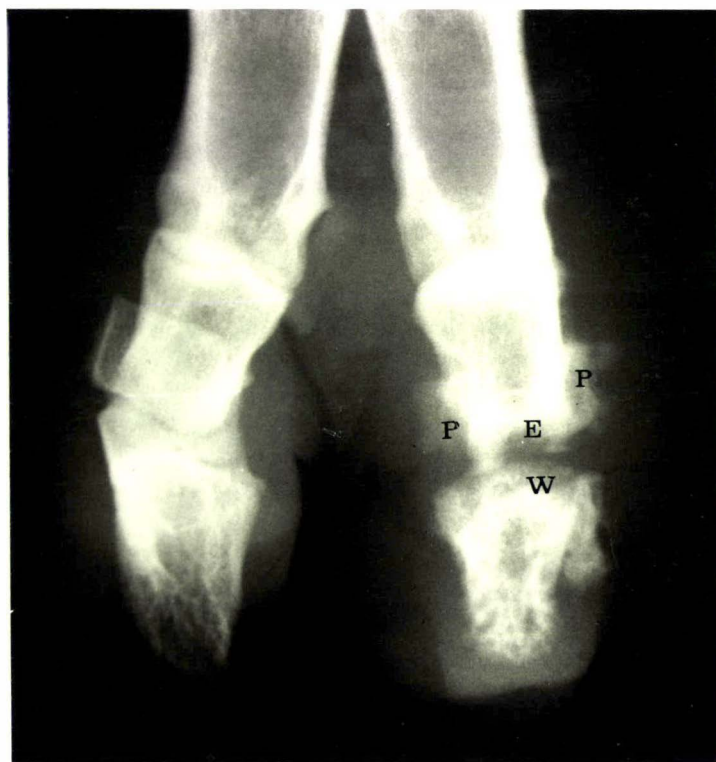
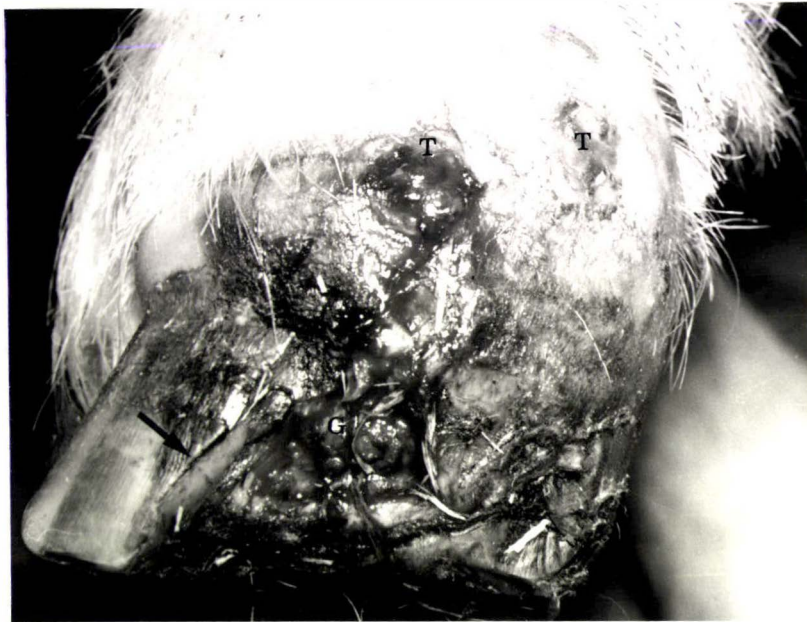


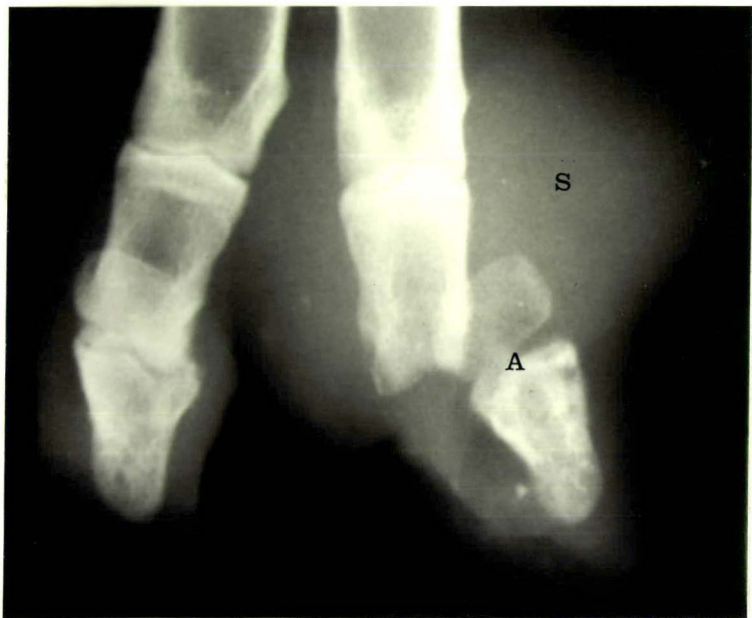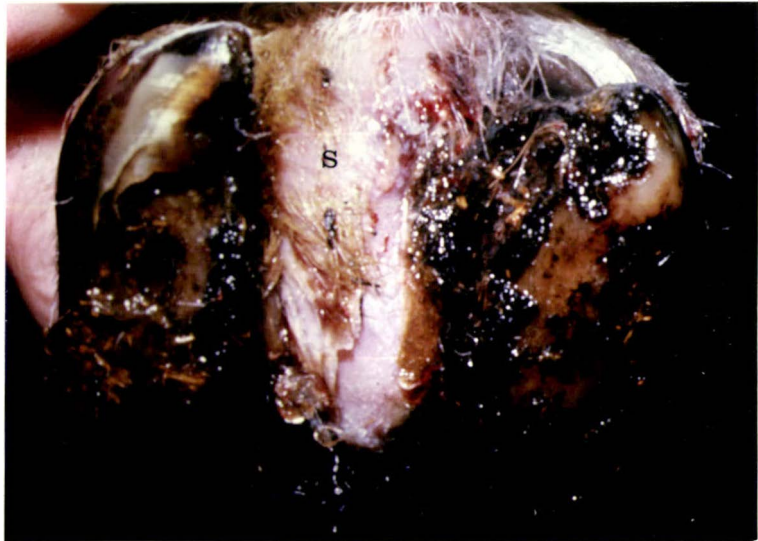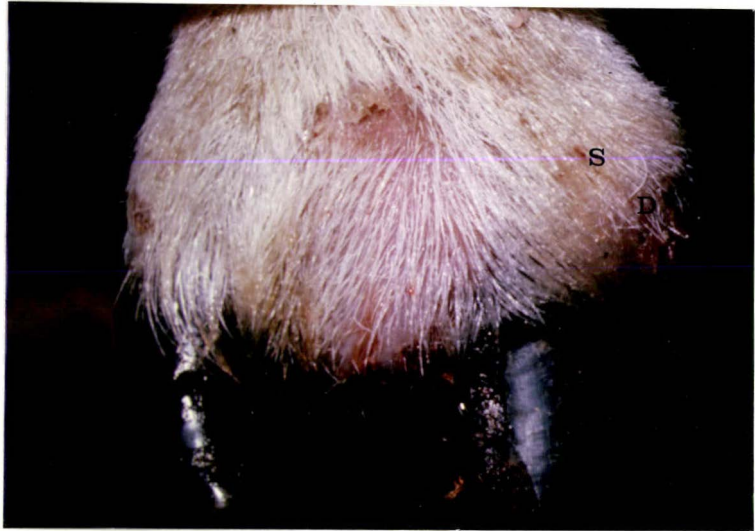FIGURE 4.3 a, b and c

The left fore foot of a Perendale ram with foot abscess of the lateral digit. Seven days previously, pus had been observed imprisoned in the lamellar region of the toe.

a) S - soft-tissue swelling
 D - discharge

b) S - swollen, but intact interdigital skin.

c) Radiograph of the foot
 S - soft-tissue swelling
 A - Abaxial displacement of the distal phalanx and distal sesamoid.



Seasonal Occurrence

Sheep with foot abscess were admitted to the Veterinary Hospital throughout the year (Table 4.I) but significantly fewer sheep were admitted during the summer months ($P < .01$).

TABLE 4.I

The number of sheep with foot abscess admitted to the Veterinary Hospital during the years 1974 to 1978, according to season.

<u>Season</u>	<u>Number of Sheep</u>
Summer	4
Autumn	18
Winter	16
Spring	15
Total	53

Breed

Greater numbers of Perendale sheep than other breeds were affected with foot abscess (Table 4.II). However a number of Perendale breeders were closely associated with the University and 29 of the 35 Perendale sheep were from the University-owned Perendale stud flock. Therefore it is considered that the proportion of Perendales affected was a reflection of the availability of this breed to the investigator.

TABLE 4.II

The breed and age of sheep with foot abscess admitted to the Veterinary Hospital

<u>Breed</u>	<u>Age of sheep (years)</u>					<u>Total</u>
	<u>0-1</u>	<u>1-2</u>	<u>2-3</u>	<u>3-4</u>	<u>4 & older</u>	
Perendale	22	6	1	2	4	35
Romney	4	3	-	-	-	7
Cheviot	3	2	-	-	1	6
Suffolk	-	-	-	3	-	3
Coopworth	1	-	-	-	-	1
Drysdale	1	-	-	-	-	1
Total	31	11	1	5	5	53

Age

More sheep less than one year of age with foot abscess were studied compared to other age groups (Table 4.II). However many of the flocks from which sheep were referred, were ram-breeding flocks which contain about 20 young rams for every mature ram present (Martin, C.A. pers. comm.). Therefore the greater number of young rams studies is attributed to the age distribution of rams in stud flocks.

Sex

Fifty of the 53 referred sheep were rams.

Distribution of the affected digit

More hind feet than fore feet were affected with foot abscess (Table 4.III); this difference being statistically significant. ($P < .05$).

If the fore foot was affected, there was a significantly greater chance that the lateral digit would be the one affected. ($P < .01$). There was no statistically significant difference in the distribution of foot abscess between the medial or lateral claw of the hind foot (Table 4.III).

TABLE 4.III

The distribution of the digit affected with foot abscess amongst sheep admitted to the Veterinary Hospital

	left fore	right fore	<u>Sub total</u> <u>fore feet</u>	left hind	right hind	<u>Sub total</u> <u>hind feet</u>
Lateral	13	5	18	11	2	13
Medial	3	0	3	14	9	23
	Total forefeet		21	Total hindfeet		36

Description

The sheep with foot abscess were at different stages in the development of infection at the time that they were first examined, and the period that they had been affected was generally not known. Because the starting point of each case is unknown it is unrealistic to compare the progress of the cases on a time scale. Similar changes were observed in all cases however, and this similarity makes it possible to describe a sequence of events common to cases of foot abscess.

The 53 sheep that were presented with foot abscess were all extremely lame, and preferred to carry the affected foot. Three sheep were affected in more than one foot and this resulted in prolonged periods of recumbency. A further sheep was affected in both digits of one foot. Despite the severe pain and the sometimes suppurative nature of the infection, the rectal temperature, heart rate and respiratory rate were not abnormally elevated.

In the early stages there was marked oedematous swelling and inflammation of the interdigital space, displacing the affected digit abaxially (Fig. 4.4 and Fig. 4.6). In places the interdigital skin was necrotic and bloody necrotic material and/or pus could be expressed from these areas. They formed most frequently on the site of the interdigital space furthest from the affected digit (Fig. 4.4 and Fig. 4.5). In later stages the discharge became more purulent in nature and contained less necrotic tissue. The discharge of pus was eventually blocked by the formation of granulation tissue so that it accumulated in the joint cavity. This pressure was transmitted to the skin above the abaxial coronet which became painful, inflamed and swollen (Fig. 4.4 and Fig. 4.5). Sinus tracts formed along the abaxial coronary border region at sites where the joint is relatively superficial. There was direct continuity between the coronary sinus tracts, the distal interphalangeal joint, and the interdigital space.

In 20 of the 57 affected digits, exaggerated movement of the digit was possible, which indicated that the necrotising joint infection had ruptured the axial collateral ligaments and the interdigital ligament, resulting in luxation of the distal phalanx and the distal sesamoid bone. The healing process in these cases was insufficient to prevent abaxial displacement of the distal phalanx when pressure was applied during locomotion. In cases where the axial collateral ligaments and the interdigital ligament remained intact, there was better alignment of the distal phalanx with the other phalanges and although some permanent thickening and deformity remained from the joint infection, the digit could function normally without becoming displaced abaxially.

As the condition progressed into the healing stages, the pain and swelling regressed and the sinus tracts stopped discharging and healed over. In some cases the granulation tissue in the interdigital space was excessive and was removed surgically. (Fig. 4.8 and Fig. 4.9 a and b).

Prognosis

Within 8 weeks of the sheep being admitted for examination, regardless of whether or not treatment had been administered, they had all progressed to a stage at which there was no active infection in the digit, sinus tracts had healed and except for some permanent fibrous thickening, the swelling had subsided. All of the sheep were slightly lame however and digital displacement was evident in the 20 sheep which apparently had permanent damage to the joint ligaments.

Radiography

Radiography of the affected foot revealed that there was evidence of infection in the distal interphalangeal joint in all cases, even when first admitted to the Veterinary Hospital. The earliest signs seen were peri-articular soft tissue swelling, distension of the joint capsule and

widening of the joint space (Fig. 4.10 and Fig. 4.11). Within a few days the articular cartilage was destroyed, exposing the subchondral bone to infection. This showed on X-ray plates as a poorly defined zone (fuzziness) of the subchondral bone (Fig. 4.13). New bone proliferated adjacent to the periosteum, particularly of the middle phalanx and eventually covered much of this bone (Fig. 4.10; Fig. 4.11; Fig. 4.12 and Fig. 4.13). In the instances where the axial collateral ligaments and the interdigital ligament had all ruptured, the distal phalanx and the distal sesamoid were luxated (Fig. 4.7 and 4.10). Osteomyelitis, particularly of the distal end of the middle phalanx created further widening of the joint space which became filled with debris and exudate. In addition to the proliferation of bone adjacent to the periosteum, calcification also developed in the periarticular tissue. (Fig. 4.13).

Radiographic changes were not always confined to the distal interphalangeal joint of the affected digit. In the more severe cases proliferation of bone occurred on the proximal phalanx. (Fig. 4.13d) or on the middle phalanx of the adjacent digit. (Fig. 4.12 and Fig. 4.13).

As the condition progressed into the healing stages the soft tissue swelling regressed and the outline of the new bone became smooth and more clearly defined. (Fig. 4.10; Fig. 4.12 and Fig. 4.13). Due to the dissolution of bone, particularly of the middle phalanx, the affected digit was shorter than the adjacent non-affected digit (Fig. 4.12 and Fig. 4.13). Ankylosis of the damaged joint space was not observed, even in cases examined 9 months after the infection had subsided.

Bacteriology

Fusobacterium necrophorum and *C. pyogenes*, either alone or in combination, were isolated from 46 of the 53 sheep with foot abscess (Table 4.IV). Isolation of micro organisms was not attempted in 5 cases because the owner had recently administered antibiotics both locally and systemically.

TABLE 4.IV

Isolations of *Fusobacterium necrophorum* and *Corynebacterium pyogenes* from sheep with foot abscess

<u>Bacteria Isolated</u>	<u>Number of cases</u>
<i>F. necrophorum</i> and <i>C. pyogenes</i>	24
<i>F. necrophorum</i>	12
<i>C. pyogenes</i>	10
Mixed organisms	2
Not sampled	5
Total	53

FIGURE 4.4 a and b

The right hind foot of a Perendale ram affected with foot abscess in the lateral digit.

- a) S - swollen interdigital space
 D - purulent discharge
 A - abaxial displacement of the
 affected digit.

- b) S - soft-tissue swelling above the
 coronet
 A - abaxial displacement of the
 affected digit.

Seven days after this photograph was taken, pus discharged from the swollen area above the coronet (S).

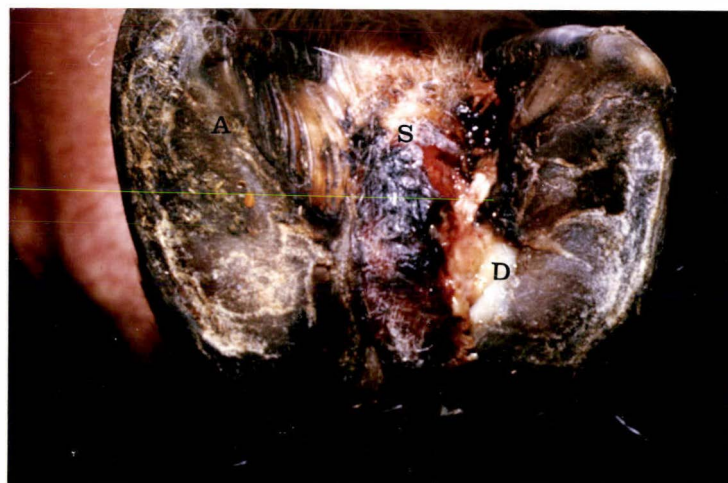

FIGURE 4.5 a and b

The left hind foot of a Cheviot ram with
foot abscess of the lateral digit.

a) S - swollen interdigital space
 D - purulent discharge

b) S - swelling above the coronet
 D - purulent discharge

Five days after this photograph
was taken, pus discharged from
the swollen area above the
coronet (S).

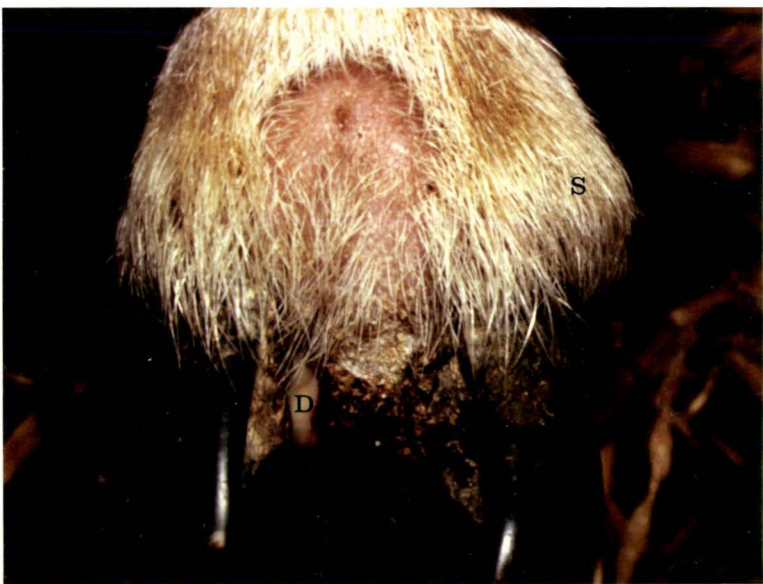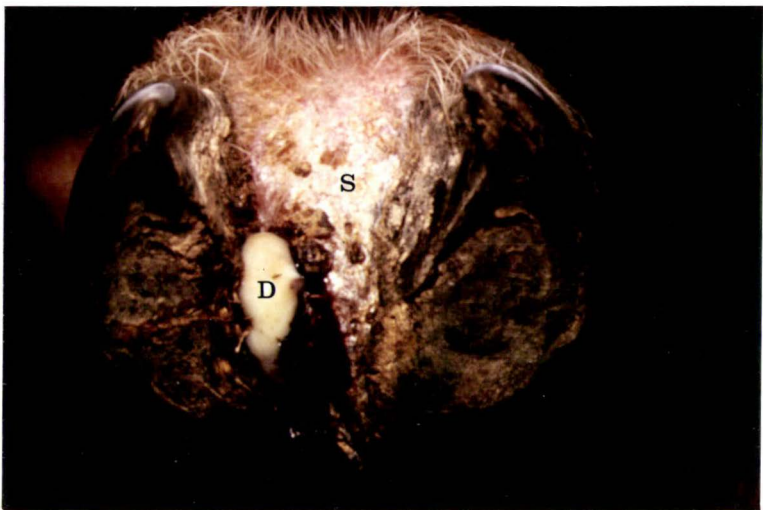


FIGURE 4.6

The left hind foot of a Perendale
ram with foot abscess of the lateral
digit.

A - abaxial displacement of the digit
D - discharge of blood and pus
T - sinus tract

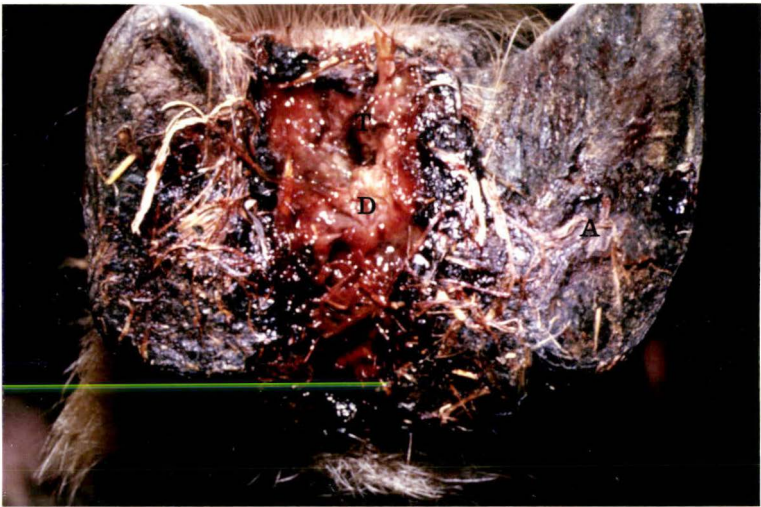


FIGURE 4.7

The left hind foot of a Perendale ram
with foot abscess of the lateral digit.

A - abaxial displacement of
the distal phalanx and the
distal sesamoid.

S - soft-tissue swelling

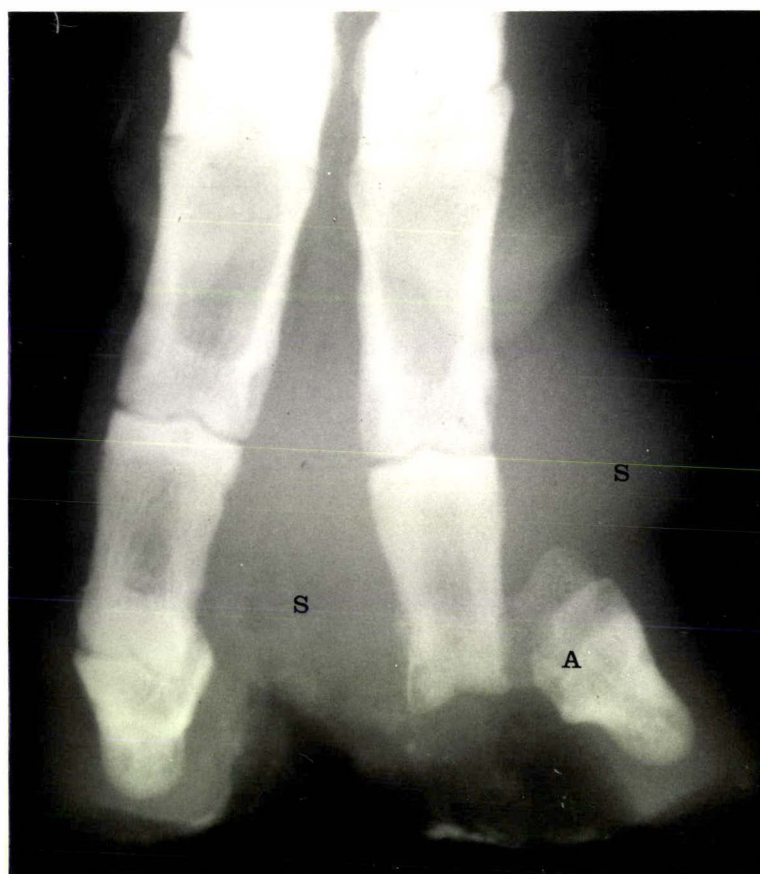

FIGURE 4.8

The left hind foot of a Perendale ram,
photographed 16 days after foot abscess
was first noticed.

G - granulation tissue.

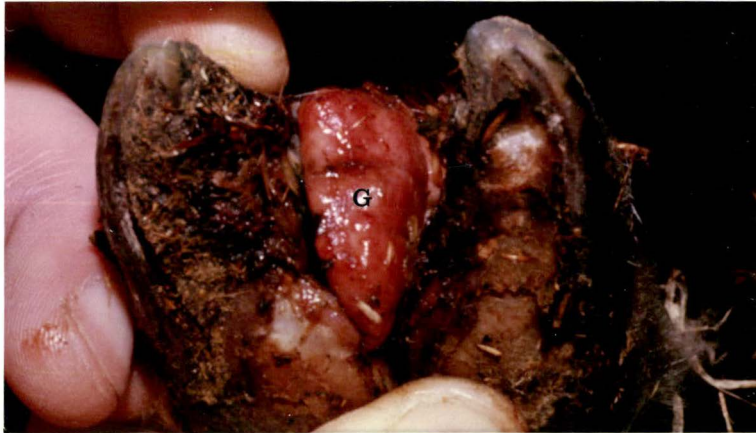

FIGURE 4.9 a and b

The left fore foot of a Cheviot ram,
photographed 14 days after foot abscess
was first noticed.

a) Distal view

G - granulation tissue

b) Anterior view

G - granulation tissue

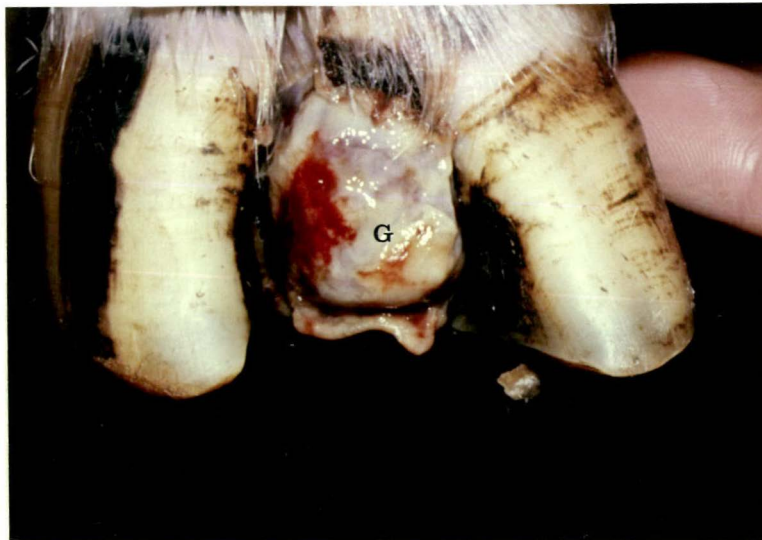
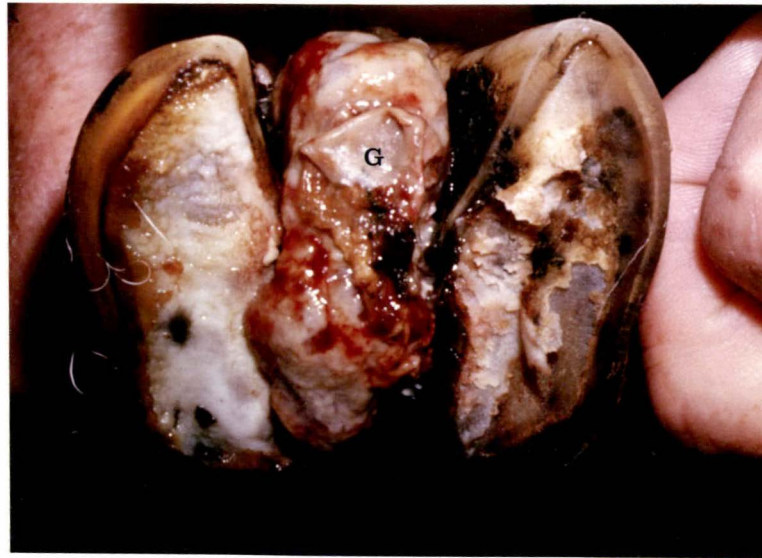
FIGURE 4.10 a, b and c

Radiographs of the left hind foot of a Perendale ram with foot abscess of the lateral digit.

- a) Radiograph on the day of admission to the Veterinary Hospital.

S - soft tissue swelling

W - widening of the joint space

- b) Radiograph - day 4.

A - abaxial displacement of the distal phalanx and the distal sesamoid.

E - erosion of bone

P - proliferation of bone

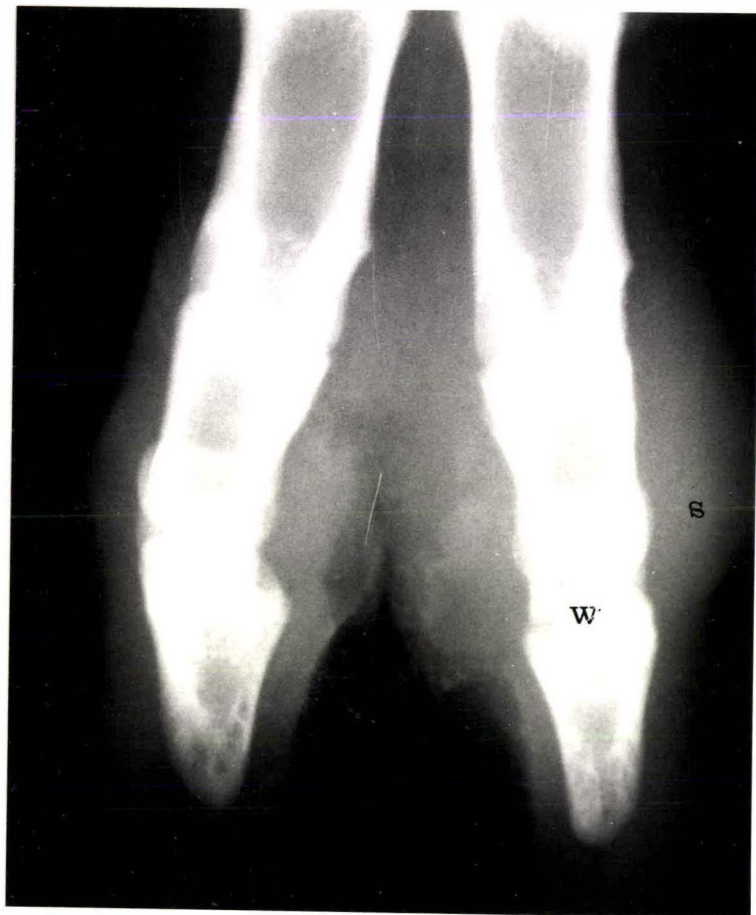S - soft tissue swelling

- c) Radiograph - day 40

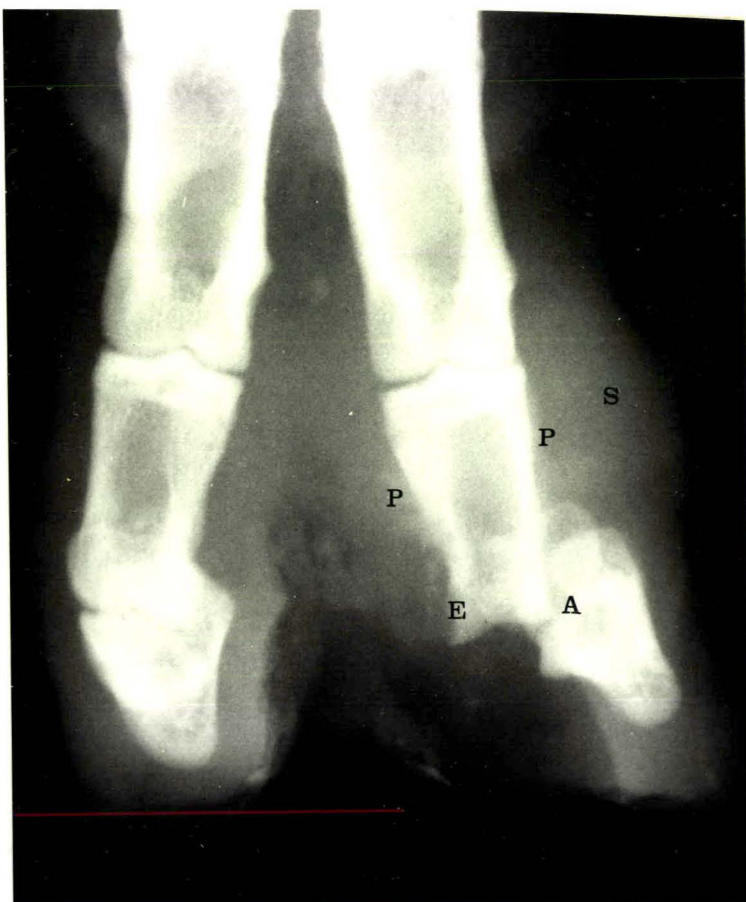P - proliferation of bone

By day 40 much of the soft tissue swelling had subsided and there was better alignment of the phalanges. The bone that had proliferated was well-defined and smooth in outline which indicated that healing had occurred.

a



b



c

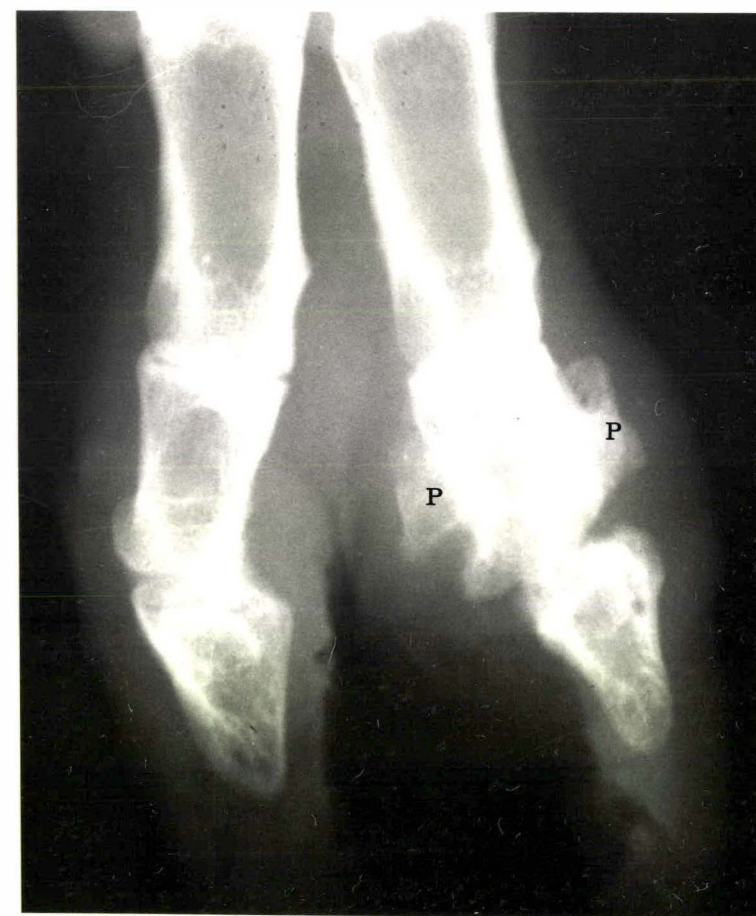

FIGURE 4.11

Radiograph of the left hind foot of a Perendale ram with foot abscess of the lateral digit.

S - soft-tissue swelling

P - proliferation of bone

W - widening of the joint space

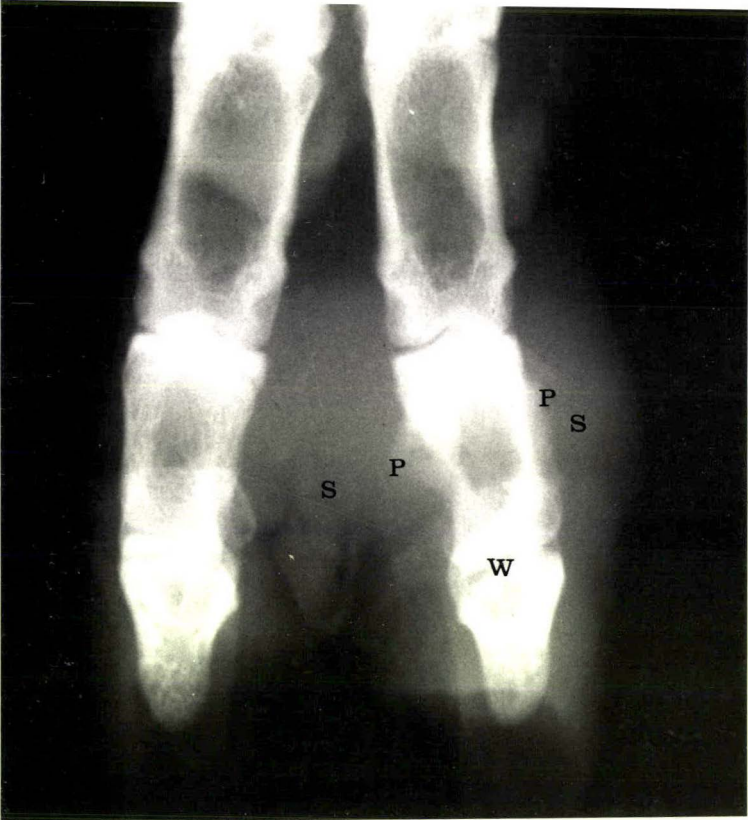


FIGURE 4.12 a, b, c and d

Radiographs of the left hind foot of a Perendale ram with foot abscess of the medial digit.

- a) Radiograph on the day of admission to the Veterinary Hospital.

S - soft-tissue swelling
E - loss of definition and density of the sub-chondral bone.
P - proliferation of bone.

- b) Radiograph - day 4

P - proliferation of bone
E - erosion of bone

- c) Radiograph - day 10

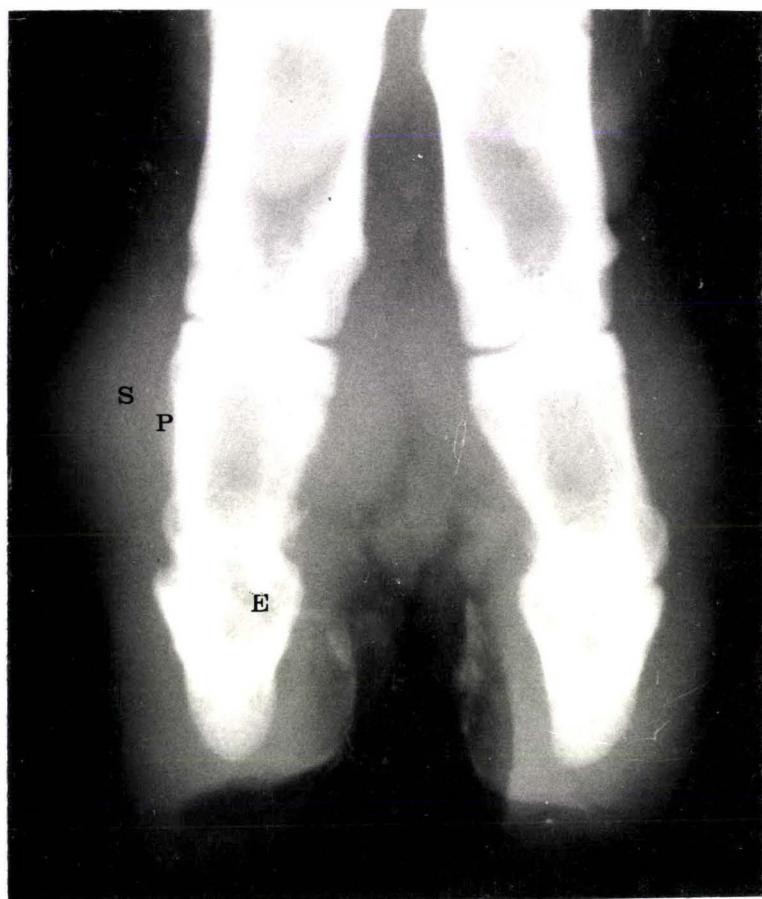P - proliferation of bone
E - erosion of bone

- d) Radiograph - day 40

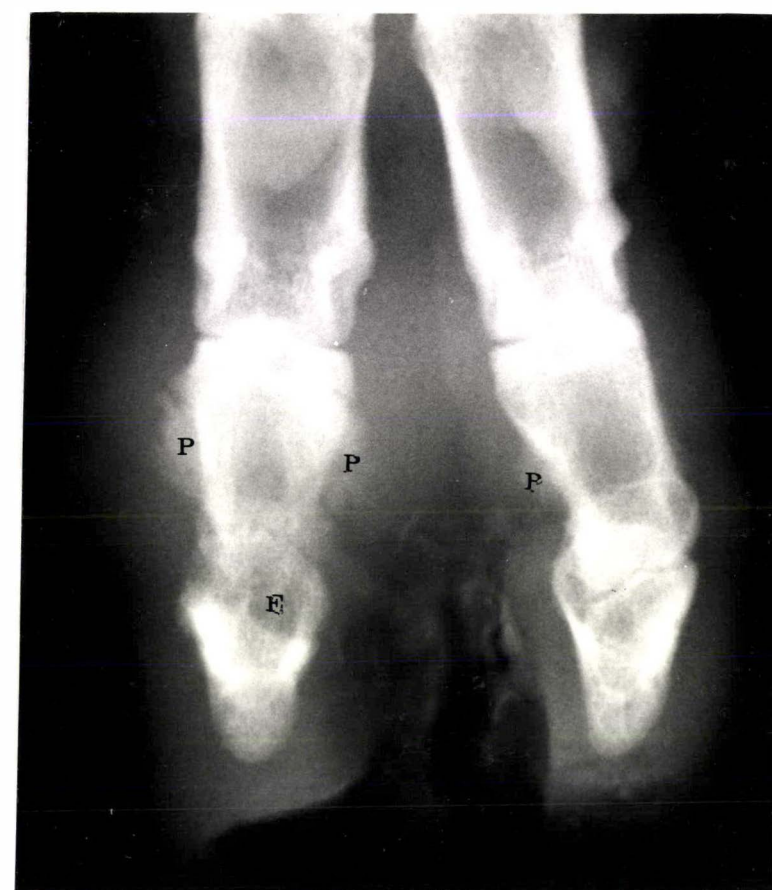P - proliferation of bone

By day 40 much of the soft tissue swelling had regressed and the outline of the new bone that had proliferated was smooth and well defined, which indicated that healing had occurred. The affected digit remained shorter than the adjacent digit.

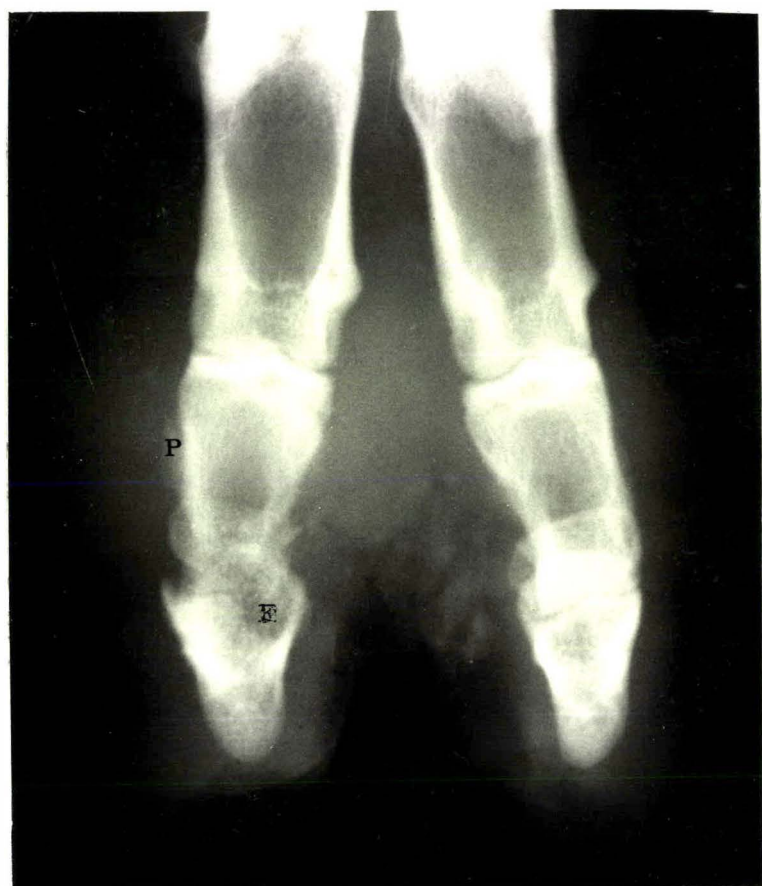a



c



b



d

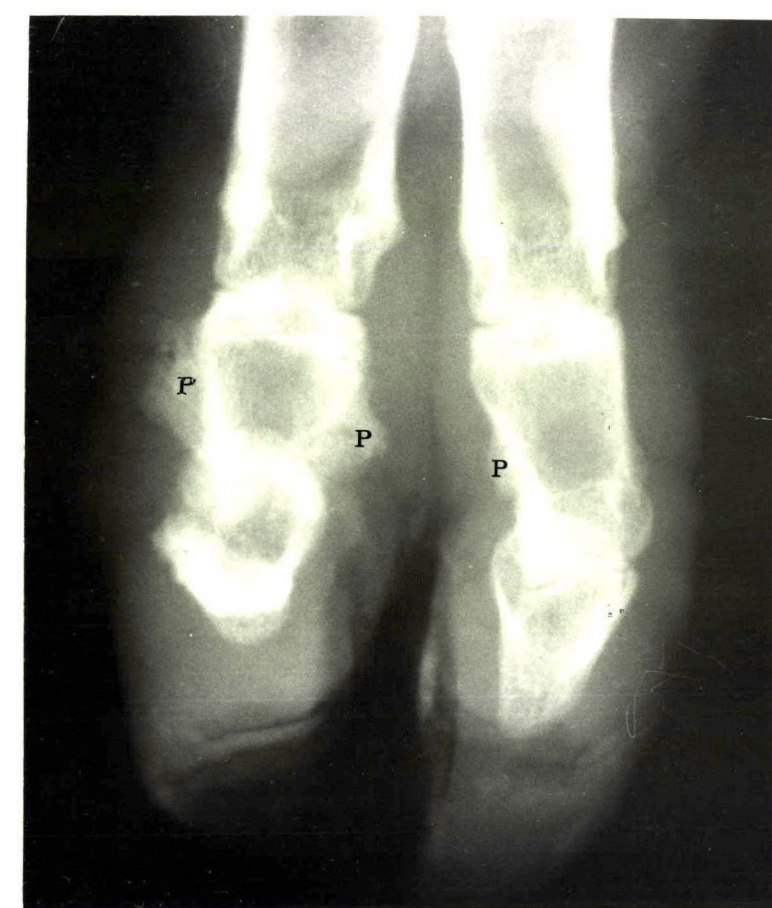


FIGURE 4.13 a, b, c and d

Radiographs of the left hind foot of a Cheviot ram with foot abscess of the lateral digit.

a) Radiograph on the day of admission to the Veterinary Hospital.

- S - soft tissue swelling
- P - proliferation of bone
- A - abaxial displacement of the distal phalanx and the distal sesamoid.

b) Radiograph - day 7

- E - erosion of bone
- P - proliferation of bone
- D - point of discharge of pus

c) Radiograph - day 14

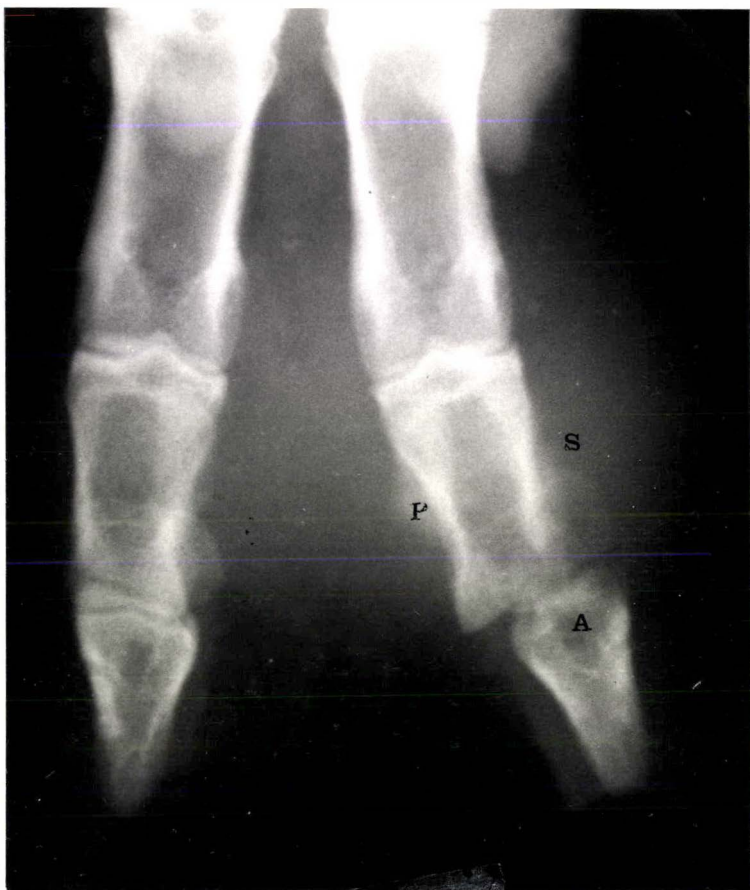- E - erosion of bone
- W - widening of the joint space
- P - proliferation of bone

d) Radiograph - day 40

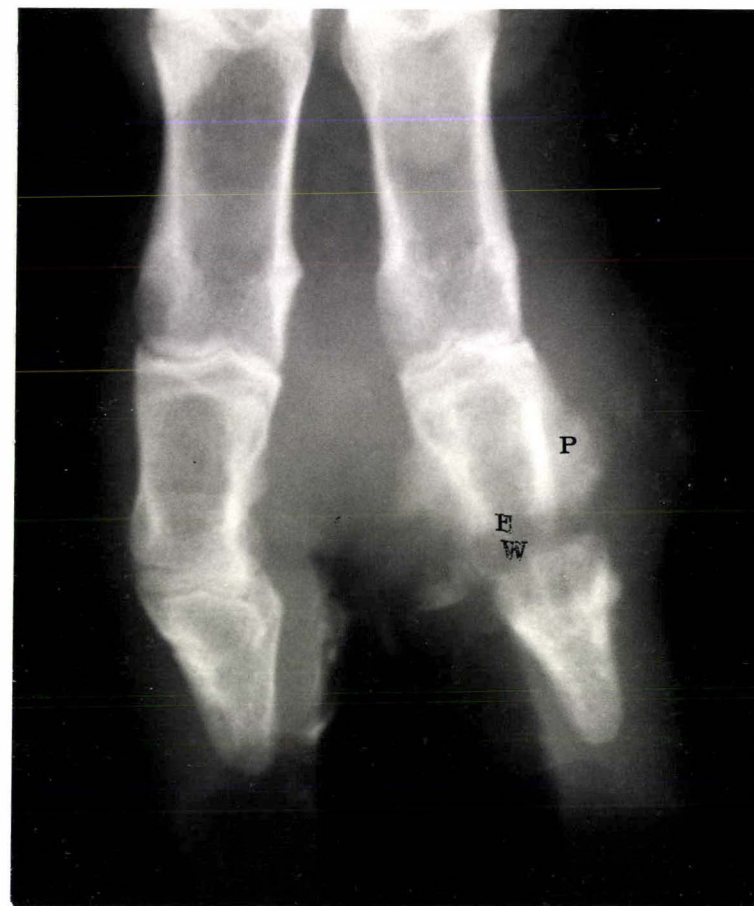- P - proliferation of bone

By day 40 much of the soft tissue swelling had regressed and the new bone that had proliferated was well defined and smooth in outline, which indicated healing. The affected digit remained shorter than the adjacent digit.

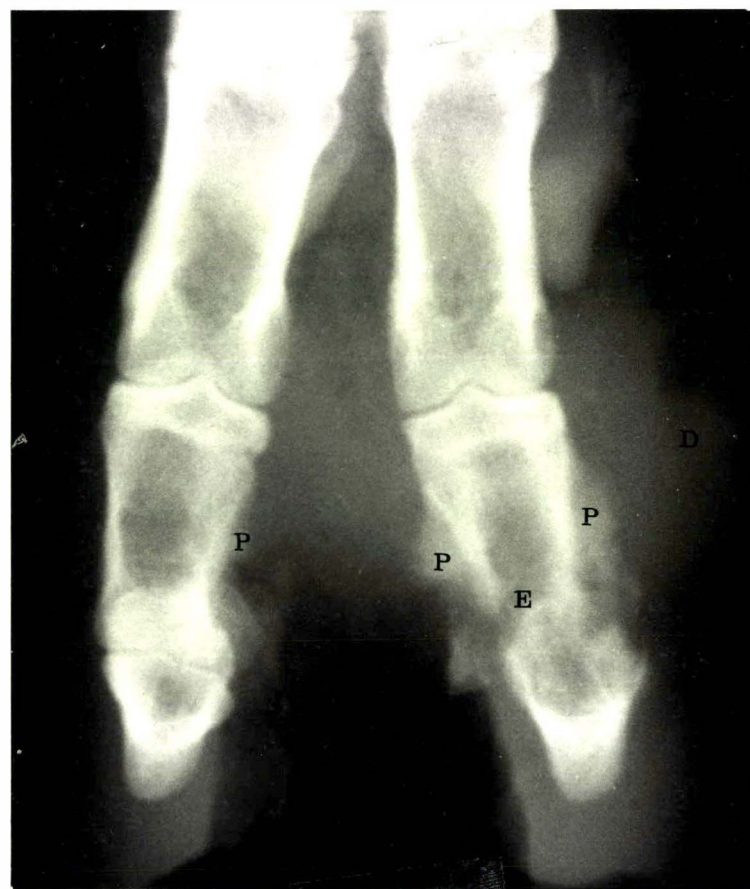a



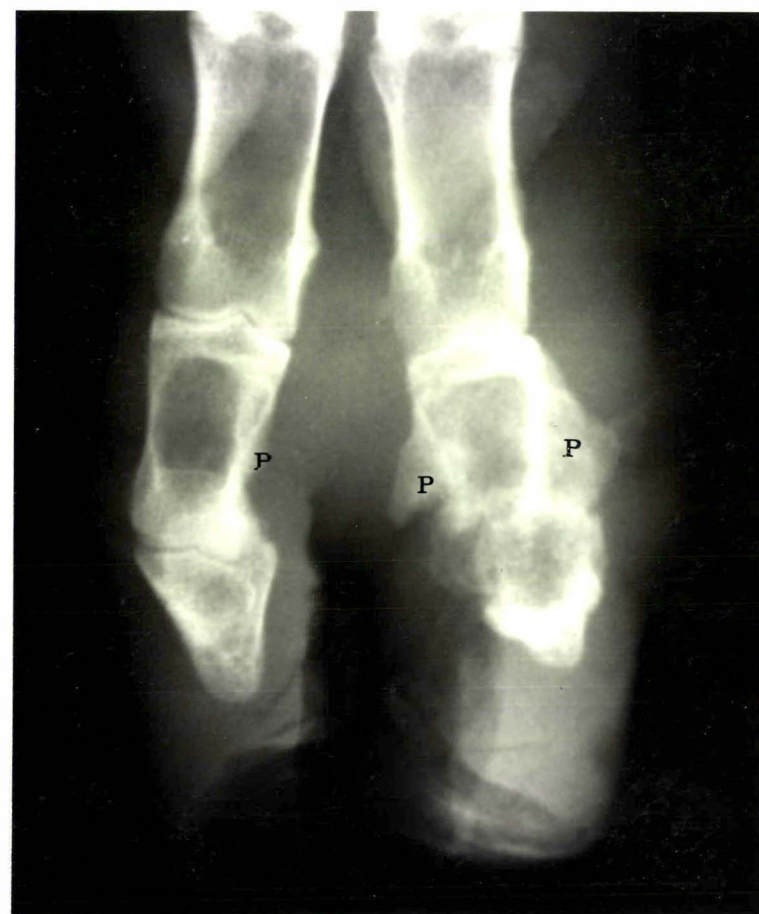c



b



d



DISCUSSION

The description of foot abscess in this case study is similar to that of Roberts *et al.* (1968), but some important differences were noted. In this study the distal interphalangeal joint was found to be the centre of the infection, not the bulbar soft tissue as described by Roberts *et al.* (1968). Apparently their opinion was formed following the dissection of affected feet and had the feet been radiographed first, they may have reached a different conclusion. It is also possible that the Australian foot condition is different from that in New Zealand, but early descriptions by others in Australia (Murnane, 1933; Gregory, 1939; Beveridge, 1941) described infection invading joints and involving ligaments. In addition, Roberts *et al.* (1968) mention the formation of sinus tracts at the abaxial coronary border region, a feature recorded by previous Australian workers and confirmed in this study. From an anatomical viewpoint it is difficult to imagine that sinuses such as these would result, if the infection was centred on the bulbar soft tissue. The anatomical study (Chapter 3) and the radiographs of affected feet, clearly demonstrate the continuity between the distal interphalangeal joint and the points of discharge at the coronet and the interdigital space. Therefore it is concluded that foot abscess is essentially an infection of the distal interphalangeal joint and that Roberts *et al.* (1968) were mistaken in incriminating the bulbar soft tissue as the centre of the infection. For this reason the term 'Infective Bulbar Necrosis' is considered inappropriate.

Roberts *et al.* (1968) also considered that foot abscess was a necrotising rather than a suppurative condition as described by Gregory (1939). In this case study necrotising lesions were seen more commonly in earlier cases of foot abscess and these tended to become more suppurative with time.

This observation is probably explained by the ratio of different bacteria involved in the infective process. Roberts *et al.* (1968) noted that *F. necrophorum* predominated in early more necrotic lesions and that *C. pyogenes* predominated in later more suppurative cases. Both descriptions are therefore considered appropriate.

In most cases the history given by the owner was inadequate to explain how the condition had developed to a stage in which infection had reached the distal interphalangeal joint. Concurrent infection with ovine interdigital dermatitis was common however, and it is likely that in these cases the interdigital space was the route of infection into the joint. Roberts *et al.* (1968) made similar observations. Two cases of foot abscess were observed to arise from infection in the lamellar region and one of these was attributed to over-vigorous paring of the wall of the hoof by the owner.

Once infection was established in the distal interphalangeal joint, a relatively uniform and thus predictable series of events took place that inevitably resulted in some permanent damage and deformity to the digit. If rupture of the axial collateral ligaments occurred, the joint became unstable and the degree of permanent deformity was greater. Treatment did not appear to markedly affect the progress of the lesion or the outcome, once infection had become established in the joint.

Except for the dorsal and volar pouches of the joint capsule (Fig. 3.1), the distal interphalangeal joint is contained within the hoof and it was impossible to effectively drain the joint (even using surgical techniques) without further damaging joint structures such as ligaments. An important component of therapy of infectious arthritis is the removal from the joint, often by surgical means, of necrotic tissue, purulent material and fibrin deposits (Verschooten, De Moor, Steenhaut, Desmet, Wouters and De Ley, 1974). To significantly

alter the outcome of infection, therapy would have to either prevent the infection becoming established in the joint, or prevent the infection involving the axial collateral ligaments with the possibility of subsequent rupture. In other words therapy would have to be initiated before or very soon after, the infection reached the joint. In instances where the route of infection is considered to be from an extension of ovine interdigital dermatitis, therapy should be initiated when the infection is seen to penetrate to deeper layers beneath the interdigital skin. In addition, bandaging the foot to prevent splaying of the digits might be expected to reduce the chances of the axial collateral ligaments rupturing, by reducing pressure on the ligaments.

In Australian commercial flocks, foot abscess was observed most often in lambing ewes (Roberts *et al.*, 1968) which contrasts with the sex ratio of 50 rams to 3 ewes found in this study. The results of the postal survey of New Zealand farmers (Chapter 2), also indicated that rams were more susceptible to foot abscess than ewes. This apparent difference between the Australian and New Zealand observations is most likely due to the composition of the flocks under observation. In Australia, the flocks studied were commercial flocks comprising very few rams and at the time of year of the study the rams would have been grazed separately and may not have been exposed to the same predisposing conditions as the ewes. In contrast the New Zealand observations were made largely in ram-producing flocks, which although still consisting of more ewes than rams, contained enough rams to highlight the difference in susceptibility associated with sex. Breed of sheep or age were not considered important predisposing factors.

The decrease in the number of sheep with foot abscess in summer was significant and the proportion of sheep that had foot abscess in each season was remarkably similar to the farmer opinion of seasonal occurrence (Table 2.III). Roberts *et al.* (1968) considered that most cases of foot

abscess occurred after heavy rain in autumn, winter and spring, and so there is general agreement that foot abscess is less prevalent during summer.

Roberts *et al.* (1968) observed that more hind feet were affected than fore feet with foot abscess. This was also observed in this study, although the difference was not as marked as that reported by Roberts *et al.* (1968).

There was a significantly greater chance that if a fore foot was affected, then the affected digit would be the lateral one. Anatomically it is difficult to explain why the lateral digit of the fore foot should be more susceptible than the medial one, but perhaps the reason is more closely related to the forces exerted on the digit than to the structure of the digits themselves.

The frequent isolation of *F. necrophorum* and *C. pyogenes* organisms from discharge from the sheep with foot abscess, agrees with the observations of Roberts *et al.* (1968), and supports their contention that these two organisms are the aetiologically important bacteria. That aspect is explored further in Chapter 6 of the thesis.

CONCLUSIONS

1. The distal interphalangeal joint is invariably involved in foot abscess, not the bulbar soft tissue as suggested by Roberts *et al.* (1968) and it is recommended that the term 'Infective Bulbar Necrosis' should be dropped.
2. Once infection becomes established in the distal interphalangeal joint, a relatively uniform and thus predictable series of events takes place that inevitably results in some permanent damage to the joint and deformity to the digit.
3. If the axial collateral ligaments of the distal interphalangeal joint rupture, then the joint becomes unstable and the likelihood of permanent deformity is greater.
4. Radiology is a particularly useful aid both for diagnosis and prognosis.
5. Once infection has become established in the distal interphalangeal joint, treatment is unlikely to markedly affect the progress of the lesion, or the outcome.
6. Prognosis for complete recovery from foot abscess is poor, but over about a 2 month period the foot heals sufficiently to allow for adequate locomotion. Deformity may persist.
7. *Fusobacterium necrophorum* and *C. pyogenes* are frequently isolated from foot abscess lesions and this supports the contention of Roberts *et al.* (1968) that these two organisms are the aetiologically important bacteria.

CHAPTER 5

INVESTIGATION OF A FLOCK OUTBREAK OF DERMATITIS, NECROSIS AND EROSION OF THE INTERDIGITAL SKIN, RESULTING IN SOME CASES OF OVINE FOOT ABSCESS.

INTRODUCTION

- Farm profile
- History of the problem

METHODS

- Bacteriology
- Radiology
- Treatment

RESULTS

- Observation
- Bacteriology
- Radiology
- Effect of treatment

DISCUSSION

- Description
- Predisposing factors contributing to ovine interdigital dermatitis and foot abscess
- Differentiation between ovine interdigital dermatitis and foot abscess

SUMMARY

INTRODUCTION

It was suggested by the Australian workers Egerton, Roberts, Graham and Parsonson (1966) that foot abscess arises most commonly as a direct sequel to ovine interdigital dermatitis. This view is supported by their subsequent observations (Roberts *et al.*, 1968) that both foot conditions can be present in one flock at the same time and that in several instances, foot abscess had been preceded by ovine interdigital dermatitis. However, proof of such a sequence has not been conclusively established, nor has there been a previous investigation in New Zealand into the relationship between ovine interdigital dermatitis and foot abscess.

Previous descriptions of interdigital dermatitis in sheep have been at variance regarding the severity of the condition. Murnane (1933) described maceration, erosion and suppuration of the interdigital tissue accompanied by marked lameness, whereas Parsonson *et al.* (1967) in their comprehensive paper, described a milder condition involving erythema, swelling and in some cases, erosion of the interdigital skin; but lameness and suppuration were not characteristic features. For these reasons it was considered important to undertake a field investigation of an outbreak of lameness associated with some foot abscess and to make a detailed description of the findings.

This investigation was conducted in a Perendale stud flock in which lameness, particularly amongst young rams, had been an annual problem during late autumn and early winter. As many as 50 individuals from the flock of 300 ram hoggets (9 months old), had required treatment for foot abscess in previous years and the manager sought advice when once again a proportion of the rams suddenly appeared lame on 12 May 1976.

Farm Profile

Location: Palmerston North/Ashhurst Road,
12 Kilometres from Palmerston North.

Property size: 440 hectares divided into 120 hectares
of flats and 320 hectares of hill
country

Soil type: Grey-brown earth (Graywake)

Altitude: 50 metres rising to 400m at the back
of the property

Annual rainfall: 1000mm on the flats
1750 mm on the higher back country

Pasture species: Predominantly ryegrass and white clover
species.

Stock numbers: Sheep - 2,260 mixed-age Perendale ewes
700 nine-month old Perendale
ewes (hoggets)
300 nine-month old Perendale
rams (hoggets)

Cattle - 150 Aberdeen Angus breeding cows

History of the Problem

At both fifteen and nine days prior to the outbreak of lameness first being observed, the ewe and ram hoggets had been yarded for drenching and crutching (Table 5.I). During the same period, heavy rainfall had resulted in very wet and muddy underfoot conditions. Over the three days, 29, 30 April and 1 May, 76.4mm of rain fell (Table 5.I) and further rain fell on 6 out of the next 10 days which preceded the outbreak of lameness.

METHODS

The property was visited on 12, 14, 20, 24 and 30 May, and 6 June. At each visit the ram hoggets were mustered and any rams carrying the foot or severely inconvenienced were separated for further examination and treatment. A total of 100 rams out of the flock of 300 were separated and treated during the course of the investigation.

Bacteriology

Twenty seven swabs taken from the interdigital lesion were stained by grams method and examined microscopically. Culture was attempted both aerobically and anaerobically using five percent sheep blood agar plates.

Radiology

In instances where foot abscess had developed, or was considered likely to develop, the affected foot was radiographed in the manner described in Chapter 4.

Treatment

Lame rams were housed on wooden gratings in the property woolshed and fed meadow hay. They were walked once through a five metre long foot bath containing a five percent formalin solution. Each ram was individually inspected and the interdigital area was cleaned to remove any dried scabs of exudate. In instances where the infection was judged to be invading the deeper tissues and suppuration was present, two grams of a penicillin/streptomycin mixture (i.e. approximately 40mg/kg of each) was administered subcutaneously in the neck of the sheep. Sixty two of the 100 rams were treated daily by this schedule for periods ranging from one to four days.

In an attempt to prevent further cases of lameness, the remainder of the ram flock was walked through a foot bath containing a five percent formalin solution on 21 May.

TABLE 5.I

The occurrence of new cases of lameness in relation to the daily rainfall and management procedures

<u>Date</u>	<u>Rainfall mm</u>	<u>New cases of lameness</u>	<u>Management procedure</u>
20 April	0.8		
21	0.0		
22	0.2		
23	7.3		
24	1.3		
25	0.0		
26	0.0		
27	0.0		ram and ewe hoggets
28	0.0		yarded and drenched
29	15.0		
30	31.8		
1 May	29.6		
2	0.5		
3	0.0		ram and ewe hoggets
4	0.0		yarded and crutched
5	0.7		
6	2.5		
7	12.0		
8	0.0		
9	16.2		
10	0.3		
11	0.0		
12	35.1	10	first veterinary visit
13	0.6		
14	0.4	10	veterinary visit
15	0.0		
16	0.0		
17	0.0		
18	0.0		
19	6.0		
20	15.8	36	veterinary visit
21	0.0		
22	0.1		
23	0.0		
24	0.0	32	veterinary visit
25	2.0		
26	5.6		
27	0.0		
28	0.0		
29	0.0		
30	0.0	12	veterinary visit
31	0.1		
1 June	0.7		
2	0.0		
3	14.6		
4	4.9		
5	11.2		
6	6.2	0	veterinary visit
7	0.0		
8	0.0		
9	2.2		
10	7.4		
Total		100	

RESULTS

Observations

The numbers of new cases of lameness reached a peak by the third visit, then declined over the following three weeks (Table 5.I).

At no stage of the investigation were any of the ewe hoggets noticeably lame although they were managed in a similar way to the ram hoggets, but grazed separately. It was noticeable however that the behaviour of the ram hoggets was different from that of the ewe hoggets. Whereas the ewes were spread fairly evenly over the available pasture, the rams formed loose groups around focal points and indulged in frequent sexual activity (Fig. 5.1). This sexual behaviour of mounting and riding one another, trampled the pasture underfoot into a mixture of mud and faeces devoid of grass.

Except for nine sheep which were classified as having typical foot abscess, the lesions in the other animals, involved only the interdigital skin and to varying degrees, the subcutis. Many of the sheep were affected in all four feet with lesions similar to those described by Parsonson *et al.* (1967). The interdigital skin was reddened and swollen and frequently covered by a moist film of whitish necrotic material (Fig. 5.2a). However, in instances where the foot was carried the lesion was more severe and the interdigital skin was necrotic and eroded, thus exposing the sensitive subcutaneous tissues (Fig. 5.2 b-f). In some instances suppuration and swelling of the deeper interdigital tissues was present (Fig. 5.2 g and h).

There was no tendency for the interdigital lesion to cause under-running of the hoof wall at the region of the axial coronet as occurs in early footrot (Beveridge, 1941) and the characteristic smell associated with *B. nodosus* infection (Egerton and Graham, 1969) was absent.

As the interdigital lesion healed, granulation tissue filled the damaged subcutaneous area (Fig. 5.1i), and epithelium growing inwards from the periphery eventually repaired the defect in the integument.

The more severe lesions, resulting in lameness occurred more often in the hind feet than the fore feet ($P < 0.001$, Table 5.II).

TABLE 5.II

The occurrence of lameness associated with necrosis and erosion of the interdigital skin.

<u>Numbers of affected sheep</u>					
<u>left</u> <u>fore</u>	<u>right</u> <u>fore</u>	<u>sub total</u> <u>fore feet</u>	<u>left</u> <u>hind</u>	<u>right</u> <u>hind</u>	<u>sub total</u> <u>hind feet</u>
19	15	34	46	36	82

In 9 sheep the foot lesions were classified as foot abscess and these animals were referred to the Massey University Veterinary Hospital for further study (included in Chapter 4 of this thesis). In seven of these nine, necrosis and erosion of the interdigital skin was observed one to two weeks before foot abscess developed. In the remaining two sheep, foot abscess was already well established at the time of the initial visit to the property, so it was impossible to confirm that foot abscess had been preceded by an interdigital lesion.

Bacteriology

Direct microscopic examination of gram-stained smears from the interdigital lesion revealed a mixture of organisms with a preponderance of gram negative bacilli and gram positive bacilli. The characteristic morphology of *B. nodosus* was not observed. Culture from this mixed flora revealed the presence of *F. necrophorum* in all but one of the 27 swabs taken, and *C. pyogenes* was grown from 20.

Radiology

The nine rams diagnosed as having foot abscess showed typical radiological signs of infection of the distal interphalangeal joint (Chapter 4).

Where only the interdigital skin and the immediate underlying tissues were involved, radiological changes were confined to an increased density of the affected tissues (Fig. 5.3), apart from 4 cases (Fig. 5.4), in which there was a periosteal reaction on the surface of the middle phalanx. This periostitis, combined with swelling of the soft tissue about the abaxial coronet, indicated that the infection had reached either the distal interphalangeal joint, or the soft tissue adjacent to the joint and middle phalanx. However the typical radiological joint changes that are seen with foot abscess (Chapter 4) did not occur and the condition resolved at this stage.

Effect of treatment

The ram hoggets appeared to respond well to treatment and by the end of May, 60 had been returned to the flock and a week later the remainder had recovered, except for the 9 rams that had developed foot abscess.

FIGURE 5.1 a and b

Ram hoggets grouped together.

Some rams (arrowed) are riding others in the group.



FIGURE 5.2 a, b and c

Photographs of the interdigital space of Perendale ram hoggets affected with ovine interdigital dermatitis.

E - erosion of the interdigital skin.

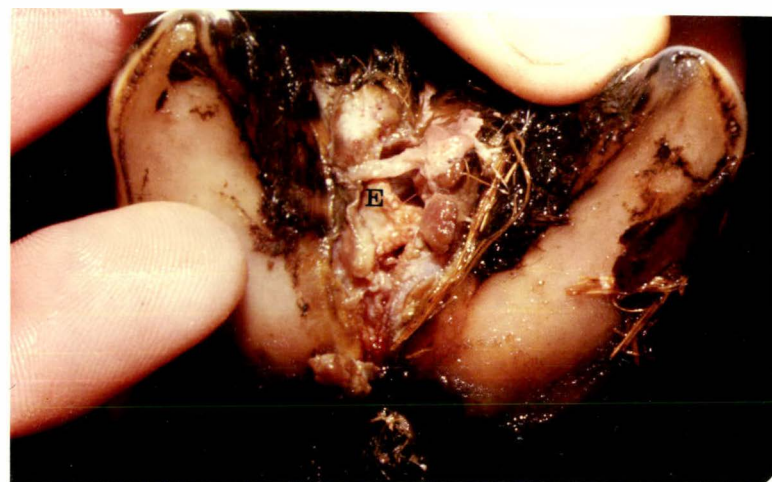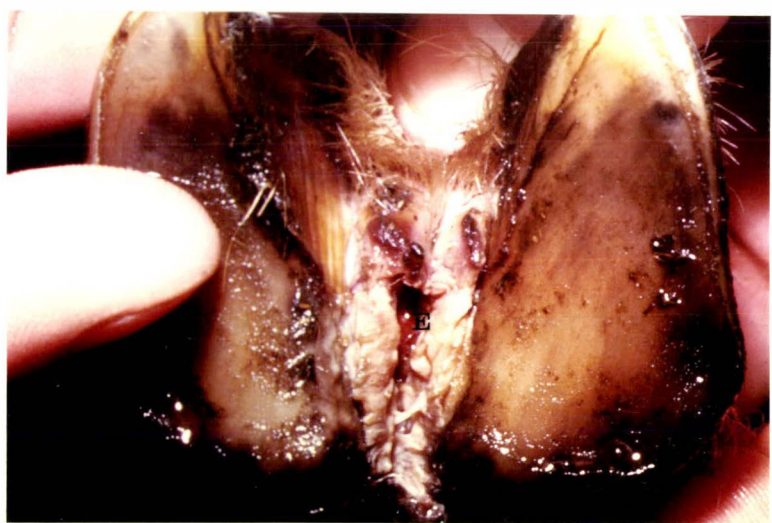

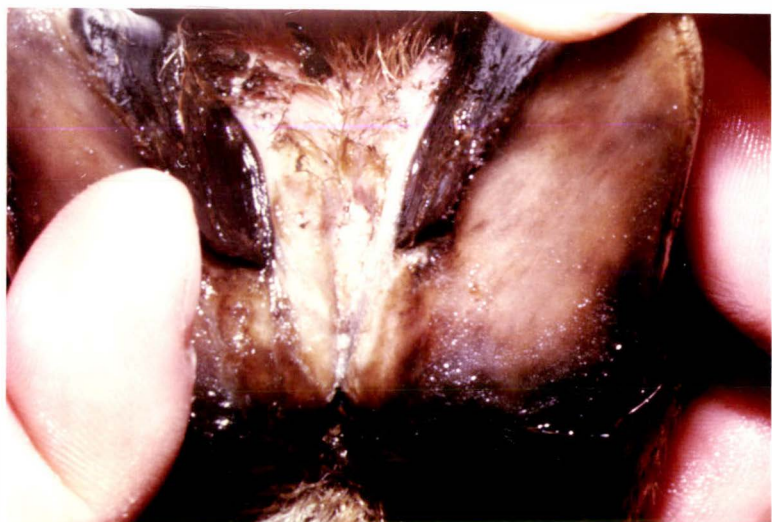
FIGURE 5.2 d, e and f

Photographs of the interdigital space of Perendale ram hoggets affected with ovine interdigital dermatitis.

E - erosion of the interdigital skin.

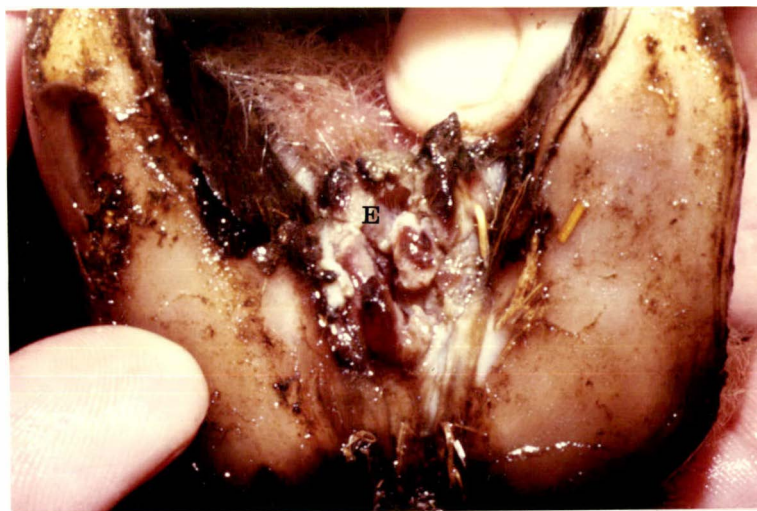
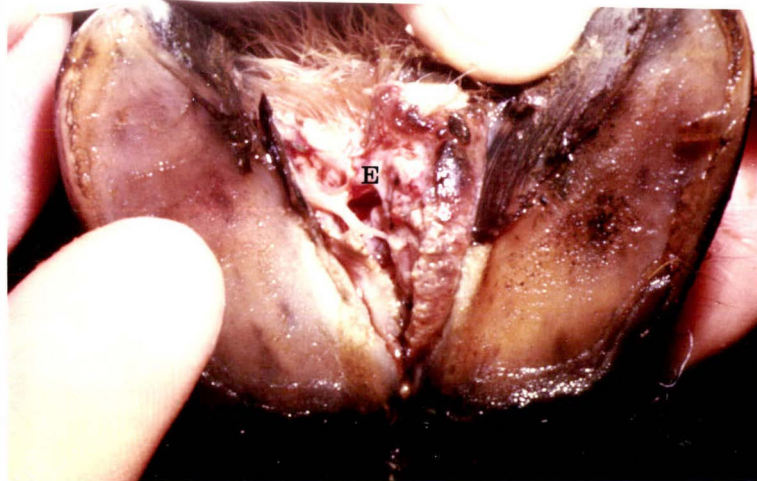
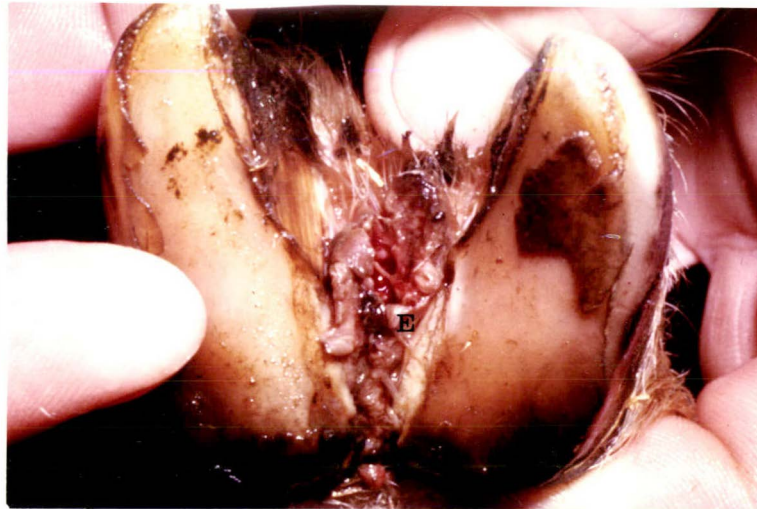


FIGURE 5.2 g, h and i

Photographs of the interdigital space of Perendale ram hoggets affected with ovine interdigital dermatitis.

P - purulent material
G - granulation tissue

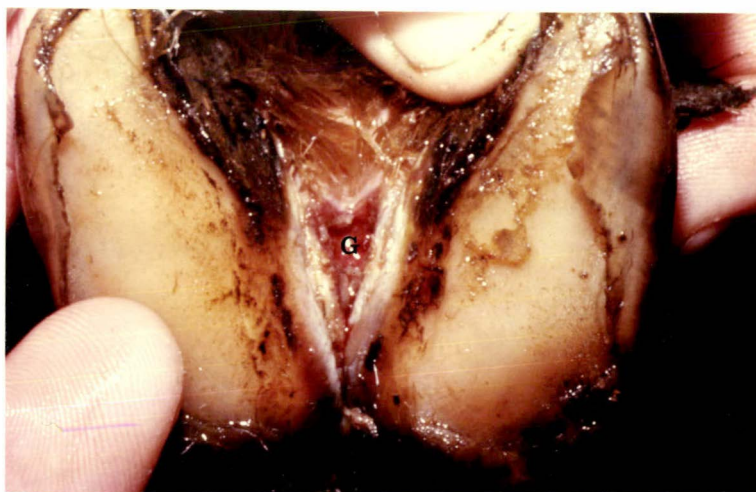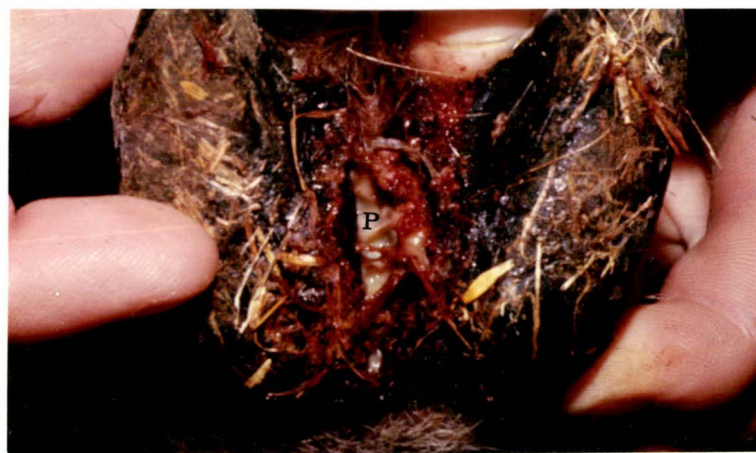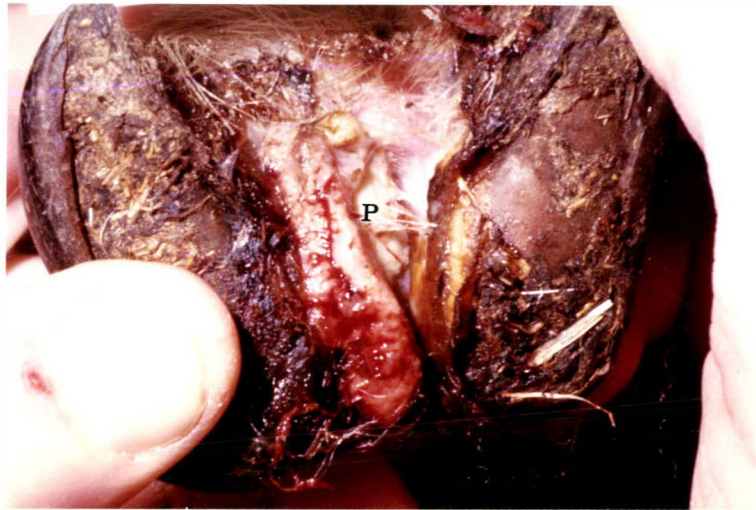


FIGURE 5.3

Radiograph of a sheep's foot affected with ovine interdigital dermatitis.

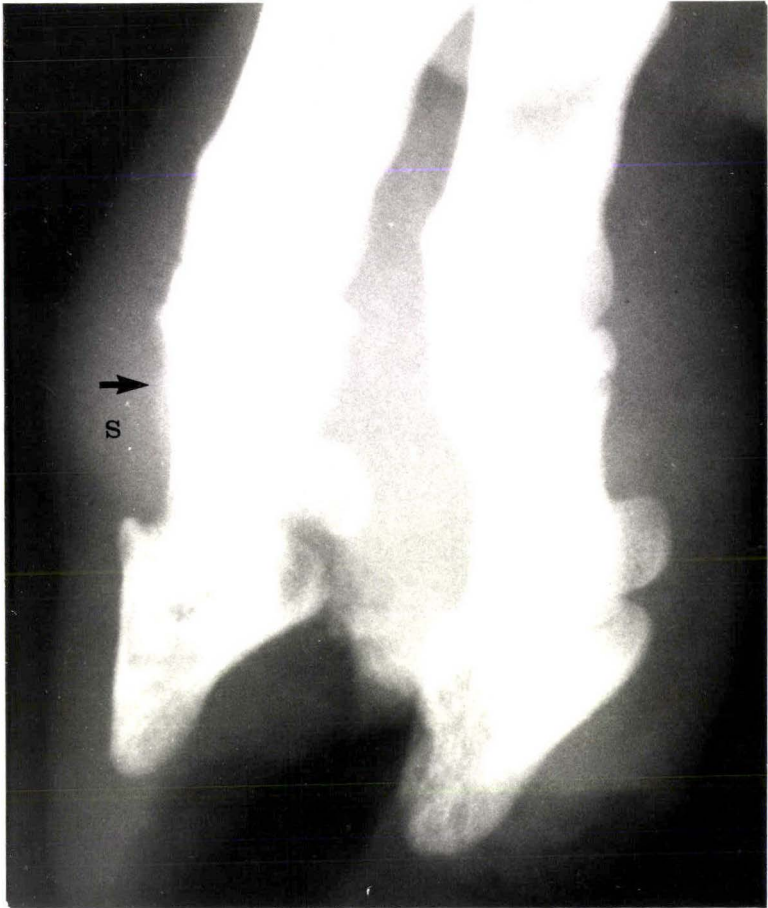
There is increased radiodensity of the interdigital tissues indicating the extent of the soft tissue swelling. The increased pressure centrally has displaced the digits abaxially.

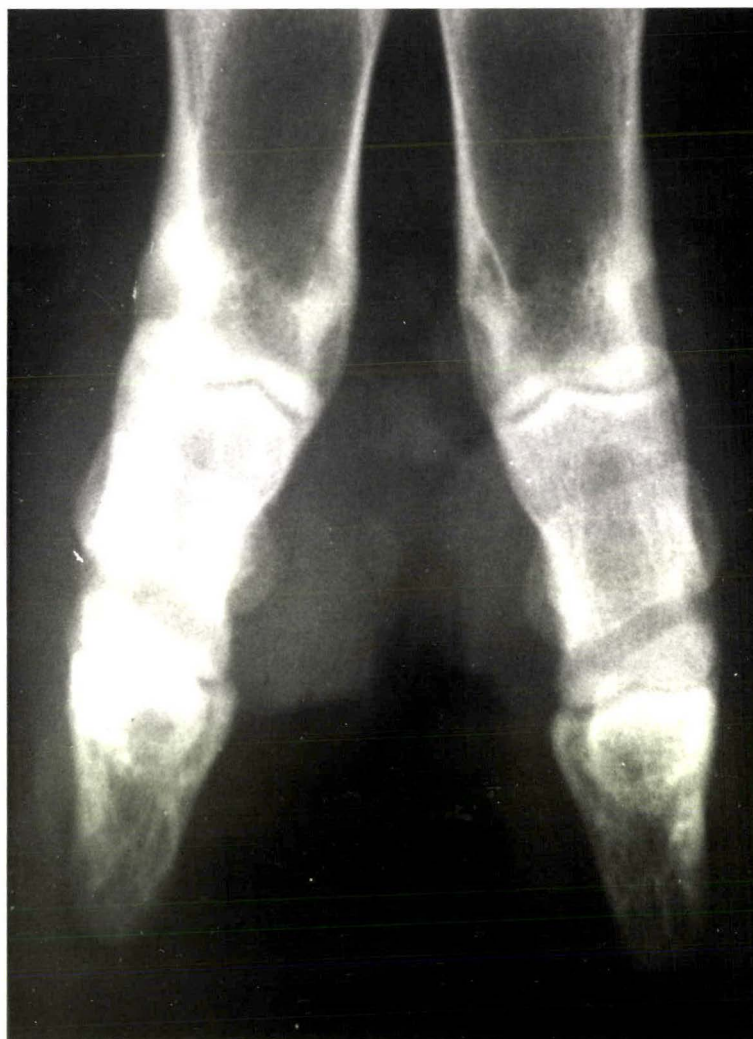

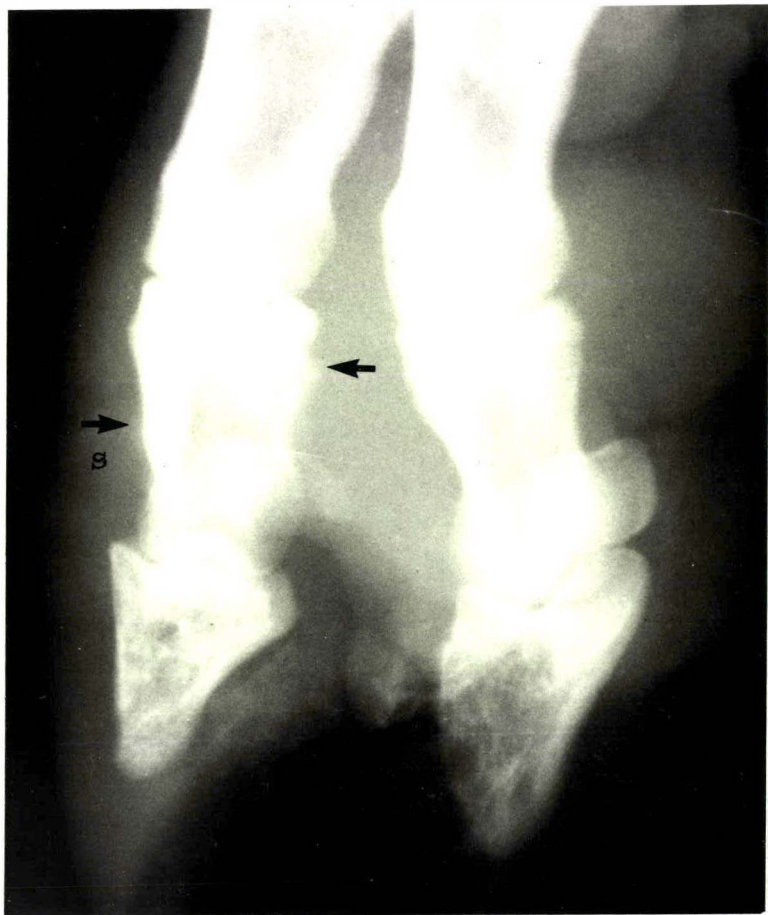
FIGURE 5.4 a, b, c and d

Radiographs of the feet of four sheep in which the infection associated with ovine interdigital dermatitis had invaded the deeper tissues of the foot.

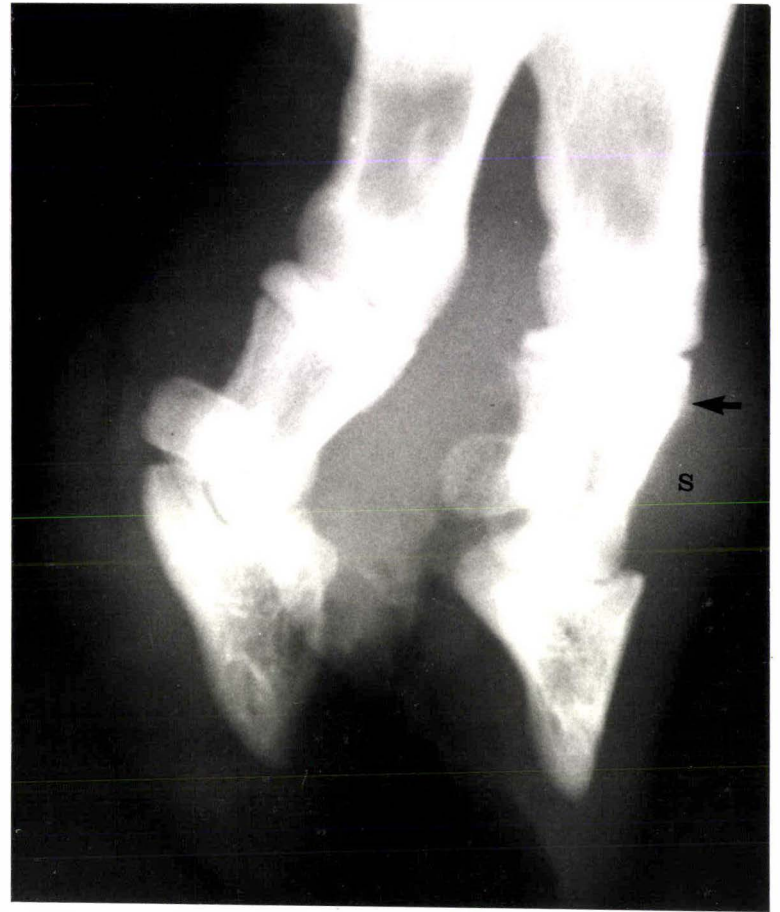
S - soft tissue swelling
arrows - proliferation of bone



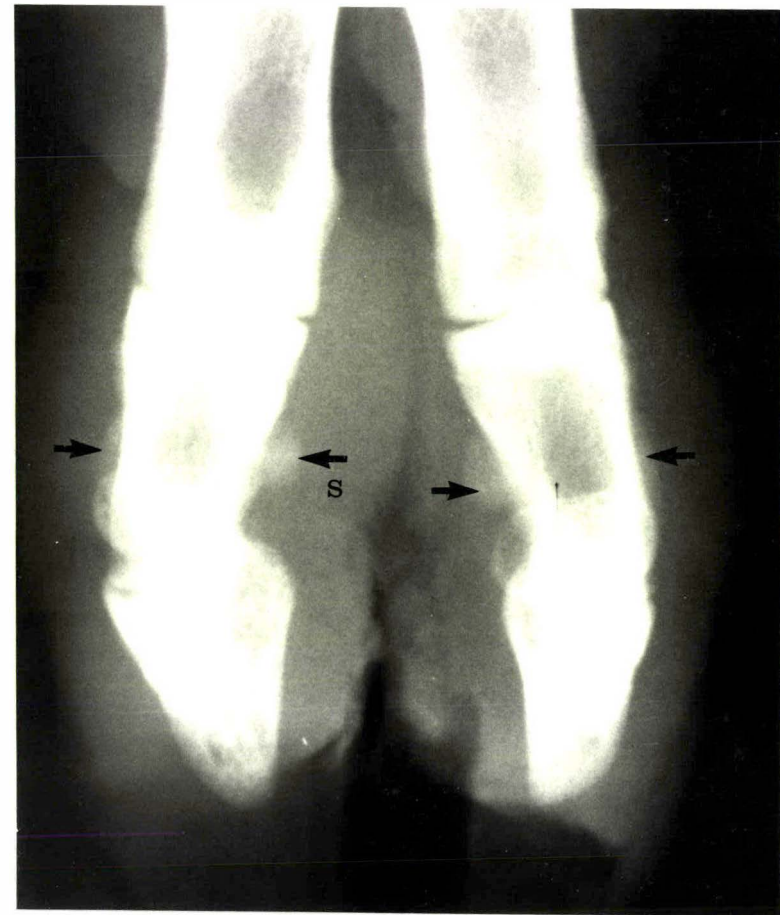
a



b



c



d

DISCUSSION

Description

The interdigital lesion observed in this outbreak of lameness was similar to the descriptions given by Murnane (1933), and Parsonson *et al.* (1967), the only difference being one of severity. Murnane (1933) described maceration, erosion and suppuration of the interdigital tissue accompanied by marked lameness, whereas Parsonson *et al.* (1967) described a milder condition of erythema, swelling and in some cases, erosion, of the interdigital skin; but lameness and suppuration were uncommon. It is evident that in the mature ewe flocks studied by Parsonson *et al.* (1967), a smaller proportion of the flock developed the more severe form of the interdigital lesion than in the outbreaks reported on by Murnane (1933): the author's observations agree with the latter.

The association of *F. necrophorum* and *C. pyogenes* organisms with the interdigital lesion is in agreement with the Australian findings (Parsonson *et al.*, 1967).

The variation in the severity of the interdigital lesion raises the question of the adequacy of the term "ovine interdigital dermatitis", first introduced by Parsonson *et al.* (1967). While this terminology adequately describes the milder condition, it does not convey an appreciation of the painful, necrotic and erosive nature of the lesion observed in some sheep. It is not intended to recommend any change in the accepted terminology at this stage but it is emphasised that the more severe form of lesion accompanied by lameness, is not uncommon in some outbreaks of ovine interdigital dermatitis in New Zealand.

Predisposing factors contributing to ovine interdigital dermatitis and foot abscess

Prior to the outbreak of ovine interdigital dermatitis, the ram hoggets and ewe hoggets had been managed similarly, except that for husbandry reasons, they were grazed separately. The difference between the sexes in the prevalence of lameness was so marked, that it is difficult to conceive that this difference could arise from minor differences between the areas grazed. It is more likely that this is a true sex difference in prevalence of ovine interdigital dermatitis, something that had already been suggested in returns from the postal survey of Romney stud sheep farmers (Chapter 2). Thirty percent of the respondents to the survey named ram hoggets as being commonly affected with foot abscess, against two percent who named ewe hoggets.

The observed difference in the behaviour of the two sex groups provides the most likely explanation for the difference in prevalence of lameness. This behaviour pattern could have the effect of: -

- a) exposing the sheep's feet to an environment heavily contaminated with *F. necrophorum* organisms arising from faeces and
- b) increasing the risk of physical damage to the interdigital skin when riding or being ridden by other sheep.

The importance of predisposing factors in the pathogenesis of the naturally occurring disease is well recognised. Under experimental conditions, interdigital skin damage sufficient to permit invasion of *F. necrophorum* organisms has been provided either by scarifying the interdigital space (Parsonson *et al.*, 1967; Egerton *et al.*, 1969) or by maceration of the interdigital skin by exposure of the sheep's feet to water (Graham and Egerton, 1968; Egerton *et al.*, 1969).

In the outbreak of lameness reported here, the important predisposing factors appeared to be the high and persistent

rainfall, combined with the sexual behaviour of the rams.

Roberts *et al.* (1968) observed that in some cases at least, foot abscess was preceded by ovine interdigital dermatitis and similar circumstances in the outbreak reported here adds further evidence that the damaged interdigital area is a common route of infection into the distal interphalangeal joint. The anatomical study reported in Chapter 3 of this thesis has demonstrated the proximity of the capsule of the distal interphalangeal joint to the interdigital skin, particularly at the sites of the dorsal and volar pouches of the joint capsule (Fig. 3.1). It is understandable then, that once the necrotic interdigital skin becomes eroded, the distal interphalangeal joint is vulnerable to infection.

Differentiation between ovine interdigital dermatitis and foot abscess

Little difficulty is normally experienced in differentiating between ovine interdigital dermatitis and foot abscess. Ovine interdigital dermatitis is restricted to the interdigital skin and subcutis, whereas in foot abscess the affected digit is painful and swollen, especially in that area above the coronet on the abaxial aspect through which the infection usually discharges (Chapter 4). However, problems of differentiation can occur at the intermediate or transitional stage between these two conditions, when infection can be seen to have invaded the subcutis and there is some swelling about the digit.

Radiology was found to be useful to assess the extent of the tissue invasion but even with this aid, equivocal cases occurred in four sheep. In these, periostitis of the middle phalanx indicated that infection had reached either the distal interphalangeal joint, or the soft tissue adjacent to the middle phalanx, but had not resulted in the typical joint changes of foot abscess (Chapter 4). The arrest of the infective process at this stage may have been due in part to the treatment regime instituted.

Therapy

Because of the potential value of the ram hoggets involved in this outbreak of lameness, the best treatment possible had to be considered for every case. It was therefore impossible to conduct any controlled treatment trials and no positive statement could be made on the relative values of the different procedures adopted.

The aim of the therapeutic measures adopted was to arrest the interdigital lesion before infection reached the deeper tissues, because permanent damage results once infection becomes established in the distal interphalangeal joint (Chapter 4). Both Murnane (1933) and Parsonson *et al.* (1967) reported that ovine interdigital dermatitis responded readily to treatment and often resolved spontaneously if affected sheep were moved to dry surroundings. It was felt that the best means of achieving a dry environment in this outbreak was to house the lame rams indoors on wooden gratings and this was considered to be an important part of the therapy.

Footbathing in five percent formalin solution has been used extensively as an aid in the control of ovine footrot (Beveridge, 1941; Egerton and Graham, 1969) and because of the relatively superficial nature of ovine interdigital dermatitis, it was considered that formalin footbathing might limit the infection. Excessive formalin footbathing has been shown to increase interdigital tissue damage (Littlejohn, 1972; Hooper and Jones, 1972), but in those instances referred to the concentration of formalin was 10 percent or greater and the sheep were footbathed as frequently as every second day for five weeks. A single session of formalin footbathing would not prevent reinfection of the interdigital lesions with *F. necrophorum* from the environment, it being an ubiquitous organism; and so the benefits may not be as long term as they are for treating ovine foot rot, a condition in which the essential transmitting agent *B. nodosus* lasts only a short time in the environment (Beveridge, 1941).

In 12 out of the 100 lame ram hoggets, the interdigital infection was not restricted to the epidermis but was seen to be involving the deeper tissues and in these cases it was considered prudent to administer antibiotics systemically. Penicillin and streptomycin mixtures have been used as an aid in the treatment of ovine foot rot (Egerton, Parsonson and Graham, 1968), and for this purpose these workers found a mixture of the two antibiotics was more effective than either drug alone. The maximum percentage of cures was achieved at high dose rates; 70mg/kg of each agent being given as a single injection. Both of the bacteria considered to be the main pathogens in ovine interdigital dermatitis and foot abscess, (*F. necrophorum* and *C. pyogenes*) show *in vitro* sensitivity to penicillin (Buxton and Fraser, 1977; Simon, 1977). In the outbreak of lameness reported here, a lower dose rate of approximately 40mg/kg of both penicillin and streptomycin was given on a daily basis for periods of up to four days depending on the response. The subjective impression was that antibiotic therapy accelerated resolution of the infection.

As judged by clinical observation the sheep responded well to the combined therapeutic measures of dry surroundings, formalin footbathing and selected antibiotic therapy. Nine out of the 100 lame rams developed foot abscess, (two of these nine had already developed foot abscess before therapy was initiated). Because of the large between-year differences in prevalence of foot abscess, it is not possible to critically evaluate the value of the therapeutic measures adopted, nevertheless the outcome compares favourably with previous years in which up to 50 rams from this flock had developed foot abscess.

SUMMARY

1. Ovine interdigital dermatitis was observed to vary in severity from erythema and swelling of the interdigital skin, to erosion and even suppuration of the interdigital tissues; the more severe form being accompanied by marked lameness.
2. Ovine interdigital dermatitis and foot abscess occurred simultaneously in the one flock and ovine interdigital dermatitis was observed to precede the occurrence of foot abscess in seven instances.
3. It was suggested that the behaviour pattern and sexual activity of young rams may predispose them to ovine interdigital dermatitis and thus to foot abscess.
4. Although no controlled trials were conducted, the lame sheep appeared to respond well to the combined therapeutic measures of dry surroundings, formalin footbathing and selected antibiotic therapy.

CHAPTER 6

THE EXPERIMENTAL REPRODUCTION OF FOOT ABSCESS BY THE INOCULATION OF BACTERIAL CULTURES INTO THE DISTAL INTERPHALANGEAL JOINT OF SHEEP

INTRODUCTION

MATERIALS AND METHODS

Sheep
Bacterial cultures
Procedure
Assessment

RESULTS

- (a) Sheep inoculated with *Fusobacterium necrophorum* organisms.
- (b) Sheep inoculated with *Corynebacterium pyogenes* organisms.
- (c) Sheep inoculated with a mixture of *Fusobacterium necrophorum* and *Corynebacterium pyogenes* organisms.

DISCUSSION

SUMMARY AND CONCLUSIONS

INTRODUCTION

From observations of clinical cases of foot abscess (Chapter 4) and a study of the anatomy of the digits (Chapter 3), it was concluded that foot abscess was an infection of the distal interphalangeal joint. Therefore it seemed likely that the inoculation of the causative organisms directly into the distal interphalangeal joint should reproduce foot abscess.

There is much circumstantial evidence that the aetiologically important organisms in ovine foot abscess are *F. necrophorum* and *C. pyogenes*. This evidence is based on the frequent isolation of both organisms from foot abscess (Roberts *et al.*, 1968; Chapter 4), the known correlated action between the two organisms (Roberts, 1967 a and b) and the distribution of morphologically similar organisms in stained sections of lesions of foot abscess (Roberts *et al.*, 1968). The same authors inoculated a mixture of cultures of those two organisms into the digital cushion and produced lesions similar to naturally occurring cases of foot abscess.

It was decided to investigate the effects of inoculation into the distal interphalangeal joint of a culture of either *F. necrophorum* or *C. pyogenes*, and a mixture of the two organisms. It was anticipated that if foot abscess could be reproduced by this means, then this would support the belief: -

- a) that foot abscess is an infection of the distal interphalangeal joint, and
- b) that *F. necrophorum* and *C. pyogenes* are the causative bacteria concerned.

Roberts *et al.* (1968) considered that *F. necrophorum* was the chief initial pathogen in foot abscess and in stained sections taken from foot abscess lesions, filamentous gram-negative organisms were commonly seen at the forefront of the tissue invasion, whereas *C. pyogenes* was considered to proliferate in the necrotic tissue resulting from the

F. necrophorum invasion. *Fusobacterium necrophorum* was considered to play a similar role in other foot infections: namely ovine foot rot (Egerton *et al.*, 1969), bovine foot rot (Berg and Loan, 1975) and ovine interdigital dermatitis (Parsonson *et al.*, 1967). Because *F. necrophorum* was seen to be the dominant organism in terms of tissue invasion, it was decided to keep the number of *C. pyogens* organisms constant in any mixture of the two species, and to vary the number of *F. necrophorum* organisms.

This investigation was undertaken in two parts. Initially a pilot trial was conducted using similar inoculations to those used by Roberts *et al.* (1968) to determine if foot abscess could be reproduced by distal interphalangeal joint inoculation. Once this was established, the definitive trial was undertaken. The results from these two trials are presented together.

MATERIALS AND METHODS

Sheep

As they were required, Romney and Romney-crossbred flock ewes were identified with ear tags and housed indoors.

Bacterial cultures

Freeze dried cultures of *F. necrophorum* and *C. pyogenes*, both isolated initially from naturally occurring cases of foot abscess, were reconstituted and grown on five percent sheep blood agar plates, anaerobically and aerobically respectively. After 48 hours incubation they were separately suspended in sterile saline. The concentration of each organism was estimated using a viable count method, whereby serial dilutions of organisms were subcultured on blood agar in triplicate and colonies counted after 48 hours.

Procedure

Following overnight fasting the sheep were anaesthetised with pentobarbitone, the feet scrubbed and the wool clipped from the coronet to the fetlock. Using an aseptic technique, a 25 gauge, 2.5cm needle was inserted into the dorsal pouch of the distal interphalangeal joint of the digit. Joint fluid was withdrawn to confirm the needle position. The bacterial cultures which had been freshly harvested, were inoculated in volumes of 0.2ml according to the schedules shown in the tables (6.I, 6.II, and 6.III) appearing under the appropriate section of Results.

In the pilot trial only one inoculation was made in each of six sheep. There are of course eight distal interphalangeal joints in any one sheep, but to avoid confusion about which digit might be responsible for any lameness, it was decided to inoculate one digit only, of each foot of the 18 sheep in

the definitive trial. Only three sheep could be handled in any one experiment due to the time involved in anaesthesia, inoculation, radiology and assessment, so the project was performed over a two year period. Thus in each series of experiments there were 12 injections (four joints x three sheep), incorporating three concentrations of the same bacteria and a normal saline control. Within each sheep, treatments were assigned randomly using a table of random numbers.

Assessment

After recovery from the anaesthetic, the sheep were examined daily for signs of swelling, lameness or discharge.

Where appropriate, the feet were photographed and radiographed according to the methods described in Chapter 4.

In instances where pus had accumulated beneath the skin, the most prominent point was cleaned and disinfected, and following lancing of the abscess a swab was taken of the contained pus. A smear of this was examined microscopically following staining by Gram's method and the material was cultured both aerobically and anaerobically on five percent sheep blood agar.

The response of the sheep to joint inoculation was classified into one of four arbitrary categories. These were designated: -

- TYPE I - no reaction
- TYPE II - The inoculated digit was painful and inflamed, but the reaction regressed within four days of inoculation
- TYPE III - The inoculated digit became swollen and painful, and purulent material discharged from the site of injection.

This resolved within four weeks and clinical and radiographic signs of foot abscess did not develop.

TYPE IV - The inoculated digit developed clinical and radiographic signs indistinguishable from foot abscess.

RESULTS

(a) Sheep inoculated with *Fusobacterium necrophorum* organisms.

The response of the sheep to the inoculation of *F. necrophorum* organisms into the distal interphalangeal joint is summarised in table (6.I).

Unfortunately, except for the two sheep in the pilot trial (P₃ and P₄) there were no inoculations between the estimated doses of 8×10^3 , and 10^{10} organisms. This occurred because the number of organisms could not be assessed until 48 hours after joint inoculation had taken place.

The two sheep P₃ and P₄ that had been inoculated with 10^8 *F. necrophorum* organisms, only developed minor changes in the inoculated digit. Pain and swelling were transient and the condition had regressed by the third day after injection. Radiological changes were restricted to the transient swelling of the soft tissues about the injection site and joint changes typical of foot abscess (Chapter 4) did not develop.

The inoculation of the much greater number of 10^{10} organisms produced a marked reaction that is described in more detail below.

TABLE 6.I

THE REACTION TO THE INOCULATION OF *Fusobacterium necrophorum* ORGANISMS INTO THE DISTAL INTERPHALANGEAL JOINT OF SHEEP.

Sheep No.	Digit	*No. of Organisms	Reaction			
			TYPE I	TYPE II	TYPE III	Type IV
1	RFL	8×10^1	1			
2	LFL	8×10^1	1			
3	LHL	8×10^1	1			
1	LHL	8×10^2	1			
2	LHL	8×10^2	1			
3	RHL	8×10^2	1			
4	LHM	8×10^2	1			
5	LHM	8×10^2	1			
6	RHM	8×10^2	1			
4	RFM	6×10^3	1			
5	LFM	6×10^3	1			
6	LHM	6×10^3	1			
1	RHL	8×10^3	1			
2	RHL	8×10^3	1			
3	LFL	8×10^3	1			
P3	LHM	10^8		1		
P4	LHM	10^8		1		
4	RHM	10^{10}				1
5	RHM	10^{10}				1
6	LFM	10^{10}				1
1	LFL	sterile saline	1			
2	RFL	" "	1			
3	RFL	" "	1			
4	LFM	" "	1			
5	RFM	" "	1			
6	RFM	" "	1			

* Contained in 0.2ml inoculum

Key LFL left fore lateral digit LHL left hind lateral digit
 LFM left fore medial digit LHM left hind medial digit
 RFL right fore lateral digit RHL right hind lateral "
 RFM right fore medial digit RHM right hind medial digit
 P = pilot

Sheep inoculated with 10^{10} *F. necrophorum* organisms

Observations

The injected digits of the three sheep inoculated with 10^{10} *F. necrophorum* organisms all developed similar changes. The digits were swollen and painful 24 hours after injection and the sheep carried the affected foot. The swelling became progressively greater, particularly above the coronet on the abaxial aspect (Fig. 6.1a and b), until by day 10, when at the point of bursting, the abscess was lanced to allow for bacteriological examination of the contents. Pus also discharged a few days later from the swollen interdigital space. The purulent material continued discharging from these sites for four to five weeks (Fig. 6.1c and d), during which time the swelling partly subsided and the sheep started putting some weight on the foot. All three sheep were still lame 40 days after inoculation and the injected digit was deformed, particularly that of sheep number 5 in which the distal phalanx was noticeably displaced abaxially (Fig. 6.2).

Radiology

The radiographic changes of all three inoculated digits were initially restricted to soft tissue swelling, but by day seven there was widening of the joint space of the distal interphalangeal joint and loss of density of the subchondral bone (Fig. 6.3a). These changes were more obvious by day 10 (Fig. 6.3b) and in addition there was proliferation of bone adjacent to the periosteum about the middle phalanx. The distal end of the middle phalanx and the proximal end of the distal phalanx became progressively eroded (Fig. 6.3b, c, and d), and the proliferation of bone eventually covered much of the surface of the middle phalanx (Fig. 6.3d). New bone also proliferated about the proximal phalanx of the injected digit (Fig. 6.3c and d).

In sheep number 5 the distal phalanx was displaced abaxially by day 14 (Fig. 6.2) and it was likely that the axial collateral ligaments and the interdigital ligaments had ruptured in this case.

By day 40 (Fig. 6.3d) the new bone that had proliferated about the phalanges was well defined and smooth in outline, indicating that resolution was occurring.

These radiographic changes are similar to those described for naturally occurring cases of foot abscess (Chapter 4).

Bacteriology

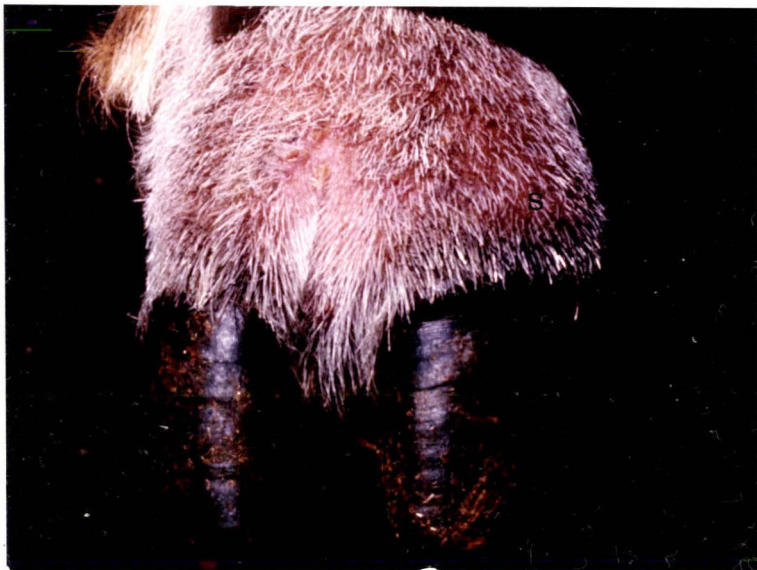Gram stained smears taken from the abscesses above the coronet, revealed the presence of numerous gram-negative filaments, and a pure culture of *F. necrophorum* was obtained from all three injected digits. A second sample taken four days after the abscess had been lanced, revealed the presence of *C. pyogenes* in addition to *F. necrophorum* in two of the three inoculated digits. It is presumed that *C. pyogenes* from the environment had infected the lesion after sinus tracts had formed.

FIGURE 6.1 a, b, c and d

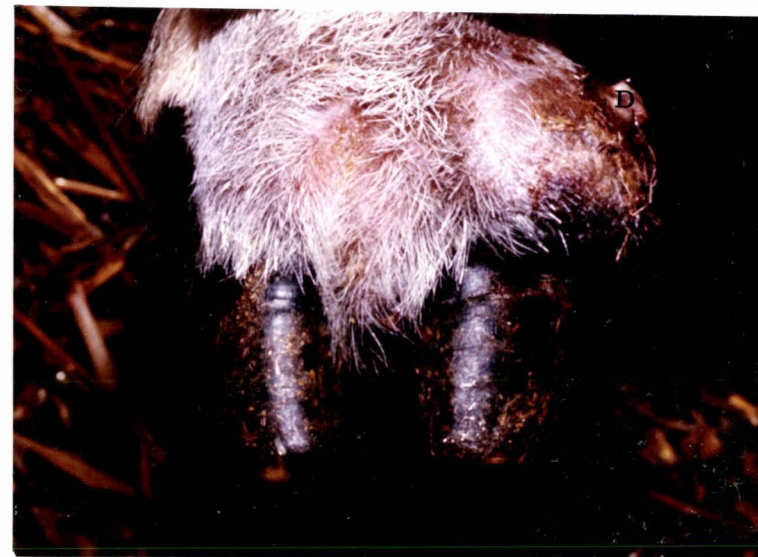The right hind foot of sheep number 4 following the inoculation of approximately 10^{10} *Fusobacterium necrophorum* organisms into the distal interphalangeal joint of the medial digit.

- (a) Day 6
S - swelling
- (b) Day 10
S - swelling
- (c) Day 14
D - purulent discharge
- (d) Day 24
D - purulent discharge. Much of the swelling had subsided and sinus tracts were present both above the coronet and interdigitally.

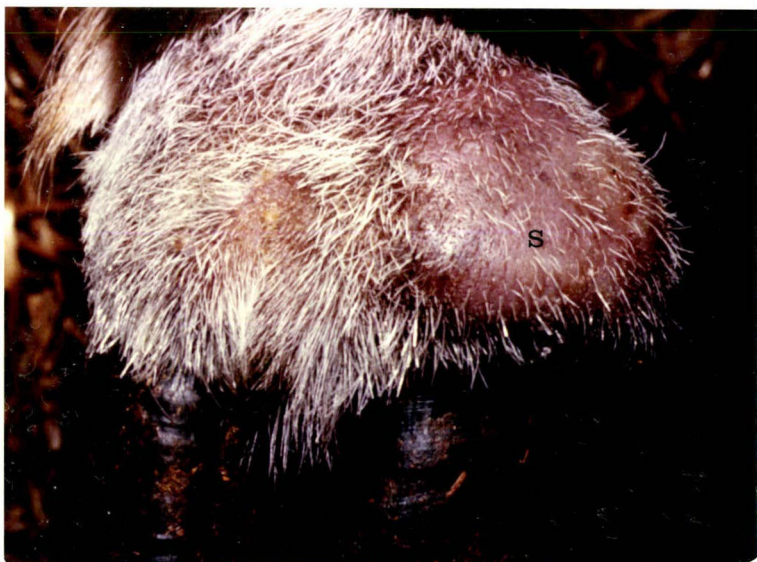a



c



b



d



FIGURE 6.2 a and b

The right hind foot of sheep number 5 a) 17 days and b) 14 days after the inoculation of approximately 10^{10} *Fusobacterium necrophorum* organisms into the distal interphalangeal joint of the medial digit.

a) A - abaxial displacement
 T - sinus tracts

b) A - abaxial displacement of the distal
 phalanx and distal sesamoid.
 E - erosion of bone
 P - proliferation of bone
 S - soft tissue swelling

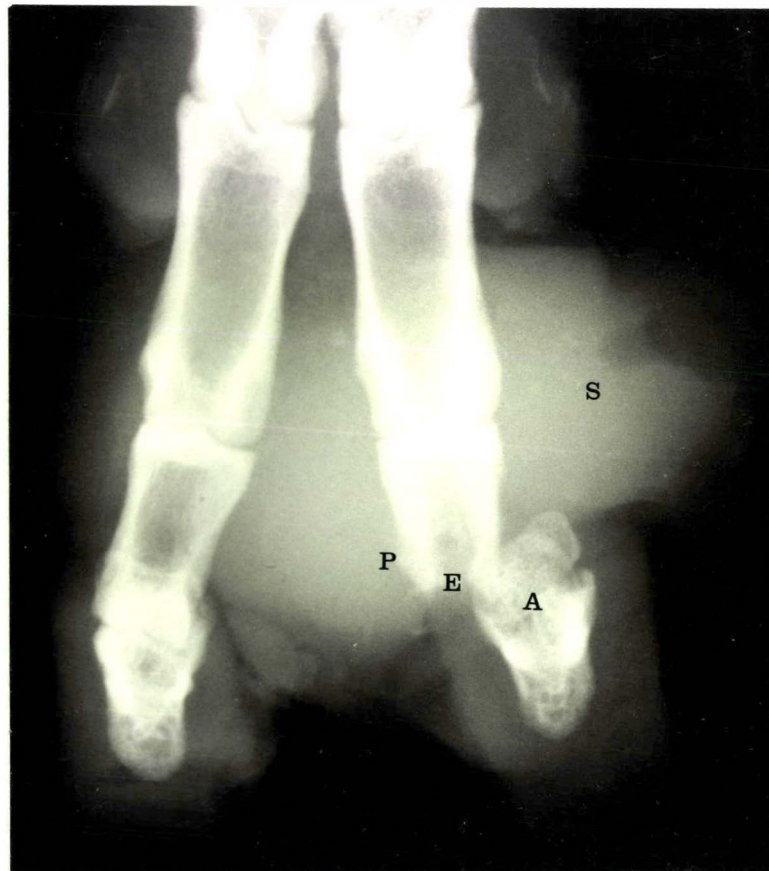
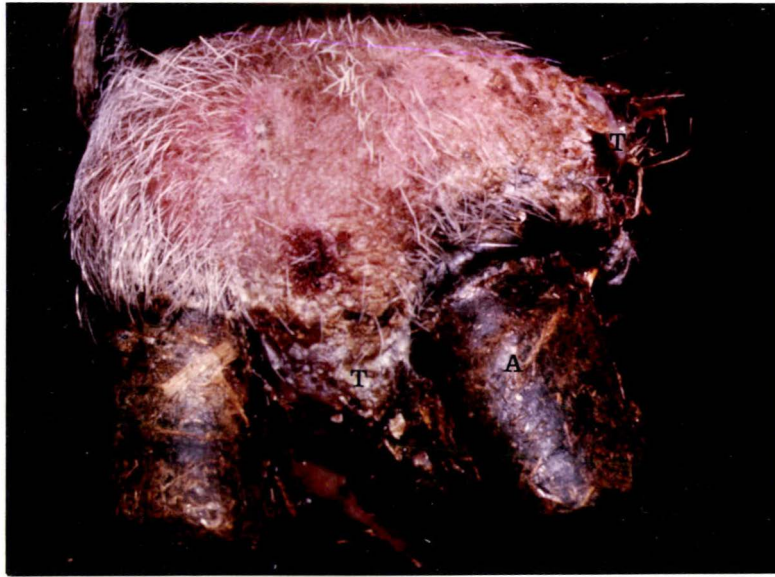

FIGURE 6.3 a, b, c and d

Radiographs of the right hind foot of sheep number 4 following the inoculation of approximately 10^{10} *Fusobacterium necrophorum* organisms into the distal interphalangeal joint of the medial digit.

(a) Day 7

- S - soft tissue swelling
- W - widening of the joint space

(b) Day 10

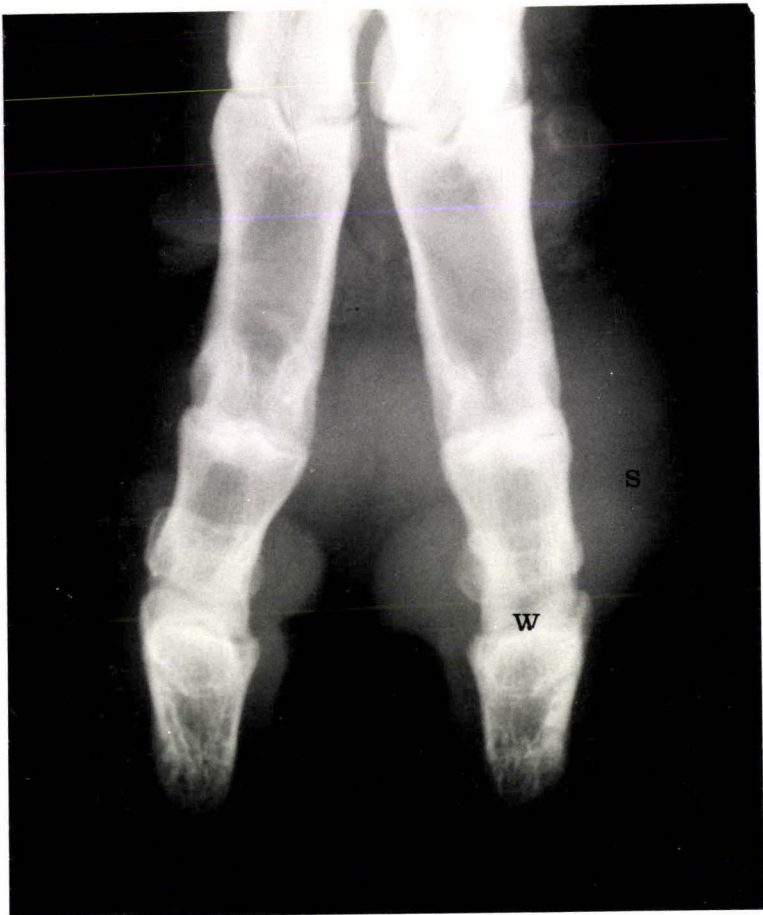- S - soft tissue swelling
- E - erosion of bone
- P - proliferation of bone

(c) Day 14

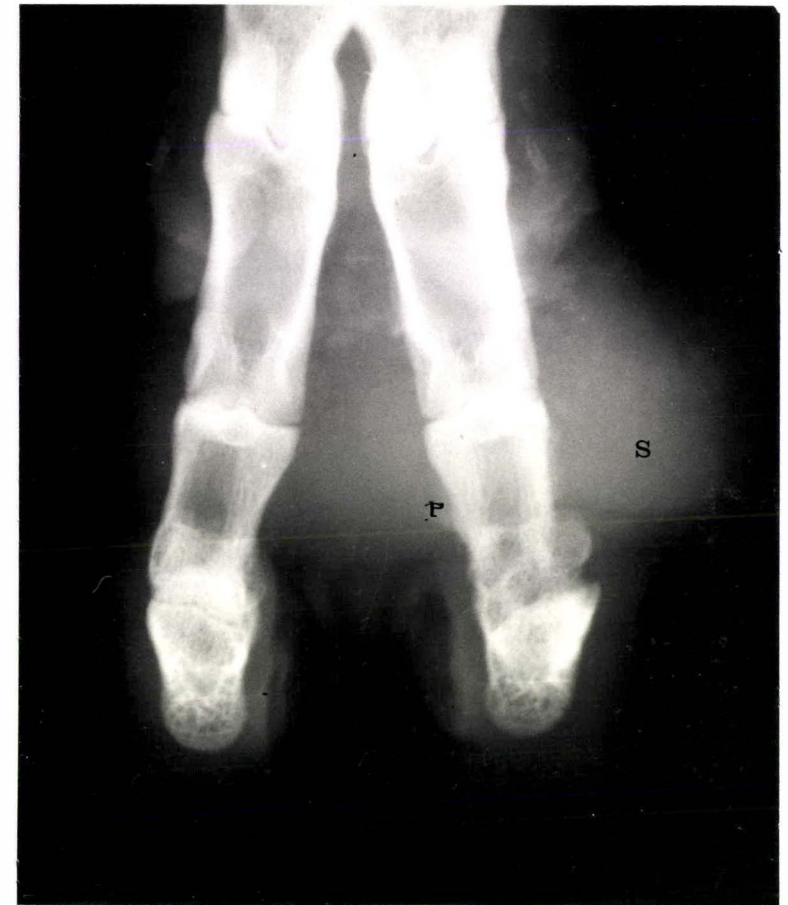- S - soft tissue swelling
- P - proliferation of bone

(d) Day 40

- P - proliferation of bone. Much of the soft tissue swelling had subsided and the outline of the new bone that had formed about the phalanges was smooth. The distal third of the middle phalanx was eroded.

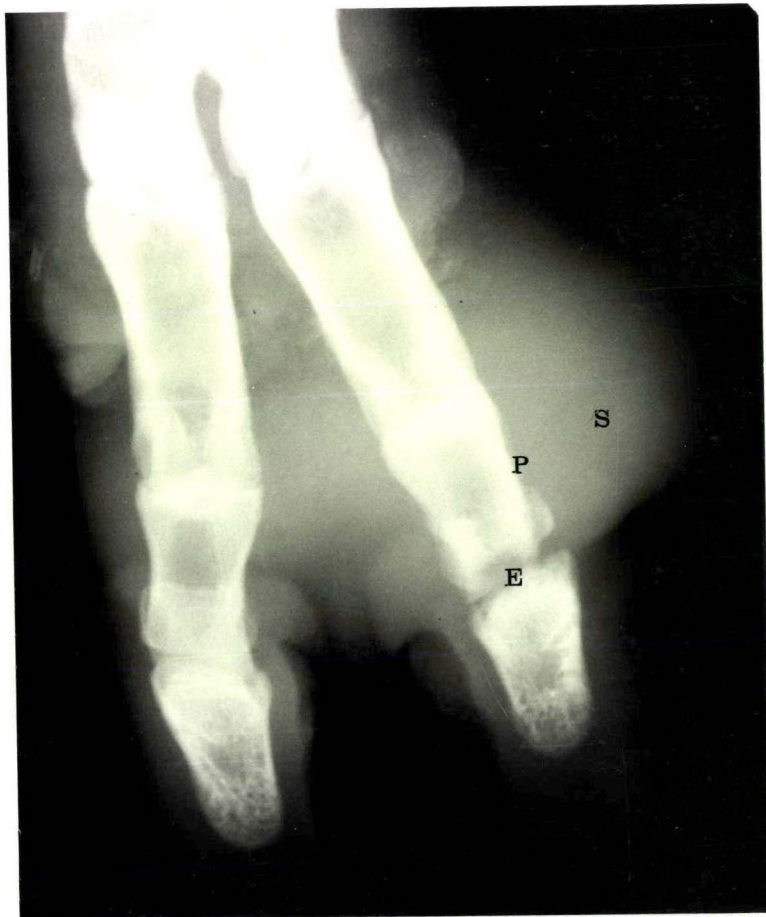

a

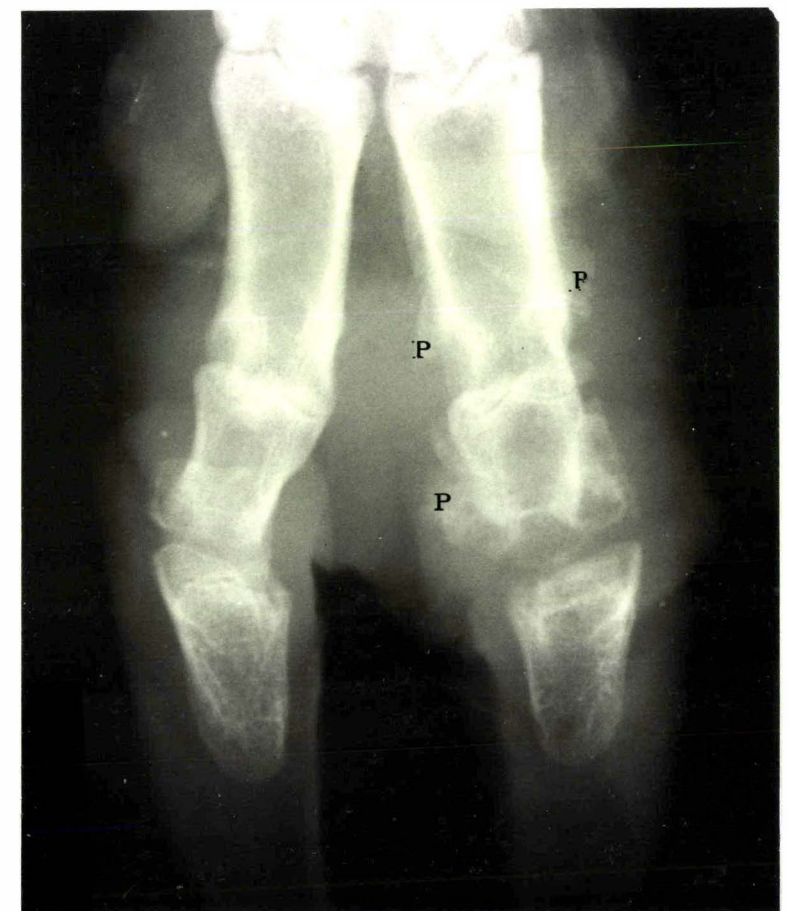

c

1



b



d

(b) Sheep inoculated with *Corynebacterium pyogenes* organisms

The response of the sheep to inoculation of various numbers of *C. pyogenes* organisms is summarised in table (6.II). The sheep did not react to inoculation of up to 2×10^5 *C. pyogenes* organisms, but inoculation of 4×10^7 or greater did produce a reaction that appeared to vary according to the dose.

Sheep inoculated with either 4×10^7 or 6×10^8 *Corynebacterium pyogenes* organisms

Observations

Three sheep, numbers 7, 8 and 9 were inoculated with 4×10^7 *C. pyogenes* organisms and two sheep, P1 and P2 were inoculated with 6×10^8 *C. pyogenes* organisms. No reaction to the inoculum occurred in sheep number 8 but the other four sheep reacted similarly. The day after inoculation the sheep were lame and the injected digit was slightly swollen. The swelling progressively increased as purulent material accumulated beneath the skin above the coronet (Fig. 6.4). An initial discharge of pus occurred on day 7 (Sheep P1) day 10 (Sheep P2) day 19 (Sheep 7) and day 20 (Sheep 9). The lesion healed rapidly following the discharge of purulent material and by day 30 the sheep were walking normally.

Radiology

The early radiographic changes were restricted to increased radiodensity associated with the accumulation of purulent material (Fig. 6.5). By day 15 (Sheep number 7) and day 19 (Sheep number 9), proliferation of bone adjacent to the periosteum of the middle phalanx was evident (Fig. 6.6). This boney change did not progress and radiographic joint changes, typical of foot abscess (Chapter 4) did not develop.

Bacteriology

Microscopic examination of smears of the initial purulent discharge, revealed the presence of numerous gram-positive bacilli. *Corynebacterium pyogenes* was grown in pure culture from the pus.

Sheep inoculated with 2×10^9 *Corynebacterium pyogenes* organisms

Two of the three sheep that were inoculated with 2×10^9 organisms reacted similarly. The other cases, sheep number 12, reacted in a similar manner to that just described for two of the sheep inoculated with 4×10^7 *C. pyogenes* organisms and is not described further.

Observations

The digits of sheep numbers 10 and 11 that had received 2×10^9 *C. pyogenes* organisms were swollen and painful 24 hours after injection. The swelling progressively increased (Fig. 6.7) and on day eight the abscesses above the coronet were lanced to allow for bacteriological examination of the pus. Pus also discharged from the swollen interdigital space (Fig. 6.7). Pus continued to discharge from these sites for about three weeks during which time the swelling subsided and the sheep started putting weight on the feet. Both sheep were still lame however, 45 days after inoculation, and the digit was misshapen.

Radiology

In both inoculated digits the radiographic changes were restricted to soft tissue swelling for the first five days. By day six there was widening of the distal interphalangeal joint space (Fig. 6.8a). This became more obvious by day 10 at which time there was also loss of density of the subchondral bone; (Fig. 6.8b). By day 17, proliferation of bone adjacent to the middle phalanx was evident and the distal phalanx was displaced abaxially in sheep number 10 (Fig. 6.8c). The distal end of the middle phalanx and the proximal end of the distal phalanx were progressively eroded (Fig. 6.8). By day 45, much of the soft tissue swelling had subsided and the new bone was well defined and smooth in outline, indicating that resolution was occurring. Permanent displacement and deformity were present however. These radiographic changes are similar to those described for naturally occurring cases of foot abscess (Chapter 4).

Bacteriology

Gram stained smears taken from the abscesses above the coronet revealed the presence of numerous gram-positive bacilli, and a pure growth of *C. pyogenes* was obtained from the pus.

FIGURE 6.4a and b

The left hind foot of a) sheep number P1 and b) sheep number P2, seven days after the inoculation of approximately 6×10^8 *Corynebacterium pyogenes* organisms into the distal interphalangeal joint of the medial digit.

a) S - swelling
D - discharge

b) S - swelling

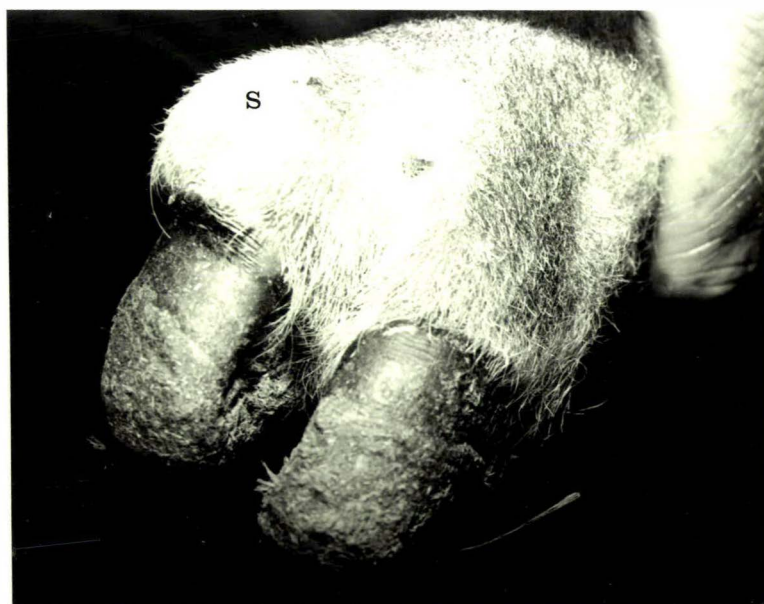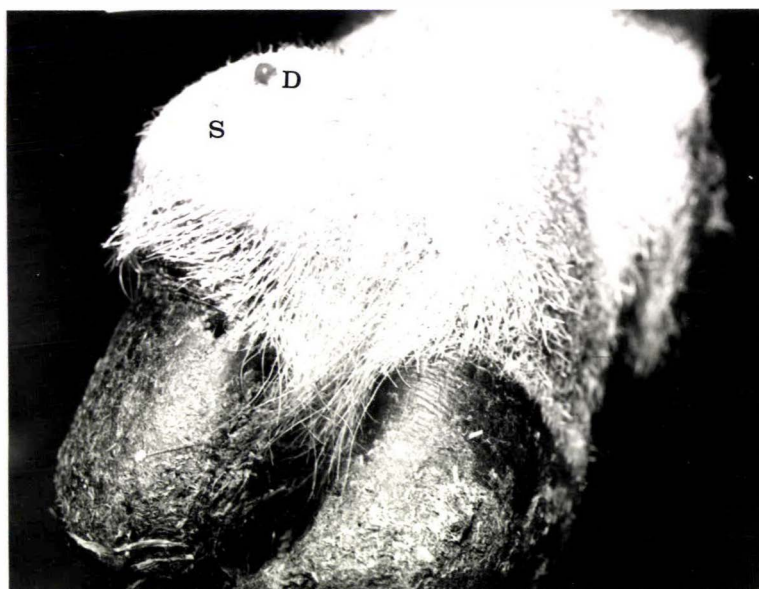


FIGURE 6.5

Radiograph of the left hind foot of sheep number P1, 9 days after the inoculation of approximately 6×10^8 *Corynebacterium pyogenes* organisms into the distal interphalangeal joint of the medial digit.

a) S - soft tissue swelling

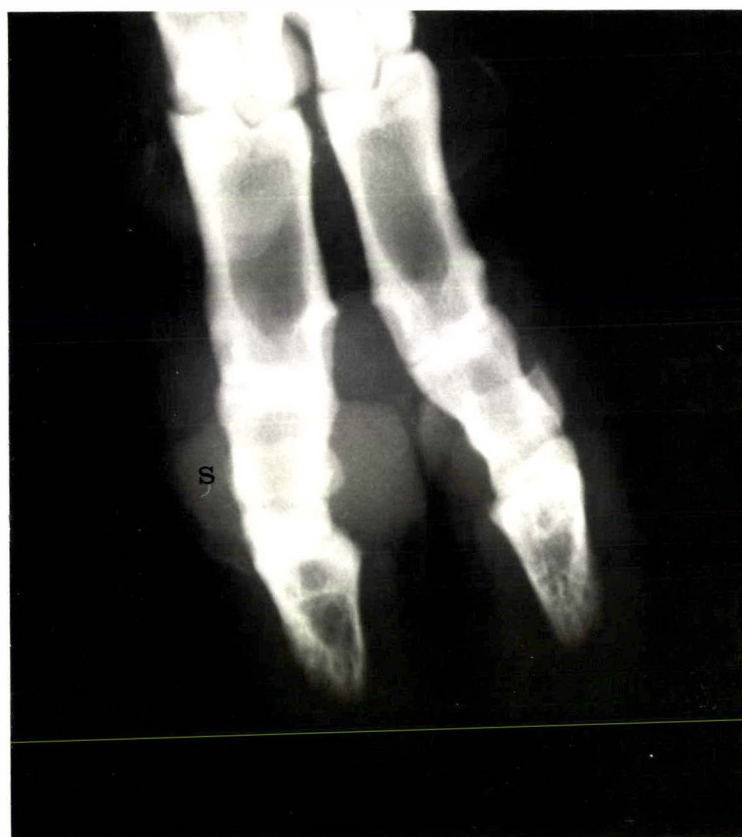

FIGURE 6.6

Radiograph of the left fore foot of sheep number 9, 19 days after the inoculation of approximately 4×10^7 *C. pyogenes* organisms into the distal interphalangeal joint of the lateral digit.

S - soft tissue swelling
P - proliferation of bone

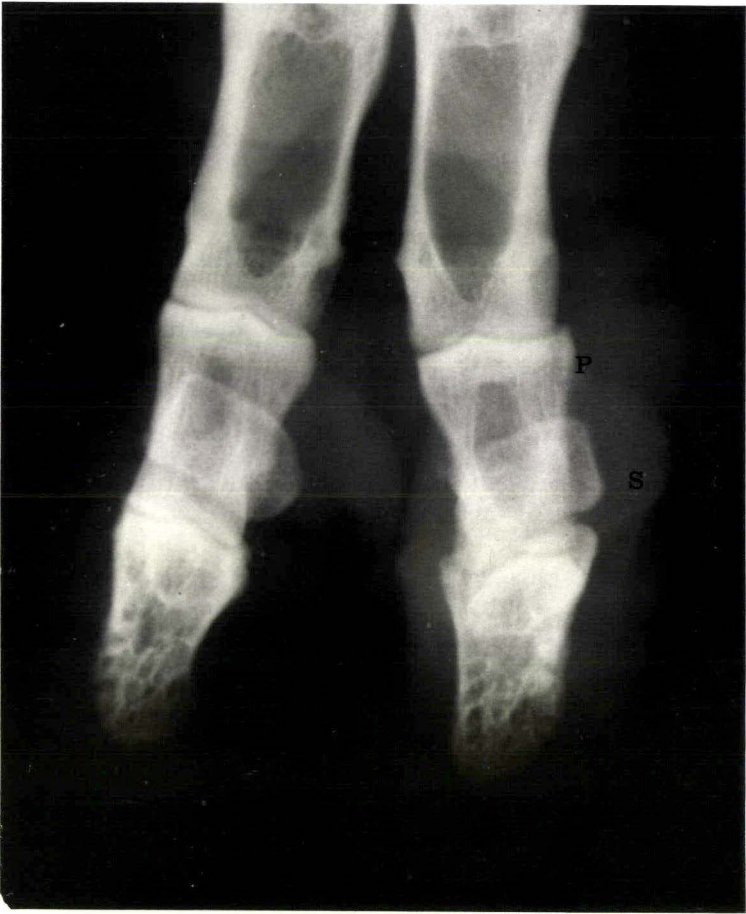

FIGURE 6.7 a, b and c

The left fore foot of sheep number 11 following the inoculation of approximately 2×10^9 *Corynebacterium pyogenes* organisms into the medial digit.

- a) Day 3
S - soft tissue swelling

- b) Day 7
S - soft tissue swelling

- c) Day 13
S - soft tissue swelling
T - sinus tracts

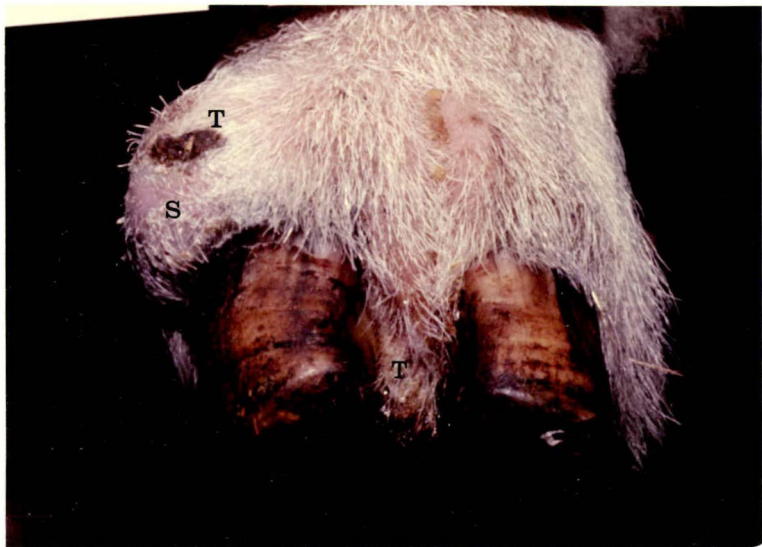
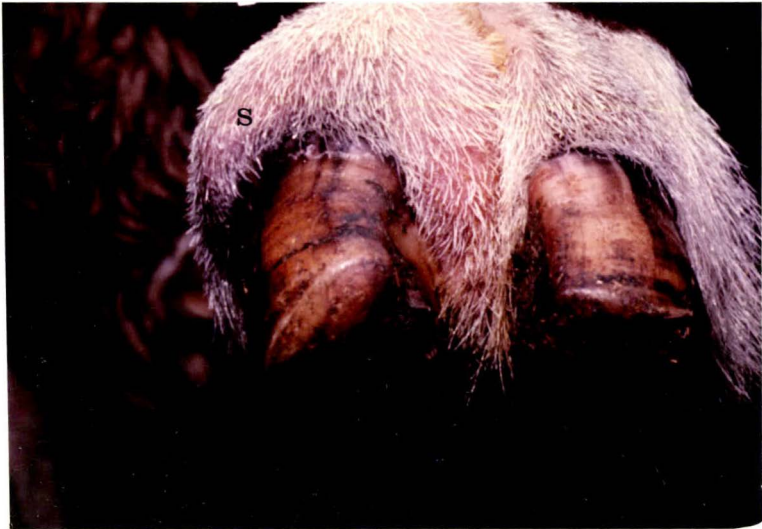
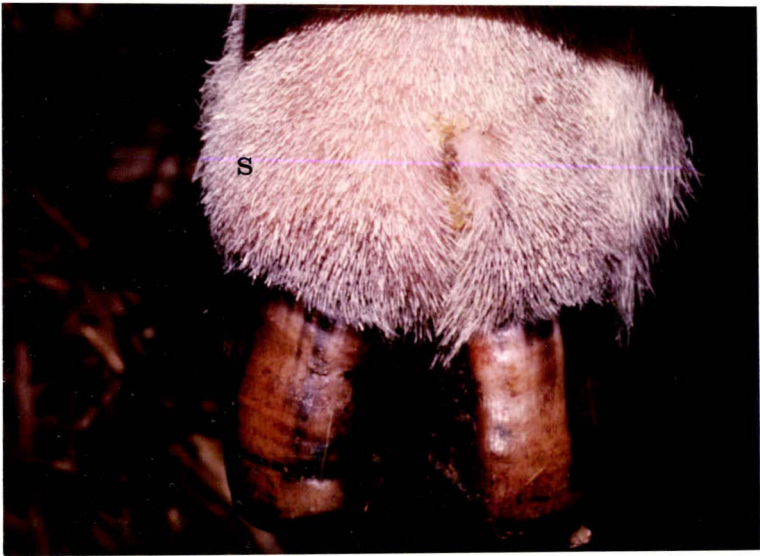FIGURE 6.8 a, b, c and d

Radiographs of the left hind foot of sheep number 10 following the inoculation of approximately 2×10^9 *Corynebacterium pyogenes* organisms into the distal interphalangeal joint of the medial digit.

(a) Day 6

S - soft tissue swelling

W - widening of the joint space

(b) Day 10

E - erosion of bone

S - soft tissue swelling

(c) Day 17

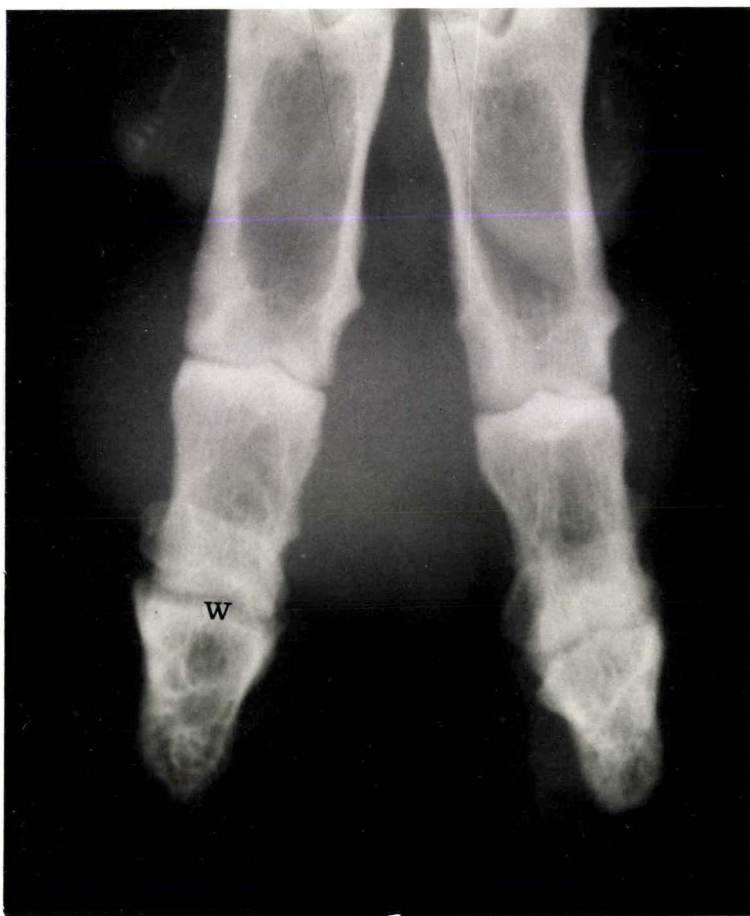A - abaxial displacement of the distal phalanx and the distal sesamoid

P - proliferation of bone

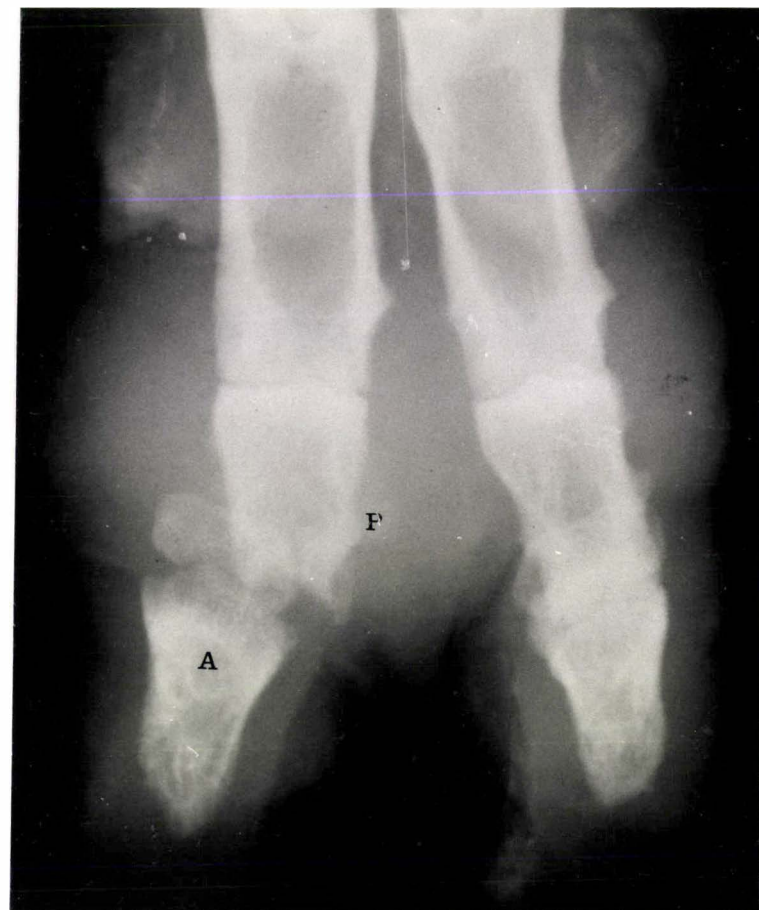(d) Day 45

Much of the soft tissue swelling had regressed and the outline of the bone that had proliferated was smooth, indicating resolution. The distal phalanx and the distal sesamoid were displaced abaxially.

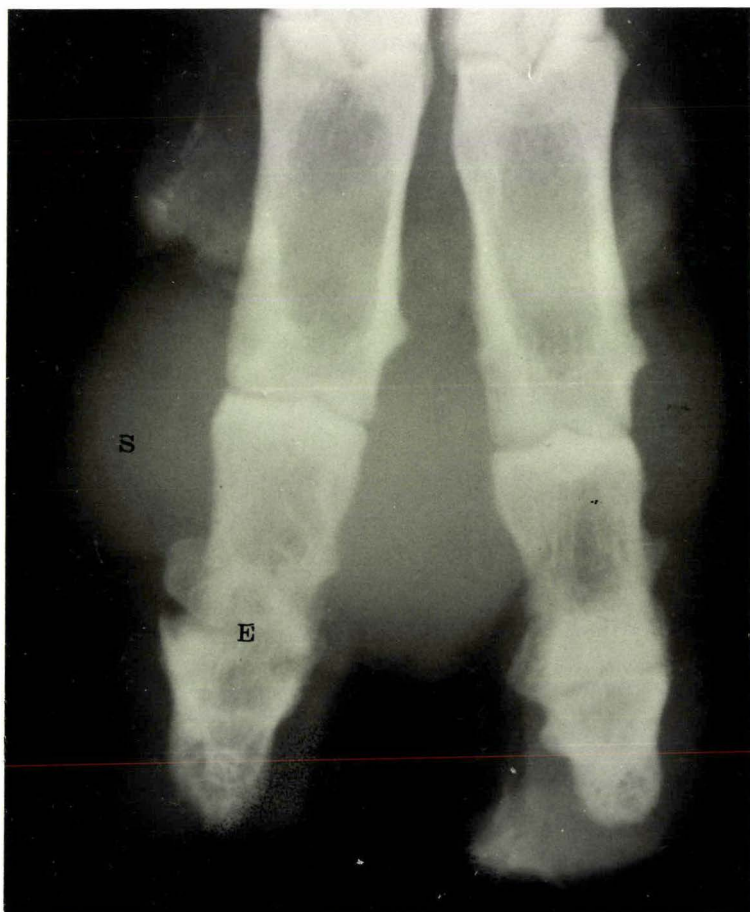
a



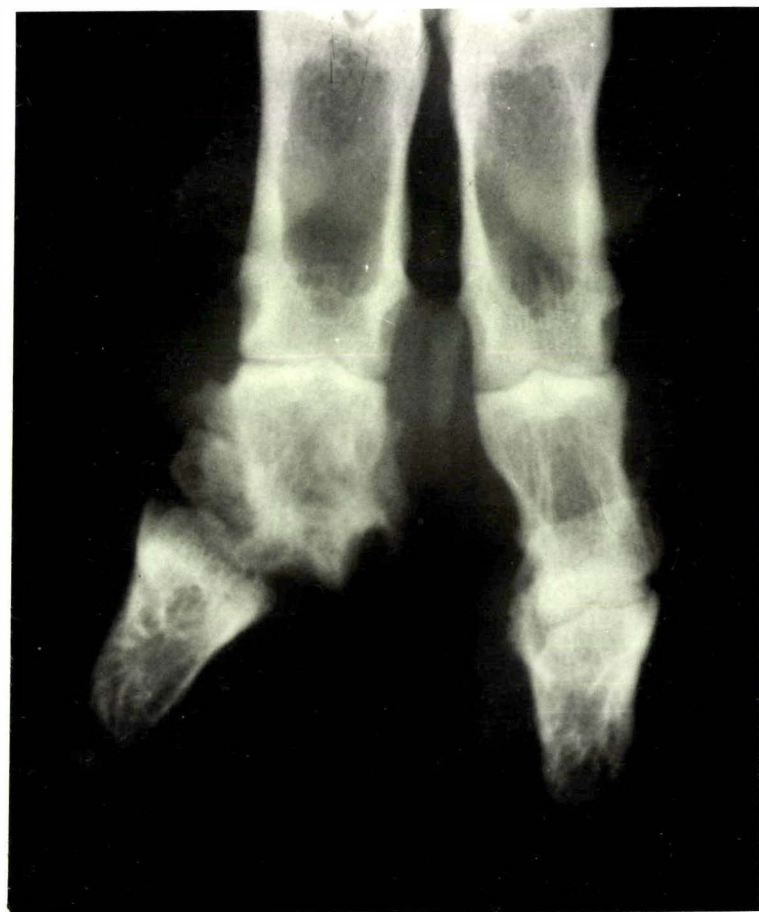c



b



d



- (c) Sheep inoculated with a mixture of *Fusobacterium necrophorum* and *Corynebacterium pyogenes* organisms.

The response of the sheep injected with a mixed inoculum of *F. necrophorum* and *C. pyogenes* is summarised in table (6.III). In the definitive trial the number of *C. pyogenes* organisms remained constant at approximately 10^4 and the number of *F. necrophorum* organisms varied. No reaction was observed until the number of *F. necrophorum* organisms injected reached approximately 6×10^6 to 10^7 . At this dose the response was only transient, lasting less than four days. However, at a 10 fold increase in the number of *F. necrophorum* organisms injected (i.e. 5×10^7 to 10^8) a marked reaction occurred, which is described in more detail below.

Observations

The seven digits which developed a type IV reaction were swollen and painful 24 hours after inoculation. Within seven days, not only the injection site, but the skin above the abaxial coronet and the interdigital space were swollen (Fig. 6.9 and Fig. 6.10). Purulent material commenced discharging from these sites between days 8 and 12, and continued to discharge for the next four weeks. During this time some of the swelling subsided and the sheep started putting weight on the foot. However, all seven sheep were still lame 56 days after the inoculation, and the digit appeared thickened and misshapen.

These changes are indistinguishable from those of naturally occurring foot abscess (Chapter 4).

Radiology

For the first five days after inoculation the radiographic changes were restricted to an increase in the density of the soft tissues around the distal interphalangeal joint, but by day seven the joint space was widened and the subchondral bone at the distal end of the middle phalanx lacked definition

TABLE 6.III

THE REACTION TO THE INOCULATION OF A MIXTURE OF *Fusobacterium necrophorum* AND *Corynebacterium pyogenes* ORGANISMS INTO THE DISTAL INTERPHALANGEAL JOINT OF SHEEP

Sheep No.	Digit	*Number of organisms <i>C. pyogenes</i> <i>F. necrophorum</i>		Reaction			
				TYPE I	TYPE II	TYPE III	TYPE IV
13	LHM	10^4	$+ 6 \times 10^5$	1			
14	RFM	10^4	$+ 6 \times 10^5$	1			
15	RHM	10^4	$+ 6 \times 10^5$	1			
16	RHM	10^4	$+ 1 \times 10^6$	1			
17	RFM	10^4	$+ 1 \times 10^6$	1			
18	LHM	10^4	$+ 1 \times 10^6$	1			
13	RHM	10^4	$+ 6 \times 10^6$		1		
14	LHM	10^4	$+ 6 \times 10^6$		1		
15	LFM	10^4	$+ 6 \times 10^6$		1		
16	LHM	10^4	$+ 1 \times 10^7$		1		
17	LHM	10^4	$+ 1 \times 10^7$		1		
18	LFM	10^4	$+ 1 \times 10^7$		1		
13	RFM	10^4	$+ 6 \times 10^7$				1
14	LFM	10^4	$+ 6 \times 10^7$				1
15	LHM	10^4	$+ 6 \times 10^7$				1
P5	LHL	3×10^8	$+ 5 \times 10^7$				1
P6	LHM	3×10^8	$+ 5 \times 10^7$				1
17	LFM	10^4	$+ 1 \times 10^8$		1		
16	RFM	10^4	$+ 1 \times 10^8$				1
18	RHM	10^4	$+ 1 \times 10^8$				1
13	LFM	sterile saline		1			
14	RHM	"	"	1			
15	RFM	"	"	1			
16	LFM	"	"	1			
17	RFM	"	"	1			
18	RFM	"	"	1			

* Contained in 0.2ml inoculum

Key: LFL left fore lateral digit LHL left hind lateral digit
 LFM left fore medial digit LHM left hind medial digit
 RFL right fore lateral digit RHL right hind lateral "
 RFM right fore medial digit RHM right hind medial "
 P = pilot

(Fig. 6.11 and Fig. 6.12). There was progressive erosion at the ends of the middle and distal phalanges. Gross abaxial displacement of the distal phalanx and the distal sesamoid occurred in sheep number P5 by day 12 (Fig. 6.11d), probably due to rupture of the axial collateral ligaments and the interdigital ligament (Chapter 3). Proliferation of bone adjacent to the periosteum of the middle phalanx was evident by day nine, and this progressed to eventually cover much of the surface of this phalanx (Fig. 6.11 and Fig. 6.12). Exostoses also developed about the distal end of the first phalanx of the inoculated digit.

Fifty six days after inoculation, much of the soft tissue swelling had subsided and there was better alignment between the middle and distal phalanges. The infection had reduced the middle phalanx to about half its original length and the new bone that had developed about the phalanges was smooth and well defined in outline, indicating that resolution was occurring.

These radiographic changes are indistinguishable from those of naturally occurring cases of foot abscess (Chapter 4).

Bacteriology

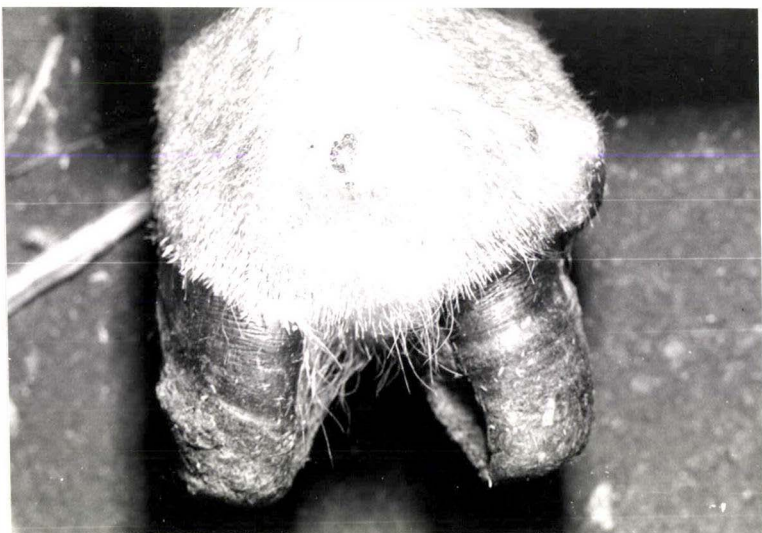Gram stained smears taken from abscesses at the coronet revealed the presence of numerous gram-negative filaments and gram-positive bacilli. *Fusobacterium necrophorum* and *C. pyogenes* only were cultured.

FIGURE 6.9 a, b, c, d, e and f

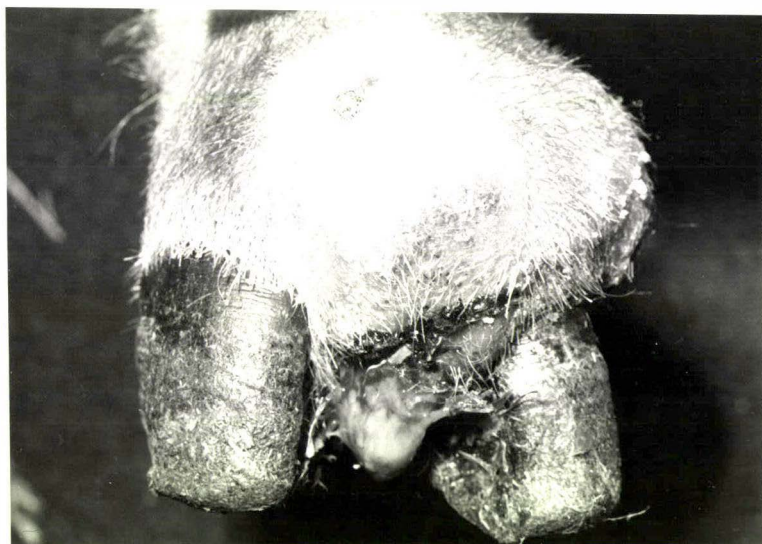Gross changes of the left hind foot of sheep number P5, following the inoculation of *Fusobacterium necrophorum* and *Corynebacterium pyogenes* organisms into the distal interphalangeal joint of the lateral digit.

- (a) Day 5 - The injected digit was swollen, particularly above the coronet on the abaxial aspect.
- (b) Day 9 - There was considerable swelling both above the coronet and in the interdigital space. Purulent material discharged from these sites.
- (c) Day 14 - Some of the swelling had subsided but purulent material was still discharging from a number of sinuses.
- (d) Day 19 - The purulent discharge had diminished and much of the swelling had subsided.
- (e & f) Day 56 - The inoculated digit was left slightly thickened and deviated abaxially. There was a small growth of tissue into the interdigital space at one of the points of previous discharge.

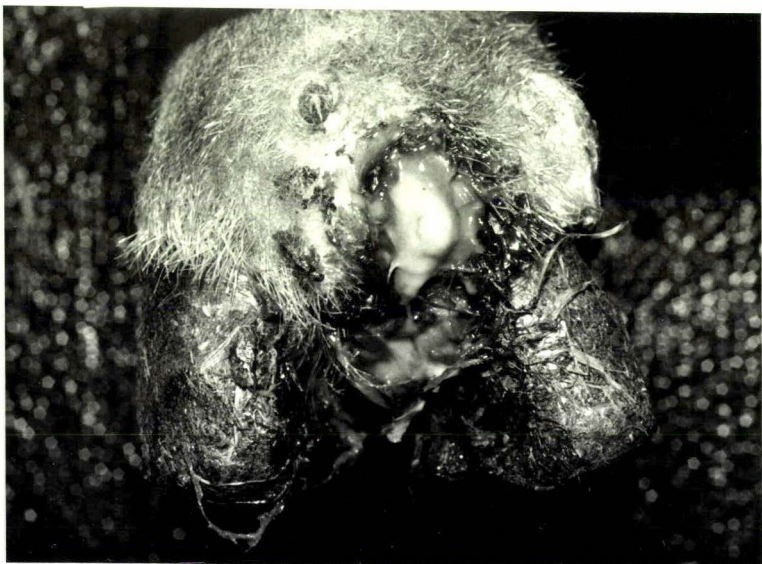a



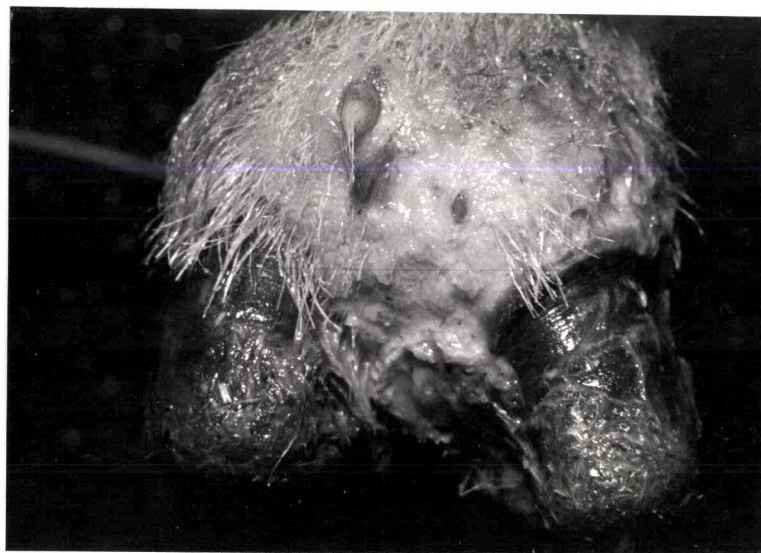b



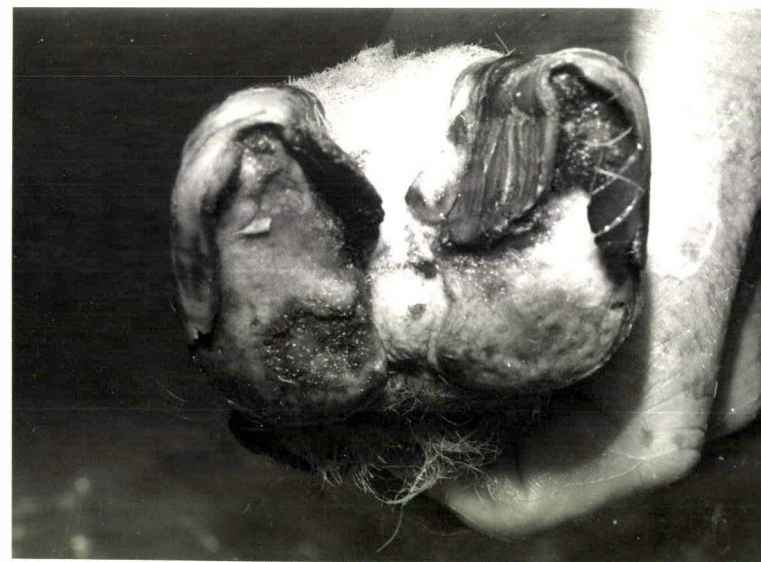
c



d



e



f

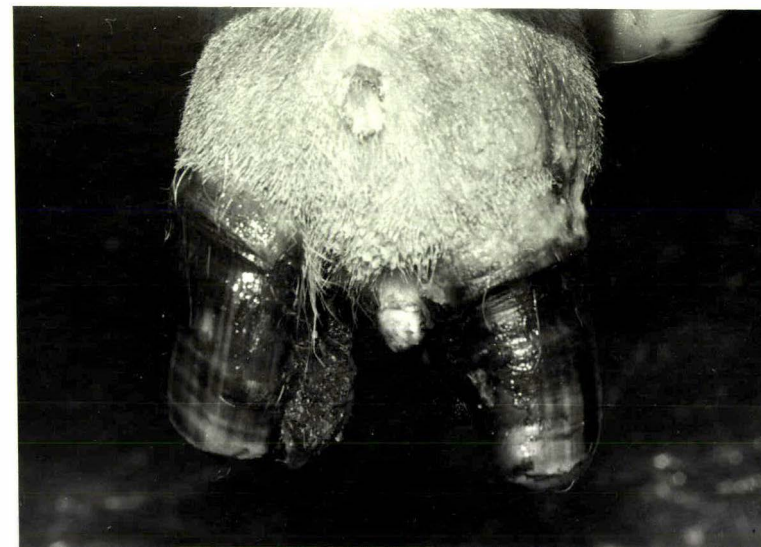
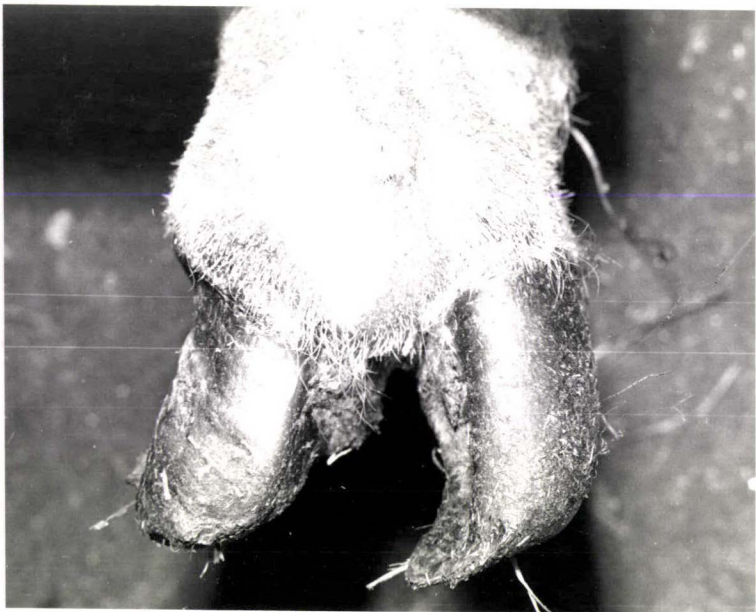

FIGURE 6.10 a, b, c, d, e and f

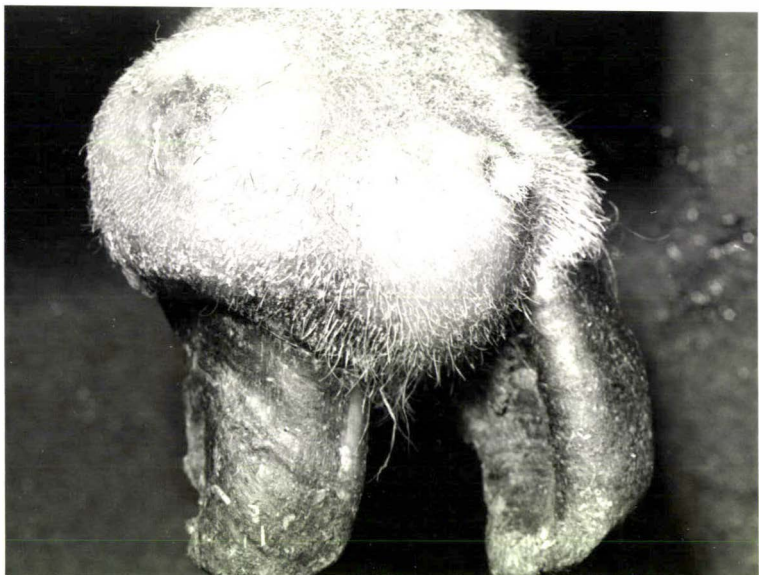Gross changes of the left hind foot of sheep number P6, following the inoculation of *Fusobacterium necrophorum* and *Corynebacterium pyogenes* organisms into the distal interphalangeal joint of the medial digit.

- (a) Day 5 - The injected digit was swollen.
- (b) Day 9 - The swelling had increased considerably, particularly in the interdigital area and above the abaxial coronet. The "abscess" discharged pus at these two sites commencing on day 12.
- (c) Day 14 - Some of the swelling had subsided with the formation of sinus tracts above the coronet and interdigitally.
- (d) Day 19 - The purulent discharge had ceased and the sinus tracts were covered by scab material. Much of the swelling had subsided.
- (e & f) Day 56 - The inoculated digit was left slightly thickened and deviated abaxially. There was a small growth of tissue into the interdigital space at one of the points of previous discharge.

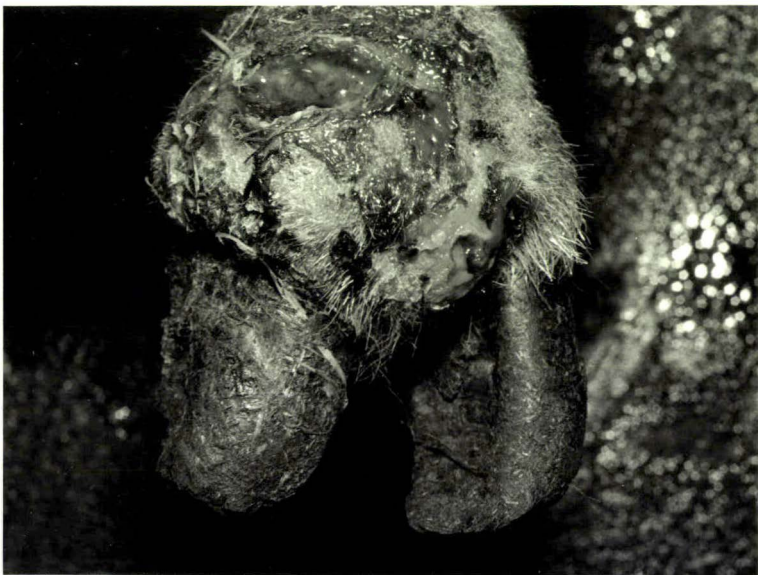a



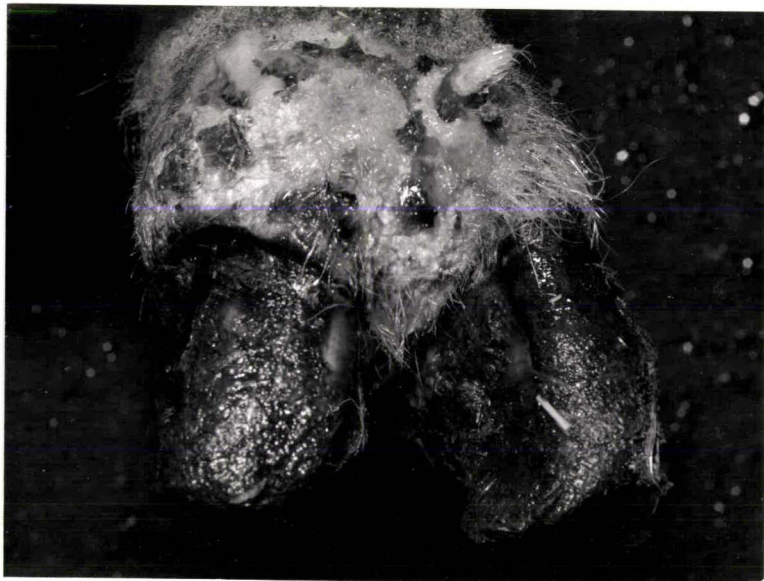b



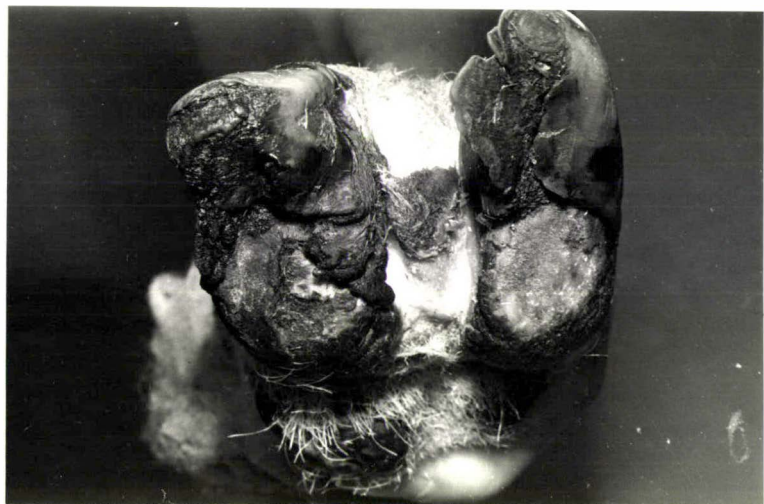c



d



e



f

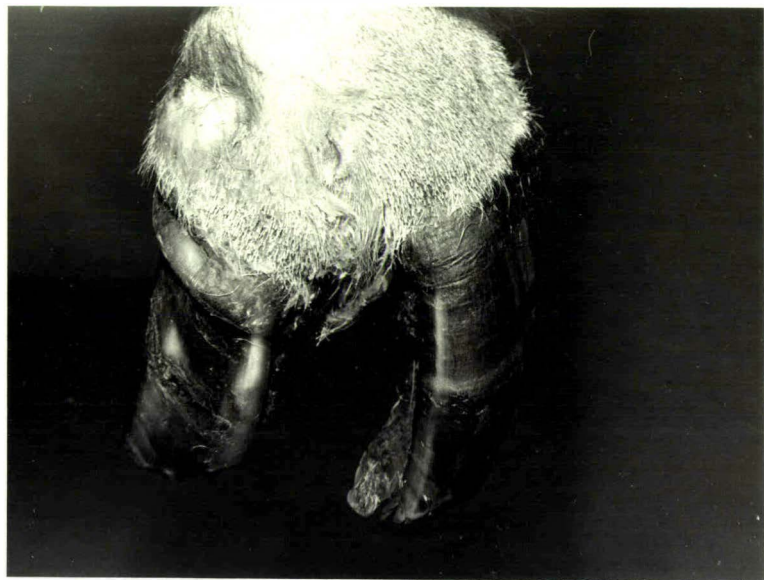
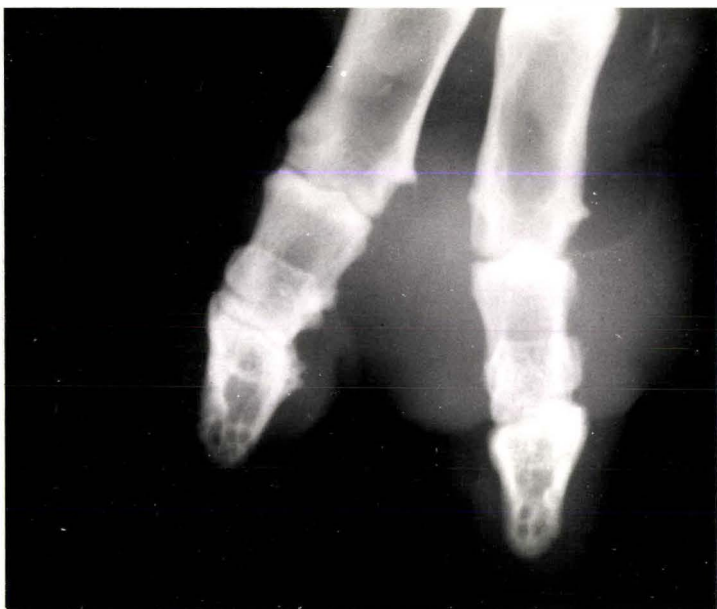
FIGURE 6.11 a, b, c, d, e and f

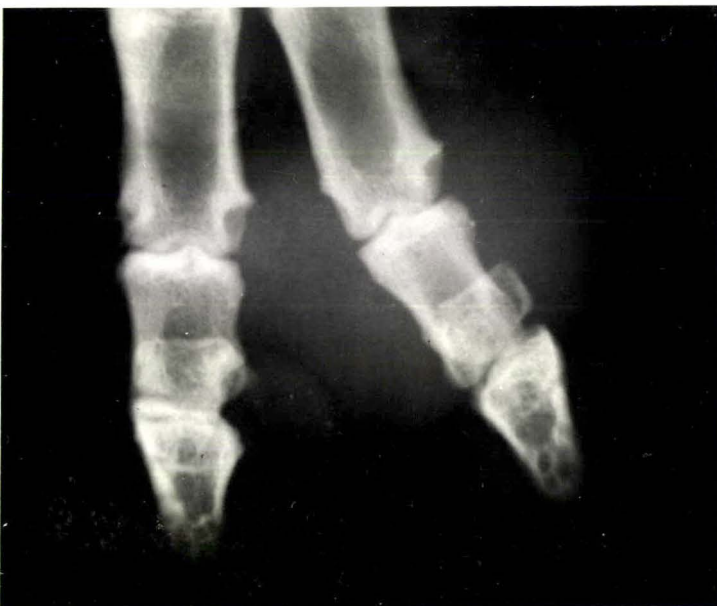Radiographically visible changes of the left hind foot of sheep number P5 following the inoculation of *Fusobacterium necrophorum* and *Corynebacterium pyogenes* organisms into the distal interphalangeal joint of the lateral digit.

- (a) Day 5 - There was increased radiodensity about the inoculated digit, indicating the extent of the soft tissue swelling.
- (b) Day 7 - The distal interphalangeal joint space was widened and there was a lack of definition of the distal end of the middle phalanx.
- (c) Day 9 - The distal interphalangeal joint space had increased in width. Bone had proliferated adjacent to the middle phalanx (arrowed).
- (d) Day 12 - The distal phalanx and the distal sesamoid were displaced abaxially and the distal end of the middle phalanx was eroded.
- (e) Day 19 - Some of the soft tissue swelling had subsided, but there was greater erosion of the distal end of the middle phalanx and of the proximal end of the distal phalanx.
- (f) Day 56 - Much of the soft tissue swelling had subsided and the distal phalanx was better aligned with the other phalanges. The middle phalanx had been reduced to about half of its original length. The new bone that had become established about the proximal, middle and distal phalanges was smooth in outline, indicating the stage of resolution.

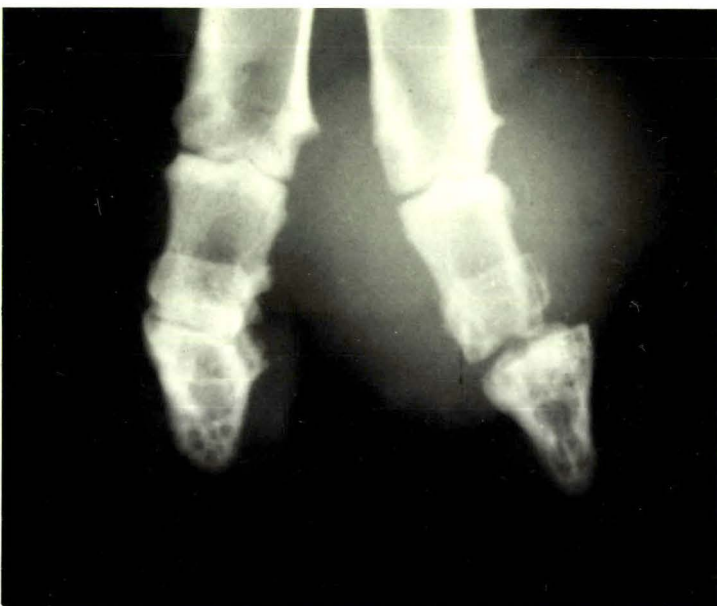a



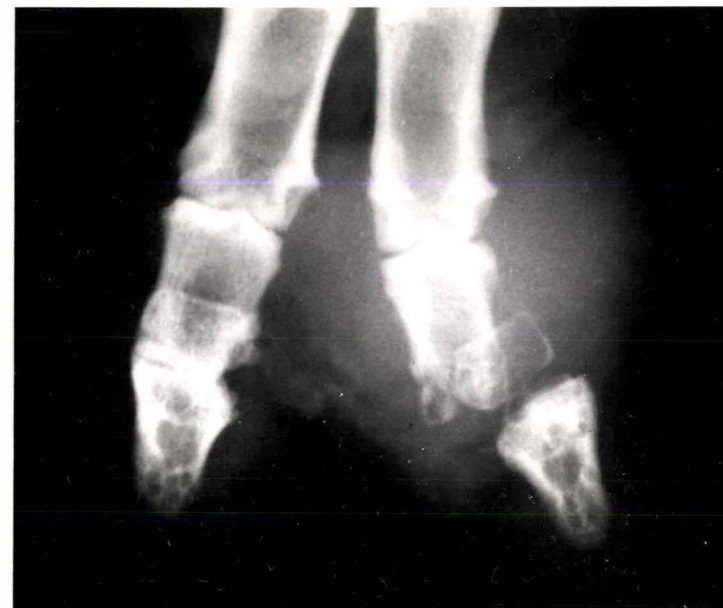b



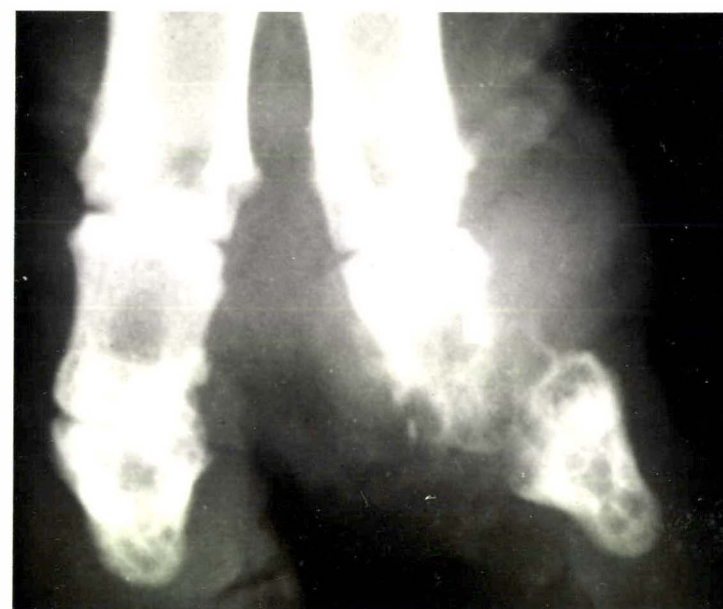c



d



e



f

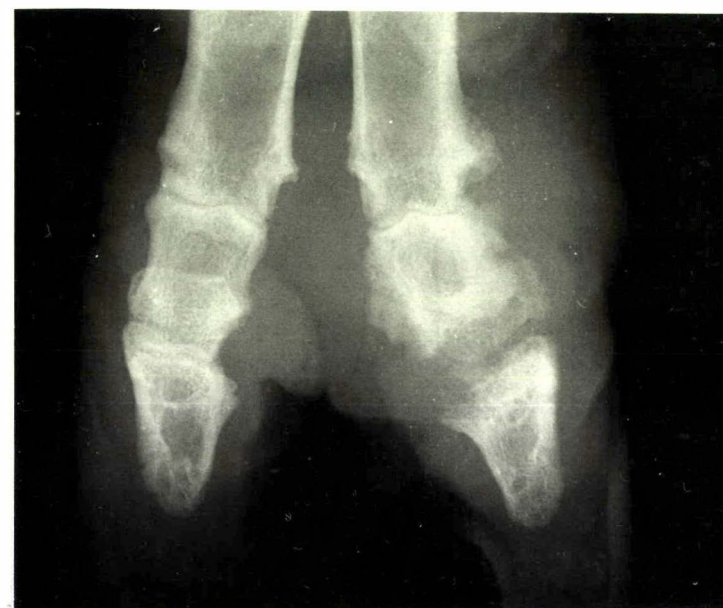
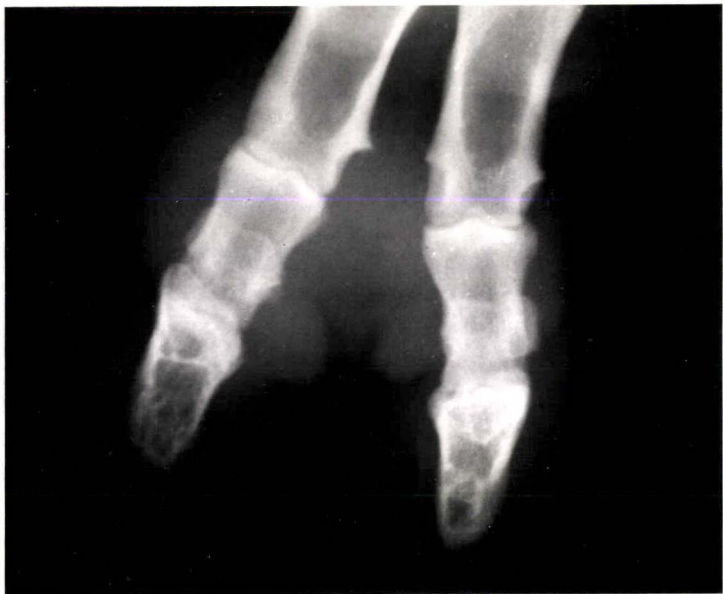
FIGURE 6.12 a, b, c, d, e and f

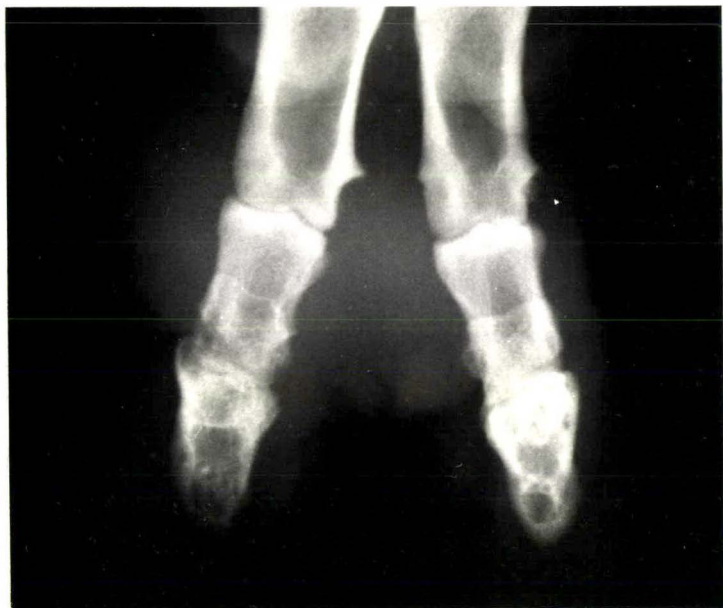Radiographically visible changes of the left hind foot of sheep number P6 following the inoculation of *Fusobacterium necrophorum* and *Corynebacterium pyogenes* organisms into the distal interphalangeal joint of the medial digit.

- (a) Day 5 - There was increased radiodensity about the inoculated digit, indicating the extent of the soft tissue swelling.
- (b) Day 7 - There was a lack of definition of the distal end of the middle phalanx.
- (c) Day 9 - The distal interphalangeal joint space was widened and the bones forming the joint were eroded. Bone had proliferated adjacent to the middle phalanx (arrowed).
- (d) Day 12 - There was further widening of the distal interphalangeal joint space and erosion of the bones forming the joint. The accumulated pus was on the point of discharging from the swollen area above the abaxial coronet.
- (e) Day 19 - Some of the soft tissue swelling had subsided but there was more bone proliferation about all phalanges of the inoculated digit.
- (f) Day 56 - Much of the soft tissue swelling had subsided. The middle phalanx had been reduced to about half its original length and the bone that had proliferated about the phalanges was smooth in outline, indicating the stage of resolution.

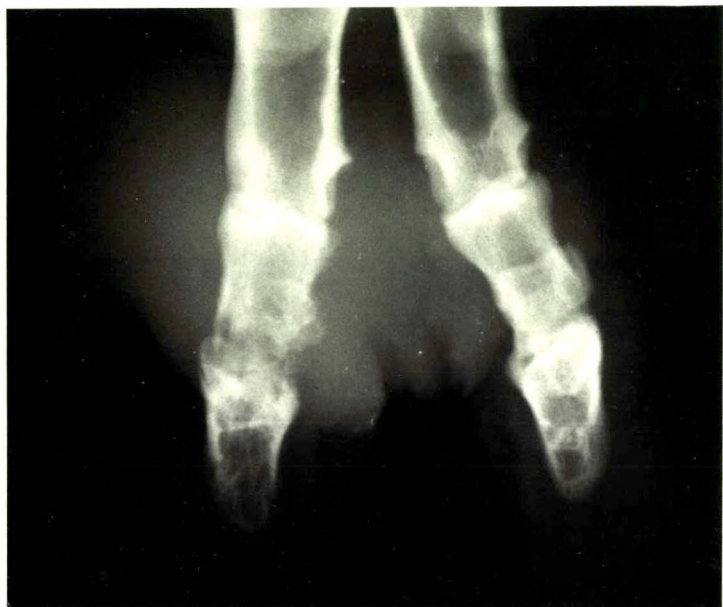a



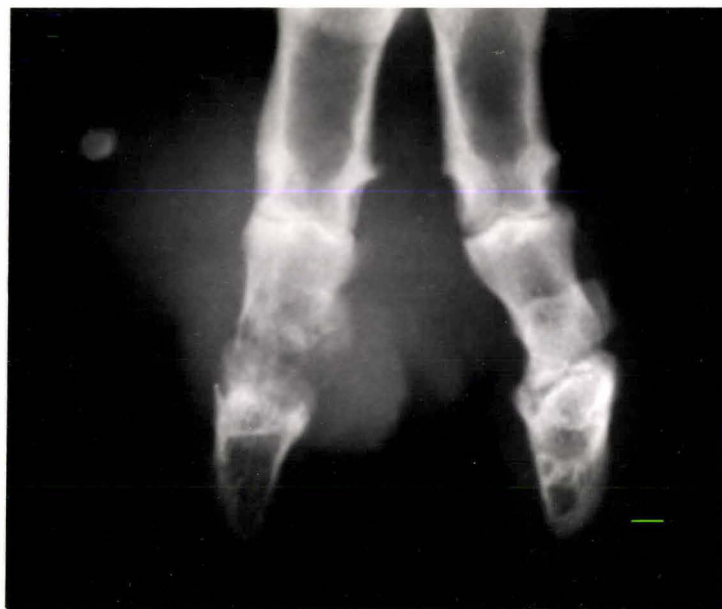b



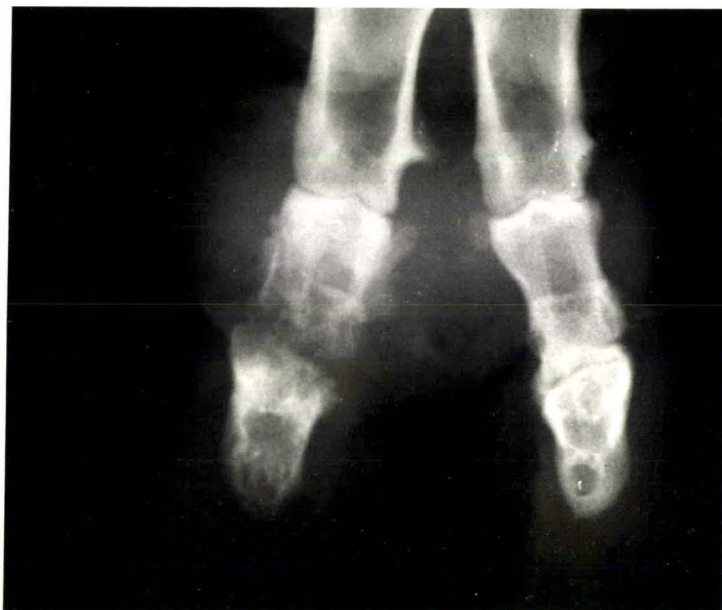c



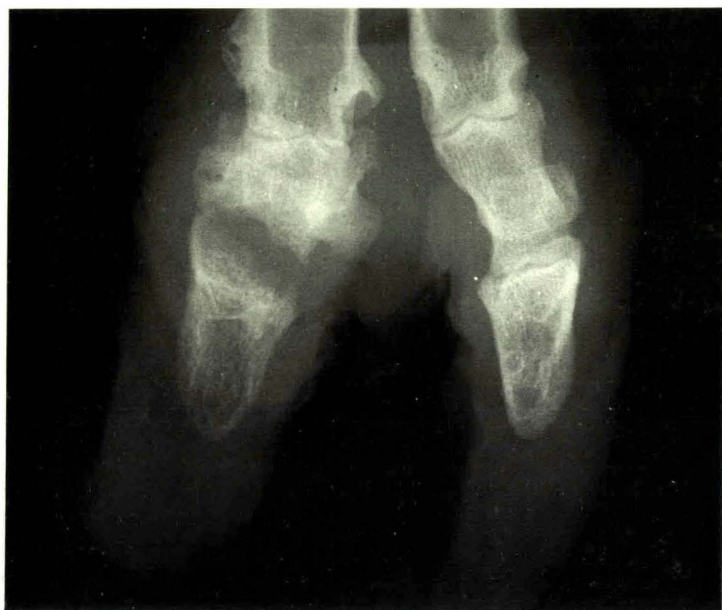d



e



f



DISCUSSION

The results demonstrate a relatively consistent response pattern to the inoculation of bacteria into the distal interphalangeal joint, and minor anomalies occurred in only three instances. In these instances, one out of the three inoculated digits either failed to react or reacted less intensely. Such minor differences are not unexpected with the inherent errors of the techniques used in the experiment. The digits were prepared for injection as if for a surgical procedure, using antibacterial preparations that could have affected the viability of the inoculum if there had been contact between them. There may also have been differences between sheep in the site that the inoculum was deposited. Furthermore the resistance of the individual sheep to the challenge was not known.

One of the difficulties of this experiment was to provide an accurate estimate of the number of organisms injected. It was considered that viable colony counting in triplicate would provide the most accurate count, but even with this technique inaccuracies undoubtedly occurred. For this reason, the figures given should be taken as an estimate only. Despite this difficulty the results were relatively consistent and similar to the findings of Roberts *et al.* (1968). These authors did not state how their figures were derived.

The results confirm that a condition of foot abscess, clinically and radiographically indistinguishable from naturally occurring cases, can be reproduced by the inoculation of a mixture of *F. necrophorum* and *C. pyogenes* organisms into the distal interphalangeal joint of sheep. In addition, it was demonstrated that a similar reaction could be reproduced by inoculating relatively large numbers of pure cultures of either organism into the same joint.

Unfortunately there were insufficient inoculations of *F. necrophorum* organisms on their own, between the dose range 10^4 and 10^{10} to be able to state conclusively that the addition of 10^4 *C. pyogenes* organisms to the inoculum was capable of reducing the dose of *F. necrophorum* required to reproduce foot abscess, from 10^{10} down to 10^8 organisms. However the results from the pilot trial using a small number of sheep demonstrated the mutually beneficial action between *F. necrophorum* and *C. pyogenes*, a feature of the mixed culture first referred to in the context of foot abscess by Roberts (1967 a & b). Although only half the number of each species of organism was injected, the combination of the two resulted in the development of foot abscess, whereas inoculation with the full number of either species, did not. These results lend strong support to the interpretation placed on the outcome of similar studies carried out by Roberts *et al.* (1968). These authors held the view that the greater pathogenicity of the mixed inoculum was associated with increased proliferation of each organism in the presence of the other. If that is true for the soft tissue site, it would seem to be equally so for inoculation into the distal interphalangeal joint, which gives rise subsequently to foot abscess.

In reproducing foot abscess by the inoculation of bacteria into the distal interphalangeal joint, the clinical and radiographic changes produced could be related to the time of joint infection. These changes were remarkably consistent and it is possible, knowing this sequence of events, to estimate the time of joint infection in naturally occurring cases. For the first five days after inoculation, the radiographic changes were restricted to soft tissue swelling about the joint. By day seven there was radiographic evidence of joint infection, which was shown as widening of the joint space and loss of density of the subchondral bone. It is evident then, that if radiographic joint changes are present, the infection has been in the joint for at least seven days. Furthermore proliferation of bone adjacent to

the periosteum was first observed nine days after joint inoculation. There was increasing proliferation of bone, especially about the middle phalanx but after three to four weeks the foot abscess began to resolve, the swelling subsided and the outline of the new bone became smooth and well defined. These radiographic changes are similar to those recorded in joint infection of cattle (Greenough *et al.*, 1972; Verschooten and De Moor, 1974).

Although inoculating bacterial cultures into the distal interphalangeal joint of sheep reproduces foot abscess, it does not help to explain how the infection reaches the joint in naturally occurring cases. Chapter 7 deals with an experimental approach to that particular aspect of foot abscess.

SUMMARY AND CONCLUSIONS

- (1) Foot abscess was reproduced by inoculating a mixture of *F. necrophorum* and *C. pyogenes* organisms into the distal interphalangeal joint of sheep.
- (2) The reproduction of foot abscess by the inoculation of a mixture of *F. necrophorum* and *C. pyogenes* organisms into the distal interphalangeal joint, supports the view that foot abscess is an infection of that joint with those organisms.
- (3) Relatively greater numbers of single species of either *F. necrophorum* or *C. pyogenes* were also capable of reproducing foot abscess when inoculated into the distal interphalangeal joint of sheep.
- (4) The experimental reproduction of foot abscess, permitted a time/change relationship to be established, so that the time of joint infection can be established in naturally occurring cases. Infection must be present in the joint for at least seven days before radiographic joint changes are observed.

CHAPTER 7

THE EXPERIMENTAL REPRODUCTION OF FOOT ABSCESS BY DAMAGING THE INTERDIGITAL TISSUES OF SHEEP

INTRODUCTION

PART A - THE ASSESSMENT OF METHODS OF INTERDIGITAL TISSUE DAMAGE

PART B - THE EXPERIMENTAL REPRODUCTION OF FOOT ABSCESS FOLLOWING LIQUID NITROGEN APPLICATION TO THE INTERDIGITAL SKIN

INTRODUCTION

MATERIALS

- Sheep
- Underfoot conditions
- Bacterial cultures
- Corticosteroid treatment
- Liquid nitrogen treatment

METHODS

- Procedure
- Assessment
- Statistics

RESULTS

- Observations
- Radiology
- Gross pathology

DISCUSSION

- Reproduction of foot abscess
- The effect of the underfoot conditions
- The effect of site of damage
- The effects of corticosteroid and bacterial cultures

CONCLUSIONS AND SUMMARY

INTRODUCTION

The direct inoculation of *F. necrophorum* and *C. pyogenes* organisms into the distal interphalangeal joint has been shown to reproduce foot abscess (Chapter 6), but this does not explain how the bacteria reach the joint in naturally occurring cases. It has been suggested that the most likely route of infection into the joint is via the interdigital space (Egerton *et al.*, 1966), usually as a sequel to ovine interdigital dermatitis (Roberts *et al.*, 1968). This suggestion was based on the observations that: -

- a) both foot conditions were present in the same flock simultaneously;
- b) in several instances foot abscess had been preceded by ovine interdigital dermatitis, and
- c) the bacterial flora of the two conditions were similar.

All of these observations have also been made by the author (Chapter 4 and Chapter 5) and in addition the anatomical study (Chapter 3) has demonstrated the vulnerability of the distal interphalangeal joint to infection from the interdigital aspect.

Further evidence in favour of the interdigital space being an important route of infection was the observations of Littlejohn (1972) and Hooper and Jones (1972) that interdigital tissue damage following the misuse of formalin permitted the entry of pathogenic organisms into the distal interphalangeal joint of sheep.

Although there is evidence that foot abscess can result as a sequel to ovine interdigital dermatitis and this latter condition can be reproduced experimentally (Parsonson *et al.*, 1969), it has not been possible to reproduce foot abscess by manipulating the underfoot conditions alone. The experiments reported here were designed to indicate what further reductions in the hosts resistance were necessary to

allow the invasion of bacteria, particularly *F. necrophorum* and *C. pyogenes*, into the distal interphalangeal joint. This would provide a more natural method of reproduction than the direct joint inoculation of the bacteria, and might help explain the pathogenesis of infection in field cases of foot abscess.

This work was undertaken in two parts. Part A was a pilot trial to investigate means of creating suitable tissue damage and Part B was a more extensive trial using one of the more promising techniques. These are presented separately.

PART A: THE ASSESSMENT OF METHODS OF INTERDIGITAL TISSUE DAMAGE

INTRODUCTION

It is possible to create tissue damage by a number of means, but this pilot trial was limited to investigating two of these; chemical damage using calcium chloride and cold exposure using liquid nitrogen. In addition all sheep were exposed to wet, faecal contaminated underfoot conditions, because foot abscess occurs under such conditions naturally (Chapter 5).

Corticosteroids have a multitude of effects on many of the stages in inflammatory and immune processes (Parrillo and Fauci, 1979), and have been used experimentally to suppress the immunity of mice to *F. necrophorum* infection (Coyle-Dennis and Lauerman, 1979). For this reason some of the sheep in the trial were treated with betamethasone.¹

1. Betsolan, Glaxo, New Zealand.

MATERIALS

Sheep and underfoot conditions

Twelve Romney ewes were identified with ear tags and housed indoors. The floor of a 2.5 metre square pen was liberally sprinkled with fresh sheep faeces and water added to a depth of 3 cm. To compensate for evaporation, water was added to the pen daily so that the sheep's feet were constantly exposed to wet faeces (Fig. 7.1).

Bacterial culture

Using a similar technique to that described in Chapter 6, cultures of *F. necrophorum* and *C. pyogenes* were mixed to provide approximately 7×10^6 *F. necrophorum* and 3×10^6 *C. pyogenes* organisms in 0.2 ml of inoculum. Administration was by subcutaneous injection.

Corticosteroid treatment

A single injection of 4 mg of betamethasone was administered subcutaneously in the neck region.

Liquid nitrogen treatment

Sheep were anaesthetised with pentobarbitone sodium and liquid nitrogen was applied to the centre of the interdigital space of each foot, via a funnel (Fig. 7.2). The internal diameter of the funnel end, in contact with the skin was 5mm. Liquid nitrogen was in contact with the interdigital skin (before vaporization) for between 120 and 180 seconds.

Calcium chloride treatment

One ml. of 10 percent calcium chloride was injected subcutaneously in the centre of the interdigital space.

FIGURE 7.1

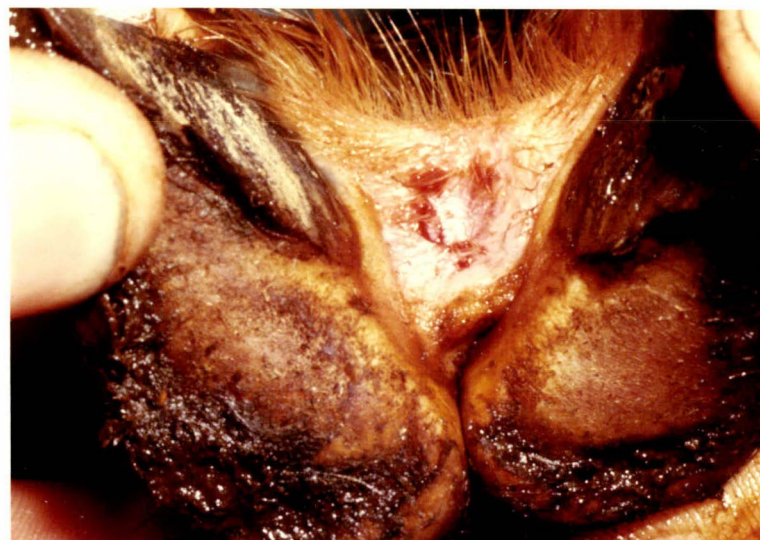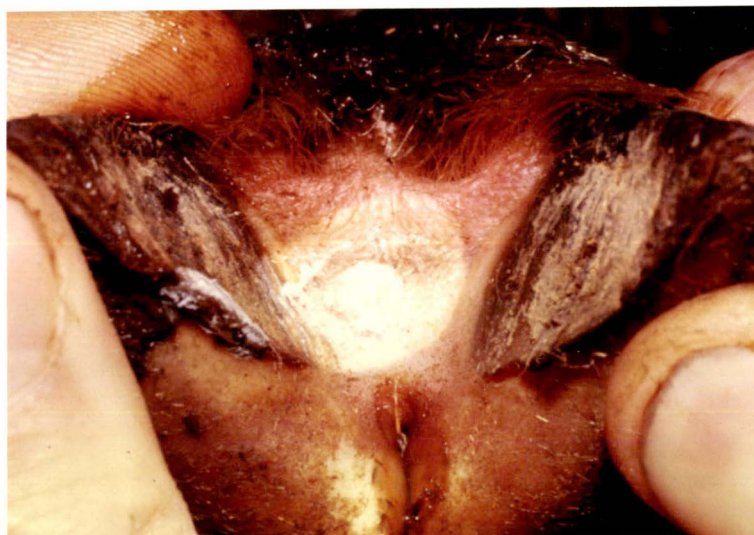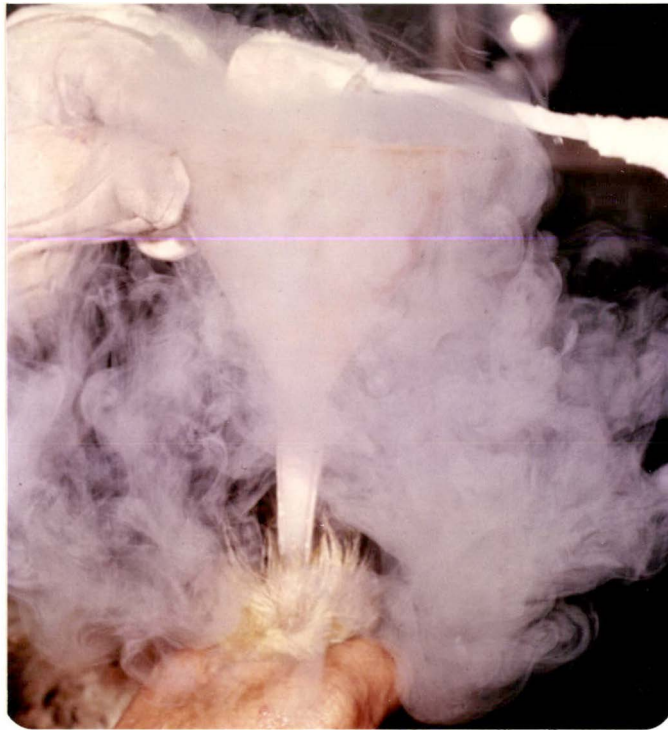A section of the pen which was covered to a depth of 3 cm. with a slurry of wet faeces.




FIGURE 7.2 a, b and c

The application of liquid nitrogen to the interdigital space of sheep.

- a) The liquid nitrogen is poured into the funnel which is held firmly against the interdigital skin. Upon contact with the skin the liquid nitrogen vaporizes.
- b) Immediately after the liquid nitrogen has vaporized the funnel was removed leaving the interdigital tissues in a frozen state.
- c) Ten minutes after the application of liquid nitrogen, the interdigital area is hyperaemic, and oedematous.



METHODS

The twelve sheep were arbitrarily assigned to one of four groups, A B C and D. The sheep were maintained in the prepared pen for 7 days before the specific treatments were applied and for a further 21 days, after which they were moved to dry surroundings for 6 days. The trial was then concluded.

The four groups were treated according to the schedules shown in Table (7.I).

TABLE 7.I
THE SCHEDULES OF TREATMENTS USED TO ASSESS METHODS OF INTER-
DIGITAL TISSUE DAMAGE

Group	Sheep No.	Treatment applied		
		Day 1	Day 2	Day 3
A	1	liquid nitrogen		
	2	liquid nitrogen	betamethasone	
	3	liquid nitrogen		bacterial cult.
	4	liquid nitrogen	betamethasone	bacterial cult.
B	5	calcium chloride		
	6	calcium chloride	betamethasone	
	7	calcium chloride		bacterial cult.
	8	calcium chloride	betamethasone	bacterial cult.
C	9			bacterial cult.
	10			bacterial cult.
D	11	control - no treatment		
	12	control - no treatment		

Assessment

The sheep were examined daily for signs of lameness, swelling, or damage to the interdigital tissues and where appropriate, photographs and radiographs were taken in a similar manner to that described in Chapter 4.

At the conclusion of the trial on day 27, the sheep were slaughtered and the distal interphalangeal joints opened with a scalpel, to examine the extent of the tissue damage.

In instances where pus was present in the distal interphalangeal joint, the purulent material was examined microscopically following staining by Gram's method and cultured both aerobically and anaerobically on five percent sheep blood agar.

RESULTS

Untreated control sheep

The interdigital skin of all feet of the two control sheep became mildly inflamed, presumably from the constant wetting, but this did not result in lameness and the interdigital skin remained intact.

Liquid nitrogen as a necrotising agent

Observations The application of liquid nitrogen to the interdigital space, damaged the interdigital skin sufficiently to cause lameness in all feet the day after treatment. Within three days the interdigital skin appeared inflamed and necrotic, (Fig. 7.3 and Fig. 7.5), and by day eight the disc of contact was beginning to slough from the interdigital space (Fig. 7.4). The sloughing of the damaged interdigital area was completed by day 14, leaving a deep ulcer. In the 11 instances in which infection

became established in the distal interphalangeal joint (Table 7.II), there was a sinus tract discharging pus into the damaged interdigital area (Fig. 7.5), and swelling was present above the coronet on the abaxial aspect of the digit. The feet affected in this way were painful and the sheep were recumbent for long periods, especially where more than one foot was affected. In three instances, both digits of the one foot were swollen.

Radiology

Radiology of the feet, revealed the presence of infection in the distal interphalangeal joint in 11 of the digits of the four sheep in group A. There was soft tissue swelling about the digit and the distal interphalangeal joint space was widened (Fig. 7.6). The distal end of the middle phalanx was eroded, indicating the extent of the infection. In some cases the distal phalanx and the distal sesamoid were displaced abaxially, suggesting that the axial collateral ligaments and the interdigital ligament had all ruptured (Fig. 7.6). New bone was apparent adjacent to the periosteum, particularly that of the middle phalanx. These radiographic changes are identical to those seen in naturally occurring cases of foot abscess (Chapter 4).

Gross Pathology

In those feet in which infection had not involved the distal interphalangeal joint, the interdigital skin was healing and no sinus tracts were visible. In contrast, in the 11 digits that developed a condition of foot abscess, sinus tracts discharged pus into the damaged interdigital space (Fig. 7.5). There was continuity between the interdigital lesion, the distal interphalangeal joint and the swollen area above the abaxial coronet. The distal interphalangeal joint was in varying stages of destruction. Pus was present and the bones forming the joint, especially the distal end of the middle phalanx, were discoloured and necrotic (Fig. 7.5). In 9 of the 11 infected joints the

TABLE 7.II

THE DIGITS THAT DEVELOPED INFECTION IN THE DISTAL INTER-PHALANGEAL JOINT FOLLOWING LIQUID NITROGEN TREATMENT.

Sheep	Digit	Infection Present in the Joint	Infected digits/ sheep digits
1	Left fore lateral	-	0/8
	medial	-	
	Right fore lateral	-	
	medial	-	
	Left hind lateral	-	
	medial	-	
2	Right hind lateral	-	4/8
	medial	-	
	Left fore lateral	-	
	medial	-	
	Right fore lateral	+	
	medial	-	
3	Left hind lateral	-	2/8
	medial	-	
	Right hind lateral	+	
	medial	+	
	Left fore lateral	-	
	medial	+	
4	Right fore lateral	-	5/8
	medial	+	
	Left hind lateral	+	
	medial	+	
	Right hind lateral	-	
	medial	-	

axial collateral ligament was necrotic and had ruptured, allowing the distal interphalangeal joint to become partly dislocated. The ruptured remains of the ligament sometimes extended into the interdigital space.

Bacteriology

Nine swabs of purulent material were taken from the infected, distal interphalangeal joints. Direct microscopic examination following staining by Gram's method revealed the presence of numerous gram-negative filaments and gram-positive cocci and bacilli. In conjunction with various mixed organisms, *C. pyogenes* was grown from all nine samples and *F. necrophorum* from seven of the nine.

Calcium chloride as a necrotising agent

Two sheep, numbers 5 and 6 that had been treated with calcium chloride subcutaneously did not become lame, nor did they develop changes in the appearance of the interdigital space, other than those observed in the control sheep.

The sheep numbers 7 and 8 which had been injected subcutaneously with cultures of *F. necrophorum* and *C. pyogenes* organisms following calcium chloride treatment, developed a minor reaction associated in some instances with lameness. Sheep 9 and 10 given the cultures alone were similarly affected. All sheep showed interdigital skin changes similar to the controls, presumably due to the underfoot conditions, but where the sheep was lame the interdigital tissues were ulcerated and pus was present in the lesion. This occurred in two of the feet of sheep numbers 8 and 9 and in one of the feet of sheep number 10.

The infection did not invade into the distal interphalangeal joint and the lesions healed within three weeks.

FIGURE 7.3

The interdigital space three days after liquid nitrogen had been applied to the interdigital skin.

The interdigital skin was inflamed and appeared discoloured in the centre.

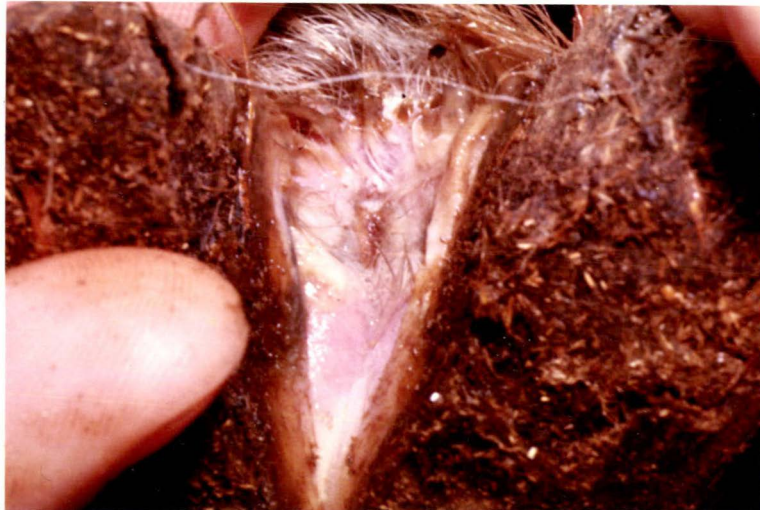

FIGURE 7.4 a and b

The interdigital space of two sheep, eight days after liquid nitrogen had been applied to the interdigital skin.

a) Purulent/necrotic material had detached from the interdigital space.

b) U - ulcerated interdigital area.

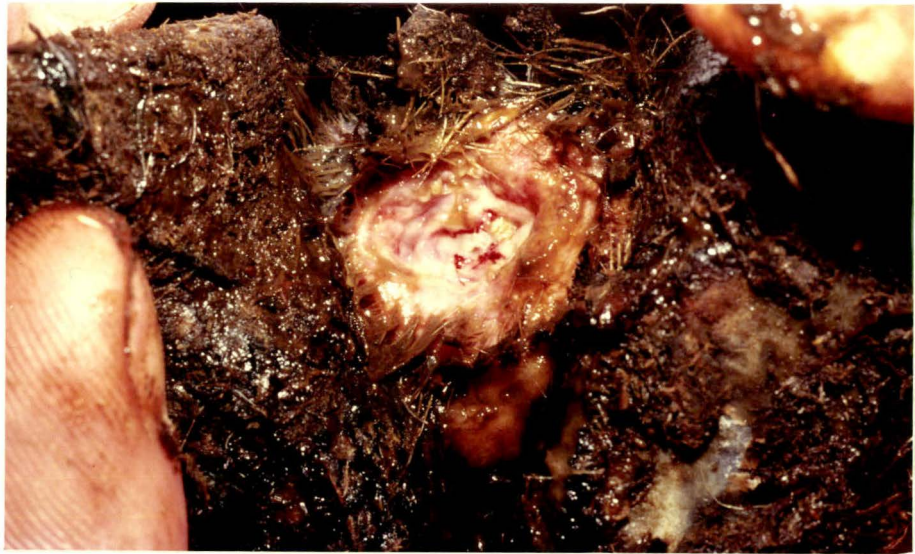
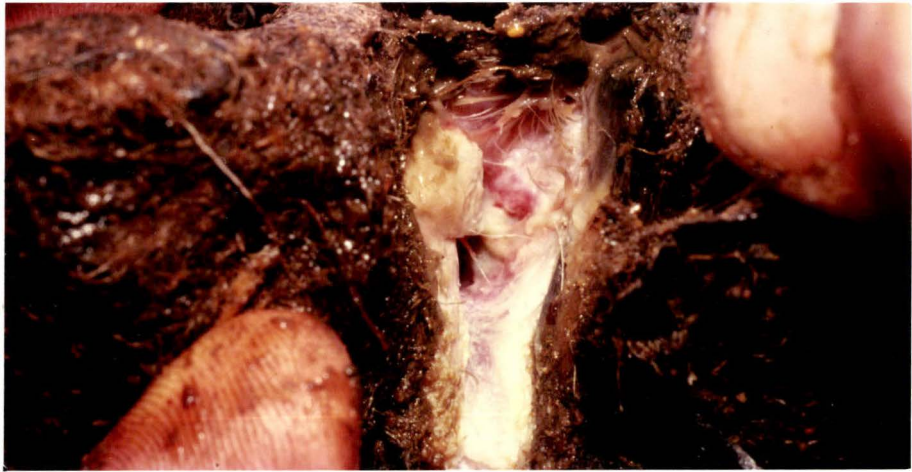
FIGURE 7.5 a, b and c

The right fore foot of sheep number 2, following the application of liquid nitrogen to the interdigital skin.

- a) Day 3
S - swollen interdigital space

- b) Day 27
T - opening into sinus tract

- c) Day 27 (directly after slaughter)
Infection was present in the lateral joint but not in the medial one.
The distal end of the middle phalanx was discoloured and appeared necrotic (N)

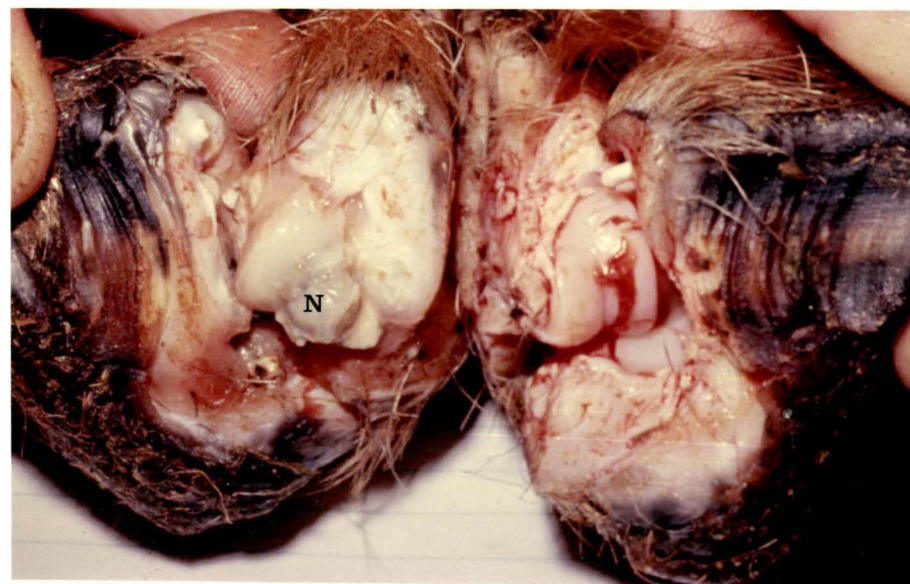
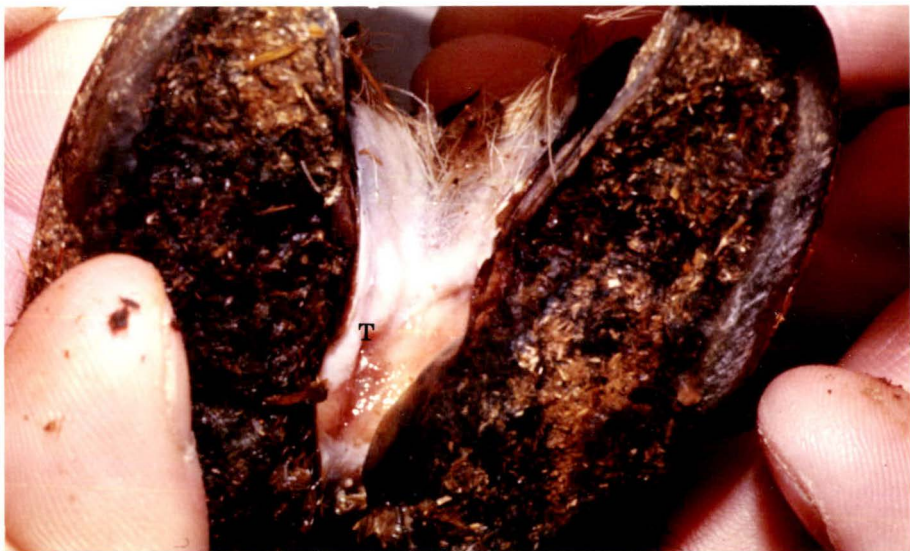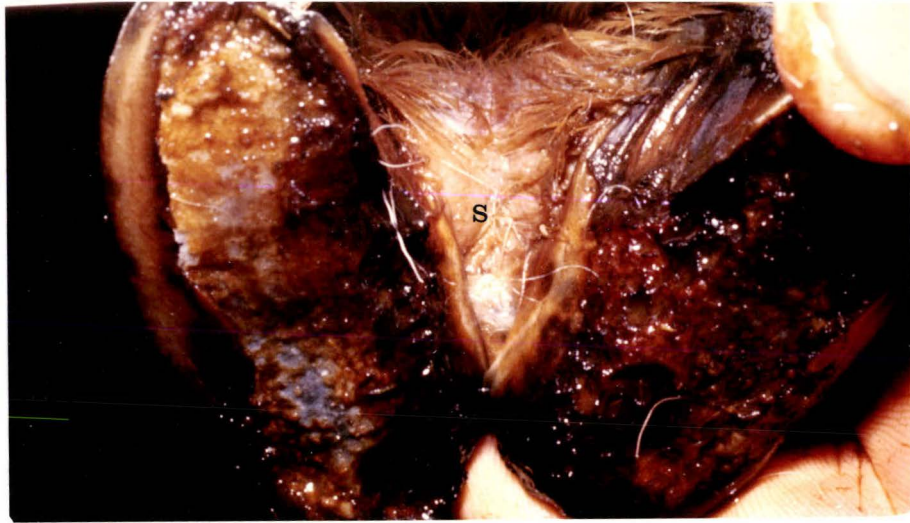


FIGURE 7.6 a, b and c

Radiographs of the feet of sheep, 27 days after liquid nitrogen had been applied to the interdigital skin.

a) The left fore foot of the sheep number 3

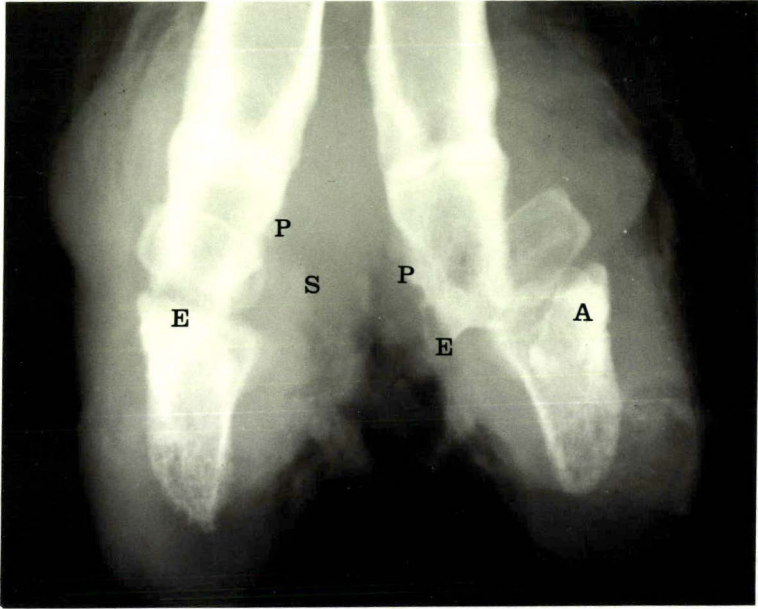
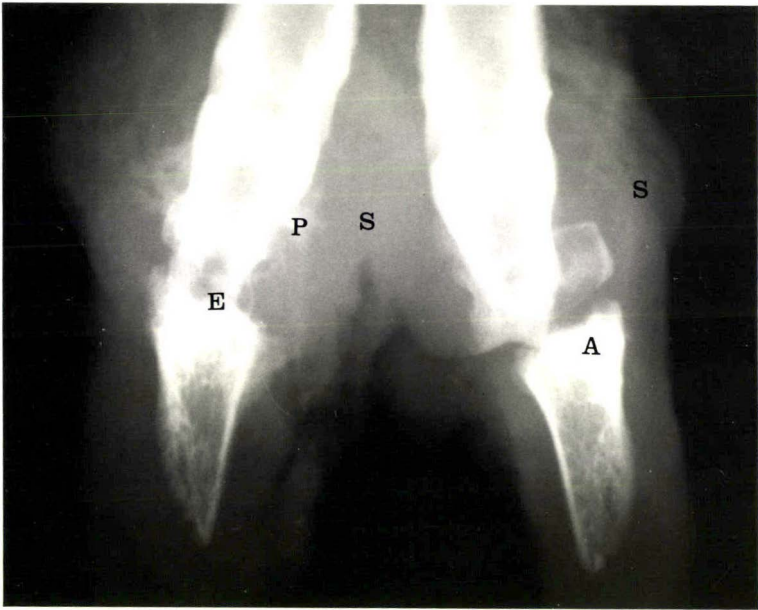
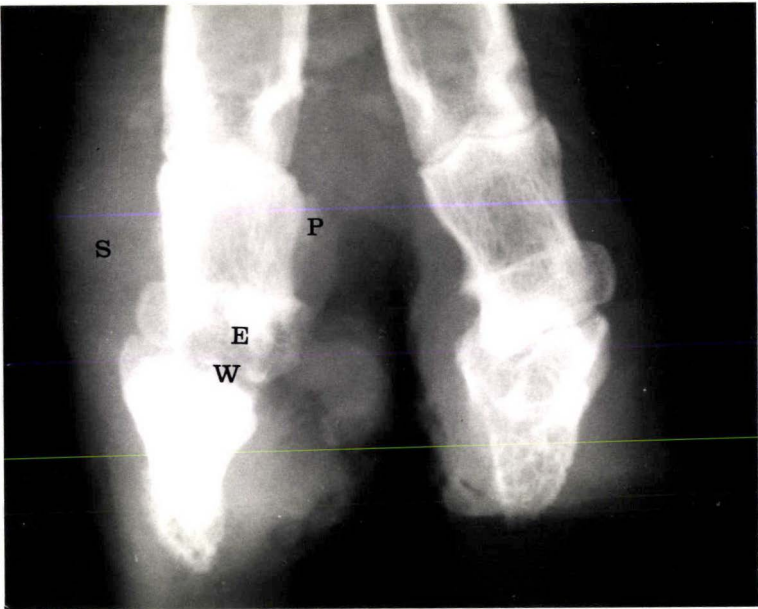
S - soft tissue swelling
E - erosion of bone
P - proliferation of bone
W - widening of the joint space

b) The left hind foot of sheep number 4

S - soft tissue swelling
E - erosion of bone
P - proliferation of bone
A - abaxial displacement of the distal
phalanx and sesamoid

c) The left fore foot of the sheep number 4

S - soft tissue swelling
E - erosion of bone
P - proliferation of bone
A - abaxial displacement of the distal
phalanx and sesamoid



The effect of corticosteroids

Of the four sheep treated with liquid nitrogen, 9 of the 11 joints that developed arthritis occurred in the two sheep that had received betamethasone.

DISCUSSION

The mild inflammation observed in the interdigital skin of the untreated control sheep was apparently similar to that induced by Egerton *et al.* (1969) following the constant wetting of the sheep's feet in an environment heavily contaminated with *F. necrophorum*. Under such conditions, the interdigital skin became macerated and *F. necrophorum* invaded the stratum corneum, resulting in inflammation and parakeratosis. Although the lesion produced was similar to ovine interdigital dermatitis (Parsonson *et al.*, 1967) the interdigital necrosis and ulceration evident in some cases of naturally occurring ovine interdigital dermatitis (Chapter 5) did not occur. Furthermore it has not been possible to reproduce foot abscess by manipulating the underfoot conditions alone.

Kreberg (1946) described the changes that occur when tissues are subjected to sudden freezing and then allowed to thaw. While frozen, the tissues appeared white and the blood vessels were constricted. Upon thawing, the whiteness of the frozen skin was replaced by a rich red colour. Within a few minutes, oedema was observed. The prominent features of the tissues after thawing were hyperaemia, oedema and necrosis.

These same changes were observed in the interdigital tissues exposed to liquid nitrogen. It appears that the interdigital tissue damage was sufficient to permit bacteria, including

F. necrophorum and *C. pyogenes*, to invade, multiply and eventually reach the distal interphalangeal joint in 11 of a possible 32 digits. The foot condition produced was clinically and radiographically similar to naturally occurring cases of foot abscess and it is suggested that this sequence of skin damage, bacterial invasion and eventual arthritis simulates what occurs in outbreaks of ovine interdigital dermatitis and foot abscess such as that reported in Chapter 5. All other means of tissue insult tried on the interdigital skin did not result in infection of the distal interphalangeal joint. The subcutaneous inoculation of cultures of *F. necrophorum* and *C. pyogenes* did not reproduce foot abscess either. Roberts and Egerton (1969) from their studies on footrot obtained similar results when *B. nodosus* was inoculated in conjunction with *F. necrophorum* and *C. pyogenes* organisms.

Calcium chloride has been used as a chemical necrotising agent to predispose sheep to tetanus infection (Cooper, 1966), but in the way used in this pilot trial it was not successful in permitting infection of the distal interphalangeal joint.

Corticosteroids have been used to increase the susceptibility of the host to *F. necrophorum* infection (Coyle-Dennis and Lauerma, 1979) and betamethasone was used in this trial for this effect. It was not intended to examine the role of corticosteroids in the pathogenesis of foot abscess. More joint infections occurred in the sheep that had received betamethasone, but the numbers of sheep were insufficient for any conclusions to be reached. Further experimentation is indicated however.

CONCLUSIONS AND SUMMARY

1. Damaging the interdigital tissues of sheep using liquid nitrogen, allowed mixed organisms including *F. necrophorum* and *C. pyogenes* to invade, multiply and eventually infect the distal interphalangeal joint. The foot condition produced was clinically and radiographically similar to

naturally occurring cases of foot abscess and it is suggested that this simulates what happens in some natural cases.

2. Subcutaneous, interdigital injection of 1 ml of 10 percent calcium chloride solution did not result in infection of the distal interphalangeal joint.
3. Injecting a mixed inoculum of *F. necrophorum* and *C. pyogenes* organisms beneath the interdigital skin did not result in infection of the distal interphalangeal joint.

PART B: THE EXPERIMENTAL REPRODUCTION OF FOOT ABSCESS FOLLOWING LIQUID NITROGEN APPLICATION TO THE INTERDIGITAL SKIN

INTRODUCTION

The previous pilot trial indicated that liquid nitrogen was a promising agent to reproduce necrosis of the interdigital tissues, thus permitting environmental bacteria to invade, multiply and eventually infect the distal interphalangeal joint. These encouraging results warranted further experimentation using similar methods, but greater numbers of sheep.

The time the liquid nitrogen needed to be in contact with the interdigital skin was not precisely defined, but between 120 and 180 seconds had proved successful in the pilot trial. It was decided that for further experimentation a constant time of 150 seconds would be used.

The anatomical study (Chapter 3) demonstrated the vulnerability of the distal interphalangeal joint, particularly on the axial (or interdigital) aspect at the sites where the

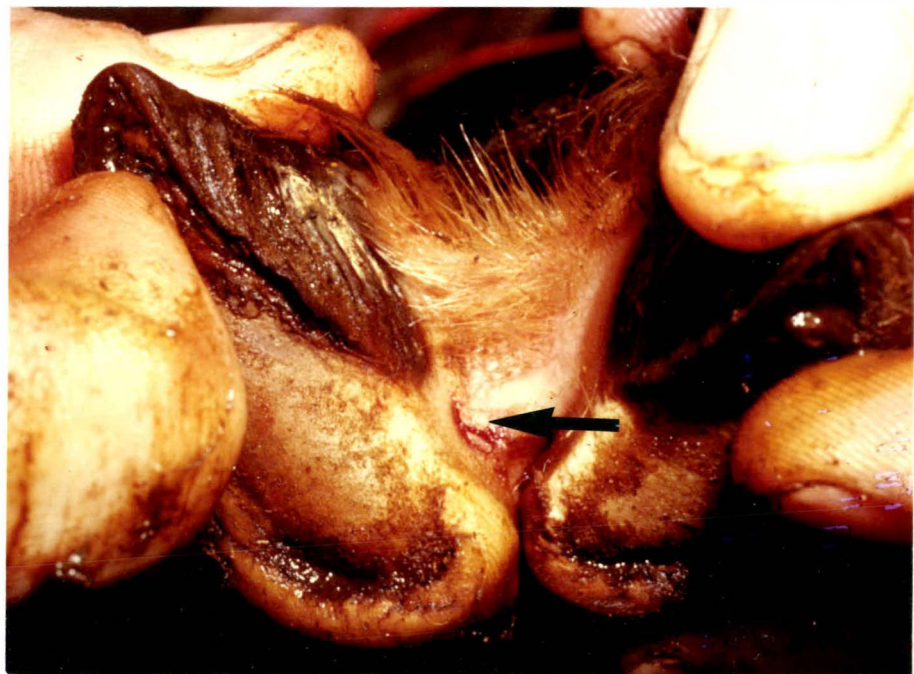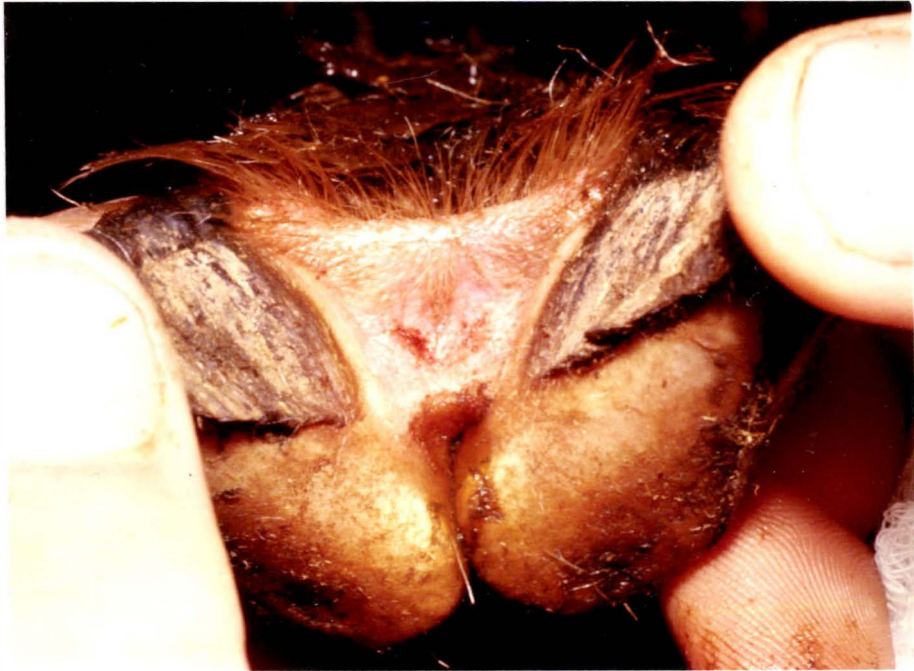joint capsule protrudes above the coronary border as the dorsal and volar pouches. Necrosis of the interdigital tissues adjacent to these sites might result in more joint infections than similar damage to other areas of the interdigital space. It was impossible to explore all the potential sites within the interdigital space and only two were chosen (Fig. 7.7).

m - in the centre of the interdigital area

s - on the side of the interdigital space
adjacent to the coronary border at the
junction of the axial groove

From the previous pilot trial it appeared that injecting a corticosteroid before bacterial cultures were applied might aid the development of joint infection.

Consequently it was decided to persist with the use of both artificial cultures and attempts at immunosuppression in an endeavour to reproduce more consistent results.



MATERIALS

Sheep

Twenty, Romney and Romney cross bred, seven month old sheep were individually identified with ear tags and housed indoors.

Underfoot conditions

An underfoot slurry of wet sheep faeces, similar to that used in the previous pilot trial, was established. Sheep were held in the pen for periods as indicated in the text.

Bacterial cultures

Using a similar technique to that described in Chapter 6, cultures of *F. necrophorum* and *C. pyogenes* were grown and mixed to provide approximately 10^6 *F. necrophorum* and 10^7 *C. pyogenes* organisms in 0.2 ml of inoculum. Administration was by subcutaneous injection of the interdigital skin at the site previously damaged with liquid nitrogen.

Corticosteroid treatment

A single injection of 4 mg of betamethasone was administered subcutaneously in the neck region.

Liquid nitrogen treatment

Liquid nitrogen was applied to the interdigital skin in a similar manner to that described in the pilot trial. The only differences were that the site of application was alternated between the middle and the side of the interdigital space according to the schedule shown in Table (7.III) and a constant time of 150 seconds was used.

TABLE 7.III

THE SITE OF APPLICATION OF LIQUID NITROGEN

Foot	Sheep numbers	
	1, 3, 5, 7, 9, 11, 13, 15	2, 4, 6, 8, 10, 12, 14, 16
Left fore	S	M
Right fore	M	S
Right hind	S	M
Left hind	M	S
Key: S - side of the interdigital space M - middle of the interdigital space		

METHODSProcedure

The 20 sheep were introduced to the underfoot slurry for seven days before the specific treatments shown in Table (7.IV) were applied.

TABLE 7.IV

SCHEDULES OF TREATMENTS USED TO REPRODUCE FOOT ABSCESS

Group	Number of sheep	Treatments applied		
		Liquid Nitrogen Day 1	Betamethasone Day 2	Bacterial Cultures Day 3
A	8	+	+	+
B	8	+	-	-
C	4	-	-	-

Following the application of the liquid nitrogen and recovery from the anaesthetic the sheep were returned to the pen for 10 days and then they were moved to a dry straw-covered pen for a further 11 days, at which point the trial was concluded.

Assessment

At the conclusion of the trial the sheep were destroyed and their feet photographed and radiographed and the digits opened with a scalpel to examine the extent of tissue damage.

Statistics

The distribution and frequencies of observations were subjected to analysis using the chi-squared test. In every case Yates' correction factor was applied and expected values were always greater than five. The probability of differences having occurred by chance (P), were read off tables for chi-squared using the appropriate degrees of freedom.

RESULTS

Observations

In virtually all respects, the results confirmed those of the pilot experiment. Initially the sheep that had been treated with liquid nitrogen were lame on all four feet. The treated area appeared necrotic and began to slough out of the interdigital space between 8 and 14 days (Fig. 7.8; Fig. 7.9; Fig. 7.10; Fig. 7.11). Within 10 days many of the sheep were showing signs consistent with infection of

the distal interphalangeal joint. These signs included swelling above the coronet on the abaxial aspect and the formation of sinus tracts in the interdigital space from which pus could be expressed. Because the 16 treated sheep, with the exception of number 10, were showing these signs in one or more feet by day 10, it was decided to move them to dry surroundings where they could feed and lie down in comfort.

The four untreated control sheep were not lame.

Radiology

Twentyone days after the initial interdigital damage, radiographic joint changes consistent with infection of the distal interphalangeal joint were present in 28 digits of the 16 treated sheep (Table 7.V). These radiographic changes indicated that there was a variation in the time of joint infection (chapter 6). In some instances (Fig. 7.8) the radiographic changes were confined to widening of the joint space and increased density of the soft tissue about the joint. From observations made following the inoculation of *F. necrophorum* and *C. pyogenes* into the distal interphalangeal joint (chapter 6) it is evident that joint infection in these cases was assumed to be of about seven days duration whereas other digits showed radiographic evidence of more long standing infection. The distal end of the middle phalanx was eroded indicating the extent of the infection and there was proliferation of bone adjacent to the middle phalanx (Fig. 7.9; Fig. 7.10; Fig. 7.11; Fig. 7.12).

These radiographic changes are indistinguishable from those seen in naturally occurring cases of foot abscess (Chapter 4).

TABLE 7.VREPRODUCTION OF FOOT ABSCESS FOLLOWING LIQUID NITROGEN
DAMAGE TO THE INTERDIGITAL TISSUES

Group	Number of sheep	Number of digits with foot abscess/ number of feet
A	8	16/32
B	8	12/32
C	4	0/16

Gross Pathology

The presence of infection in the joint was confirmed in 28 digits of the 16 sheep in groups A and B (table 7.V). There was direct continuity between the sinus tracts opening into the interdigital space and the distal interphalangeal joint. The amount of damage to the joint structures was variable. In more recent infections (Fig. 7.8 and Fig. 7.12) the joint surfaces were eroded and discoloured but the axial collateral ligaments were intact. Where joint infection had been present for some time, the joint ends of the phalanges were discoloured and necrotic, and the axial collateral ligaments had ruptured (Fig. 7.9; Fig. 7.11). The joint space was filled with partly liquified, necrotic material and granulation tissue had developed within and adjacent to the joint.

In a further 11 feet, infection had tracked down to the soft tissues adjacent to the distal interphalangeal joint but had not penetrated the joint. It is possible that given more time, some of these digits may have developed joint infections.

Twenty joint infections resulted when the centre of the interdigital space had been damaged compared with eight occurring when the side of the interdigital space was the site of

damage. This difference was statistically significant ($P < 0.05$).

In every instance that liquid nitrogen was applied to the centre of the interdigital space, the right digit of the foot was the one affected.

FIGURE 7.8 a, b and c

The right fore foot of sheep number 7, after the application of liquid nitrogen to the interdigital skin.

a) Day 9

N - necrotic tissue

b) Day 21 (immediately after slaughter)

E - erosion of bone

G - granulation tissue

c) Day 21

S - soft tissue swelling

W - widening of the joint space

The radiographic changes indicate that the distal interphalangeal joint had been infected for approximately 9 days.

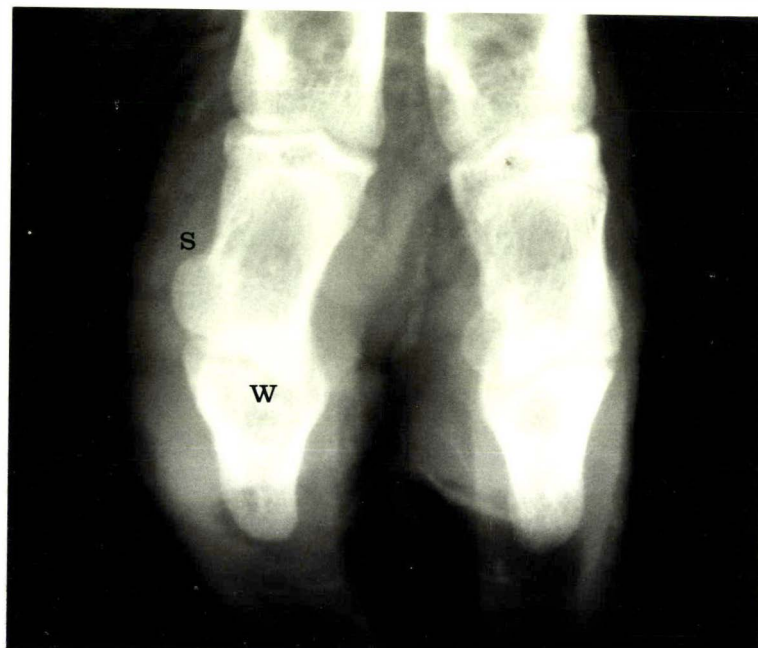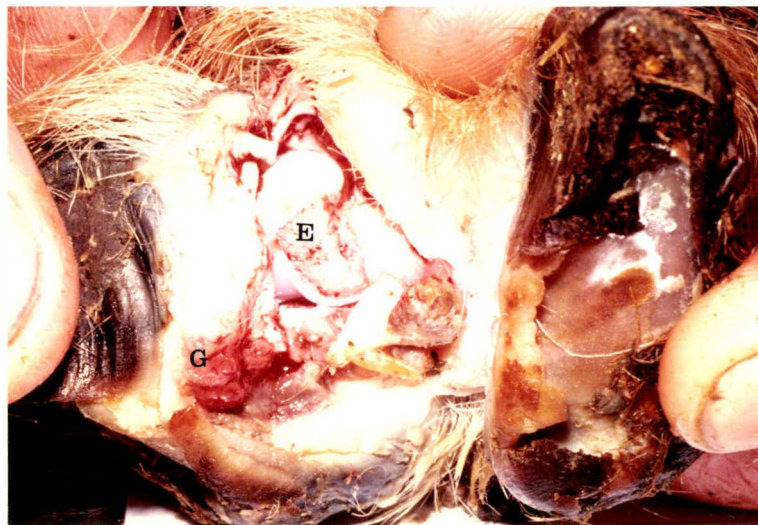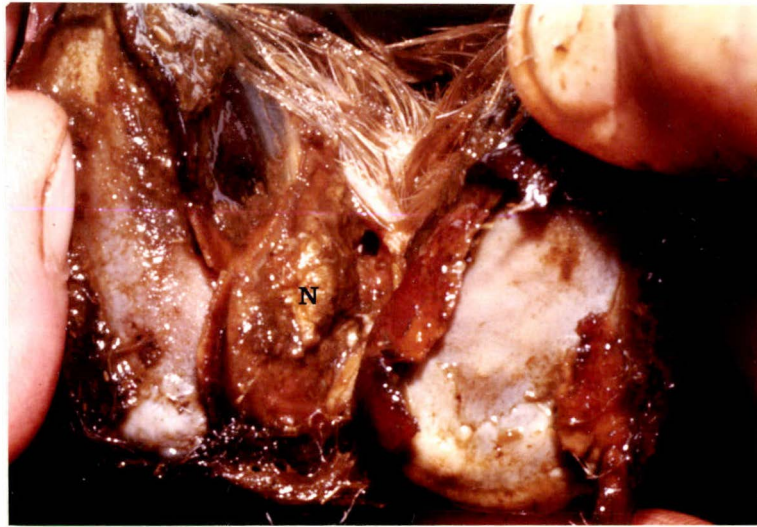


FIGURE 7.9 a, b and c

The right hind foot of sheep number 7, after the application of liquid nitrogen to the interdigital skin.

a) Day 9

N - necrotic tissue

b) Day 21 (immediately after slaughter)

G - granulation tissue

T - sinus tract

L - ruptured axial common collateral
ligament

c) Day 21

S - soft tissue swelling

E - erosion of bone

P - proliferation of bone

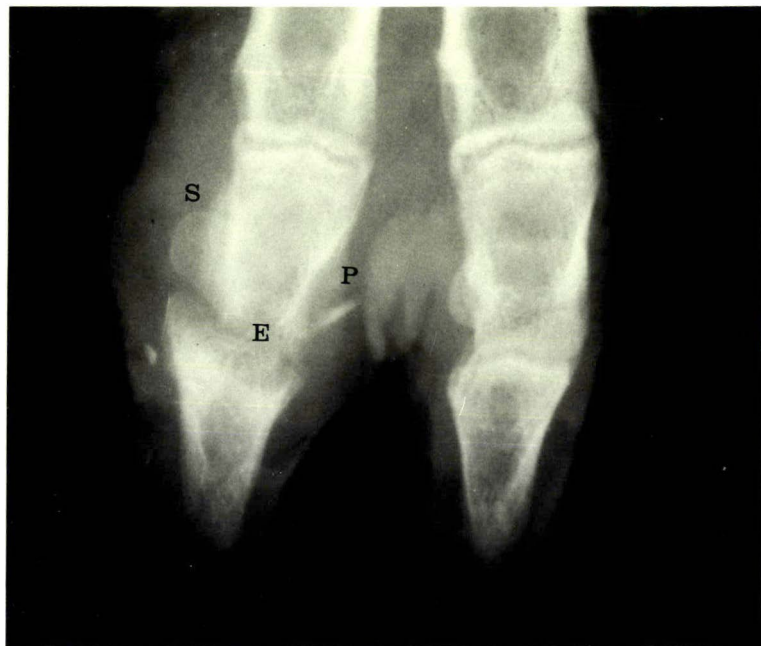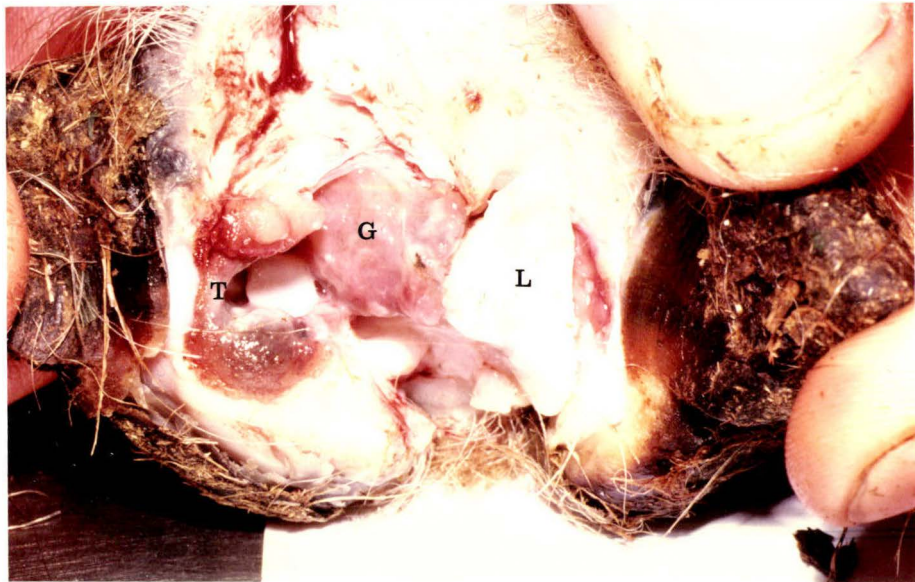
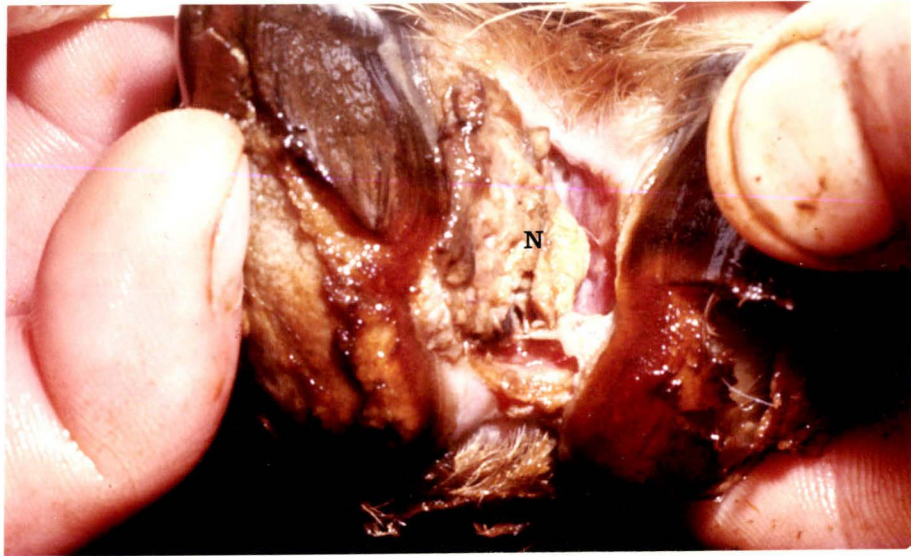


FIGURE 7.10 a, b and c

The right hind foot of sheep number 6, after the application of liquid nitrogen to the interdigital skin.

a) Day 9

N - necrotic tissue

b) Day 21 (immediately after slaughter)

G - granulation tissue

T - sinus tract

c) Day 21

E - erosion of bone

P - proliferation of bone

A - abaxial displacement of the distal
phalanx and sesamoid

S - soft tissue swelling

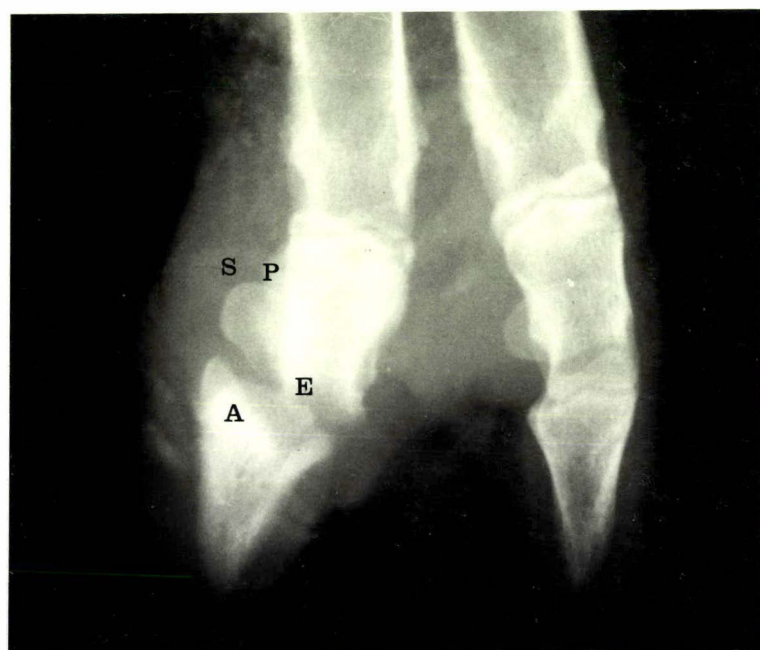
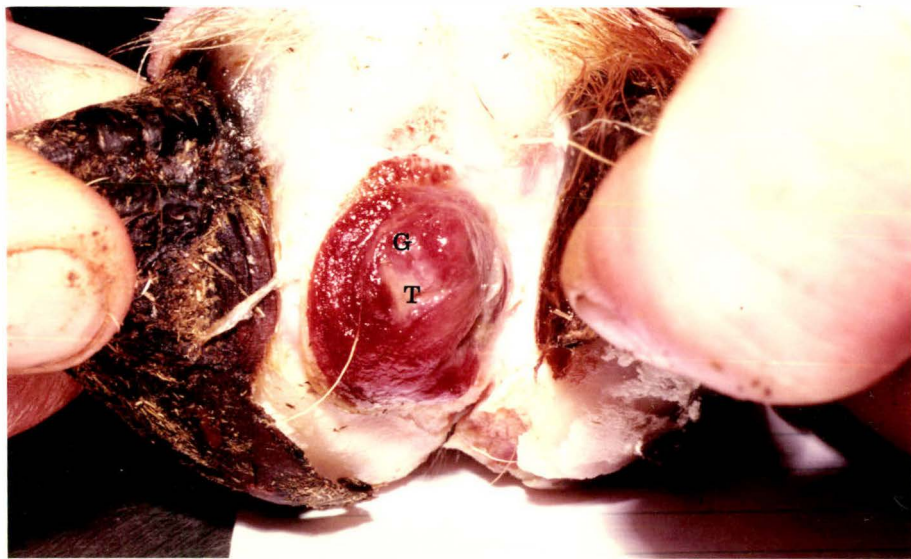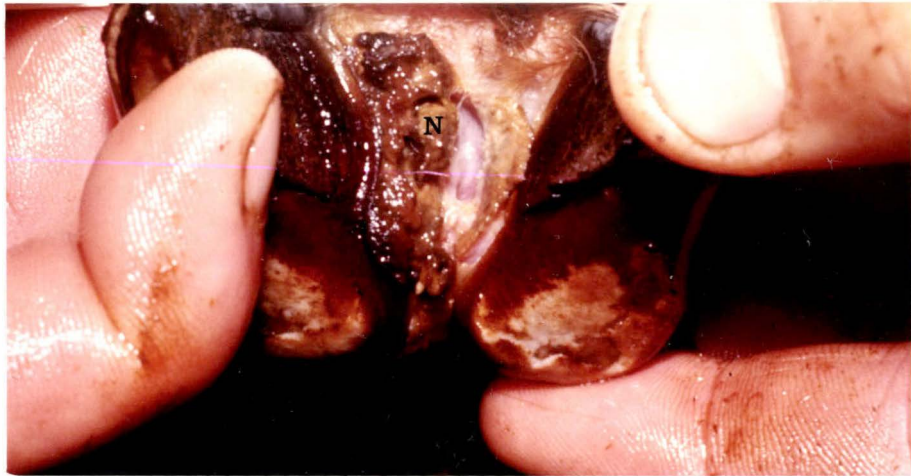


FIGURE 7.11 a, b and c

The left hind foot of sheep number 16, after the application of liquid nitrogen to the interdigital skin.

a) Day 9

N - necrotic tissue

b) Day 21 (immediately after slaughter)

N - necrotic bone

G - granulation tissue

L - ruptured axial common collateral
ligament

c) Day 21

E - erosion of bone

P - proliferation of bone

S - soft tissue swelling

A - abaxial displacement of the distal
phalanx and sesamoid

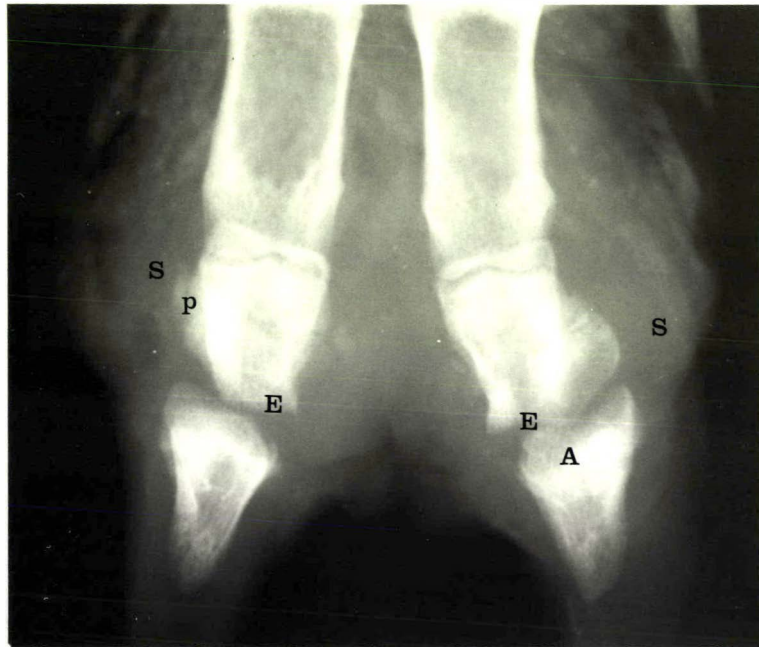
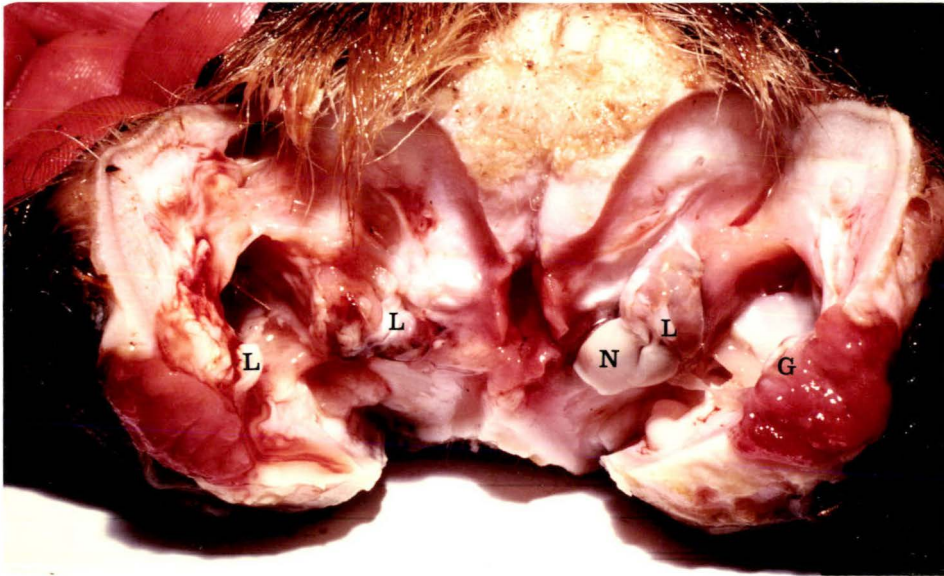
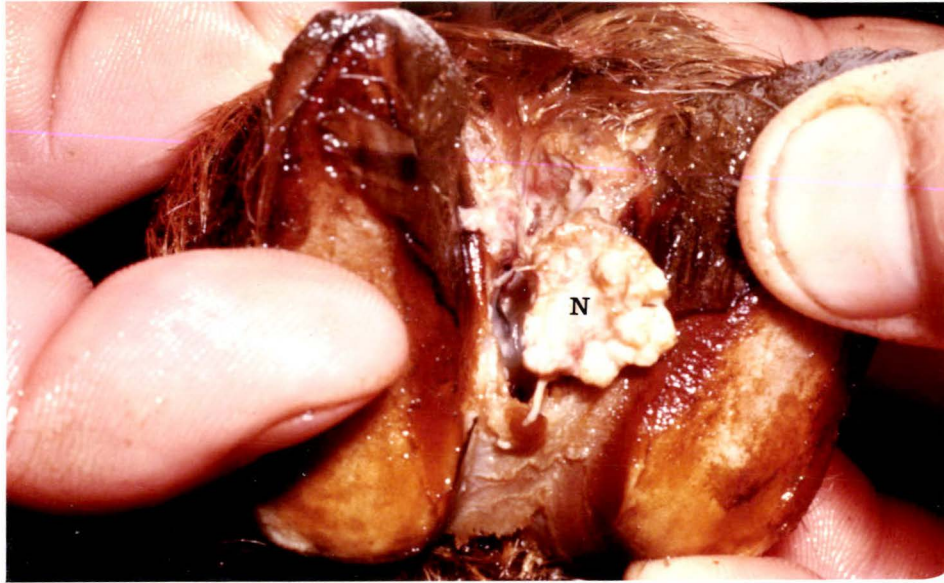


FIGURE 7.12a and b

The left hind foot of sheep number 15 after the application of liquid nitrogen to the interdigital skin.

a) Day 21 (immediately after slaughter)

G - granulation tissue

L - axial common collateral ligament
(transected)

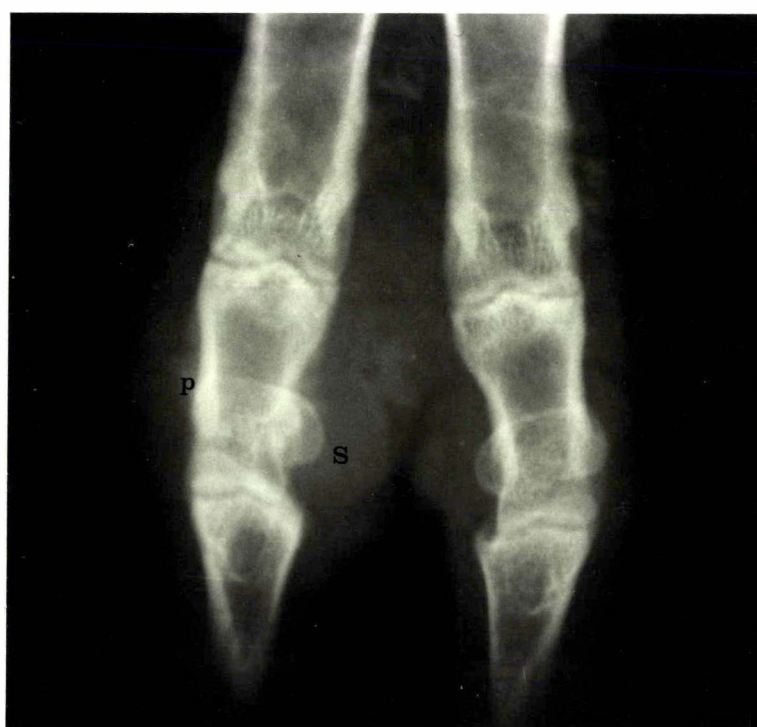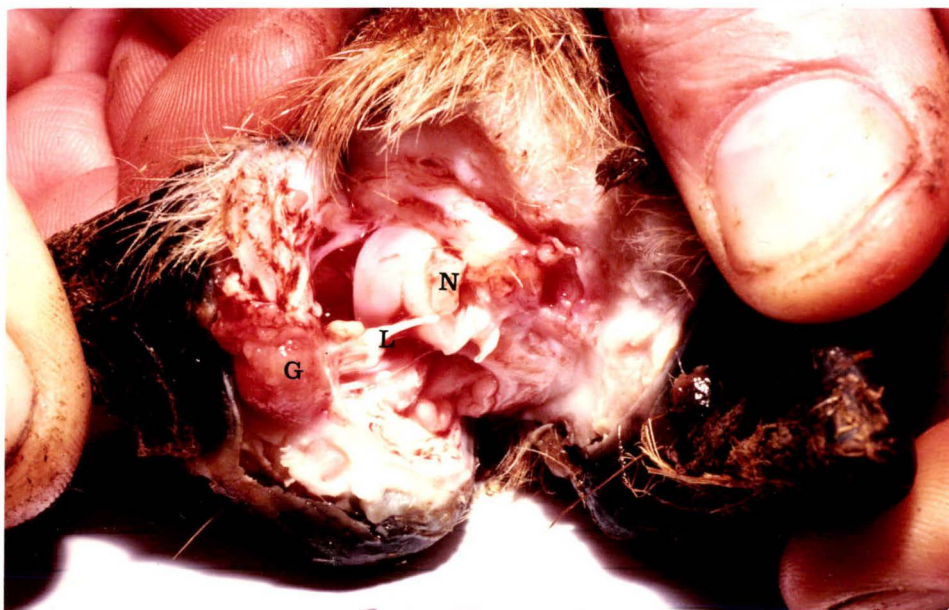N - necrotic bone

b) Day 21

S - soft tissue swelling

P - proliferation of bone

The radiographic changes indicate that the distal interphalangeal joint had been infected for approximately 9 days.



DISCUSSION

Reproduction of foot abscess

This later experiment confirmed the indications from the pilot trial that foot abscess can be readily reproduced by damaging the interdigital area with liquid nitrogen, thereby facilitating the multiplication and subsequent invasion of the distal interphalangeal joint by environmental bacteria, including *F. necrophorum* and *C. pyogenes*. The suggested pathogenesis is that freezing the interdigital tissues to ice, followed by thawing, resulted in a vascular deficiency in the area leading to tissue necrosis (Kreyberg, 1946). Bacteria from the environment, including *F. necrophorum* and *C. pyogenes* invaded this necrotic tissue and extended the area of tissue necrosis. Because of the proximity of the distal interphalangeal joint, infection reached the joint and once established, a relatively uniform series of events ensued, similar to that observed following direct intra-articular inoculation of *F. necrophorum* and *C. pyogenes* (chapter 6).

It is suggested that tissue damage following liquid nitrogen application, simulates ovine interdigital dermatitis. Although this might appear a rather extreme means of creating tissue damage, severe interdigital necrosis and erosion has been observed in naturally occurring cases of ovine interdigital dermatitis (chapter 5).

The reproduction of foot abscess by liquid nitrogen application to the interdigital space provides a more natural means of reproduction than direct joint inoculation of bacteria. Furthermore it may explain why damage to the interdigital space following the misuse of formalin (Littlejohn, 1972; Hooper and Jones, 1972) resulted in the development of foot abscess.

The effect of the underfoot conditions

The role of underfoot conditions in predisposing sheep to foot infections is well recognised (Murnane, 1933; Beveridge, 1934). Beveridge (1941) showed that normal healthy skin was relatively resistant to infection. Experimentally, interdigital skin damage sufficient to permit *F. necrophorum* to invade, has been provided by either continuous exposure of sheep's feet to water for three to four days (Egerton *et al.*, 1969), or by scarifying the interdigital skin (Parsonson *et al.*, 1967). In the experiment reported here, the combined effect of creating interdigital tissue damage with liquid nitrogen and exposure to wet faeces underfoot, facilitated the development of foot abscess. Although the underfoot conditions were created artificially, they were not dissimilar to what has been observed on farms during periods of high rainfall (Chapter 5). However exposure to the underfoot conditions alone did not result in foot abscess, which suggests that in naturally occurring cases interdigital tissue damage due to such things as sheep walking on stones, stubble or thistles, or friction between the digits may also play an important role.

The sheep were held in the underfoot conditions for 10 days after the initial interdigital damage; a shorter period than the 21 days incorporated in the pilot trial. It is possible that had the sheep been retained in the pen for a longer period, more digits might have developed foot abscess, as the interdigital area of most of the sheep still appeared susceptible to infection. However, all the treated sheep except number 10 were severely lame by this time and on humane grounds, dry conditions were provided.

The effect of site of damage

Damage with liquid nitrogen applied to the side of the interdigital space adjacent to the axial groove in the hoof wall, resulted in fewer cases of foot abscess than when the centre of the interdigital space was damaged (20 versus 8); this difference was statistically significant ($P < 0.05$). This is contrary to what was expected, as the joint capsule is more superficial close to the side of the interdigital space (chapter 3). However the site chosen on the side of the interdigital space may not have been the optimal one. The distal interphalangeal joint is protected at this point by two ligaments: the interdigital ligament and the axial common collateral ligament. Furthermore the horny wall immediately adjacent to the site, being more resistant to cold treatment, resulted in less damaged tissue than if the site was surrounded by vascular soft tissue. Had a site been chosen that was directly overlying either the dorsal or volar pouches of the joint capsule, it is possible that more joint infections would have occurred.

Applying the liquid nitrogen to the centre of the interdigital space resulted in 20 digits out of a possible 64 developing foot abscess, but in every instance it was the right digit of the foot that was affected. There should have been equal opportunity for either digit to develop foot abscess. However when the liquid nitrogen was applied to the interdigital area the sheep was tilted towards the operator, who was on the right side of the sheep. This resulted in the end of the funnel inadvertently favouring the right side of the interdigital space where more damage was created. This emphasises the importance of the site of tissue damage within the interdigital space in determining the subsequent development of foot abscess.

The effects of corticosteroid and bacterial cultures

The administration of corticosteroids and bacterial cultures resulted in no observable differences in the severity or type of lesion produced. Although more digits did develop foot abscess (16/32 compared with 12/32) the difference is not statistically significant. This is not surprising as it is likely that both *F. necrophorum* and *C. pyogenes* were present in the slurry anyway, and the attempts at immunosuppression were not particularly vigorous compared with those of Coyle-Dennis and Lauerman (1979).

CONCLUSIONS AND SUMMARY

1. Damaging the interdigital tissues of sheep by applying liquid nitrogen for 150 seconds, combined with wet faeces-contaminated underfoot conditions, allowed mixed organisms including *F. necrophorum* and *C. pyogenes* to infect the distal interphalangeal joint.

The foot condition produced was clinically and radiographically similar to naturally occurring cases of foot abscess.

2. The interdigital tissue damage following liquid nitrogen application was similar to that observed in some cases of ovine interdigital dermatitis.
3. Radiography of the foot provided a useful means of determining if, and when, the distal interphalangeal joint had become infected.
4. The site of tissue damage within the interdigital space was considered important in determining if infection was to reach the distal interphalangeal joint.

CHAPTER 8

SUMMARY AND CONCLUSIONS

From a radiographic study of naturally occurring cases of foot abscess, and from a study of the anatomy of the digits, it is concluded that foot abscess of sheep may be defined as an infection of the distal interphalangeal joint. Furthermore it is suggested that 'foot abscess' is a more appropriate term than 'infective bulbar necrosis' (Roberts *et al.*, 1968) because it conveys an appreciation of the suppurative nature of the lesion and is also distinct from the other important ovine condition, foot rot. Gregory (1939) proposed the two terms 'digital suppuration' and 'foot abscess' for the same condition, but it is the latter term that has been used most frequently.

A disadvantage of the term 'foot abscess' is the possible confusion that could arise in differentiating between toe abscess (suppuration of the lamellar region) and foot abscess. However these two conditions can be readily distinguished clinically, and careful use of terminology will overcome this disadvantage.

Roberts *et al.* (1968) advanced the view that foot abscess was a true mixed infection with *F. necrophorum* and *C. pyogenes*. This was based on the frequent isolation of both organisms from foot abscesses, the known mutually beneficial action between the two organisms and the distribution of morphologically similar organisms in stained sections of lesions of foot abscess. The study reported here supports their view in that both *F. necrophorum* and *C. pyogenes* were isolated frequently from cases of foot abscess and an identical condition could be reproduced by the inoculation of these two organisms into the distal interphalangeal joint of sheep. It appeared that relatively greater numbers of single species of either organism were required to reproduce foot

abscess by this means, than by using a mixture of the two organisms. Thus there is considerable evidence that *F. necrophorum* and *C. pyogenes* are the causative organisms of ovine foot abscess, but the possibility of other organisms playing an essential or supporting role cannot be dismissed.

It is apparent from replies received in the postal survey that in New Zealand, foot abscess occurs sporadically in most sheep flocks, and that the attack rate of foot abscess is higher for rams than for ewes. This latter conclusion was also supported by the case study in which 50 of the 53 sheep admitted to the Veterinary Hospital were rams. A possible explanation for this difference in attack rate attributed to sex, was provided from the investigation of an outbreak of ovine interdigital dermatitis and foot abscess (Chapter 5). The sexual behaviour of the rams in which large numbers congregated in one place, combined with the effects of periods of high rainfall, resulted in areas of pasture being trampled to a mixture of mud and faeces. In contrast, the ewes were spread evenly over the whole paddock. It is suggested that the behaviour pattern and sexual activity of rams, combined with periods of high rainfall, provides a set of circumstances in which foot damage and a grossly contaminated environment may work together to predispose them to interdigital dermatitis and thus to foot abscess.

The suggestion that foot abscess arises as a sequel to ovine interdigital dermatitis was first proposed by Egerton *et al.*, (1966). The anatomical study (Chapter 3) has demonstrated the vulnerability of the distal interphalangeal joint to infection or trauma on the interdigital aspect where the joint capsule protrudes above the coronary border of the hoof as the dorsal and volar pouches. Furthermore, interdigital tissue damage produced by the application of liquid nitrogen to the interdigital skin (Chapter 7), resulted in infection gaining entry to the distal interphalangeal joint, reproducing foot abscess. Naturally occurring ovine interdigital dermatitis was observed to vary in severity from

erythema and swelling of the interdigital skin as described by Parsonson *et al.* (1967), to erosion and suppuration of the interdigital tissues. It was this latter, more severe form of lesion, somewhat inadequately described by the term 'ovine interdigital dermatitis', which was observed to precede the occurrence of foot abscess. Thus there is considerable evidence that ovine interdigital dermatitis frequently precedes foot abscess.

If ovine interdigital dermatitis precedes foot abscess, it is logical that treatment should be initiated before the distal interphalangeal joint becomes infected. In the outbreak of lameness reported in Chapter 5, the lame sheep appeared to respond well to the combined therapeutic measures of dry surroundings, formalin foot-bathing and selected antibiotic therapy.

Once infection becomes established in the distal interphalangeal joint the above treatment is no longer effective, and a relatively uniform and thus predictable series of events takes place. Permanent joint damage and deformity is inevitable, but the effects of this can be minimized if the axial collateral ligaments remain intact. The anatomical study emphasized the important role that these ligaments play in maintaining the alignment of the phalanges. Therefore, therapy of foot abscess should be directed at maintaining the integrity of the ligaments. This can be done by drainage of the abscess, bandaging to prevent stress on the ligaments, and countering the bacterial infection by chemotherapy.

Although the prognosis for complete recovery from foot abscess is poor in most cases, the foot heals sufficiently to allow for adequate locomotion, after a period of about two months. Only in exceptional circumstances should the affected digit be amputated.

From the experimental reproduction of foot abscess and the use of radiography, it was possible to establish a time/change relationship by which the duration of joint involvement could be estimated. Infection must be present in the joint for at least seven days before radiographic joint changes are observed. Thus it is possible, using a radiographic technique, to assess if the infection has reached the distal interphalangeal joint, approximately when the infection reached the joint, and the likely degree of permanent damage and deformity.

Finally, as it has now been shown that foot abscess can be reproduced and studied radiographically, the way appears open for more objective therapeutic studies of the disease. These could include the testing of foot abscess vaccines, the use of various forms of general chemotherapy and local chemotherapy combined with joint protection techniques.

REFERENCES

- Abe, P.M.; Lennard, E.S.; Holland, J.W. (1976): *Fusobacterium necrophorum* infection in mice as a model for the study of liver abscess formation and induction of immunity. *Infect. Immun.* 13: 1473-1478.
- Abe, P.M.; Majeski, J.A.; Lennard, E.S. (1976): Pathological changes produced by *Fusobacterium necrophorum* in experimental infection of mice. *J. comp. Path.* 86: 365-369.
- Alexander, D.C.; Garcia, M.M.; McKay, K.A. (1973): Assessment of various adjuvants in *sphaerophorus necrophorus* toxids. *Can. vet. J.* 14: 247-250.
- Anon., (1969): Scald in Sheep. Members information supplement, *Vet. Rec.* 84: 18-20.
- Barone, R. (1968): *Anatomie compare's des mammiferes domestiques* 2nd. volume, Laboratoire D'anatomie Ecole nationale veterinaire, Lyon.
- Belschner, H.G. (1939): Foot-rot in sheep. *Aust. vet. J.* 15: 219-222.
- Berg, J.N.; Loan, R.W. (1975): *Fusobacterium necrophorum* and *Bacteroides melaninogenicus* as aetiologic agents of foot rot in cattle. *Am. J. vet. Res.* 36: 1115 - 1122.
- Bergey's manual of determinative bacteriology. 8th ed. Edited by R.E. Buchanan and N.E. Gibbons. The Williams and Wilkins Co., Baltimore, 1974.
- Beveridge, W.I.B. (1934): Foot-rot in sheep - skin penetration by *strongyloides* larvae as a predisposing factor. *Aust. vet. J.* 10: 43 - 51.

- Beveridge, W.I.B. (1941): Foot-rot in sheep: a transmissible disease due to infection with *Fusiformis nodosus* (n. sp.)
Bull. Aust. Counc. scient. ind. Res. Melb. No. 140.
- Blood, D.C.; Henderson, J.A. (1974): *Veterinary Medicine*,
4th ed. Baillière Tindall, London.
- Buxton, A.; Fraser, G. (1977): *Animal microbiology* Volume 1.
Blackwell scientific publications. Oxford, London,
Edinburgh, Melbourne.
- Cameron, C.M.; Fuls, W.J.P. (1977): Failure to induce in
rabbits effective immunity to a mixed infection of
Fusobacterium necrophorum and *corynebacterium pyogenes* with a
combined bacterin. *Onderstepoort J. vet. Res.* 44: 253-256.
- Clark, R.G. (1966): Malvern Farmers Veterinary Club,
1966 Survey.
- Cooper, B.S. (1966): Protection of lambs against tetanus.
N.Z. vet. J. 14: 186-90.
- Cooper, B.S. (1967): Contagious conjunctivo-keratitis
(C.C.K.) of sheep in New Zealand. *N.Z. vet. J.* 15: 79-84.
- Coyle-Dennis, Janice, E.; Lauerman, L.H. (1978): Biological
and biochemical characteristics of *Fusobacterium necrophorum*
leukocidin. *Am. J. vet. Res.* 39: 1790-1793.
- Coyle-Dennis, Janice, E.; Lauerman, L.H. (1979): correlations
between leukocidin production and virulence of two
isolates of *Fusobacterium necrophorum*. *Am. J. vet. Res.* 40:
274-276.
- Cross, R.F. (1978): Influence of environmental factors on
transmission of ovine contagious foot-rot. *J. Am. vet.
med. Ass.* 173: 1567-1568.

- Deane, H.M.; Davis, R.W.; Epling, G.P.; Jensen, R. (1955):
The anatomy of the integument of the ovine foot.
Am. J. vet. Res. 16: 197-202.
- Egerton, J.R.; Graham, N.P.H. (1969): Diseases causing
lameness in sheep. *Veterinary Review* No. 5, University of
Sydney Post-Graduate Foundation in Veterinary Science,
N.S.W.
- Egerton, J.R.; Parsonson, I.M.; Graham, N.P.H. (1968):
Parenteral chemotherapy of ovine foot-rot. *Aust. vet. J.*
44: 275-283.
- Egerton, J.R.; Roberts, D.S.; Graham, N.P.H.; Parsonson,
I.M. (1966): Ovine interdigital dermatitis and its
relationship to foot-rot and foot abscess. *Aust. vet. J.*
42: 440.
- Egerton, J.R.; Roberts, D.S.; Parsonson, I.M. (1969): The
aetiology and pathogenesis of ovine foot-rot. 1. a
histological study of the bacterial invasion. *J. comp.*
Path. 79: 207-216.
- Engel, A.E. (1953): cited by Parsonson *et al.*, (1967)
Proceedings of conference of veterinary officers on footrot and
other diseases of the feet of sheep, Young, 1953. Mimeo.,
McMaster annual Health laboratory; Sydney.
- Fales, W.H.; Warner, J.F.; Teresa, G.W. (1977): Effects of
Fusobacterium necrophorum leukotoxin on rabbit peritoneal
macrophages *in vitro*. *Am. J. vet. Res.* 38: 491-495.
- Garcia, M.M.; Alexander, D.C.; McKay, K.A. (1975):
Biological characterization of *Fusobacterium necrophorum* cell
fractions in preparation for toxin and immunization
studies. *Infect. Immun.* 11: 609-616.

- Garcia, M.M.; Charlton, K.M.; McKay, K.A. (1975):
Characterization of endotoxin from *Fusobacterium necrophorum*.
Infect. Immun. 11: 371-379.
- Garcia, M.M.; Dorward, W.J.; Alexander, D.C.; Magwood, S.E.;
McKay, K.A. (1974): Results of a preliminary trial with
Sphaerophorus necrophorus toxoids to control liver abscesses
in feedlot cattle. *Can. J. comp. Med.* 38: 222-226.
- Garcia, M.M.; Neil, D.H.; McKay, K.A. (1971): Application
of immunofluorescence to studies on the ecology of
sphaerophorus necrophorus. *Appl. Microbiol.* 21: 809-814.
- Gardner, D.E. (1961): Acute lameness in sheep caused by
Corynebacterium pyogenes. *N.Z. vet. J.* 9: 59.
- Graham, N.P.H.; Egerton, J.R. (1968): Pathogenesis of
ovine foot-rot: The role of some environmental factors.
Aust. vet. J. 44: 235-240.
- Greenough, P.R.; MacCallum, F.J.; Weaver, A.D. (1972):
Lameness in cattle. Oliver and Boyd, Edinburgh.
- Gregory, T.S. (1939): Footrot in sheep. *Aust. vet. J.* 15:
160-167.
- Hooper, R.S.; Jones, T.W. (1972): Corono-pedal abscessation
following the excessive use of formalin as a treatment
for foot-rot in sheep. *Vet. Rec.* 90: 697-699.
- Kreyberg, L. (1946): Tissue damage due to cold. *Lancet* 250:
338-340.
- Langworth, Barbara F. (1977): *Fusobacterium necrophorum*: Its
characteristics and role as an animal pathogen.
Bacteriol. Rev. 41: 373-380.

- Littlejohn, Annie I. (1972): The potential danger arising from the misuse of formalin in the treatment of foot-rot in sheep. *Vet. Rec.* 90: 693-697.
- Mantovani, A.; Restani, R.; Ricci-Bitti, G.; Sanguinetti, V; Biavati, S. (1974): Transmission of *sphaerophorus necrophorus* in sheep through *strongyloides papillosus* infective larvae. *Veterinaria Italiana*. 25: 122-132.
- May, N.D.S. (1970): *The anatomy of the sheep*. 3rd ed. University of Queensland Press, Queensland.
- Murnane, D. (1933): Footrot in sheep. *J. Coun. scient. ind. Res. Aust.* 6: 252-259.
- New Zealand meat and wool boards economic service, (1979): *Annual review of the sheep and beef industry, 1978/1979*. Publication no. 1813, Wellington.
- Nickel, R.; Schummer, A.; Seiferle, E. (1968): *Lehrbuch der anatomie der haustiere* Volume 1 Paul Parey, Berlin and Hamburg.
- Parrillo, J.E.; Fauci, A.S. (1979): Mechanisms of glucocorticoid action on immune processes. *Ann. Rev. Pharmacol. Tonicol.* 19: 179-201.
- Parsonson, I.M.; Egerton, J.R.; Roberts, D.S. (1967): Ovine interdigital dermatitis. *J. comp. Path.* 77: 309-313.
- Pryor, W.J. (1959): Two foot syndromes in sheep following excessive foot bathing. *Aust. vet. J.* 35: 493-494.
- Roberts, D.S. (1967a): The pathogenic synergy of *Fusiformis necrophorus* and *Corynebacterium pyogenes*. 1. Influence of the leucocidal exotoxin of *F. necrophorus*. *Br. J. exp. Path.* 48: 665-673.

- Roberts, D.S. (1967b): The pathogenic synergy of *Fusiformis necrophorus* and *Corynebacterium pyogenes*. II. The response of *F. necrophorus* to a filterable product of *C. pyogenes*. *Br. J. exp. Path.* 48: 674-679.
- Roberts, D.S. (1969): Synergic mechanisms in certain mixed infections. *J. infect. Dis.* 120: 720-723.
- Roberts, D.S. (1970): Toxic, allergenic and immunogenic factors of *Fusiformis necrophorus*. *J. comp. Path.*, 80:247-257.
- Roberts, D.S.; Egerton, J.R. (1969): The aetiology and pathogenesis of ovine foot-rot. II. The pathogenic association of *Fusiformis nodosus* and *F. necrophorus*. *J. comp. Path.* 79: 217-227.
- Roberts, D.S.; Graham, N.P.H.; Egerton, J.R.; Parsonson, I.M. (1968): Infective bulbar necrosis (Heel-abscess) of sheep, a mixed infection with *Fusiformis necrophorus* and *Corynebacterium pyogenes*. *J. comp. Path.* 78: 1-7.
- Simon, P.C.; Stovell, P.L. (1969): Diseases of animals associated with *Sphaerophorus necrophorus*: characteristics of the organism. *Vet. Bull. Lond.* 39: 311-315.
- Simon, P.C. (1977): Susceptibility of *Fusobacterium necrophorum* to antimicrobials, Part 1: as determined by the disc method. *Can. J. comp. Med.* 41: 166-168.
- Sisson, S; Grossman, J.D. (1966): *The anatomy of the domestic animals*. 4th ed. W.B. Saunders company, Philadelphia and London.
- Snowdon, W.A. (1953): cited by Parsonson *et al.*, (1967) *Proceedings of conference of veterinary officers on footrot and other diseases of the feet of sheep*, Young, (1953). Mimeo., McMaster Animal Health Laboratory; Sydney.

- Thomas, J.H. (1962): The differential diagnosis of footrot in sheep. *Aust. vet. J.* 38: 159-163.
- Verschooten, F.; De Moor, A. (1974): Infectious arthritis in cattle: a radiographic study. *J. Am. vet. rad. Soc.* 15: 60-69.
- Verschooten, F.; De Moor, A.; Steenhaut, M.; Desmet, P.; Wouters, L.; De Ley, G. (1974): Surgical and Conservative treatment of infectious arthritis in cattle. *J. Am. vet. med. Soc.* 165: 271-275.
- Warner, J.F.; Fales, W.H.; Teresa, G.W. (1974): Passive hemagglutination test for determining the immune response of rabbits to *sphaerophorous necrophorus* of bovine hepatic abscess origin. *Am. J. vet. Res.* 35: 551-554.
- Williamson, G.T. (1953): Foot abscess in sheep. *N.Z. vet. J.* 1: 128.