

NOVEL VIRUSES

Update on the significance of papillomavirus infections in cats



John S Munday, Claire R Sharp and Julia A Beatty

Papillomaviruses

Papillomaviruses (PVs) are small, non-enveloped, icosahedral, double-stranded DNA viruses. Most animals are infected by PVs and hundreds of different PV types are recognised.¹ Five different *Felis catus* papillomavirus (FcaPV) types are currently known to infect domestic cats including: FcaPV-1, a lambdapapillomavirus; FcaPV-2, a dyothetapapillomavirus; and FcaPV-3, -4 and -5, which probably form their own separate PV genus.² Cats are also dead-end hosts for *Bos taurus* papillomavirus (BPV)-14, a deltapapillomavirus.³

Virus discovery

- ❖ PVs were first reported as having a role in feline skin disease in 1990 when PV virions were observed in a cutaneous plaque.⁴ The PV present within the plaque was fully sequenced and classified as FcaPV-1 in 2002.⁵
- ❖ PVs were first associated with Bowenoid in situ carcinomas (BISCs) in 1997 after PV antigens were detected in around half of BISCs by immunohistochemistry.⁶ In 2007, PCR was used to amplify PV DNA from 11/18 BISCs, and revealed that the same PV type was present in most BISCs.⁷ This PV type was fully sequenced and classified as FcaPV-2 in 2009.⁸
- ❖ FcaPV-3 was amplified from a feline BISC in 2013.⁹
- ❖ FcaPV-4 was amplified in 2014 from an oral swab of a cat that showed no clinical lesions attributed to the PV infection.¹⁰
- ❖ FcaPV-5 was amplified from a viral plaque in 2017.² This viral plaque was unusual because PV infection had resulted in marked hyperplasia of the sebaceous glands and evidence of PV infection was visible close to the base of the hair follicles.¹¹
- ❖ A role for PVs in feline sarcoids was first proposed in 2001.¹² Subsequent studies revealed that all tested feline sarcoids contained the

Practical relevance: Prior to 1990 papillomaviruses (PVs) were not recognised to infect or cause disease in domestic cats. Since this time, the use of histology, immunohistochemistry and, more recently, molecular techniques has revealed that PVs almost certainly cause feline viral plaques and Bowenoid in situ carcinomas, oral papillomas and feline sarcoids. In addition, there is increasing evidence that PVs play a significant role in the development of feline cutaneous squamous cell carcinomas, one of the most common skin cancers of cats. Recent studies have also revealed that most cats are asymptotically infected with PVs. This raises a critical question that is currently unanswered: why do only a small proportion of infected cats develop disease? In the future it may be possible to prevent PV-induced diseases by using a vaccine to prevent PV infection. Alternatively, novel therapies may be developed that prevent PVs from causing clinical disease by stimulating the host immune response.

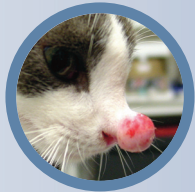Clinical challenges: A recognition of the skin diseases caused by PVs is important to more accurately predict disease progression. Unfortunately, there are currently no non-surgical treatments that have been proven to be beneficial in cats and clinical management of PV-induced skin disease in cats can be challenging.

Global importance: PVs have a worldwide distribution and negatively impact feline health and welfare globally.

Audience: This review is aimed at clinicians, especially those who regularly treat cats with skin disease. The review will also be useful to oncologists and researchers who have an interest in how cancer develops in cats.

Evidence base: In producing this update the authors have drawn on recently published peer-reviewed literature.

Keywords: Virus; papillomavirus; viral plaque; Bowenoid in situ carcinoma; skin cancer



John S Munday*
BVSc, PhD, Dipl ACVP
School of Veterinary Science,
Massey University,
Palmerston North, 4410 New Zealand

Claire R Sharp
BSc, BVMS(Hons), MS, DACVECC
College of Veterinary Medicine,
School of Veterinary and Life Sciences,
Murdoch University, Australia

Julia A Beatty
BSc, BVetMed, PhD, FANZCVS, MRCVS
University of Sydney, Faculty of Science,
Sydney School of Veterinary Science,
NSW 2006, Australia

*Corresponding author: j.munday@massey.ac.nz

same 'FeSarPV' viral sequence,¹²⁻¹⁴ which was determined to be of bovine origin and classified as BPV-14 in 2015.³

While six PV types are currently recognised to infect cats, evidence from other species suggests that cats are likely to be infected with many additional PV types that have yet to be recognised.

Epidemiology

PVs have co-evolved with their hosts over a long time. As the host and virus are in such good balance the vast majority of PV infections in all species are asymptomatic.

In cats, the majority of the research into the epidemiology of PV infections has focused on FcaPV-2. Such studies have revealed that almost all cats are infected with FcaPV-2.¹⁵ Additionally, FcaPV-2 is detectable in very young kittens, suggesting that, like some cutaneous human papillomavirus (HPV) types, infection occurs around the time of birth.¹⁶ Transplacental infection by FcaPV-2 may also be possible.¹⁷ While almost all cats are infected by FcaPV-2, most infections do not induce a humoral response and serum antibodies against this PV type are only detectable in around a quarter of cats.¹⁸

With the important exception of the delta-papillomaviruses, such as BPV-14, PVs are strictly host-specific.¹⁹ Therefore, while HPV DNA has been amplified from feline samples,²⁰ sample contamination appears the most likely explanation, and current evidence suggests that HPVs are unlikely to infect cats and feline PVs are unlikely to infect people.

Feline sarcoids are thought to be caused by cross-species infection by BPV-14 and this PV has never been detected in any non-sarcoïd feline sample.^{13,21} Unsurprisingly, feline sarcoïds are restricted to cats that have contact with cattle.



Feline sarcoïds are restricted to cats that have contact with cattle.



Most cats are asymptotically infected by papillomaviruses (PVs). This raises a critical question that is currently unanswered: why do only a small proportion of infected cats develop disease?

Diseases associated with papillomaviruses in cats

PVs infect stratified epithelium and the life cycle of the virus is intimately associated with the progression of cells from the basal to the superficial cell layers.²² A fundamental property of PVs is that viral replication is dependent on stimulating cell division within normally post-mitotic keratinocytes. Additionally, the greater the increase in keratinocyte cell division induced by the virus, the greater the number of viral particles that will be produced as a result of the infection.²² All PVs produce proteins that alter normal cell regulation, and the diseases caused by PVs in cats (Table 1) are all due to increased cell replication and growth.

Occasionally in cats, PVs are able to induce a rapid, albeit transient, increase in cell replication that results in a self-resolving hyperplastic papilloma (wart);²⁰ however, more frequently, PVs cause more modest cell replication that leads to the development of a raised plaque. The increased replication of cells within the plaque results in an increased rate of DNA mutations in these cells, predisposing to neoplastic transformation. Whether PVs directly cause DNA mutations in infected cells of cats is currently unknown. Unlike the human high-risk PVs that are well recognised to cause neoplasia by accidental integration into the cellular DNA,²³ there is currently no

Table 1 Summary of diseases that have been evaluated for a potential papillomavirus (PV) aetiology in cats

Disease	Associated PV types	Strength of association	Histological evidence of PV infection†	p16 ^{CDKN2A} protein immunostaining expected†
Viral plaque/Bowenoid in situ carcinoma	FcaPV-2, -3, -5	High	Yes	Yes
Cutaneous squamous cell carcinoma	FcaPV-2	Moderate	No	Yes
Basal cell carcinoma	FcaPV-3	Unknown*	Yes	Yes
Oral papilloma	FcaPV-1	High	Yes	Yes
Oral squamous cell carcinoma	None	Minimal	No	No
Feline sarcoïd	BPV-14	High	No	No


FcaPV = *Felis catus* papillomavirus; BPV = *Bos taurus* papillomavirus

*Although some basal cell carcinomas (BCCs) are strongly associated with PV infection in cats, the proportion of BCCs that are associated is unknown

†Immunostaining is expected to be present in lesions that are thought to be caused by PVs. For example, not all squamous cell carcinomas contain evidence of a PV aetiology, but those putatively caused by PVs will consistently contain p16^{CDKN2A} protein immunostaining

Case notes

A 3-year-old castrated male domestic shorthair cat was presented due to the development of three small raised non-ulcerated plaques within non-pigmented skin on the right side of the muzzle. The lesions were initially pink, but became darker over a period of about a week.

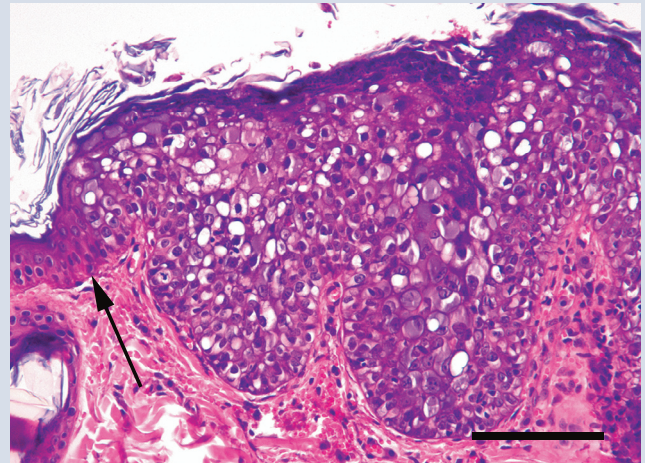


Multiple viral plaques (arrows) appearing as hairless foci within the non-pigmented skin of the right side of the face

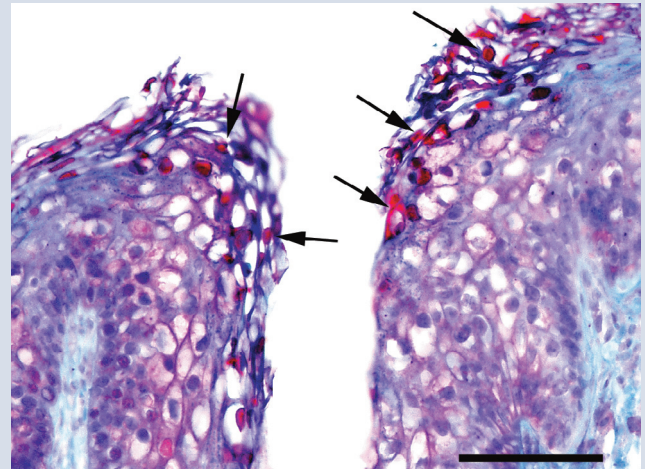
Treatment The lesions were treated for 4 weeks with an antibacterial and anti-inflammatory ointment without any clinical improvement. No treatment was given for the next 3 weeks. The lesions did not appear to change significantly during this time. Antibodies against FIV were detected in a blood sample, although the cat was not showing any overt evidence of generalised immunosuppression.

Histology A punch biopsy of one lesion was taken and examination revealed a well-demarcated focus of moderate hyperplasia of the surface epidermis and, to a lesser extent, the follicular infundibula. There was no cellular atypia or loss of orderly keratinocyte maturation. Keratinocytes that contained large amounts of blue-grey cytoplasm were prominent within the thickened epidermis. The lesion was considered consistent with a viral plaque. As the lesion contained histological evidence of PV replication, immunohistochemistry to detect PV L1 antigen was performed. This revealed the presence of intranuclear immunostaining within cells of the stratum corneum overlying the hyperplastic epidermis. The presence of FcaPV-2 DNA within the lesion was confirmed using JMPF/JMPR primers, which are specific for this PV type.²⁸

Follow-up No further treatment was administered. The plaques persisted for 12 months without any noticeable change in appearance. They then spontaneously resolved and no additional PV-associated skin lesions had developed at the time of writing.



Photomicrograph of a viral plaque. Hyperplasia of the surface epidermis and the follicular infundibula is visible. The interface between normal and hyperplastic epidermis is clearly defined (arrow). Orderly keratinocyte maturation is retained within the plaque. Note the presence of numerous cells containing PV-induced expansion of the cytoplasm with blue-grey material. Haematoxylin and eosin (H&E). Bar = 70 µm



Photomicrograph of a viral plaque. The use of anti-PV antibodies reveals immunostaining within keratinocyte nuclei (arrows) in the superficial layers of the epidermis. Streptavidin-biotin-peroxidase complex system and Mayer's hematoxylin. Bar = 40 µm

✚ **What this case demonstrates:** Not all PV-induced lesions progress and some lesions can spontaneously regress without treatment. While this cat was infected with FIV, there is no evidence to suggest that retrovirus infection influenced the development or clinical course of the disease.

The three images in this 'Case notes' discussion were reproduced, with permission, from Munday JS et al, *Vet Dermatol* 2008; 19: 400-404.

evidence that FcaPV DNA becomes integrated. Therefore, it may simply be that the chronically increased cell replication and altered cell regulation caused by the PVs predispose to the accumulation of spontaneous mutations and subsequent neoplastic transformation. Additionally, PV infection could act as a co-factor, potentiating the effect of other carcino-

gens such as ultraviolet (UV) light.^{24,25}

Most cats are infected by PVs, but PV-induced disease is rare.¹⁵ This suggests that a key process in the pathogenesis of these diseases is the inability of the host defences to inhibit PV replication. Without inhibition of replication by the host, the PV is able to induce marked epithelial proliferation. If

this epithelial proliferation results in the development of a clinically visible lesion, the infection will progress from an asymptomatic to a clinical infection.²⁶ Currently, the mechanisms that might lead to reduced defences are poorly understood and cats with seemingly normal immune systems can develop PV-induced disease. While coinfection by feline immunodeficiency virus (FIV) has been reported in some cases of PV-induced skin disease in cats,²⁷ there is currently little evidence for a significant role of either FIV or feline leukaemia virus in disease development (see 'Case notes' on page 411).

Feline viral plaques/Bowenoid in situ carcinomas

While initially thought to be separate disease entities, viral plaques and BISCs are probably best considered mild and severe forms of the same disease process.^{26,29} These rare lesions are pre-cancerous and can progress to invasive squamous cell carcinomas (SCCs), although the proportion of lesions that remain static vs the proportion that progress is currently unknown.

Viral plaques/BISCs typically develop on cats between the ages of 8 and 14 years.²⁹ They most frequently appear around the face, head and neck, although they can be found anywhere on the body. Lesions are often multiple and pigmented, and can develop within pigmented or non-pigmented, haired or non-haired skin.²⁹ Viral plaques are generally less than 1 cm in diameter, slightly raised, hairless lesions covered in a thin crust. BISCs are larger and are typically markedly raised ulcerated lesions covered by a significant serocellular crust or a thick layer of keratin.

FcaPV-2 is the predominant cause of feline viral plaques/BISCs, although FcaPV-3 and FcaPV-5 have also been associated with lesion development (Table 1).^{2,30,31} Devon Rex and the closely related Sphynx breeds of cat appear to develop BISCs at an earlier age than other breeds, and the BISCs that develop in these cats tend to be highly aggressive and can rapidly metastasise (see 'Case notes' on page 413).^{32,33}

Cutaneous squamous cell carcinomas

SCCs are one of the most common skin cancers of cats and, while the role of UV light in cancer development cannot be disputed, there is increasing evidence that FcaPV-2 may



Current evidence suggests that PVs could be the primary cause, or a cofactor in the development, of between a quarter and a third of all feline cutaneous squamous cell carcinomas (SCCs).



Devon Rex and Sphynx cats appear to be predisposed to rapidly progressing Bowenoid in situ carcinomas and the resultant invasive SCCs also demonstrate high metastatic potential.

also cause SCC development. This evidence includes the detection of PV DNA more frequently in SCCs than in non-SCC skin samples,^{28,34} the detection and localisation of FcaPV-2 RNA within a proportion of SCCs but not samples of normal skin,³⁵ and the demonstration that FcaPV-2 proteins can influence neoplastic transformation of a cell.^{24,36} In addition, p16^{CDKN2A} protein (p16) immunostaining (see later) is visible in a proportion of SCCs.^{37,38}

The use of PCR and immunohistochemistry allows feline cutaneous SCCs to be subdivided into PV-positive and PV-negative lesions. Current evidence suggests that around 80% of SCCs from areas of the body protected from UV exposure are caused by PV infection.³⁴ UV light is a well recognised cofactor in PV-induced cutaneous cancers in people.³⁹ It appears probable that the same is true for cats and current evidence suggests that PVs could be the primary cause, or a cofactor in the development, of between a quarter and a third of all feline cutaneous SCCs.^{35,36}

Basal cell carcinomas

A potential role of PVs in the development of basal cell carcinomas (BCCs), which are rare feline skin neoplasms, was first proposed after PV-induced cell changes were noted in the epidermis overlying a proportion of neoplasms.⁴⁰ More recently, feline BCCs that contain PV-induced cell changes within the neoplastic cells have been reported and both FcaPV-3 and a novel feline PV type have been amplified from these tumours.^{41,42} Interestingly, FcaPV-2 has not been detected within a BCC.

Although typically these are single ulcerated raised lesions, a cat with multiple cutaneous PV-associated BCCs has been reported.⁴² Currently too few feline cutaneous BCCs have been evaluated to determine what proportion are associated with PV infection and whether, like SCCs, they can be subdivided into PV-positive and PV-negative lesions.

Oral papillomas

There are few reports of oral papillomas in cats, although the true incidence is unknown as these are self-resolving lesions and do not cause dysphagia. They typically appear as multiple exophytic filiform masses on the ventral surface of the tongue. Histologically they contain prominent virally induced changes and are thought to be caused by FcaPV-1.⁴³

Oral squamous cell carcinomas

Oral SCCs are the fourth most common neoplasm of cats and an important cause of mortality. While bacterial toxins released into the mouth due to poor dental hygiene are hypothesised to promote cancer development, the cause of the high rate of oral SCCs in cats has not been

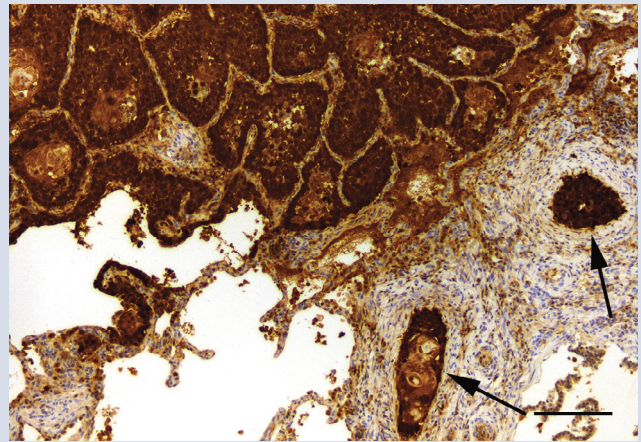
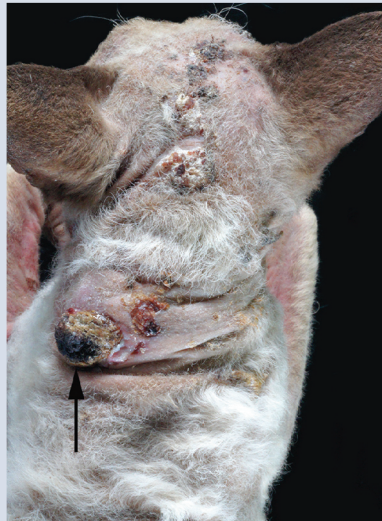Case notes

An 8-year-old spayed female seal point Devon Rex cat was presented due to the development of approximately 10 crusting, 0.5–1 cm diameter lesions that were predominantly on the head.

Histology Three lesions were surgically excised and submitted for histological examination. This revealed moderate to marked epidermal hyperplasia with extension to the follicular infundibula. Crowding of the basal cells and moderate atypia of keratinocytes was visible in all three sampled lesions. In addition, invasion of the basement membrane was visible in one of the lesions. None of the lesions contained any PV-induced cell changes. Histology of two lesions was consistent with advanced BISC, while the other was consistent with an invasive SCC.

Due to the presence of large numbers of lesions, surgical excision of the remaining lesions was not considered possible and no treatment was given.

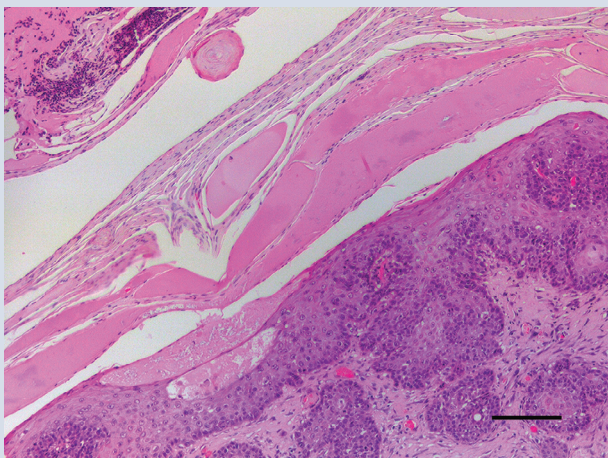
Progression Over the next 8 months the existing lesions increased in size and additional lesions developed. Examination at this time revealed approximately 30 dark sessile masses that ranged in size from 0.5–3 cm in diameter. The majority were over the dorsum, extending from the head to the tail base; smaller numbers of masses were also present on the face of the cat. The largest mass was within the interscapular region and was slightly raised and covered by a thick layer of dense keratin. At this time the cat became depressed and anorexic, and was euthanased.



Photomicrograph of metastatic foci within the lungs of a cat with multiple cutaneous BISCs. The neoplastic cells contain intense nuclear and cytoplasmic immunostaining using anti-p16^{CDKN2A} protein (p16) antibodies. Multiple emboli containing epithelial cells with p16 immunostaining are visible within the pulmonary arteries (arrows). Bar = 40 µm

Post-mortem findings Samples of the skin masses again revealed a mixture of BISCs and invasive SCCs, and PCR using specific primers showed the presence of FcaPV-2 in 2/4 skin lesions tested. As there were no virally induced cell changes, immunostaining using anti-PV antibodies was not attempted. However, intense p16 immunostaining was present within the neoplastic cells of the lesions that contained PV DNA.

Multiple BISCs are visible predominantly over the dorsum of the cat. The lesions are variably pigmented and appear as a thickened area of skin covered by a keratin crust. The largest lesion (arrow) was covered in a thick plate of adherent keratin that could easily be removed to reveal an underlying sessile hyperaemic area



Photomicrograph of a BISC. Thickening of the epidermis by a population of neoplastic cells is visible. Neoplastic cells are observed extending into follicles, but are also present infiltrating the underlying dermis. The hyperplastic epidermis is covered by a thick plate of keratin. H&E. Bar = 70 µm

In addition to the skin masses, multiple pale masses, up to 1 cm in diameter, which were particularly numerous within the caudal lung lobes, were seen on necropsy examination. Histology revealed that these were intravascular SCCs. FcaPV-2 DNA was amplified from the metastatic neoplasms and the neoplastic cells contained intense p16 immunostaining.

✦ What this case demonstrates: BISCs appear to be more likely to have an aggressive clinical course in Devon Rex and Sphynx cats. This case illustrates the rapid progression and subsequent metastasis of these lesions in a Devon Rex.

The three images in this 'Case notes' discussion were reproduced, with permission, from Munday JS et al, *Vet Dermatol* 2016; 27: 215–e55.

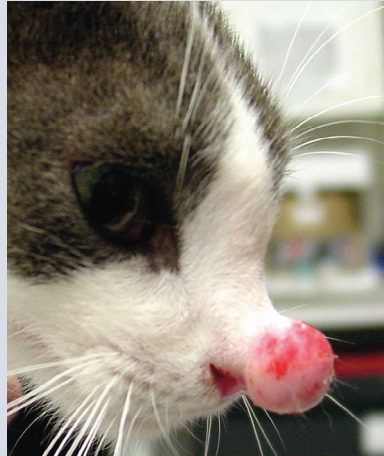
Case notes

A young adult female domestic shorthair cat was observed to have a 5 mm diameter cone-shaped mass growing dorsally from the bridge of the nose close to the junction with the nasal planum.

History The cat had recently been adopted after previously living in a dairy barn in New York State, USA with approximately 20 other cats. An intralesional injection of cisplatin had been given, but the mass continued to grow over the next few weeks.

Diagnosis The mass was surgically excised and a presumptive diagnosis of feline sarcoid was made by histology.

As sarcoids do not contain replicating virus, no PV-induced cell changes were visible and immunohistochemistry using anti-PV antibodies was not attempted. Likewise, immunohistochemistry to detect p16 was not performed as deltapapillomaviruses cause neoplasia by mechanisms that do not increase cell p16. PCR was performed using the MY09/11 consensus primers,⁴⁷ and sequencing of the resultant amplicon revealed the presence of BPV-14 DNA.



Feline sarcoid visible as a protruding nasal mass

PCR using the specific jmpSA-F/-R primers also amplified BPV-14 DNA.¹³ As BPV-14 does not appear to produce asymptomatic infections in cats, its detection confirmed a diagnosis of feline sarcoid.

Progression Sarcoid regrowth was observed shortly after surgery and imiquimod cream was applied to the mass every 2 days for 2 weeks. Imiquimod treatment did not have any detectable effect and the sarcoid continued to grow slowly. An additional surgery was performed 12 months later to debulk the mass. Neoplasm recurrence was observed shortly after this surgery and euthanasia was performed 2 months later when the sarcoid began to interfere with eating.

✦ **What this case demonstrates:** This case illustrates the requirement for molecular techniques to make a definitive diagnosis of feline sarcoid. In addition, the invasive growth of a sarcoid can make complete excision difficult, predisposing to local tumour recurrence. No non-surgical treatments have yet been shown to be beneficial.

The image in this 'Case notes' discussion was reproduced, with permission, from Munday JS et al, *Vet Microbiol* 2015; 177: 289–295.

definitively determined.⁴⁴ Around a quarter of human oral SCCs are thought to be caused by PV infection.⁴⁵ However, while PV DNA sequences have been detected in a small proportion of feline oral SCCs,^{31,46} there is currently no evidence that PVs cause feline oral SCCs.

Feline sarcoids

As the causative PV has a bovine definitive host, feline sarcoids are restricted to cats with outside access in rural areas and appear to be most common in cats that live in dairy barns.¹² Fighting is hypothesised to be important in allowing the PV entry into the dermis and sarcoids are more common in male cats.¹²

Feline sarcoids typically develop around the face, especially the nasal philtrum, although they can also develop on the extremities and tail. Like equine sarcoids, these are mesenchymal neoplasms and histology reveals a proliferation of dermal mesenchymal cells covered by hyperplastic epithelium. PV DNA is present within the proliferating mesenchymal cells,¹⁴ but as feline sarcoids do not support viral replication, they do not contain histological evidence of PV infection. Their behaviour is similar to equine sarcoids, with local invasion and frequent recurrence

following surgical excision (see 'Case notes' above), but no metastatic potential.

Confirmation of diagnosis

Many SCCs of the pinnae and nasal planum are diagnosed on clinical examination. However, tissue scraping and cytology is always recommended to confirm the diagnosis. Diagnosis of the other skin lesions that have been associated with PV infection in cats can be more difficult and requires histological examination (see page 415) for confirmation. Distinguishing between a viral plaque/BISC and an SCC is important, as viral plaques/BISCs remain confined within the epidermis and so cannot invade or metastasise. In contrast, the presence of invasion of the epithelial basement membrane defines an SCC and such neoplasms typically rapidly invade surrounding tissue, making complete excision more difficult.

The development of an exophytic non-ulcerated mass around the nasal philtrum of a cat is suggestive of a feline sarcoid. Histology reveals a proliferation of fibroblasts and hyperplasia of the overlying epidermis. While clinical presentation and histology can strongly support a diagnosis of feline sarcoid, the identification of deltapapillomavirus DNA within the lesion using molecular techniques is required for definitive diagnosis.

Distinguishing between a viral plaque/BISC and an SCC is important, as viral plaques/BISCs remain confined within the epidermis and so cannot invade or metastasise.

Investigation of a papillomavirus aetiology

Histology

Histology can reveal PV-induced cell changes (enlarged keratinocytes with smudged blue-grey cytoplasm or with a shrunken nucleus surrounded by a clear halo [koilocytes]) within some lesions and their presence can be a useful diagnostic feature. Such cell changes occur as a result of PV replication within a cell and are expected to be visible in recently developed viral plaques/BISCs, oral papillomas and a proportion of BCCs. Viral replication does not occur in feline sarcoids or in the less well-differentiated cells of an advanced BISC or SCC, and PV-induced cell changes are not expected to be present in these lesions.

If histological evidence of PV-induced cell changes is not present within a lesion, there are other methods available to investigate a potential PV aetiology – notably immunohistochemistry and molecular techniques.

Evidence from other species suggests that cats are likely to be infected with many additional PV types that have yet to be recognised.



Clinical relevance of determining PV causation

Determining whether or not a lesion was caused by a PV can have clinical relevance. For example, differentiation between a solar-induced actinic in situ carcinoma and a viral plaque/BISC is important due to differences in the expected disease progression and in the ways that can be used to try to prevent the development of additional lesions. Further, studies have suggested that PV-positive SCCs may have a less aggressive clinical course and a more favourable prognosis than PV-negative SCCs.³⁸ However, it should be noted that there are currently no specific therapies for the treatment of PV infection in cats.

Immunohistochemistry

Immunohistochemistry has the advantage of being able to be performed at most veterinary or human diagnostic laboratories. Options available for immunohistochemistry include using antibodies to detect either the presence of PV L1 protein or increased p16 within the cell. The PV L1 protein forms the capsid that surrounds the viral particle. This protein is targeted because large amounts are produced in the process of viral replication. The disadvantage of using antibodies against the L1 protein is that this protein is only produced late in the process of viral replication. Therefore, if no viral replication is present, no immunostaining will be visible. Viral replication appears to be rarely present in advanced BISCs and in PV-positive SCCs and, in the authors' experience, PV L1 protein immunostaining is rarely present in lesions that do not contain histologically visible PV-induced cell changes. An additional disadvantage of using antibodies against the PV L1 protein is that it is unknown if the commercially available anti-

bodies, which have generally been created using human or bovine PV antigens, are able to cross-react with the L1 protein of the different FcaPV types.

Human diagnostic laboratories rarely use anti-PV antibodies to determine a PV aetiology of a neoplasm. Instead, to differentiate between a PV-positive oral SCC and a PV-negative oral SCC they will typically use immunohistochemistry to detect increased cell p16.⁴⁸ Cancers that are caused by PVs consistently contain increased p16 because PVs consistently promote cell replication by altering pathways that also increase p16.⁴⁹ This differentiation is of critical clinical importance for human oral SCCs because PV-positive neoplasms are more likely to respond to treatment and have a more favorable prognosis than PV-negative cancers.⁵⁰ In cats, studies have shown good correlation between the presence of increased p16 within the neoplastic cells and the presence of PV DNA or RNA within the neoplasm (Figure 1).^{36,37}

Advantages of using p16 immunostaining to determine a PV aetiology in a feline lesion include a consistent increase in the protein regardless of whether or not the PV is replicating and the known cross-reactivity of the anti-human G175-405 p16 clone antibodies to the feline p16 protein. However, the specificity of this test for a PV aetiology in cats has not been definitively shown and it remains possible that spontaneous mutations within a cell's DNA could also result in increases in p16 that are independent of a PV infection.

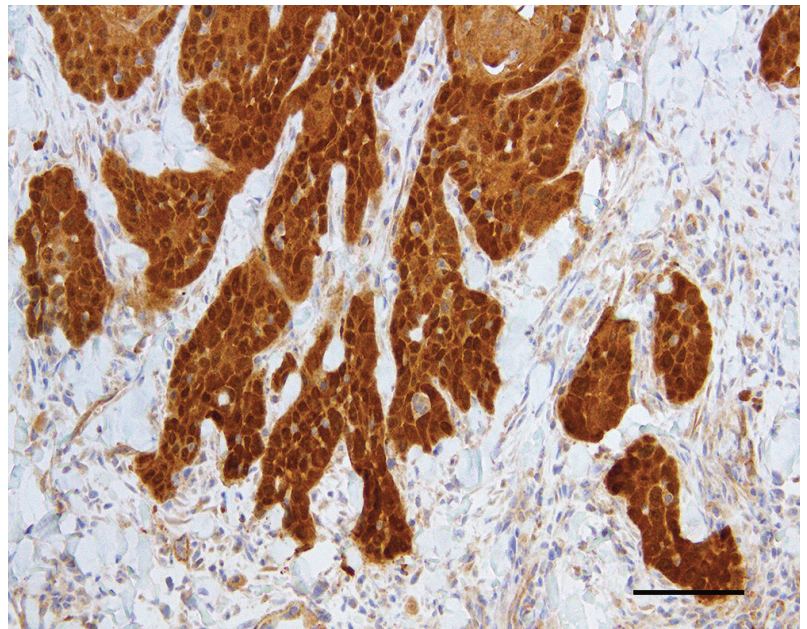


Figure 1 Feline cutaneous SCC. This neoplasm contained PV DNA and was from an area of the body that was protected from solar exposure. Note the consistent intense nuclear and cytoplasmic immunostaining against p16^{CDKN2A} protein (p16). Bar = 50 µm

Molecular techniques

Molecular tests to detect viral nucleic acids such as PCR and in situ hybridisation can also be used to investigate a PV aetiology for a lesion. The advantage of these techniques is that very small quantities of PV DNA or RNA can be detected. However, as asymptomatic PV infections are so common, simply detecting the presence of a PV within a lesion does not prove that the lesion was caused by the PV. In addition, these tests are not routinely available and are currently restricted to use in a research setting.

Treatment approaches

Surgical excision

There have been few studies evaluating treatment options for PV-induced lesions in cats. However, complete surgical excision is suggested for single or small numbers of viral plaques/BISCs, SCCs and BCCs. While surgical excision of a viral plaque/BISC is expected to be curative, clients should be advised that affected cats are more likely to develop additional lesions of this type. More aggressive treatment is suggested for Devon Rex and Sphynx cats due to the observation that BISCs can rapidly progress to metastatic SCCs in these breeds.^{32,33}

Non-surgical therapies

Evidence supporting non-surgical therapies to treat viral plaques/BISCs is limited. However, as these lesions are confined to the epidermis, treatment using cryotherapy is expected to be successful. In humans, CO₂ laser is considered one of the best treatment modalities for genital warts.⁵¹ As this modality was recently used to successfully treat numerous large viral plaques on a dog,⁵² CO₂ laser could be a useful treatment for larger lesions in cats.

Alternatively, imiquimod cream stimulates toll-like receptors and locally increases interferon alpha (α) and tumor necrosis factor- α .⁵³ While initially marketed as a treatment for human genital warts, imiquimod does not specifically target PV-induced lesions. In humans, this treatment has also been used for BCCs and actinic lesions, although imiquimod is only recommended as a primary treatment for pre-neoplastic or neoplastic skin lesions if better established therapies are not available.⁵⁴ In an uncontrolled study of 12 cats with BISCs, imiquimod resulted in partial resolution of at least one BISC in all 12 cats and complete resolution of at least one BISC in five cats.⁵⁵ However, significant side effects were reported including local erythema in five cats and systemic toxicity in two cats. While there is anecdotal evidence supporting the use of

Prevention

As host factors appear to be important in the development of PV-induced disease,²⁶ ensuring cats remain immunocompetent may prevent some PV-induced lesions. Vaccination against PVs has been shown to be effective at preventing PV-induced cancers in people.⁵⁷ While such vaccines could also be useful in cats, they have to be given prior to first exposure to the PV. As cats appear to be infected very early in life, novel vaccination strategies may have to be developed.

While there is anecdotal evidence supporting the use of imiquimod cream, additional controlled studies are required to determine efficacy and safety.



imiquimod cream, additional controlled studies are required to determine the efficacy and safety of this treatment. Evidence from human studies suggests that imiquimod may be equally effective in PV-induced and non-PV-induced pre-neoplastic feline lesions, although its use should probably be restricted to situations where other treatments are impractical.

Photodynamic therapy has also been reported to be effective for feline cutaneous in situ carcinomas, although whether any of the treated lesions were PV induced is uncertain.⁵⁶

There is no evidence that autologous vaccines influence the resolution of an established PV-induced lesion in any species and it seems unlikely that such vaccines would be useful to treat PV-induced lesions in cats.

Complete excision of a feline sarcoid is expected to be curative; however, given the common location of these neoplasms, this can be difficult and they are prone to local recurrence.

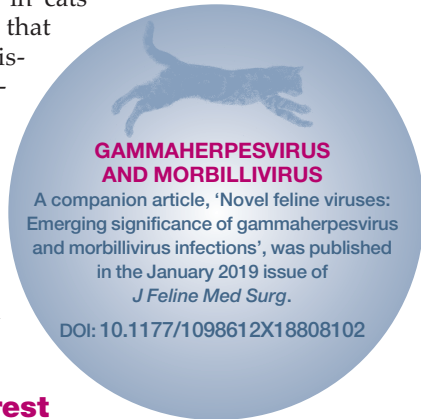
KEY POINTS

- ❖ Most cats harbour asymptomatic PV infections.
- ❖ It is unknown why a minority of infections result in clinical disease, but the development of disease is likely to be due to an inability of the host to maintain low levels of PV replication.
- ❖ PVs cause viral plaques/BISCs, which can become large and multiple, and can progress to SCCs. Surgical excision should be curative, but additional lesions are likely. Other unproven treatment options include cryotherapy, CO₂ laser and imiquimod cream.
- ❖ PVs may cause a proportion of cutaneous SCCs and BCCs, although the role of the virus in neoplastic transformation is currently unclear.
- ❖ Cross-species infection by a bovine PV causes feline sarcoids. These neoplasms can be locally recurrent after excision but do not metastasise.
- ❖ PVs cause oral papillomas in cats, but there is no evidence that PVs cause oral SCCs.



Conclusions

The role of PVs in the development of disease in cats is increasingly being recognised. This increased recognition will, in turn, allow further subclassification of feline skin diseases (eg, into PV-positive or PV-negative SCC), which may allow for a more accurate prognosis and better targeted therapies. Additionally, recognition of the role that PVs play in skin disease in cats raises the possibility that the PV-induced diseases can be prevented – either by protective vaccination or by enabling the host immune system to control virus replication and prevent the virus from causing clinical disease.



Conflict of interest

The authors declared no potential conflicts of interest with respect to the research, authorship, and/or publication of this article.

Funding

The authors received no financial support for the research, authorship, and/or publication of this article.

References

- Rector A and Van Ranst M. **Animal papillomaviruses.** *Virology* 2013; 445: 213–223.
- Munday JS, Dittmer KE, Thomson NA, et al. **Genomic characterisation of *Felis catus* papillomavirus type 5 with proposed classification within a new papillomavirus genus.** *Vet Microbiol* 2017; 207: 50–55.
- Munday JS, Thomson N, Dunowska M, et al. **Genomic characterisation of the feline sarcoid-associated papillomavirus and proposed classification as *Bos taurus* papillomavirus type 14.** *Vet Microbiol* 2015; 177: 289–295.
- Carney HC, England JJ, Hodgin EC, et al. **Papillomavirus infection of aged Persian cats.** *J Vet Diagn Invest* 1990; 2: 294–299.
- Tachezy R, Duson G, Rector A, et al. **Cloning and genomic characterization of *Felis domesticus* papillomavirus type 1.** *Virology* 2002; 301: 313–321.
- LeClerc SMC and Haines EG. **Papillomavirus infection in association with feline cutaneous squamous cell carcinoma in situ.** Proceedings of the AAVD/ACVD meeting. 1997 April 20; Nashville, TN, USA, pp 125–126.
- Munday JS, Kiupel M, French AF, et al. **Detection of papillomaviral sequences in feline Bowenoid in situ carcinoma using consensus primers.** *Vet Dermatol* 2007; 18: 241–245.
- Lange CE, Tobler K, Markau T, et al. **Sequence and classification of FdPV2, a papillomavirus isolated from feline Bowenoid in situ carcinomas.** *Vet Microbiol* 2009; 137: 60–65.
- Munday JS, Dunowska M, Hills SF, et al. **Genomic characterization of *Felis catus* papillomavirus-3: a novel papillomavirus detected in a feline Bowenoid in situ carcinoma.** *Vet Microbiol* 2013; 165: 319–325.
- Dunowska M, Munday JS, Laurie RE, et al. **Genomic characterisation of *Felis catus* papillomavirus 4, a novel papillomavirus detected in the oral cavity of a domestic cat.** *Virus Genes* 2014; 48: 111–119.
- Munday JS, Marshall S, Thomson NA, et al. **Multiple viral plaques with sebaceous differentiation associated with an unclassified papillomavirus type in a cat.** *NZ Vet J* 2017: 1–17.
- Schulman FY, Krafft AE and Janczewski T. **Feline cutaneous fibropapillomas: clinicopathologic findings and association with papillomavirus infection.** *Vet Pathol* 2001; 38: 291–296.
- Munday JS, Knight CG and Howe L. **The same papillomavirus is present in feline sarcoids from North America and New Zealand but not in any non-sarcoid feline samples.** *J Vet Diagn Invest* 2010; 22: 97–100.
- Teifke JP, Kidney BA, Lohr CV, et al. **Detection of papillomavirus-DNA in mesenchymal tumour cells and not in the hyperplastic epithelium of feline sarcoids.** *Vet Dermatol* 2003; 14: 47–56.
- Thomson NA, Dunowska M and Munday JS. **The use of quantitative PCR to detect *Felis catus* papillomavirus type 2 DNA from a high proportion of queens and their kittens.** *Vet Microbiol* 2015; 175: 211–217.
- Thomson NA, Thomas DG, Weidgraaf K, et al. ***Felis catus* papillomavirus type 2 DNA loads on kittens are transient and do not reflect their susceptibility to infection.** *J Feline Med Surg* 2018; 20: 332–338.
- Altamura G, Jebara G, Cardeti G, et al. ***Felis catus* papillomavirus type-2 but not type-1 is detectable and transcriptionally active in the blood of healthy cats.** *Transbound Emerg Dis* 2018; 65: 497–503.
- Geisseler M, Lange CE, Favrot C, et al. **Geno- and seroprevalence of *Felis domesticus* papillomavirus type 2 (FdPV2) in dermatologically healthy cats.** *BMC Vet Res* 2016; 12: 147. DOI: 10.1186/s12917-016-0776-7.
- Sundberg JP, Van Ranst M, Montali R, et al. **Feline papillomas and papillomaviruses.** *Vet Pathol* 2000; 37: 1–10.
- Munday JS, Hanlon EM, Howe L, et al. **Feline cutaneous viral papilloma associated with human papillomavirus type 9.** *Vet Pathol* 2007; 44: 924–927.
- Munday JS and Knight CG. **Amplification of feline sarcoid-associated papillomavirus DNA sequences from bovine skin.** *Vet Dermatol* 2010; 21: 341–344.
- Doorbar J. **The papillomavirus life cycle.** *J Clin Virol* 2005; 32 Suppl 1: S7–15.
- Munday JS. **Bovine and human papillomaviruses: a comparative review.** *Vet Pathol* 2014; 51: 1063–1075.
- Altamura G, Corteggio A, Pacini L, et al. **Transforming properties of *Felis catus* papillomavirus type 2 E6 and E7 putative oncogenes in vitro and their transcriptional activity in feline squamous cell carcinoma in vivo.** *Virology* 2016; 496: 1–8.
- Munday JS and Kiupel M. **Papillomavirus-associated cutaneous neoplasia in mammals.** *Vet Pathol* 2010; 47: 254–264.
- Munday JS, Thomson NA and Luff JA. **Papillomaviruses in dogs and cats.** *Vet J* 2017; 225: 23–31.

- 27 Egberink HF, Berrocal A, Bax HA, et al. **Papillomavirus associated skin lesions in a cat seropositive for feline immunodeficiency virus.** *Vet Microbiol* 1992; 31: 117–125.
- 28 Munday JS, Kiupel M, French AF, et al. **Amplification of papillomaviral DNA sequences from a high proportion of feline cutaneous in situ and invasive squamous cell carcinomas using a nested polymerase chain reaction.** *Vet Dermatol* 2008; 19: 259–263.
- 29 Wilhelm S, Degorce-Rubiales F, Godson D, et al. **Clinical, histological and immunohistochemical study of feline viral plaques and bowenoid in situ carcinomas.** *Vet Dermatol* 2006; 17: 424–431.
- 30 Munday JS, Fairley R and Atkinson K. **The detection of *Felis catus* papillomavirus 3 DNA in a feline bowenoid in situ carcinoma with novel histologic features and benign clinical behavior.** *J Vet Diagn Invest* 2016; 28: 612–625.
- 31 O'Neill SH, Newkirk KM, Anis EA, et al. **Detection of human papillomavirus DNA in feline premalignant and invasive squamous cell carcinoma.** *Vet Dermatol* 2011; 22: 68–74.
- 32 Munday JS, Benfell MW, French A, et al. **Bowenoid in situ carcinomas in two Devon Rex cats: evidence of unusually aggressive neoplasm behaviour in this breed and detection of papillomaviral gene expression in primary and metastatic lesions.** *Vet Dermatol* 2016; 27: 215–e55.
- 33 Ravens PA, Vogelnest LJ, Tong LJ, et al. **Papillomavirus-associated multicentric squamous cell carcinoma in situ in a cat: an unusually extensive and progressive case with subsequent metastasis.** *Vet Dermatol* 2013; 24: 642–645, e161–162.
- 34 Munday JS, Gibson I and French AF. **Papillomaviral DNA and increased p16^{CDKN2A} protein are frequently present within feline cutaneous squamous cell carcinomas in ultraviolet-protected skin.** *Vet Dermatol* 2011; 22: 360–366.
- 35 Hoggard N, Munday JS and Luff J. **Localization of *Felis catus* papillomavirus type 2 E6 and E7 RNA in feline cutaneous squamous cell carcinoma.** *Vet Pathol* 2018; 55: 409–416.
- 36 Thomson NA, Munday JS and Dittmer KE. **Frequent detection of transcriptionally active *Felis catus* papillomavirus 2 in feline cutaneous squamous cell carcinomas.** *J Gen Virol* 2016; 97: 1189–1197.
- 37 Munday JS, French AF, Peters-Kennedy J, et al. **Increased p16^{CDKN2A} protein within feline cutaneous viral plaques, bowenoid in situ carcinomas, and a subset of invasive squamous cell carcinomas.** *Vet Pathol* 2011; 48: 460–465.
- 38 Munday JS, French AF, Gibson IR, et al. **The presence of p16^{CDKN2A} protein immunostaining within feline nasal planum squamous cell carcinomas is associated with an increased survival time and the presence of papillomaviral DNA.** *Vet Pathol* 2013; 50: 269–273.
- 39 Akgul B, Cooke JC and Storey A. **HPV-associated skin disease.** *J Pathol* 2006; 208: 165–175.
- 40 Gross TL, Ihrke PJ, Walder EJ, et al (eds). **Epidermal tumors.** In: *Skin diseases of the dog and cat: clinical and histopathologic diagnosis*. 2nd ed. Oxford, UK: Blackwell Science, 2005, pp 562–603.
- 41 Munday JS, French A and Thomson N. **Detection of DNA sequences from a novel papillomavirus in a feline basal cell carcinoma.** *Vet Dermatol* 2017; 28: 236–e60.
- 42 Munday JS, Thomson NA, Henderson G, et al. **Identification of *Felis catus* papillomavirus 3 in skin neoplasms from four cats.** *J Vet Diagn Invest* 2018; 30: 324–328.
- 43 Munday JS, Fairley RA, Mills H, et al. **Oral papillomas associated with *Felis catus* papillomavirus type 1 in 2 domestic cats.** *Vet Pathol* 2015; 52: 1187–1890.
- 44 Munday JS, Lohr CV and Kiupel M. **Tumors of the alimentary tract.** In: Meuton DJ (ed). *Tumors in domestic animals*. 5th ed. Hoboken, NJ, John Wiley and Sons, 2017, pp 499–601.
- 45 Marur S, D'Souza G, Westra WH, et al. **HPV-associated head and neck cancer: a virus-related cancer epidemic.** *Lancet Oncol* 2010; 11: 781–789.
- 46 Munday JS, Knight CG and French AF. **Evaluation of feline oral squamous cell carcinomas for p16^{CDKN2A} protein immunoreactivity and the presence of papillomaviral DNA.** *Res Vet Sci* 2011; 90: 280–283.
- 47 Manos MM, Ting Y, Wright DK, et al. **The use of polymerase chain reaction amplification for the detection of genital human papillomaviruses.** *Cancer Cells* 1989; 7: 209–214.
- 48 Smeets SJ, Hesselink AT, Speel EJ, et al. **A novel algorithm for reliable detection of human papillomavirus in paraffin embedded head and neck cancer specimen.** *Int J Cancer* 2007; 121: 2465–2472.
- 49 Parry D, Bates S, Mann DJ, et al. **Lack of cyclin D-Cdk complexes in Rb-negative cells correlates with high levels of p16INK4/MTS1 tumour suppressor gene product.** *EMBO J* 1995; 14: 503–511.
- 50 Chung CH, Zhang Q, Kong CS, et al. **p16 protein expression and human papillomavirus status as prognostic biomarkers of nonoropharyngeal head and neck squamous cell carcinoma.** *J Clin Oncol* 2014; 32: 3930–3938.
- 51 Bertolotti A, Dupin N, Bouscarat F, et al. **Cryotherapy to treat anogenital warts in nonimmunocompromised adults: systematic review and meta-analysis.** *J Am Acad Dermatol* 2017; 77: 518–526.
- 52 Knight EC, Munday JS, Stone BM, et al. **Carbon dioxide laser treatment of extensive pigmented viral plaque lesions in a golden retriever dog.** *Vet Dermatol* 2016; 27: 442–e117.
- 53 Miller RL, Gerster JF, Owens ML, et al. **Imiquimod applied topically: a novel immune response modifier and new class of drug.** *Int J Immunopharmacol* 1999; 21: 1–14.
- 54 Love W, Bernhard JD and Bordeaux JS. **Topical imiquimod or fluorouracil therapy for basal and squamous cell carcinoma: a systematic review.** *Arch Dermatol* 2009; 145: 1431–1438.
- 55 Gill VL, Bergman PJ, Baer KE, et al. **Use of imiquimod 5% cream (Aldara) in cats with multicentric squamous cell carcinoma in situ: 12 cases (2002–2005).** *Vet Comp Oncol* 2008; 6: 55–64.
- 56 Flickinger I, Gasymova E, Dietiker-Moretti S, et al. **Evaluation of long-term outcome and prognostic factors of feline squamous cell carcinomas treated with photodynamic therapy using liposomal phosphorylated meta-tetra(hydroxylphenyl)chlorine.** *J Feline Med Surg* 2018; 20: 1100–1104.
- 57 Anderson LA. **Prophylactic human papillomavirus vaccines: past, present and future.** *Pathology* 2012; 44: 1–6.

Available online at jfms.com

Article reuse guidelines: sagepub.com/journals-permissions
For reuse of images only, contact the corresponding author