STOMACH ANATOMY OF THE NEW ZEALAND FUR SEAL (*Arctocephalus forsteri* Lesson, 1828) AND THE LONG-FINNED PILOT WHALE (*Globicephala melas* Traill, 1809)

A thesis presented in partial fulfilment of the requirements
for the Degree of Master of Science in Anatomy at Massey University,
Palmerston North, New Zealand

Nadine Jasmine Gibbs

1999

Abstract

The New Zealand fur seal (*Arctocephalus forsteri*) and the long-finned pilot whale (*Globicephala melas*) represent two phylogenetically unrelated species that inhabit the same environment and utilise similar prey. The stomach anatomy of the New Zealand fur seal and the long-finned pilot whale has not been well studied. Because of the scarcity of published information on these two species, this study was undertaken to identify differences and similarities between the two species. A literature review considers work on the stomach anatomy of other marine mammal species to allow for comparisons and parallels to be made. The stomachs of 10 New Zealand fur seal and 7 long-finned pilot whale cadavers were examined macroscopically and microscopically.

The single chambered stomach of the New Zealand fur seal was similar to that of other pinnipeds. The stomach was J-shaped: with an elongate proper-gastric region, a sharply bent incisura angularis and narrow pyloric portion that extended cranially to a well-developed pyloric sphincter. The lining of the empty stomach was arranged into well-defined rugae that were sparser and less tortuous beyond the pyloric antrum. The microscopic anatomy of the stomach wall was similar to the typical mammalian carnivore plan. However, some differences were evident, including a narrower cardiac zone, and longer proper-gastric glands because of the numerous mucous neck and parietal cells.

The multi-chambered stomach of the long-finned pilot whale was similar to that of other cetaceans. The stomach consisted of three chambers: a muscular, pear-shaped forechamber followed by a bulbous proper-gastric chamber and a thin walled pyloric chamber divided into a channel-like cranial portion that was further subdivided by a transverse septum and a tubular caudal portion. The orifices between chambers and the chambers themselves progressively decreased in size. The proper-gastric and pyloric chambers are comparable to those zones of the typical mammalian stomach. However some differences were evident, including the abrupt changes in mucosa between chambers, lack of a cardiac zone, a forechamber lined by non-glandular epithelium and a thicker stomach wall.

It is concluded that the stomachs of the New Zealand fur seal and the long-finned pilot whale are macroscopically different but microscopically similar. The stomachs are similar to those of other pinnipeds and cetaceans, respectively. Therefore, anatomical variations are likely to be phylogenetic in origin as otariids are believed to be derived from bear-like carnivorous ancestors whereas cetaceans are from the ancestors of ruminants.

Acknowledgements

I would like to dedicate this thesis to my parents Pat and John Gibbs, my sisters Melanie and Emma and to Skye and Jimi, all to whom I am indebted for their loving support, inspiration and strength.

I am grateful to a number of people for without their help my study would not have been possible. First I would like to acknowledge the staff of Department of Conservation (DOC), especially Bruce Dix and Dick Gill (DOC Wellington), Malcolm Smith, Helen Jonas and Clinton Duffy (DOC East Coast) and Hans Rook (DOC Hawkes Bay) for help in access to carcasses.

Thanks to Associate Professor E.J Kirk who supervised this thesis.

Special thanks to Dr Padraig Duignan, Dr Jane Hunter and Gareth Jones for friendship, supportive advice and help with access to specimens.

I would like to acknowledge Mr Mervyn Birtles (Senior Lecturer in Histology) who gave access to the histology laboratory and equipment and who offered advice with interpretation of slides and photomicrographs.

I am also grateful to the Comparative Physiology and Anatomy technicians, particularly Guy Hessell who gave constructive advice and provided a relaxed efficient working atmosphere; and Jenny Neale who was always helpful even when it seemed there really was no more space! Thank you to Angus Fordham who endured unsightly dissections and produced some of the photographs.

Thanks to all my friends, particularly Mark Smith, Sarah Todd, David Simcock, Mhairi Sutherland, Liz Gillespie and Ricci Wesselink for their support.

Finally, thank you to Simon Childerhouse (DOC, Science and Research Unit) who presented opportunities to work with live animals in the Subantarctic Auckland Islands and who helped put many of the ideas presented in this study into perspective.

Table of Contents

List of Figures

List of Tables

List of Plates

Chapter One

Introduction

The objectives of this study were to describe the macroscopic and microscopic stomach anatomy of the New Zealand fur seal (*Arctocephalus forsteri* Lesson, 1828) and the long-finned pilot whale (*Globicephala melas* Traill, 1809). Specifically, to identify the differences and similarities between the two species and to determine if they conform to the typical pinniped and cetacean plans, respectively.

Marine mammals belong to several morphologically and phylogenetically distinct taxa of which pinnipedia and cetacea are two principal groups. Pinnipedia is comprised of three families: the odobenid (walrus), phocid (earless seals) and otariid (eared seals and sea lions). While cetacea is comprised of two suborders: the odontoceti (toothed whales) and mysticeti (baleen whales) (Barnes *et al.* 1985). Among the marine mammals of New Zealand, the New Zealand fur seal and the long-finned pilot whale are two species representing otariidae and odontoceti and provide an opportunity to compare phylogenetically unrelated species that inhabit the same environment and utilise similar prey.

The stomach is an important organ as it is a major site for digestion (Dyce *et al.* 1996) and provides energy to physiological systems, including thermoregulatory mechanisms. These mechanisms maintain the thermal balance of the body, which is particularly important in marine mammals as they reside in a cold environment (Ridgway 1972).

The stomach anatomy of some marine mammal species has been well studied, but that of the New Zealand fur seal and the long-finned pilot whale have not. For example, there is only a brief description of the New Zealand fur seal stomach in an unpublished Bachelor of Philosophy thesis (Yates 1984) and an early study of a single long-finned pilot whale stomach (Murie 1873). Thus, because of the limited data on the stomachs of these species this study was undertaken.

Chapter Two

Literature Review

The New Zealand fur seal is a semi-aquatic marine mammal and has a southern Australasian distribution (Crawley & Wilson 1976, Shaughnessy *et al.* 1994). The long-finned pilot whale is fully aquatic and has a cosmopolitan distribution (Desportes & Mouritsen 1993).

The stomach anatomy of some marine mammals has been well studied. However, that of the New Zealand fur seal and the long-finned pilot whale has not. Because of this lack of information it is necessary to consider work reported from other marine mammal species to allow for comparisons and parallels to be made. Therefore the bulk of this chapter describes the stomach anatomy of other species of marine mammals.

The common and scientific names of all species mentioned in the text are listed in Appendix 1. The nomeclature used in the text follows terminology recommended in Nomina Anatomica Veterinaria, 4th Edition and Nomina Histologica, 2nd Edition (1994).

2.0 **Introduction to literature on stomach anatomy in marine mammals**

It appears that Owen (1830) was the first to report that pinnipeds have a simple, monogastric stomach, and Hunter (1787) (as cited by Ridgway 1972) was the first to report that cetaceans have a large multi-chambered stomach.

There were few publications in the 19th and early 20th century on the stomachs of marine mammals. Most comprised observations on only single animals, likely because of the unavailability of large numbers of animals for study. For example, Owen (1830, 1853) and Burne (1909) each studied a single walrus (*Odobenus rosmarus*), Murie (1874) studied a single Steller sea lion (*Eumetopias jubatus*) and Hepburn (1896) studied a single grey seal (*Halichoerus grypus*) specimen. The early studies were followed by a gap in the literature before the more recent anatomical studies in the latter parts of the 20th century, which frequently involve a greater number of animals and frequently more than one species. For example, Langer's (1996) study of 2 Blainville's beaked whales (*Mesoplodon densirostris*), 4 common dolphins (*Delphinus delphis*), 5 bottlenose dolphins (*Tursiops truncatus*), 2 long-snouted spinner dolphins (*Stenella longirostris*), and 2 humpback dolphins (*Sousa* *chinensis*). More recent studies have involved both macroscopic and microscopic observations, perhaps due to the advancing development of light microscopy and the invention of electron microscopy.

To date, there is only a brief description of the New Zealand fur seal stomach in an unpublished Bachelor of Philosophy thesis (Yates 1984), and an early anatomical study on a single long-finned pilot whale (Murie 1873).

2.1 **General mammalian digestive anatomy**

The stomachs of pinnipeds share many characteristics of the carnivorous stomach (Ridgway 1972). There has been little described about the general pinniped stomach anatomy and the plan of other carnivores such as the dog (*Canis familiaris*) can be used as a model. This is also true of the microscopic anatomy. This section provides a brief description of the stomach and its relationship to other parts of the digestive system.

Digestive organs are concerned with ingestion of food and fluids, mechanical and chemical digestion, absorption of ingesta and elimination of unabsorbed residues (Dyce *et al.* 1996). Parts of the typical mammalian digestive system in a cranial-caudal sequence comprises the oral cavity, pharynx, esophagus, stomach, small intestine, large intestine and accessory glands such as the salivary glands, liver and pancreas that drain by ducts into the digestive tract (Figure 2.1) (Dyce *et al.* 1996). The stomach is a bulbous dilation of the digestive tract where processes of physical and chemical digestion break down ingested food (Dyce *et al.* 1996). The stomach is diverse in morphology and can be either simple-chambered (Figure 2.2) as in pinnipeds, or complex (Figure 2.3) as in cetaceans (Williams *et al.* 1989, Dyce *et al.* 1996).

During embryonic development, the morphogenesis of the simple and complex stomachs is identical. Differential enlargement of a simple ventrally located tube forms the greater and lesser curvatures of the stomach followed by expansion of the greater curvature to form the fundus (Noden & Lahunta 1985). After this stage, the simple and complex stomachs differ in their development. In animals with a simple stomach, reorientation and displacement positions the stomach in the abdomen. In ruminant animals with a complex stomach, reorientation and differential enlargements of the fundus form the primordium of the rumen and reticulum, and of the lesser curvature form the omasum. Further fetal and postnatal growth results in the adult complex stomach (Noden & Lahunta 1985).

Figure 2.1 Schematic diagram of the digestive tract in the dog (*Canis familiaris*) (modified from Dyce *et al*. 1996)

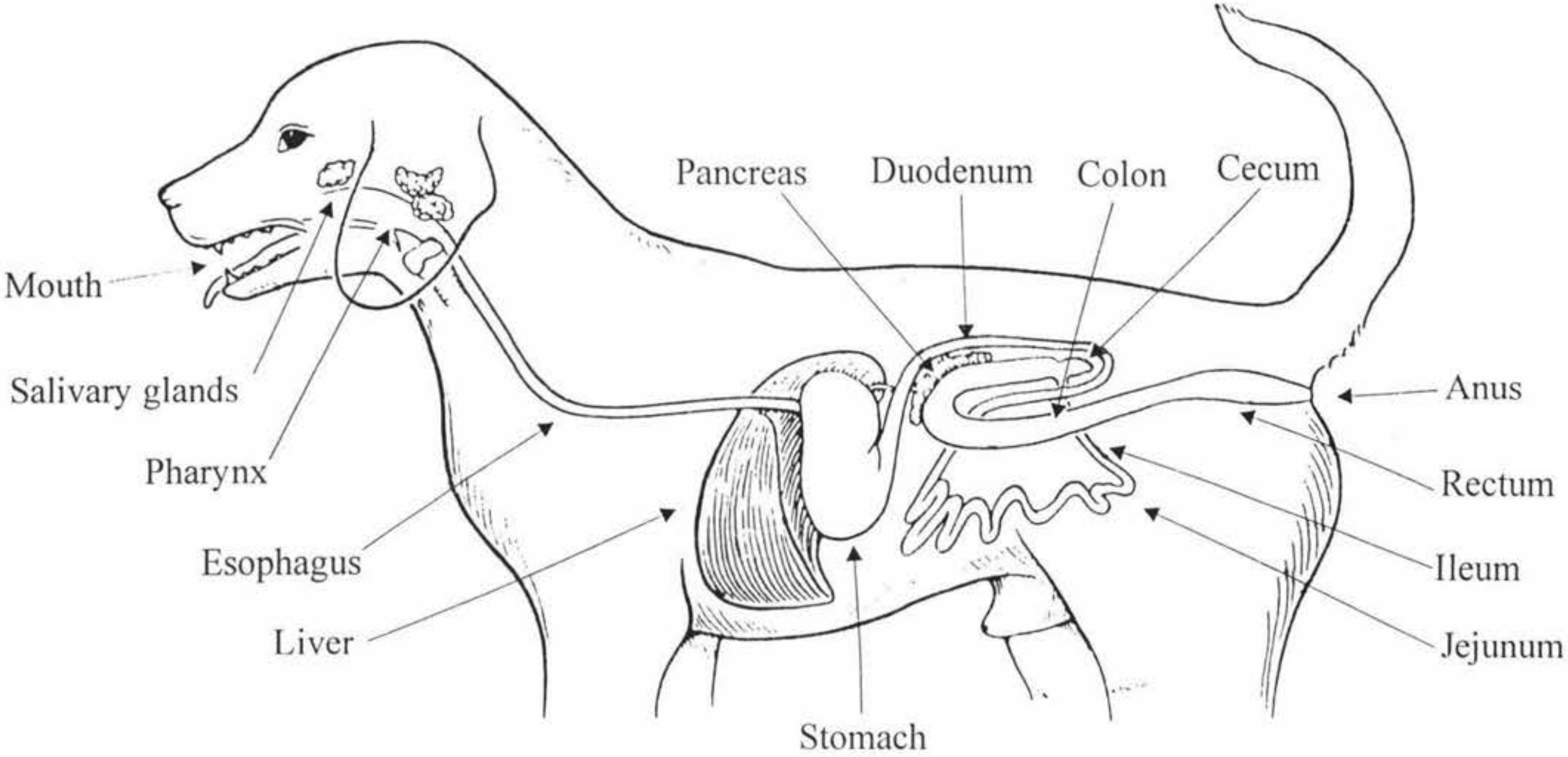

2.2 **Macroscopic anatomy of pinniped stomachs**

The stomachs of pinnipeds are simple and analogous to those of other carnivores (Eastman & Coalson 1974, Olsen *et al.* 1996).

2.2.1 Position of pinniped stomachs

The position of the stomach in the abdominal cavity varies depending on whether it is empty or distended with ingesta. Yates (1984) briefly described the stomach of the New Zealand fur seal as occupying a craniomedial position in the abdomen. The cardia was ventral to thoracic (T) vertebra 13, the most caudal port of the stomach at the level of lumbar (L) vertebra 4, and the pyloric portion curved cranially from L_4 to the level of T_{15}.

2.2.2 External appearance of pinniped stomachs

The pinniped stomach is J-shaped with the longitudinal axis of the "J" corresponding to the craniocaudal axis of the body with the pyloric portion bent at the incisura angularis along the lesser curvature (Owen 1830, 1853; Murie 1874). The pyloric canal is narrow, the ostium small and the sphincter well developed (Eastman & Coalson 1974). The stomach of the New Zealand fur seal follows this generalised description (Yates 1984).

The simple stomach has two orifices: cardiac and pyloric; four regions: cardiac, fundic, proper-gastric and pyloric; two curvatures: greater and lesser; and two surfaces: dorsal and ventral (Figure 2.2) (Williams *et al.* 1989). The cardiac region is narrow and is where the esophagus terminates at the cardiac orifice of the stomach. The dome-shaped fundic region is usually full of gas and projects cranially and to the left of the cardiac orifice (Dyce *et al.* 1996). The proper-gastric region is the largest region and extends from the cardiac region to the incisura angularis. It is followed by the pyloric region, which is divided into the antrum and canal by the sulcus intermedias, and extends from the incisura angularis to the pyloric orifice (Dyce *et al.* 1996). The pyloric orifice forms an anatomical and physiological sphincter at the exit from the stomach, and controls the rate of discharge of stomach contents into the duodenum (Dyce *et al.* 1996).

Figure 2.2 Schematic diagram of the simple mammalian stomach (modified from Williams *et al*. 1989)

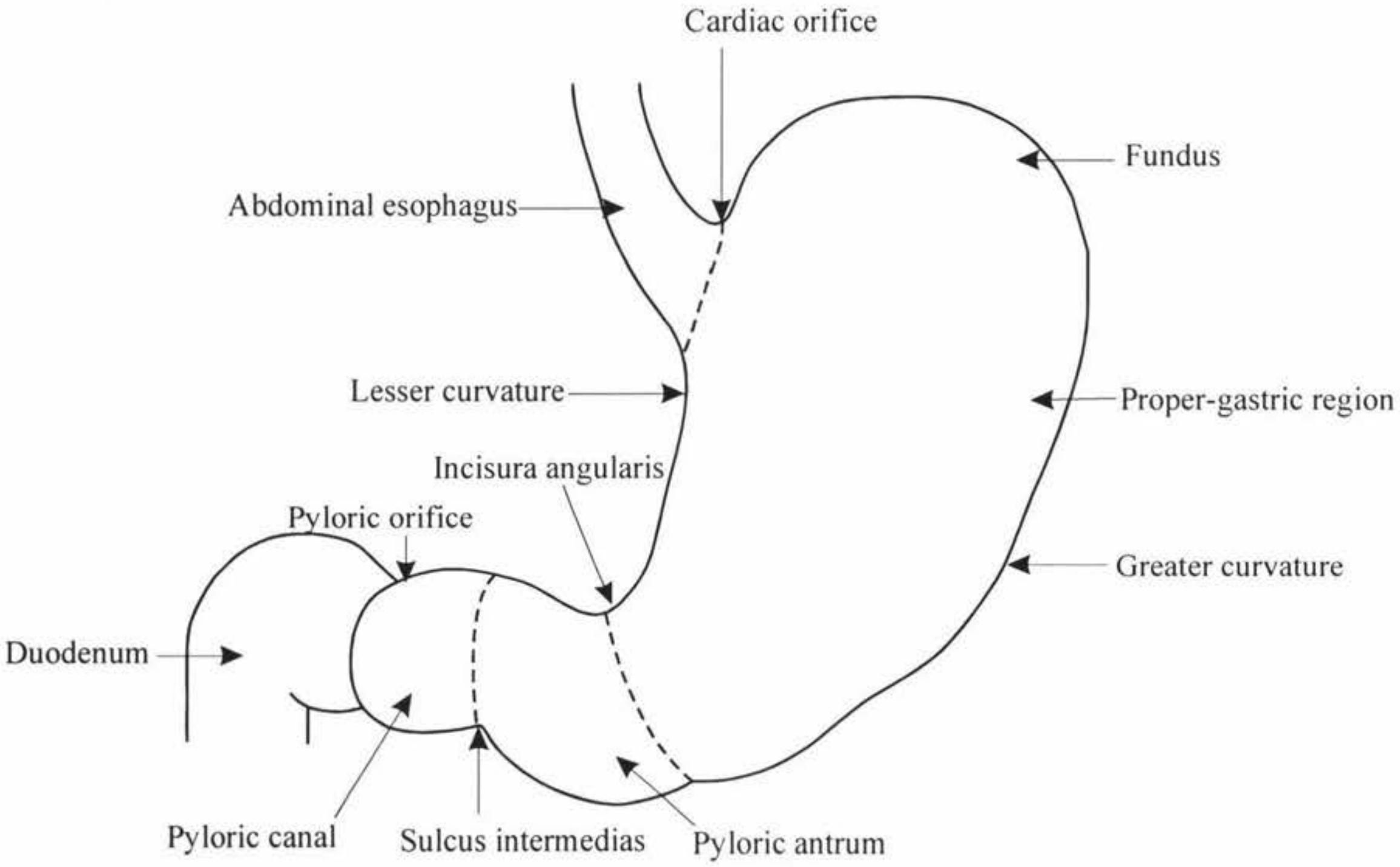

The greater curvature of the simple stomach is convex. It extends from the left of the cardiac orifice, over the fundus and along the left border of the proper-gastric region and right border of the pyloric region to the pyloric orifice (Murie 1874, Eastman & Coalson 1974, Dyce *et al.* 1996). In comparison, the concave lesser curvature extends from the right of the cardiac orifice, along the right border of the proper-gastric region, sharply changes direction at the incisura angularis and along the left border of the pyloric region to the pyloric orifice (Figure 2.2) (Dyce *et al.* 1996).

Stomach diverticula have been reported in some pinniped species (Green 1972). For example, Hepburn (1896) described a small diverticulum in the lesser curvature of the pyloric canal in a single grey seal specimen. Diverticula have not been reported in the stomach of the New Zealand fur seal (Yates 1984).

2.2.2.1 Mesogastria of pinnipeds

Attached to the greater and lesser curvatures of the simple stomach are the greater and lesser omenta, respectively (Dyce *et al.* 1996). The omenta are mesenteries derived from the dorsal mesogastrium, which in early development attaches the gastrointestinal tract to the dorsal embryonic trunk. During development the mesogastrium becomes drawn out and folded in on itself forming the omenta and creating a pouch called the omental bursa (Dyce *et al.* 1996).

The omenta of pinnipeds are devoid of fat and are relatively thin and transparent (Murie 1874, Eastman & Coalson 1974). This is in contrast to terrestrial mammals where the greater omentum usually contains fat, initially deposited along the small omental vessels (Dyce *et al.* 1996).

The arrangement of omenta has been poorly described in pinnnipeds but the information available suggests they differ among species. For example, the greater omentum of a single Steller sea lion did not cover the intestinal coils but was folded within the cranial intestinal coils (Murie 1874), while Eastman & Coalson (1974) reported that the greater omentum of the Weddell seal (*Leptonychotes weddellii*) covered the most cranial intestinal coils. The omenta of the New Zealand fur seal stomach have not been described.

2.2.2.2 Blood, lymphatic and nerve supply of pinniped stomachs

It appears there are no descriptions of the blood, lymphatic or nerve supply of pinniped stomachs. However, in most mammalian species the blood supply to the simple stomach arises from three main branches of the celiac artery: the hepatic, splenic and left gastric (Dyce *et al.* 1996). These branches anastomose and penetrate the external stomach wall where they pass into the tunica submucosa before branching to form a plexus that supplies the muscular layers of the stomach wall (Dyce *et al.* 1996). The veins are similarly arranged to the arteries and combine to form trunks that drain into the portal vein. The lymph vessels are prevalent throughout the stomach wall and lead to several gastric lymph nodes and drain particular areas of the stomach wall (Dyce *et al.* 1996). Parasymphathetic nerve fibers and sympathetic nerve fibers travel with blood vessels to reach the stomach. Parasympathetic efferent fibers augment and sympathetic fibers inhibit the activity of the gastric muscle (Dyce *et al.* 1996). Parasympathetic and sympathetic fibers also innervate the lamina epithelialis mucosae (Dyce *et al.* 1996).

2.2.2.3 Size and volume of pinniped stomachs

The size of the pinniped stomach varies according to species and age, the latter because of changing from liquid to solid food (Bryden 1971). For example, stomach capacity of 150 ml has been measured in a juvenile female New Zealand fur seal, of 1.5 l in an adult male New Zealand fur seal (Yates 1984), and of 2.6-7.5 l in adult male and female harp seals (*Phoca groenlandica*) (Olsen *et al.* 1996). The empty stomach of the Northern fur seal (*Callorhinus ursinus*) represents 0.8-1.1% of the total body weight in the adult male and 1.0-1.7% in the adult female (Scheffer 1960). Other species show lower proportions including adult Southern elephant seals (*Mirounga leonina*) of 0.5% (Bryden 1971), Ross seals (*Ommatophoca rossii*) of 0.3% and crabeater seals (*Lobodon carcinophagus*) of 0.4% (Bryden & Erickson 1976).

2.2.2.4 Stomach contents of pinnipeds

Diets of pinnipeds have been determined by examining regurgitates, stomach contents and fecal samples. These analyses have shown pinnipeds are generally opportunistic feeders and the predominance of particular prey items varies geographically and seasonally (Harkonen 1987). The New Zealand fur seal diet consists of octopus (*Octopus maorum*), squid (*Nototodarus sloanii; Sepioteuthis bilineata*) and fish species including barracouta (*Thyrsites atun*), red and blue cod (*Physiculus bachus, Perapercis colias*), hoki (*Macruronus novaezealandiae*), lanternfish (*Symbolophorus* species & *Lamponyctodes hectoris*), lamprey (*Geotria australis*), anchovy (*Engraulis australis*) and ahuru (*Auchenoceros punctatus*). Rock lobster (*Jasus* species), crab and penguins (*Eudyptes* species) have also been identified (Street 1964, Carey 1991, Dix 1993). Adults are reported to ingest an average of 4.1-4.5 kg per meal (Street 1964).

Stones of varying sizes and quantities have been recorded in the stomachs of many pinnipeds (Fiscus & Baines 1966), with up to 11 kg of stones found in the stomach of a single otariid (King 1983). Several possibilities exist for the function of stones: accidental ingestion, to alleviate colic (Eastman & Coalson 1974), to regulate buoyancy or to grind up parasitic worms (King 1983). It is possible that they break up ingested food, assist stomach muscles in ejecting indigestible material (King 1983) or provide bulk upon which stomach muscles act to relieve hunger pangs during periods of fasting (Laws 1953, Harrison & Kooyman 1968, Eastman & Coalson 1974). They may also prevent the movement of large pieces of ingesta into the pylorus (Needham 1985).

It is likely that the reason for stones in the stomachs of pinnipeds varies between species but the most likely explanation is their use for helping to grind up ingested food, functioning similarly to the crop of birds.

2.2.3 Internal appearance of pinniped stomachs

The stomach mucosa in most pinniped species changes abruptly at the cardiac orifice from the white longitudinal folds of the esophagus to large well-developed, irregular rugae that occupy the proper-gastric to pyloric antral surfaces of the stomach (Murie 1874, Eastman & Coalson 1974, Olsen *et al.* 1996). The rugae lose their tortuosity distal to the pyloric antrum and run straight from the pyloric canal to the pyloric orifice (Eastman & Coalson 1974, Olsen *et al.* 1996). The rugae temporarily flatten when substantial meals are ingested, allowing distension of the stomach (Williams *et al.* 1989). The lining of the stomach of the New Zealand fur seal follows this generalised description (Yates 1984).

In a single Steller sea lion, a partial septum at the pyloric antrum, formed by a semilunar fold of membrane, projects caudally in a line with the incisura angularis, and minute holes throughout the mucosal lining were macroscopically detected, signifying the openings of zymogenic glands (Murie 1874).

2.2.3.1 Pathology of pinniped stomachs

Gastric ulcers occur in many species of mammals. The cause of ulcers in marine mammals is often unclear or unidentified. Most reports directly associate the ulcers with parasitism by roundworms, e.g., *Anisakis* sp (Vik 1964, Wilson & Stockdale 1970), *Contracaecum osculatum* (Keyes 1965, Liu & Edward 1971), *Pholeter gastrophilus* (Migaki *et al.* 1971) and *Phocanema decipiens* (Keyes 1965). A typical ulcer associated with the attachment of parasites consists of a small to large ulcer in which the anterior ends of one or more immature worms are buried (Vik 1964, Keyes 1965, Migaki *et al.* 1971). The ulcers can be in various states, some being fresh, others hemorrhagic or healing. In many cases they extend as far as the muscular layers of the stomach wall and can cause peritonitis (Vik 1964, Keyes 1965, Liu & Edward 1971, Migaki *et al.* 1971).

Simpson & Gardner (1972) have reported presumed non-parasitic ulceration of the esophagus and stomachs in both captive and stranded pinnipeds. These types of ulcers are attributed to histamine toxicosis where high concentrations of histamine as part of a herring diet may have caused excessive acid secretion through direct and indirect stimulation of parietal cells (Geiger 1955, Geraci 1981). Alternatively, starvation, stress or trauma may also cause spontaneous formations of gastric ulcers (Brodie & Hanson 1960, Geraci & Gerstmann 1966). No gastric ulcers, either parasitic or non-parasitic have been reported in the stomach of the New Zealand fur seal.

2.3 **Macroscopic anatomy of cetacean stomachs**

2.3.1 Position of cetacean stomachs

The cetacean stomach is located cranially and occupies both the left and right sides of the abdomen (Green 1972), a pattern similar to ruminant animals that also have a complex stomach (Dyce *et al.* 1996).

Figure 2.3 Schematic diagram of the ruminant stomach (modified from Dyce *et al.* 1996)

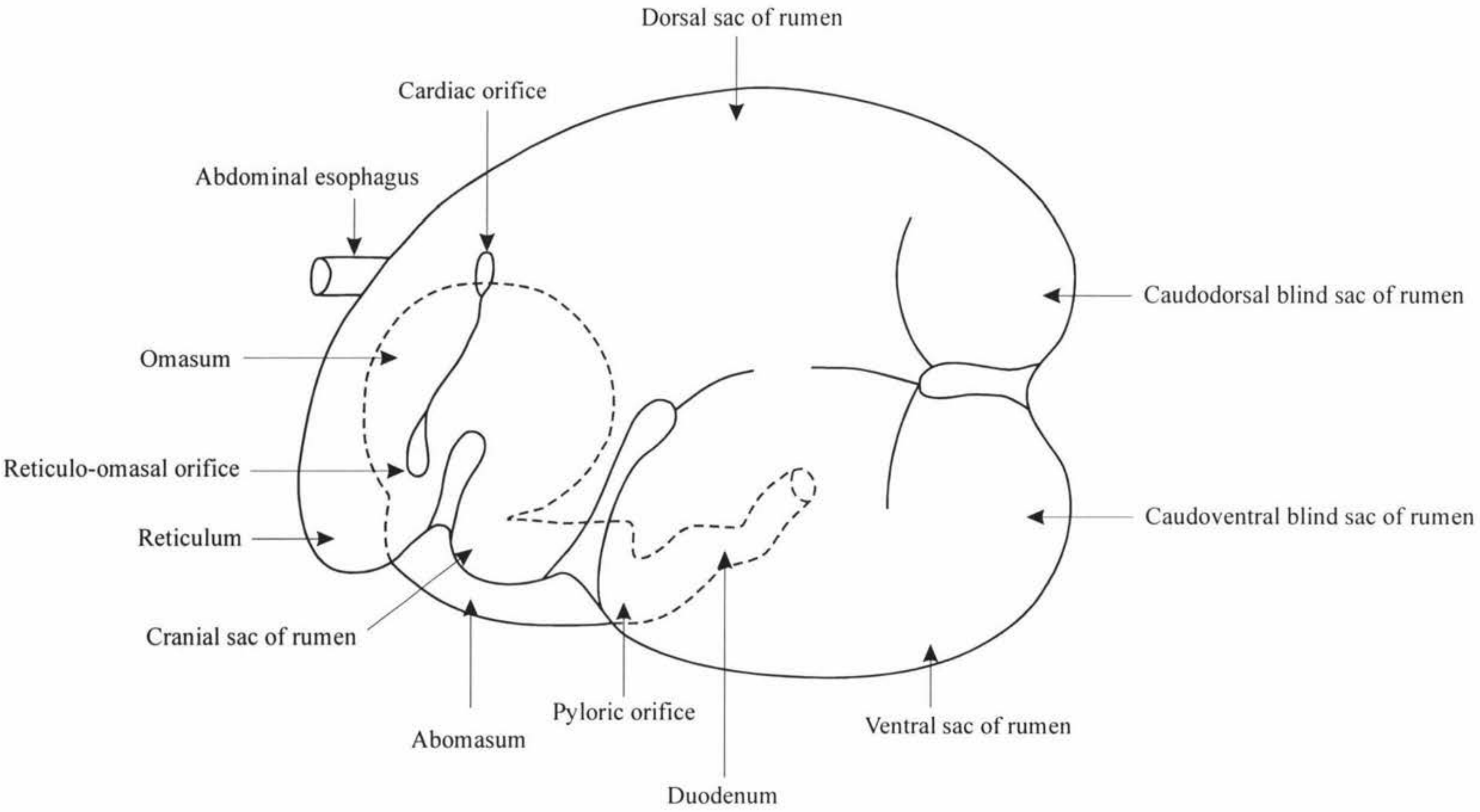

2.3.2 External appearance of cetacean stomachs

The complex cetacean stomach is large and multi-chambered with differences among major groups of cetacean species. The gross external appearance of the cetacean stomach resembles the four-chambered stomach of ruminants (Figure 2.3) (Langer 1988, Olsen *et al.* 1994). The stomachs of many cetaceans have three main chambers with a short 'connecting channel' leading from the second chamber to the third chamber (Figure 2.4A). Orifices that separate the chambers progressively reduce in diameter through the stomach (Harrison et al. 1970, Tarpley *et al.* 1987, Rice & Wolman 1990). The stomach of the pilot whale follows this generalised description (Murie 1873). The first three chambers (rumen, reticulum, omasum) of the ruminant stomach are non-glandular and are followed by a glandular chamber (abomasum) comparable to the monogastric mammalian stomach (Dyce *et al.* 1996).

The stomachs of beaked whales and some river dolphins (Figure 2.4B) vary from those of other cetaceans because they lack a non-glandular forechamber and beaked whales have a greater number of chambers (as many as 14) (Turner 1889, Yamasaki *et al.* 1974, Pfeiffer 1993, Langer 1996).

2.3.2.1 Concordance of terminology

Terminology to describe the cetacean stomach in the literature has been used inconsistently (see Appendix 2). Some authors have called the chambers of the cetacean stomach 'stomachs' implying there is more than one stomach when in fact there is only one stomach with multiple compartments. Other authors have used 'first chamber', 'second chamber', 'third chamber' and 'fourth chamber' to describe the chambers. However, in some cetaceans, particularly beaked whales, the non-glandular 'first chamber' is absent and the 'first chamber' in these animals has glands. The terms 'glandular chamber' or 'gastric chamber' used by some authors may also seem inappropriate because 'glandular chamber' implies it is the only chamber of the stomach with glands, which is inaccurate and 'gastric chamber' implies the whole stomach.

Some authors consider the cetacean stomach to have more than three chambers because they include the 'connecting channel' (Home 1807, Turner 1868, 1889; Murie 1873, Olsen *et al.* 1994) and the duodenal ampulla (Hosokawa & Kamiya 1971) as being distinct chambers of the stomach.

Figure 2.4 Schematic diagram of the stomachs in the (A) long-snouted spinner dolphin (*Stenella longirostris*), and (B) La Plata dolphin (*Pontoporia blainvillei*) (modified from Harrison *et al*. 1970, Yamasaki *et al.* 1974)

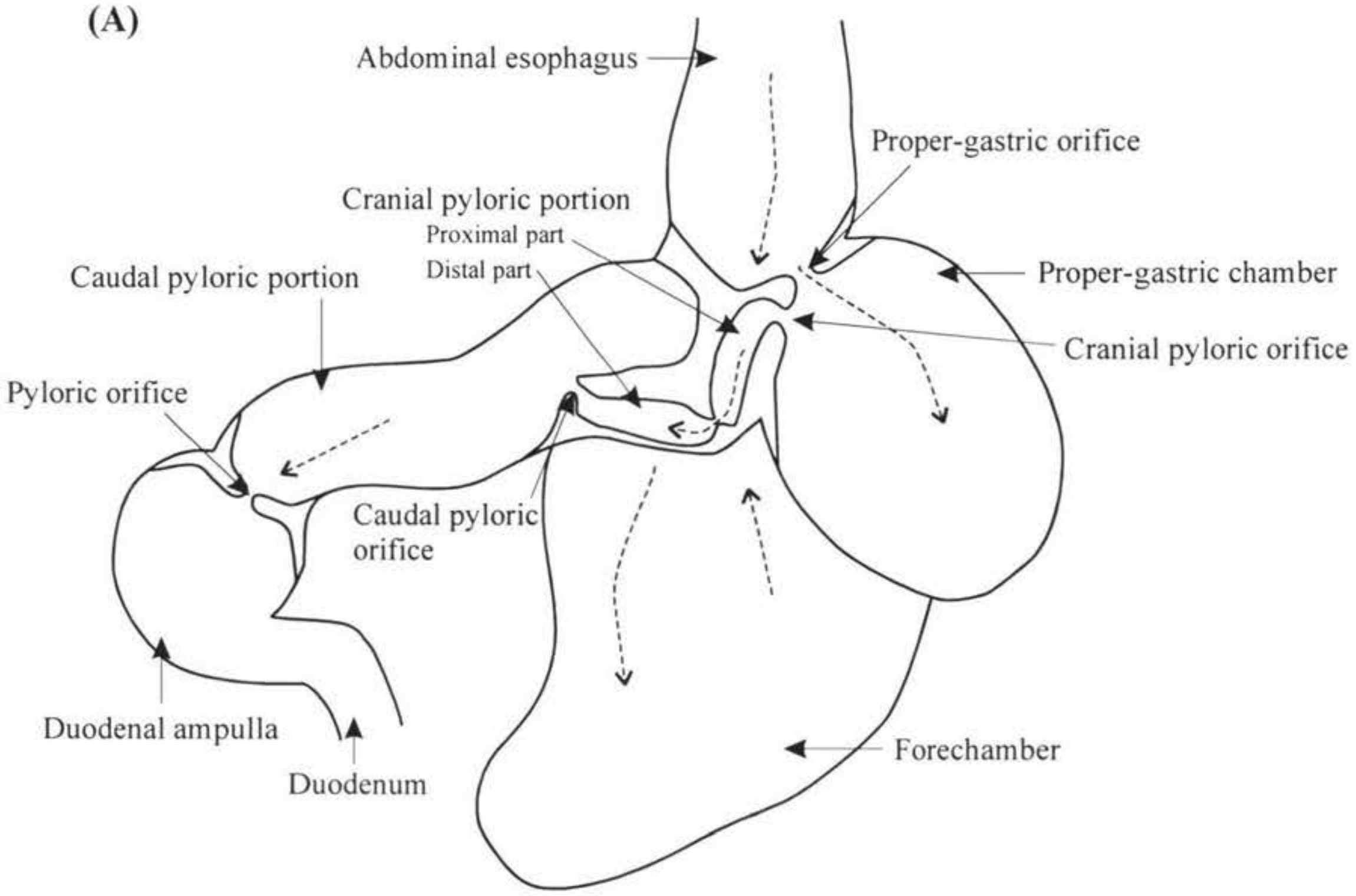

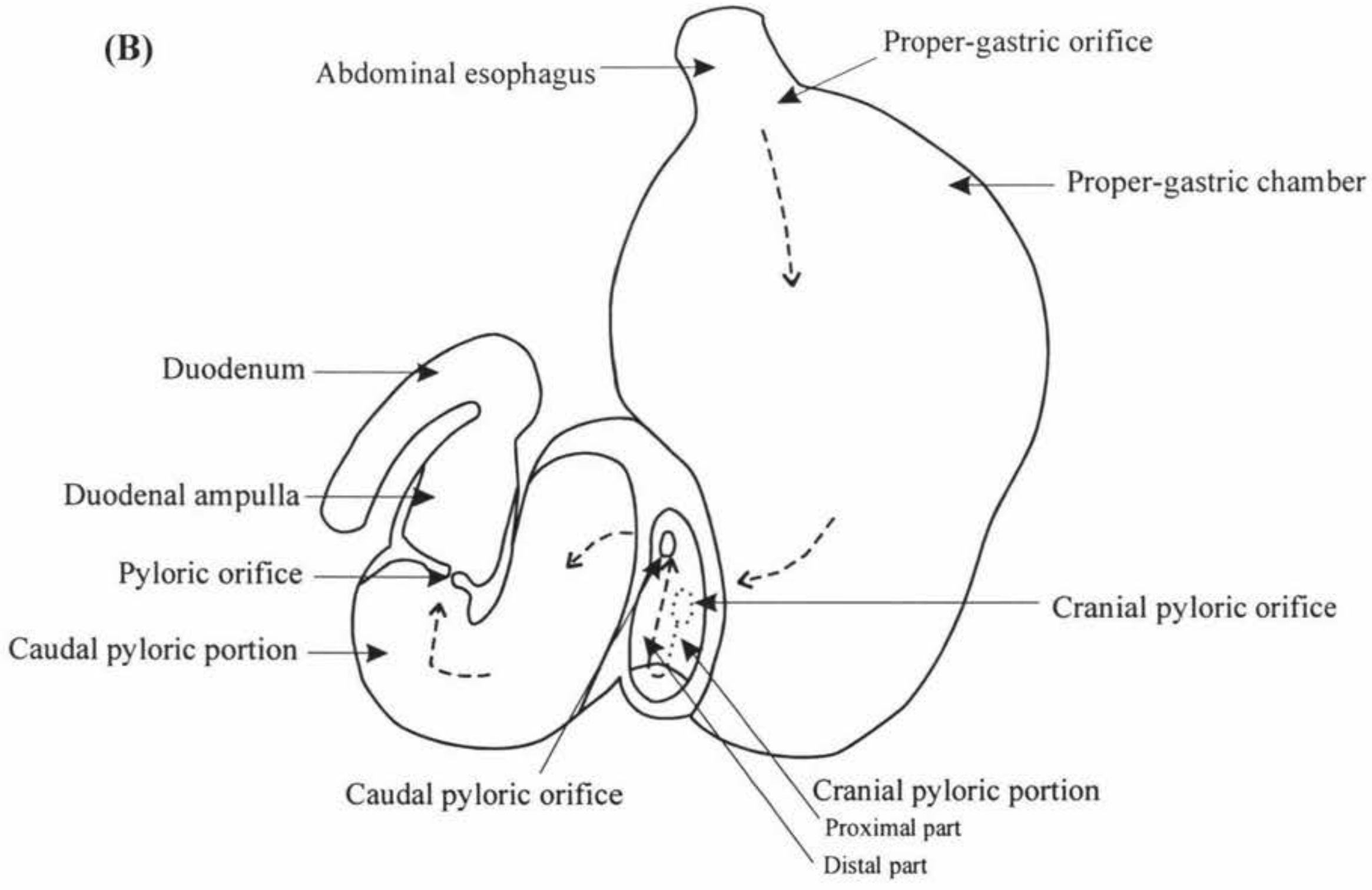

In this study, each compartment of the cetacean stomach is called a chamber. There are three main chambers. The non-glandular chamber is called the 'forechamber', the chamber containing proper-gastric glands is named 'proper-gastric chamber', and the succeeding chamber containing pyloric glands is named 'pyloric chamber' which is divisible into cranial and caudal portions. The connecting channel between the proper-gastric chamber and pyloric chamber is called the cranial portion of the pyloric chamber and the remainder of the chamber is the caudal pyloric portion. The duodenal ampulla is considered as a specialisation of the intestinal tract because a well developed pyloric sphincter separates the pyloric chamber from the ampulla and the ampulla is histologically similar to the duodenum proper (Yamasaki *et al.* 1974). It is therefore separate from the stomach.

Each of the chambers of the cetacean stomach will now be discussed separately as they differ from each other markedly.

2.3.2.2 External appearance of cetacean gastric forechambers

In baleen whales and some toothed whales, the forechamber is a large, pear-shaped chamber with a thick muscular wall and a tough white lining (Turner 1889, Harrison *et al.* 1970, Rice & Wolman 1990). The stomach of the long-finned pilot whale follows this generalised description (Murie 1873).

Some authors have described the forechamber to be a terminal sacculation of the esophagus (Harrison *et al.* 1970, Rice & Wolman 1990, Langer 1996). However, study of the morphogenesis of the forechamber reveals that it develops from a stomach bud without involvement from the esophagus (Amasaki *et al.* 1989 as cited by Olsen *et al.* 1994).

2.3.2.3 External appearance of cetacean proper-gastric chambers

In most baleen and toothed whales, the proper-gastric chamber is globular or elongate-oval and thick-walled (Figure 2.4A) (Turner 1889, Harrison *et al.* 1970, Rice & Wolman 1990). The stomach of the long-finned pilot whale follows this generalised description (Murie 1873). The proper-gastric chamber in the La Plata dolphin (*Pontoporia blainvillei*), Northern bottlenose whale (*Hyperoodon ampullatus*) and beaked whales is the first chamber of the stomach (Figure 2.4B) (Turner 1889, Yamasaki *et al.* 1974, Rice & Wolman 1990).

In most cetacean species, the proper-gastric chamber is a single compartment but in some species such as Sowerby's beaked whale (*Mesoplodon bidens*) the proper-gastric chamber is divided into two parts: cranial and caudal. The cranial and caudal parts are separated by an external constriction that corresponds to an internal mucosal fold or septum (Turner 1889, Yamasaki & Takahashi 1971, Yamasaki *et al.* 1974).

2.3.2.4 External appearance of cetacean pyloric chambers

The cranial portion of the pyloric chamber is present in baleen whales and some toothed whales and is not easily seen without opening the stomach (Turner 1889, Harrison *et al.* 1970, Yamasaki & Kamiya 1981, Rice & Wolman 1990). Therefore the cranial pyloric portion will be discussed in section 2.3.3.3: the internal appearance of cetacean pyloric chambers.

The caudal pyloric portion is thin-walled and can be tubular (Turner 1889, Harrison *et al.* 1970), spheroidal (Rice & Wolman 1990) or J-shaped (Yamasaki *et al.* 1974). It extends to the right of the proper-gastric chamber and caudally to end at the pyloric orifice (Harrison *et al.* 1970, Yamasaki & Kamiya 1981).

As mentioned in section 2.3.2, the stomachs of beaked whales have a greater number of chambers (Pfeiffer 1993). The extra chambers are sub-compartments of variable size that form an "A-shaped" figure and are separated by a series of external constrictions and internally by a broad fold of mucous membrane (Turner 1889, Pfeiffer 1993). They are comparable to the pyloric chamber of other cetaceans (Pfeiffer 1993). From personal observations during postmortem examination of a Cuvier's beaked whale (*Ziphius cavirostris*) the sub-compartments appear more like an inverted "U" shape.

2.3.2.5 Mesogastria of cetaceans

The mesogastria of the cetacean stomach are thin and transparent containing blood vessels and very little fat (Yamasaki & Takahashi 1971). In common and Risso's dolphins, the dorsal mesogastrium starts where the external surface of the forechamber wall is connected with the diaphragm, near the forechamber orifice, and runs on the left side of the proper-gastric chamber (Figure 2.5). It passes over the proper-gastric chamber and follows the fold between the proper-gastric and pyloric chambers. Then, with a sharp bend the dorsal mesogastrium crosses over to the pyloric chamber and follows the greater curvature of this chamber before passing over the pyloric orifice region and the duodenal ampulla to the duodenum proper (Figure 2.5) (Langer 1996). The small dorsal mesogastrium connects the proper-gastric chamber with the cranial end of the pyloric chamber (Langer 1996). The dorsal mesogastrium attaches the spleen to the forechamber in the common dolphin (Turner 1889), but in Risso's dolphin (*Grampus griseus*) the spleen is attached to the proper-gastric chamber (Langer 1996).

As with the dorsal mesogastrium, the ventral mesogastrium in the common and Risso's dolphins is attached to the external forechamber wall. The ventral mesogastrium extends over the cranial part of the proper-gastric chamber, follows the lesser curvature of the pyloric chamber and ends at the termination of the pancreatico-choledochal ampulla as it empties into the duodenal ampulla (Figure 2.5) (Langer 1996).

2.3.2.6 Blood, lymphatic and nerve supply of cetacean stomachs

The blood supply of cetacean stomachs varies between species (Langer 1996). Some patterns of branching are similar to those of the simple and complex stomachs of terrestrial mammals. Other patterns of branching are different with the celiac artery having extra branches (Langer 1996).

2.3.2.7 Size of cetacean stomachs

In baleen whales and most adult toothed whales, the forechamber is the largest chamber followed by the proper-gastric and pyloric chambers (Smith 1972, Yamasaki *et al.* 1974). For example, in minke whales (*Balaenoptera acutorostrata*) the maximal capacity of the forechamber is 68-321 l, the proper-gastric chamber 63-100 l, and the pyloric chamber 18-39 l, representing 44-70%, 22-44% and 11% of the total expanded stomach volume, respectively (Olsen *et al.* 1994).

The variability in volumes of the forechamber and proper-gastric chamber is because of the large orifice between the two chambers (Olsen *et al.* 1994).

Figure 2.5 Schematic diagram of the attachments of the dorsal and ventral mesogastria to the stomach of the common dolphin (*Delphinus delphis*) (modified from Langer 1996)

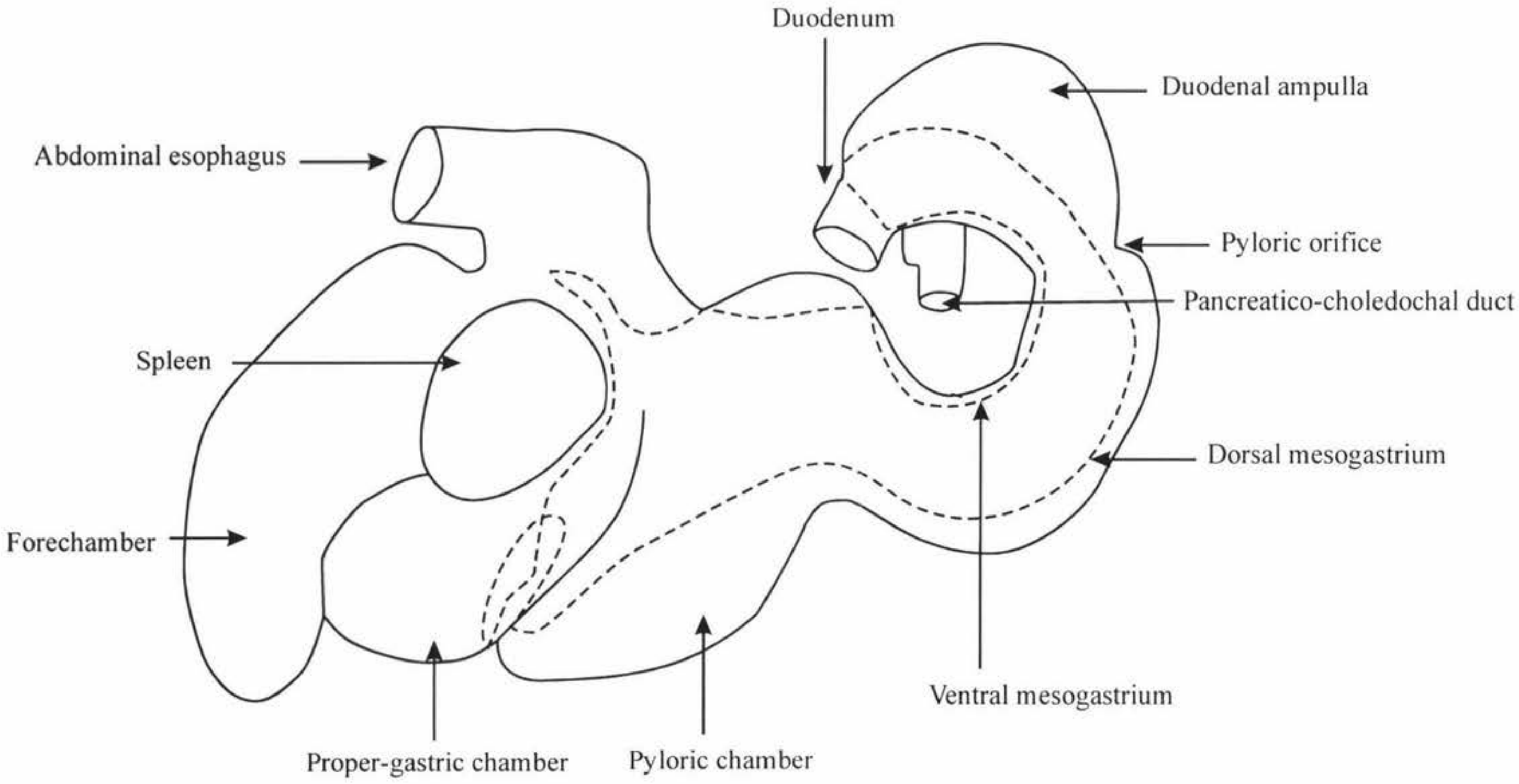

A large forechamber is not present in all cetaceans. For example, the Boutu dolphin (*Inia geoffrensis*), pygmy sperm whale (*Kogia breviceps*) and juvenile toothed whales have a forechamber smaller than the proper-gastric chamber (Yamasaki & Kamiya 1981, Rice & Wolman 1990, Langer 1996). However, in juvenile toothed whales, postnatal growth of the forechamber increases the size and volume relative to other chambers (Langer 1996). Postnatal growth in toothed whales is also accompanied by an increase in size and volume of the proper-gastric chamber, and a decrease of the pyloric chamber (Langer 1996). This suggests stomach size and volume are influenced by the physical and biochemical characteristics of the diet, quantity of food ingested and rates of ingestion (Olsen *et al.* 1994, Langer 1996).

There is no general trend regarding the proportional size of the proper-gastric chamber in species without a forechamber (Yamasaki *et al.* 1974, Yamasaki & Kamiya 1981). In some species such as the La Plata dolphin it is larger than most other species and in some such as Cuvier's beaked whale it is smaller. The larger proper-gastric chamber may compensate for the absent forechamber (Yamasaki *et al.* 1974, Yamasaki & Kamiya 1981).

2.3.2.8 Stomach contents of cetaceans

Like that of pinnipeds, analyses of regurgitates, stomach contents and fecal samples have shown cetaceans are opportunistic feeders and the predominance of particular prey items varies geographically and seasonally (Evans 1987, Young & Cockcroft 1994, Blanco *et al.* 1995). This is also true of long-finned pilot whales which show seasonal movements towards the coast, related to inshore movements of mostly oceanic, neritic or inshore gregarious squid and luminous squid species (Desportes & Mouritsen 1993). The long-finned pilot whale diet is predominantly cephalopods such as the short-finned squid (*Illex illecebrosus*), long-finned squid (*Loligo pealei*), *Sepioteuthis australis, Nototodarus gouldi, Sepia apama*, *Gonatus* species and *Todarodes sagittatus* (Gales & Pemberton 1992, Desportes & Mouritsen 1993, Gannon *et al.* 1997). Other less frequent prey items include fish species such as greater Argentine (*Argentina silus*), and blue whiting (*Microcesistius poutassou*); shrimps (*Pandalus montagui*); and miscellaneous items such as feathers, algae, polychaete worms and gastropods (Gales & Pemberton 1992, Desportes & Mouritsen 1993, Gannon *et al.* 1997). Indigestible items such as fishing hooks, nylon threads, plastic bags and stones have been observed in long-finned pilot whale stomachs and have proven fatal in some cases (Desportes & Mouritsen 1993, Gorzelany 1998).

2.3.3 Internal appearance of cetacean stomachs

In baleen whales and some toothed whales, the esophagus empties into the forechamber via the forechamber orifice. The forechamber opens into the more ventral proper-gastric chamber, via the proper-gastric orifice located near the forechamber orifice (Figure 2.4A) (Home 1807, Harrison *et al.* 1970, Olsen *et al.* 1994). The proper-gastric chamber opens into the pyloric chamber via the cranial pyloric orifice in the cranial or caudal wall of the proper-gastric chamber (Figure 2.4A) (Turner 1889, Smith 1972, Yamasaki & Kamiya 1981, Rice & Wolman 1990). When the cranial pyloric orifice is in the cranial wall it is closely associated with the proper-gastric orifice and the proper-gastric chamber appears like a suspended sac (Harrison *et al.* 1970). The cranial pyloric portion opens into the caudal pyloric portion via the caudal pyloric orifice. The caudal pyloric portion is separated from the intestinal tract by the pyloric orifice, which consists of a well-developed sphincter (Harrison *et a*l. 1970).

The orifices are identified by an aperture of reduced diameter and by an abrupt change in the lining between chambers. There are no visible anatomical sphincters present (Smith 1972, Yamasaki *et al.* 1974, Yamasaki & Kamiya 1981, Rice & Wolman 1990).

2.3.3.1 Internal appearance of cetacean forechambers

The lining of the empty forechamber has well-developed longitudinal rugae with a few shorter transverse folds that allow distension of the chamber (Harrison *et al.* 1970, Yamasaki & Takahashi 1971, Smith 1972). The mucosa is unmarked by pores or pits, which is in accordance with its non-glandular nature, except for a narrow zone of scattered papillary projections located in the proximity of the forechamber and proper-gastric orifices in the narwhal (*Monodon monoceros*) (Turner 1889).

At the proper-gastric orifice, several mucosal folds project into the forechamber and may prevent the movement of fish bones and large pieces of digesta from leaving the forechamber, as solid material has only ever been found in the forechamber (Home 1807, Turner 1868, 1889; Smith 1972). In a single common dolphin, there was a canal between the forechamber and proper-gastric chamber that opened into the latter by a projecting orifice (Home 1807). Other subsequent authors have not identified this canal (Harrison *et al.* 1970, Yamasaki & Kamiya 1981, Rice & Wolman 1990).

2.3.3.2 Internal appearance of cetacean proper-gastric chambers

The lining of the proper-gastric chamber is arranged into a number of low or deep longitudinal rugae, with numerous, shorter, interdigitating transverse folds. The rugae increase the surface area and create a labyrinth or honeycomb appearance (Turner 1889, Harrison *et al.* 1970, Smith 1972). A fold of membrane separates the proper-gastric and cranial pyloric orifices, and could be a short food channel (Turner 1889, Harrison *et al.* 1970).

2.3.3.3 Internal appearance of cetacean pyloric chambers

As mentioned in section 2.3.2.4, the cranial pyloric portion can not easily be seen externally. In oceanic dolphins, it is closely associated with the wall of the proper-gastric chamber, but in the narwhal and beluga whale (*Delphinapterus leucas*) it has no direct association (Turner 1889). The length and configuration of the cranial pyloric portion varies among groups of cetacean species (Rice & Wolman 1990). It can be narrow and long, wide and short, or spheroidal. In some oceanic dolphins and the narwhal and beluga whale, the cranial pyloric portion is divided into two parts by a septum, or remains as a single channel in the harbour porpoise (*Phocoena phocoena*) and white-beaked dolphin (*Lagenorhychus albirostris*) (Turner 1889). It may have sphincter-like functions (Harrison *et al.* 1970, Olsen *et al.* 1994).

A few shallow mucosal folds line the pyloric chamber (Yamasaki & Takahashi 1971, Smith 1972, Yamasaki & Kamiya 1981).

2.3.3.4 Pathology of cetacean stomachs

As in pinnipeds, non-parasitic and parasitic ulceration of the esophagus and stomach occurs in captive and stranded cetaceans (Vik 1964, Geraci & Gerstmann 1966, Simpson & Gardner 1972). The reasons for the ulcers are similar to those described for pinnipeds in section *2.2.3.1*.

2.4 **Microscopic anatomy of pinniped stomachs**

2.4.1 Basic layers of pinniped stomachs

The microscopic anatomy of the pinniped stomach is similar to the typical mammalian plan. The stomach wall is composed of a series of layers arranged from the lumen-outwards as follows:

1) tunica mucosa consisting of lamina epithelialis mucosae, lamina propria mucosae and lamina muscularis mucosae;
2) tunica submucosa;
3) tunica muscularis; and
4) tunica serosa (Figure 2.6) (Williams *et al.* 1989).

The tunica mucosa of the stomach has three different zones: cardiac, proper-gastric and pyloric. Simple columnar mucous epithelial cells line these zones and extend to line the gastric pits formed by invaginations of the tunica mucosa (Simpson & Gardner 1972, Schumacher *et al.* 1995). At the base of the gastric pits are zymogenic glands (Figure 2.7) that extend into the lamina propria mucosae (Williams *et al.* 1989). Each zymogenic gland has a lumen lined by different cells depending on the zone and is divided into three regions: upper, middle and basal (Figure 2.7). Cells that may be present along these regions include mucous neck cells, parietal, zymogenic and scattered enteroendocrine cells (Karam & Leblond 1995). Other cells include dividing, immature and maturing surface epithelial cells, which are found in the upper and middle regions and constitute the germinal zone from which surface and epithelial cells of the tunica mucosa are renewed (Karam & Leblond 1995). The location of the zones and the type of zymogenic glands present will be discussed in following sections. The epithelial cells and some cells of the zymogenic glands secrete mucus, which is thought to act as a vehicle for proton transport toward the gastric lumen. At the same time the mucus constitutes a barrier to prevent proton back-diffusion, thereby preventing autodigestion and ulceration of the stomach wall (Schreiber & Shield 1997).

The lamina muscularis mucosae is a thin smooth muscle layer that produces independent local movement and folding of the mucosa to facilitate digestion by bringing the mucosa into closer contact with ingesta (Cormack 1993). Evidence from electron microscopy suggests an additional or alternative function: that of expressing and moving glandular secretions by extending muscle fibers upward into the epithelium causing slight contractions of the glands and thereby inducing the release of their glandular secretions (Di Fiore 1963).

The connective tissue layers of the lamina propria mucosae and tunica submucosa are composed of elastic and collagen fibres that unite the glandular and muscular layers of the stomach wall. These connective tissue layers allow movement of the stomach wall layers and along with the lamina muscularis mucosae, form the characteristic mucosal rugae (Dyce *et al.* 1996). They also provide support and protection for glands, major blood vessels, lymphatic and nerve plexuses (Dyce *et al.* 1996). In the Weddell seal, the vascular submucosal plexus is extensive and the veins have valves and heavy muscular walls (Eastman & Coalson 1974).

The tunica muscularis consists of smooth muscle that can be composed of up to three layers. It moves independently of the lamina muscularis mucosae and is responsible for the mechanical break down of ingesta in the stomach and movement of luminal contents through the stomach by peristalsis (Dyce *et al.* 1996).

The tunica serosa covers the entire external surface of the stomach, adhering to the tunica muscularis, except along the curvatures where it is reflected to form the omenta (Dyce *et al.* 1996).

2.4.2 Cardiac zone of pinniped stomachs

In the Weddell seal, the cardiac zone lines the cardiac region of the stomach. It has a thin tunica mucosa with long gastric pits and tubular glands. The glands have short upper portions and branched or coiled basal portions and are lined by mucous neck cells with a few gastric argentaffin cells (Eastman & Coalson 1974). The mucous neck cells synthesise and store mucigen granules, mucigen being a precursor to a more acidic glycoprotein and less-viscous mucus (Schreiber & Shield 1997). In the harbour seal (*Phoca vitulina*) and Steller sea lion there is no cardiac zone (Pilliet 1894 as cited by Eastman & Coalson 1974).

Figure 2.6 Schematic diagram of the structure of the typical mammalian stomach wall

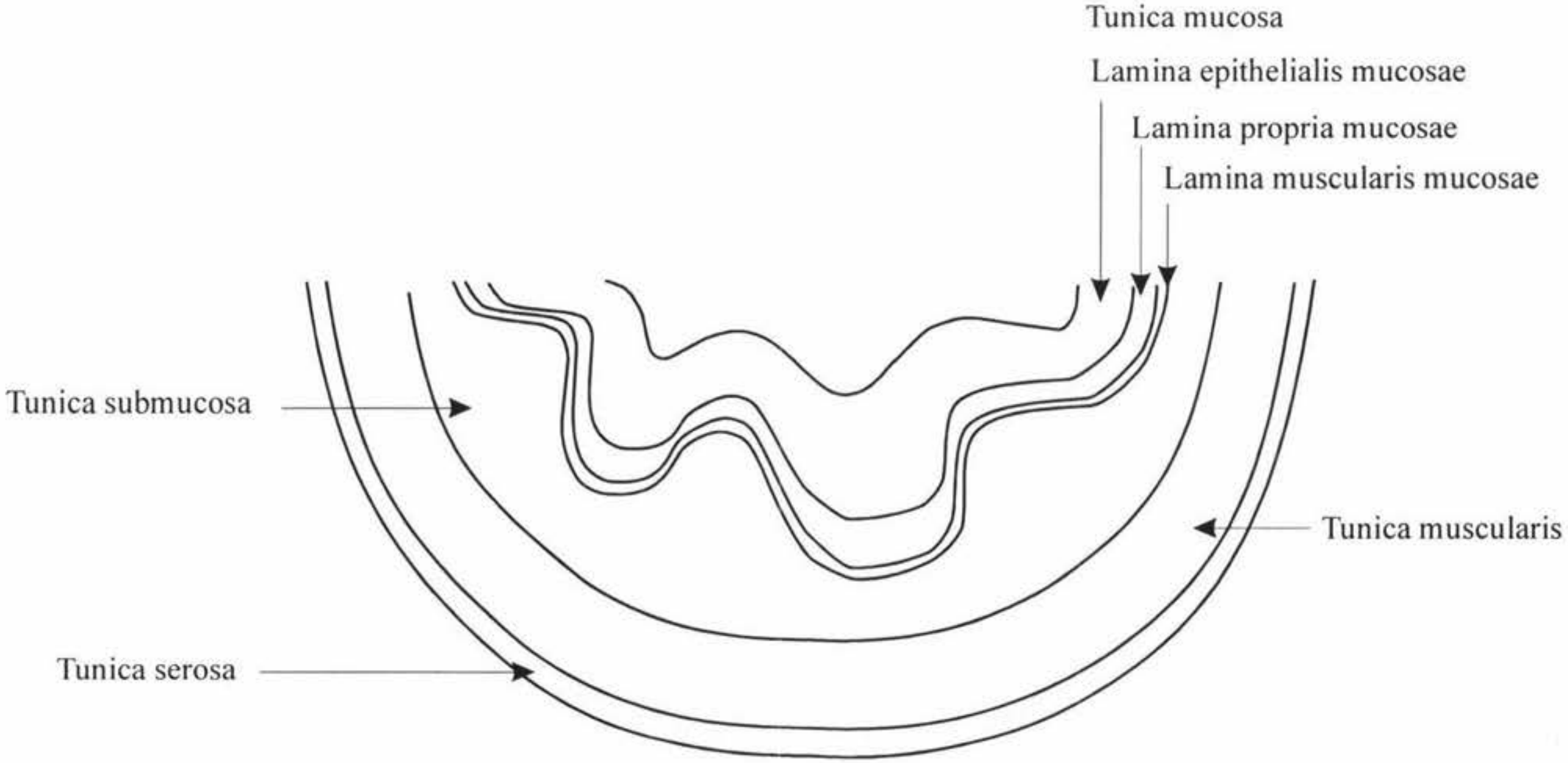

2.4.3 Proper-gastric zone of pinniped stomachs

In the Weddell seal, harbour seal and Steller sea lion the proper-gastric zone lines the fundic and proper-gastric regions of the stomach (Pilliet 1894 as cited by Eastman & Coalson 1974). In the harbour seal and Steller sea lion the proper-gastric zone also lines the cardiac region of the stomach (Pilliet 1894 as cited by Eastman & Coalson 1974). The proper-gastric zone has a thick tunica mucosa with shallow gastric pits and long proper-gastric glands, which are the most widely distributed type of mucosal gland in the stomach (Eastman & Coalson 1974). The proper-gastric glands have straight upper and middle portions lined with mucous neck and parietal cells, while the basal portions are slightly coiled and lined with chief cells. A few parietal and entero-endocrine cells are also present in the basal portions (Eastman & Coalson 1974).

Parietal cells are large, oval cells located on the outside of zymogenic glands. They synthesise and secrete hydrochloric acid (HCl) and bicarbonate ions (HCO_3^-) (Harrison *et al.* 1970, Olsen *et al.* 1994, Schumacher *et al.* 1995). Parietal cells are more abundant in marine mammals than in other mammals, which suggests either a greater volume of HCl is produced or that individual cell activity is relatively low (Smith 1972).

The chief cells are smaller than parietal cells and are situated next to the lumen of the gland (Olsen *et al.* 1994). They synthesise and secrete pepsinogen. Pepsinogen is a precursor to the protein pepsin and is optimally activated in the stomach at pH 1.0-3.0 and activated progressively less as pH rises (Simpson & Gardner 1972, Karam & Leblond 1995).

In the Weddell and crabeater seals, six types of gastric enteroendocrine cells have been found (Schumacher *et al.* 1995). They are crescent-shaped cells with an irregular-shaped nucleus and have lateral cytoplasmic extensions that grip around the neighbouring cells (Schumacher *et al.* 1995).

In the crabeater seal, the proper-gastric mucosa is thicker than that of the Weddell seal. The greater thickness is because of the longer length of the glands, which would increase the amount of mucus, HCl and gastric enzymes produced. The increased gastric secretions are required for the digestion of krill, which makes up a large proportion of the crabeater seals diet (Schumacher *et al.* 1995).

Figure 2.7 Schematic diagram of the structure of the typical mammalian stomach wall (modified from Karam & Leblond 1995)

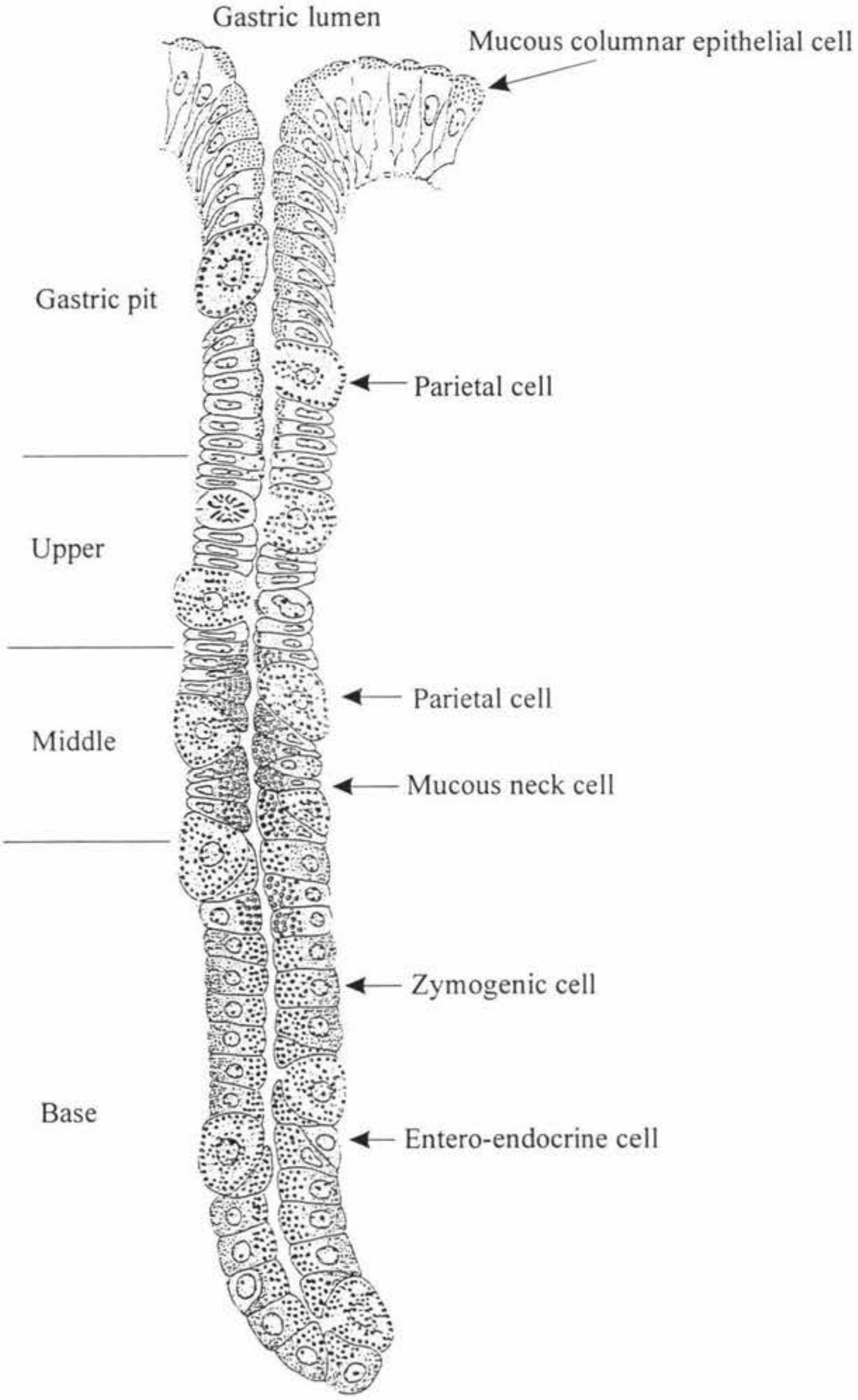

In the harbour seal, small villi line the proper-gastric and pyloric zones (Oppel 1896 as cited by Eastman & Coalson 1974) and in the Weddell seal, line the pyloric zone of the stomach (Eastman & Coalson 1974).

2.4.4 Pyloric zone of pinniped stomachs

The pyloric zone of the pinniped stomach lines the pyloric antrum and canal (Eastman & Coalson 1974). This zone has a thinner mucosa than that of the cardiac and proper-gastric zones, and has deep and irregular gastric pits and pyloric glands. The pyloric glands have short upper portions and poorly developed pleomorphic (simple or branched and straight or coiled) bases containing pyloric mucous cells and some scattered parietal cells (Eastman & Coalson 1974).

2.5 **Microscopic anatomy of cetacean stomachs**

2.5.1 Basic layers of cetacean stomachs

The basic layers of the cetacean stomach are similar to those of the pinniped stomach described in section 2.4. However, some differences are evident and these will be discussed in the following sections.

2.5.2 Cardiac zone of cetacean stomachs

A narrow cardiac zone adjacent to the termination of the esophageal mucosa has been observed in the blue whale (*Balaenoptera musculus*), minke whale, La Plata, Boutu and Ganges dolphins (*Platanista gangetica*) (Hosokawa & Kamiya 1971, Yamasaki & Kamiya 1981, Olsen *et al.* 1994). A cardiac zone is absent in the harbour porpoise (Smith 1972).

2.5.3 Forechamber of cetacean stomachs

The forechamber of cetaceans is lined by non-glandular stratified squamous epithelium that may be superficially keratinised (Harrison *et al.* 1970, Smith 1972, Yamasaki & Kamiya 1981, Olsen *et al.* 1994). The lining of the forechamber is analogous to the epithelial lining of the ruminant forechambers i.e., rumen, reticulum and omasum (Hosokawa & Kamiya 1971, Tarpley *et al.* 1987).

In their review, Olsen *et al.* (1994b) divide the forechamber epithelium into three layers according to the cells present: basal, intermediate and superficial. The basal stratum is the innermost single layer of strongly basophilic cuboidal (Olsen *et al.* 1994) or columnar (Harrison *et al.* 1970, Smith 1972) cells that abut the basal lamina. They are the germinative cells that give rise to the cells in the intermediate stratum. The intermediate stratum consists of layers of cells that become increasingly flattened as they move closer to the superficial stratum. The superficial stratum is the outer layer of non-nucleated, squamous cells, which contain only a few small granules in their cytoplasm (Harrison *et al.* 1970, Smith 1972, Olsen *et al.* 1994).

The lamina propria mucosae of the forechamber has numerous, prominent, irregular connective tissue papillae, which invaginate the epithelium. In some species the papillae occupy up to 80% of the total thickness of the epithelium (Yamasaki & Takahashi 1971, Rice & Wolman 1990, Olsen *et al.* 1994). These papillae anchor the epithelium to the tunica submucosa to allow independent movement of the epithelium to the tunica muscularis (Smith 1972).

2.5.4 Proper-gastric chamber of cetacean stomachs

The wall of the proper-gastric chamber is similar to the proper-gastric zone in pinnipeds (section 2.4.3). The gastric pits are approximately one-sixth the length of the simple, tubular glands that show little evidence of branching (Harrison *et al.* 1970, Yamasaki & Kamiya 1981, Olsen *et al.* 1994). Mucous neck cells are present along the proper-gastric glands in the sei (*Balaenoptera borealis*), fin (*Balaenoptera physalus*), blue and minke whales, Ganges and La Plata dolphins and in the Pacific white-sided dolphin (*Lagenorhynchus obliquidens*) (Hosokawa & Kamiya 1971, Yamasaki *et al.* 1974, Olsen *et al.* 1994). However, no mucous neck cells have been found in the bottlenose, common, long-snouted spinner or Boutu dolphins, or in the pygmy sperm whale (Harrison *et al.* 1970, Yamasaki & Kamiya 1981, Rice & Wolman 1990).

Typical parietal and chief cells are present along the proper-gastric glands (Tarpley *et al.* 1987, Rice & Wolman 1990, Olsen *et al.* 1994). The chief cells are more abundant than parietal cells: the ratio being approximately 3:1 (Hosokawa & Kamiya 1971, Yamasaki & Takahashi 1971, Yamasaki *et al.* 1974). No argentaffin cells have been seen after selective staining (Harrison *et al.* 1970).

The tuncia muscularis layer is thinner in the proper-gastric chamber than in the forechamber (Harrison *et al.* 1970, Yamasaki & Takahashi 1971, Rice & Wolman 1990).

Pfeiffer (1993) observed intercalated striations in the tunica muscularis of the proper-gastric chamber in Cuvier's beaked whale that resembled intercalated discs commonly observed in cardiac tissue of most vertebrates. These striations, as well as extensive colonic myenteric plexuses, were also found in the tunica muscularis of the colon of beluga whales (Pfeiffer 1993). The striations may be involved in voluntary or involuntary gastrointestinal motility, i.e., ingestion by sucking in beaked whales and acute rectal discharge escape mechanism in beluga whales (Pfeiffer 1993).

2.5.5 Pyloric chamber of cetacean stomachs

The wall of the pyloric chamber is similar to the pyloric zone in pinnipeds (section 2.4.4). The tunica mucosa contains short, tubular glands lined with predominantly columnar mucus (Harrison *et al.* 1970, Simpson & Gardner 1972, Olsen *et al.* 1994) or sero-mucus cells (Yamasaki *et al.* 1974). Argentaffin cells are present and secrete gastrin, which triggers the release of HCl by the parietal cells (Harrison *et al.* 1970, Smith 1972, Yamasaki *et al.* 1974). There is also indirect evidence that the argentaffin cells contain a powerful stimulant of smooth muscle contraction (Benditt & Wong 1957), suggesting they are involved in the hormonal control of peristalsis in the pyloric chamber rather than control of HCl secretion (Smith 1972).

2.6 **Function of pinniped and cetacean stomachs**

The pinniped stomach uses mechanical and biochemical digestion to break down ingesta. Peristalsis causes small particles to pass through the stomach, while larger particles and relatively indigestible parts of prey are either retained for further digestion or are vomited (Needham 1985, Richardson & Gales 1987). In pinnipeds, larger particles could be prevented from reaching the pyloric orifice by ingested stones or by the sharply bent incisura angularis and narrow pyloric canal, or as in the Australian sea lion (*Neophoca cinerea*) by a pyloric torus and fossa that act as a secondary valve (Richardson & Gales 1987).

The stomach of cetaceans is more complex, with storage and mechanical break down occurring in the forechamber, biochemical digestion in the proper-gastric chamber and peristalsis causing the movement of particles into successive chambers (Green 1972, Simpson & Gardner 1972, Pfeiffer 1993). In cetaceans that lack a forechamber, storage, mechanical and biochemical digestion occur in the proper-gastric chamber (Yamasaki *et al.* 1974). The cranial portion of the pyloric chamber prevents the onward flow of swallowed sea water, regulates the flow of liquids from the proper-gastric chamber and prevents large chunks of material from entering the caudal portion of the pyloric chamber (Harrison *et al.* 1970, Yamasaki *et al.* 1974, Rice & Wolman 1990). The mucus secreted by the pyloric glands buffers the pH of digesta before it enters the duodenum, and the pyloric orifice regulates the flow of digesta into the duodenum and prevents back-flow of duodenal contents (Smith 1972, Yamasaki & Takahashi 1971).

In pinnipeds and cetaceans, mechanical break down is vigorous and biochemical digestion of the readily digestible parts of prey is rapid. Initial defecation times (IDT's) of 5-6 hours and up to 18 hours has been recorded for some pinniped species, and 8 hours for cetaceans (Sergeant 1962 as cited by Desportes & Mouritsen 1993, Helm 1984, Richardson & Gales 1987).

2.7 **General Summary**

This review of literature has detailed the structure of pinniped and cetacean stomachs. In summary the stomachs of pinnipeds and cetaceans differ in their macroscopic and microscopic anatomy. Possible reasons for these differences could be related to their phylogeny, environment, diets and methods of feeding or because of body size and metabolism.

Chapter Three

Materials and Methods

3.1 **Animals used**

Gross observation and macroscopic dissection was carried out on the thoracic and abdominal viscera of cadavers of 10 New Zealand fur seals and 7 long-finned pilot whales. The stomachs were obtained from 8 juveniles (4 female and 4 male), 1 subadult (female) and 1 adult (male) New Zealand fur seals (Table 3.1); and from 5 juveniles (3 female and 2 male), 1 fetal (male) and 1 subadult (male) long-finned pilot whales (Table 3.2). Most animals studied had come ashore and died (Appendix 3) but had no visible injuries that involved the digestive tract.

The small sample size of animals used in this study is because of the restriction of using animals that strand and die around New Zealand's coastlines and at the time this study was undertaken the animals used were all that were available.

3.2 **Preliminary gross observations and measurements**

All reference in the following text to the "fur seal" relates to the New Zealand fur seal (Af) and to the "pilot whale" relates to the long-finned pilot whale (Gm).

The fur seals were identified using descriptions listed in King (1983). Sites where study animals were collected are rarely reached by other species of fur seals such as the Australian fur seal (*Arctocephalus pusillus doriferus*) and Subantartic fur seal (*Arctocephalus tropicalis*), but morphology is sufficient to distinguish these species from the New Zealand fur seal (King 1983). The pilot whales were identified by reference to the species directory compiled by Baker (1990).

Standard body lengths of fur seals (Table 3.1) were measured according to the criteria published by the American Society of Mammalogists (1967) and of pilot whales (Table 3.2) according to Nishiwaki (1972). Standard lengths were used to estimate the maturity of fur seals as defined by Crawley (1975) and of pilot whales (Table 3.2) as defined by Desportes & Mouritsen (1993).

Table 3.1 Details of New Zealand fur seals sampled

Specimen	Code	Maturity†	Sex	Condition when sampled	Standard length (cm)	Body weight (kg)
Af1	CW174	Juvenile	M	Preserved*	96.0	11.0
Af2	CW183	Subadult	F	Fresh	127.0	23.5
Af3	CW185	Juvenile	M	Fresh	93.0	9.0
Af4	CW186	Juvenile	M	Fresh	78.0	7.5
Af5	CW188	Juvenile	F	Fresh	80.0	7.5
Af6	CW197	Juvenile	F	Thawed	71.0	7.0
Af7	CW198	Juvenile	F	Thawed	97.0	11.5
Af8	CW199	Juvenile	F	Thawed	77.0	7.5
Af9	CW211	Adult	M	Thawed	164.0	55.6
Af10	CW216	Juvenile	M	Preserved‡	93.0	10.3

M = male, F = female

†Defined using standard lengths (Crawley 1975)

*Kaiserling I solution

‡10% formalin solution

Body weights of all 10 fur seals (Af.1-Af.10) (Table 3.1) and 1 pilot whale (Gm.2) (Table 3.2) were measured on a Tru test, Economy Plus, Model 700 scales. Four pilot whales (Gm.3-Gm.6) dissected on the beach were not weighed due to their large size and the lack of appropriate equipment. The weights of 7 pilot whales (Gm.1-Gm.7) (Table 3.2) were calculated using standard lengths and the following equation where W = weight in kg and L = standard length in cm, published by Bryden (1972).

$$W = 0.000025 \ L^{2.895}$$

3.3 **Macroscopic dissection**

All 10 fur seals (Af.1-Af.10) and 2 of the 7 pilot whales (Gm.2, Gm.7) were dissected in the laboratory. Five pilot whales (Gm.1, Gm.3-Gm.6) were dissected on the beach where they stranded. All animals were freshly dead when found and of these 4 fur seals (Af.2-Af.5) and 5 pilot whales (Gm.1, Gm.3-Gm.6) were dissected while fresh. The other 6 fur seals (Af.1, Af.6-Af.10) and 2 pilot whales (Gm.2, Gm.7) were preserved and dissected later. Of the preserved specimens, 2 fur seals (Af.1, Af.10) were preserved by intravenous infusion of Kaiserling I solution through cannulae in an external jugular vein and a common carotid artery. This procedure simplified storage in a chiller and permitted careful study over a lengthy period of time. Four fur seals (Af.6-Af.9) and 2 pilot whales (Gm.2, Gm.7) were frozen for simple storage and thawed prior to dissection.

3.3.1 Macroscopic dissection procedure for fur seals

The 10 fur seal cadavers were positioned in dorsal recumbency and an incision was made through the skin along the ventral midline, from the genital aperture to the first rib. The cut extended through the blubber, muscle, and the pleura and peritoneum membranes lining the thoracic and abdominal cavities, respectively. The diaphragm was cut away from the sternum and ribs. Ribs 7, 8 and 9 were detached from the sternum using bone cutters and reflected to expose the caudal region of the thoracic cavity and the cranial region of the abdominal cavity. In 9 fur seals (Af.1-Af.9) the lungs, liver and intestinal coils were removed to expose the stomach, which was tied off from the esophagus and duodenum by string.

Table 3.2 Details of long-finned pilot whales sampled

Specimen	Code	Maturity†	Sex	Condition when sampled	Standard length (cm)	Pectoral Flipper length (cm)	Body weight (kg)*
Gm1	CW200	Newborn	F	Fresh	167.5	39.0	68.6
Gm2	CW203	Newborn	F	Thawed	185.0	38.0	91.5
Gm3	X1	Fetus	M	Fresh	168.0	37.0	69.2
Gm4	X38	Juvenile	M	Fresh	233.0	49.0	178.4
Gm5	X3	Juvenile	M	Fresh	270.0	49.0	273.4
Gm6	X2	Subadult	M	Fresh	310.0	59.0	407.8
Gm7	WB97-25Gm	Newborn	F	Thawed	172.5	39.50	74.7

M = male, F = female

†Defined using standard lengths (Desportes & Mouritsen 1993)

*Calculated using standard lengths in formula given by Bryden (1972)

The stomach was separated from the diaphragm, from the esophagus approximately 1 cm cranial to the esophageal junction, from the duodenum approximately 1 cm caudal from the pyloric sphincter and from the spleen.

Photographs and sketches of lateral and ventral views of the thoracic cavity and abdomen of 2 fur seals (Af.1, Af.10) were taken throughout the dissections to facilitate comparisons and for the production of illustrations.

Once measurements and tissue samples had been taken, the stomachs of all 10 fur seals were labeled, immersed in 10% formalin solution and stored for future reference. The dissection of 1 fur seal (Af.1) that had been preserved was undertaken over a number of weeks. The skin and muscle layers were folded back over the cadaver between dissections and it was wrapped in a damp sheet that was occasionally soaked in 4% formalin to prevent the tissues from drying out when stored in the chiller.

3.3.2 Macroscopic dissection procedure for pilot whale

The dissections of 6 pilot whales (Gm.2-Gm.7) undertaken in the laboratory and on the beach were similar to the fur seals, with a few differences. With the whales lying on their right side two incisions were made through the skin, blubber and muscle layers from the first rib to the genital slit: one along the ventral midline, the other lateral to the vertebral column on the left side. The skin, blubber and muscle layers were removed, followed by the ribs by separating them from the sternum and at their articulation with the vertebrae. The diaphragm was detached, the lungs, liver and spleen removed, whereupon the stomach was also removed. Photographs of lateral views of the thoracic cavity and abdomen of 1 pilot whale (Gm.2) were taken throughout the dissection and of the removed stomachs of 3 pilot whales (Gm.1-Gm.2, Gm.6) to facilitate comparisons and for the production of illustrations.

Once measurements and tissue samples had been taken, the stomachs of all 7 pilot whales were labeled, immersed in 10% formalin solution and stored for future reference.

The dissection of 1 pilot whale (Gm.1) was undertaken on the beach by Department of Conservation and Massey University staff. The stomach was removed and histology samples were taken 5.5 hours after death.

3.3.3 External stomach measurements

External measurements of the stomachs of 8 fur seals (Af.1, Af.4-Af.10) and 6 pilot whales (Gm.2-Gm.6) were made with a metal tape measure.

3.3.4 Stomach weight

The stomachs with mesenteries attached from 6 fur seals (Af.4-Af.9) and 5 pilot whales (Gm.2-Gm.6) were weighed on a Mettler P10 electronic scale.

3.3.5 Stomach volume

In 5 pilot whales (Gm.2-Gm.6), total stomach volume was measured. The pyloric sphincter was tied off tightly with string and clamps and a known volume of tap water at ambient temperature was slowly poured, via a funnel, into the esophageal opening of the empty stomach until it was full. In 5 pilot whales, the volume of each chamber was measured by tying off the opening between consecutive chambers and pouring in a known volume of tap water until full.

Relative volumes of each chamber to total stomach volume were also calculated for 5 pilot whales (Gm.2-Gm.6). For example, total forechamber volume, proper-gastric chamber volume, and pyloric chamber volume as percentages of total stomach volume.

3.3.6 Stomach mucosal morphology, wall thickness, and openings of stomach

In 9 fur seals (Af.1-Af.9) and 6 pilot whales (Gm.1-Gm.6), an incision was made through the depth of the stomach wall along the cranio-caudal axis to examine the mucosal surface. The number and orientation of mucosal folds, colour and texture of mucosa and the presence of parasites or other stomach contents were recorded. In 8 fur seals (Af.2-Af.9) and 5 pilot whales (Gm.2-Gm.6) the thickness of the stomach wall and the diameter of the cardiac and pyloric orifices were measured to the nearest mm using callipers. In addition, the orifices into each successive chamber were also measured using callipers.

3.3.7 Stomach contents

The stomach was examined for ingesta and any remains were retained in 10% formalin solution and sent to Department of Conservation for identification. A representative sample from 1 fur seal (Af.7) was retained and the number of small worms (<3cm) and large worms (>3cm) were sorted and counted.

3.3.8 Stomach wall sampling

Tissue samples of approximately 3 x 2 cm were taken from the stomachs of 8 fur seals (Af.1-Af.7, Af.9) and 3 pilot whales (Gm.1-Gm.2, Gm.5) and preserved in 10% formalin solution or Bouins fluid for histology. Tissue samples preserved in Bouins fluid were removed after 12 hours and placed into 10% ethanol.

3.4 **Recording of gross observations and preparation of figures**

Observations were recorded on a note pad or by dictaphone (Sanyo M-5699) during dissections.

Statistical analysis of data were calculated with a Pentium computer using the software package 'Microsoft Excel 5.0'.

In the first fur seal dissected (Af.1), figures were drawn using a quadrat that was placed over the abdomen and the organs were drawn at twice the size and then decreased in size by photocopying. This method reduced the extent of parallax, which occurs when converting 3 dimensional images to 2 dimensions. The method was unsuitable for fresh dissections and so photographs of all other animals and were used to construct figures 4.1, 4.2, 4.3 and 4.4. Photographs were taken with either an Olympus Trip AF Super camera, Kodak 100 asa film, or an Olympus OM4Ti camera with a macro ring flash and reflector and using Fuji Sensia 100 asa slide film, or a Nikon 401s SLR camera and using Fuji Sensia 100 asa print or 200 asa slide film.

The photographs were scanned with a Microtek Scanmaker E6 and Pentium 160 computer using the software package 'Adobe Photoshop 3.0'. These images were then opened using the software package 'Corel Draw 7.0' and figures were drawn from them to scale.

3.5 **Microscopic examination**

3.5.1 Processing of tissues

The tissue samples removed for histology were prepared for light microscopy using the following standard method.

1. Tissues were cut into blocks and separated into two groups: large blocks (>5mm) and small blocks (<5mm) in preparation for paraffin processing.

2. The tissue blocks were dehydrated through a series of graded alcohols (from 70-100%), cleared with chloroform (<5mm thick tissues only) and xylene, and infiltrated with Paraplast by a Shandon automatic tissue processor. Processing schedule is detailed in Appendix 4.

3. The blocks were then embedded in fresh Paraplast using a Miles Scientific TissueTex wax dispensing (model: 4594) and thermal console (model: 4593), and a TissueTex cryo console (Sakura Finetechnical Company Ltd, Tokyo, Japan).

4. The blocks were sectioned with a Leitz rotary or sledge microtome at 5-7 µm and floated on warm water (43-45°C) to remove wrinkles in the sections. Some blocks were difficult to cut and the blade would shred the embedded tissue. In these cases the tissue blocks were either left in a freezer for 10 minutes or ice was placed on the tissue block for 10 minutes, making it easier to cut. Once sections where made, the tissue blocks were catalogued and stored in the histology laboratory of the Comparative Physiology and Anatomy section of the Institute of Veterinary, Animal and Biomedical Sciences, Massey University, for future reference.

5. The sections were mounted on glass slides that had 40% PVA glue thinly smeared across them, air dried and left in a oven overnight at 56-57°C.

6. The sections were stained with Haematoxylin & Eosin (H&E) for general cytological examination, Haematoxylin & van Gieson (H.vG) for muscle and collagen, Verhoff's Haematoxylin & van Geison (VH.vG) for elastic, collagen, and muscle fibers, and

Alcian Blue & Periodic Acid Schift (AB/PAS) for mucopolysaccharides. Complete details of staining procedures are listed in Appendix 5.

7. The stained tissue slides were prepared for microscopic study by being covered by a glass coverslip using DPX mountant, and left horizontally on a flat surface overnight for the DPX to set.

8. The slides were examined at magnifications of 4x, 10x and 40x using a light microscope (Nikon Alphaphot 2, YS2, Japan).

9. Photomicrographs were taken of selected slides using a photomicroscope (Zeiss Axiophot, Germany) and using Professional RTP Fujichrome 64T 36 exposure tungsten slide film.

Gram stains for bacteria were trialed on tissue sections from the forechamber, proper-gastric chamber, and pyloric chamber of 1 pilot whale (Gm.1). The method did not reveal any specific staining for bacteria, indicating bacteria were not present, so it was discontinued.

3.6 **Recording of histological observations**

Observations of histology from prepared slides were recorded in a notebook including,

1. morphology of the lamina epithelialis mucosae such as type of cells lining the lumen and zymogenic glands, the distribution of the cells and the number of parietal cells
2. type of connective tissue in the lamina propria mucosae, tunica submucosa and serosa
3. nature of the lamina muscularis mucosae and tunica muscularis layers such as type of muscule fibers present and number of muscle layers
4. thickness of each tunica layer and the entire stomach wall.
5. any other distinctive features or modifications to the processing schedule.

Chapter Four

Results

4.1 **Macroscopic anatomy of the New Zealand fur seal stomachs**

4.1.1 Position of fur seal stomachs

In each of the 10 fur seal (Af.1-Af.10) dissections, only part of the caudal end of the stomach was immediately evident when the abdomen was opened ventrally. This was because the multi-lobed liver and intestinal coils concealed the rest of the stomach (Plate 4.1A, Figure 4.1). The stomach lay in the cranial part of the abdominal cavity. The cranial pole of the stomach was dorsal to the cartilaginous attachment of rib 7 to the sternum, and the caudal part of the stomach was in the transverse plane of the most caudal extent of the thoracic cavity at rib 15. Thus the empty stomach was wholly within the costal arch. The proper-gastric region of the stomach was situated mainly to the left and in the midline, with the pyloric region to the right of the midline.

In each animal, the stomach was in contact craniodorsally, laterally and ventrally with the visceral surfaces of 5 of the 6 liver lobes: right and left medial, right and left lateral, quadrate and caudate (Plate 4.1, Figure 4.1). The ventral surface of the proper-gastric region was dorsal to and in contact with the visceral surfaces of all lobes except the right lateral and caudate. The cranial pole of the stomach was caudal to and in contact with the visceral surface of the left lateral liver lobe, which then curved dorsally and medially around the cranial half of the greater curvature to contact the lateral and dorsal surfaces of the proper-gastric portion. The pyloric region was dorsal to and in contact with the visceral surface of the right medial lobe; was medial to and in contact with the visceral surfaces of the right caudate and medial liver lobes; and was caudal to and in contact with the gall bladder. The pyloric region lay ventral to and in contact with the descending duodenum, the terminal end of the jejunum, the ileum and the left transverse lobe of the pancreas. The right lateral lobe was lateral to but not in contact with the stomach.

In one fur seal (Af.10), the visceral surface of the right medial lobe had a caudally orientated, elongated ridge that lay along the lesser curvature of the stomach, medial to the pyloric and proper-gastric regions. It extended from the level of the pyloric orifice caudally to the incisura angularis.

Plate 4.1 Ventral view of the abdominal viscera of the New Zealand fur seal (Af.10).

(A) the liver (l) intestinal tract (i) and spleen (s) 'in situ' after displacement of ribs.

(B) after parts of liver are displaced, the J-shaped stomach (st) is revealed 'in situ'.

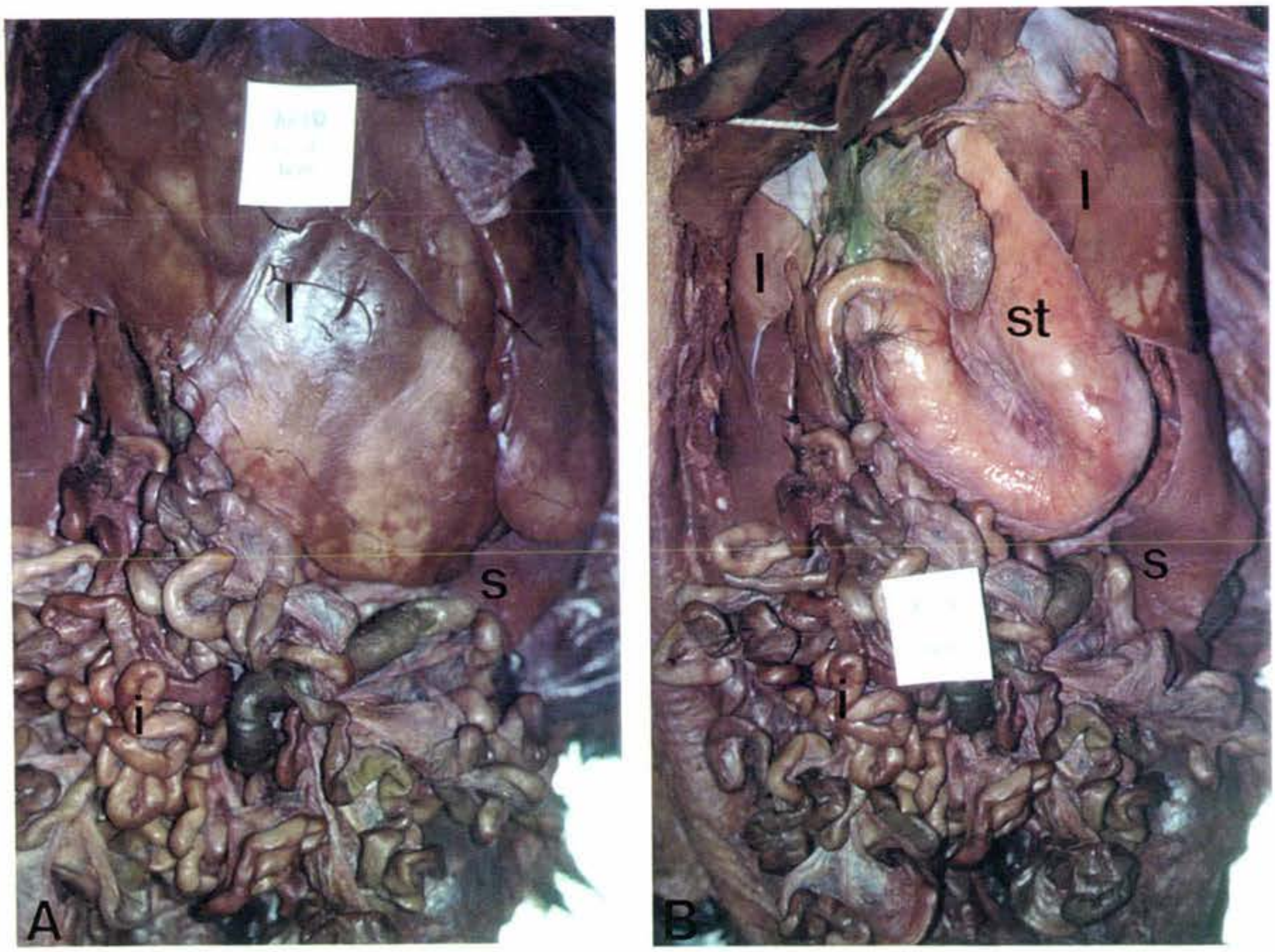
l
s
i
A
l
l
st
s
i
B

Figure 4.1 Ventral view of the abdominal viscera of the New Zealand fur seal (Af.10)
(dashed lines represent demarcations of liver lobes underlying the other more ventral lobes)

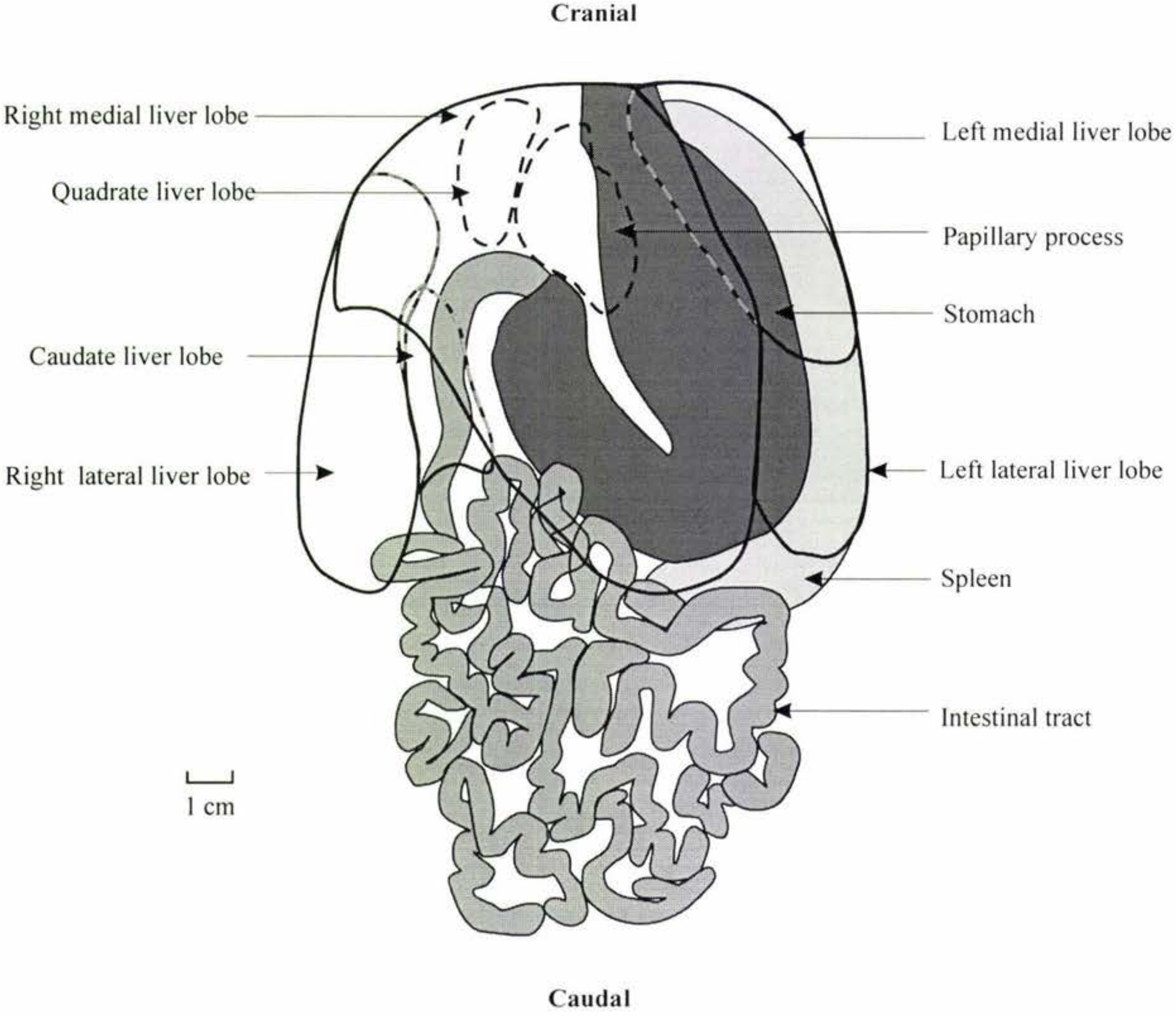

Along the greater cruvature of the stomach was the relatively flat, elongated spleen. The cranial end of the spleen curved cranio-dorsally around and was in contact with the greater curvature of the stomach. It ended dorsal to the stomach and to the left of the termination of the esophagus. The caudal end of the spleen curved medially and ventrally around and was in contact with the greater curvature of the stomach. It lay transversely across the ventral surface of the caudal part of the stomach and ended.

4.1.2 External appearance of fur seal stomachs

Once the liver was removed and the intestinal coils were displaced, the stomachs of all 10 fur seals were revealed as large J-shaped dilations of the digestive tract. The stomach was between the esophagus, after it had passed through the diaphragmatic hiatus and terminated, and the small intestine (Figure 4.1B).

The stomach was single chambered, J-shaped, curvaceous, cream coloured and smooth (Plate 4.1). The cranio-caudal axis of the "J" of the stomach extended longitudinally within the abdominal cavity. The cranial portion of the stomach was relatively wide but tapered caudally towards the incisura angularis. The narrow pyloric portion consisted of the more proximal antrum and more distal canal divided by the sulcus intermedius. It was bent sharply at the incisura angularis and extended cranially, almost to the point where the esophagus terminated. No diverticula of the stomachs were observed.

The dorsal and ventral surfaces of the empty stomach were convex, thick walled and firm. The greater curvature of the stomach lay at 45° from the dorsal body wall. It originated from the cardiac notch where it arched cranially and to the left to form the fundus. The greater curvature then followed caudally with a slightly convex contour to form the lateral wall of the proper-gastric region. It curved to the right and cranially to form the lateral wall of the pyloric region and end at the pyloric orifice (Figure 4.2).

The lesser curvature lay close to the midline of the abdominal cavity and was shorter than the greater curvature. It extended caudally from the esophagus to form the medial wall of the proper-gastric region. At the incisura angularis the lesser curvature was bent acutely at 45° and extended cranially to form the medial wall of the pyloric region before terminating at the pyloric orifice (Figure 4.2).

All fur seal stomach measurements are listed in Table 4.1 and weights in Table 4.2. See Appendix 6 for a complete list of all measurements from fur seals.

Table 4.1 Stomach measurements of the New Zealand fur seal (measurements in cm)

Specimen	Cardiac orifice diameter	Standard stomach length	Proper-gastric region width	Pyloric region length*	Pyloric antrum width	Sulcus intermedius width	Pyloric canal width	Pyloric orifice diameter	Wall thickness Proper-gastric region	 Pyloric region
Af1	-	-	-	-	-	-	-	-	0.34	0.34
Af2	-	-	-	-	-	-	-	-	0.84	0.51
Af3	-	-	7.5	-	-	-	3.0	-	0.34	0.22
Af4	2.0	15.0	6.0	-	-	3.0	3.0	0.5	-	0.34
Af5	2.5	12.0	6.0	-	-	3.0	3.0	0.5	0.36	0.29
Af6	1.5	12.5	4.5	8.0	-	2.5	2.5	0.7	0.66	0.41
Af7	2.0	17.5	7.0	5.5	4.5	4.0	3.0	1.5	-	-
Af8	2.0	13.5	6.0	5.5	-	3.5	2.5	1.0	-	-
Af9	6.0	30.0	16.0	10.5	10.5	7.0	5.5	1.5	-	-
Af10	2.0	13.5	4.5	7.0	3.0	-	3.0	0.5	-	-
Mean	2.6	16.3	7.2	7.3	6.0	3.8	3.2	0.9	0.51	0.35
SD	1.5	6.3	3.7	2.1	4.0	1.6	1.0	0.5	0.23	0.10

*along lesser curvature

4.1.2.1 Mesogastria of fur seals

In all 10 fur seals, the greater and lesser omenta were thin, transparent membranes devoid of adipose tissue. Gastric lymph nodes were suspended within the omenta: along the greater curvature and adjacent to the pyloric orifice and the incisura angularis.

The greater omentum formed a continuous attachment from the cardiac orifice, along the entire length of the greater curvature and terminated at the pyloric orifice. It passed dorsal to the stomach and attached to the approximate midline of the spleen, forming an omental bursa dorsal to the stomach. The greater omentum suspended the horizontal left lobe of the pancreas and then attached to the midline of the dorsal body wall.

The lesser omentum was attached along the entire length of the lesser curvature of the stomach and extended from the medial wall of the proper-gastric region to the medial wall of the pyloric region. The lesser omentum radiated from its attachment to the stomach towards the liver, where enroute it passed over the ventral surface of the papillary process of the liver, enclosed the cystic and bile ducts, and attached to the visceral surfaces of the right medial and left lateral liver lobes.

In 1 fur seal (Af.9), there was a zone along the greater curvature of 1.5 cm wide without peritoneal cover. This was because the two layers of mesothelium from the dorsal and ventral surfaces of the stomach had not joined. Lying in the zone, were torturous anastomotic blood vessels. This zone was not present in any of the other fur seals examined.

4.1.2.2 Stomach contents of fur seals

The fur seal stomachs examined were relatively devoid of solid or liquid food. The few contents that were present did not produce obvious distension of the stomach and did not obscure the lining of the stomach from view. They were limited to arrow squid (*Nototodarus sloanii*) beaks [B.Dix, *pers.comm.*], shell, sand and small stones.

One feature evident in all the fur seal stomachs was the presence of parasites: in one fur seal (Af.7) there were 703 parasitic worms.

Figure 4.2 Ventral view of the stomach of the New Zealand fur seal (Af.10)
(dashed lines represent internal demarcations between different regions)

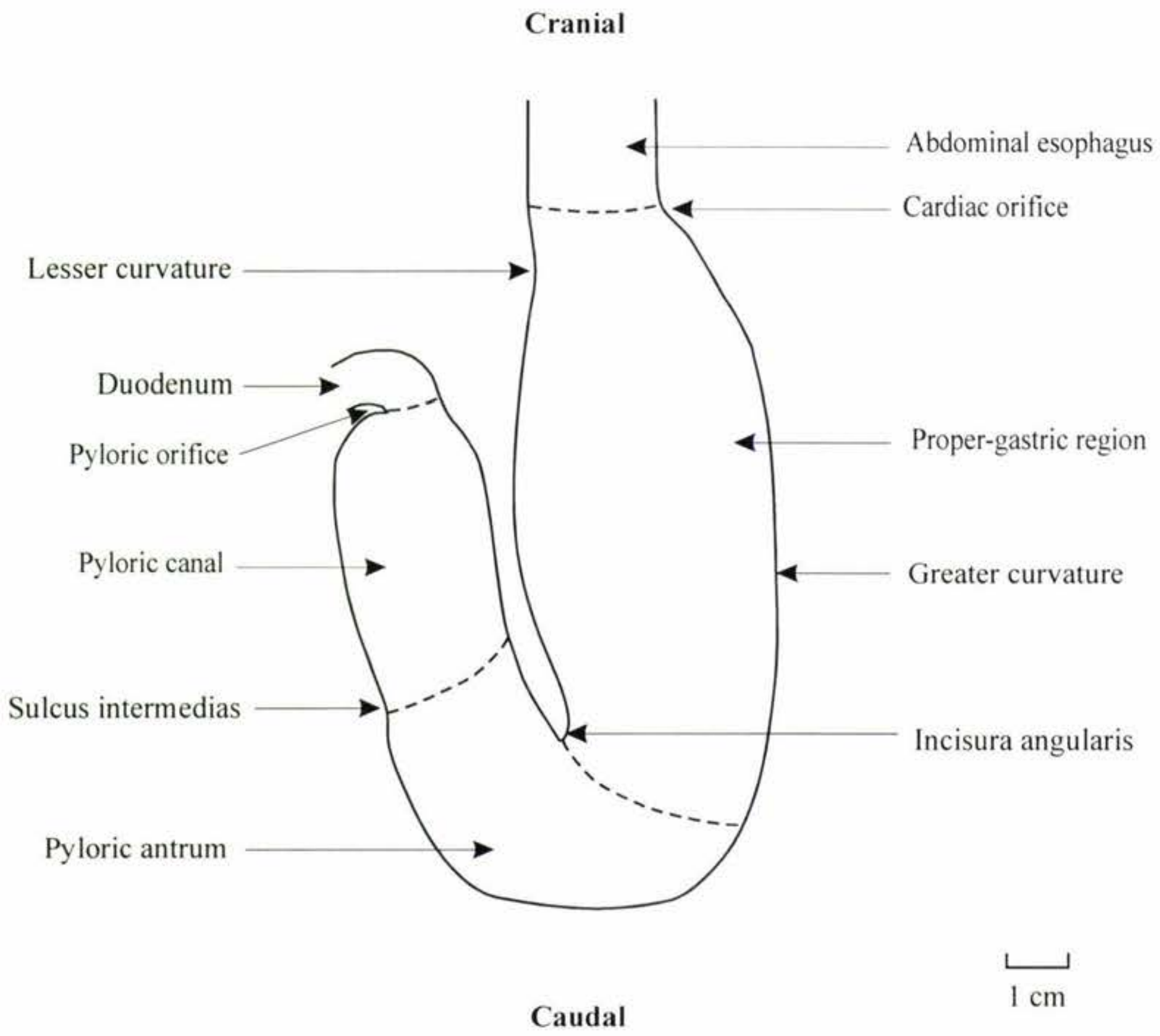

4.1.3 Internal appearance of fur seal stomachs

When the stomachs of 9 fur seals (Af.1-Af.9) were opened the lining was visible and the stomach was confirmed to comprise a single compartment as there were no internal sulci and the only openings of significantly reduced diameter were those of the cardiac and pyloric orifices. The cardiac orifice marked the cranial entrance to the stomach where the esophagus terminated. Grossly, no esophageal sphincter was evident. The pyloric orifice marked the exit from the stomach and was identified by the well-developed circular constriction of the pyloric sphincter.

The cardiac region was pale cream and had 2-3 low circular folds. The lining of the proper-gastric region was pale pink and when empty arranged into 9-10 well-defined, tortuous longitudinal rugae that extended from the cardiac orifice to the incisura angularis and that were interspersed by smaller shorter transverse rugae. The rugae were more prominent (thicker and larger) in the subadult (Af.2) and adult (Af.9) fur seals than in the juveniles. In the juvenile fur seals (Af.1, Af.3-Af.8) there were two larger folds of mucosa along the lesser curvature that extended from the cardiac orifice to the incisura angularis, forming a tube-like passage. These folds were not as prominent in the subadult and adult fur seals (Af.2, Af.9).

In all 9 fur seals (Af.1-Af.9) a circular fold of mucosa defined the left border of the pyloric antrum. Beyond this region the rugae became less well defined and tortuous, sparser, and extended parallel with the pyloric lumen to the pyloric orifice. Adjacent to the pyloric orifice there were two fleshy folds of mucosa (one in the left wall and one in the right) that projected into the lumen, with their tips closely contacting each other.

Minute holes were observed throughout the mucosal lining of the stomach indicating the openings of the zymogenic glands. In 2 fur seals (Af.3-Af.4) thick mucus was smeared over the mucosa.

4.1.3.1 Pathology of fur seal stomachs

No gastric ulcers were observed in the mucosal lining of any of the stomachs examined.

Table 4.2 Relationship of stomach weight to body size in the New Zealand fur seal

Specimen	Body weight (kg)	Body length (cm)	Stomach weight (g)	$\frac{\text{Stomach weight}}{\text{Body weight}}$ %	$\frac{\text{Stomach weight}}{\text{Body length}}$ %
Af1	11.0	96.0	-	-	-
Af2	23.5	127.0	-	-	-
Af3	9.0	93.0	-	-	-
Af4	7.5	78.0	12	0.15	0.015
Af5	7.5	80.0	15	0.20	0.019
Af6	7.0	71.0	17	0.24	0.023
Af7	11.5	97.0	35	0.30	0.036
Af8	7.5	77.0	20	0.27	0.026
Af9	55.6	164.0	113	0.20	0.069
Af10	10.3	93.0	-	-	-
Mean	15.0	97.6	35.3	0.23	0.031
SD	15.1	28.2	39.0	0.05	0.020

4.2 Macroscopic anatomy of the long-finned pilot whale stomachs

4.2.1 Position of pilot whale stomachs

In each of the 6 pilot whale cadavers (Gm.2-Gm.7) dissected, only the forechamber was visible as the bilobed liver and intestinal coils covered the rest of the stomach (Plate 4.2, Figure 4.3). The stomach lay in a cranio-medial position in the abdomen and was multi-chambered. The cranial pole of the stomach was ventral to the articulation of rib 9 (of a total of 7 fixed and 4 floating ribs on each side) to the vertebral column. The caudal pole of the stomach was cranial to the most caudal part of rib 11, thereby the stomach was wholly within the costal arch. The forechamber was to the left of midline, the proper-gastric chamber was central and to the right of midline, and the pyloric chamber was to the right of the midline. The caudal pole of the forechamber extended to the cranial pole of the left kidney.

In each animal, the stomach was surrounded ventrally and laterally by, and was in contact with the visceral surfaces of the liver. The visceral surface of the left liver lobe was ventral to, and in contact with the forechamber, and was ventral and lateral to the proper-gastric chamber (Plate 4.2, Figure 4.3). The visceral surface of the right liver lobe was ventral and lateral to, and in contact with the proper-gastric chamber. The stomach was also surrounded caudolaterally by and in contact with the intestines (Plate 4.2, Figure 4.3).

4.2.2 External appearance of pilot whale stomachs

Once the liver was removed and the intestines were displaced, in 6 pilot whales (Gm.2-Gm.7) the stomach, as in fur seals, was a large dilation between the esophagus and small intestine, but in the pilot whales it was multi-chambered.

In all 7 pilot whales (Gm.1-Gm.7) the stomach appeared to consist of 3 voluminous chambers separated by external demarcations, with consecutive chambers having varying coloured and textured surfaces (Plate 4.2B). Because of the differences among the chambers of the pilot whale stomachs, the external appearance and measurements of each chamber will now be discussed separately.

All pilot whale stomach weights are listed in Table 4.3. See Appendix 7 for a complete list of all measurements from pilot whales.

Plate 4.2 Left lateral view of the abdominal viscera of the long-finned pilot whale (Gm.2).

(A) after every second rib (r) is removed the forechamber (f) is seen to be caudal to left lung (lu), dorsal to left liver lobe (l), extends caudally to left kidney (k) and is surrounded caudolaterally by intestinal tract (i).

(B) after ribs together with left lung and left liver lobe are removed, the proper-gastric chamber (g) can be seen to extend cranial to forechamber and the pyloric chamber (p) extends dorsal and to the right.

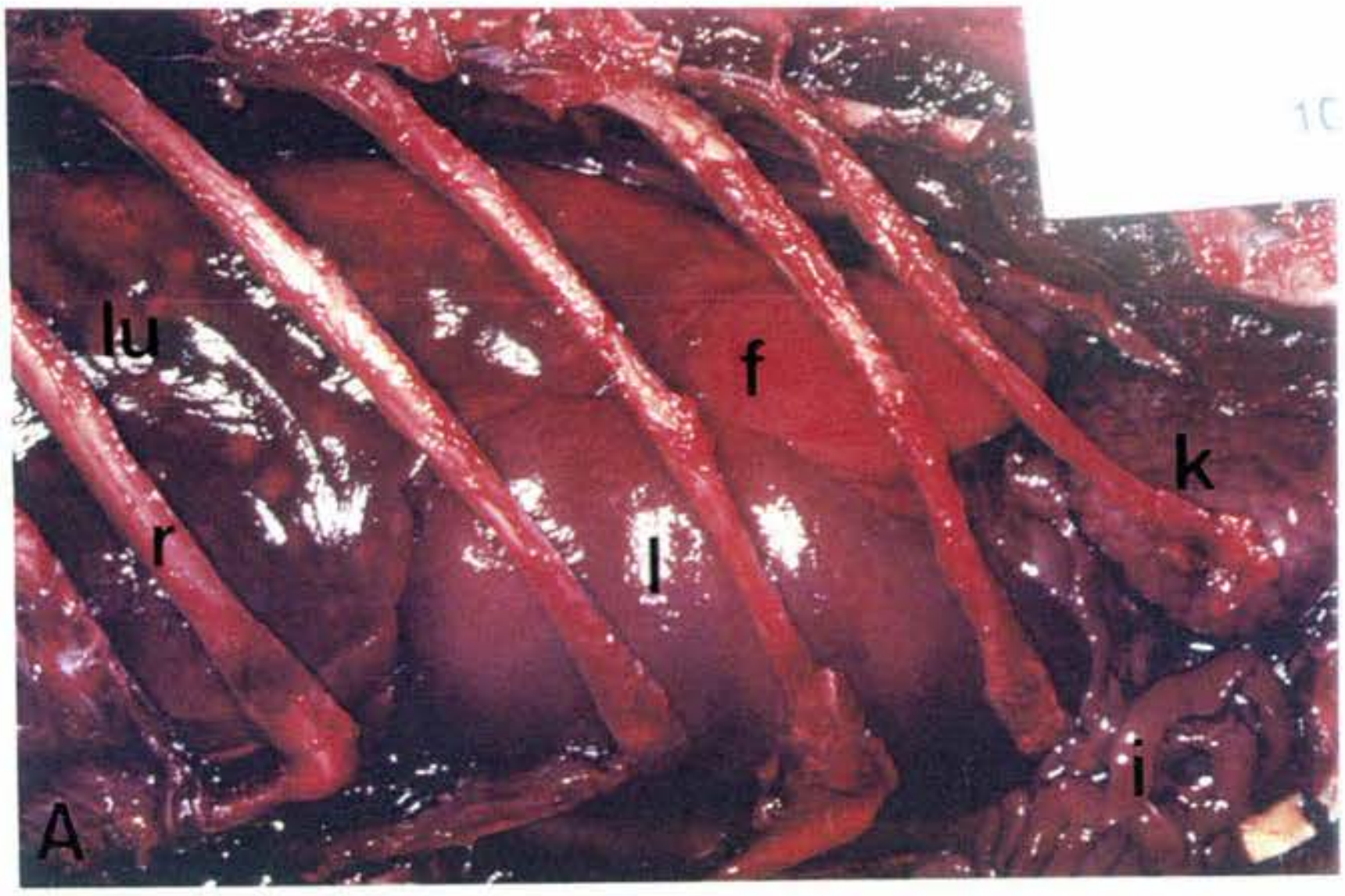
10
lu
f
k
r
l
i
A

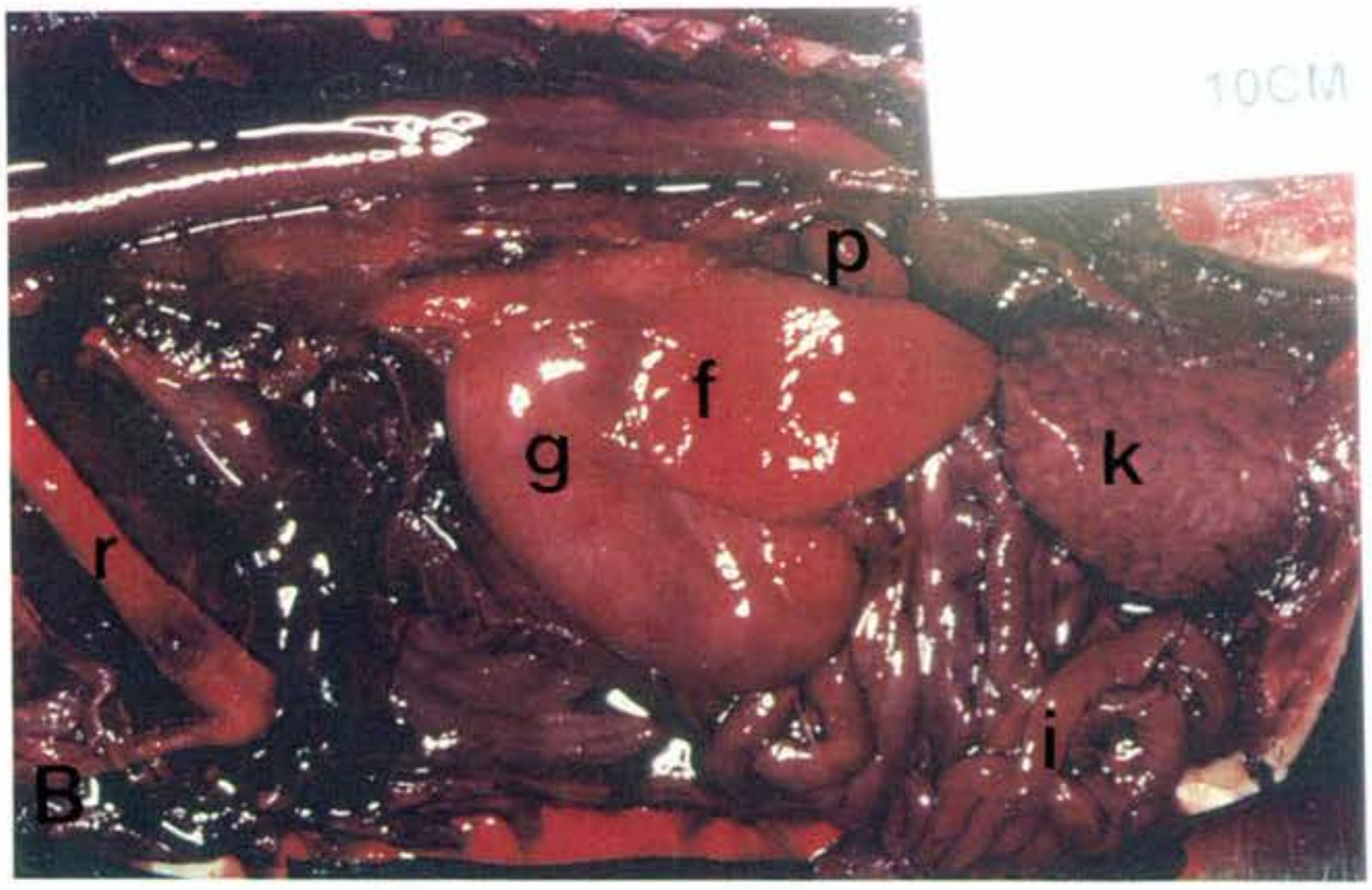
10CM
p
f
g
k
r
i
B

Figure 4.3 Left lateral view of the abdominal viscera of the long-finned pilot whale (Gm.2)

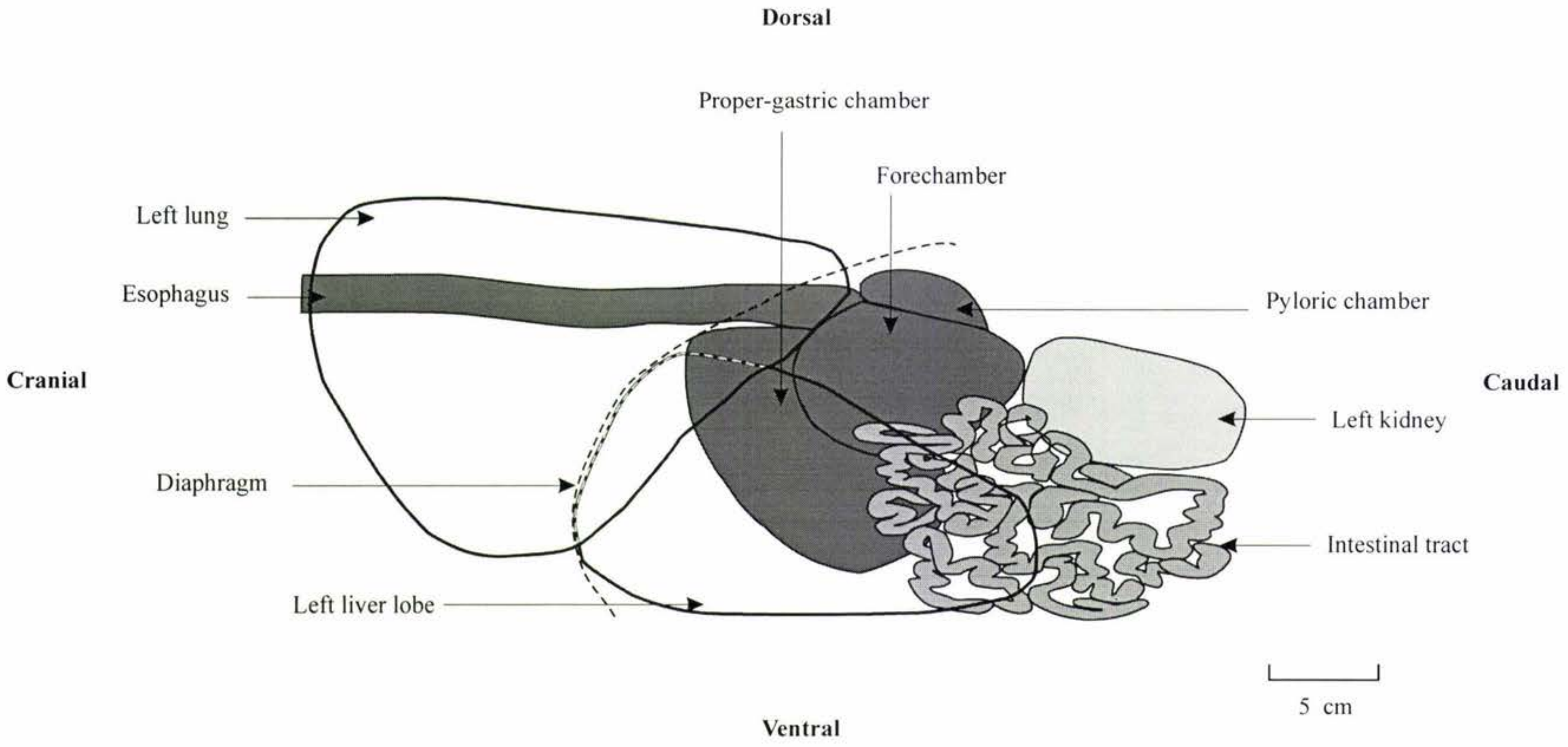

4.2.2.1 External appearance of pilot whale forechambers

In 6 pilot whales, the cranio-caudal axis of the forechamber extended longitudinally within the abdomen. In all pilot whales the forechamber was pear-shaped: the cranial part was relatively wide, but tapered caudally (Plate 4.2B & Figure 4.4). In the fresh state, the exterior was light red and when empty the chamber was taunt, muscular and slightly furrowed. The forechamber appeared to open into the proper-gastric chamber, because part of the cranioventral wall of the forechamber was intimately associated with the wall of the proper-gastric chamber, while the caudal portion was separate.

Attachments of the ventral and dorsal mesogastria to the external surface of the forechamber are described in section 4.2.2.4.

Measurements of the pilot whale forechamber are listed in Table 4.4.

4.2.2.2 External appearance of pilot whale proper-gastric chambers

In 6 pilot whales, the cranial portion of the proper-gastric chamber was cranial to the forechamber and curved ventrally to the right, whereupon it followed caudally. In all pilot whales, the proper-gastric chamber was oval and bulbous (Plate 4.2B & Figure 4.4). In the fresh state, the exterior was dark maroon, supple, velvety, thick walled and smooth. The proper-gastric chamber appeared to open into the pyloric chamber, as part of the craniolateral wall of the proper-gastric chamber lead to the pyloric chamber with a slight constriction defining the junction between the two chambers.

Attachments of the ventral and dorsal mesogastria to the external surface of the proper-gastric chamber are described in section 4.2.2.4.

Measurements of the pilot whale proper-gastric chamber are listed in Table 4.4.

4.2.2.3 External appearance of pilot whale pyloric chambers

The pyloric chamber in all 7 pilot whales extended dorsally from the proper-gastric chamber and was elongate, tubular and appeared to be divided into two portions. The cranial portion of the pyloric chamber was not easily seen externally as it was enclosed partially in the proper-gastric chamber and the pyloric chamber walls, but when palpated could be felt as a channel with a firm transverse septum (Figure 4.4). The caudal portion followed dorsally from the cranial portion.

Table 4.3 Relationship of stomach weight to body size in the long-finned pilot whale

Specimen	Body weight (kg)	Body length (cm)	Stomach weight (g)	$\frac{\text{Stomach weight}}{\text{Body weight}}$ %	$\frac{\text{Stomach weight}}{\text{Body length}}$ %
Gm1	68.6	168	-	-	-
Gm2	91.5	185	571	0.62	0.31
Gm3	69.2	168	300	0.43	0.18
Gm4	178.4	233	1400	0.78	0.60
Gm5	273.4	290	2766	1.01	0.95
Gm6	407.8	310	4669	1.14	1.51
Gm7	74.7	173	-	-	-
Mean	166.2	218	1941	0.80	0.71
SD	130.9	61	1802	0.29	0.54

Table 4.4 Stomach measurements of the long-finned pilot whale (measurements in cm)

	Forechamber			**Proper-gastric chamber**			**Cranial pyloric portion**							**Caudal pyloric portion**		
Specimen	**length**	**width**	**wall thickness**	**length**	**width**	**wall thickness**	**length proximal**	**width proximal**	**length distal**	**width distal**	**length dilation**	**width dilation**	**wall thickness**	**length**	**width**	**wall thickness**
Gm1	-	-	1.1	-	-	0.3	-	-	-	-	-	-	0.2	-	-	0.3
Gm2	10.0	6.3	-	8.0	11.5	-	-	-	-	-	-	-	-	13.5	4.5	-
Gm3	12.5	7.5	0.5	8.5	9.0	0.3	3.0	1.5	3.0	2.0	1.5	2.0	0.2	11.0	4.0	0.2
Gm4	27.5	10.0	0.9	14.0	15.5	0.4	5.5	2.8	5.5	4.0	7.5	4.0	0.3	21.5	6.0	0.3
Gm5	33.5	21.0	0.8	16.5	17.0	0.6	5.5	3.5	5.5	5.0	5.5	4.5	0.3	22.5	5.5	0.3
Gm6	31.0	20.5	1.5	16.5	17.0	1.0	7.0	3.5	7.0	3.0	5.0	4.5	0.6	23.5	5.5	0.6
Mean	22.9	13.1	1.0	12.7	14.0	0.5	5.3	2.8	5.3	3.5	4.9	3.8	0.3	18.4	5.1	0.3
SD	10.9	7.1	0.4	4.2	3.6	0.3	1.7	0.9	1.7	1.3	2.5	1.2	0.2	5.7	0.8	0.2

Palpation of the pyloric chamber wall identified the location of the pyloric orifice, which was otherwise not easily seen as it was enclosed in the pyloric chamber wall. The pyloric orifice was distinguished as a small circular muscular constriction surrounded by the pyloric wall.

In the fresh state, the exterior of the pyloric chamber was light red and thin walled (Figure 4.4). It was the only chamber to have a greater and lesser curvature (Figure 4.4). The greater curvature originated from the caudoventral fold between the proper-gastric chamber and the cranial portion of the pyloric chamber. The greater curvature followed dorsally with a convex contour to form the caudal border of the pyloric chamber and end at the pyloric orifice. The lesser curvature originated from the dorsal fold between the proper-gastric chamber and the cranial portion of the pyloric chamber. The lesser curvature then followed dorsally, with a slight concave contour to form the cranial border of the pyloric chamber and end at the pyloric orifice.

Attachments of the ventral and dorsal mesogastria to the external surface of the pyloric chamber are described in section 4.2.2.4.

Measurements of the pilot whale pyloric chamber are listed in Table 4.4.

4.2.2.4 Mesogastria of pilot whales

In all pilot whales, the mesogastria were thin and transparent, with no obvious adipose tissue. The dorsal mesogastrium enclosed and suspended the spleen for approximately 3 cm halfway along the right medial surface of the forechamber. From the spleen the dorsal mesogastrium passed caudally and around the ventral side of the caudal pole of the forechamber and came to lie on the left side of the forechamber. It then passed cranially, and curved ventrally to cross over the caudal limit of the junction between the forechamber and proper-gastric chamber. It continued to curve ventrally across the caudal surface of the proper-gastric chamber, and passed sharply to the right side to gain the cranial part of the greater curvature of the pyloric chamber. The dorsal mesogastrium then followed the greater curvature of the pyloric chamber and ended by merging with the mesoduodenum at the junction of the duodenal ampulla and duodenum proper. The dorsal mesogastrium radiated out from its attachment to the greater curvature of the pyloric chamber, and curved towards the left medial side of the pyloric chamber where it reconnected to the pancreas, forming an omental bursa.

Figure 4.4 Left lateral view of the stomach of the long-finned pilot whale (Gm.2) (dotted lines represent external demarcations of the proper-gastric chamber medial to the forechamber and esophagus, dashed lines represent internal demarcations of different regions)

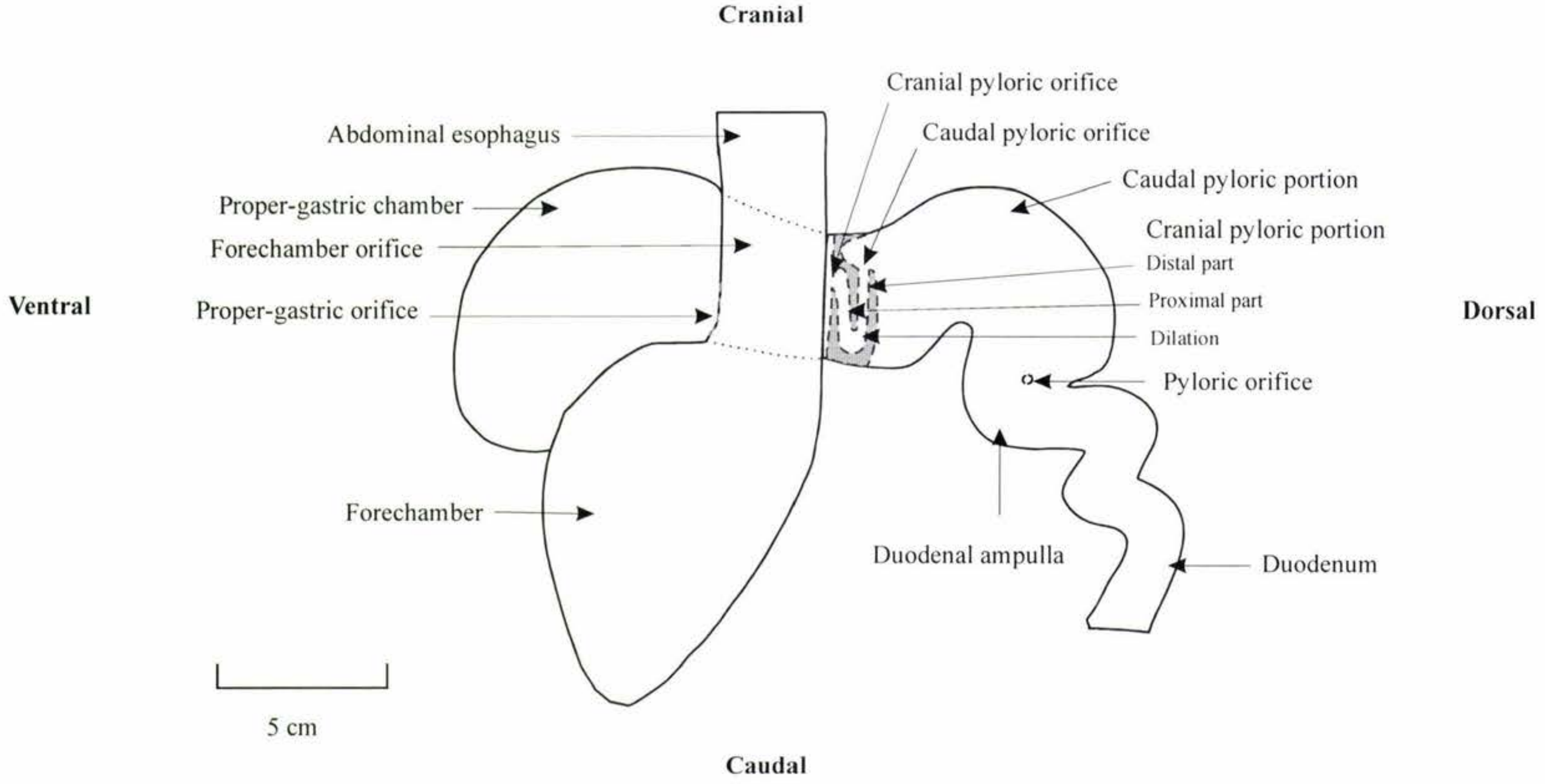

The ventral mesogastrium passed cranially and ventrally over the cranial right medial surface of the forechamber. It then crossed over to the cranial left medial surface of the proper-gastric chamber, continued to curve cranioventrally and then caudoventrally to gain the cranial part of the lesser curvature of the pyloric chamber. The ventral mesogastrium became shortened and thickened as it extended dorsally along the lesser curvature of the pyloric chamber to attach the pancreas, and terminated at the junction between the duodenal ampulla and duodenum proper.

4.2.2.5 Size of pilot whale stomachs

Measurements of chamber volume and total stomach volume are listed in Table 4.5.

4.2.2.6 Stomach contents of pilot whales

The pilot whale stomachs examined were relatively devoid of solid and liquid food. The few stomach contents that were present, as in the fur seals, did not produce obvious distension of the stomach and did not obscure the lining of the stomach from view. They were limited to shells and sand in the forechamber. However, in one pilot whale (Gm.4), 75 pairs of upper and lower warty squid (*Mocoteuthis ingens*) beaks [B.Dix, *pers. comm.*] were identified from the forechamber; and in another pilot whale (Gm.6), 381 parasitic worms were found in the proper-gastric chamber.

4.2.3 Internal appearance of pilot whale stomachs

When the stomachs of 6 pilot whales (Gm.1-Gm.6) were opened the lining was visible and the stomachs were confirmed to comprise of 3 main chambers separated by openings that corresponded to external demarcations. There were also small openings between the cranial and caudal parts of the pyloric chamber. The openings between successive chambers were distinguished by an aperture of reduced diameter and by an abrupt change in the gross appearance of the lining (Plate 4.3A). The openings progressively decreased in size, but there were no detectable anatomical sphincters except at the pyloric orifice (Plate 4.3B).

The esophagus emptied into the forechamber via the forechamber orifice. The forechamber entered directly into the more ventral proper-gastric chamber via the proper-gastric orifice, which was in proximity to the forechamber orifice (Figure 4.4).

Table 4.5 Chamber volume as a percentage of total stomach volume in the long-finned pilot whale (volumes in ml)

Specimen	Total stomach volume	Forechamber		Proper-gastric chamber		Pyloric chamber	
		volume	% of total vol	volume	% of total vol	volume	% of total vol
Gm2	545	150	28	300	55	95	17
Gm3	410	150	37	200	49	60	15
Gm4	1860	1000	54	550	30	310	17
Gm6	5450	3400	62	1450	27	600	11
Mean	2066	1175	45	625	40	266	15
SD	2349	1537	16	569	14	248	3

Table 4.6 Measurements of chamber orifice diameter in the long-finned pilot whale (measurements in cm)

Specimen	Forechamber orifice diameter	Proper-gastric orifice diameter	Cranial pyloric orifice diameter	Caudal pyloric orifice diameter	Pyloric orifice diameter
Gm1	-	-	-	-	-
Gm2	3.0	5.5	-	-	-
Gm3	3.0	5.5	0.7	0.5	0.3
Gm4	7.5	7.5	1.5	1.0	1.0
Gm5	8.5	10.0	1.5	1.5	0.8
Gm6	5.0	10.0	1.0	1.5	0.5
Mean	5.4	7.7	1.2	1.1	0.7
SD	2.5	2.3	0.4	0.5	0.3

There was no canal present. The proper-gastric chamber entered the pyloric chamber via the cranial pyloric orifice, which was located in the cranial wall of the proper-gastric chamber. The proper-gastric and cranial pyloric orifices were in proximity to each other, with only a fold of membrane separating them (Plate 4.3A, Figure 4.4). The cranial pyloric portion of the pyloric chamber opened into the caudal pyloric portion via the caudal pyloric orifice. The pyloric orifice separated the stomach from the intestinal tract (Plate 4.3B).

Measurements of orifice diameter are listed in Table 4.4.

The internal morphology of each chamber was different and will be discussed separately.

4.2.3.1 Internal appearance of pilot whale forechambers

The interior of the forechamber was white and similar to that of the esophagus. It was largely devoid of pits or pores except for a narrow region around the proper-gastric orifice. The lining of the empty forechamber was arranged into 9-10 thick, well-developed longitudinal rugae with occasional shorter and shallower transverse rugae. The rugae disappeared when the chamber was distended.

Measurements of the thickness of the forechamber wall are listed in Table 4.4.

4.2.3.2 Internal appearance of pilot whale proper-gastric chambers

The interior of the proper-gastric chamber was lined by smooth, red epithelium arranged into numerous tall fleshy longitudinal folds, interspersed with shorter thinner transverse folds creating a labyrinth appearance (Plate 4.3A). The mucosal folds radiated outward from the proper-gastric and cranial pyloric orifices (Plate 4.3A). Minute holes indicating the openings of mucosal glands where observed throughout the mucosal lining.

Measurements of the thickness of the proper-gastric chamber wall are listed in Table 4.4.

4.2.3.3 Internal appearance of pilot whale pyloric chambers

The cranial portion was narrow and sub-divided by a narrow transverse septum into two parts: proximal and distal. The proximal part extended caudally and entered a slight dilation at the caudal end of the septum, from which the distal part of the channel extended cranially to the caudal pyloric orifice. The proximal and distal parts were of similar length and diameters.

Plate 4.3 Views of the long-finned pilot whale (Gm.1) (A) proper-gastric chamber (g) and (B) pyloric chamber (p).

(A) parts of forechamber mucosa (f, white) can be seen through the proper-gastric orifice (go). Probe from pyloric chamber projects through the cranial pyloric orifice (co).

(B) well-developed, sphincter-like pyloric orifice (po).

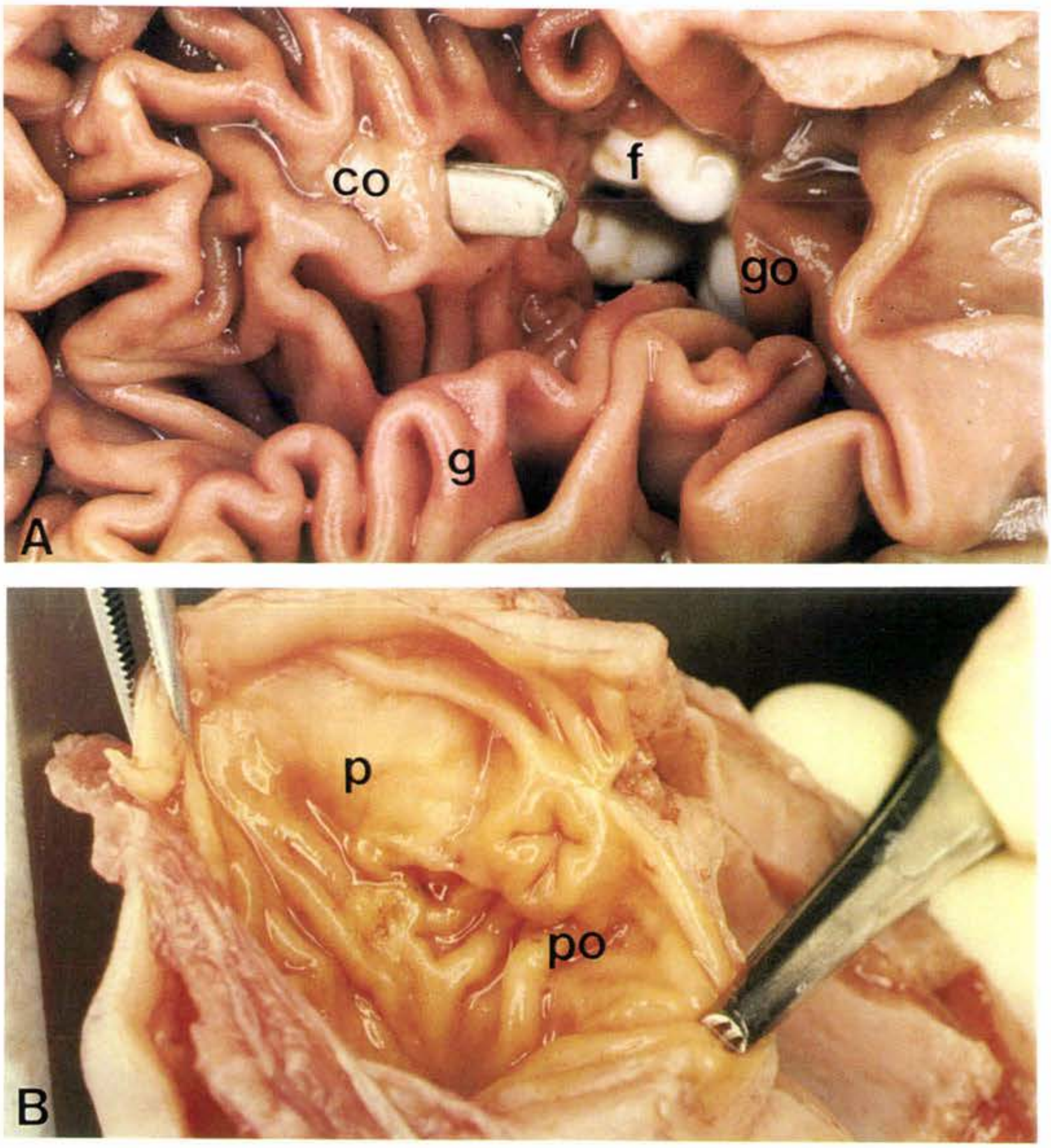
co
f
go
g
A
p
po
B

The caudal pyloric portion continued dorsally from the caudal pyloric orifice to the pyloric orifice. At the proximal part of the caudal pyloric portion a blind sac was present.

Measurements of the blind sac are listed in Appendix 7.

The interior of the pyloric chamber was lined by smooth, pale yellow epithelium and had a few shallow, irregular rugae (Plate 4.3B). Minute holes were observed throughout the mucosal lining, indicating the openings of mucosal glands.

Measurements of the cranial and caudal pyloric portions and the thickness of the pyloric chamber wall are listed in Table 4.4.

4.2.3.4 Pathology of pilot whale stomachs

Gastric ulcers were observed in 2 pilot whales (Gm.4-Gm.5). In the forechamber of 1 pilot whale (Gm.4) a small ulcer with a diameter of 1-2 cm was present. In the other pilot whale (Gm.5), 3 large gastric ulcers with diameters of 3-4 cm were in the proper-gastric chamber, and 2 smaller ulcers with diameters of 1-2 cm were in the pyloric chamber.

4.3 **Microscopic anatomy of the New Zealand fur seal stomachs**

4.3.1 Basic layers of fur seal stomachs

In each of the 9 fur seals (Af.1-Af.9) the stomach is composed of cardiac, proper-gastric and pyloric zones. The stomach wall at each of the zones is composed of the tunica mucosa including lamina epithelialis, propria and muscularis mucosae, the tunica submucosa, muscularis and serosa. All layers except for the lamina epithelialis are similar throughout the zones.

The lamina epithelialis mucosae is lined of simple, mucous columnar epithelial cells that extend into gastric pits, formed as invaginations of the mucosa. The columnar epithelial cells have an acidophilic granular cytoplasm and a basophilic oval nucleus positioned towards the basal lamina portion of the cell. The zymogenic glands of the lamina epithelialis mucosa are different according to the stomach zone and will be discussed separately.

The lamina propria mucosae is thin and composed of dense fibrous connective tissue with numerous small fenestrated blood vessels that extend up between the zymogenic glands. It has typical resident cells such as mesenchymal cells, fibroblasts, mast cells, and macrophages. The muscularis mucosae consists of irregular bundles of longitudinally orientated smooth muscle, with some fibres that extend up between the glands.

The tunica submucosa consists of loose fibrous connective tissue, with large fenestrated blood vessels, small lymphatic vessels, aggregations of lymphocytes and small bundles of non-myelinated nerves (Meissner's plexuses). There is no evidence of ganglia.

The tunica muscularis is composed of 3 layers of smooth muscle: the outer longitudinal and middle circular layers being only half the thickness of the inner oblique layer. The three layers are separated by loose fibrous connective tissue in which large blood vessels, lymphatics and small Auerbach's plexuses are found.

The tunica serosa is composed of loose, irregular fibrous connective tissue surrounded by mesothelium, and has large blood and lymphatic vessels and numerous small non-myelinated nerve bundles.

4.3.2 Cardiac zone of fur seal stomachs

In all fur seals there is an abrupt transition in the tunica mucosa: from the stratified squamous esophageal mucosa to the narrow cardiac gland zone of the stomach (Plate 4.4B). The tubuloalveolar glands of the esophagus project into the lamina propria mucosae of the cardiac zone (Plate 4.4B).

The cardiac zone is characterised by an increase in thickness of the lamina epithelialis mucosae, gastric pits that occupy about half of the lamina epithelialis mucosae thickness and cardiac glands at the base of the pits. The cardiac glands are short, tubular, loosely packed and coiled superficially throughout their length. They can be divided into upper, middle and basal regions and are lined principally by cuboidal acidophilic mucous-secreting cells. The cuboidal cells have a basal flattened nucleus and a cytoplasm filled with mucigen granules.

At the junction of the esophagus and cardiac zone there is a large non-myelinated nerve bundle in the tunica serosa, in addition to the usual smaller nerve bundles normally present. The remaining layers of the cardiac gland region are like those described in section 4.3.1.

4.3.3 Proper-gastric zone of fur seal stomachs

The lamina epithelialis mucosae of the proper-gastric zone is thicker than the cardiac zone, attributable to the long, tightly packed tubular proper-gastric glands (Plate 4.6A). The proper-gastric glands are straight for two-thirds of their length and have slightly coiled

Plate 4.4 Histology of the New Zealand fur seal (A) esophagus (Af.1) and (B) gastro-esophageal junction (Af.5).

(A) esophageal mucosal glands (em) and a duct (ed) can be seen extending upwards towards the stratified squamous esophageal epithelium (basal layer deep purple) (H&E stain at magnification x10).

(B) arrow indicates abrupt junction between esophageal mucosa (above) and gastric mucosa (below). Arrowhead marks junction between narrow cardiac region (above) and proper-gastric region (below). The tunica submucosa (central red zone) and tunica muscularis (to right) extend uninterrupted past these junctions (HvG stain at magnification x2.5).

Plate 4.5 Histology of the long-finned pilot whale (Gm.1) (A) esophagus and (B) forechamber.

(A) epidermal pegs (ep) project down into lamina propria mucosae (red) and interdigitate with lamina propria papillae (lp) (HvG stain at magnification x10).

(B) arrow indicates one of the few mitotic figures seen in these layers (H&E stain at magnification x20).

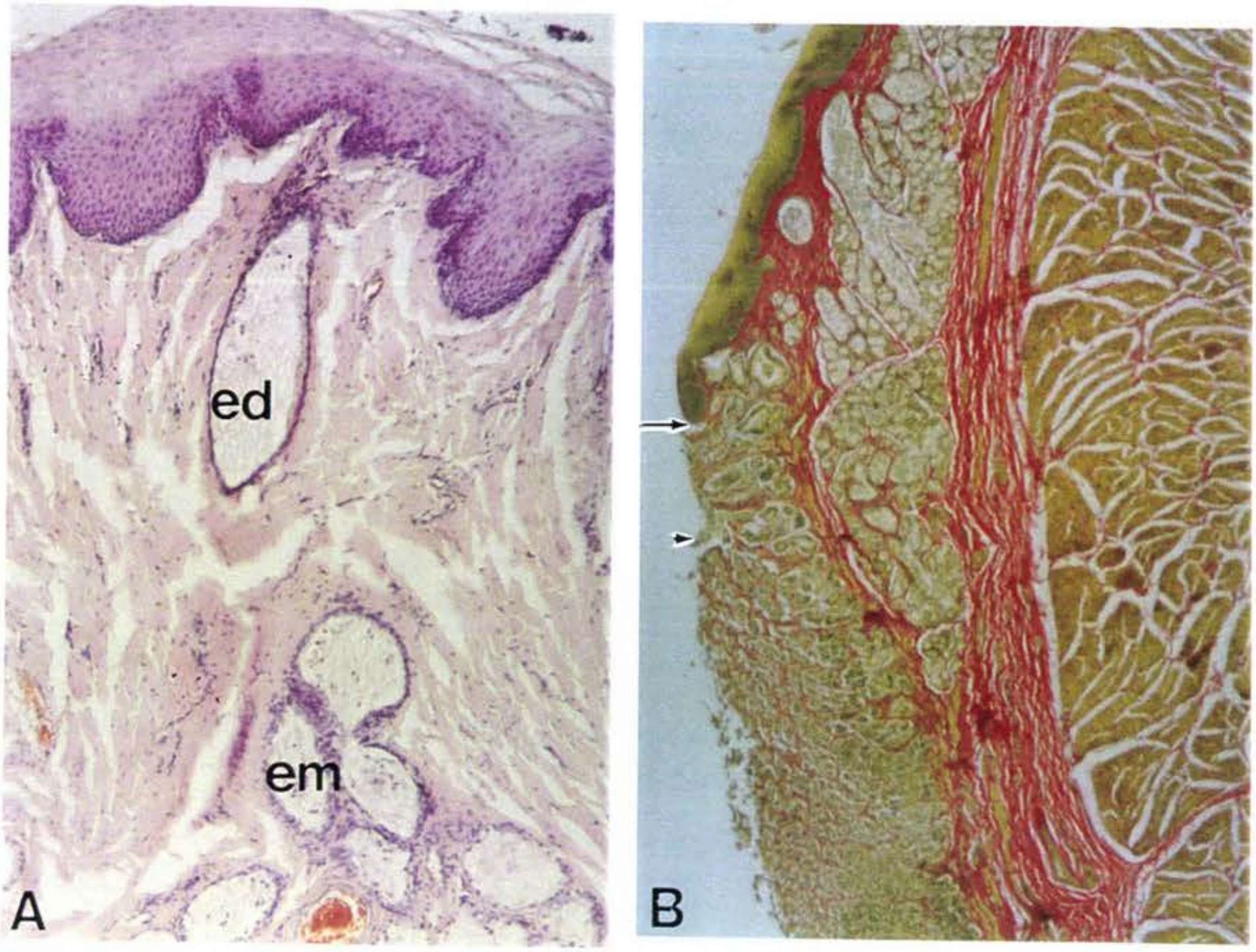
ed
em
A
B

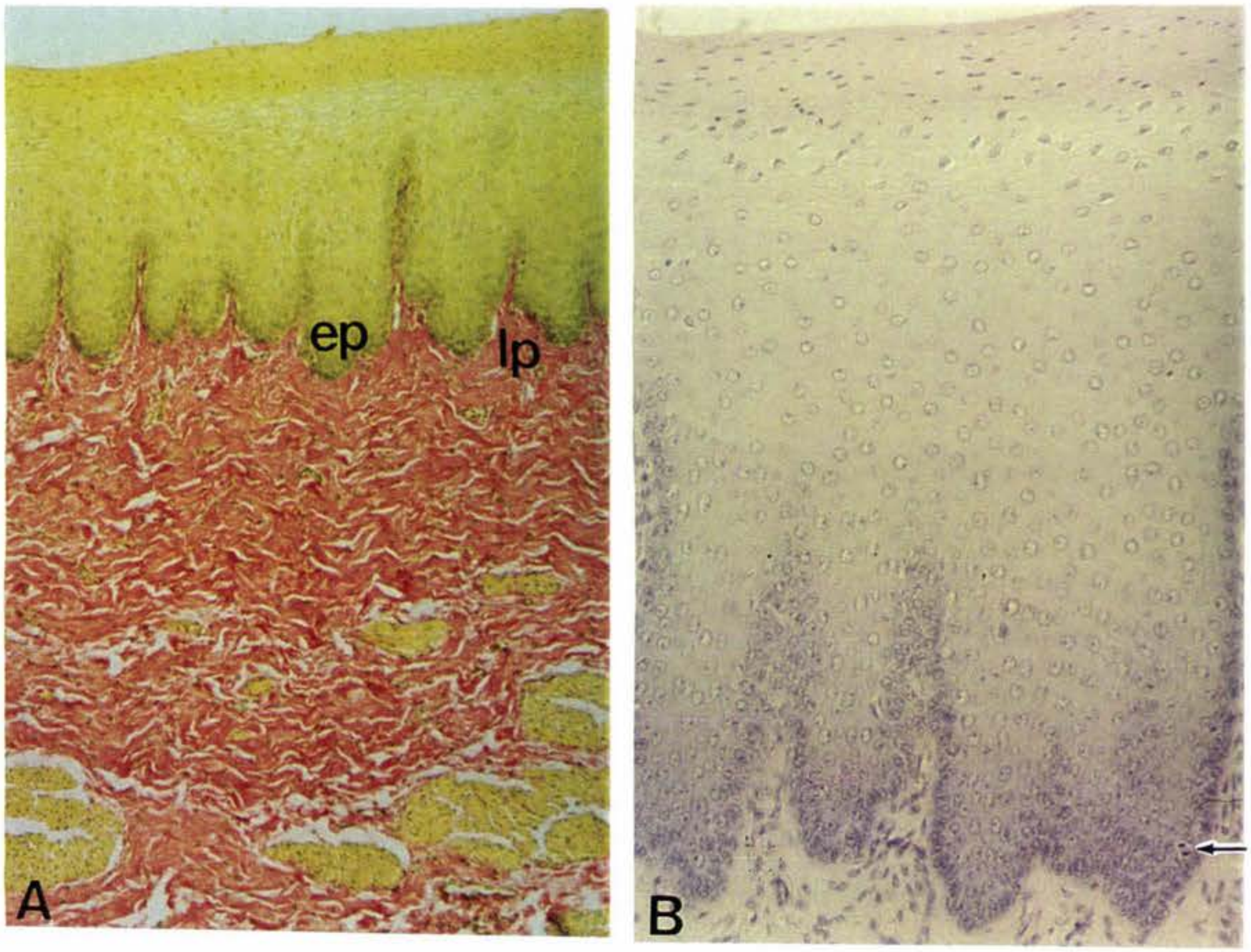
ep
lp
A
B

bases. Although the mucosa has increased in thickness, the gastric pits are relatively short, only occupying between one-quarter to one-fifth of the lamina epithelialis mucoasal thickness. The great depth of the lamina epithelialis mucosae is because of the elongated proper-gastric glands which are lined by mucous neck, parietal and chief cells.

The mucous neck cells are cuboidal cells situated next to the narrow gastric gland lumen and are less numerous at the base of the glands. They have an acidic cytoplasm, compared to the more neutral surface mucous cells (Plate 4.6B). Interspersed among the mucous neck cells are numerous, large parietal cells.

The parietal cells are large, oval cells with an acidophilic cytoplasm and an even more acidophilic nucleus, which is centrally located in the cell. Some binucleated parietal cells can be found. Parietal cells have a uniform distribution throughout the upper, middle and base of the proper-gastric glands (Plate 4.6A). They are adjacent to the basal membrane, away from the lumen of the gland.

In the base of the proper-gastric glands, chief cells are distributed. They are columnar cells with a basophilic granular cytoplasm and a darker basophilic spherical nucleus situated towards the basal lamina side of the cell. The chief cells are smaller than parietal cells and lie closer to the lumen of the glands (Plate 4.6A, B). Few mitotic figures are found throughout the glands.

The remaining layers of the stomach wall are similar to those described in section 4.3.1. However, some differences are evident. There are aggregations of lymphocytes in the lamina propria mucosae and a larger number of blood and lymphatic vessels in the tunica submucosa. The tunica muscularis is thicker and the tunica serosa is thinner than those in the cardiac zone. In 1 fur seal (Af.2) part of a parasitic worm was found in the submucosa with numerous lymphocytes and macrophages surrounding it. No mast cells were detected.

4.3.4 Pyloric zone of fur seal stomachs

In all fur seals the proper-gastric mucosa changes gradually to the thinner pyloric mucosa. The mucosa has long gastric pits that make up between one-half to one-third of the mucosal thickness, but the pyloric glands are shorter and less tightly packed. The pyloric glands are simple and tubular with basal portions more coiled than those in the cardiac and proper-gastric zones (Plate 4.7A). They are lined by mucous-secreting cells and sparsely distributed parietal cells.

Plate 4.6 Histology of proper-gastric regions of the New Zealand fur seal (Af.4) using (A) AB/PAS stain at magnification x10, (B) AB/PAS stain at magnification x40; and of the long-finned pilot whale (Gm.1) using (C) AB/PAS stain at magnification x10, (D) AB/PAS stain at magnification x40.

(A) and (B) gastric pits (dark purple) line the lumen (upper most) of the stomach. Mucous neck cells (m, bright pink) and parietal cells (o, pale pink) are uniformly distributed along the middle of the glands, while zymogenic cells (z, light purple) are predominantly location in basal portions.

(C) and (D) show a similar disposition of glands in the pilot whale, but with different staining intensities: (D) shows mucous neck cells (pale blue) and parietal cells (faintly pink).

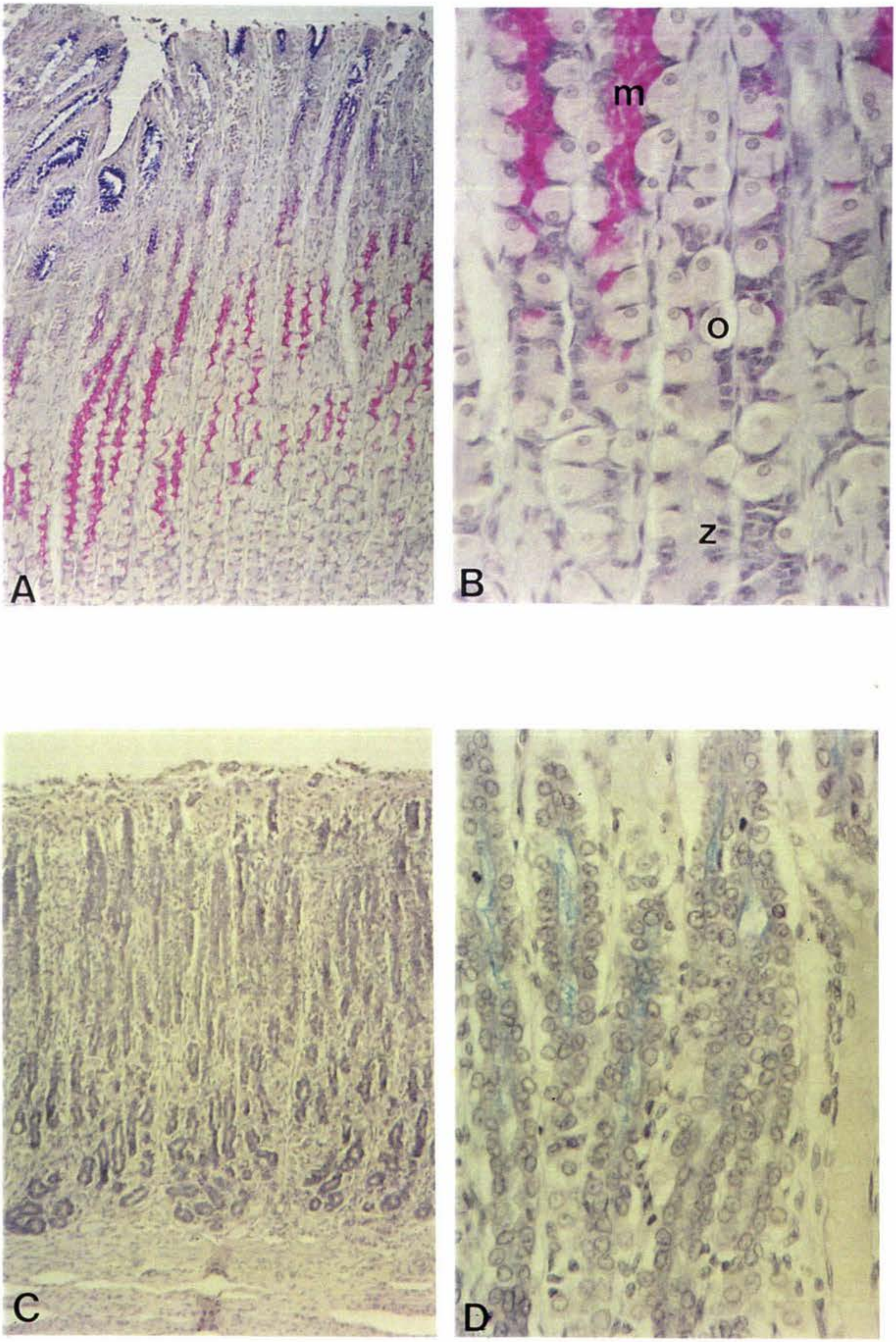
m
o
z
A
B
C
D

The pyloric mucous cells have a light-coloured foamy cytoplasm and a dark basophilic spherical nucleus that is situated near the basal lamina region of the cell. The mucous cells along the pyloric glands stain with different intensities using AB/PAS. The surface mucous cells stain dark purple/blue, the cells in the upper and middle regions stain a light blue, and the cells in the base are lighter blue.

The remaining layers of the stomach wall are similar to those described in section 4.3.1. However, some differences are evident. There are numerous aggregations of lymphocytes in the lamina propria mucosae that extend up in between the glands in the lamina epithelialis. The lamina muscularis mucosae and tunica serosa are thicker and there are adipose cells in the tunica submucosa and serosa compared to the cardiac and proper-gastric zones.

4.4 **Microscopic anatomy of the long-finned pilot whale stomachs**

4.4.1 Basic layers of pilot whale stomachs

In all pilot whales, the stomach wall has the same series of layers as described for the fur seal stomachs in section 4.3.1. However, the tunica layers are thicker in the pilot whale compared to the fur seal. The lamina epithelialis mucosae of each chamber is different and will now be discussed separately.

4.4.2 Cardiac zone of pilot whale stomachs

Histological examination confirmed the absence of cardiac glands in the pilot whale stomach.

4.4.3 Forechamber of pilot whale stomachs

In all pilot whales, the tunica mucosa of the forechamber consists of thick, stratified squamous non-keratinised epithelium (Plate 4.5B). It has three strata: basal, intermediate, and superficial. The basal stratum is a single layer of cuboidal or columnar cells, which abut the basal lamina. Mitotic figures identified by the intensely dark colour and irregular outline, are sparsely distributed amongst the cells of this stratum (Plate 4.5B).

The intermediate stratum consists of several tiers of tightly packed cells. The cells closest to the basal stratum are irregular and polyhedral, with an acidophilic cytoplasm and a large acidophilic centrally placed spherical nucleus.

Plate 4.7 Histology of pyloric regions of the New Zealand fur seal (Af.1) using (A) H&E stain at magnification x2.5; and of the long-finned pilot whale (Gm.1) using (B) AB/PAS stain at magnification x20, (C) AB/PAS stain at magnification x40.

The pyloric glands are short, tubular with coiled basal portions and have predominately mucous-secreting cells (pm, pale blue).

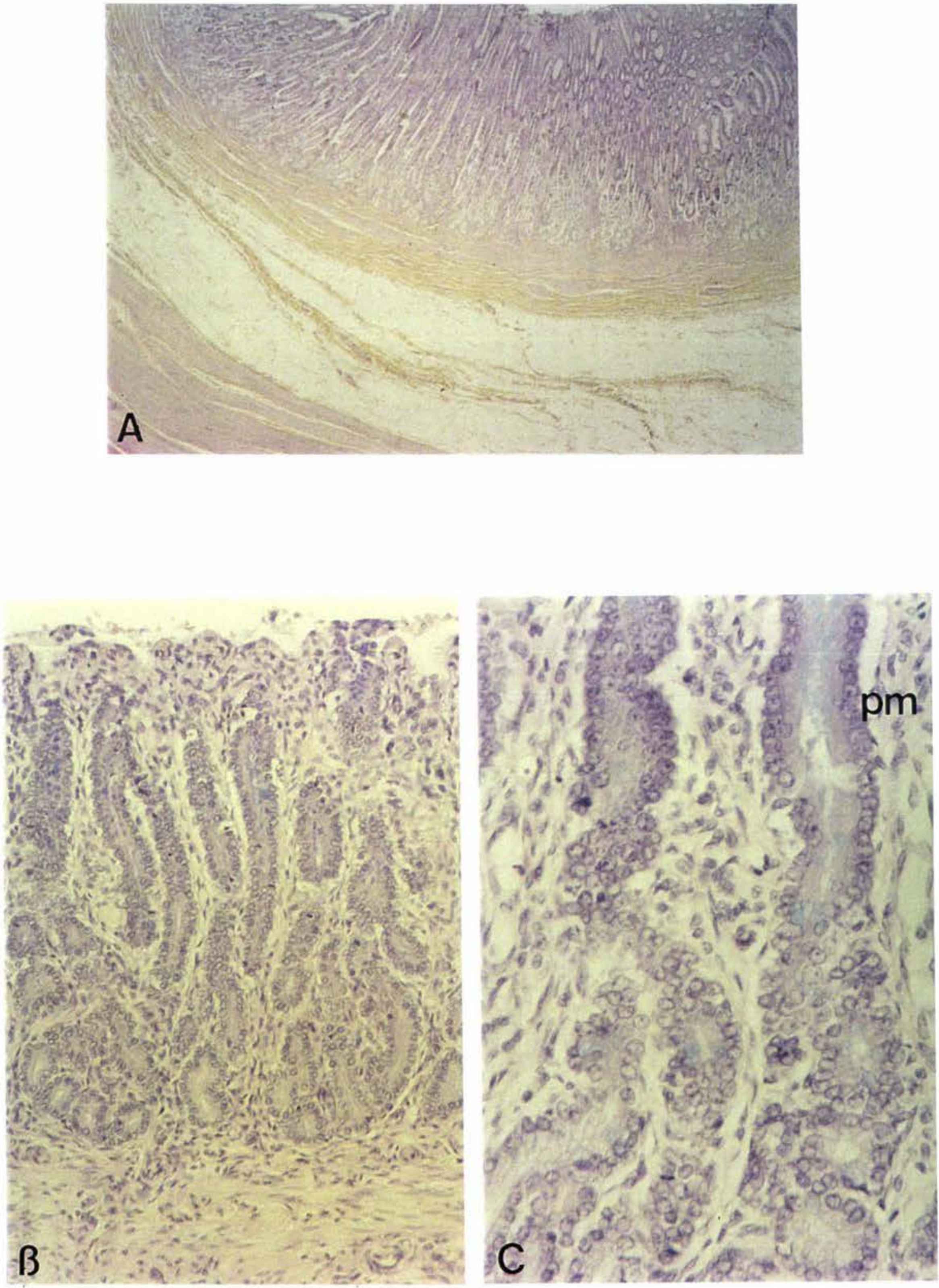
A
ß
C
pm

Closer to the lumen of the stomach the cells of the intermediate stratum flatten and have darker staining granular pyknotic nuclei with a smooth outline. The superficial stratum is the outer layer of flattened surface cells. These surface cells have no nuclei and are sloughing off into the lumen (Plate 4.5B).

The lamina epithelialis mucosae projects downwards into the lamina propria mucosae forming epidermal pegs that interdigitate with irregular, fingerlike papillae, which extend up from the lamina propria mucosae (Plate 4.5).

Histological examination of the grossly identified region of pores around the proper-gastric orifice shows the pores are pitting of the lamina epithelialis mucosae and are not associated with glands or ducts.

4.4.4 Proper-gastric chamber of pilot whale stomachs

In all pilot whales, the proper-gastric chamber is similar to the proper-gastric zone described in the fur seal stomach in section 4.3.3. However, some differences are evident. The mucous neck cells are less numerous and poorly differentiated in the pilot whale (Plate 4.6C, D).

4.4.5 Pyloric chamber of pilot whale stomachs

In all pilot whales, the pyloric chamber is similar to the pyloric zone described in the fur seal stomach in section 4.3.4 (Plate 4.7B, C). However, some differences are evident. In the pilot whale the change from proper-gastric to pyloric mucosa is more abrupt and there are larger Auerbach's plexuses in the tunica muscularis.

Chapter Five

Discussion

5.1 Methodology

In this study, fresh tissue was difficult to collect, particularly from pilot whales, because the delay from time of death until sampling was lengthy. The main cause for the delay was the time taken for the animals to be found because of the isolated places they often strand. Other causes include delays in contacting people, organising equipment and travel time to the stranding. This meant that the animal was dead for at least 5 but typically 12 hours or more before sampling. The delay in sampling meant that autolysis of the stomach lining had occurred, so samples for histology were taken from animals that were dead for less than 12 hours.

A full set of measurements were not taken from all specimens, particularly in the initial stages of the study, because as the study progressed additional measurements were added. As a detailed study on the stomachs of marine mammals has not been done before, there was not a complete list of measurements reported in the literature. Therefore it was necessary to examine several stomachs to determine what measurements were required. In the future, it would be useful to undertake a pilot study of stomach anatomy to establish a methodology that will ensure a complete set of observations and measurements are made on all study animals.

Body weights of all pilot whales were calculated using an equation from Bryden (1972). It was found there was a large difference between the calculated and actual body weights of the only pilot whale (Gm.2) in which true weight was known (i.e., known weight = 54 kg, calculated weight = 91.5 kg). This indicates either that the equation is highly variable and not reliable, or that Gm.2 did not conform to the typical long-finned pilot whale pattern. Therefore, the calculated body weights should be considered with caution.

In the initial stages of the study, a quadrat was used for drawing figures. This method proved unreliable and another more sophisticated and reliable method was devised that involved constructing figures from photographs. This ensured highly accurate figures to be made to scale.

The histological processing of tissue proved to be efficient and effective. The stains used were similar to those used by other authors (Harrison *et al.* 1970, Yamasaki *et al.*

1974, Schumacher *et al.* 1995) and illustrated the components of the tissue sections well.

5.2 **Anatomy of the fur seal stomach**

The anatomy of the fur seal stomach follows the general pinniped plan of a single chambered, J-shaped stomach consisting of cardiac, fundic, proper-gastric and pyloric regions with three histological zones (Owen 1830, 1853, Murie 1874, Hepburn 1896, Eastman & Coalson 1974, Olsen *et al.* 1996). The general pinniped stomach plan closely resembles that in terrestrial carnivores (Ridgway 1972, Eastman & Coalson 1974, Olsen *et al.* 1996).

The fur seal stomach is mainly positioned on the left side of the abdomen and is covered by the liver and intestines and is closely associated with the spleen. This is because the organs have been compacted to minimise protuberances. The stomach is J-shaped: with a small fundus, an elongate proper-gastric portion, sharply bent incisura angularis, cranially extended narrow pyloric canal and small pyloric orifice. Pinnipeds carry out minimal mastication (Scheffer 1958), therefore the elongated proper-gastric portion accomodates food that is swallowed relatively whole, while the sharply bent incisura angularis, narrow pyloric canal and small pyloric orifice impede the passage of large chunks of ingested food, which is either digested further or regurgitated.

The swallowing of prey relatively whole was confirmed by personal observations on the feeding behaviour of a non-study animals including a Subantarctic fur seal pup and from the stomach contents of 112 adult fur seals and 27 New Zealand sea lions (*Phocarctos hookeri*) caught incidentally in commercial fishing nets. The Subantartic fur seal would swallow fish and squid headfirst and whole unless the food was too large then the seal would break it into chunks by vigorous shaking of the head before swallowing. The stomachs of the fur seals and sea lions had fish and squid that had been swallowed whole and were stacked headfirst in the stomach, parallel to the longitudinal axis of the stomach. In one fur seal there were 21 whole squid stacked in the stomach in this manner.

Diverticula were not observed in any of the stomachs. Although diverticula are not common in pinnipeds there have been a few reports of their presence in the stomach of some species (Hepburn 1896, Green 1972). Personal observations during postmortem examination of a non-study fur seal caught incidentally in commercial fishing nets found a single globular diverticulum in the greater curvature of the pyloric canal of the stomach. The low frequency of occurance, small size and lack of obvious change in the mucosa suggested it was an aberrant feature with no important digestive function.

A narrow zone along the greater curvature of the adult stomach is absent of peritoneal cover. This is likely to be an unusual feature because it is not observed in the juveniles or subadult examined in this study or in any non-study adults examined.

The omenta of the stomachs were devoid of fat. This is because fat is deposited and mobilised by the liver into the subcutaneous blubber of marine mammals (Eastman & Coalson 1974). It is also likely to be related to body condition as the animals examined in this study were in poor body condition, but personal observations on non-study fur seals in good condition found extensive fat deposits in the omenta. This suggests that in very healthy or obese animals, fat can be mobilised in the omenta.

The lining of the empty stomach is arranged into well-developed rugae that are sparser and less tortuous beyond the pyloric antrum. The rugae flatten out to allow distension of the stomach while feeding (Williams *et al.* 1989) and then allow the stomach to shrink when it is empty so it occupies less space in the abdomen.

The proper-gastric region has larger rugae and a thicker wall than the pyloric region. This is for greater trituration and provides an increased surface area, which are important during breakdown of food that is swallowed relatively whole. They are not so prominent in the pyloric region because the ingesta that enter this portion consist of small particles and liquid.

There are two prominent rugae that extend along the lesser curvature of the stomachs of the juvenile fur seals. The rugae form a tubular passageway for the movement of fluids from the cardiac region straight to the pyloric region while solid food is held in the proper-gastric portion and broken down further. They may be remnants from when the juveniles were still suckling because these rugae are not seen in adults. These rugae have not been described in any other pinniped species.

No septum were present in the fur seal stomachs, although they have been described in a single Steller sea lion which had a partial septum at the pyloric antrum (Murie 1874).

The fur seals show basic mammalian histology of the stomach wall, with some differences evident in the mucosa. The cardiac zone of the fur seal stomachs is narrow. This is because of the reduced requirement for cardiac mucous glands as swallowed seawater and the mucus-coat of the prey itself would provide sufficient lubrication for the passage of food into the stomach. This cardiac zone is absent in the harbour seal and Steller sea lion (Pilliet 1894 as cited by Eastman & Coalson 1974).

The zymogenic glands of the proper-gastric zone of the fur seal stomach are long. The long glands are because of an increased number of parietal cells, which along with the mucous neck cells have a uniform distribution along the glands. This is similar to that found in other pinniped species (Smith 1972, Eastman & Coalson 1974, Schumacher *et al.* 1995). The increased number of parietal cells suggest that there is an increased volume of HCl secreted, which is required to digest food that is swallowed whole or in large chunks (Schumacher *et al.* 1995). However, it is possible that the sparse number of mitotic figures in the proper-gastric zone indicates that parietal cell turnover is low and the greater number of parietal cells may be a compensatory mechanism to maintain sufficient HCl secretion.

No villi were present in the stomachs. However, they have been described in the harbour seal, which had small villi lining the proper-gastric and pyloric zones (Oppel 1896 as cited by Eastman & Coalson 1974) and in the Weddell seal, which have villi lining the pyloric zone of the stomach (Eastman & Coalson 1974).

The weight of the stomach increases with age. However, the proportion of stomach weight to body weight is similar between all age classes, but the proportion of stomach weight to body length increases with age. Stomach weight increases with age because juvenile fur seals have a predominantly liquid diet that does not need such a voluminous chamber or strong muscular activity, which is required for the mechanical breakdown of food that has undergone minimal mastication as seen in adults. The proportion of stomach weight to total body weight in fur seals is less than that in other pinnipeds (Scheffer 1960, Bryden 1971, Bryden & Erickson 1976). This may be because the animals in this study were mostly juveniles while most of those reported in the literature were adults.

The stomachs were mostly empty of solid or liquid food. This is because most digestion by pinnipeds occurs while they are at sea so that when they are ashore their stomachs are mostly empty (King 1983). The few contents that were present consist of hard remains such as arrow squid beaks and small stones. Identification of arrow squid beaks in some study animals is consistent with prey types previously found in the fur seal stomach (Street 1964, Carey 1991, Dix 1993). Small stones have been recorded in the stomachs of many pinnipeds but their purpose is unclear (Fiscus & Baines 1966). There are several possibilities including accidental ingestion, to alleviate colic (Eastman & Coalson 1974). It is possible that the stones assist the stomach muscles in ejecting indigestible material (King 1983) or provide bulk upon which the muscles act to relieve hunger pangs (Laws 1953, Slijper 1962, Harrison & Kooyman 1968, Eastman & Coalson 1974). It is unlikely that the stones are useful for crushing or expelling parasites as in some species nematodes are only loosely attached to the stomach wall and can be spontaneously regurgitated (Eastman & Coalson 1974). The use of stones as ballast is unlikely because the small quantity of stones found is an insignificant addition (Harrison & Kooyman 1968). Stones could impede large pieces of ingesta into the pyloric canal because it was found during fluoroscopic observations that when stones were present ingested fish skeletons lay oral to the level of the incisura angularis (Needham 1985). However, as previously mentioned the narrow pyloric canal and sharply bent incisura angularis of the fur seal stomach would prevent the passage of chunks of food without the stones. It is likely that the reason for stones in the stomach varies between species, but the most likely explanation is their use for helping to grind up ingested food.

Gastric ulcers were not observed in the stomachs. However, parasitic and non-parasitic ulceration of the stomach has been described widely in pinnipeds (Keyes 1965, Migaki *et al.* 1971, Simpson & Gardner 1972) and personal observations have found presumed parasitic ulceration of the stomach of non-study adult fur seals. The lack of gastric ulcers in the study animals is because they were mostly juveniles and have not had heavy exposure to parasites, or to abrasive objects such as fish bones. Abrasive objects can damage the lining of the stomach exposing it to the corrosive action of gastric juice and resulting in the formation of gastric ulcers.

The most likely explanation for the anatomical structure of the fur seal stomach is to accommodate unmasticated food and impede the passage until the food is sufficiently broken down, while maintaining a streamlined body shape. Streamlining is important in marine mammals and constrains the development of all anatomical features in order to be maintained. Ancestry also influences the anatomy of the fur seal stomach because genetic codes passed on from their carnivorous ancestors predetermines the course of development that an individual undertakes.

5.3 **Anatomy of the pilot whale stomach**

The anatomy of the pilot whale stomach follows the general cetacean plan of a three chambered stomach consisting of forechamber, proper-gastric and pyloric chambers. Between each chamber the lining changes abruptly and there are orifices that progressively reduce in diameter through the stomach (Turner 1889, Harrison *et al.* 1970, Yamasaki & Kamiya 1981, Tarpley *et al.* 1987, Rice & Wolman 1990, Olsen *et al.* 1994). The gross general cetacean stomach plan is similar to that of ruminant animals (Stevens 1988, Dyce *et al.* 1996).

The stomach is positioned on the left and right sides of the abdomen. This is because the stomach is voluminous and as the forechamber occupies most of the left side of the abdominal cavity the proper-gastric and pyloric chambers are forced to the right side. The stomach, as in the fur seal, is covered by the liver and intestines and is closely associated with the spleen.

The structure of the stomach wall is similar to the typical mammalian plan, with some differences evident in the mucosa of different chambers. The cardiac zone is absent in the pilot whale and harbour porpoise (Smith 1972) but is present in most other cetacean species (Yamasaki & Kamiya 1981, Olsen *et al.* 1994). The variation in the presence or absence of the cardiac zone implies that it is not a prominent feature of the cetacean stomach.

The esophagus empties into the muscular, voluminous forechamber that when empty is lined by well-developed rugae. The mucosa consists of non-glandular stratified squamous epithelium with epidermal pegs that interdigitate with lamina propria papillae. It is resistant to abrasion and the pegs and papillae strongly connect the epithelium to the lamina propria and yet allow mobility of the epithelium in relation of the underlying layers. This suggests that unmasticated food enters the forechamber, which is distensible and strong mechanical action breaks the food down into smaller pieces that can pass into the proper-gastric chamber. The diameter of the proper-gastric orifice is relatively wide suggesting that there is back-flow of gastric juices from the proper-gastric chamber into the forechamber with preliminary chemical digestion also occurring in the forechamber (Ridgway 1972). The mucosa of the forechamber does not appear to be able to withstand chemical erosion, but there may be unidentified protective mechanisms, such as backflow of mucus along with the gastric acid, the mucus coat of the swallowed prey itself, and swallowed seawater (Smith 1972). Rapid proliferation of the forechamber mucosa is unlikely to be a protective mechanism because few mitotic figures are found in the basal cell layers, indicating a low level of epithelial cell replacement (Smith 1972).

In the bowhead whale (*Balaena mysticetus),* grey whale (*Eschrichtius robustus*), fin and minke whales, the forechamber functions as a microbial fermentation chamber, which may allow better utilisation of prey (Morii & Kanazu 1972, Herwig *et al.* 1984, Olsen *et al.* 1994). This is not evident in the pilot whale.

The proper-gastric chamber is bulbous and lined by a labyrinth of rugae. The mucosa consists of long zymogenic glands with mucous neck, parietal and chief cells. Mucous neck cells are absent in many cetacean species (Harrison *et al.* 1970, Yamasaki & Kamiya 1981, Rice & Wolman 1990). The long zymogenic glands, as in fur seals, are as a result of the increased number of parietal cells, which may indicate an increased HCl secretion. This suggests that the proper-gastric chamber has a large surface area with great trituration of the small chunks of food that are broken down principally by chemical action. The increased HCl secretion may be required because the proper-gastric chamber has to supply gastric juice to the forechamber for the breakdown of large chunks of ingested food.

The proper-gastric chamber opens into the pyloric chamber via the narrow cranial pyloric orifice. The cranial pyloric portion is closely associated with the wall of the proper-gastric chamber and is divided into two parts by a soft tissue septum and opens into the tubular caudal pyloric portion via a narrow orifice. This suggests that the cranial pyloric portion acts as a valve to restrict the passage of chunks of ingesta and regulate the flow of ingesta into the caudal pyloric portion (Harrison *et al.* 1970, Yamasaki & Takahashi 1971, Rice & Wolman 1990). Some cetacean species diverge from this general plan. For example, the cranial pyloric portion has no direct association to the proper-gastric chamber wall in the narwhal and beluga whale, and is a single channel in the harbour porpoise and white-beaked dolphin (Turner 1889, Harrison *et al.* 1970, Yamasaki & Kamiya 1981). The reasons for these are unclear.

The tubular caudal pyloric portion is thin walled, lined by sparse rugae and empties into the duodenum by the well-developed pyloric orifice. The mucosa consists of pyloric mucous glands, which suggests that in the pyloric chamber the digesta becomes more alkaline before it leaves the stomach, and like the cranial pyloric portion, the pyloric orifice regulates the flow of digesta into the duodenum.

The closeness of the forechamber, proper-gastric and cranial pyloric orifices to each other result in the forechamber and proper-gastric chamber appearing like suspended sacs. This suggests there is rapid movement of fluids and small particles from esophagus to forechamber to proper-gastric and pyloric chamber, or even direct from the esophagus to the proper-gastric chamber, while larger chunks of ingested food are held in the forechamber. This arrangement could be equivalent to the reticular groove in suckling ruminants, which shunts suckled milk directly from the esophagus to the abomasum, avoiding possible fermentation in the as yet non-functional ruminoreticulum (Titchen & Newhook 1975).

The pilot whale stomach is similar to that described for most other cetacean species (Harrison *et al.* 1970, Smith 1972, Yamasaki *et al.* 1974, Olsen *et al.* 1994, Langer 1996). However, in some cetacean species, the stomach plan is different to the pilot whale as the esophagus empties into both the forechamber and proper-gastric chamber (Turner 1889) or into the proper-gastric chamber first (Yamasaki & Takahashi 1971, Yamasaki & Kamiya 1981). This suggests that ingesta and gastric juice move between the chambers, or that ingesta is regurgitated from the proper-gastric chamber into the forechamber (Yamasaki & Takahashi 1971, Yamasaki & Kamiya 1981).

In beaked whales and some river dolphins, the forechamber is absent, the proper-gastric chamber is divided into two parts and there are a greater number of pyloric subcompartments (Yamasaki & Takahashi 1971, Yamasaki *et al.* 1974, Yamasaki & Kamiya 1981, Pfeiffer 1993). This may be a specialisation related to the method of ingestion by sucking (Pfeiffer 1993), or the absent forechamber may be a result of regression or confluence with the proper-gastric chamber or just did not develop. It is unlikely that they are because of diet (Fitch & Brownell 1971, Yamasaki & Kamiya 1981).

The stomachs of the pilot whales were often empty. The few contents that were present consist mainly of warty squid beaks, which have not previously been reported in pilot whale stomachs because there have been no dietary studies on this species in New Zealand waters. Although stones were absent in the stomach they have been found in other cetaceans and are present for similar reasons as discussed for the fur seal (Fiscus & Baines 1966, Laws 1953, Harrison & Kooyman 1968).

Gastric ulcers were found in the forechamber, proper-gastric and pyloric chambers of the stomach. The ulcers in the forechamber were presumed to be because of parasitic and non-parasitic effects. This is because parasites were present in the chamber, although not directly associated with the ulcers, and because the chamber is exposed to abrasive objects such as fish bones, which may damage the lining and result in subsequent ulceration. The ulcers in the proper-gastric and pyloric chambers are likely to be because of non-parasitic effects as parasites were absent in these chambers. This is similar to that reported in other cetaceans (Geraci & Gerstmann 1966, Simpson & Gardner 1972, Geraci 1981). Personal observations of the cranial pyloric portion of the stomach of a captive common dolphin found presumed non-parasitic ulceration from the herring diet that may cause histamine toxicosis and subsequent ulceration (Geraci & Gerstmann (1966).

The mesogastria were devoid of fat and form an omental bursa. The presence of fat is for similar reasons described for the fur seal. The attachments of the dorsal and ventral mesogastria are similar to that reported in other cetaceans (Langer 1996). However, the dorsal mesogastrium in the pilot whale and common dolphin closely attaches the spleen to the right medial surface of the forechamber, but in Risso's dolphin it is attached to the proper-gastric chamber (Turner 1889, Langer 1996). It is unclear why there are different locations of splenic attachment, but the close attachment in all species is because of the organs being compacted to minimise protuberances.

The weight of the stomach increases with age and is because of similar reasons described for the fur seal. The proportion of stomach weight to body weight and length has not been reported for other cetacean species. However, the chamber volumes as a proportion of total volume are similar values to the minke whale (Olsen *et al.* 1994).

The relative sizes of the chambers change with age of the animal. The forechamber increases proportionally while both the proper-gastric and pyloric chambers decrease. This suggests that the functional importance of each chamber change with maturity of the animal. Therefore, the proper-gastric chamber is more important for chemical digestion in suckling juvenile whales and the forechamber for mechanical digestion in older whales (Smith 1972, Yamasaki *et al.* 1974, Olsen *et al.* 1994, Langer 1996). This general pattern is different in beaked whales and river dolphins that lack a forechamber.

Olsen *et al.* (1994) and Langer (1996) suggested that stomach size and volume are influenced by the physical and biochemical characteristics of the diet, quantity of food ingested and rates of ingestion.

In summary, swallowed food enters the forechamber where by mechanical and preliminary chemical activity it is digested into pieces small enough to pass into the proper-gastric chamber where it is further digested primarily by chemical activity. The ingesta then passes through the pyloric chamber where it becomes more alkaline and empties into the duodenum.

The most likely explanation for the anatomical structure of the pilot whale stomach is, like that of the fur seal, to accommodate unmasticated food and impede the passage until the food is sufficiently broken down, while maintaining a streamlined body shape. It is also likely to allow the ingestion of a greater quantity of prey per feeding episode, rapid passage of fluids and small particles and shorter times between each feeding episode. This is because each chamber can hold ingesta independently and therefore several stages of digestion can be occurring simultaneously and as long as the forechamber is relatively empty it can accommodate more food.

Ancestry also influences the anatomy of the pilot whale stomach as they have evolved from a the same ancestor as ruminants, which is reflected in their basic anatomy.

5.4 **Comparative anatomy of the fur seal and the pilot whale stomachs**

The results of this study indicate that the stomach of the New Zealand fur seal is grossly different but histologically similar to the stomach of the long-finned pilot whale.

Whereas the fur seal stomach is single chambered, the stomach of the pilot whale is composed of three chambers. The fur seal stomach has two orifices and the pilot whale stomach has five. The lining of the fur seal stomach is grossly similar throughout the stomach except for differences in rugae between proper-gastric and pyloric regions. In comparison, the lining and rugae of the pilot whale stomach are grossly different in each chamber, with the changes occurring abruptly. The structure of the stomach walls of the fur seal and the pilot whale are similar. However, differences are evident in the mucosa and the wall thickness. The mucosa of the fur seal stomach consists of three histological zones. The change between cardiac and proper-gastric zones is abrupt but the change between proper-gastric and pyloric zones is gradual. In the pilot whale, the mucosa also consists of three histological zones. However, the cardiac zone is absent and a non-glandular zone is present. The proper-gastric and pyloric zones are present but the change between all zones is abrupt. Both the fur seal and the pilot whale share the long zymogenic glands and increased number of parietal cells in the proper-gastric zone. The mucous neck cells have a uniform distribution along the glands in the fur seal stomach, but are found only in the upper portions of the glands in the pilot whale stomach. The muscle layers in the walls of the pilot whale forechamber and proper-gastric chamber are thicker than those of the fur seal stomach. However, both the fur seal and pilot whale share the thin wall of the pyloric region. The proportional stomach weight to total body weight and body length is less in the fur seal than the pilot whale.

An explanation for the differences and similarities in stomach anatomy between the fur seal and pilot whale is due to ancestral and environmental influences, which play equally important roles in development (Avey 1965). It is unlikely that diet significantly affects the stomach anatomy because the fur seal and pilot whale utilise similar prey and methods of feeding.

The fur seal and pilot whale are phylogenetically unrelated species (Barnes *et al.* 1985).

The fur seal is an otariid seal that descended from carnivorous bear-like ancestors (Mitchell & Tedford 1973), while the pilot whale is an odontocete whale that descended from artiodactyls, which are also the ancestors of ruminants (Gingerich *et al.* 1990, Milinkovitch *et al.* 1993, Thewissen & Hussain 1993).

The fur seal and pilot whale, as in all mammals, once shared a common vertebrate ancestor but evolved into different animals reflecting specialisations from the different ecological niches. As evolution continued they started utilising similar niches and converged into similar behavioural and physiological states while retaining the different anatomical characters of their divergent ancestors. Evidence of the distant shared ancestor is apparent in the early stages of embryonic development where all mammals have common features (Avey 1965). However, during the course of embryonic development the resemblances diminish as the individual passes through stages determined by the series of adult ancestors from which they have descended (Avey 1965).

In the fur seal and the pilot whale the phylogenetic differences are evident in the stomach anatomy with the fur seal retaining typical carnivorous characteristics of the stomach, while the pilot whale has retained typical artiodactyl characteristics.

Both species have developed special features of their stomach that have evolved because they reside in water with a temperature below their critical body temperature and that has a greater density than air. To maintain thermal balance marine mammals use theremoregulatory mechanisms that require energy (Wartzok 1991). To fulfil these energy requirements marine mammals have increased nutritive demands, which suggests they devote more time to foraging, ingest a greater volume of prey per feeding episode and increase the rate of food passage through the digestive tract (Smith 1972, Needham 1985, Dellinger & Trillmich 1988). The stomach is therefore required to process a greater amount of unmasticated food, by more effective mechanical and chemical breakdown and with a rapid clearance rate (Needham 1985, Richardson & Gales 1987).

Stomach anatomy is also influenced by the requirement to maintain streamlining of the body shape. Streamlining is important in marine mammals because water is denser than air, and streamlining ensures that they can move through the water with minimal exertion. It is maintained by minimising protuberances, which is achieved by many adjustments including compacting of organs. The compacting of organs affect the anatomy of the stomach including restricting the volume of the stomach and thereby requiring an increase in the rate of food passage to ensure the distended stomach does not disrupt the external body contour.

Although pinnipeds and cetaceans have grossly different stomachs they appear to be equally successful in utilising ingested prey (Keiver *et al.* 1984, Nordoy *et al.* 1993, Martensson *et al.* 1994).

5.5 **Possibilities for future research**

The results of this study have highlighted a number of possible topics for future research. Anatomical work could be undertaken on the embryological development of the stomachs of marine mammals to compare them with those of terrestrial mammals to provide some insight on the evolution of the stomach in marine mammals.

Further light microscopy could be undertaken to determine the numbers of mucous neck, parietal and chief cells and their relative proportions in the stomachs of marine mammals compared to terrestrial mammals. Electron microscopy could be undertaken to determine the activity of mucous neck and parietal cells and whether the increased numbers of these cells indicates an increased secretory activity.

It appears some cetaceans utilise microbial fermentation. Considerations as to how they cope with the end products of the process need to be addressed. For example, how do they process the gases and buffer the volatile fatty acids produced by the microbes?

In the future, with further studies and the development of new techniques, our knowledge of the digestive strategies employed by marine mammals will be enhanced.

Chapter Six

Conclusions

It is concluded that the New Zealand fur seal stomach is grossly different to the stomach of the long-finned pilot whale. The composition of the stomach wall and its histological architecture are generally similar in both species. However, they differ in the following aspects: the long-finned pilot whale has a non-glandular forechamber, the cardiac zone is absent, the stomach wall is thicker and the transitions between histological zones are more abrupt.

The stomach of the New Zealand fur seal is similar to the general pinniped plan, while that of the long-finned pilot whale is similar to the general cetacean plan.

The similarities in stomach anatomy are due to a common but distant vertebrate ancestor. However, since this common ancestor they diverged into phylogenetically different families: one a bear-like carnivore, and the other an artiodactyl. The New Zealand fur seal and the long-finned pilot whale have evolved from these intermediate ancestors, but have retained some of the typical characteristics, therefore explaining many of the differences in stomach anatomy between the two species.

Similar environmental pressures such as being warm-blooded animals in a cold sea and streamlining have also contributed to the evolution of the stomachs in both species.

Literature cited

Amasaki, H., M. Daigo, J. Taguchi and S. Nishiyama. 1989. Morphogenesis of the digestive tract in the fetuses of the Southern minke whale, *Balaenoptera acutorostrata*. *Anatomischer Anzeiger* **169**: 161-168. (cited by Olsen *et al.* 1994b).

American Society of Mammalogists, Committee on Marine Mammals. 1967. Standard measurements of seals. *Journal of Mammalogy* **48**: 459-462.

Avey, L.B. 1965. *Developmental anatomy: a textbook and laboratory manual of embryology*. 7th Edition. WB Saunders Company, Philadelphia. pp 645.

Baker, A.N. 1999. *Whales and dolphins of New Zealand and Australia: an identification guide*. 3rd Edition. Victoria University Press, Wellington. pp 133.

Barnes, L.G., D.P. Domning, C.E. Ray. 1985. Status of studies on fossil marine mammals. *Marine Mammal Science* **1**: 15-53.

Benditt, E.P. and R.L. Wong. 1957. On the concentration of 5-hydroxytryptamine in mammalian enterchromaffin cells and its release by reserpine. *Journal of Experimental Medicine* **105**: 509-519.

Blanco, C., J. Aznar and J.A. Raga. 1995. Cephalopods in the diet of the striped dolphin, *Stenella coeruleoalba*, from the Western Mediterranean during an epizootic in 1990. *Journal of Zoology* **237**: 151-158.

Brodie, D.A. and H.M. Hanson. 1960. A study of the factors involved in the production of gastric ulcers by the restraint technique. *Gastroenterology* **38**: 353-360.

Bryden M.M. 1971. Size and growth of viscera in the Southern elephant seal, *Mirounga leonina* (L.). *Australian Journal of Zoology* **19**: 103-120.

Bryden, M.M. 1972. Growth and development of marine mammals. *In Functional anatomy of marine mammals*. Volume 1. Edited by RJ Harrison. Academic Press, New York. pp 1-79.

Bryden, M.M. and A.W. Erickson. 1976. Body size and composition of crabeater seals (*Lobodon carcinophagus*) with observations on tissue and organ size in Ross seals (*Ommatophoca rossi*). *Journal of Zoology, London* **179**: 235-247.

Burne, R.H. 1909. Notes on the viscera of a walrus (*Odobenus rosmarus*). *Proceedings of the Zoological Society of London*: 732-738.

Carey, P.W. 1991 Fish prey species of the New Zealand fur seal (*Arctocephalus forsteri* Lesson.*)*. *Department of Conservation Science and Research Internal Report* No. **115**.

Cormack, D.H 1993. *Essential Histology*. JB Lippincott Company, Philadelphia. pp 271-306.

Crawley, M.C. 1975. Growth of New Zealand fur seal pups. *New Zealand Journal of Marine and Freshwater Research* **9**: 539-545.

Crawley, M.C. and G.J. Wilson. 1976. The natural history and behaviour of the New Zealand fur seal (*Arctocephalus forsteri*). *Tuatara* **22**:1-29.

Dellinger, T. and F. Trillmich. 1988. Estimating diet composition from scat analysis in otariid seals (Otariidae): is it reliable? *Canadian Journal of Zoology* **66**: 1865-1870.

Desportes, G. and R. Mouritsen. 1993. Preliminary results on the diet of long-finned pilot whales off the Faroe Islands. *In Biology of Northern Hemisphere Pilot Whales. Report of the International Whaling Commission*. Special issue 14. Edited by GP Donovan, CH Lockyer and AR Martin. Cambridge. pp 305-324.

Dix, B. 1993. Population changes and diet preferences of the New Zealand fur seal *Arctocephalus forsteri* MSc thesis. Victoria University, Wellington. pp 98.

Di Fiore, M.S.H. 1963. *An atlas of human histology*. 2nd Edition. Lea & Febiger, Philadelphia. pp 224.

Dyce, K.M., W.O. Sack and C.J.G. Wensing. 1996. *Textbook of veterinary anatomy*. 2nd Edition. WB Saunders Company, Philadelphia. pp 820.

Eastman, J.T. and R.E. Coalson. 1974. The digestive system of the Weddell seal, *Leptonychotes weddelli*: a review. *In Functional anatomy of marine mammals*. Volume 2. Edited by RJ Harrison. Academic Press, London. pp 253-320.

Evans, P.G.H. 1987 Food and feeding. *In The natural history of whales and dolphins*. Christopher Helm, London. pp 119-158.

Fiscus, C.H. and G.A. Baines. 1966. Food and feeding behaviour of Steller and California sea lions. *Journal of Mammalogy* **47**: 195-200.

Gales, R. and D. Pemberton. 1992. Stomach contents of long-finned pilot whales (*Globicephala melas*) and bottlenose dolphins (*Tursiops truncatus*) in Tasmania. *Marine Mammal Science* **8**: 405-413.

Gannon, D.P., A.J. Read, J.E. Craddock and J.G. Mead. 1997. Stomach contents of long-finned pilot whales (*Globicephala melas*) stranded on the U.S. mid-Atlantic coast. *Marine Mammal Science* **13**: 405-418.

Geiger, E. 1955. Role of histamine in poisoning with spoiled fish. *Science* **121**: 865-866.

Geraci, J.R. 1981. Dietary disorders in marine mammals: synthesis and new findings. *Journal of the American Veterinary Medical Association* **179**: 1183-1191.

Geraci, J.R. and K.E. Gerstmann. 1966. Relationship of dietary histamine to gastric ulcers in the dolphin. *Journal of the American Veterinary Medical Association* **149**: 884-890.

Gingerich, P.D., B.H. Smith and E.L. Simons. 1990. Hind limbs of Eocene *Basilosaurus*: evidence of feet in whales. *Science* **249**: 154-157.

Gorzelany, J.F. 1998. Unusual deaths of two free-ranging Atlantic bottlenose dolphins (*Tursiops truncatus*) related to ingestion of recreational fishing gear. *Marine Mammal Science* **14**: 614-617.

Green, R.F. 1972. Observations on the anatomy of cetaceans and pinnipeds. *In Mammals of the sea: biology and medicine*. Edited by SH Ridgway. Charles C Thomas Press, USA. pp 247-297.

Harkonen, T. 1987. Seasonal and regional variation in the feeding habits of the harbour seal, *Phoca vitulina* in Skagerrak and the Kattegat. *Journal of Zoology* **213**: 535-543.

Harrison, R.J., F.R. Johnson and B.A. Young. 1970. The esophagus and stomach of dolphins (*Tursiops, Delphinus, Stenella*). *Journal of the Zoological Society of London* **160**:377-390.

Harrison, R.J. and G.L. Kooyman. 1968. General physiology of the pinnipedia. *In The behaviour and physiology of pinnipeds.* Edited by RJ Harrison, RC Hubbard, RS Peterson, CE Rice and RJ Schusterman. Appleton Century Crofts, New York. pp 211-296.

Helm, R.C. 1984. Rate of digestion in three species of pinnipeds. *Canadian Journal of Zoology* **62**: 1751-1756.

Hepburn, D. 1896. *Halichoerus grypus*: the grey seal. Observations on its external appearances and visceral anatomy. *Journal of Anatomy and Physiology* **30**: 413-488.

Herwig, R.P., J.T. Staley, M.K. Nerini and H.W. Braham. 1984. Baleen whales: preliminary evidence for forestomach microbial fermentation. *Applied and Environmental Microbiology* **47**:421-423.

Home, E. 1807. Observations on the structure of the different cavities, which constitute the stomach of the whale, compared with those of ruminating animals, with a view to ascertain the situation of the digestive organ. *Philosophical Transactions of the Royal Society of London* **97**: 93-103.

Hosokawa, H. and T. Kamiya. 1971. Some observations on the cetacean stomachs, with special considerations on the feeding habits of whales. *Scientific Reports: Whales Research Institute* **23**: 91-101.

Karam, S. and C.P. Leblond. 1995. Origin and migratory pathways of the 11 epithelial cell types present in the body of the mouse stomach. *Microscopy Research and Technique* **31**: 193-214.

Keiver, K.M., K. Ronald and F.W.H. Beamish. 1984. Metabolisable energy requirements for maintenance and faecal and urinary losses of juvenile harp seals (*Phoca groenlandica*). *Canadian Journal of Zoology* **62**: 769-776.

Keyes, M. 1965. Pathology of the Northern fur seal. *Journal of the American Veterinary Medical Association* **147**: 1090-1095.

King, J.E. 1983. *Seals of the world.* 2nd Edition. British Museum of Natural History, London; and Oxford University Press, Oxford. pp 208.

Langer, P. 1988. *The mammalian herbivore stomach: comparative anatomy, function and evolution.* Gustav Fischer, Stuttgart, New York. pp 557.

Langer, P. 1996. Comparative anatomy of the stomach of the cetacea. Ontogenetic changes involving gastric proportions, mesenteries, arteries. *Zeitschrift fur Saugetierkunde (International Journal of Mammalian Biology)* **61**: 140-154.

Laws, R.M. 1953. The elephant seal (*Mirounga leonina* Linn.). I. Growth and age. *Falkland Islands Dependencies Survey. Scientific Reports* **8**: 62.

Liu, S.K. and A.G. Edward. 1971. Gastric ulcers associated with Contracaecum spp. (Nematoda: Ascaroidea) in a Steller sea lion and a white pelican. *Journal of Wildlife Diseases* **7**: 266-271.

Martensson, P.E., E.S. Nordøy and A.S. Blix. 1994a. Digestibility of crustaceans and capelin in harp seals (*Phoca groenlandica*). *Marine Mammal Science* **10**:325-331.

Mead, J.G. and R.L. Brownell. 1993. Order cetacea. *In Mammal species of the world: a taxonomic and geographic reference.* 2nd Edition. Edited by DE Wilson and DM Reeder. Smithsonian Institution Press, Washington. pp 349-364.

Migaki, G., D. Van Dyke and R.C. Hubbard. 1971. Some histopathological lesions caused by helminths in marine mammals. *Journal of Wildlife Diseases* **7**: 281-289.

Milinkovitch, M.C., G. Orti and A. Meyer. 1993. Revised phylogeny of whales suggested by mitochondrial ribosomal DNA sequences. *Nature* **361**: 346-348.

Mitchell, E..D. and R.H. Tedford. 1973. The Enaliarctinae: a new group of extinct aquatic carnivora and a consideration of the origin of the Otariidae. *Bulletin of the American Museum of Natural History* **151**: 201-284.

Morii, H. and R. Kanazu. 1972. The free volatile fatty acids in the blood and stomach fluid from porpoise, *Neomeris phocaenoides. Bulletin of the Japanese Society of Scientific Fisheries* **38**:1035-1039.

Murie, J. 1873. On the organisation of the Caaing whale, *Globiocephalus melas*. *Transactions of the Zoological Society of London* **8** (part 4): 235-301.

Murie, J. 1874. Researches upon the anatomy of the pinnipeda: descriptive anatomy of the sea lion (*Otaria jubata*). *Transactions of the Zoological Society of London* **8**:501-582.

Needham, D.J. 1985. The role of stones in the sea lion stomach. *Proceedings of the Anatomical Society of Australia and New Zealand.* pp 67.

Nishiwaki, M. 1972. General biology. *In Mammals of the sea: biology and medicine*. Edited by SH Ridgway. Charles C Thomas, USA. pp 3-204.

Noden, D.M. and A. De Lahunta. 1985. Digestive system. *In The embryology of domestic animals: developmental mechanisms and malformations.* Williams & Wilkins, Baltimore, London. pp 292-311.

Nomina Anatomica Veterinaria, 4th Edition and Nomina Histologica. 2nd Edition. 1994. Published by the International Committee on Veterinary Gross Anatomical and Histological Nomenclature, and authorised by the World Association of Veterinary Anatomists; Ithaca, New York. pp 269.

Nordøy, E.S., W. Sørmo and A.S. Blix. 1993. *In vitro* digestibility of different prey species of minke whales (*Balaenoptera acutorostrata*). *British Journal of Nutrition* **70**: 485-489.

Olsen, M.A., E.S. Nordøy, A.S. Blix and S.D. Mathiesen. 1994b. Functional anatomy of the gastrointestinal system of Northeastern Atlantic minke whale (*Balaenoptera acutorostrata*). *Journal of the Zoological Society of London* **234**:55-74.

Olsen, M.A., K.T. Nilssen and S.D. Mathiesen. 1996b. Gross anatomy of the gastrointestinal system of harp seals (*Phoca groenlandica*). *Journal of Zoology, London* **238**: 581-589.

Olsen, M.A., T.H. Aagnes and S.D. Mathiesen. 1994a. Digestion of herring by indigenous bacteria in the minke whale forestomach. *Applied Environmental Microbiology* **60**: 4445-4455.

Oppel, A. 1896. Lehrbuch der vergleichenden mikroskopischen Anatomie der Wirbeltiere. *Gustav Fisher, Jena.* pp 1-3.

Owen, R. 1830. Untitled. *Proceedings of the Zoological Society of London* **1**:151-154.

Owen, R. 1853. On the anatomy of the walrus. *Proceedings of the Zoological Society of London*:103-106.

Pfeiffer, C.J. 1993. Neural and muscular control functions of the gut in odontocetes: morphologic evidence in beaked whales and beluga whales. *Journal of Physiology* **87**:349-354.

Pilliet, A.H. 1894. *Competes Rendus des Seances. Societe de Biologie, Paris* **1**: 743-745.

Rice, D.W. and A.A. Wolman. 1990. The stomach of *Kogia breviceps*. *Journal of Mammalogy* **71**: 237-242.

Richardson, K.C. and N.J. Gales. 1987. Functional morphology of the alimentary tract of the Australian sea lion, *Neophoca cinerea. Australian Journal of Zoology* **35**: 219-226.

Ridgway, S.H. 1972. *Mammals of the sea: biology and medicine*. Charles C Thomas Press, USA. pp 812.

Scheffer, V.B. 1960. Weights of organs and glands in the Northern fur seal. *Mammalia* **24**: 476-481.

Schreiber, S. and P. Shield. 1997. Gastric mucus of the guinea pig: proton carrier and diffusion barrier. *American Journal of Physiology* **272**: G63-70.

Schumacher, U., P. Klein, J. Plotz and U. Welsch. 1995. Histological, histochemical, and ultrastructural investigations on the gastrointestinal system of Antartic seals: Weddell seals (*Leptonychotes weddelli*) and crabeater seals (*Lododon carcinophagus*). *Journal of Morphology* **225**: 229-249.

Sergeant, D.E. 1962. The biology of the pilot or pothead whale *Globicephala melaena* (Traill) in Newfoundland waters. *Bulletin Fisheries Research Board Canada* **132**: 1-84. (cited by Desportes & Mouritsen 1993).

Shaughnessy, P.D., N.J. Gales, T.E. Dennis and S.D. Goldsworthy. 1994. Distribution and abundance of New Zealand fur seals *Arctocephalus forsteri* in South Australia and Western Australia. *Wildlife Research* **21**: 667-695.

Simpson, J.G. and M.B. Gardner. 1972. Comparative microscopic anatomy of selected marine mammals. *In Mammals of the sea: biology and medicine.* Edited by SH Ridgway. Charles C Thomas Press, USA. pp 298-418.

Slijper, E.J. 1962. *Whales.* Butterworth, London. pp 274.

Smith, G.J.D. 1972. The stomach of the harbour porpoise *Phocoena phocoena. Canadian Journal of Zoology* **50**:1611-1616.

Sorensen, J.H. 1969. New Zealand fur seals with special reference to the 1946 open season. Fisheries Technical Report, New Zealand Marine Department 42. pp 80.

Stevens, C.E. 1988. *Comparative physiology of the vertebrate digestive system.* Cambridge University Press, USA. pp 300.

Street, R.J. 1964. Feeding habits of the New Zealand fur seal, *Arctocephalus forsteri. New Zealand Marine Department Fisheries Technical Report* **9**.

Tarpley, R.J., R.F. Sis, T.F. Albert, L.M. Dalton and J.C. George. 1987. Observations on the anatomy of the stomach and duodenum of the bowhead whale, *Balaena mysticetus. The American Journal of Anatomy* **180**: 295-322.

Thewissen, J.G.M. and S.T. Hussain. 1993. Origin of underwater hearing in whales. *Nature* **361**:444-445.

Titchen, D.A. and J.C. Newhook. 1975. Physiological aspects of suckling and the passage of milk through the ruminant stomach. *In Digestion and metabolism in the ruminant.* Edited by IW McDonald and ACI Warner. University New England Publication Unit, Armidale. pp 15-29.

Turner, W.M. 1868. Further observations on the stomach in the cetacea. *Journal of Anatomy and Physiology* **3**: 117-119.

Turner, W.M. 1889. Additional observations on the stomach in the Ziphoid and Delphinoid whales. *Journal of Anatomy and Physiology* **13**: 466-492.

Vik, R. 1964. Penetration of stomach wall by Anisakis-type larvae in porpoises. *Canadian Journal of Zoology* **42**: 513.

Wartzok, D. 1991. Physiology of behaviour in pinnipeds. *In The behaviour of pinnipeds.* Edited by D Renouf. Chapman and Hall, London. pp 236-299.

Williams, P.L., R. Warwick, M. Dyson and L.H. Bannister. 1989. The alimentary system. *In Gray's Anatomy.* 37th *Edition.* Churchill Livingstone, Edinburgh. pp 1286-1396.

Wilson, T.M. and P.H. Stockdale. 1970. The harp seal, *Pagophilus groenlandicus* (Erxleben, 1777) XI. *Contracaecum* sp. infestation in a harp seal. *Journal of Wildlife Diseases* **6**: 152-154.

Wozencraft, W.C. 1993. Order carnivora. *In Mammal species of the world: a taxonomic and geographic reference.* 2nd Edition. Edited by DE Wilson and DM Reeder. Smithsonian Institution Press, Washington. pp 279-348.

Yamasaki, F. and K. Takahashi. 1971. Digestive tract of Ganges dolphin, *Plantanista gangetica.* Oesophagus and stomach. *Okajimas Folia Anatomica Japonica* **48**: 271-293.

Yamasaki, F., K. Takahashi and T. Kamiya. 1974. Digestive tract of La Plata dolphin, *Pontoporia blainvillei.* Oesophagus and stomach. *Okajimas Folia Anatomica Japonica* **51**: 29-52.

Yamasaki, F. and T. Kamiya. 1981. The stomach of the Boutu, *Inia geoffrensis*: comparison with those of other Platanistids. *Scientific Report: Whales Research Institute* **33**: 69-81.

Yates, C.R-B. 1984. The anatomy of the digestive system of the New Zealand fur seal (*Arctocephalus forsteri*, Lesson 1828). Unpublished Bachelor of Philosophy thesis, Massey University, Palmerston North, New Zealand. pp 89.

Young, D.D. and V.G. Cockcroft. 1994. Diet of common dolphins, *Delphinus delphis*, off the south-east coast of Southern Africa: opportunism or specialisation. *Journal of Zoology* **234**: 41-53.

Appendix 1

Species named in the text

Data from Wozencraft (1993) and Mead & Brownell (1993)

Common name	**Scientific name**	**Described by**
Order: Pinnipedia		
Family: Otariidae		
Australian fur seal	*Arctocephalus pusillus doriferus*	Wood Jones, 1925
Australian sea lion	*Neophoca cinerea*	(Péron, 1816)
New Zealand fur seal	*Arctocephalus forsteri*	(Lesson, 1828)
New Zealand sea lion	*Phocarctos hookeri*	(Gray, 1844)
Northern fur seal	*Callorhinus ursinus*	(Linnaeus, 1758)
Steller sea lion	*Eumetopias jubatus*	(Schreber, 1776)
Subantarctic fur seal	*Arctocephalus tropicalis*	(Gray, 1872)
Family: Odobenidae		
Walrus	*Odobenus rosmarus*	(Linnaeus, 1758)
Family: Phocidae		
Crabeater seal	*Lobodon carcinophagus*	(Hombron & Jacquinot, 1842)
Grey seal	*Halichoerus grypus*	(Fabricius, 1791)
Harbour seal	*Phoca vitulina*	Linnaeus, 1758
Harp seal	*Phoca groenlandica*	Erxleben, 1777
Ross seal	*Ommatophoca rossii*	Gray, 1844
Southern elephant seal	*Mirounga leonina*	(Linnaeus, 1758)
Weddell seal	*Leptonychotes weddellii*	(Lesson, 1826)

Order: Cetacea

Suborder: Odontoceti

Family: Delphinidae

Bottlenose dolphin	*Tursiops truncatus*	(Montagu, 1821)
Common dolphin	*Delphinus delphis*	Linnaeus, 1758
Dusky dolphin	*Lagenorhynchus obscurus*	(Gray, 1828)
Humpbacked dolphin	*Sousa chinensis*	(Osbeck, 1765)
Long-finned pilot whale	*Globicephala melas*	(Traill, 1809)
Long-snouted spinner dolphin	*Stenella longirostris*	(Gray, 1828)
Pacific white-sided dolphin	*Lagenorhynchus obliquidens*	Gill, 1865
Risso's dolphin	*Grampus griseus*	Cuvier, 1812
White beaked dolphin	*Lagenorhychus albirostris*	(Gray, 1846)

Family: Monodontidae

Beluga whale	*Delphinapterus leucas*	(Pallas, 1776)
Narwhal	*Monodon monoceros*	Linnaeus, 1758

Family: Phocoenidae

Harbour porpoise	*Phocoena phocoena*	(Linnaeus, 1758)

Family: Physeteridae

Pygmy sperm whale	*Kogia breviceps*	(Blainville, 1838)

Family: Platanistidae

Boutu dolphin	*Inia geoffrensis*	(Blainville, 1817)
Ganges dolphin	*Platanista gangetica*	(Roxburgh, 1801)
La Plata dolphin	*Pontoporia blainvillei*	(Gervais & d'Orbigny, 1844)

Family: Ziphiidae

Blainville's beaked whale	*Mesoplodon densirostris*	(Blainville, 1817)
Cuvier's beaked whale	*Ziphius cavirostris*	Cuvier, 1823
Northern bottlenose whale	*Hyperoodon ampullatus*	(Forster, 1770)

Southern bottlenose whale	*Hyperoodon planifrons*	Flower, 1882
Sowerby's beaked whale	*Mesoplodon bidens*	(Sowerby, 1804)

Suborder: Mysticeti

Family: Balaenidae

Bowhead whale	*Balaena mysticetus*	Linnaeus, 1758

Family: Balaenopteridae

Blue whale	*Balaenoptera musculus*	(Linnaeus, 1758)
Fin whale	*Balaenoptera physalus*	(Linnaeus, 1758)
Minke whale	*Balaenoptera acutorostrata*	Lacépède, 1804
Sei whale	*Balaenoptera borealis*	Lesson, 1828

Family: Eschrichtiidae

Grey whale	*Eschrichtius robustus*	(Lilljeborg, 1861)

Appendix 2

Concordance of Terminology

Terminology used	Alternative terminology	Authors using alternative terminology
Forechamber	First chamber	(Turner 1889, Yamasaki & Takahashi 1971, Rice & Wolman 1990)
	First stomach	(Home 1807)
	First gastric cavity	(Murie 1873)
	Forestomach	(Harrison *et al.* 1970, Yamasaki & Takahashi 1971, Smith 1972, Yamasaki & Kamiya 1981, Tarpley *et al.* 1987, Rice & Wolman 1990, Langer 1996)
	Esophageal stomach	(Yamasaki & Takahashi 1971)
	Esophageal compartment	(Turner 1889)
Proper-gastric chamber	Second chamber	(Murie 1873, Turner 1889)
	Second stomach	(Home 1807)
	True gastric cavity	(Murie 1873)
	Main stomach	(Harrison *et al.* 1970, Smith 1972, Yamasaki *et al.* 1974, Yamasaki & Kamiya 1981, Rice & Wolman 1990, Langer 1996)
	Cardiac compartment	(Turner 1889)
	Fundic chamber	(Tarpley *et al.* 1987, Rice & Wolman 1990)
	Fundus glandular chamber	(Yamasaki & Takahashi 1971)

Pyloric chamber

-cranial	Third chamber	(Turner 1889)
	Third stomach	(Home 1807)
	Third gastric cavity	(Murie 1873)
	Connecting stomach	(Langer 1996)
	Connecting channel	(Harrison *et al.* 1970, Smith 1972, Yamasaki *et al.* 1974, Yamasaki & Kamiya 1981, Tarpley *et al.* 1987, Rice & Wolman 1990)
	Intermediate compartment	(Turner 1889)
-caudal	Fourth chamber	(Turner 1889)
	Fourth stomach	(Home 1807)
	Fourth gastric cavity	(Murie 1873)
	Pyloric stomach	(Harrison *et al.* 1970, Smith 1972, Yamasaki *et al.* 1974, Yamasaki & Kamiya 1981, Langer 1996)
	Pyloric chamber	(Turner 1889, Rice & Wolman 1990)
	Pyloric glandular stomach	(Yamasaki & Takahashi 1971)

Mesogastrium

Dorsal	Omentum majus	(Yamasaki & Takahashi 1971, Yamasaki *et al.* 1974)
Ventral	Omentum minus	(Yamasaki & Takahashi 1971, Yamasaki *et al.* 1974)

Appendix 3

Sources of study animals

Animal number	Date stranded	Location of stranding
New Zealand fur seals		
Af1	28 September 1995	Himitangi beach, Palmerston North
Af2	06 August 1996	Waikanae beach, Wellington
Af3	21 August 1996	Papamoa beach, Bay of Plenty
Af4	22 August 1996	Waikanae beach, Wellington
Af5	30 August 1996	Waikanae beach, Wellington
Af6	26 August 1996	Napier beach, Hawkes Bay
Af7	10 September 1996	Whirinaki Bluff, Hawkes Bay
Af8	02 October 1996	Whirinaki Bluff, Hawkes Bay
Af9	08 September 1997	Plimmerton beach, Wellington
Af10	3 August 1998	Waikanae beach, Wellington
Long-finned pilot whales		
Gm1	22 November 1996	Waikanae beach, Wellington
Gm2	unknown	unknown
Gm3	08 October 1997	Karikari beach, Kaitaia
Gm4	08 October 1997	Karikari beach, Kaitaia
Gm5	08 October 1997	Karikari beach, Kaitaia
Gm6	08 October 1997	Karikari beach, Kaitaia
Gm7	26 October 1997	Waikanae beach, Wellington

Appendix 4

Histological tissue processing schedule

Based on a schedule employed by histology laboratory of the Comparative Physiology and Anatomy section of the Institute of Veterinary, Animal and Biomedical Sciences, Massey University.

Small tissue samples schedule

Process	Reagent	Time (hrs)
Dehydration	70% alcohol	3
	95% alcohol	1
	absolute alcohol	1
	absolute alcohol	1
	absolute alcohol	0.75
	absolute alcohol	2.25
Clearing	chloroform	1
	xylene	1
	xylene	1
Impregnation	paraffin wax	2
	paraffin wax	2

Large tissue samples schedule (<5 mm)

Process	Reagent	Time (hrs)
Dehydration	70% alcohol	2
	95% alcohol	1
	absolute alcohol	1
	absolute alcohol	1
	absolute alcohol	2
	absolute alcohol	2
Clearing	xylene	1
	xylene	1
Impregnation	paraffin wax	2
	paraffin wax	2

Appendix 5

Histological tissue staining

Based on methods employed by the histology laboratory of the Comparative Physiology and Anatomy section of the Institute of Veterinary, Animal and Biomedical Sciences, Massy University

Haematoxylin & Eosin (H&E)

1. Dewax to water: (a) Immerse in 2 changes of xylene, 5 minutes each
    - (b) Rinse in absolute ethanol until slides clear
    - (c) Rinse in 70% ethanol until slides clear
    - (d) Rinse in tapwater
2. Stain in Mayer's Haemalum for 10 minutes
3. Rinse in tapwater
4. Blue in Scott's tapwater for 2 minutes
5. Rinse in tapwater
6. Stain in 1% aqueous eosin for 2 minutes
7. Rinse in tapwater
8. Differentiate and dehydrate in 70% ethanol and two changes of absolute ethanol until slides clear
9. Clear in two changes of xylene
10. Coverslip and mount with DPX.

Haematoxylin & van Gieson (H.vG)

1. Dewax to water: (a) Immerse in two changes of xylene, 5 minutes each
    - (b) Rinse in absolute ethanol until slides clear
    - (c) Rinse in 70% ethanol until slides clear
    - (d) Rinse in tapwater
2. Stain in Celestin Blue for 10 minutes
3. Rinse in tapwater
4. Stain in Mayer's Haemalum for 10 minutes

5. Rinse in tapwater
6. Blue in Scotts tapwater for 2 minutes
7. Rinse in tapwater
8. Stain in Van Gieson for 7 minutes
9. Rinse rapidly in tapwater
10. Differentiate, dehydrate rapidly in 70% ethanol and two changes of absolute ethanol until slides clear
11. Clear in two changes of xylene
12. Coverslip and mount with DPX

Verhoeffs Haematoxylin & van Gieson (VH.vG)

1. Dewax to water (a) Immerse in two changes of xylene, 5 minutes each
    (b) Rinse in absolute ethanol until slides clear
    (c) Rinse in 70% ethanol until slides clear
    (d) Rinse in tapwater
2. Mordant in Lugols iodine for 5 minutes
3. Rinse in tapwater
4. Immerse in 5% sodium Thiosulphate for 5 minutes
5. Rinse in tapwater
6. Stain in Verhoffs haematoxylin for 20-30 minutes or until sections are jet-black
7. Rinse in tapwater
8. Differentiate in 2% Ferric Chloride until collagen is almost colourless but elastic tissue remains black
9. Rinse in running tapwater for 5 minutes
10. Stain in Van Gieson for 7 minutes
11. Rinse in tapwater very quickly
12. Dehydrate very quickly in 70% ethanol and two changes of absolute ethanol until slides clear
13. Clear in two changes of xylene
14. Coverslip and mount with DPX

Alcian Blue & Periodic Acid Schiff (AB/PAS)

1. Dewax to water (a) Immerse in two changes of xylene, 5 minutes each
    (b) Rinse in absolute ethanol until slides clear
    (c) Rinse in 70% ethanol until slides clear
    (d) Rinse in tapwater
2. Stain in 0.3% Alcian Blue in 3% acetic acid for 15 minutes
3. Rinse in tapwater
4. Oxidise in 1% periodic acid for 10 minutes
5. Rinse in running tapwater for 5 minutes
6. Rinse in three changes of distilled water
7. Stain with Schiffs reagent for 15 minutes (on staining rods)
8. Rinse in running tapwater for 10 minutes
9. Stain in Mayer's Haemalum for 5 minutes
10. Rinse in tapwater
11. Blue in Scott's tapwater for 2 minutes
12. Rinse in tapwater
13. Dehydrate in 70% ethanol and two changes of absolute ethanol until slides clear
14. Clear in two changes of xylene
15. Coverslip and mount with DPX

Appendix 6

Measurements of New Zealand fur seals

Study animal	Standard body length (cm)	Axillary girth (cm)	Pectoral flipper length (cm)	Pelvic flipper length (cm)	Body weight (kg)	Stomach weight (g)	Cardiac orifice diameter (cm)	Stomach length (cm)	Proper gastric region width (cm)	Number of proper gastric rugae
Af. 1	96.0	48.0	32.0	22.5	11.0	-	-	-	-	10
Af. 2	127.5	58.5	40.5	31.0	23.5	-	-	-	-	-
Af. 3	93.0	42.0	25.9	20.1	9.0	-	-	-	7.5	9-10
Af. 4	78.0	40.5	27.2	19.7	7.5	11.5	2.0	15.0	6.0	10
Af. 5	80.0	43.0	26.0	21.5	7.5	15.1	2.5	12.0	6.0	9-10
Af. 6	70.5	41.0	25.0	19.5	7.0	16.6	1.5	12.5	4.5	10
Af. 7	97.0	46.0	31.0	22.0	11.5	35.0	2.0	17.5	7.0	9-10
Af. 8	77.0	42.0	25.0	20.0	7.5	20.3	2.0	13.5	6.0	9-10
Af. 9	164.0	92.5	49.0	36.0	55.6	113.0	6.0	30.0	16.0	9-10
Af. 10	93.0	52.5	28.5	21.0	10.3	-	2.0	13.5	4.5	-

Study animal	Proper gastric wall thickness (mm)	Pyloric antrum width (cm)	Pyloric canal length (cm)	Pyloric canal width		Pyloric canal height (cm)	Pyloric wall thickness (mm)	Pyloric orifice diameter (mm)
				proximal (cm)	distal (cm)			
Af. 1	-	-	-	-	-	-	-	-
Af. 2	-	-	-	-	-	-	-	-
Af. 3	3.4	-	-	-	-	-	2.2	-
Af. 4	-	-	-	7.5	3.0	7.0	3.4	5.0
Af. 5	3.6	-	-	6.0	3.0	7.0	2.9	5.0
Af. 6	6.6	-	8.0	5.0	2.5	6.0	4.1	7.0
Af. 7	-	4.5	5.5	7.0	3.0	10.0	-	1.5
Af. 8	-	-	5.5	6.5	2.5	8.0	-	1.0
Af. 9	-	7.0	10.5	-	5.5	-	-	1.5
Af. 10	-	3.0	7.0	-	3.0	-	-	5.0

Appendix 7

Measurements of long finned pilot whales

Study	Standard	Axillary	Pectoral	Tail fluke	Body	Stomach	Fc orifice	Fc		Fc rugae		Fc wall	P-g orifice	P-g chamber	
animal	body L	girth	flipper L	L	W	W	D	L	W	number	depth	T	D	L	W
	(cm)	(cm)	(cm)	(cm)	(kg)	(g)	(cm)	(cm)	(cm)		(mm)	(mm)	(mm)	(cm)	(cm)
Gm. 1	168	88.5	39	27	-	-	-	-	-	-	-	-	-	-	-
Gm. 2	185	77.5	38	17	54	570	3	10	6.3	-	-	-	5.5	8	11.5
Gm. 3	168	92	37	-	-	300	3	12.5	7.5	9	3	5	5.5	8.5	9
Gm. 4	233	-	42	-	-	1400	7.5	27.5	10	9	1.5	9	7.5	14	15.5
Gm. 5	290	166	49	-	-	2766	-	33.5	21	-	-	8	10	16.5	17
Gm. 6	310	172	59	-	-	4669	5	31	20.5	-	-	-	10	16.5	17
Gm. 7						-	-	-	-	-	-	-	-	-	-

Study	P-g chamber rugae		P-g chamber	Cr-Py	Dst between P-g	Cr-Py portion L			Septum	Cr-Py portion D			Cr-Py portion
animal	number	depth	wall T	orifice D	& Cr-Py orifices	proximal	dilation	distal	L	proximal	dilation	distal	wall T
		(mm)	(mm)	(mm)	(cm)	(cm)	(cm)	(cm)	(cm)	(cm)	(cm)	(cm)	(mm)
Gm. 1	-	-	-	-	-	-	-	-	-	-	-	-	-
Gm. 2	-	-	-	-	-	-	-	-	-	-	-	-	-
Gm. 3	9	2	3	7	1.2	4.5	-	4.5	3	1.5	2	2	2
Gm. 4	9	3	4	15	2	5.5	7.5	5.5	5.5	2.8	4	4	3
Gm. 5	9	2.5-4.0	6	1.5	1.5	5.5	5.5	5.5	5.5	3.5	4.5	5	3
Gm. 6	-	-	-	1	3	-	-	-	-	3.5	4.5	3	-
Gm. 7	-	-	-	-	-	-	-	-	-	-	-	-	-

Notes: L = length, W = width, D = diameter, T = thickness, Dst = distance, V = volume, Fc = forechamber, P-g = proper-gastric, Py = pyloric, Cr-Py = cranial pyloric, Cu-Py = caudal pyloric

Appendix 7 cont.

Measurements of long finned pilot whales

Study animal	Cu-Py orifice D (mm)	Cu-Py bulb L (cm)	Cu-Py bulb W (cm)	Cu-Py chamber L (cm)	Cu-Py chamber W proximal (cm)	Cu-Py chamber W distal (cm)	Py chamber rugae number	Cu-Py portion wall T (mm)	Py orifice D (mm)	Fc V (ml)	P-g chamber V (ml)	Py chamber V (ml)	Total stomach V (ml)
Gm. 1	-	-	-	-	-	-	-	-	-	-	-	-	-
Gm. 2	-	-	-	13.5	4	4.5	-	-	-	150	300	95	545
Gm. 3	5	2.5	2.5	11	4	3	0	2	3	150	200	60	410
Gm. 4	1	4	4.5	21.5	5.5	6	0	3	10	1000	550	310	1860
Gm. 5	15	5	6	22.5	5.5	3.5	-	3	8	-	-	-	-
Gm. 6	-	-	-	-	-	-	-	-	-	-	-	-	-
Gm. 7	-	-	-	-	-	-	-	-	-	-	-	-	-

Notes: L = length, W = width, D = diameter, T = thickness, Dst = distance, V = volume, Fc = forechamber, P-g = proper-gastric, Py = pyloric, Cr-Py = cranial pyloric, Cu-Py = caudal pyloric