STUDIES ON THE TESTICULAR DEVELOPMENT OF THE NEW ZEALAND ROMNEY RAM

A thesis presented in partial fulfilment of
the requirements for the degree of
Master of Veterinary Science
at Massey University

IAN JAMES STEFFERT

July, 1971

ABSTRACT

The growth of 33 N.Z. Romney rams was observed between birth and 269 days of age. The weight and histology of the testes of these lambs were studied and compared with the histological changes of the testes in 44 foetuses between the ages of 42 days and birth.

Testis growth changed sharply to a faster rate, from 70 days of age when the body weight exceeded 20 kilograms. This change in growth rate was associated with the commencement of spermatogenesis. The completion of the first cycle of spermatogenesis was dependent on the attainment of a testis size of 34 grams in a ram at least 22 weeks of age.

Changes in the epithelium and boundary tissue of the sex cords and seminiferous tubules were closely related to the different phases of testes' growth. The sex cords were present in the testis of the 42-day foetal lamb, but did not show a definite boundary tissue until 53 days of foetal life. Little variation in their development was apparent until the onset of spermatogenesis. The transition from sex cords to seminiferous tubules followed a greater rate of increase in tubular diameter. The gonocytes which were more centrally placed in the sex cords than the nuclei of the supporting cells, became transformed into prospermatogonia before their evolution to adult stem cells at the boundary tissue. Lumen formation in the seminiferous tubule was concomitant with the completion of Sertoli cell development and the appearance of the more advanced forms of germ cells.

At birth the boundary tissue consisted of a non-cellular layer, which had reached its widest margins, and an outer multi-cellular layer of fibroblast-like cells. Differentiation

of the four component tissues in the mature tubular wall, the inner non-cellular layer, the inner cellular layer, the outer non-cellular layer and the outer cellular layers, became apparent about the time spermatogenesis commenced, and appeared to be fully developed when the first cycle of spermatogenesis was completed. The inner non-cellular layer became thinner as the outer non-cellular layer became evident.

Throughout their developmental phases fibres of elastic tissue were dispersed evenly within the two non-cellular layers. During puberty increases to adult proportions were most rapid in the outer non-cellular layer. The significance of elastin in the boundary tissue of the seminiferous tubules in the ram could not be determined. The density of the elastin component as a measure to indicate the degree of immaturity of the testis of a ram was postulated.

ACKNOWLEDGEMENTS

I wish to thank many people, without whom this thesis could not have been completed. Firstly to my supervisors, Dr. A.N. Bruere, Reader, and Professor E.D. Fielden, Department of Veterinary Clinical Sciences, Massey University, to whom I am indebted for their continued interest and valued advice and encouragement given during this study. I appreciate the facilities they put at my disposal and the provision of sheep.

To the management of Longburn Freezing Works C.W.S. Limited I am grateful for the provision of foetal lambs.

My sincere thanks are extended to Professor R.E. Munford for his assistance with the statistical problems, Mrs. J. Lang and Mr. D.P.J. Ward for technical skill in the preparation of testis tissue for histological studies, Mr. D. Taylor for illustrations and assistance in the preparations of the figures, and Mr. J. Austin for his patience and skill in reproducing the many photographs which form an integral part of this thesis. To the library staff, other colleagues and staff members at Massey University, I am truly grateful for their advice and practical assistance.

Finally I wish to extend special thanks to Miss May Soo, Mrs. Joy Pearce, and my wife Diana, for the mammoth tasks of typing drafts and final copy with patience and understanding.

TABLE OF CONTENTS

APPENDICES

REFERENCES

LIST OF TABLES

LIST OF FIGURES

STUDIES ON THE TESTICULAR DEVELOPMENT OF THE NEW ZEALAND ROMNEY RAM

INTRODUCTION

The normal cellular and tissue development of testes from early foetal life through to maturity has been determined for a number of breeds of sheep. The purpose of this study is to follow the pattern of testicular development in rams of the New Zealand Romney breed.

Sexual Development in the Ram

In the male puberty is regarded as having been reached when spermatogenesis is complete, the sexual organs have developed sufficiently to allow reproduction to be possible and the animal shows characteristic male behaviour (Hammond and Marshall, 1952; Abdel-Raouf, 1960; Donovan and van der Werff ten Bosch, 1965; Skinner *et al.*, 1968; Skinner and Rowson, 1968; Foote, 1969). It is a phase of animal development in which growth of the reproductive tract is most marked.

Ram lambs develop signs of adult male behaviour long before reaching physiological sexual maturity. Initially these may be seen when rams a few days old mount other lambs and even adult ewes. As puberty occurs there is a progressive expression of this incipient sexual behavioural pattern. The signs of nudging, aggressive bunting, flehmen and nosing of the perineal area, partial erection of the penis, mounting and pelvic oscillations make up the display of courtship. These signs are frequently devoted to other males, particularly if such a group is held together as one flock (Banks, 1964).

Evidence of the androgenic activity of the testis is indicated by the presence of fructose and citric acid in the secretions of the accessory sex glands and marks the onset of puberty in the ram. This phase includes the commencement and the period of completion of the initial cycle of spermatogenesis and ends about the time that spermatozoa are found in the seminal fluid (Skinner *et al.*, 1968; Skinner and Rowson, 1968). Sexual maturity has not been reached at this stage as the testis continues to develop to its full reproductive capacity (Courot, 1962).

The completion of sexual development has been assessed in the ram by observing the nature of the seminal ejaculates over the pubescent period. The first appearance of spermatozoa in the ejaculate has been reported for several breeds and some cross-breds (see Table I). In general spermatozoa are observed in the semen of the British breeds of sheep at an earlier age than that of other breeds and are present after the earlier signs of libido occur (Banks, 1964).

An assessment of the post-natal development of the ram's testis can be made from the appearance of the different cell types in the developing seminiferous epithelium. There is a gradual layering of the cellular components (spermatogonia, primary spermatocytes, spermatids and spermatozoa) which assume positions characteristic of the pattern in the adult seminiferous tubules.

TABLE I: AGE AND LIVE WEIGHT OF LAMBS OF DIFFERENT BREEDS AT THE TIME OF APPEARANCE OF SPERMATOZOA IN THE EJACULATE

Breed	No. of Rams	Age (days) Mean ± S.E.	Range	Weight (kg) Mean ± S.E.	Range	Reference
Merino	10	200	185-213	28.6	24.5-33.2	Dun (1955)
German Merino	3	250	-	35.9	-	Symington (1961)
Persian	4	224	-	21.8	-	Symington (1961)
Rhodesian indigenous	3	169	-	20.9	-	Symington (1961)
Dorper	20	128±2.3	112-145	27.3±0.78	-	Louw & Joubert (1964)
Welsh Mountain Suffolk						
Spring birth	6	117±6.0	103-131	29.9±0.58	27.3-32.7	Skinner & Rowson (1968)
Summer birth	6	138±6.9	122-168	20.3±0.95	17.3-23.6	Skinner & Rowson (1968)
Suffolk	18	126±2.2	115-146	36.8±1.40	29.5-50.0	Skinner & Rowson (1968)
Merino						
H.P. nutrition	13	191.4±7.1	-	28.4±1.1	-	Pretorius & Marincowitz (1968)
H.P. nutrition	13	191.6±4.8	-	28.6±1.1	-	Pretorius & Marincowitz (1968)
L.P. nutrition	13	219.7±7.7	-	24.5±0.5	-	Pretorius & Marincowitz (1968)

These progressive phases of development have been related to the age and body weight of the lamb, the size of the testis, and the growth of the seminiferous tubules (Phillips and Andrews, 1936; Carmon and Green, 1952; Watson et al., 1956; Courot, 1961, 1962; Sapsford, 1962a; Skinner et al., 1968). Studies on the growth and development of the Leydig cells in the interstitial tissue of the testis (Baillie, 1960; Sapsford, 1962a), the epididymis (Carmon and Green, 1952; Watson et al., 1956), and the accessory glands of the reproductive tract (Aitken, 1959) have been recorded in the ram and the growth of these tissues has been related in turn to the androgenic activity of the testis (Skinner et al., 1968).

The growth of the penis and the extent of prepucial adhesions is dependent on the age and weight of the ram and can be an indicator of the onset of puberty (Johnstone, 1948; Wiggins and Terrill, 1953; Dun, 1956; Watson et al., 1956; Belonje, 1965; Pretorius and Marincowitz, 1968; Skinner and Rowson, 1968).

The Gross Anatomy of the Ram Testis

The ram testis is enclosed within a fibrous capsule, the tunica albuginea, containing a number of elastic fibres. This tissue thickens along the posterior border of the testis, and extends deep into the gland to form a mass of fibrous tissue, the mediastinum. Trabeculae of fibrous tissue radiate from the mediastinum dividing the testis into a number of indistinct lobules which are composed of many tortuous seminiferous tubules (see Figs. 1, 2 and 3). The seminiferous tubules unite to form straight tubules in which spermatogenesis usually does not take place, and ultimately form a

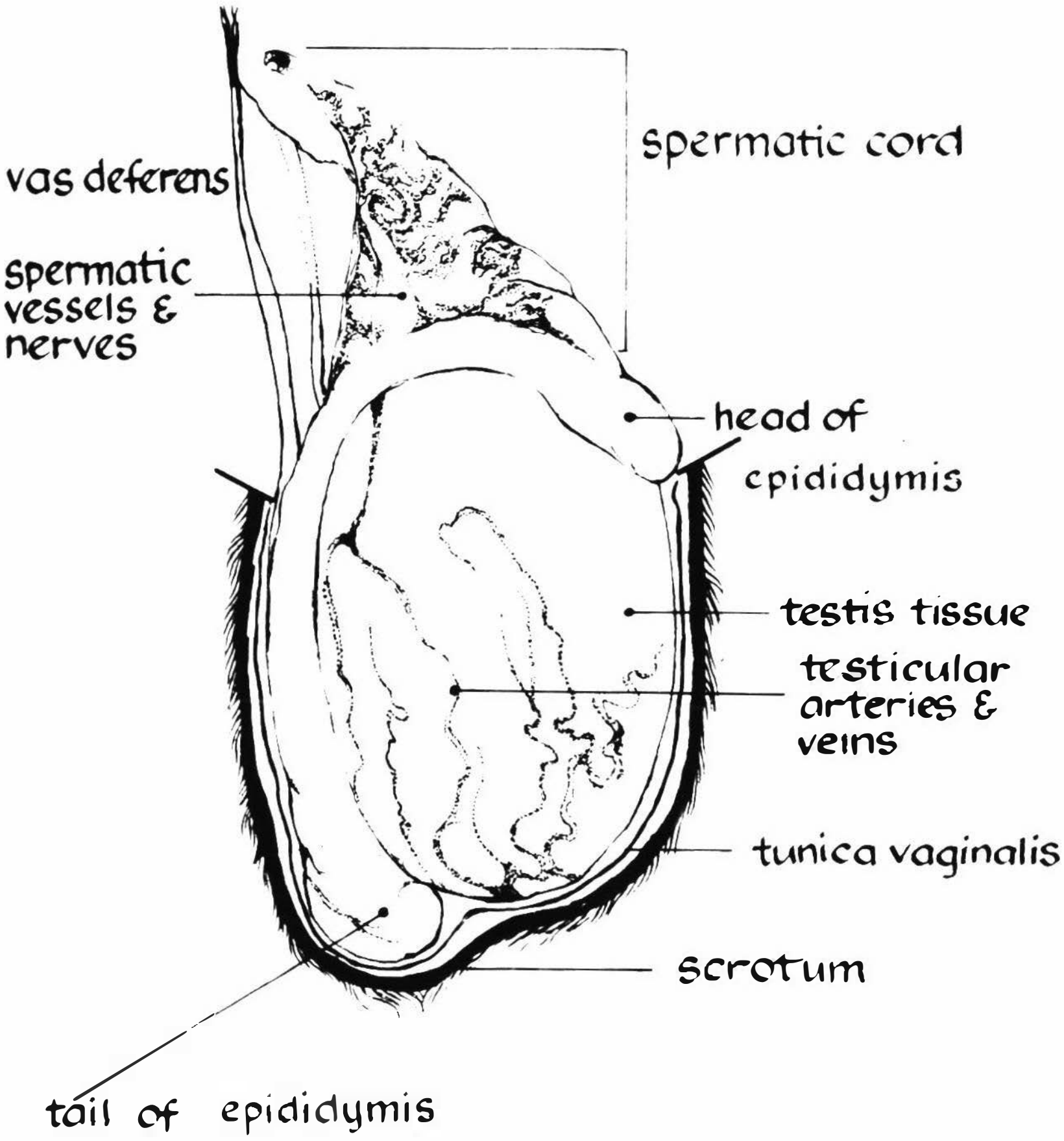

FIGURE 1 : LATERAL VIEW OF TESTIS

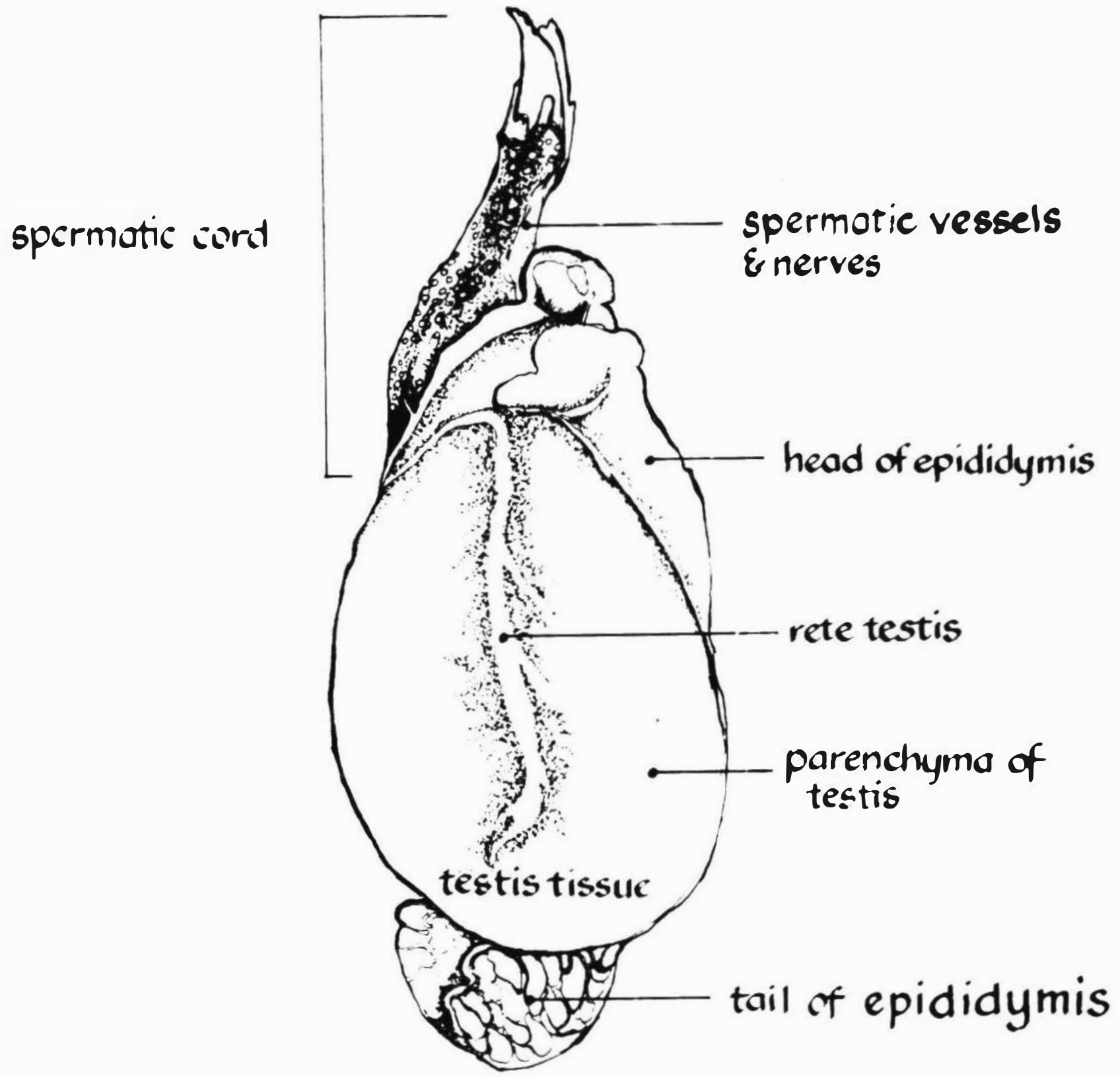

FIGURE 2: LONGITUDINAL SECTION OF TESTIS

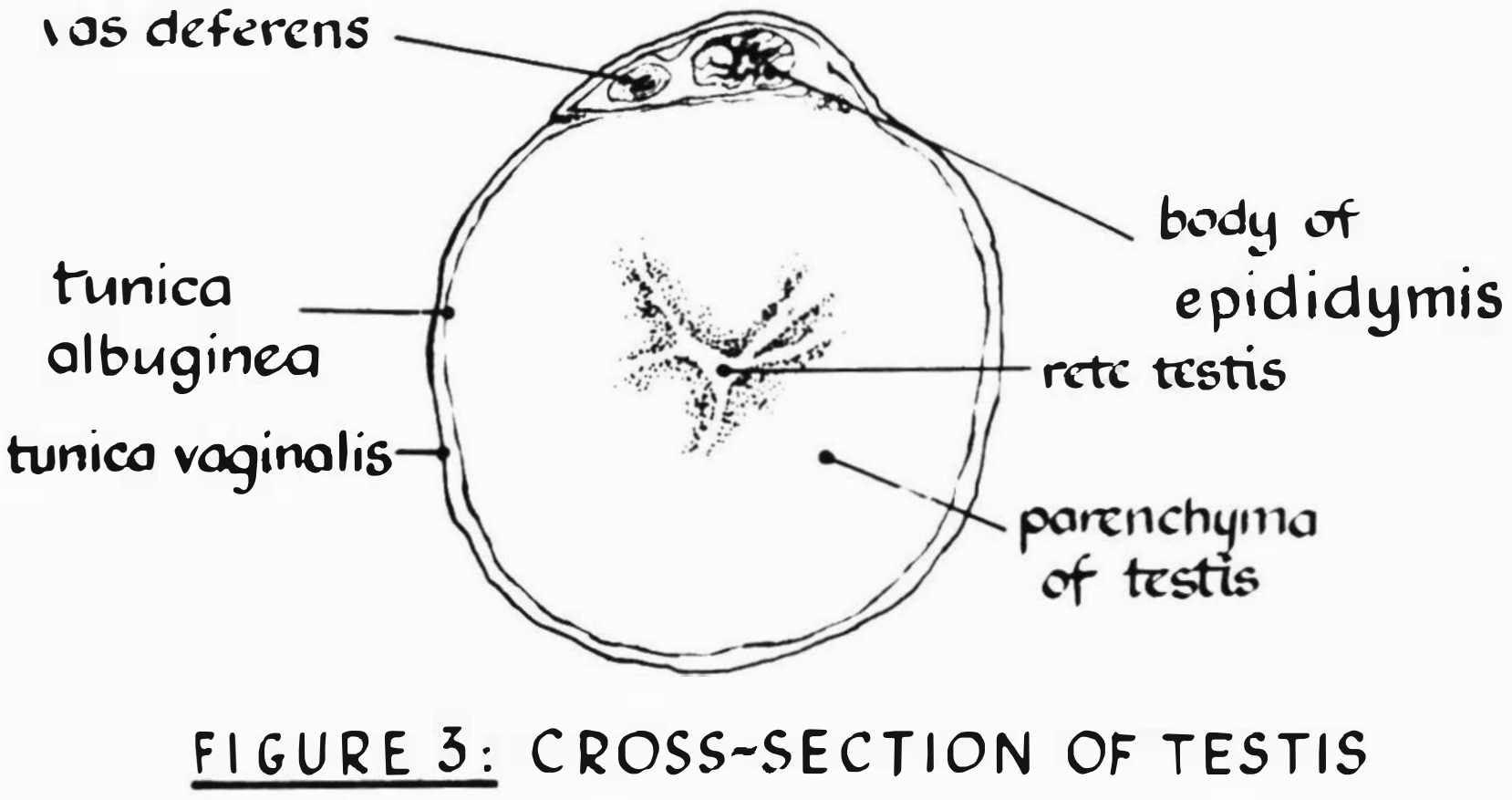

FIGURE 3: CROSS-SECTION OF TESTIS

network of non-seminiferous tubules in the mediastinum, the rete testis. The efferent ducts pierce the tunica albuginea and combine to form the head of the epididymis (caput epididymis) (Sisson and Grossman, 1956; Bishop and Walton, 1960; May, 1963).

The seminiferous tubules of the adult ram testis are composed of sperm cells at progressive stages of development and Sertoli cells (Clermont and Leblond, 1955; Ortavant, 1959; Sapsford, 1962a) enclosed within a multilayered tubular wall known as the boundary tissue. The latter tissue provides a blood-testis barrier which regulates the passage of nutrients, the composition of fluid (Lacy, 1967; Waites and Setchell, 1969) and the maintenance of pressure to facilitate the transportation of spermatozoa to the rete testis (Leeson and Leeson, 1963; Ross, 1967). The interstitial tissue consists of the blood vessels and lymphatic ducts within the testicular parenchyma, and the interstitial or Leydig cells which are arranged singly or in groups dispersed throughout the intertubular connective tissue.

GENERAL MATERIALS AND METHODS

The Animals

a. Postnatal Animals

The lambs used in this study were New Zealand Romney crossbred sheep from an experimental flock kept for surgical studies at Massey University. They were obtained over a six week lambing period from September to mid-October in the two seasons of 1968 and 1969. A total of thirty-three rams were reared. Twenty-one were reared over the 1968/1969 season to the age of 269 days and twelve were reared over the 1969/1970 season to the age of 70 days. The lambs were either singles or twins, and were born either naturally or by caesarian section performed at full term of pregnancy.

In addition specimens were obtained from a two-tooth Romney ram aged 300 days, and a mature Romney ram aged six years. These rams were from the same parent flock as the lambs.

b. Foetal Animals

A total of forty-four male foetuses from Romney crossbred ewes were obtained from a local abattoir during the months of June and July, 1970. Their estimated ages ranged from 42 days to near birth. The estimation of age was based on the crown-rump measurements and the foetal weights given by Galpin (1935), Stephenson (1959), and Stephenson and Lambourne (1960).

Management of Animals

The animals were grazed from September to the following June on improved pasture at Massey University. They were tailed at two to four weeks of age, weaned at about fourteen weeks of age and shorn at twenty to twenty-four weeks of age. All lambs were vaccinated with an alum-precipitated pulpy kidney, blackleg and malignant oedema vaccine at four to six weeks of age. Throughout the 1968/1969 season, the lambs were weighed at approximately two weekly intervals. The body weights were recorded at the time of their castration, after which they were removed from the flock.

Selection of Animals for Castration

The aim was to obtain and study the testes of lambs at two weekly intervals, commencing at the time of birth. Generally the time of castration depended on the birth dates of the lambs and the availability of sufficient numbers for the convenient processing of the tissues.

Treatment of Testes

a. Postnatal lambs

The testes from the very young rams were collected by removal of the distal portion of the scrotum incising each tunica vaginalis to expose the testis and epididymis and then severing the spermatic cord. In the older lambs the testes and epididymides were exposed through two longitudinal incisions of the scrotum and tunica vaginalis following the subcutaneous infiltration of a local anaesthetic solution (2% w/v solution lignocaine hydrochloride*). The testes and epididymides were removed by severing each spermatic cord.

Within thirty minutes of castration the epididymis and the spermatic cord were removed by trimming close to the testis. Each testis was weighed to the nearest 100 mg. The smaller testes were incised transversely about the mid-section of the testis and each half portion was placed in the fixative fluid. The larger testes (greater than 2.5 G in weight) were incised similarly and pieces of testicular tissue 4 mm in thickness were taken from this surface and placed in the fixative fluid.

b. Foetal Lambs

The testes were removed from the foetuses and trimmed of excess tissue before placing in the fixative fluid. There was a delay of up to four hours between the slaughtering of the pregnant ewe and the removal and fixing of the testicular tissue.

c. Fixatives Used

Initially six different fixative solutions were used: Bouin's fluid, Carnoy's fluid, Davidson's solution, 10% formalin, Zenker's fluid and a mercuric chloride solution (see Appendix V). Best definition of the morphology of the testis was obtained in tissues fixed in Bouin's fluid. The shrinkage of tissues in Bouin's fluid was minimal resulting in less distortion of the microscopic features. Testicular tissue fixed in Carnoy's fluid gave the best overall results with the elastin stains used to differentiate elastic tissue within the walls of the seminiferous tubules.

* Xylocaine 2% (Astra)

d. Tissue Preparation

The sections of testis tissue were washed and dehydrated by processing through increasing concentrations of ethyl alcohol, cleared and embedded in paraffin. Microscope sections were cut at five microns and ten microns, mounted and stained with haematoxylin and eosin (see Appendix IV). Similarly prepared sections from tissue fixed in Carnoy's fluid were cut at five microns, mounted and stained separately with Weigert's elastin stain, modified fuchsin stain and Gomori's aldehyde stain for elastic tissue (see Appendices I, II and III). The testis tissue stained with Weigert's elastin stain consistently gave the best definition and staining of elastic tissue.

e. Examination of Tissue

Sections from each testis from each animal were examined at x 160, x 320, x 500, and x 1125 magnifications on an Ortholux* microscope. Photomicrographs, using an Orthomat* microscope camera and a Leica* camera with a micro-attachment, were taken of suitable tubules so that stages and differences in their development could be assessed. Assessments were based on a visual appraisal of the types, morphology and sizes of the germ cells, the supporting cell components, and the boundary tissues of the tubules in each animal.

---

* Leitz Wetzlar, Germany

THE POSTNATAL GROWTH OF THE TESTIS IN RAMS

Review of Literature

The first few months of the ram's life are characterised by rapid increases in the body's growth rate. Skinner et al. (1968) recorded maximum rates of body weight gains in Suffolk lambs up to seventy days from birth, followed by less rapid gains as the lambs matured. Initially growth rate of the testis was slow in relation to body weight gains. The weight of the testis increased gradually from birth to forty-two days when a sharp change to a more rapid rate of growth occurred. In the young Merino ram the maximum growth rate of the testis was recorded when the body weight increased beyond 21 kg (Watson et al., 1956), whilst in the Ile-de-France breed a definite increase in the testicular growth rate occurred when the testis weight exceeded 6 G at approximately eighty days after birth (Courot, 1961, 1962, 1967). The established pattern therefore is that the maximum growth rate of the testes takes place when body weight changes are decreasing and corresponds to the establishment of spermatogenesis (Courot, 1962; Skinner et al., 1968). A similar pattern of testis development has been noted in young bulls (Abdel-Raouf, 1960; Attal and Courot, 1963).

A closer relationship exists between testicular size and body weight than testicular weight and the age of the ram (Dun, 1955; Watson et al., 1956; Courot, 1962). Similarly the completion of spermatogenesis, indicated histologically by the appearance of spermatozoa within the testis, is more closely related to the physiological age than to the chronological age (Carmon and Green, 1952; Watson *et al.*, 1956; Courot, 1962; Skinner *et al.*, 1968). Growth of the testis does not cease at this stage however, but continues until the adult size is reached. The testis of the mature ram is approximately three-fold the weight of the testis when spermatozoa first appear. In the Ile-de-France breed with an adult testis size of 200 G spermatozoa are present in the 65 G testis (Courot, 1962) and in the Suffolk breed with an adult testis size of about 300 G, spermatozoa are present in the 100 G testis (Skinner *et al.*, 1968).

In some studies the development of the testis has been determined by the appearance of spermatozoa in the seminal ejaculate of the ram, and similarly there was a closer relationship between testicular weight and the body weight than with age (Dun, 1955; Symington, 1961; Louw and Joubert, 1964; Pretorius and Marincowitz, 1968; Skinner and Rowson, 1963).

Changes in the size of the testis can be determined by palpation. Dun (1955) assessed testicular growth by this method and considered Merino rams with firm plump testes four inches to five inches in length and a penis free from prepucial adhesions as having completed puberal development. The use of orchidometry has been suggested as a refinement to the present subjective measurement techniques (Bruere, 1970). In human medicine a technique using calipers to measure the longitudinal and the transverse axes of the testes has been described (Hansen and With, 1952). Podany and Sstwiertna (1969) adapted this technique to measure the size of testes in rams. It is common practice in human infertility clinics to use a comparative palpation technique by employing a set of standard models (Prader, 1966). Bruere (1970) suggested that a similar set of standard models be established for rams, and the testes for individuals be compared and recorded in a simple grading system. Another method of measuring testicular function has been described by Hahn et al. (1969) for use in bulls. It is an instrument called the tonometer and measures testis consistency as a means of providing a prediction for semen quality. The advantages of these measuring techniques over subjective manual palpation is that they provide a standard for testicular size which possibly could be related more closely to semen production.

Methods Used

a. Postnatal Growth of the Ram

The body weights of all rams in the 1968/1969 season were measured at two weekly intervals. Beginning at birth the weights were classified into groups within ten day periods and the mean body weight and standard error of the mean for each group was estimated. The body weight and age for each ram was recorded at the time of castration.

b. Postnatal Testicular Growth

Lambs for castration were not selected at random, but every endeavour was made to obtain samples of testes for each two weekly period during the postnatal phases of development. The sum of the weights of the left and right testes was used in all analyses referring to the growth of the testis, these combined testis weights for each lamb being referred to as testes weight.

c. Statistical Treatment of the Data

The testes weight (G) was plotted against the age of the lamb (days) and its body weight (kg) at the time of castration. Similarly the testes weight was plotted against the logarithm of the body weight, to emphasise the change in growth rate of the testes in relation to the body weight increases (Courot, 1962; Skinner et al., 1968). Increases in the weight of the testes were also studied by determining the weight of the testes as a percentage of the total body weight. These figures were plotted against age.

The growth rates of the testes relative to the increases in the body weight were shown by plotting the logarithm of the testes weights against the logarithm of the body weights (Brody, 1945; Watson et al., 1956).

Change points in the linear rate of testes growth relative to body weight were obtained and the data were divided at these points and analysed in separate classes. Correlation and regression coefficients were obtained for the two classes of testes weight and age, and the corresponding two classes of testes weight and body weight and the significance of their values tested by determining their "t"-distribution (Snedecor, 1956). The difference between the regressions of testes weight on age and testes weight on body weight for each of the two ranges of testes weights were obtained by comparing regression and correlation coefficients, and the F-values in analyses of covariance (Snedecor, 1956). Similarly the two relative rates of testes growth determined from the logarithmic data were compared by treating them separately within each class of body weight (Brody, 1945; Snedecor, 1956). Data from similar studies of rams of other breeds have been treated in a like manner, and at least two different rates of testes growth have been determined (Watson et al., 1956; Courot, 1962; Skinner et al., 1968).

Results

a. Postnatal Growth of the Ram

The growth of the lambs is shown in Figure 4 from data presented in Table II and Appendix VI. The rate of increase in body weight at the time of castration was higher in the lambs under 84 days of age, than in the period after 99 days. The differences in the growth rates of the lambs resulted in wide variations in their body weights at any particular age. The mean growth curve for all lambs in the 1968/1969 season showed a steady rate of growth for the first 120 days following birth. Thereafter the number of contributors to the mean of each age group was small which meant that the standard error of the means could not be given.

b. Postnatal Testicular Growth

The body weights and ages at castration listed in order of ascending testicular weights have been recorded for each ram (Table II). Changes in the weight of testes with age are shown in Figure 5. There was a slight increase from birth to 49 days of age followed by a greater increase between 50 days and 84 days. Beyond this age testes growth was rapid and became more variable in the older lambs. Similarly the general increase in the weight of the testes in relation to the body weight of the ram is shown in Figure 6. The weight of the testes increased slowly until a body weight of 20 kg was reached and thereafter the testes increased in weight at a relatively more rapid rate than did the body weight. The increase in the weight of the testes as a percentage of the body weight was plotted against age and shown in Figure 7. The relative size of the testes remained static from birth to 40 days followed by an increasingly rapid change until 99 days, after which the relative increase in testes size was slower (see also Table II). The testes weight continued to increase along with the growth of the lamb until 269 days of age, when collection of data ceased.

Testes weights showed at least two rates of growth. The initial rate was slow and linear until about 70 days of age. A greater but still linear rate of testes growth followed after 99 days. A closer relationship existed between the testes weight and the body weight of the ram than between the testes weight and age (see Table III). One class of data for testes weights was taken for lambs from birth to 70 days of age, and another for lambs of 84 days of age and older. Further evidence for the relationship was shown by the fact that the regressions of the testes weight on body weight fitted the data better than the regressions of the testes weight on age (see Table III). The constants of the regression lines fitted to the data of the two classes of testes weight were

$$T\,W\,(G) = b\,B\,W\,(kg) + a$$

and $$T\,W\,(G) = b\,Age\,(days) + a$$

(T W = testes weight; B W = body weight)

There was a difference between the two regressions at the 1% level of significance for both classes of data (see Tables IV & V).

As the body weight increased there was a relative increase in the weight of the testes (Figure 8). A linear relationship existed between the two parameters from birth to 70 days of age, and a similar relationship existed between 99 days and 269 days of age. No difference was shown to be present between the regression coefficients of these two lines determined by the equation:

$$\log T\,W\,(G) = b \log B\,W\,(kg) + \log a$$

(T W = testes weight; B W = body weight)

(see Tables VI and VII). A significance difference at the 1% level between the intercepts of the regressions with the testes weight base line indicated that the two regressions were independent and different (Table VIII). Limited data between the ages of 70 days and 99 days prevented closer examination of this period. Logarithmic data presented suggest that a much greater rate of testes growth occurred between these two ages, hence the data for 84 days of age were not included in the regression analyses.

TABLE II: THE RELATIONSHIP OF THE TESTES WEIGHT WITH BODY WEIGHT AND AGE OF ROMNEY RAMS

Ram No.	Testes Wt (G)	Body Wt (kg)	TW/BW %	Age (days)
5	-	2.72	-	1
70	1.5	4.08	0.0367	3
59	1.6	5.66	0.0282	22
68	1.8	5.66	0.0318	17
63	1.9	6.11	0.0311	33
18	2.1	7.70	0.0277	61
69	2.9	7.25	0.0400	10
22	-	8.60	-	16
62	4.3	11.55	0.0372	28
67	5.7	10.88	0.0524	24
72	5.8	12.69	0.0457	40
73	7.7	12.23	0.0629	46
25	-	15.40	-	30
71	12.8	16.30	0.0785	49
2	-	18.60	-	45
21	15.4	19.90	0.0774	60
64	17.8	14.95	0.1190	69
15	21.1	19.00	0.1110	70
66	27.8	21.75	0.1278	60
4	49.8	20.4	0.2438	84
20	112.7	20.8	0.5418	136
9	126.5	26.3	0.4809	154
7	129.2	24.9	0.5188	99
3	131.3	30.8	0.4263	126
17	140.0	26.3	0.5323	269
23	161.6	28.6	0.5650	112
16	174	29.0	0.6000	236
11	178.5	28.6	0.6241	165
1	195	34.0	0.5735	178
10	196	28.1	0.6975	223
8	224.5	36.3	0.6184	252
12	305	31.3	0.9744	196
24	351	37.6	0.9335	210

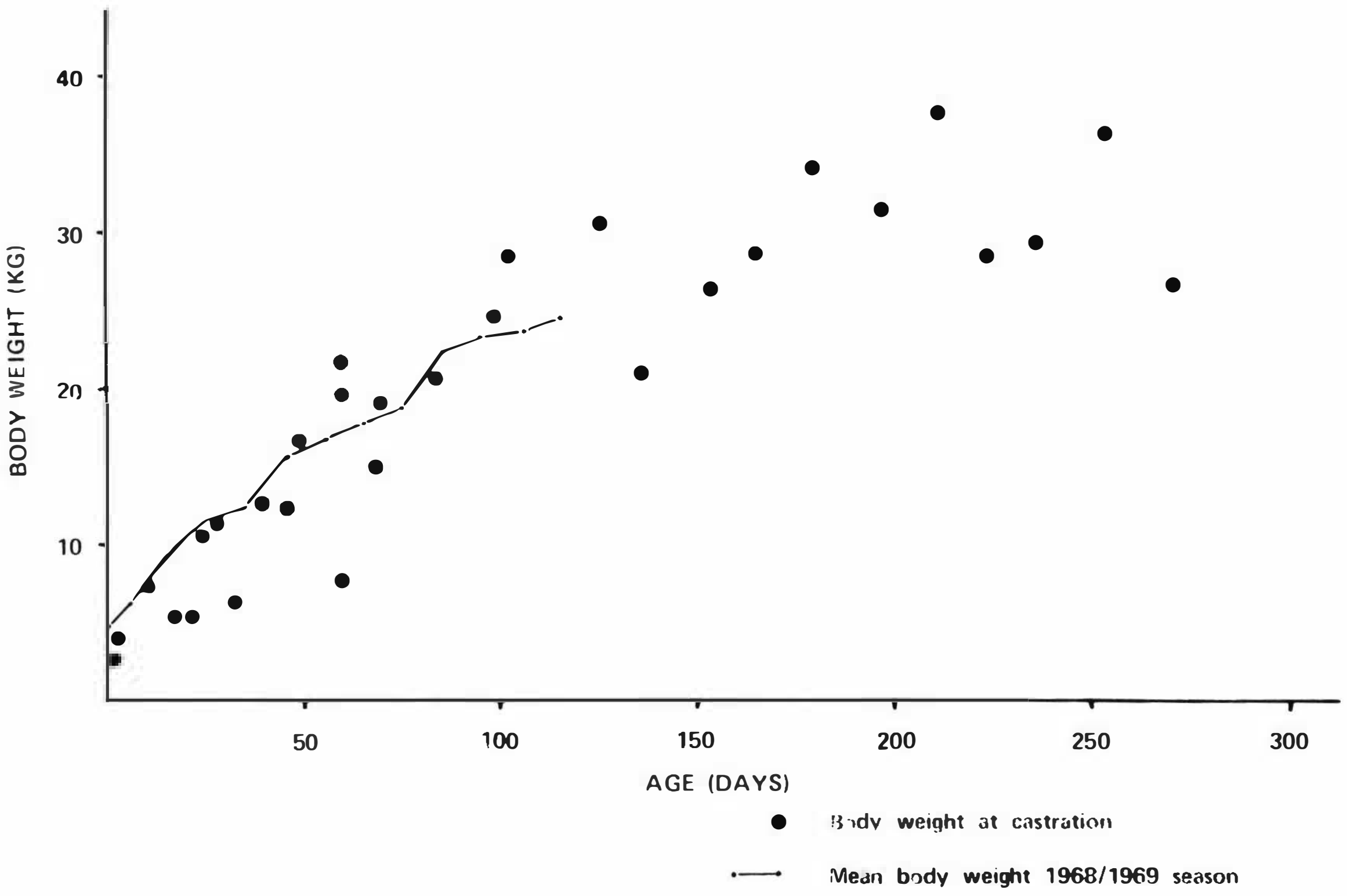

FIGURE 4: BODY WEIGHT OF RAMS AT CASTRATION COMPARED WITH THE MEAN GROWTH RATE

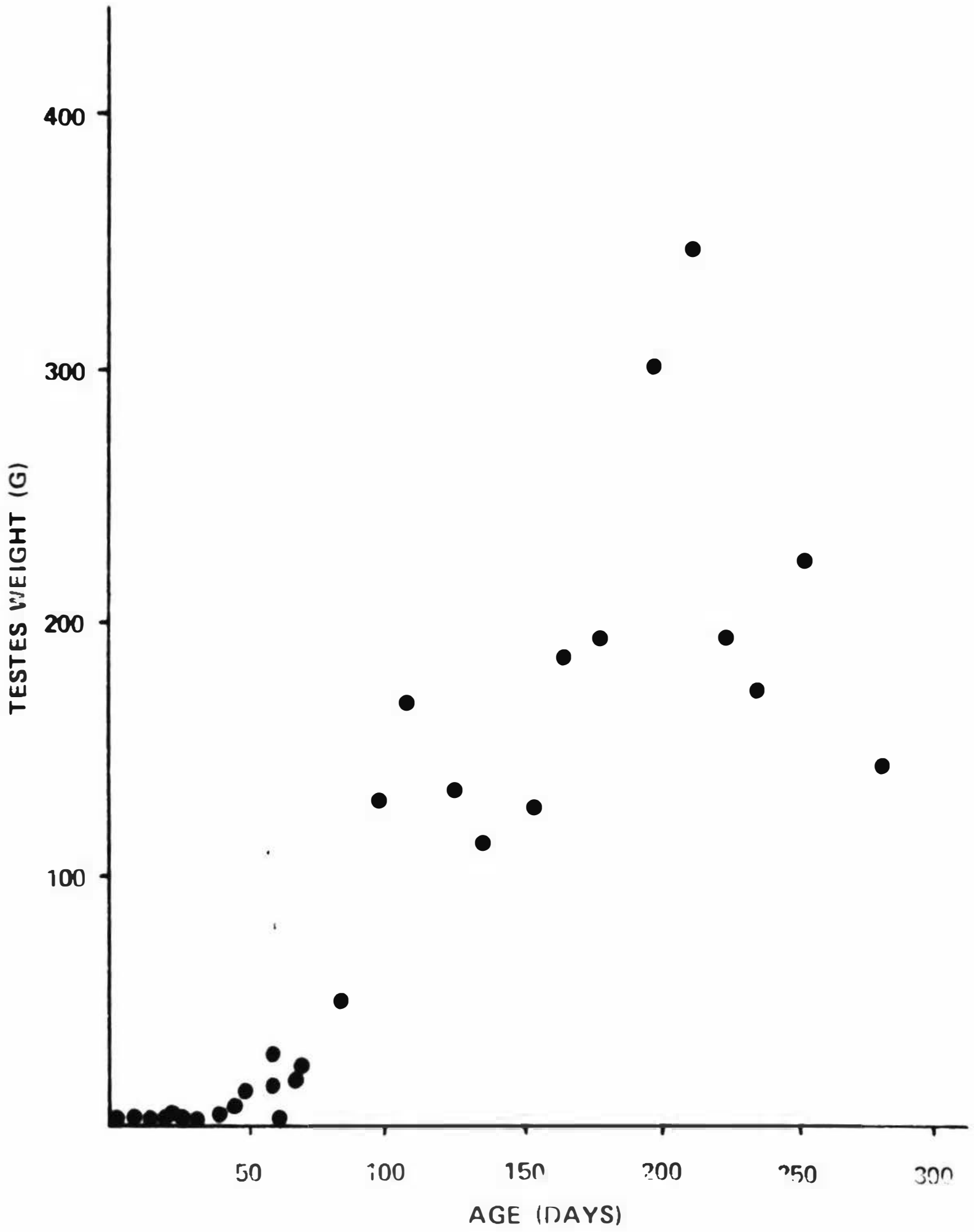

FIGURE 5: RELATION OF TESTES WEIGHT TO AGE OF RAM AT TIME OF CASTRATION

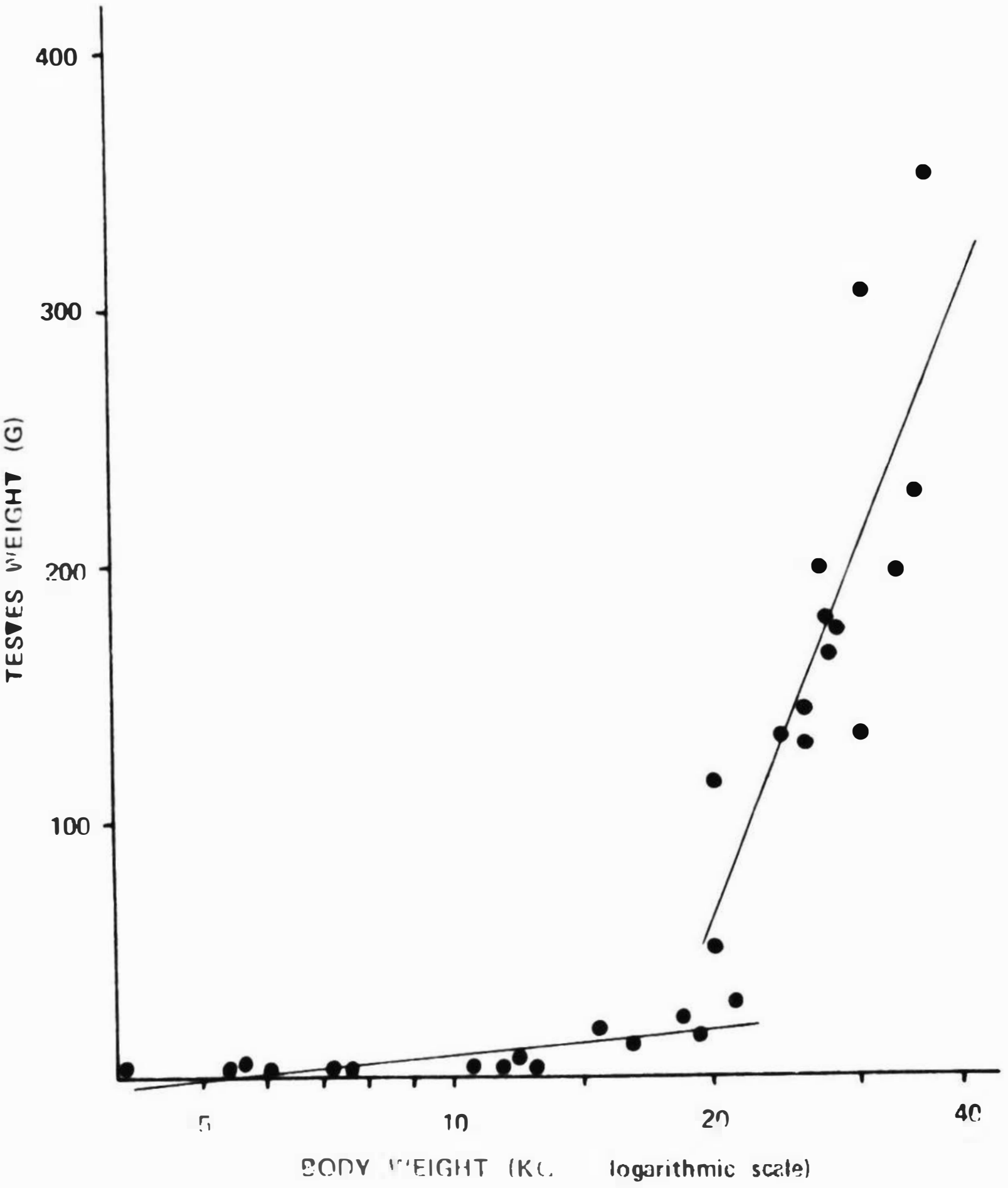

FIGURE 6: RELATION OF TESTES WEIGHT TO BODY WEIGHT OF RAM AT TIME OF CASTRATION

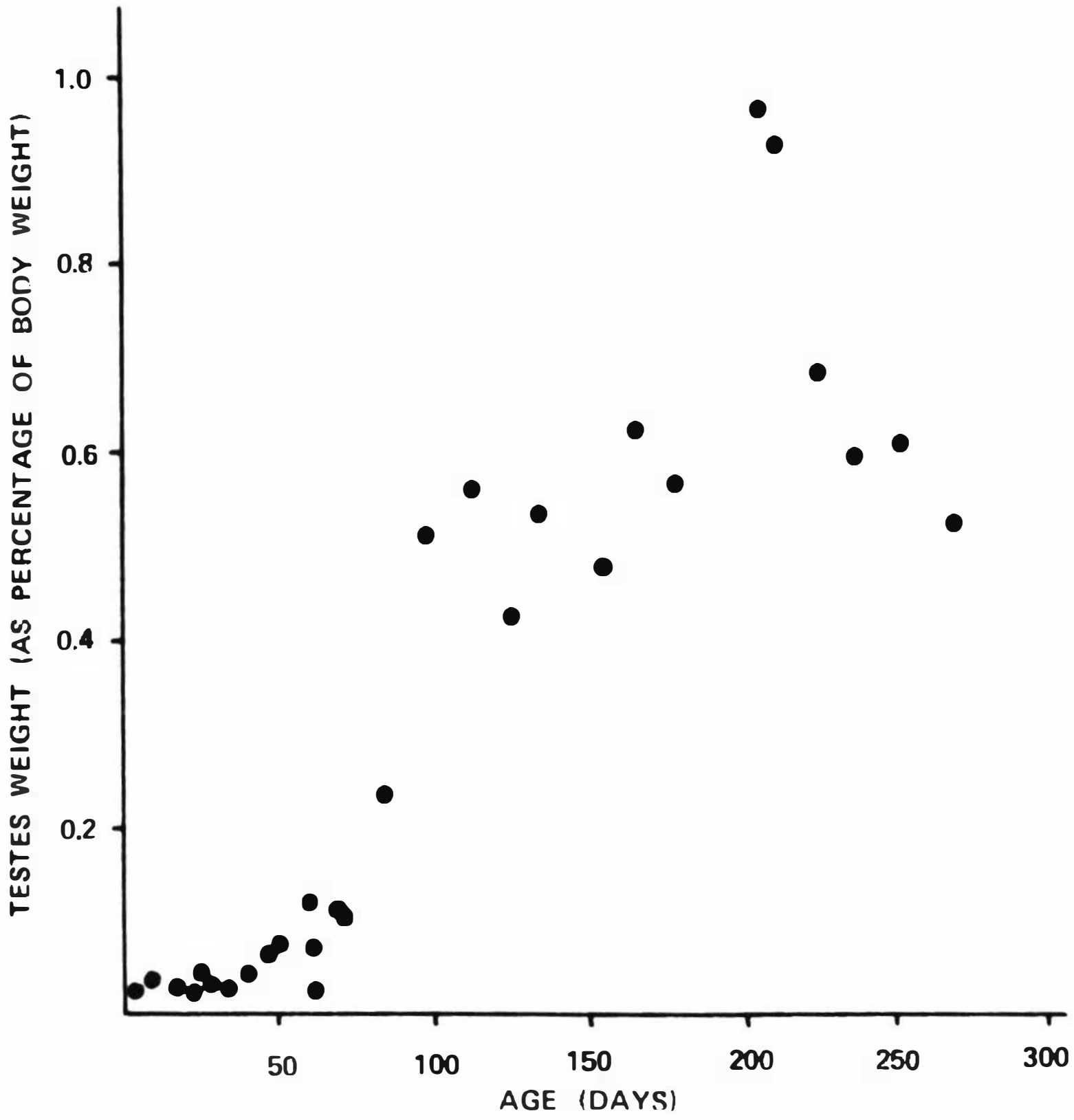

FIGURE 7: RELATION OF TESTES WEIGHT IN PROPORTION TO BODY WEIGHT WITH CHANGES IN AGE OF RAM AT TIME OF CASTRATION

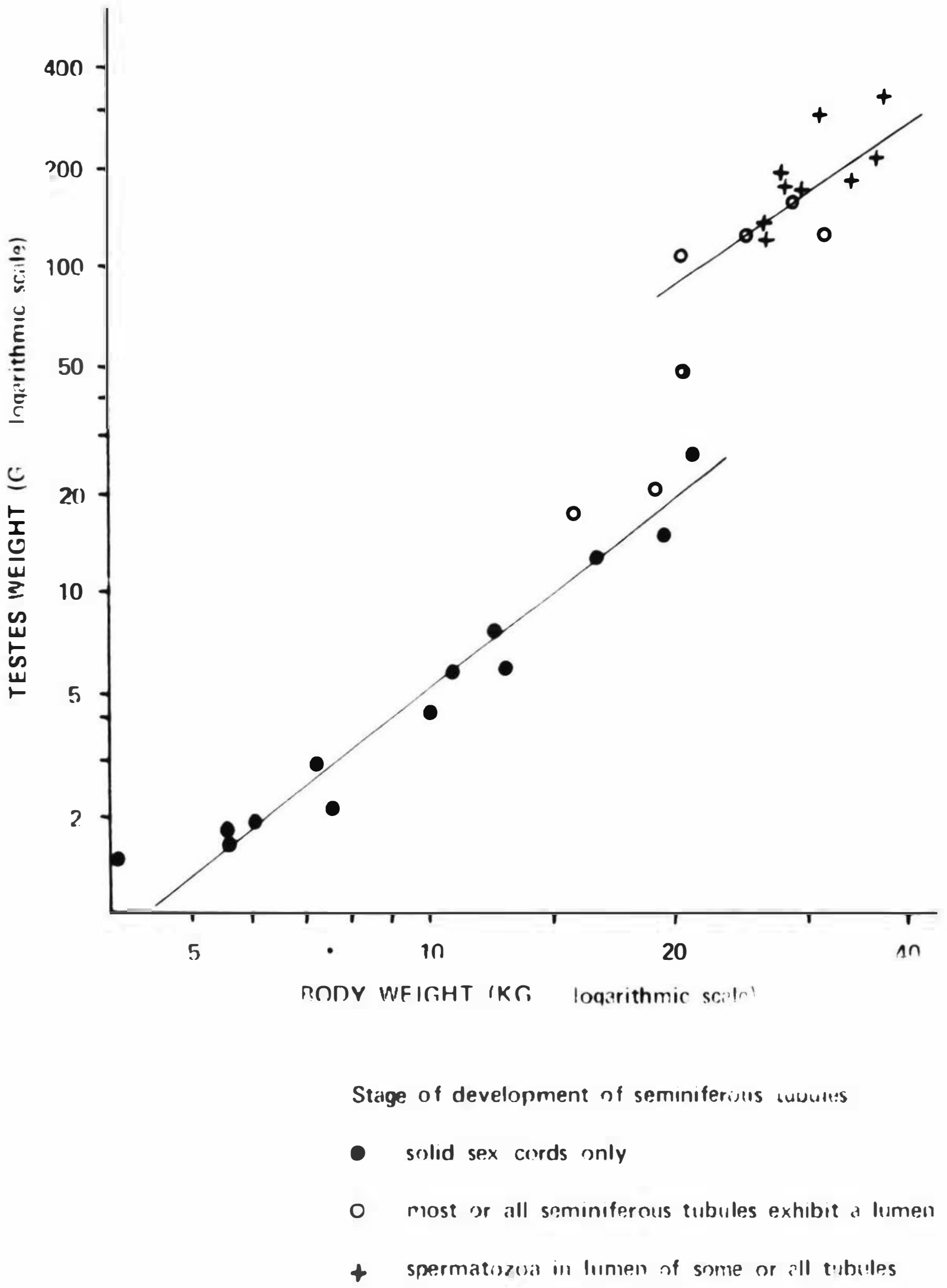

FIGURE 8: TESTES WEIGHT (LOGARITHMIC SCALE) RELATIVE TO BODY WEIGHT (LOGARITHMIC SCALE) OF RAM AT TIME OF CASTRATION

TABLE III: CORRELATIONS AND REGRESSIONS ON THE BODY WEIGHT AND ON THE AGE (X) OF THE TESTES WEIGHT (Y) OF THE ROMNEY RAM

Relationship	Age Class (days)	n	r	Equation	S.E. of b	Distribution of t	d.f.
Testes' weight (G)	< 71	15	+0.926**	$Y = 1.36X - 7.22$	0.15	8.836**	13
and Body weight (kg)	> 83	14	+0.828**	$Y = 12.54X - 184.18$	2.55	4.927**	12
Testes' weight (G)	< 71	15	+0.753**	$Y = 0.29X - 2.68$	0.07	4.131**	13
and Age (days)	> 83	14	+0.534*	$Y = 0.71X + 53.95$	0.32	2.190*	12

Levels of significance ** $p < 0.01$ * $p < 0.05$

TABLE IV: SUMMARY OF ANALYSIS OF VARIANCE DETERMINING THE DIFFERENCES OF THE REGRESSIONS OF TESTES WEIGHT (Y) ON BODY WEIGHT AND AGE (X) IN ROMNEY RAMS BETWEEN BIRTH AND 70 DAYS

Source of Variation	Sum of Squares	Degrees of Freedom	Mean Square	Value of F	Result
Differences between Regressions of Testes Wt. on Body Wt. and Testes Wt. on Age	484.95	1	484.95	22.51	$P < .01$
Error	560.15	26	21.54		
Deviation from average Regression	1045.10	27			

TABLE V: SUMMARY OF ANALYSIS OF VARIANCE DETERMINING THE DIFFERENCES OF THE REGRESSIONS OF TESTES WEIGHT (Y) ON BODY WEIGHT AND AGE (X) IN ROMNEY RAMS BETWEEN 84 AND 296 DAYS

Source of Variation	Sum of Squares	Degrees of Freedom	Mean Square	Value of F	Result
Differences between Regressions of Testes Wt. on Body Wt. and Testes Wt. on Age	46406.79	1	46406.79	13.57	$P < .01$
Error	82050.77	24	3418.82		
Deviation from average Regression	128457.56	25			

TABLE VI: CORRELATIONS AND REGRESSIONS ON THE LOGARITHM OF THE BODY WEIGHT (X) OF THE LOGARITHM OF THE TESTES' WEIGHT (Y) IN THE ROMNEY RAM

Age Class (days)	n	r	Equation	S.E. of b	Distribution of t	d.f.
< 77	15	+0.964**	$Y = 1.88 X - 1.17$	0.14	12.98**	13
> 99	13	+0.794**	$Y = 1.70 X - 0.25$	0.39	4.33**	11

Levels of significance ** $p < 0.01$

TABLE VII: ANALYSIS OF COVARIANCE DETERMINING THE DIFFERENCES OF THE REGRESSIONS OF THE LOGARITHM OF THE TESTES WEIGHT (Y) ON THE LOGARITHM OF THE BODY WEIGHT (X) IN THE ROMNEY RAMS BETWEEN BIRTH AND 70 DAYS OF AGE, AND 99 - 269 DAYS OF AGE

Source of Variation	Sum of Squares	Degrees of Freedom	Mean Square	Value of F	Result
Difference between Regressions of 0-70 days and 99-269 days	0.0016	1	0.0016	0.1296[a]	NS
Error	0.2964	24	0.0124		
Deviation from average Regression	0.2980	25	0.0119		
Deviation from adjusted means	1.1410	1	1.1410	95.8824[b]	**
Total	1.4390	26			

Levels of Significance NS = non-significance ** $P < 0.01$

[a] $F = 0.0016/0.0124$ [b] $F = 1.1410/0.0119$

Discussion

Wide variation in body weights for any one age group did exist. This would probably result from different feed conditions which prevailed over the two seasons affecting the nutrition of the ewes, milk production and the nutrition of the lambs after weaning. Surgery had some effect on the mothering ability of those ewes resulting in relatively slower growth of the lambs during the first few days of life.

The results obtained from Romney crossbred lambs indicated that a closer relationship existed between testis development and changes in body weight than between testis weight at castration and increasing age. Body weight is a reflection of transient under or over-nutrition as well as age and is therefore a better independent characteristic to which testis weight changes can be related. This finding is consistent with observations on rams of other breeds (Carmon and Green. 1952; Watson et al., 1956; Courot, 1962) and the male animals of other species (Green and Winters, 1944; Hauser et al., 1952; Bratton et al., 1959; Abdel-Raouf, 1960; Attal and Courot, 1963; Macmillan and Hafs, 1969).

When the growth of the testis was compared with changes in body weight, relatively faster changes in testicular size were evident after 40 days. The increasing rate continued steadily but data were not available after 269 days to determine if a plateau associated with maturity would have been reached at some later stage. The growth curves of the testes measured against age and changes in body weight were sigmoid in shape but specific testis growth rates could be transformed to linear relationships from logarithmic data. Initially the specific growth rate of the testis when compared with that of the body weight was low, but altered abruptly to a higher value after 70 days of age.

In these observations increases in the testes weight were rapid in the next 30 days but insufficient sheep numbers prevented a closer study of the testes weight changes within this short period. However Watson *et al.*, (1956) showed that in Merino rams the most rapid growth of the testes occurred between 23 and 27 kg body weight. This can be compared with the results of Courot (1962) who demonstrated a definite change of testicular growth rate in the Ile-de-France breed after the testis had attained 6 G. A similar change was reported by Skinner *et al.* (1968) whose Suffolk rams showed a steep rise in testicular growth rates after 42 days of age. In Merino rams Watson *et al.* (1956) were able to show that when the body weight had reached 27 kg there was a markedly decreased growth rate of the testis relative to body growth. Distinctive break-points in the growth curve of the testis have been shown in other species (Abdel-Raouf, 1960; Attal and Courot, 1963; Spencer, 1968). Spencer (1968) related these changes to the time of puberty, but could not explain the increase in relative growth in man and the elephant, and the decrease in the rat. More data at the extreme ranges of the body weights and about the transitional period in these species probably would have accentuated the three distinctive phases of relative growth demonstrated in the ram by Watson *et al.* (1956). For the same reasons the second point of change to a relatively slower testicular growth rate could not be determined in both the Romney sheep of this study and the Ile-de-France sheep of Courot (1962).

In this investigation the breakpoint where the testes weights increased at a more rapid rate relative to the body weight changes occurred between 70 and 84 days of age. The analysis of the data for each of the two phases of growth was completed for the two parameters, testes weight and body weight, which were independently grouped according to increasing age. In no case has a previous author indicated how the particular point of change of growth rate was determined. One can surmise that the rams of Watson <u>et al</u>. (1956) were grouped according to body weights i.e. less than 23 kg between 23 and 27 kg and greater than 27 kg. In Courot's (1962) study the rams were grouped according to the testis weights, whether they were smaller or larger than 6 G. Grouping of data for analysis about this transitional point in this way could have resulted in a bias towards either body weight or testis weight.

The relationship between body growth and testes growth is similar for all breeds of sheep. However some breed differences exist in the weights of the testes from rams of the same body weights and the same ages (see Tables VIII and IX). Differences were more variable when related to age.

It would appear therefore that maturity of the testis in the ram is a function of the testis weight, which is a reflection of the body weight and the age of particular breed of sheep. If testis weight only was the criteria for determination of maturity then all breeds of rams complete puberty at a similar age. On the other hand if it was a function of body weight only, one would expect the testis weight of the Romney and the Southdown to be heavier than those of the other breeds when puberty is reached. Yao and

TABLE VIII: SUMMARY OF RANGE OF TESTIS WEIGHTS FOR EACH BREED AT PARTICULAR BODY WEIGHTS

Body Weight (Kilograms)	Testis Weight (grams)					
	Hampshire +	Southdown +	Merino *	Ile-de-France +	Suffolk *	Romney +
0 - 5	-	-	1.0 - 2.5	0.8	1.0	0.75
5 - 10	0.1	-	1.0 - 2.5	0.8 - 1.6	1.0 - 3.0	0.8 - 1.5
10 - 15	3.3 - 3.4	3.6 - 11.4	1.3 - 3.0	1.4 - 3.1	3.0 - 6.0	2.1 - 8.9
15 - 20	4.2 - 11.1	26.8 - 31.0	2.5 - 6.0	3.3 - 5.5	6.0 - 10.0	6.4 - 10.6
20 - 25	20.5 - 20.7	14.8 - 67.4	5.0 - 58.0	4.2 - 13.6	10.0 - 22.0	13.9 - 64.6
25 - 30	28.9	57.2	16.0 - 64.0	8.2 - 66.1	14.0 - 65.0	63.8 - 98.0
30 - 35	61.9 - 96.9	-	20.0 - 160.0	11.9 - 165.5	42.0 - 100.0	65.7 - 153.0
35 - 40	-	-	75.0 - 130.0	53.0 - 152.5	102.0 - 155.0	112.0 - 175.5
40 - 45	104.4 - 121.7	-	70.0 - 275.0	66.5 - 172.5	100.0 - 136.0	-
Reference	Carmon & Green (1952)	Carmon & Green (1952)	Watson et al. (1956)	Courot (1962)	Skinner et al. (1968)	Present study

+ from experimental data

* estimated from data plotted on graph

TABLE IX: SUMMARY OF RANGE OF TESTIS WEIGHT FOR EACH BREED AT PARTICULAR AGES

Age (days)	Testis Weight (grams)					
	Hampshire +	Southdown +	Merino *	Ile-de-France +	Suffolk *	Romney +
0 - 25	0.1	-	-	0.7 - 2.0	1.5 - 2.5	0.7 - 2.8
25 - 50	3.3 - 3.4	-	-	1.0 - 5.5	2.5 - 8.0	0.9 - 6.4
50 - 75	4.2 - 11.1	3.6 - 11.4	-	2.7 - 5.5	13.0 - 23.0	7.7 - 13.9
75 - 100	20.7 - 28.9	5.5 - 31.0	6.0 - 55.0	4.8 - 59.3	23.0 - 100.0	25.9 - 64.6
100 - 125	61.9	26.8 - 57.2	12.0 - 105.0	8.2 - 98.0	80.0	80.8
125 - 150	20.5	38.0 - 67.4	50.0 - 160.0	13.6 - 116.0	105.0 - 130.0	56.3 - 65.6
150 - 175	96.9 - 121.7	-	6.0 - 120.0	36.3 - 172.5	133.0 - 170.0	63.2 - 84.2
175 - 200	104.4	-	-	-	-	97.5 - 152.5
200 - 225	-		10.0 - 130.0	-	-	98.0 - 175.0
Reference	Carmon & Green (1952)	Carmon & Green (1952)	Watson et al. (1956)	Courot (1962)	Skinner et al. (1968)	Present study

\+ from experimental data

* estimated from data plotted in graph

Eaton (1954) showed that the testis weight of goats was closely related to birth weight only over the period of initial spermatogenesis. From birth until the appearance of spermatozoa in the testes, the testicular weight was closely related to the body weight and both factors remained independent of the birth weight until the rate of testicular growth increased. Unfortunately during this restricted and relatively short period of development there was a change from maximum to slower body growth rates, at the same time as the transition to maximum growth rates of the testes, and exact change points in the separate growth curves could be difficult to determine. One would expect however that the effects of nutrition and growth over an extended period would eventually eliminate the influence of different birth weights on later body and testis weights. If a multiple relationship for testis growth in lambs is to be considered, then the birth weight would probably be an additional influencing factor until puberty.

THE CYTOLOGICAL DEVELOPMENT OF THE SEMINIFEROUS TUBULES IN THE RAM

Review of Literature

In the newborn male mammal the sex cords which develop into seminiferous tubules, are composed of two types of cells, the gonocytes (primordial germ cells) and the supporting cells (indifferent cells). These cells and the cellular changes taking place over the puberal period in the young ram have been described by a number of investigators and include observations on the morphological and general development of the testicular tissues (Watson *et al.*, 1956; Sapsford, 1962a; Skinner *et al.*, 1968; Skinner and Rowson, 1968) as well as quantitative analyses of the cellular changes (Phillips and Andrews, 1936; Carmon and Green, 1952; Courot, 1961 1962; Sapsford, 1964).

Similarly testicular development has been described for other farm animals such as young bulls (Phillips and Andrews, 1936; Hooker, 1944; Fossland, 1954; Santamarina and Reece, 1957; Abdel-Raouf, 1960, 1961; Fossland and Schultze, 1961; Hay *et al.*, 1961; Attal and Courot, 1963; Macmillan and Hafs, 1969), goats (Yao and Eaton, 1954) and boars (Phillips and Andrews, 1936; Phillips and Zeller, 1943; Green and Winters, 1944; Hauser *et al.*, 1952; McFee and Eblen, 1967).

For a number of years the role of both the gonocytes and the supporting cells has been controversial (Everett, 1945). The early observations of Phillips and Andrews (1936) and Carmon and Green (1952) made no reference to gonocytes in the developing ram, but inferred that definitive spermatogonia arose from supporting cells.

By qualitative and measurement studies of the changes in the germ cell nuclei Sapsford (1962a, 1964) was able to distinguish the germ cells from the supporting cells and their derivatives, the Sertoli cells, at all stages of development. This continuity between the germ cells of the developing testis and the spermatogonia of the adult ram was similar to the observations of Courot (1962).

Uncertainty existed also over the development of the germinal elements of the calf and goat testes. Phillips and Andrews (1936), Hooker (1944), Yao and Eaton (1954), Santamarina and Reece (1957), and Fossland and Schultze (1961) claimed that gonocytes degenerated after birth and that the proliferating supporting cells developed into spermatogonia as well as Sertoli cells. More recent studies in developing bulls have substantiated the findings in the ram of both Sapsford and Courot (Abdel-Raouf, 1961; Nicander et al., 1961; Attal and Courot, 1963).

The morphology of the mammalian testis varies remarkably during the phases of development. At least four periods, each with their distinctive histological patterns, can be recognised (Sniffen, 1952; Sapsford, 1962a). They are the sexual differentiation of the gonad in the foetus, the remainder of foetal life and neo-natal period, the puberal period with the initiation of spermatogenesis, and the mature adult when the spermatozoa appear.

Differentiation of the indifferent gonad into testis is first apparent in the foetal ram after thirty-four days of development (Mauleon, 1961; Sapsford, 1962a) and by forty-two days the sex cords and aggregations of more differentiated epithelial cells can be recognised (Sapsford, 1962a). A complete description of the origins of the primordial germ cells and their development is not available for the ram (Sapsford, 1962a) but evidence from other animals would indicate that these cells migrate from the yolk sac to the genital ridge area, become incorporated in the coelomic epithelium and form a germinal epithelium (Gier and Marion, 1969). Eventually invaginations of the germinal epithelium into the mesenchyme tissue become separated from the surface epithelial cells by a developing tunica albuginea to form sex cords deeper in the testis tissue. The sex cords are surrounded by a basement membrane and a fine connective tissue sheath which creates a barrier between the cord and mesenchyme tissue. The primordial germ cells proliferate and differentiate as gonocytes, while the derivatives of the coelomic epithelial cells remain as supporting cells at the periphery of the cord (Everett, 1945; Brambell, 1956; Sapsford, 1962a; Gier and Marion, 1969).

At the time of sex differentiation the sex cords are relatively short bars orientated radially within the gonad. Throughout the remainder of the foetal period and the early postnatal life the cords grow slowly, increasing in diameter, and elongating until each end becomes attached to either the rete testis, or another cord within the same lobule (Gier and Marion, 1969). At birth the sex cords account for approximately 50% of the volume of the testicular tissue in the ram (Courot, 1962).

Within a cross section of a sex cord in the ram testis there are one or more large rounded gonocytes more centrally placed than the numerous supporting cells at the basement membrane. The cytoplasm of the gonocyte is visible about a lightly stained nucleus containing five or six chromatin masses surrounding the two or four nucleoli.

The gonocytes differentiate into mature gonocytes, characterised by a fine nuclear distribution of chromatin surrounding two or more nucleoli, and in turn develop into prospermatogonia containing single or double true nucleoli (Sapsford, 1962a, 1964). The cytoplasm of the supporting cells is less well defined and extends towards the centre of the cord, whilst their small highly stainable nuclei remain about the periphery. The supporting cells proliferate during this period and at the beginning of the puberal phase cease active division and gradually transform into Sertoli cells.

The most spectacular changes in the development of the seminiferous tubules are seen during puberty. At this stage there is movement of the germ cells to the periphery of sex cords and within a relatively short space of time they have changed to more actively dividing cells. The spermatogonial numbers increase as they become positioned on the basement membrane and as cell division increases numbers of primary and secondary spermatocytes, spermatids and spermatozoa make their appearance (see Fig. 9). Spermatogenesis takes place in a step by step manner and the succeeding cell types become orientated in layers towards the lumen of the tubule until finally spermatozoa are released.

Most changes in the gradual transformation of the supporting cells to Sertoli cells are observed after the establishment of the initial stages of spermatogenesis. They occur about the time of the meiotic divisions of the spermatocytes and appear to be complete when spermatids are first appearing (Courot, 1962; Skinner et al., 1968). Prior to or coincident with these changes, a number of small spaces appear in the cytoplasmic mass of the supporting cells. These

Figure 9: DIFFERENTIATION OF GERM CELLS AND SUSTENTACULAR CELLS IN THE DEVELOPING TESTIS

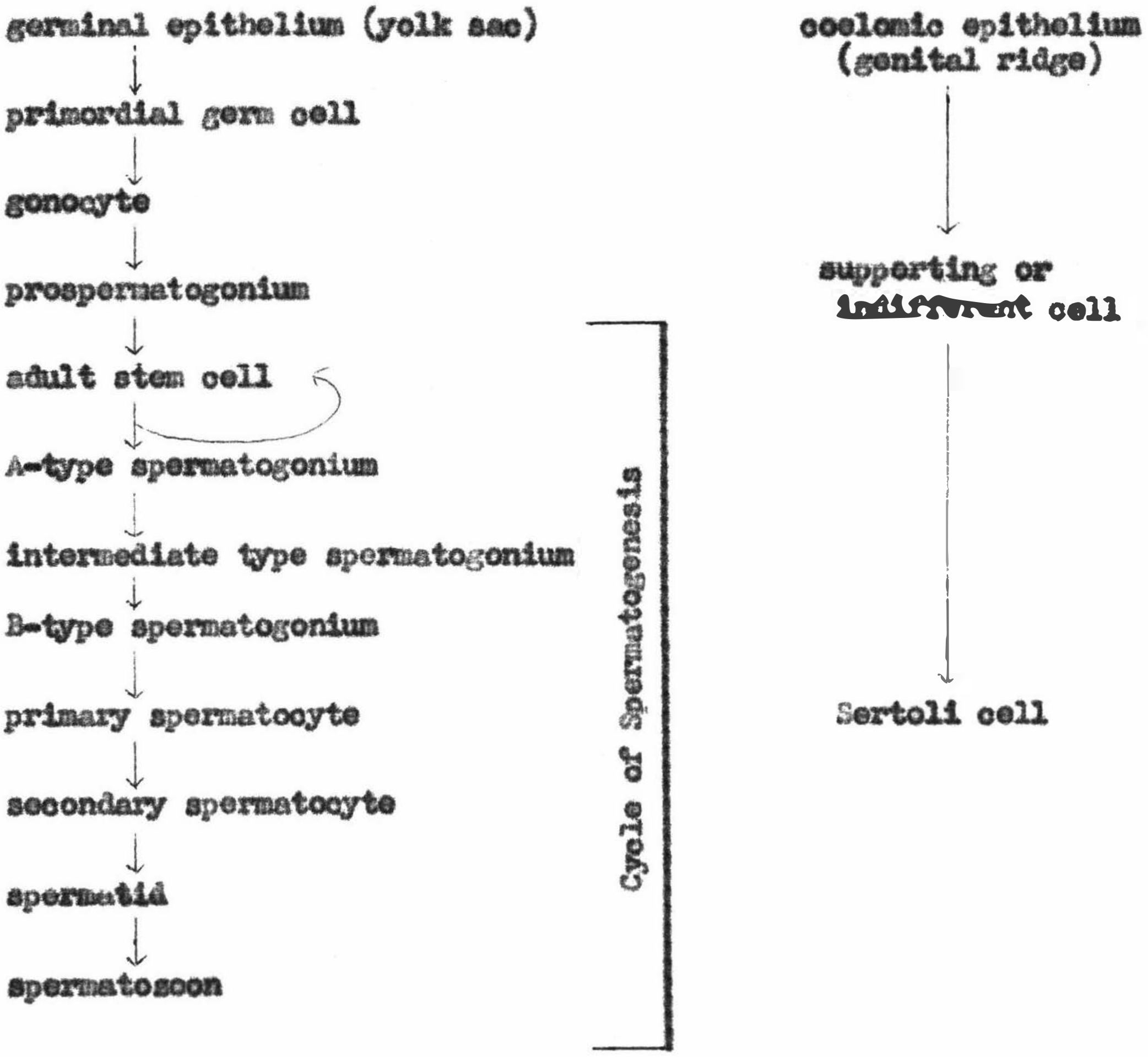

gradually coalesce and the sex cords acquire a central lumen to become tubules (Carmon and Green, 1952; Sapsford, 1962a).

The appearance of spermatozoa in the tubules marks the adult phase of testicular development. This is characterised by an increase in testis size mainly due to increases in the diameter and the length of the seminiferous tubules. The volume of the testicular tissue occupied by the tubular contents remains at about 80% (Courot, 1962). It is during this period that the quantitative output of spermatozoa increases to that of the mature adult ram.

There is some variation in the development of spermatogenesis between breeds and limited information would indicate that developments takes place earlier in the English breeds (Skinner et al., 1968). As a close relationship exists between the growth of the testis, coincident with the onset of spermatogenesis, and the body weight of the ram the breed differences may be a result of nutritional effects on the growth rate of sheep in their separate environments. However once spermatogenesis has commenced there is general agreement between authors on the time intervals between the appearance of the different cell types (Phillips and Andrews, 1936; Carmon and Green, 1952; Watson et al., 1956; Courot, 1962; Skinner et al., 1968).

In the ram's testis the interstitial cells or Leydig cells show signs of development soon after the sexual differentiation of the gonad (Baillie, 1960; Sapsford, 1962a). They differentiate from mesenchyme tissue and initially are difficult to distinguish from other cellular elements of the interstitial connective tissue. The nucleus, containing one or more nucleoli becomes rounded, and as the cytoplasm increases the cells are more clearly defined. About the mid-foetal period other forms of interstitial cells also appear including cells with varying numbers of eosinophilic granules present in the cytoplasm and cells with shrunken and pyknotic nuclei. In time most of these cells disappear but some persist and are still present in the developing and the adult testis (Sapsford, 1962a).

The interstitial cells occur as single cells or in clumps and become more widely scattered after birth. At puberty the diameters of the seminiferous tubules increase rapidly appearing to reduce the interstitial spaces and to decrease the size of the interstitial cells. Baillie (1960) found no evidence of a reduction in the number of interstitial cells in the ram before birth and Sapsford (1962a) was unable to determine whether, as in other animals, there was any obvious fluctuation in their numbers during development (Hooker, 1944; Roosen-Runge and Anderson, 1959; Baillie, 1961; Niemi and Ikonen, 1963; Clegg, 1966; Gier and Marion, 1969; Knorr _et al_., 1970).

Methods

In this study the recognition of cells in the developing sex cords and seminiferous tubules of the ram was based on the observations of Ortavant (1959), Courot (1962) and Sapsford (1962a). To facilitate comparisons with other studies the size of testis described in the following sections refer to the weight of one testis only.

The identification of the respective cells was as follows:

a. The Germ Cells and their Derivatives

Primordial Germ Cells

The primordial germ cell has well defined cytoplasmic boundaries about a spherical nucleus. Sapsford (1962a) restricts the use of the term to the germ cells at the stage of development before the formation of the sex cords.

Gonocytes

The term gonocyte was introduced by Clermont and Perey (1957) and used to name the primordial germ cells which are surrounded by the supporting cells in the sex cord (Sapsford, 1962a). They are large regularly shaped oval or round cells with a visible cytoplasmic zone defining their limits, and encircled by the dense processes of the supporting cells. The cytoplasm of the gonocytes in the prenatal testes contains large spherical inclusions which are replaced later by a greater number of coarse but well dispersed granules. The nuclei of these cells contain five or six chromatin masses of coarse granules irregular in both shape and size, and surrounding the true nucleoli. During the early post-natal phase of growth the nucleus of the gonocyte consists of two to four true nucleoli surrounded by a homogeneous distribution of fine dust-like chromatin (Courot, 1962; 1967). Sapsford (1962a) terms these cells mature gonocytes. They change into prospermatogonia before the establishment of spermatogenesis.

Prospermatogonia

Prospermatogonia are identified by the presence of a single or double nucleolus in a nucleus which is larger and more round than that of the adult stem cell or A-type spermatogonium. Within the sex cord these cells are centrally placed and their cytoplasms are not in contact with the basement membrane (Sapsford, 1962a).

Spermatogonia

The A-type spermatogonium is indistinguishable from the adult stem cell and is the starting point of the spermatogenic cycle. In the ram, new stem cells and the succeeding A-type spermatogonia arise from the first division of the stem cells (Ortavant, 1959; Ortavant *et al.*, 1969).

The A-type spermatogonium is a large oval cell and is somewhat flattened against the basement membrane of the seminiferous tubule. Its oval or round nucleus consists of very fine chromatin granules surrounding a single or occasionally double, large true nucleolus (Sapsford, 1962a; Ortavant *et al.*, 1969). Sapsford (1962a) describes further the nature of the extensive cytoplasm as containing numerous coarse and predominantly perinuclear inclusions. The Intermediate-type spermatogonium contains a nucleus with coarser chromatin. The B-type spermatogonium, which succeeds the Intermediate-type spermatogonium, contains a smaller round nucleus with a greater number of chromatin granules about the nuclear membrane (Ortavant *et al.*, 1969).

Spermatocytes

The primary spermatocytes are the products of the mitotic divisions of B-type spermatogonia. It is at this stage of spermatogenesis that the germ cells undergo meiosis. The nuclei of the young primary spermatocytes are difficult to distinguish from those of the B-type spermatogonia, but as progressive phases of meiosis takes place the nuclei assume characteristic and more easily distinguishable features. The chromatin crusts within the nuclear membrane become dispersed and give rise to thin chromatin filaments. There is contraction of the filaments and thickening of the chromosomes as they pair off and divide. In the older primary spermatocytes the chromosomes have contracted and are less easily distinguishable one from another (Ortavant, 1959; Ortavant et al., 1969).

The secondary spermatocytes are seen less frequently as this phase passes quite rapidly. They are recognised as germ cells with a smaller spherical nucleus containing five or six darker staining particles within a network of filaments. The spermatocytes in two or more stages of development occupy the positions of several rows of cells within the seminiferous tubule.

Spermatids

The spermatids are progressive stages of the germ cells following the second maturation division of the spermatocytes. The nuclei of the young spermatids are spherical and smaller but similar in appearance to those of the secondary spermatocytes. Initially the nuclei contain many large darker staining granules which gradually disintegrate to form a homogeneous mass as the nuclei elongate and flatten dorsoventrally. The cytoplasm of the spermatids is quite dense and contains the components which gradually develop into the acrosome, caudal sheath and the tail of the spermatozoa (Ortavant, 1959; Ortavant et al., 1969). The spermatids occupy a number of rows of germ cells at the centre of the seminiferous tubule, the older spermatids migrating towards the lumen where the immature spermatozoa are finally released.

b. The Supporting Cells and Derivatives

Supporting Cells

Supporting cells are also known as indifferent cells or sustentacular cells. Their cell boundaries are indistinct so that they are generally recognised by their characteristic nuclei. The nuclei are smaller than those of the germ cells and are visible in larger numbers in a single row, about the periphery of the sex cords. About the time of establishment of spermatogenesis two or more rows of supporting cells are present. In the foetal and early post-natal life of the ram, the round supporting cell nuclei contain granular chromatin which later tend to coalesce into even coarser chromatin surrounding the one or two nucleoli (Sapsford, 1962a). The cytoplasm of the supporting cells gradually increases in amount, with the lightly stained cytoplasmic processes becoming more pronounced and extending towards the centre of the sex cord.

Sertoli Cells

The Sertoli cells are a progressive and mature stage of the supporting cells. The triangular or irregularly shaped nuclei of the Sertoli cells have many deep indentations in their nuclear membranes that vary during the cycle of the seminiferous epithelium. They are found between the germ cells, near to but not necessarily on the basement membrane. A number of intranuclear coarse granules are scattered about the large single or double nucleolus. The cytoplasm of these cells surround all the germ cells in the tubule, with the exception of the spermatogonia, which remain in contact with the basement membrane (Courot, 1962; Sapsford, 1962a).

Observations

a. General Observations

The earliest sample studied in detail was the testicular tissue from a 42-day foetus. This would correspond to the commencement of the second phase of development as described by Sapsford (1962a) or the "gonocyte" phase of the impuberal testis of Courot (1962, 1967). For convenience the changes of the cellular elements of the sex cords and seminiferous tubules are described in two separate phases. The first or prepuberal phase followed the differentiation of the gonad when the sex cords showed some definition. This phase extended throughout later foetal life and early post-natal life, and was completed when the body weight of the ram was approximately 21 kg. The limits of this phase were defined by changes which occurred in the germ cells. The second, or puberal, or maturation phase of development (Courot, 1962) was associated with the commencement of spermatogenesis which took place as the body weight increased beyond 21 kg. Progressive changes and differentiation of the adult stem cells proceeded and finally spermatozoa were produced and released in the seminiferous tubules. During the period that followed the initial production of spermatozoa very few morphological changes were obvious, and all eight stages of the cycle of the seminiferous epithelium (Ortavant, 1959) were observed constantly.

Variations in the lines of demarcation between each of these phases could be considerable. The transition was arbitrary and could be indefinite between rams of similar ages and body weights, and even between or within the testis of the same ram.

b. Cell Changes in the Prepuberal Phase

General

The essential components of the developing sex cords were recognised in the 42-day old foetus (Fig. 10). Supporting cells and germ cells were seen as groups of cells aggregated in an irregular pattern and showing very little differentiation (Fig. 14). The characteristic nuclear pattern of the supporting cells arranged at the periphery of the sex cord and the one or more gonocytes in an eccentric position near the centre of the cord was obvious in the region adjacent to the developing tunica albuginea of the foetuses between the ages of 45 and 53 days (see examples in Figs. 11, 15 and 16).

Throughout the foetal and early post-natal life there was a small but steady increase in the diameters of the sex cords (Figs. 11, 12, 13, 16, 17 and 18). This was accelerated through the transitional period and into the next phase of development (Figs. 19, 20, 21, 22 and 23). At the time of early differentiation the sex cords were separated from each other by the interstitial tissue (Figs. 11 and 16). This state remained until the 45th day following birth, when the boundary of a number of sex cords were seen regularly in close contact with each other (Fig. 19).

The interstitial cells (Leydig cells) were recognised in the testicular tissue of the 42 day foetus (Fig. 14). Their appearance was as described by Baillie (1960) and Sapsford (1962a). The nuclei contained chromatin granules aggregating at the nuclear membranes about one or more nucleoli and were more rounded than the oval and spindle shaped nuclei of the other cells of the interstitial tissue (Fig. 16). The interstitial cells were evenly dispersed throughout the mesenchymal tissue during this early foetal period either as single cells or clumped together in groups of a few cells as seen later in foetal life (Figs. 17 and 28). After the birth of the lamb larger numbers of these interstitial cells aggregated and groups of them became separated widely (Figs. 18, 19 and 40). Generally little variation occurred in the sizes of the early interstitial cells once their outlines were clearly defined. There were changes in the morphology of some cells and the emergence of a number containing eosinophilic granules within their cytoplasm. The numbers of these cells reached a maximum at mid-foetal life and then slowly regressed to small numbers in the early post natal period and remained as such through to adulthood.

Supporting Cells

Supporting cells were distinguishable in the testis of the 42 day old foetus (Fig. 14). They were oval shaped but in many instances the staining techniques employed did not define adequately the cellular boundaries and the extent of their cytoplasm. Identification of the supporting cells was based on the appearance of their nuclei, which were round and smaller than those of the gonocytes and generally were located about the periphery of the sex cord (Figs. 28, 29, 40 and 41). A number of gonocytes were located in a similar position within the sex cords (Figs. 15 and 16) but from about 60 days of foetal life (Figs. 17, 28) they were consistently observed in a central position of the sex cord, surrounded by the nuclei of supporting cells.

The diameters of the sex cords increased slowly but steadily (Figs. 16, 17, 18 and 19) and were accompanied by a small increase in the number of supporting cell nuclei seen in cross section. The observation of mitosis in some nuclei of the supporting cells provided additional evidence of active multiplication of these cells. Between 42 days and 50 days of foetal life no regular pattern was apparent in the location of the supporting cells (see Figs. 14 and 15 as examples of this period) but with increasing numbers their nuclei assumed widely spaced positions at the periphery of the sex cord (Figs. 17 and 28).

In the 77 day foetus and older, the nuclear boundaries of the increasing number of cells appeared to be in close contact and were maintained as a regular formation of a single row of nuclei until about 50 days of post natal life (see examples in Figs. 17, 18 and 19).

The outlines of the supporting cells were only indistinctly visible for a short period about the time of the differentiation of the sex cords. Their scant cytoplasm was seen as a small evenly stained circular mass around the nucleus (Fig. 15). Within a few days the boundaries of the cytoplasm of the individual cells were indistinct and the individual cells appeared to coalesce forming a dense but evenly distributed mass of cytoplasmic strands within the sex cord (Fig. 29). This mass engulfed all the nuclei of the supporting cells and outlined the boundaries of the gonocytes (Figs. 28, 29, 30 and 31). The strands of cytoplasmic tissue extending as elongated processes towards the centre of the sex cords were most pronounced in the testis of the lamb weighing 16 kg (Figs. 19 and 20).

`At the transitional stage between the two phases of development the cytoplasmic mass became a series of coarse filamentous strands which by separating were forming less dense areas in the centre of the cord (Figs. 22 and 42). This preceded the formation of the lumen of the mature seminiferous tubule (Figs. 23 and 27). Fine indefinite cytoplasmic inclusions described by Sapsford (1962a) were visible in the strands of cytoplasm from the time of birth.

The sizes of the supporting cell nuclei remained quite constant, but changes in their morphology appeared at the transitional period between the two phases of development. In the lamb weighing 16 kg the dark staining coarse chromatin granules within the nucleus became more pronounced and possibly enlarged (Figs. 32, 41 and 42). At the same time the nuclei of a number of supporting cells gradually occupied more central positions in the sex cord forming rows two or three deep within the boundary tissue (Figs. 20, 21, 22 and 40). Generally these positions were maintained until the transformation into Sertoli cells took place during the next phase of development (Figs. 23, 24).

Gonocytes

The germ cells of the foetal ram were present when the sex cords had differentiated (Fig. 14). Their nuclei were round and larger than the nuclei of the supporting cells and they were surrounded by a mass of cytoplasm, the boundaries of which were defined throughout the developing period. When the sex cords were formed the primordial germ cells became enveloped by a number of supporting cells. It was not until 53 days in foetal life that the germ cells took up their positions at the centre of the sex cords and became surrounded by the nuclei of the supporting cells (Fig. 16). From 60 days in foetal life the occasional germ cell was seen with its cytoplasmic membrane in contact with the boundary tissue of the sex cord, but this phenomenon was not common as the germ cells, now termed gonocytes, continued to maintain this generally central position (Figs. 17, 18, 19 and 31).

Gonocytes were not always observed in a cross-section of the sex cord. Most sections however contained at least one gonocyte and less frequently, two or more. At all ages a number of gonocytes were seen at some stage of mitosis, indicating a steady increase in their number. Early in post natal life a gonocyte with a grossly enlarged nucleus (a degenerate form of the cell) was encountered occasionally.

The stage of development of the germ cells were indicated by the appearance of their nuclei. Throughout the foetal period the nucleoli were surrounded by a number of moderately stained nuclear granules of irregular size (Fig. 30). These granules became smaller and less densely stained during the neo-natal period and gradually appeared as a number of fine particles, evenly distributed about the two, three or four nucleoli within the nucleus (Fig. 31). These cells in the lamb weighing 6 kg at an age of 16 days were readily identified as the mature gonocytes defined by Sapsford (1962a).

Further changes in the gonocytes were inapparent until near the termination of the first phase of development when the lamb weighed 15 kg. As their nuclei increased in size there was a reduction in the number of nucleoli accompanied by a dispersion of finer nuclear granules (Fig. 32). Prospermatogonia, the next progressive stage of germ cell development then became more apparent. They were still in a more central position than the supporting cells and their cytoplasm did not come in contact with the boundary tissue of the sex cord. The nuclei with one or sometimes two nucleoli, were larger than those of the gonocytes and were contained within cytoplasm enclosing a number of medium sized and dark staining granules. The nuclei of the prospermatogonia had many similarities in appearance to those of the A-type spermatogonia in the adult testis, but were rounder, more regular in shape, and did not lie on the boundary tissue of the developing seminiferous tubules (Figs. 32, 34 and 42).

Although the germ cells could be distinguished from the supporting cells at all stages throughout this phase of development, there were many similarities in the appearance and staining characteristics of the different nuclei during the foetal period. It was not until the neonatal stage when the chromatin within the nuclei of the germ cells became more finely dispersed, that the true nuclear forms of the two types of cells were obvious, and easier to differentiate.

c. Cell Changes in the Maturation Phase

General

As the body weight of the ram increased beyond 21 kg the growth of the testis which weighed about 10 G increased at a more rapid rate. The cytoplasm of the supporting cells changed from a homogeneous type to one of a dense fibrous network with pronounced processes extending from their nuclei towards the centre of the sex cords (Fig. 22). As the testis weight increased to 14 G many of those processes became separated at the centre and vacuole-like spaces appeared between the heavier staining strands of cytoplasmic tissue. These small and imperfectly formed spaces increased in size and appeared to coalesce forming a single larger space or lumen at the centre of the sex cord (Fig. 23). The formation of the seminiferous tubules proceeded slowly as the testis grew, and the testis weighing 25 G contained only the occasional sex cord which had not been transformed. The central lumen of the developing seminiferous tubule increased in diameter over a relatively short period. As the seminiferous tubules increased in size they occupied much larger portions of testis tissue, resulting in greater areas of boundary tissue coming in contact with each other. The rate of testis growth was greatest during this period, and was associated with the rapid proliferation of the germinal epithelium and the establishment of the spermatogenic cycle.

Little apparent change took place in the interstitial cells. They became grouped together in loosely formed aggregates in the interstitial spaces which gradually became restricted by the enlarging tubules. At the stage when spermatozoa were released into the tubules the interstitial spaces were generally triangular areas bounded by three or more seminiferous tubules.

Supporting Cells

At the transitional period between the developing phases, the nuclei of the supporting cells were frequently seen in a second or third row arranged about the periphery of the sex cord (Figs. 21, 22 and 40). They were interspersed with the developing germ cells taking up positions about the basement membrane (Fig. 21) or between the increasing numbers of A-type spermatogonia and primary spermatocytes which were moving towards the centre of the seminiferous tubules (Fig. 22). Gradually the darker staining granules within the nucleus dispersed as fine less densely staining material about the one or two nucleoli (Figs. 41 and 42). The nuclei gradually changed from round or oval shapes to larger irregularly cuboidal or triangular shapes which distinguished the Sertoli cells in the mature testis (Figs. 41, 42 and 43). The filamentous cytoplasm of the supporting cells became more diffuse and occupied the tissue within the seminiferous tubules not taken up by the developing germ cells (Fig. 43).

Although changes appeared slowly all the supporting cells were transformed into Sertoli cells as the testis weight increased from 25 G to 56 G (Fig. 24). It was during this same period that the gradual transformation of sex cords to seminiferous tubules was completed. This was before the appearance of increasing numbers of spermatids in the tubules.

Adult Stem Cells

The germ cells became interspersed between the nuclei of the supporting cells at the periphery of the developing seminiferous tubule (Figs. 20 and 21). The numbers of prospermatogonia increased and progressed to A-type spermatogonia. In any one section of the tubule all prospermatogonia had proceeded in development to A-type spermatogonia before any subsequent changes to more progressive stages of stem cells had occurred (Fig. 21, 22). The stem cells were seen in mitotic activity and their numbers increased rapidly relative to the apparently static numbers of supporting cell nuclei (Fig. 33). Progressive stages of germ cells (intermediate and B-type spermatogonia and primary spermatocytes) were seen later but not necessarily in the same tubule (Figs. 23, 24, 34, 35 and 36). All tubules in the same testis did not develop at the same rate. Although the germ cells in some sections had progressed to the meiotic stages, other sections of tubules in the same testis were slower in development and prospermatogonia were still interspersed within the multiple layers of supporting cell nuclei.

As the testis grew, spermatogenesis increased. A-type spermatogonia and signs of mitotic activity and active multiplication of these cells were seen first in the testes of the ram weighing 19 kg at about 70 days of age. The appearance of early spermatids following meiosis of the germ cells were observed first in the 56 G testis of an older ram weighing 21 kg (Figs. 24, 25, 26, 38 and 39). The initial appearance of spermatozoa in the lumen of the seminiferous tubule was a function of both the chronological and physiological ages of the ram. They were present in the lumen of the seminiferous tubule in the 63 G testis of a ram weighing at least 26.3 kg. Spermatozoa were not seen in rams younger than 154 days.

d. Changes in the Adult Phase

The initial release of spermatozoa into the lumen of the seminiferous tubules completed the first cycle of spermatogenesis. Growth of the testis continued and greater numbers of tubules completed the spermatogenic cycle. The testis proceeded to grow relatively faster than increases in the body weight of the ram and few if any changes in the cellular components of the tubules were apparent. The appearance of the tubular sections was the same as that observed in the testis of the mature ram (Fig. 27).

Discussion

Associated with the weight increases of the testis were progressive changes in the size of the seminiferous tubules, and changes in the relationships of their cellular components. Once the differentiation of the sex cords had occurred three successive phases of development took place. The prepuberal phase began early in foetal life, continued through gestation and for a variable time following birth. This period can vary from several years in man (Charny et al., 1952a; 1952b; Sniffen, 1952; Mancini et al., 1960), a few months in rams, bulls and boars (Phillips and Andrews, 1936;

Phillips and Zeller, 1943; Hooker, 1944; Green and Winters, 1944; Carmon and Green, 1952; Hauser et al., 1952; Watson et al., 1956; Santamarina and Reece, 1957; Abdel-Raouf, 1960, 1961; Fossland and Shultze, 1961; Courot, 1962; Attal and Courot, 1963; McFee and Eblen, 1967; Skinner et al., 1968; Macmillan and Hafs, 1969; Matschte and Erickson, 1969) to a few days in rats and mice (Clermont and Perey, 1957; Nebel et al., 1961; Beaumont and Mandl, 1963; Huckins, 1963; Franchi and Mandl, 1964; Hilscher and Hilscher, 1968; Hilscher and Makoski, 1968; Novi and Saba, 1968).

The maturation phase commenced with the initiation of spermatogenesis and lasts for a relatively short period of time. The adult phase was achieved when spermatozoa were released into the lumen of the seminiferous tubules. This general pattern of development was observed in the Romney ram used in this investigation and was similar to that described in other breeds of sheep and other species of animals.

In this study it was found that differentiation of the sex cords had occurred in the testis of the 42-day foetus. However, the arrangement of the germ cells in relation to the supporting cells was not clearly defined until 10 days later when the gonocytes had appeared as definite entities at a central position within the sex cords.

The development of the seminiferous tubules was gauged by changes in their diameters, the differentiation of lumina and the progressive development of the cellular components. Initially a greater number of circular sections of sex cords was observed near the tunica albuginea of the testis, indicating that the cords were lengthening and folding along their course to a greater degree in the peripheral region. Clermont and Huckins (1961) have demonstrated this clearly in the developing tubules of rat testes.

Once established, there was very little change in the diameters of the sex cords until after birth when the rates of increase could be related to the three periods of testicular growth. From birth until about 50 days of age there was a two-fold increase in size followed by a more rapid two-fold increase between 60 days and 99 days. Finally, greatest tubular diameters were reached at about 200 days but this phase was at a much slower rate than those occurring during the earlier periods. The overall increase in the diameter of the tubules from birth to the adult was found to be about five-fold which is similar to previous observations in the ram (Phillips and Andrews, 1936; Carmon and Green, 1952; Courot, 1962; Skinner et al., 1968), and in the bull (Abdel-Raouf, 1960; Attal and Courot, 1963). A curvilinear relationship has been demonstrated between the changes in the diameters of the seminiferous tubules and the lamb's age, the testis weight and the body weight of rams (Carmon and Green, 1952; Watson et al., 1956; Courot, 1962). However, Courot (1962) was unable to correlate tubular diameter with testis weight as a simple mathematic expression. Similarly, Skinner et al.(1968) were unable to relate changes in the tubular diameter with any particular stage of spermatogenesis.

The most rapid increases in diameter of the seminiferous tubules in the ram coincided with the formation of the lumen within the sex cords (Watson et al., 1956). Attal and Courot (1963) considered that the appearance of the lumen was an important developmental state of the seminiferous tubule. It was concomitant with the appearance of spermatids, and a change in growth rhythms of the diameters and the lengths of the seminiferous tubules. In this study the lumen was not present in rams less than 69 days of age, but about this age the cellular tissue at the centre of the sex cord showed signs of parting, leaving spaces which radiated toward the periphery. The spaces coalesced to form star-shaped lumina, which gradually became circular in shape. Between 150 days and 196 days lumen formation was completed in most of the tubules in the testis. The lumina were lined by either spermatozoa or spermatids. These observations, particularly the cellular changes, substantiated those of Phillips and Andrews (1936), Carmon and Green (1952), and Watson et al. (1956).

The sex cords in foetal and newborn lambs were morphologically similar to those seen in other species. Two types of cells were present, gonocytes and supporting cells. Although all authors, particularly before 1960, did not agree on the origin of the germinal lines, recent evidence in the ram (Courot, 1962; Sapsford, 1962a, 1964), the bull (Abdel-Raouf, 1960, 1961; Nicander et al., 1961; Attal and Courot, 1963), the golden hamster (El Gohary, 1964), man (Mancini et al., 1960), and the rat and mouse (Clermont and Perey, 1957; Sapsford, 1957, 1962b, 1964; Nebel et al., 1961; Beaumont and Mandl, 1963; Baillie, 1964a; Franchi and Mandl, 1964; Hilscher and Hilscher, 1968; Hilscher and Makoski, 1968; Novi and Saba, 1968) definitely confirms that the adult stem cells arise from the primordial germ cells through the gonocytes, and at all stages they are distinguishable from the supporting cells and their derivatives, the Sertoli cells.

In this study some degenerating gonocytes were seen particularly in later foetal life and the early post natal period. Gonocytes with abnormally large nuclei, as described by Sapsford (1962a), were present also during this phase. It can be postulated that these forms of germ cells do not develop normally but ultimately degenerate as in man

(Mancini et al., 1960). Their fate and significance is unknown (Sapsford, 1962a).

The steady increase in gonocyte numbers in the prepuberal phase was more apparent in the post natal period. These observations were supported by the greater frequency of mitotic divisions seen with the formation of prospermatogonia prior to the onset of spermatogenesis. During this period the tubules were increasing in length and if the numbers of germ cells were not increasing, fewer would have been seen in each tubule. The quantitative analyses of Courot (1962) confirm these and similar observations in the ram by Sapsford (1962a). In man, however, Mancini et al. (1960) recognised three waves of intermittant germ cell activity during this phase but only the third wave gave rise to complete spermatogenesis.

The precise measurements of Sapsford (1964) on the germ cell nuclei in the developing testes of both the ram and the rat established that prior to the onset of spermatogenesis, the nuclei of the prospermatogonia in the ram and the mature gonocytes in the rat have reached their greatest size. By the time spermatogenesis had been established the size of the cell nuclei had diminished. Sapsford (1964) concluded that these changes were part of the normal differentiation of the gonocytes and could be a development paralleled by the increases in the nuclei of A-type spermatogonia before stage 1 of the cycle of the seminiferous epithelium.

Mature gonocytes were present in the ram testis until about 50 days of age when increasing numbers of prospermatogonia emerged between the supporting cells close to the boundary tissue. In this study both prospermatogonia and A-type spermatogonia were present in some seminiferous tubules of the 10 G testis from a 70 day old ram weighing 19 kg. In the 84 day old ram with 25 G testis both spermatogonia and primary spermatocytes were present in the tubules. Courot (1962) showed that at this stage the numbers of A-type spermatogonia per tubular cross-section had reached a maximum and continued to remain about this level throughout adult life. During the period before the reproductive capacity of the adult ram had been reached however, the total numbers of adult stem cells increased regularly with the growth of the testis. Attal and Courot (1963) suggested that additional active stem cells were derived from divisions of some immature spermatogonia which were outside the framework of the established spermatogenic cycle.

The primary spermatocytes first observed in the 25 G testis of the 84 day old ram were present in the testes of all the older rams studied. Because of insufficient samples the rate of development of the primary spermatocytes could not be determined. Courot (1962) observed primary spermatocytes in small numbers in the testis weighing between 8 and 12 G. They slowly increased in number until the testis weighed 14.5 G and then quickly reached the observed number in the adult testes. These changes occurred at an older age and in a lighter testis than that of the Romney. The observations in this study agreed with those of Skinner <u>et al.</u> (1968) in the Suffolk ram, but the appearance of primary spermatocytes was later than recorded in breeds other than the Ile-de-France (see Table X). In the testes of the more developed rams the numbers of primary spermatocytes showed wide variations between tubules. The actual number depended on the stage of the cycle of the seminiferous epithelium. The transition through the reduction

TABLE X: TIME AND STAGE OF GROWTH OF BOTH THE TESTIS AND THE BODY WEIGHTS WHEN THE GERM CELLS FIRST APPEARED IN THE DEVELOPING LAMB TESTES

Breed and Reference	Primary Spermatocytes			Spermatids			Spermatozoa		
	Age (days)	T.W. (grams)	B.W. (kilograms)	Age (days)	T.W. (grams)	B.W. (kilograms)	Age (days)	T.W. (grams)	B.W. (kilograms)
Southdown/Shropshire (Phillips & Andrews, 1936)	63	-	-	126	-	-	147	-	-
Hampshire (Carmon & Green, 1952)	56	4	15.75	168	121	43	168	121	43
Southdown (Carmon & Green, 1952)	63	3.6	10	154	67	24	154	67	24
Merino (Watson et al., 1956)	-	-	-	-	-	-	126	90	27
Ile-de-France (Couret, 1962)	91	13.6	24	105	30	27	117	65	33
Suffolk (Skinner et al., 1968)	70-84	22		105	64		112	95	
N.Z. Romney (present study)	70-84	25	20.5	99	56	21	154	63	26

T.W. = Testis Weight

B.W. = Body Weight

divisions of meiosis was rapid, and secondary spermatocytes were seen in very few tubules. This is because their presence before the appearance of young rounded spermatids is transitory, present for only 0.6% of the spermatogenic cycle (Ortavant, 1959).

The proportion of spermatids among the germ cells was highest in the 56 G testis of rams older than 99 days. At this stage the numbers of younger round spermatids had increased rapidly. The spermatids were evolving into elongated and more mature forms. Subsequently both types were found in the same section of the tubule. Their numbers increased until spermatozoa appeared at the margins of the lumina of the seminiferous tubules. There were wide variations in the spermatid numbers in individual tubules, and those tubules with large numbers and no spermatozoa corresponded to stage 1 of the cycle of the seminiferous epithelium (Ortavant, 1959).

The youngest ram with spermatozoa in this study was 154 days of age and weighed 26.5 kg. Spermatozoa were not observed in the younger rams with heavier testes and body weights. This suggests that the completion of spermatogenesis may be in part a function of age as well as of absolute growth of the ram. When spermatozoa were seen first they were present as an occasional solitary sperm. In the Romney, as in the Southdown (Carmon and Green, 1952) and the Ile-de-France breeds (Courot, 1962), when the testis weight exceeded 67 G larger numbers of spermatozoa were present, and cycles of the seminiferous epithelium were completed regularly.

The time of the appearance of the different cell types in the Romney ram is in general agreement with the other authors (see Table X). The pattern followed the changes in the testis weight indicated by

Courot (1962) and was very closely related to changes in the body weight of the ram (Watson et al., 1956). Spermatogenesis commenced earlier in the Hampshire, Southdown and Shropshire rams (Phillips and Andrews, 1936; Carmon and Green, 1952), than in the Romney and Suffolk (Skinner et al., 1968) but later in the Ile-de-France (Courot, 1962). The completion of spermatogenesis in the Romney and Southdown however was later than in the Suffolk, the Ile-de-France breeds and the Merino (Watson et al., 1956), but earlier than in the Hampshire although there was not a great variation between their testis weights.

The numbers of supporting cells increased slowly but steadily throughout the foetal and post natal periods reaching maximum numbers before their transformation to Sertoli cells between 84 and 99 days. Once Sertoli cells appeared their numbers apparently diminished compared with the larger numbers of their precursors, and stabilised at a lower number about the time of the release of spermatozoa into the tubules (Courot, 1962). Courot (1962) did not see any degeneration or elimination of these cells and concluded that their numbers were fairly static and that they became more spread with the growth in the length of the tubule. Baillie (1964a) was unable to detect mitotic activity in the supporting cells of the mouse and rat at the time of appearance of A-type spermatogonia. Supporting cells whose nuclei were situated both at the periphery of the tubule or closer to the centre, changed to the mature form. Although all supporting cells in the plane of the tubule appeared to mature at the same time, not all tubules in the one testis contained Sertoli cells. Maturation is rapid and the transition was completed as the testis increased from 25 G to 56 G in a short space of about 14 days. Abdel-Raouf (1960) noted a similar sequence in the bull, and Clermont and Perey (1957) established a level in the rat to which the numbers of supporting cells became reduced, before maturation to a fixed number of Sertoli cells.

Studies by earlier authors were unable to determine the cellular outline of the supporting cells so that their nature was in doubt. Both the supporting cells and Sertoli cells in the ram were described as forming a syncytium (Watson *et al.*, 1956) but different microscopic techniques and ultrastructural studies have shown that these cells exist in many animals as mononucleate units (Fawcett and Burgos, 1956; Sapsford, 1957, 1962a, 1962b; Gardner and Holyoke, 1964; Flickinger and Fawcett, 1967; Leik, 1968). Two types of supporting cells with lighter and darker ultrastructure have been seen in the rat. Although the significance of the lighter form is not known, Novi and Saba (1968) have suggested that they represent a stage of degeneration and the majority of darker forms proceed to form Sertoli cells. Abdel-Raouf (1960) described two types of Sertoli cells in the bull, one with the long axis parallel and the other with the long axis perpendicular to the basement membrane. Both types could be seen in the one cross section of the tubule in the ram. Leblond and Clermont (1952) stated that during some stage in the cycle of the seminiferous epithelium in the rat, one type changed into the other. Present evidence, particularly ultrastructural studies, leaves little doubt that the supporting cells are the precursors of Sertoli cells only (Sapsford, 1957, 1962a, 1962b; Clermont and Perey, 1957; Mancini *et al.*, 1960; Nebel *et al.*, 1961; Baillie, 1964a; El Gohary, 1964; Novi and Saba, 1968; Hilscher and Hilscher, 1968).

The cytoplasm of supporting cells and Sertoli cells completely surrounds the gonocytes in the developing animal (Nicander *et al.*, 1961; Franchi and Mandl, 1964) and the spermatocytes, spermatids and some of the spermatogonia in the adult (Vilar *et al.*, 1962). In addition to their structural support and nutritive properties, Courot (1967) postulated that these somatic cells act as the first site for the initial hormone action in the seminiferous tubule, and become the triggering point to initiate the onset of spermatogenesis. Roosen-Runge and Leik (1968) have suggested also that in the rat supporting cells apparently phagocytise the degenerating gonocytes.

Difficulty was experienced in determining the numbers of interstitial cells and in distinguishing them all from other cells in the interstitial tissue. In the ram, Hay and Deane (1966) and Skinner *et al.* (1968) were unable to distinguish with certainty the active and mature Leydig cells described as typical for most species by earlier authors. Sniffen (1950), Montagna (1956 - see Fawcett and Burgos, 1956), and Balze *et al.* (1960) were unable to distinguish smaller Leydig cells from the morphologically similar fibroblasts before puberty was completed in man. Hooker (1948) observed similarities between these cells in the bull. During the progression of these cells from the mesenchyme tissue to the adult state they may remain indistinguishable morphologically and often are differentiated only by histochemical methods and ultrastructural studies (Baillie, 1960; Niemi and Ikonen, 1963; Niemi *et al.*, 1967).

A number of interstitial cells with eosinophilic granules in the cytoplasm described by both Baillie (1960) and Sapsford (1962a) were observed in testes of the older foetal and neonatal Romney rams. These forms were no longer seen after the maturation phase when the apparently normal forms became more widely scattered. In the foetal ram Baillie (1960) also described a second atypical form of Leydig cell with a shrunken and pycnotic nucleus.

The numbers of interstitial cells fluctuate in the different species at different ages, but this was not apparent in the ram (Sapsford, 1962a). In the rat maximum numbers were reached a few days before birth, followed by a reduction to the lowest level a few days after birth (Roosen-Runge and Anderson, 1959). Separate foetal and puberal generations of Leydig cells have been postulated (Niemi and Ikonen, 1963). This was not supported in the mouse by Baillie (1961) who concluded that these cells were relatively slow growing in the post natal period. At puberty, Clegg (1966) and Knorr et al. (1970) showed that the numbers of Leydig cells in the rat declined after a phase of rapid growth but there was a concurrent increase in the output of testicular androgens.

In summary therefore the findings of other investigators strongly suggest that the adult stem cells arise from gonocytes and thus maintain genetic continuity of the germ cell line while the Sertoli cells develop from the supporting cells. Concurrent with germ cell evolution is the separation of tissues at the centre of the sex cord to form a lumen within the developing seminiferous tubule, and maturation of Sertoli cells before the appearance of spermatids. Hence during this developmental period the changes of each characteristic are closely interrelated.

Over many studies on the developing testes of the ram, only approximate times can be established for the appearance of changes in the seminiferous tubule; this investigation has proved no exception.

Like Skinner et al. (1968), in their investigations of the Suffolk, the time interval between sampling in this study was too long over the later prepuberal and the maturation phases of growth to establish precise time relationships. Similarly the numbers of lambs available at each stage were probably too few to adequately cover the variations present at each step. Courot's (1962) observations on 59 lambs over 160 days following birth gave a more thorough picture of the relative changes.

The normal rhythm of spermatogenesis is apparent once changes in the germinal line commence and the evolution of the progressive cellular elements become synchronised (Courot, 1962). This could not be shown precisely by the qualitative observations made in the investigation reported here.

FIGURE 10: Testis of a 42-day foetus. H. & E. stain. x 160.

E, coelomic epithelial cells covering the surface of the testis.

Ta, tunica albuginea.

C, sex cords.

FIGURE 11: Testis of a 53-day foetus. H. & E. stain. x 160.

E, coelomic epithelial cells covering the surface of the testis.

Ta, tunica albuginea.

C, sex cords.

I, interstitial tissue.

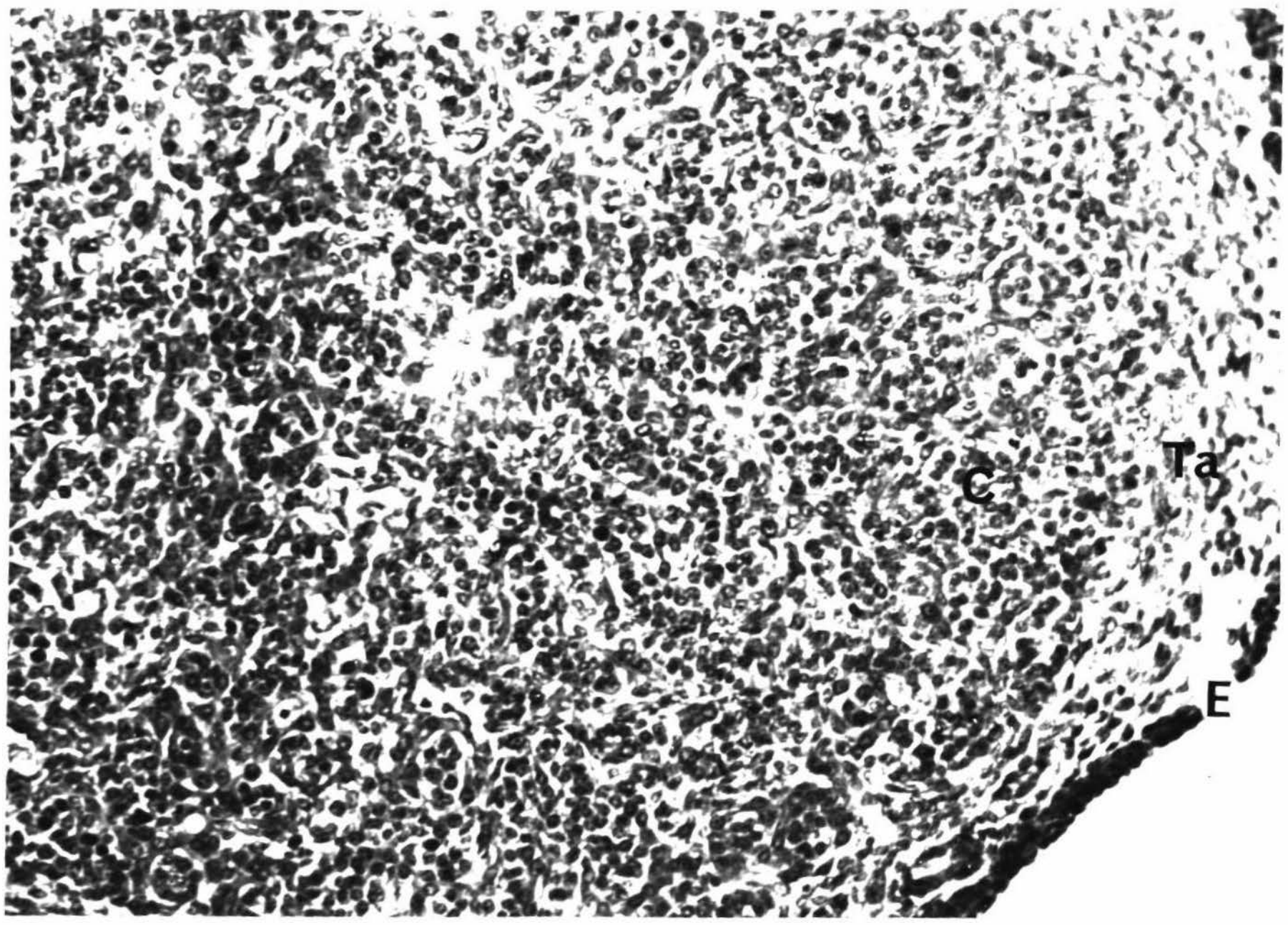
Ta
C
E


C
I
Ta
E

FIGURE 12: Testis of a 109-day foetus. H. & E. stain. x 160.

Ta, tunica albuginea.

C, sex cords.

I, interstitial tissue.

FIGURE 13: Testis of a 1-day lamb. H. & E. stain. x 160.

Ta, tunica albuginea.

C, sex cords.

I, interstitial tissue.

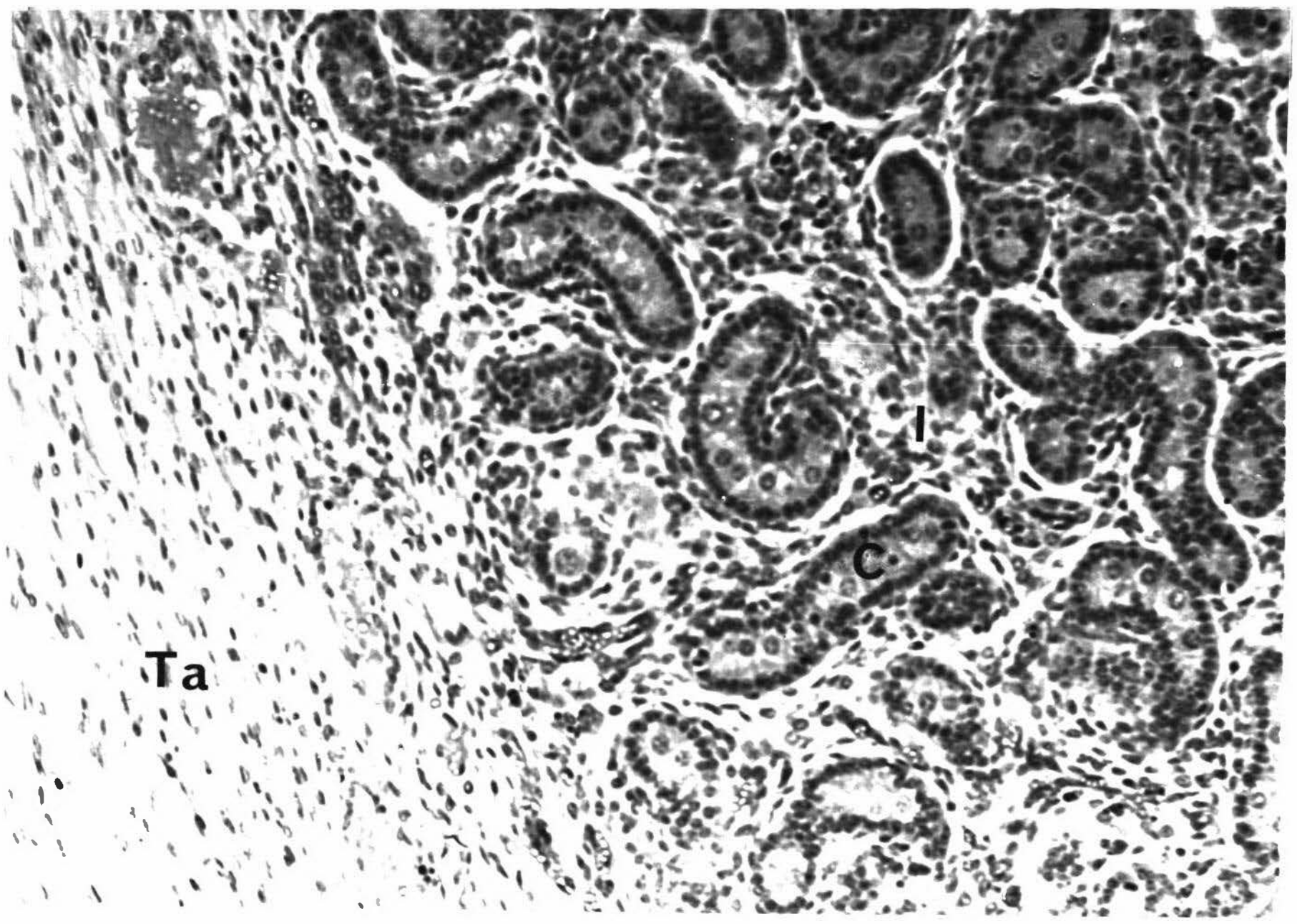
I
C
Ta

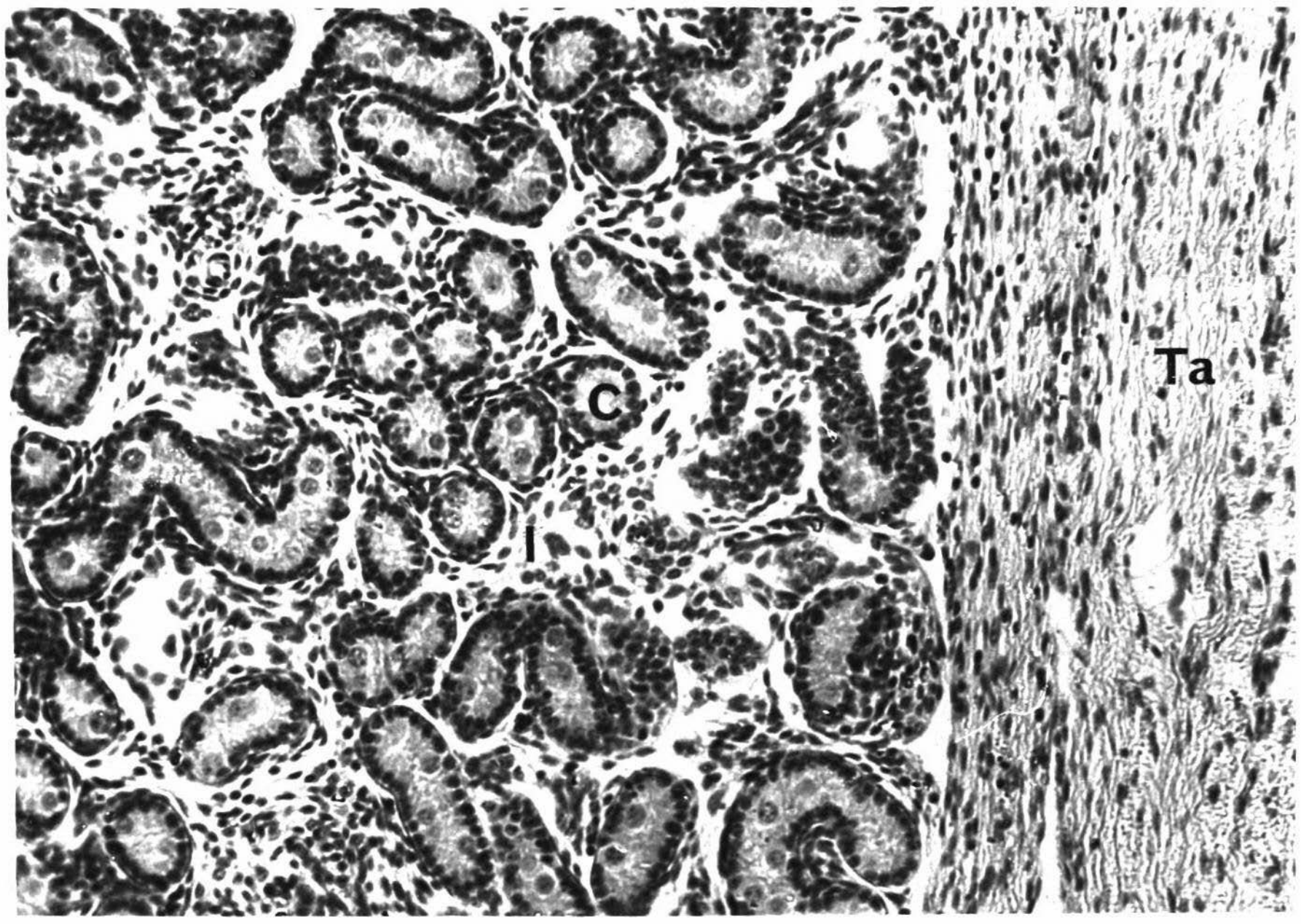
Ta
C
I

FIGURE 14: Testis of a 42-day foetus. H. & E. stain. x 320.

Ta,	tunica albuginea.
C,	sex cords.
G,	genocytes.
S,	nuclei of supporting cells.
I,	interstitial cells.

FIGURE 15: Testis of a 47-day foetus. H. & E. stain. x 320.

C,	sex cord, longitudinal section.
G,	genocyte.
S,	nuclei of supporting cells.

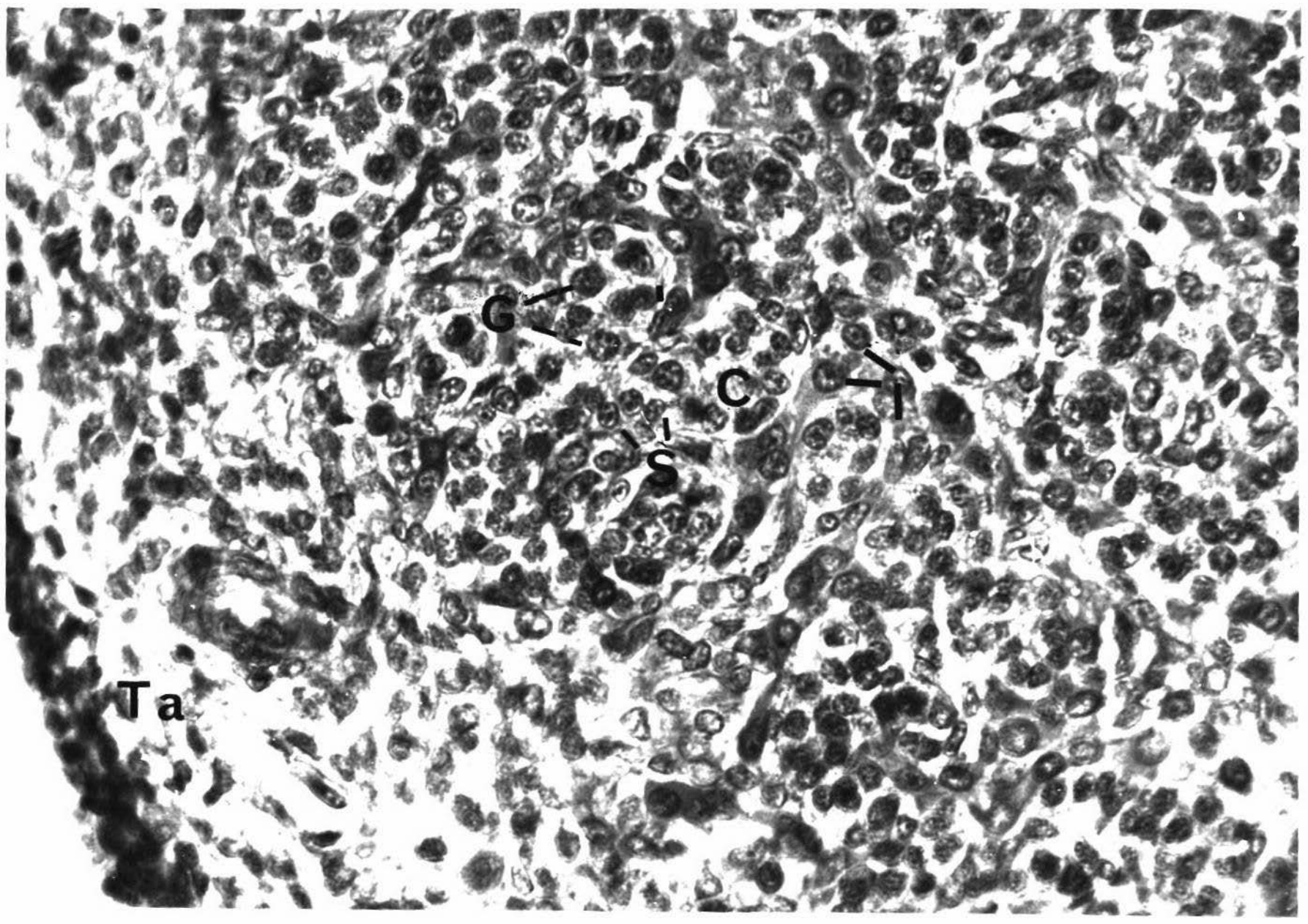
G
C
S
Ta

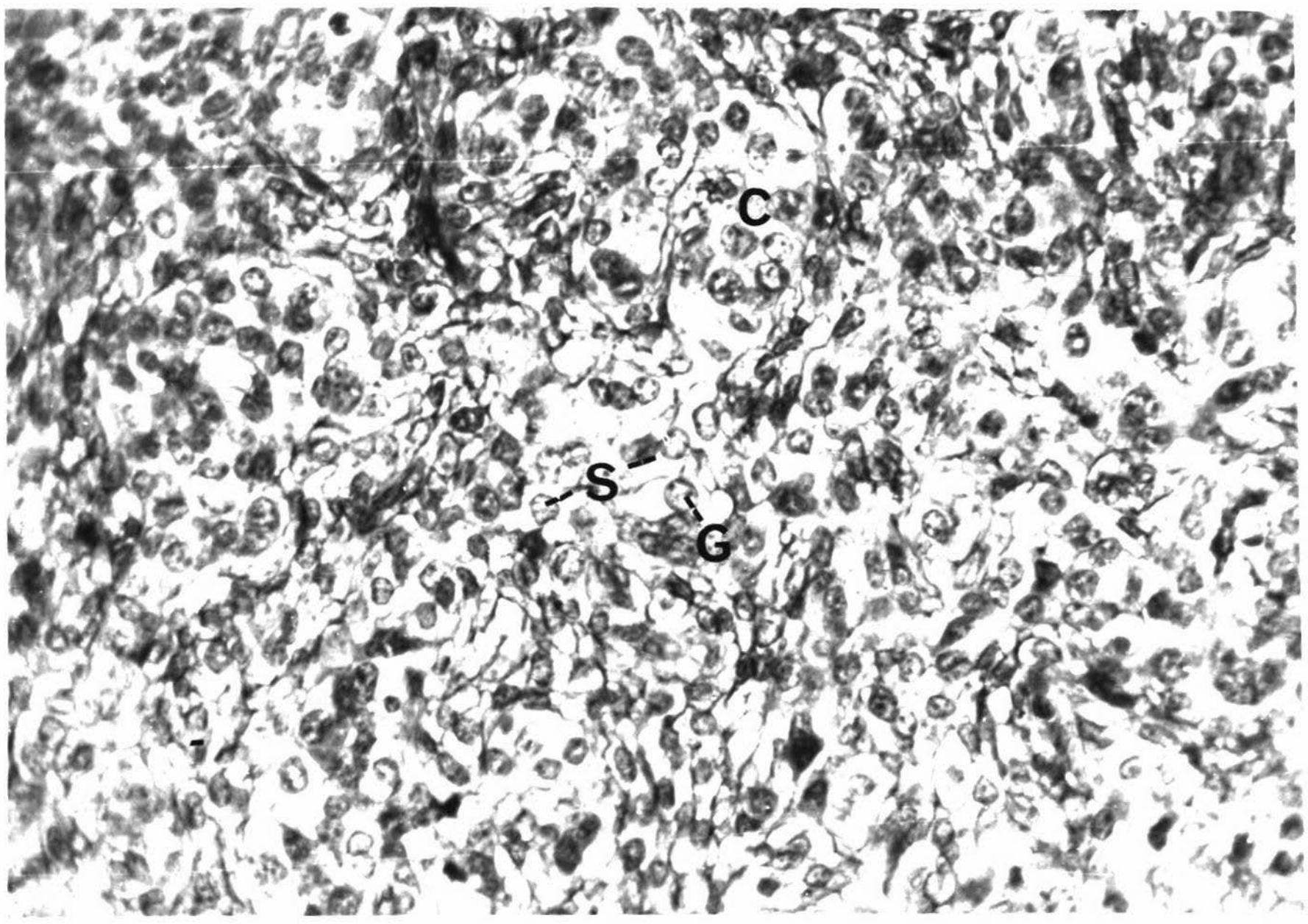
C
S
G

FIGURE 16: Testis of a 93-day foetus. H. & E. stain. x 320.
Sex cords consisting of gonocytes (G) surrounded
by nuclei of supporting cells (S).
I, interstitial cells.

FIGURE 17: Testis of a 109-day foetus. H. & E. stain. x 320.
Sex cords consisting of gonocytes (G) surrounded
by nuclei of supporting cells (S).
I, interstitial tissue consisting of interstitial
cells and fibroblasts.

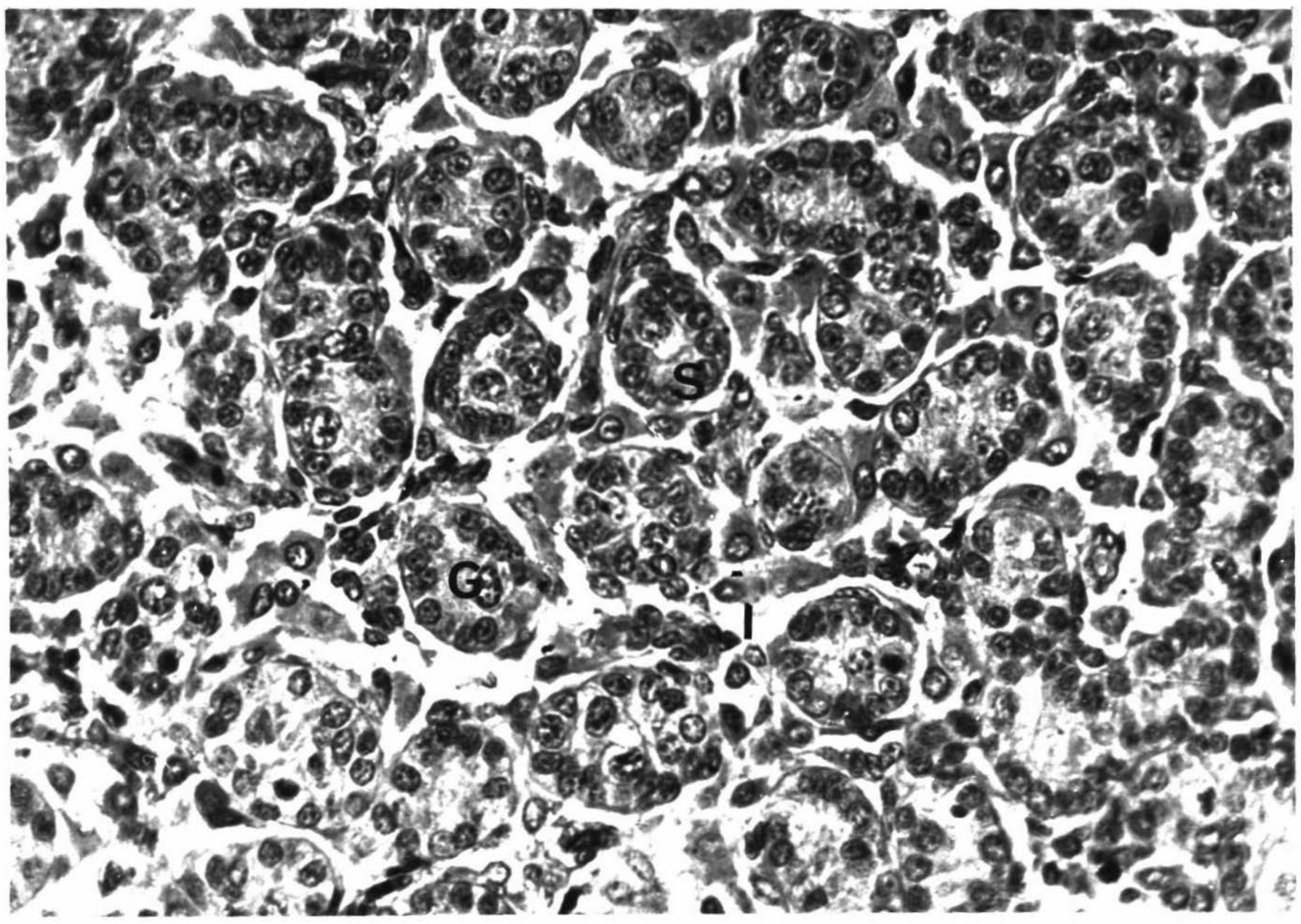
S
G
I

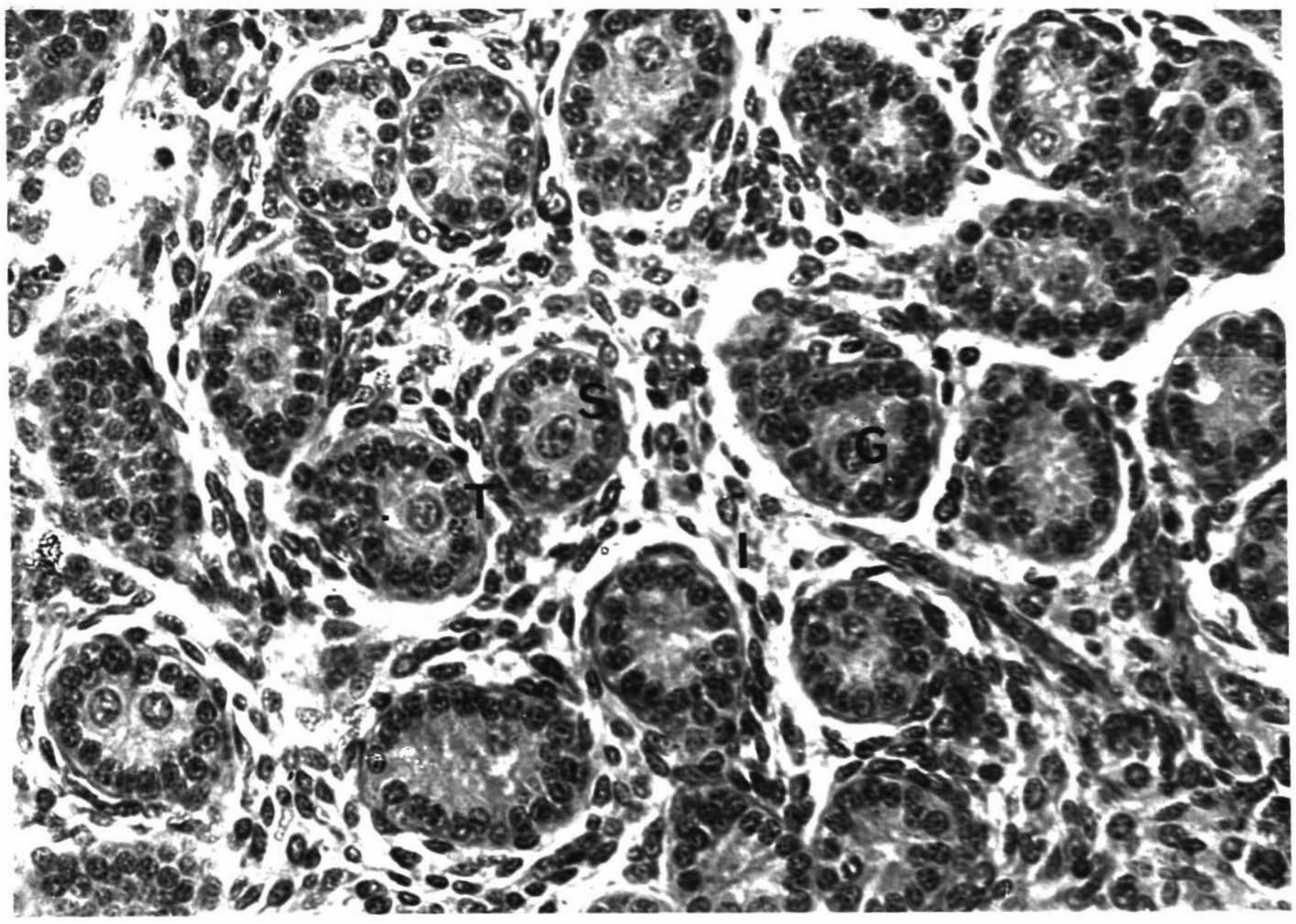
S
T
G
I

FIGURE 18: Testis of a 28-day lamb. H. & E. stain. x 320. Sex cords containing mature gonocytes (G) surrounded by a single row of nuclei of supporting cells (S).

I, interstitial tissue.

FIGURE 19: Testis of a 49-day lamb. H. & E. stain. x 320. Sex cords of increasing diameter containing mature gonocytes (G) surrounded by a single row of nuclei of supporting cells (S).

Ic, interstitial cells.

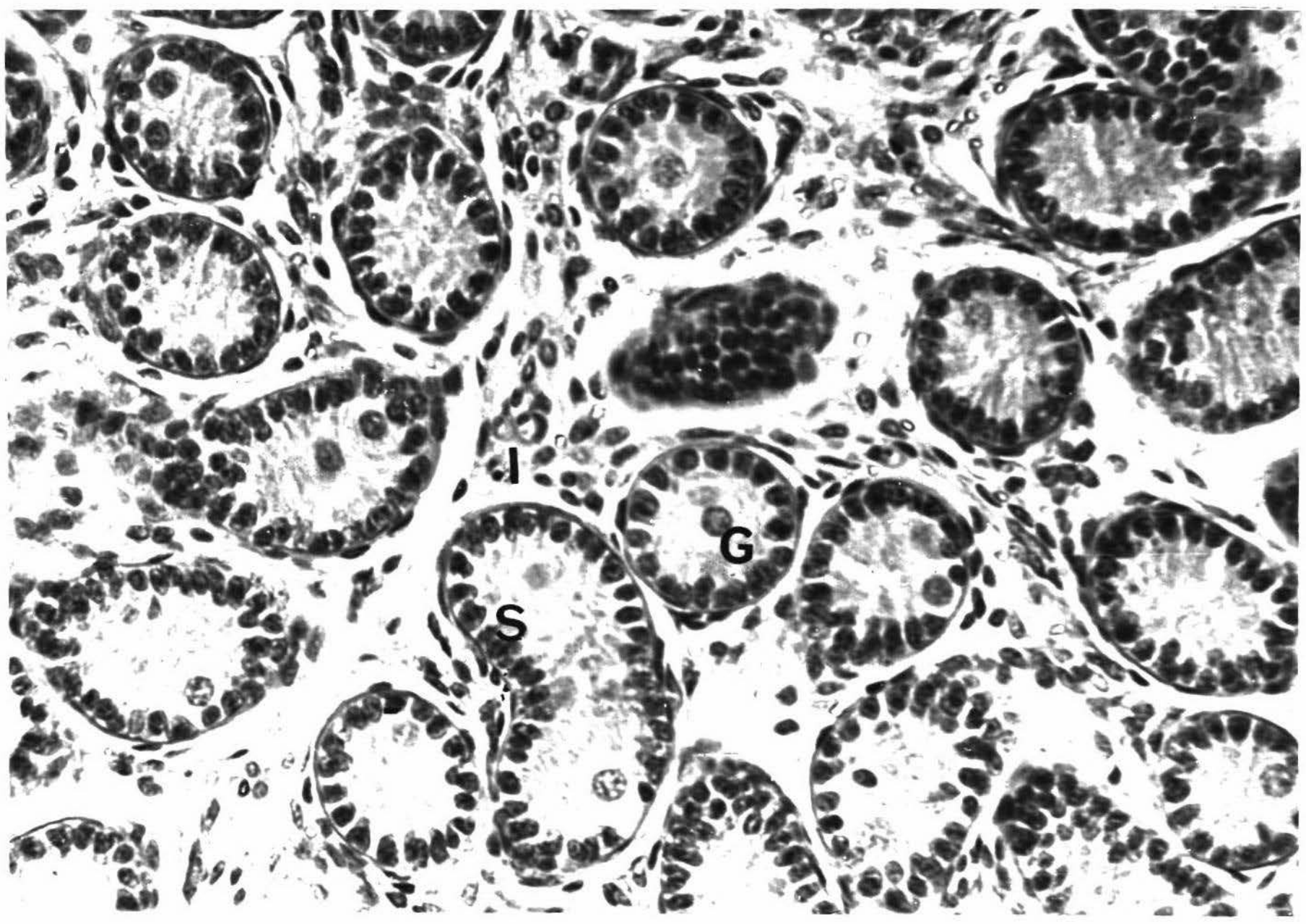
I
G
S


Ic
G
S

FIGURE 20: Testis of a 60-day lamb. H. & E. stain. x 320. Sex cords of increasing diameters containing prospermatogonia (P) moving towards the peripheral row of supporting cell nuclei (S).

FIGURE 21: Testis of a 60-day lamb. H. & E. stain. x 320. Prospermatogonia (P) within a double peripheral row of supporting cell nuclei (S).

cy, strands of cytoplasm of the supporting cells.

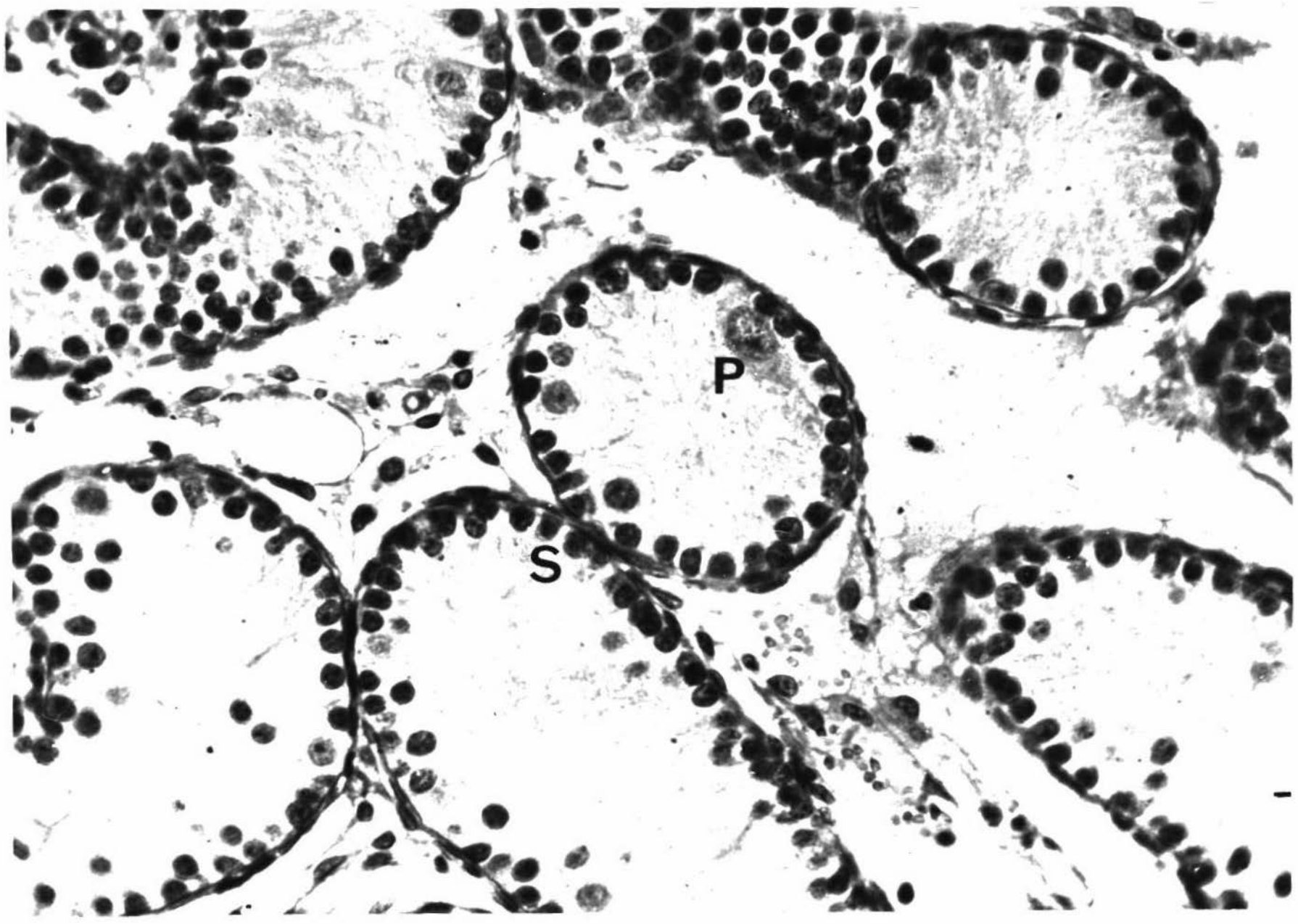
P
S

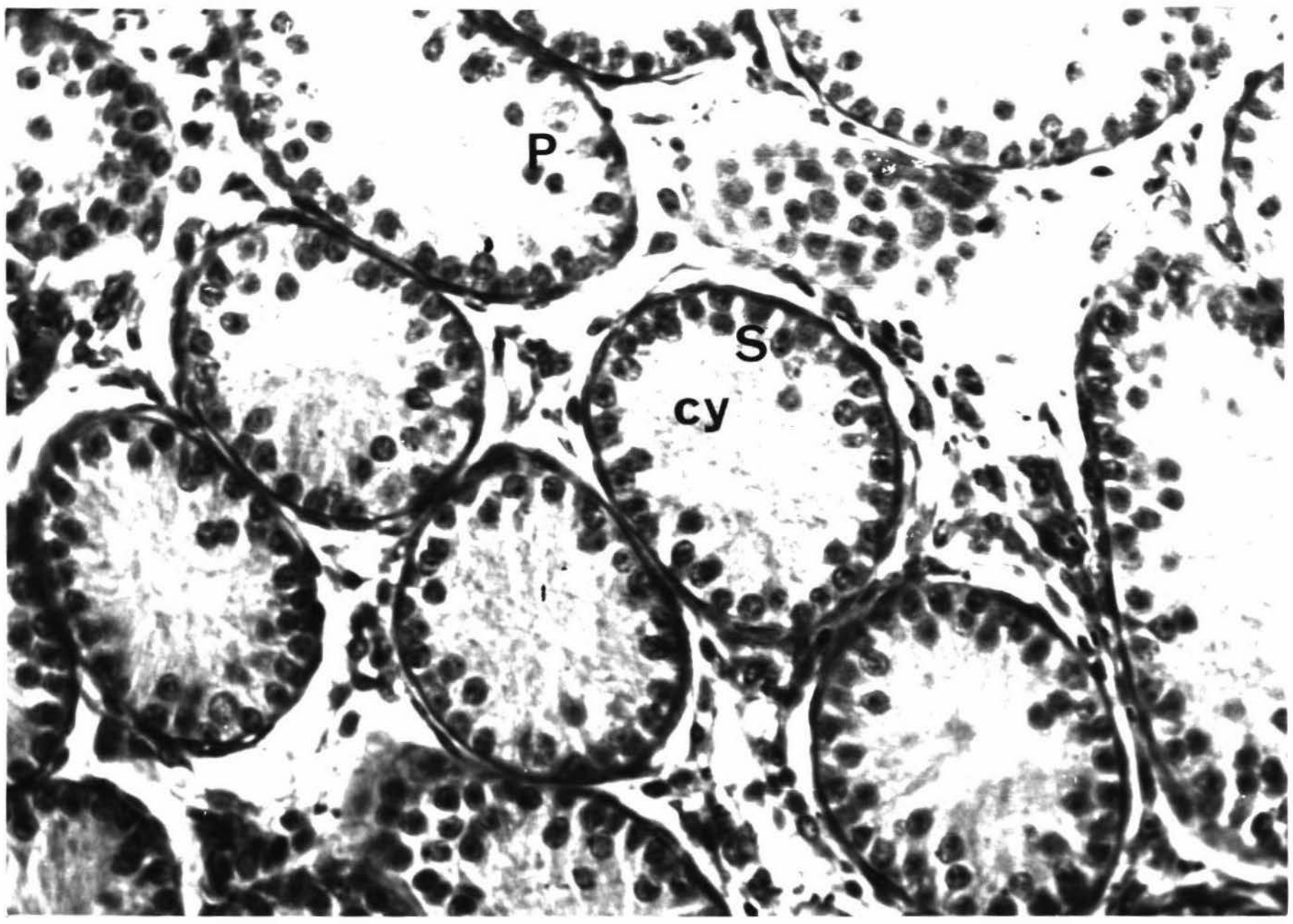
P
S
cy

FIGURE 22: Testis of a 69-day lamb. H. & E. stain. x 320. A-type spermatogonium (As) in contact with boundary tissue of sex cord. Nuclei (S) and cytoplasmic strands (cy) of the supporting cells.

FIGURE 23: Testis of a 84-day lamb. H. & E. stain. x 320. Seminiferous tubule with central lumen (lu).

As, A-type spermatogonium.
Y, younger forms of primary spermatocytes.
S, nuclei of supporting cells.

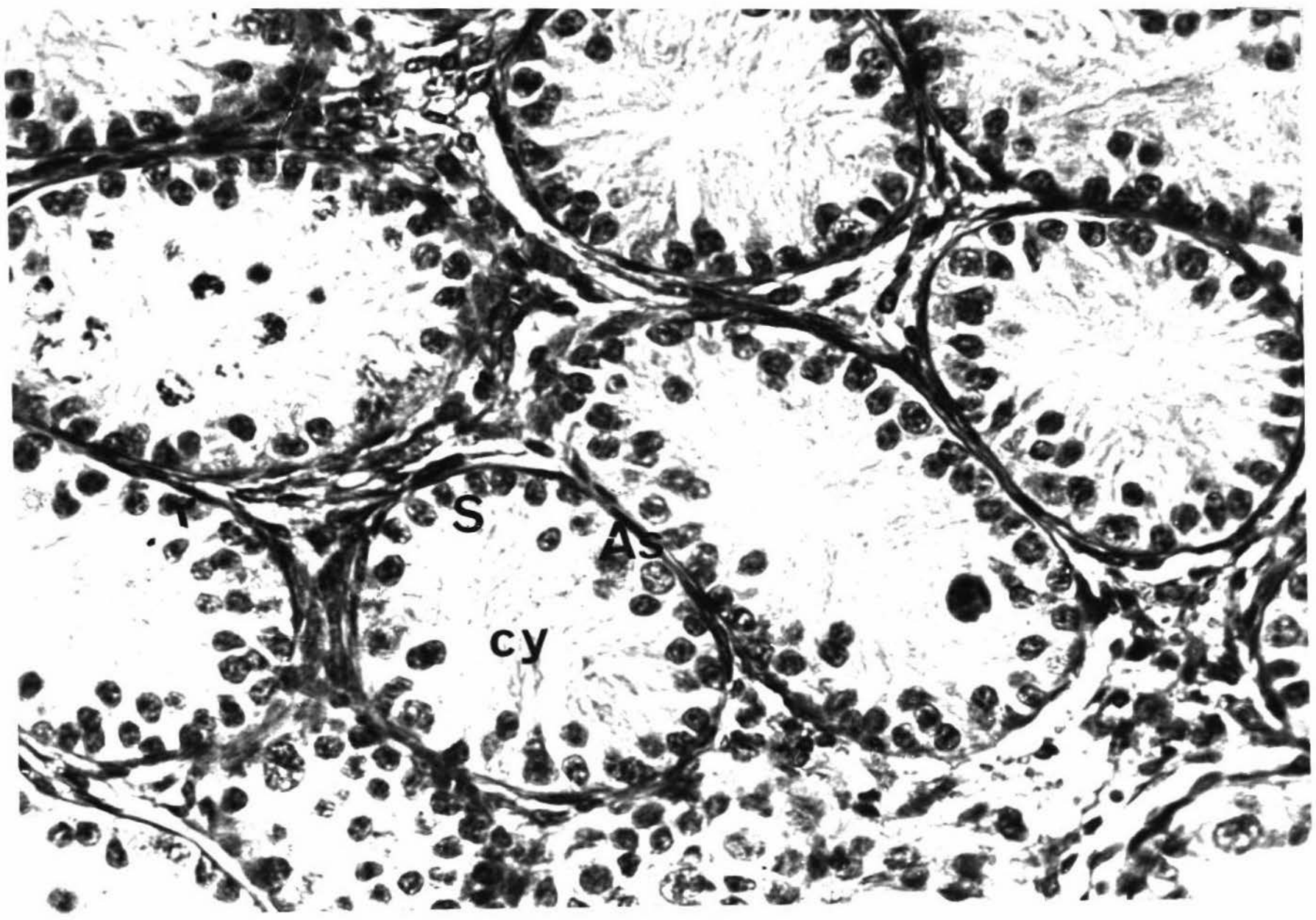
S
As
cy

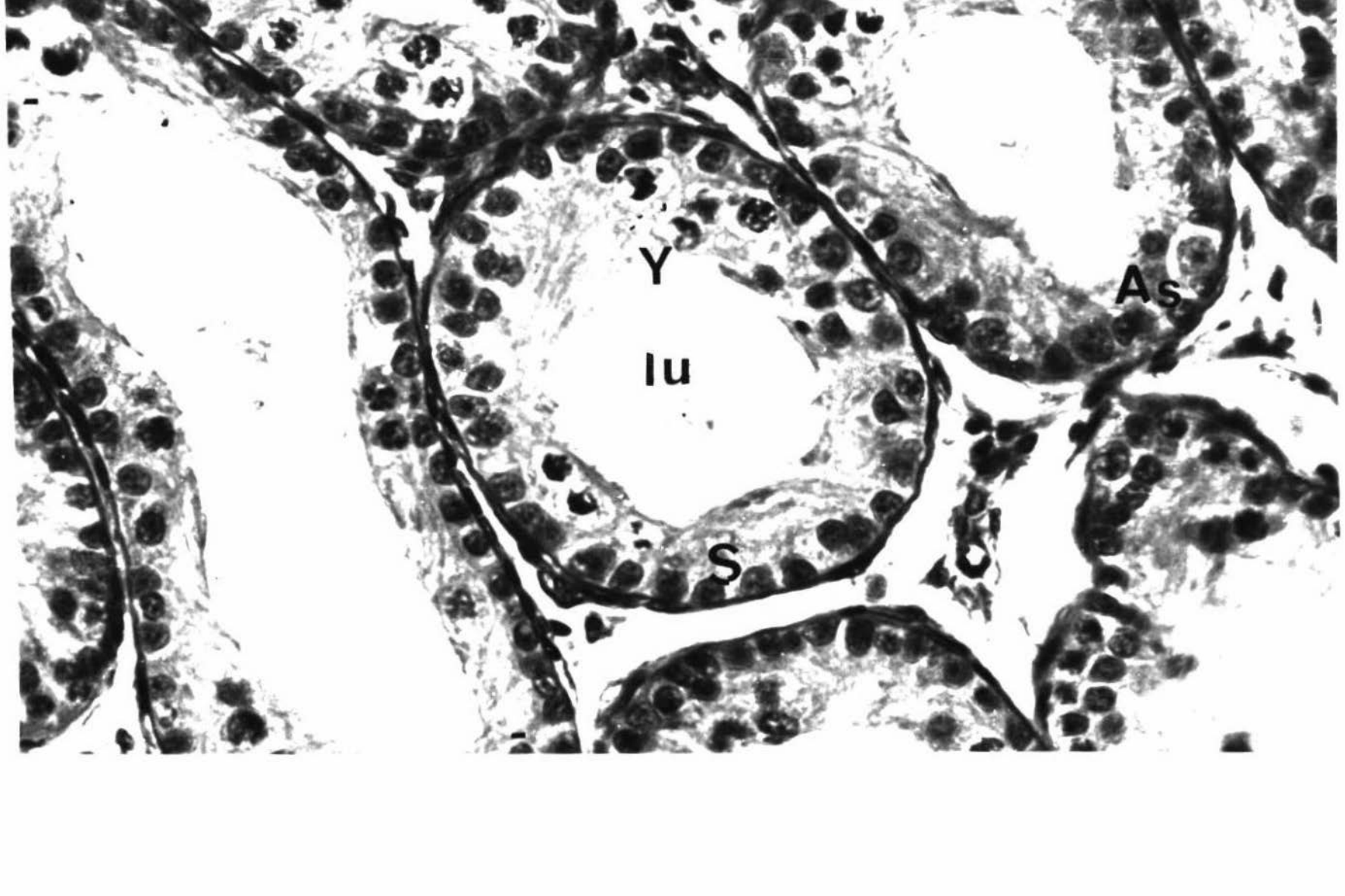
Y
As
lu
S

FIGURE 24: Testis of a 99-day lamb. H. & E. stain. x 320.

Seminiferous tubule with central lumen (lu).

Y, younger primary spermatocyte.

O, older primary spermatocyte.

R, round spermatids.

se, Sertoli cell nucleus.

FIGURE 25: Testis of a 136-day lamb. H. & E. stain. x 320.

As, A-type spermatogonium.

Y, younger primary spermatocyte.

R, round spermatids.

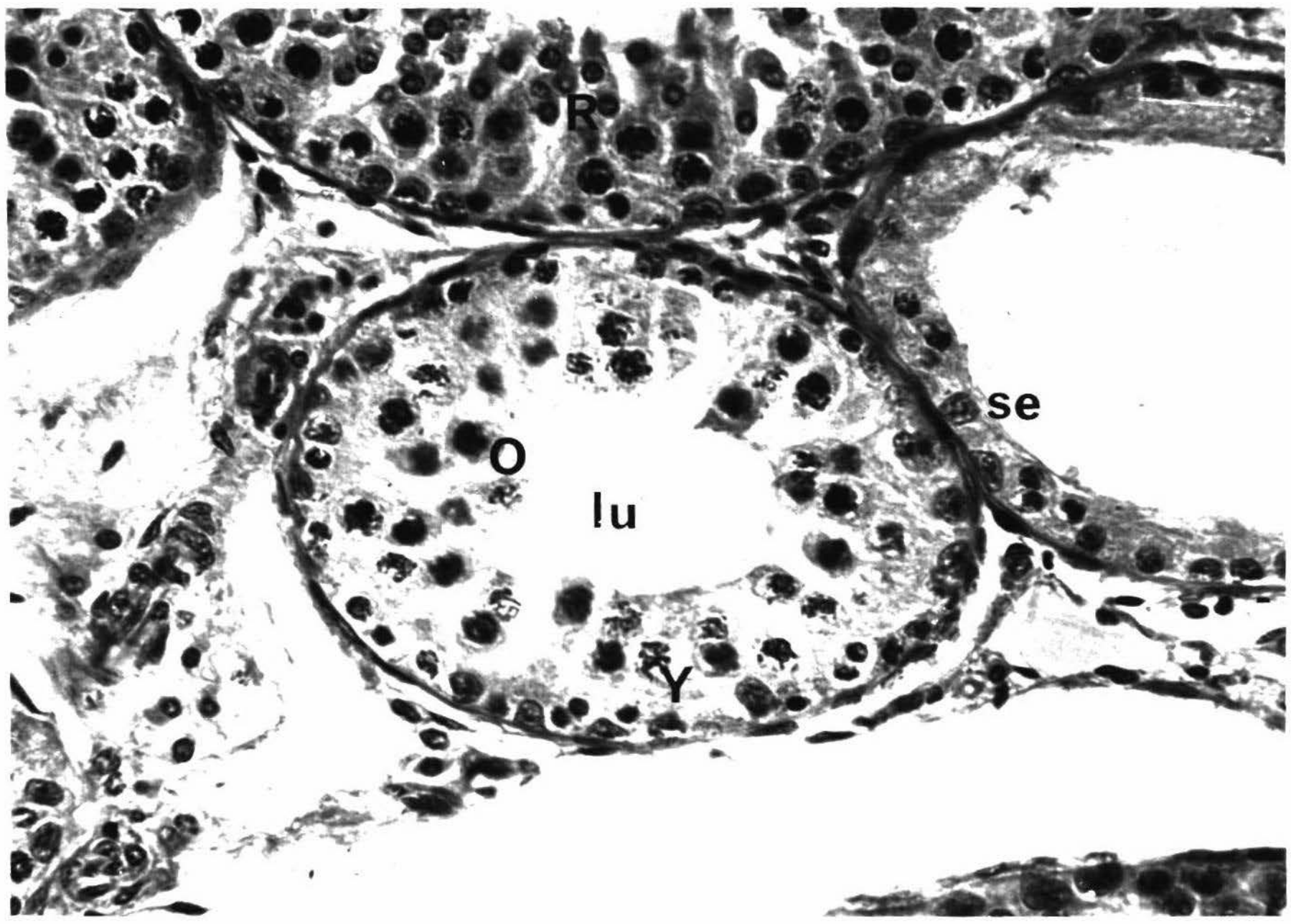
R
se
O
lu
Y

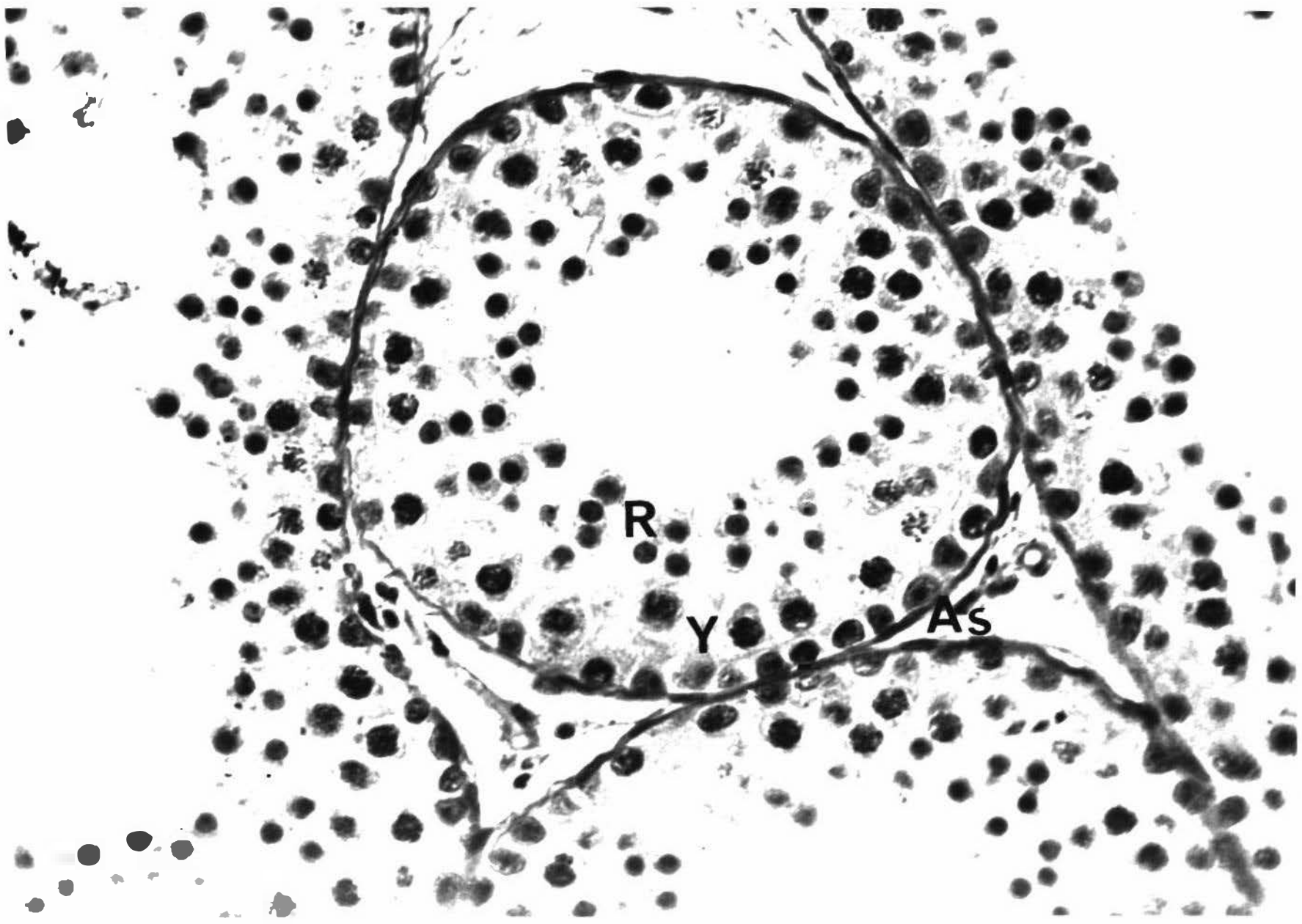
R
Y
As

FIGURE 26: Testis of a 154-day lamb. H. & E. stain. x 320.

As, A-type spermatogonium.

O, older primary spermatocyte.

E, elongate spermatids.

se, Sertoli cell nuclei.

FIGURE 27: Testis of a 252-day lamb. H. & E. stain. x 320.

Seminiferous tubule at completion of cycle of spermatogenesis.

R, round spermatids.

Z, immature spermatozoa.

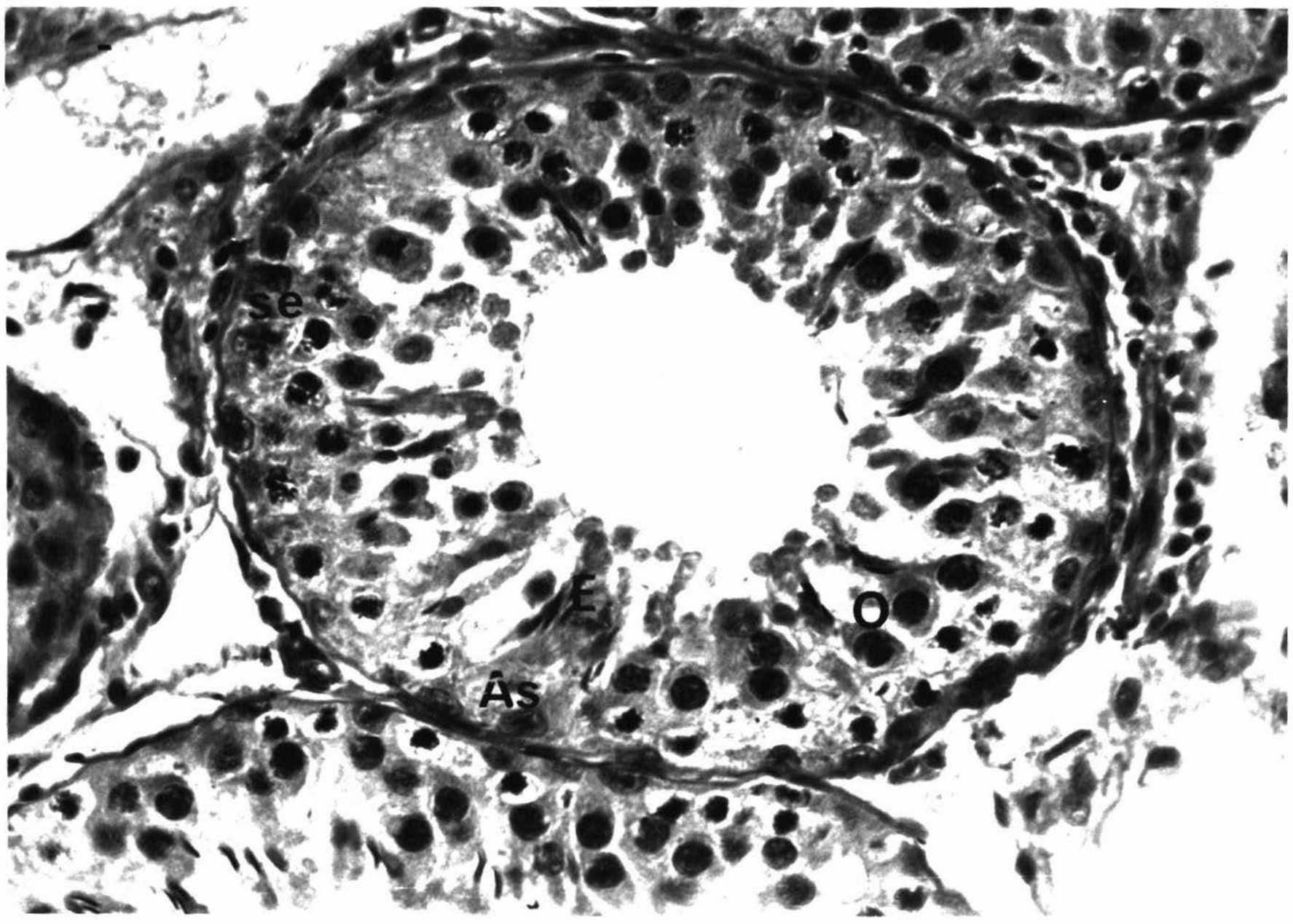
se
E
O
Âs

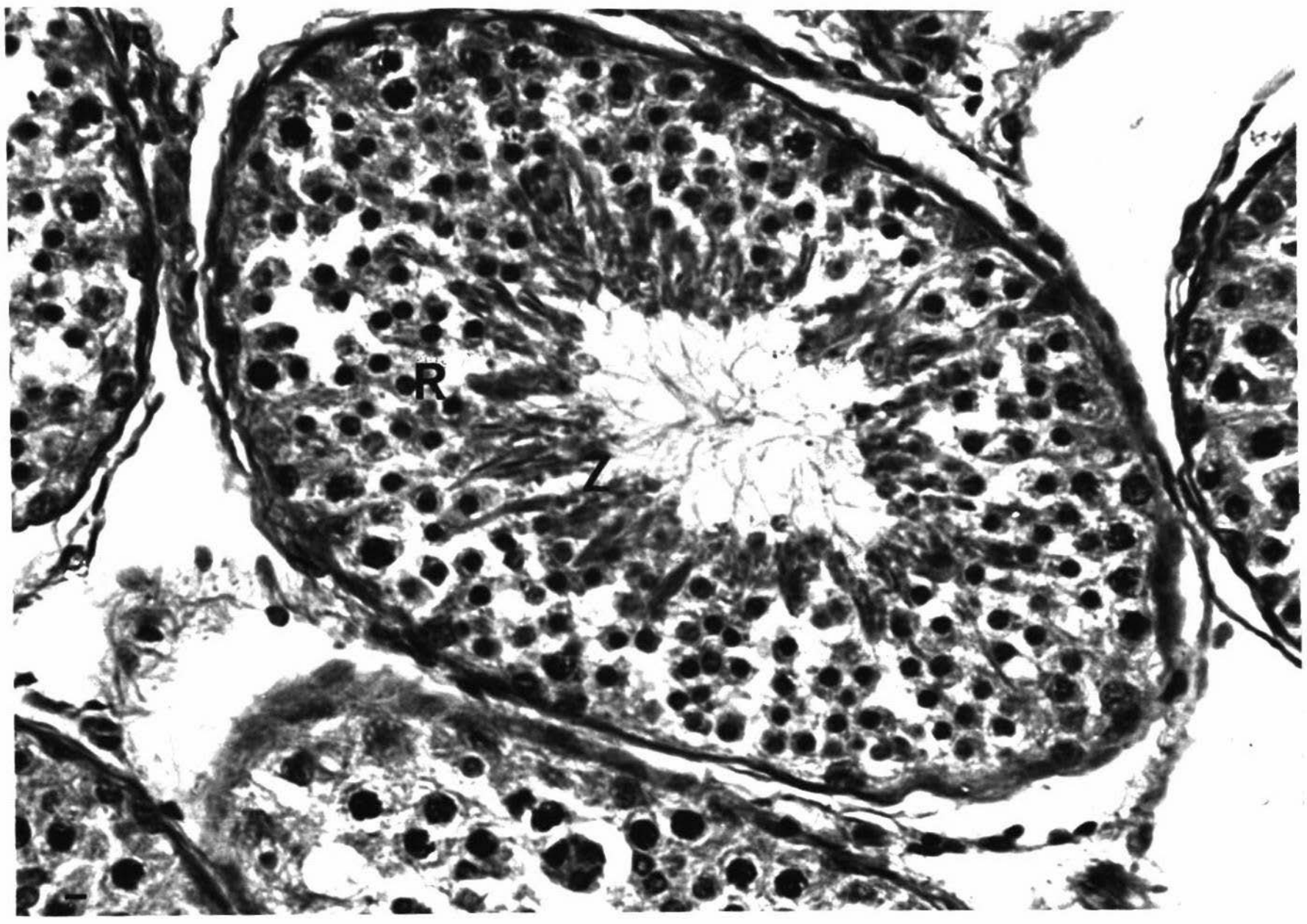
R
Z

FIGURE 28: Sex cords in testis of a 77-day foetus.

H. & E. stain. x 500.

G, Gonocyte.

S, Nuclei of supporting cells.

I, interstitial cell.

FIGURE 29: Sex cord in testis of a 51-day foetus.

H. & E. stain. x 1125.

G, Gonocyte.

S, nuclei of supporting cells.

FIGURE 30: Gonocyte in testis of a 53-day foetus.

H. & E. stain. x 1125.

G, gonocyte with coarse intranuclear inclusions.

S, nuclei of supporting cells.

FIGURE 31: Mature gonocyte (G) in testis of a 40-day lamb. H. & E. stain. x 1125.

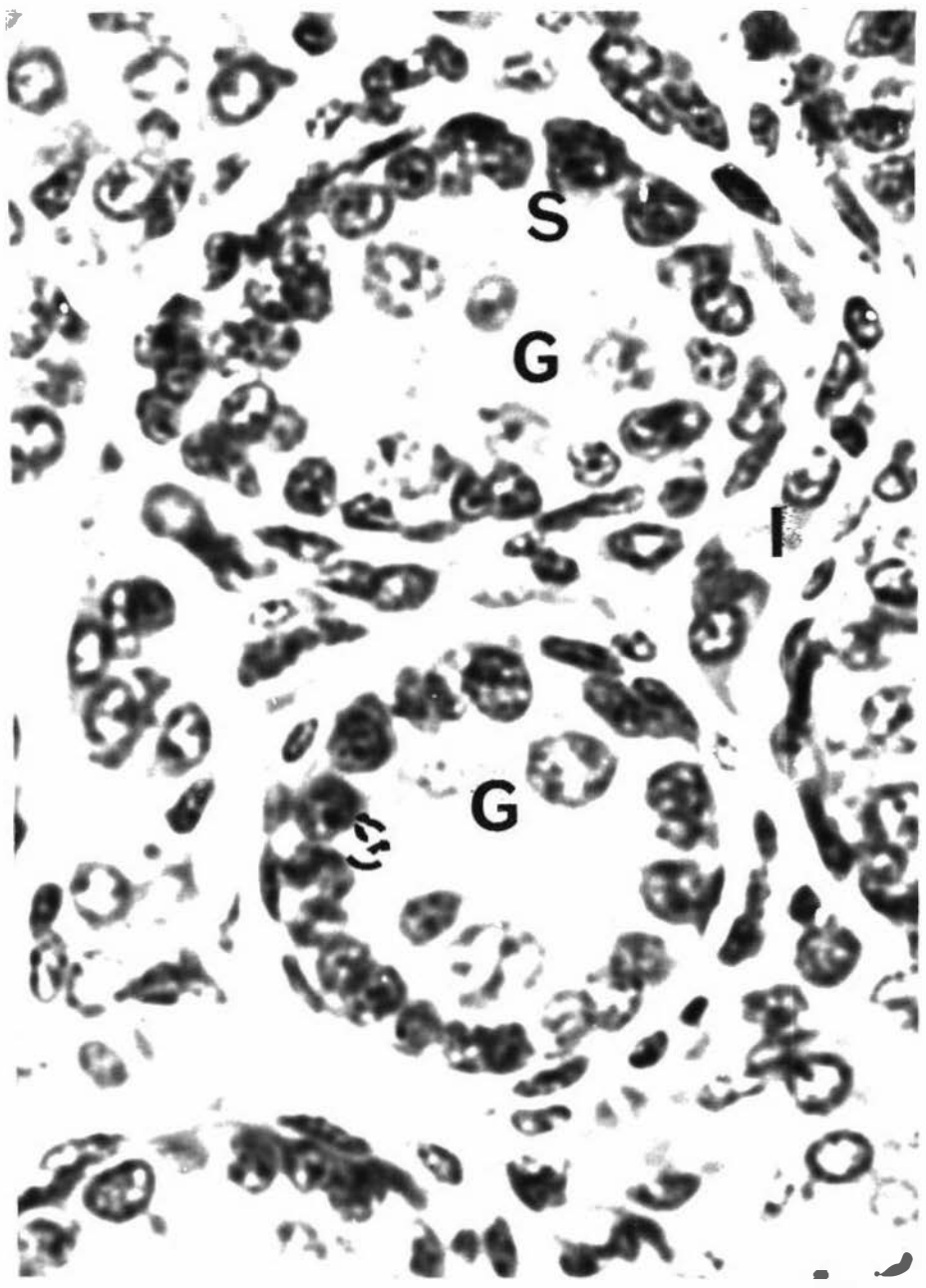

28

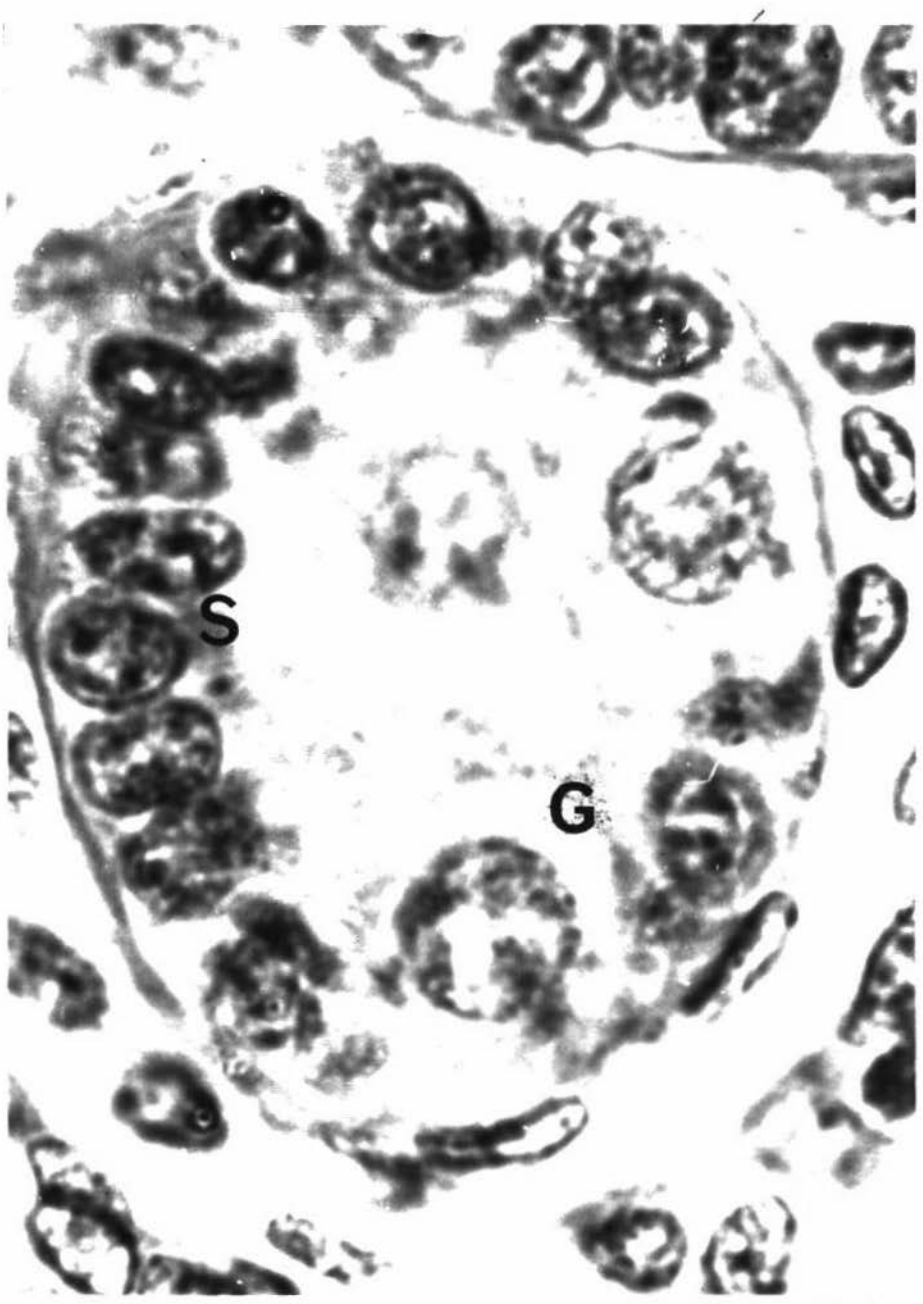

29

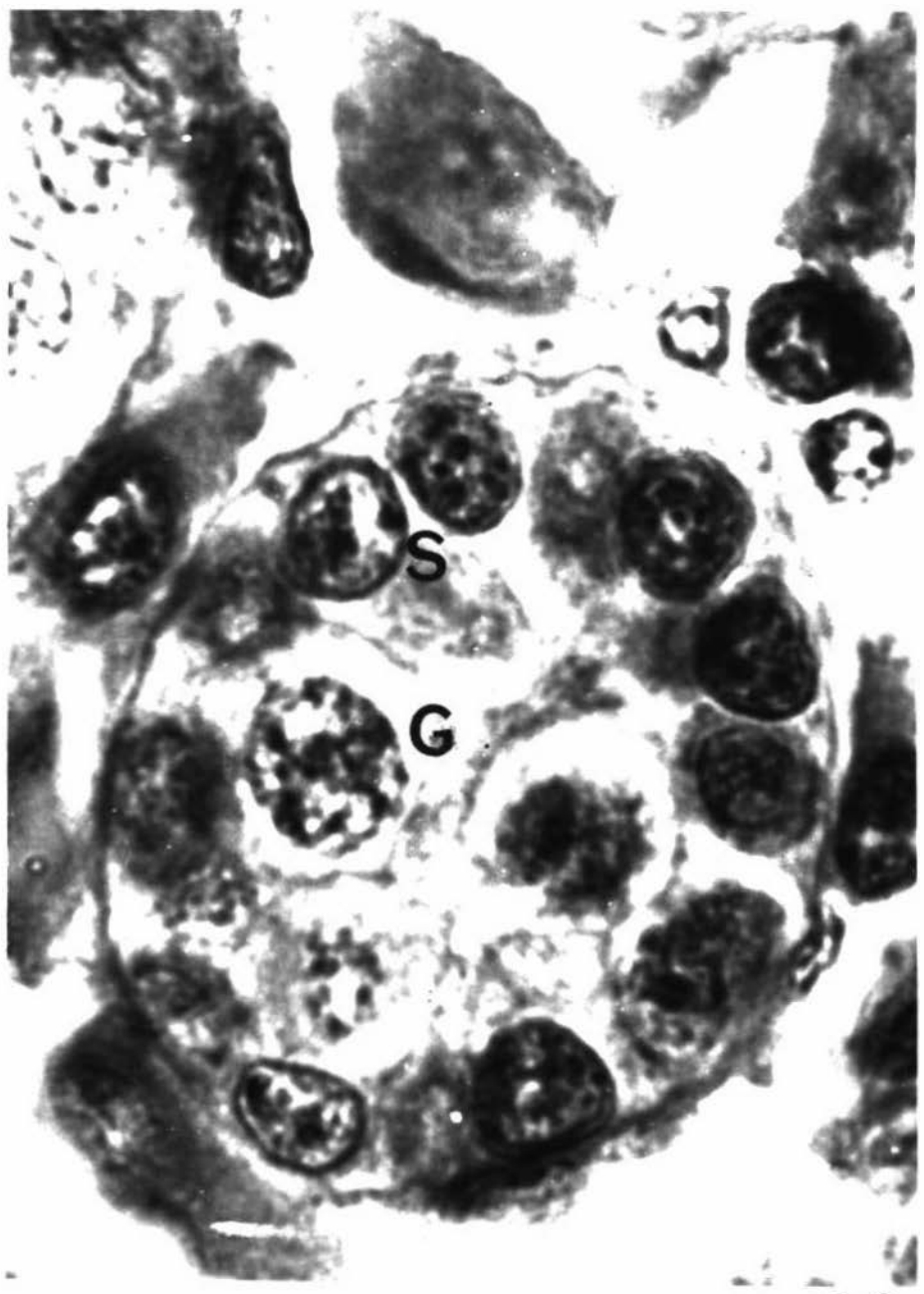

30

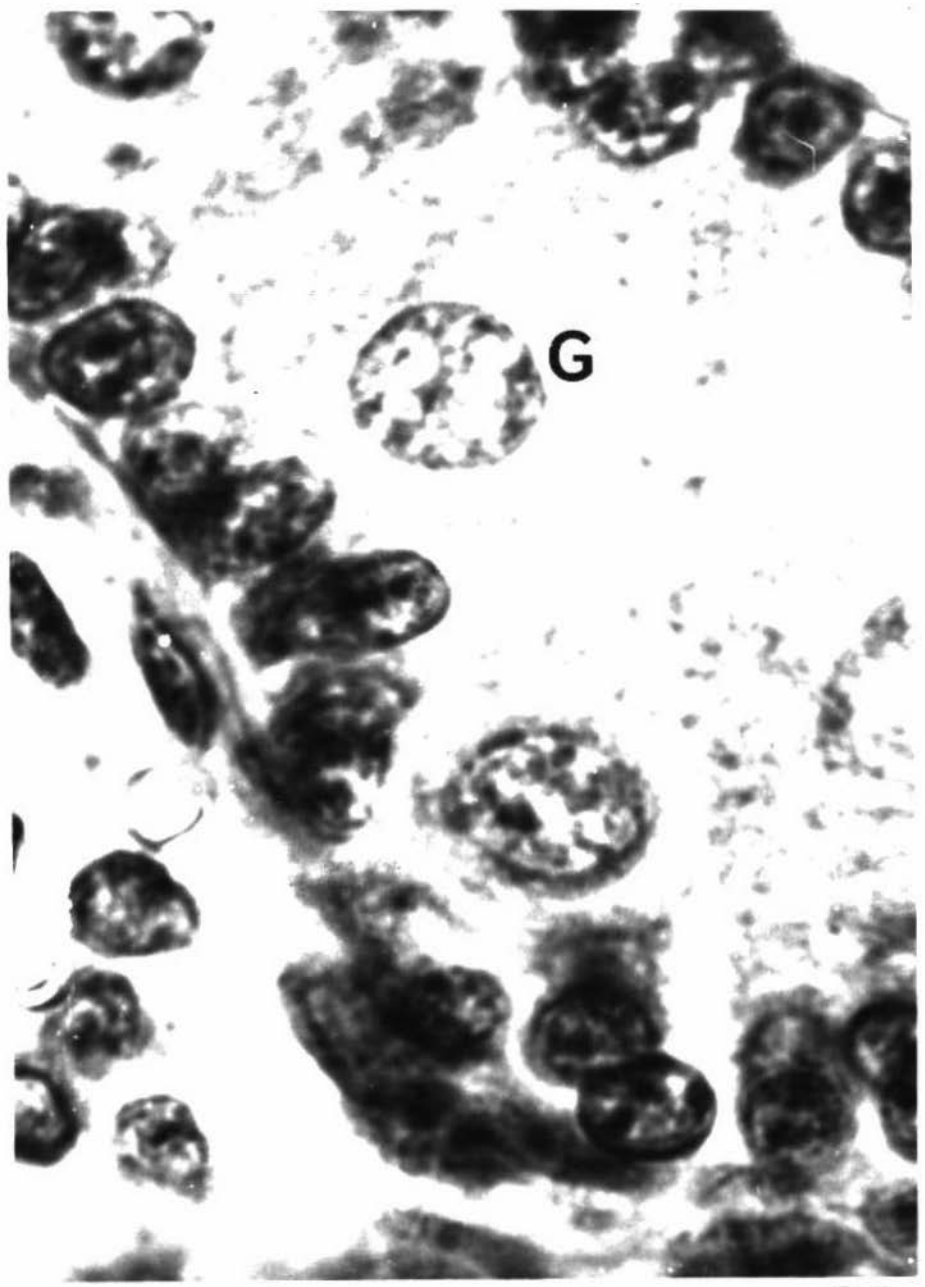

31

FIGURE 32: Prospermatogonium (P) in testis of a 66-day lamb. H. & E. stain. x 1125.

FIGURE 33: Prospermatogonia (P) in a stage of mitosis in testis of a 69-day lamb. H. & E. stain. x 1125.

FIGURE 34: A-type spermatogonium (As) in testis of a mature ram. H. & E. stain. x 1125.

FIGURE 35: B-type spermatogonium (Bs) in testis of a mature ram. H. & E. stain. x 1125.

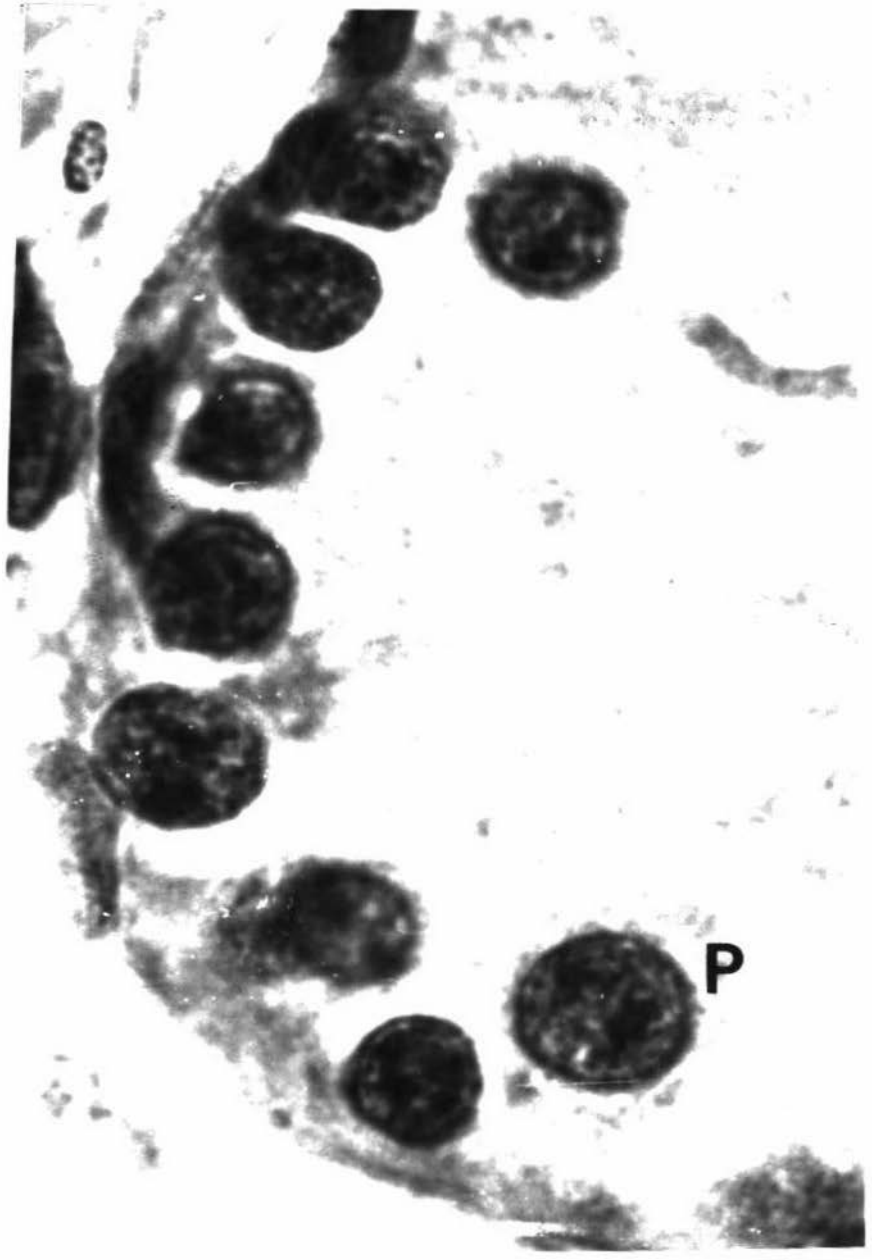

32

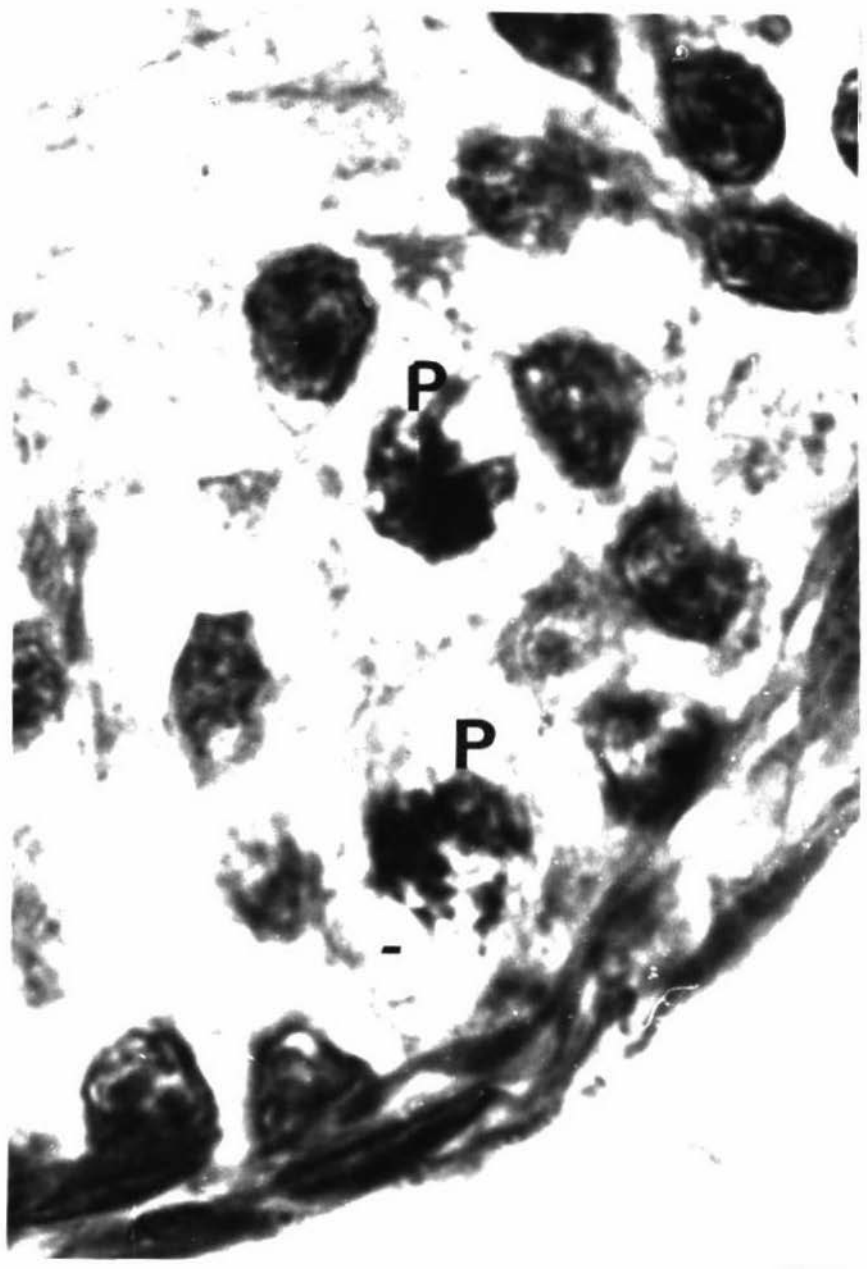

33

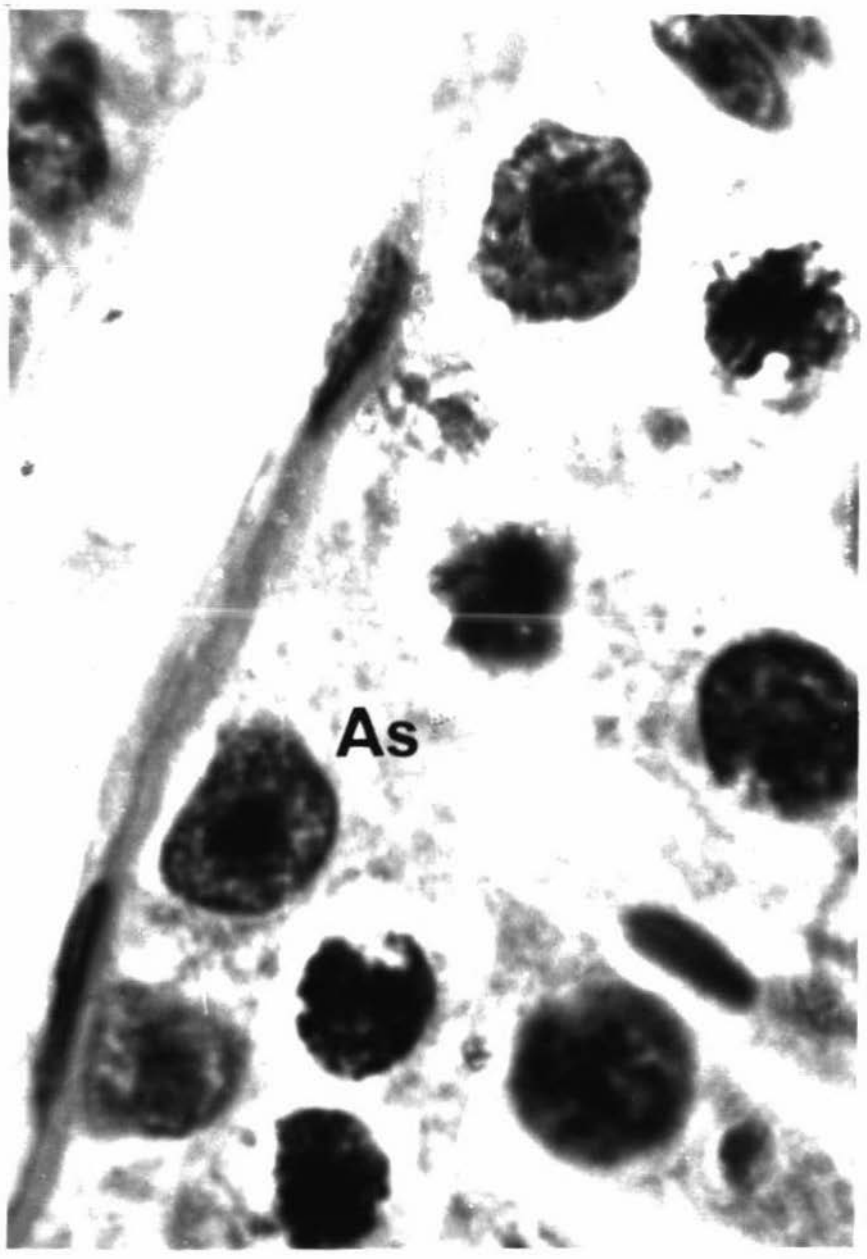

34

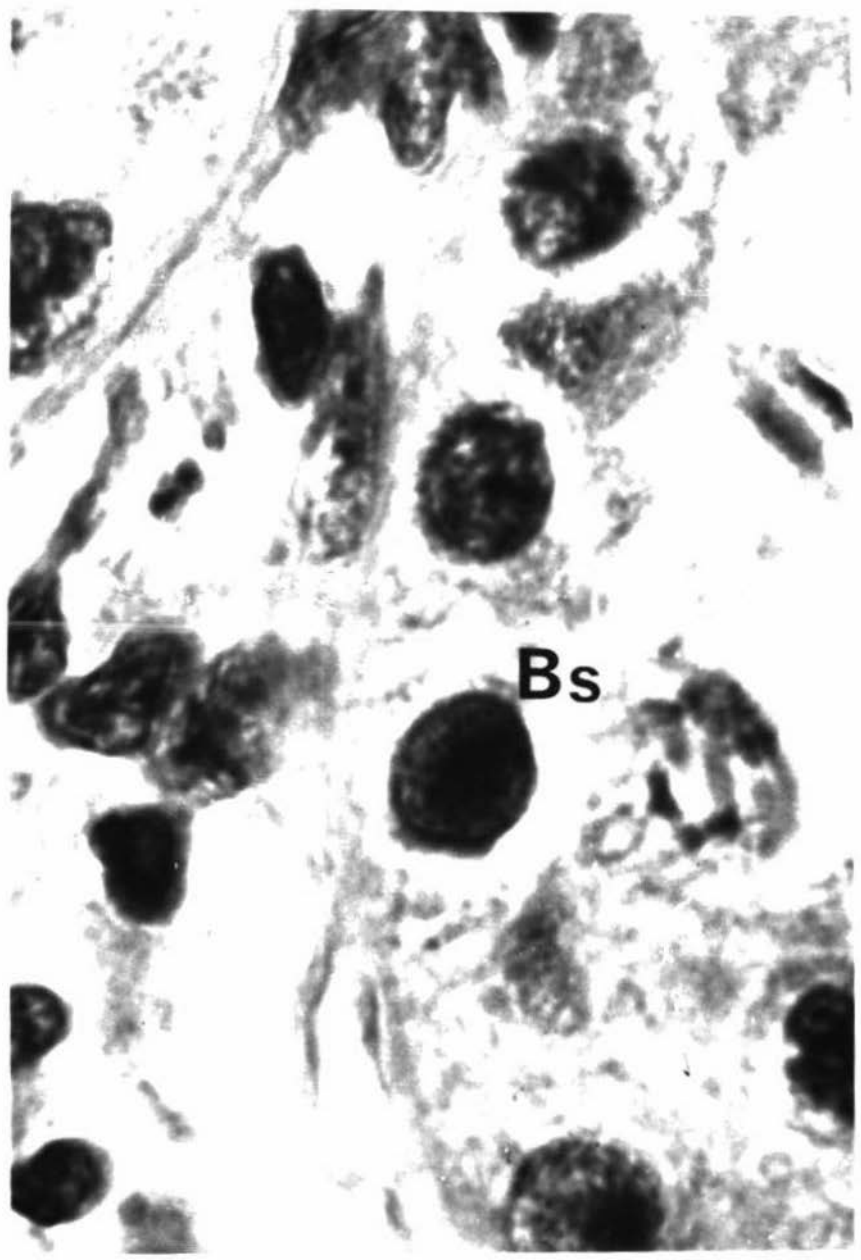

35

FIGURE 36: Primary spermatocytes in testis of a 84-day lamb. H. & E. stain. x 1125.

Y, younger primary spermatocytes.

O, older primary spermatocytes.

FIGURE 37: Primary and secondary spermatocytes in testis of a 136-day lamb. H. & E. stain. x 1125.

Y, younger primary spermatocyte.

S, secondary spermatocyte.

FIGURE 38: Round spermatids (R) in testis of a 154-day lamb. H. & E. stain. x 1125.

FIGURE 39: Elongate spermatids (E) in testis of a 154-day lamb. H. & E. stain. x 1125.

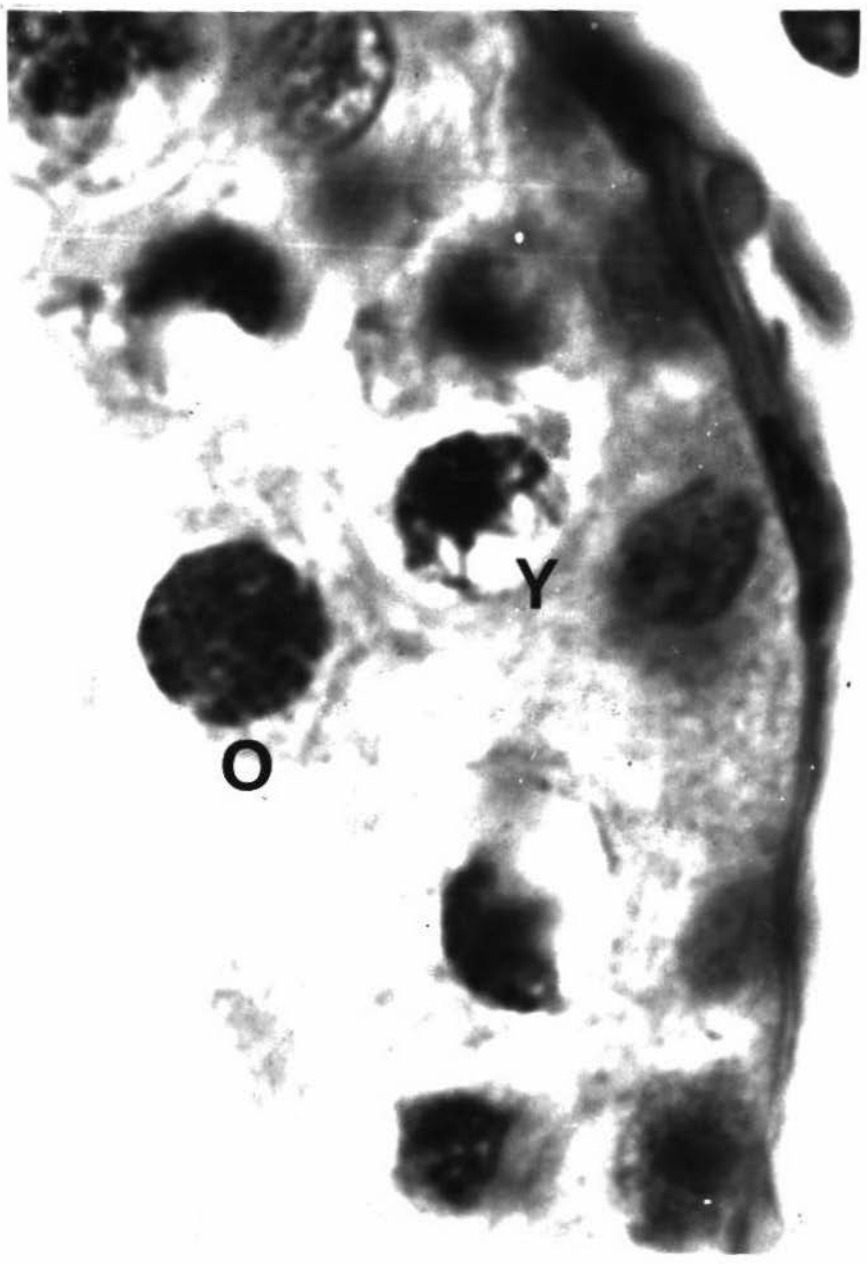

36

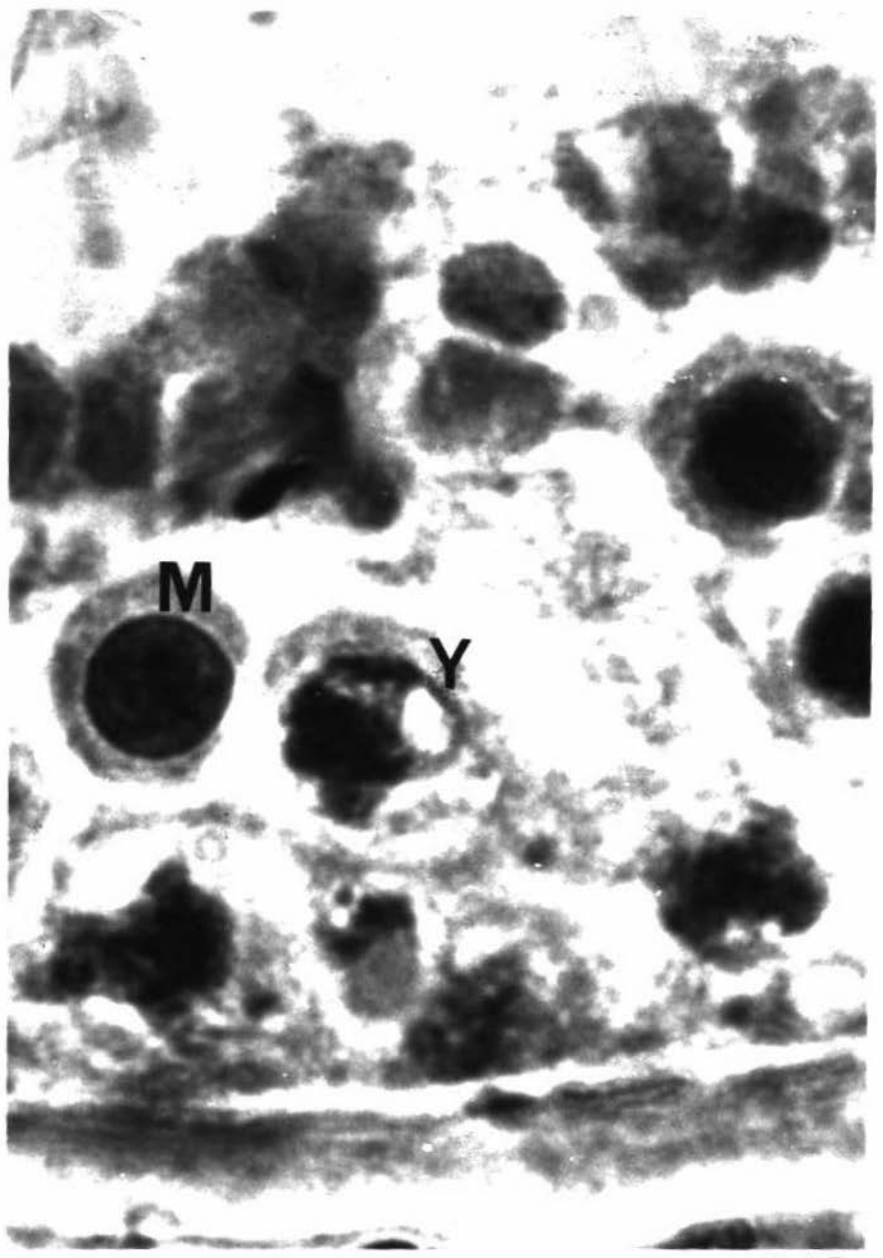

37

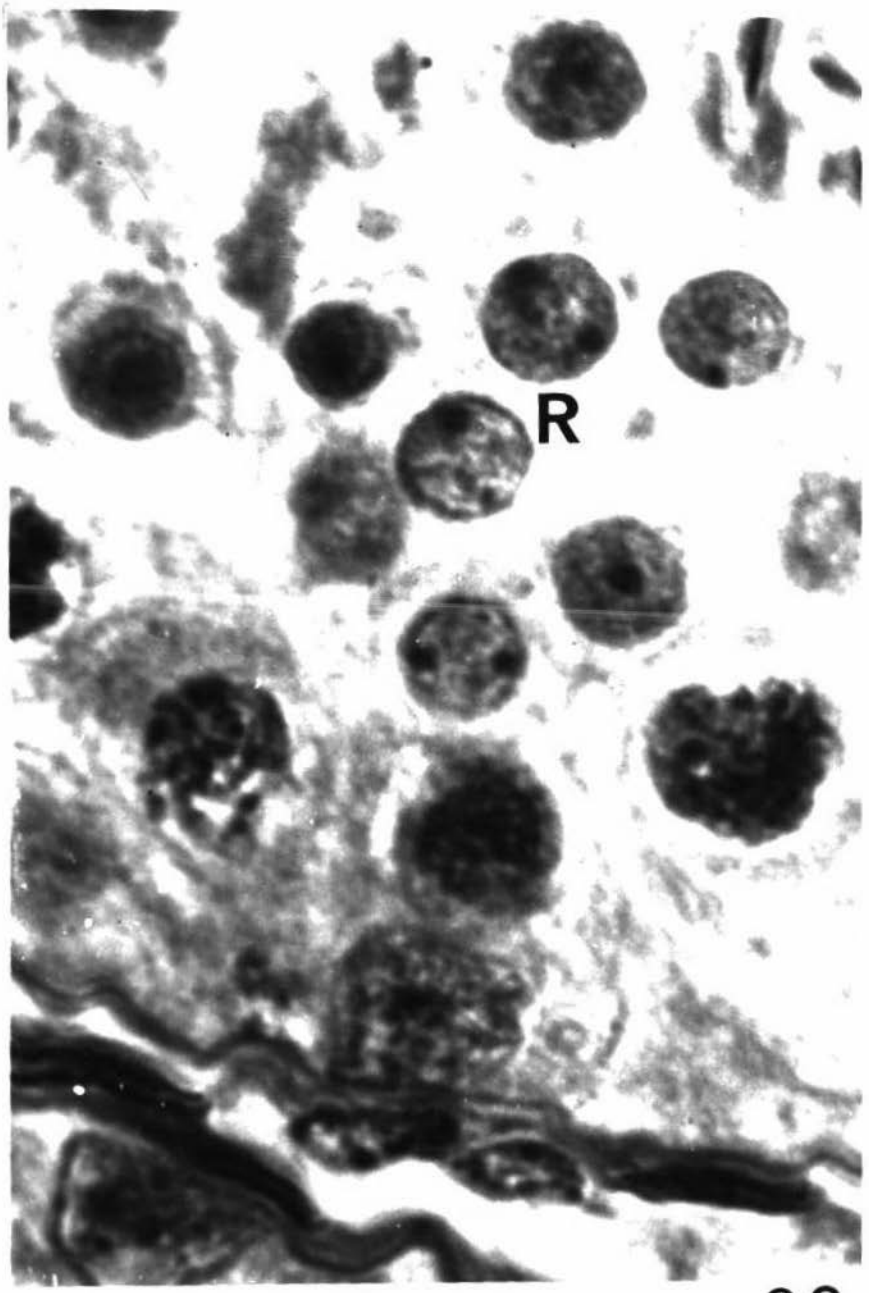

38

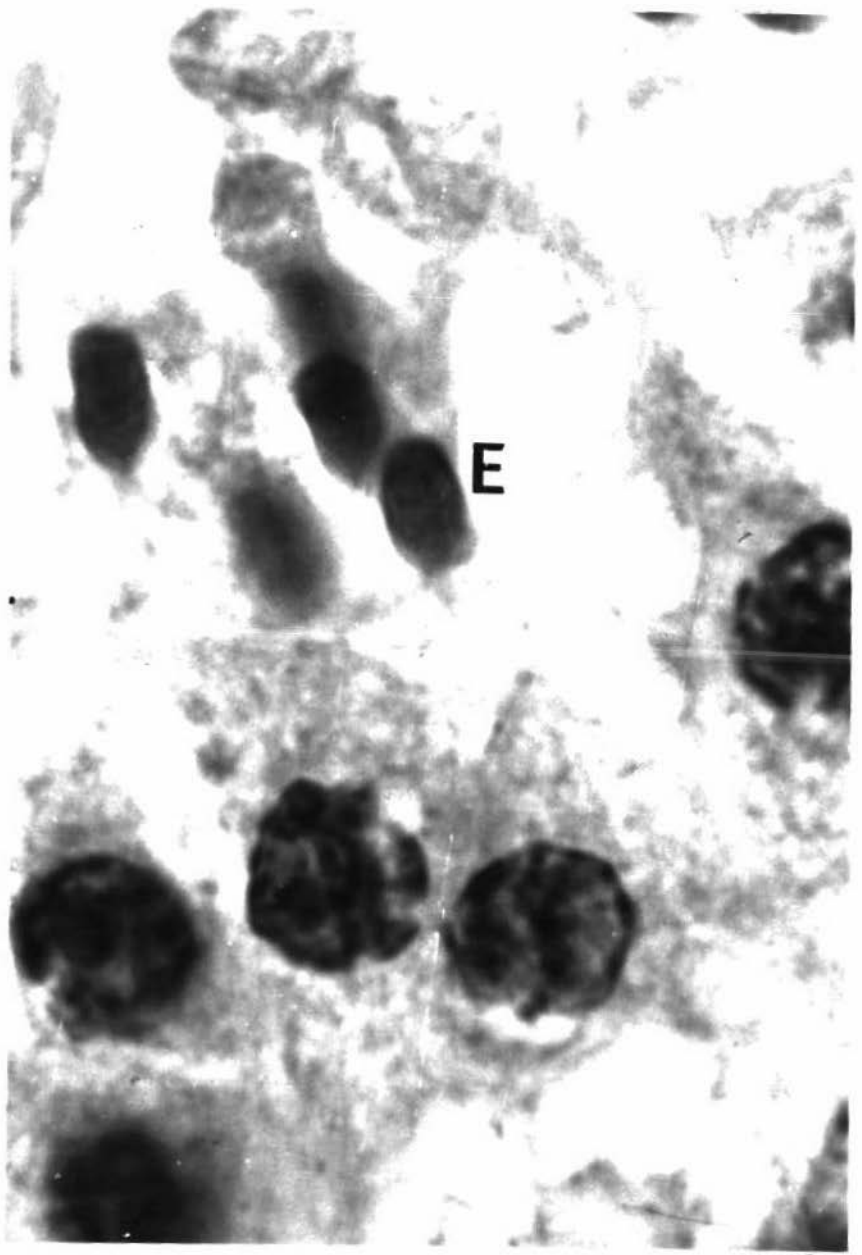

39

FIGURE 40: Multiple layers of supporting cell nuclei in testis of a 69-day lamb. H. & E. stain. x 320.

FIGURE 41: Supporting cell nuclei (S) in testis of a 70-day lamb. H. & E. stain. x 1125.

FIGURE 42: Supporting cell nucleus (S) and A-type spermatogonium (As) in testis of a 69-day lamb. H. & E. stain. x 1125.

FIGURE 43: Sertoli cell nuclei (Se) and elongate spermatids (E) in testis of a mature ram. H. & E. stain. x 1125.

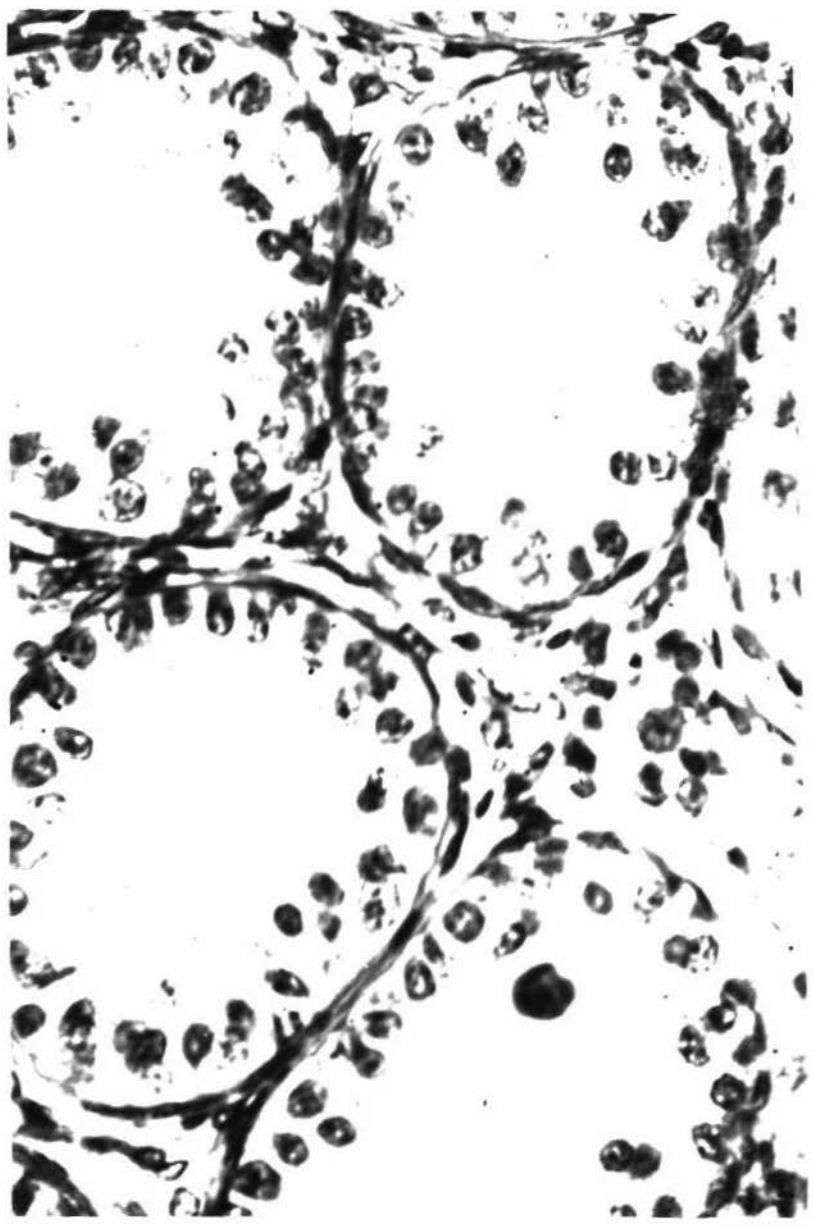

40

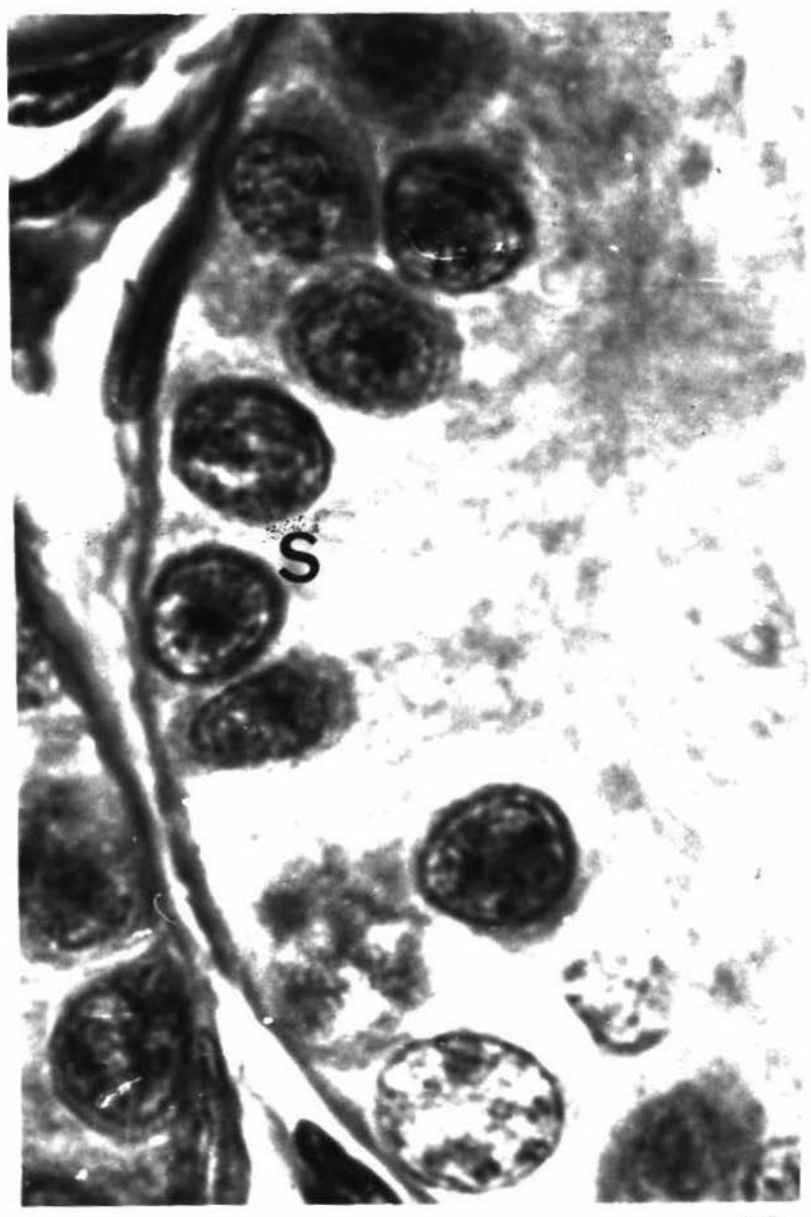

41

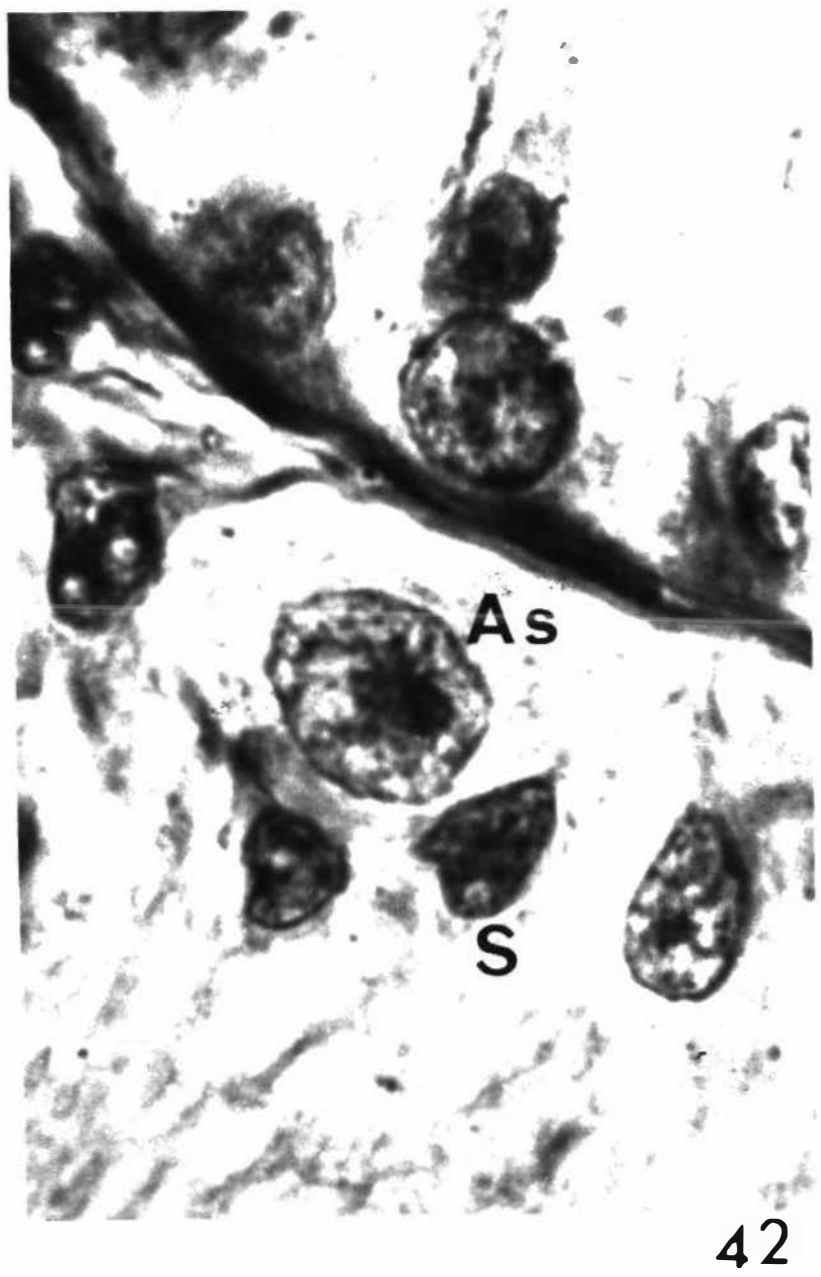

42

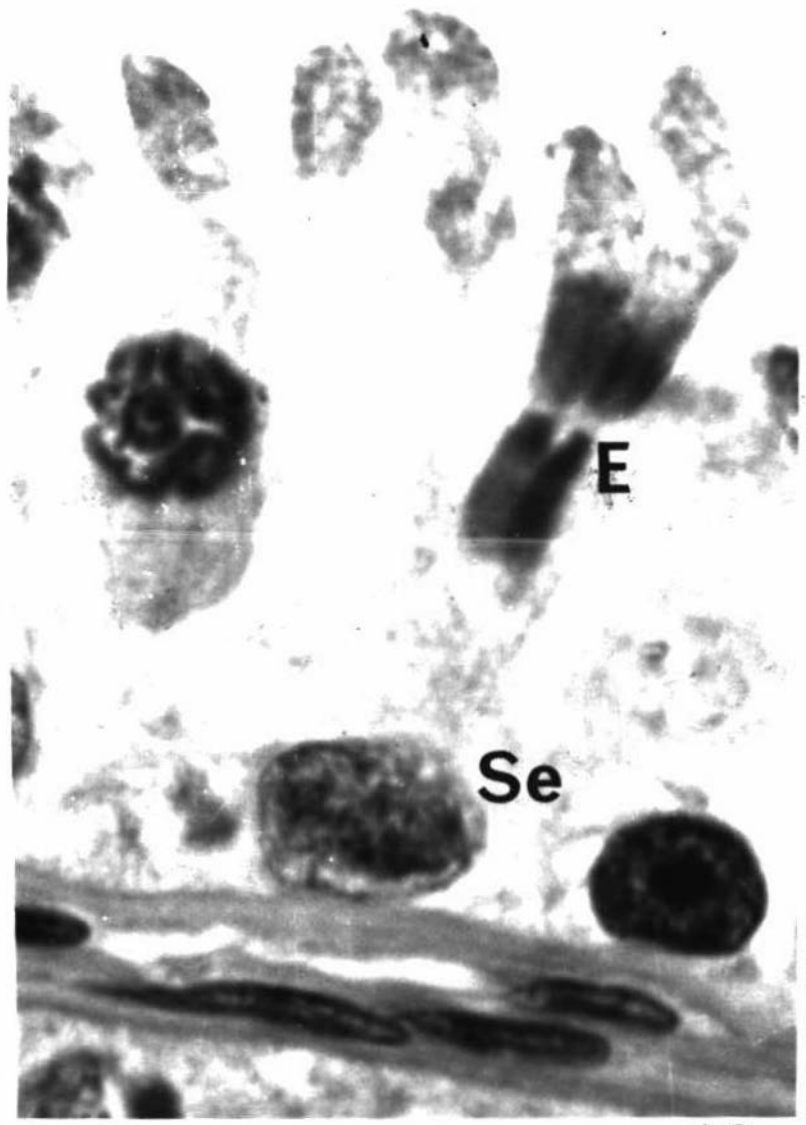

43

THE DEVELOPMENT OF THE BOUNDARY TISSUE OF THE SEMINIFEROUS TUBULE IN THE RAM

Review of Literature

Earlier reports on the fine structure of the mammalian testes described the boundary tissue of the seminiferous tubules as consisting of a basement membrane, and an outer layer of cellular and non-cellular connective tissue, or tunica propria (Nelson and Heller, 1945; Sniffen, 1950; Mancini et al., 1952; Montagna, 1952a, 1952b; Balse et al., 1954; Balse et al., 1960). More recent investigations using the electron-microscope have revealed that this limiting tissue is composed of a number of definite layers. Detailed investigations of the rat testis describe four quite distinct layers; an inner non-cellular layer closely applied to the seminiferous epithelium, an inner cellular layer, an outer non-cellular layer and an outer cellular layer of connective tissue cells (Clermont, 1958; Brokelman, 1960; Lacy and Rotblat, 1960; Lacy, 1962, 1967; Leeson and Leeson, 1963). Although the general structure of the boundary tissue of the seminiferous tubule between species bears many similarities, some differences in the morphology appear to exist in the mouse (Baillie, 1964b; Gardner and Holyoke, 1964; Ross, 1967), the guinea pig and the chinchilla (Fawcett et al., 1969a; Fawcett et al., 1969b; Fawcett, 1970), the bull (Nicander et al., 1961), the ram (Lacy and Rose, 1964), and man (Montagna, 1952a, 1952b; Burgos, 1960; Lacy, 1962; Ross and Long, 1966; Straus and Kao, 1968).

In the ram, the inner non-cellular layer is relatively wide and consists of about fifteen parallel lamellae. It is separated from the inner cellular layer by a number of collagen and reticulin fibrils. The outer non-cellular layer between the two comparatively thin cellular layers contains many connective tissue fibrils (Lacy and Rose, 1964; Lacy, 1967; Setchell et al., 1969; Morris, 1971 - see Figs. 44 and 45).

Similarly, the inner non-cellular layer, or basement membrane in the bull consists of ten to fifteen lamellae (Nicander et al., 1961) with a number of knob-like infoldings on the innermost lamellae. These are not seen in the testes of some other domestic animals.

Using an electron-microscope in sections of human testis, Burgos (1960) described the presence of a series of lamellae penetrated by irregular invaginations from the seminiferous epithelium. Following the use of differential stains he suggested that the lamellae contained some fibres of elastic tissue.

Under the light microscope the cells of the inner cellular layer have similarities with the fibrocytes of the more peripheral outer cellular layer, but electron-microscope studies in the rat, mouse, guinea pig and man have demonstrated that a contractile type cell exists in this inner layer (Clermont, 1958; Lacy and Rotblat, 1960; Lacy, 1962; Leeson and Leeson, 1963; Baillie, 1964b; Gardner and Holyoke, 1964; Kormano and Niemi, 1966; Ross and Long, 1966; Ross, 1967; Straus and Kao, 1968; Fawcett et al., 1969a; Fawcett et al., 1969b; Fawcett et al., 1970). Roosen-Runge (1951) demonstrated contractions in the seminiferous tubules of the rat and dog, and suggested that this activity was caused by contractions and relaxation of the Sertoli cells, but Clermont (1958) was able to demonstrate physiologically that the wall of the seminiferous tubule contained contractile elements. These

FIGURE 44: Electronmicrograph of the boundary tissue of a seminiferous tubule from the testis of a ram (x 17,800).

Nu	Nucleus of cell within seminiferous tubule
Cy	Cytoplasm of cell within seminiferous tubule.
La	Inner non-cellular layer - lamellae.
Pc	Inner cellular layer - peritubular contractile cells.
Co	Outer non-cellular layer - collagen fibres.
Fc	Outer cellular layer - fibroblasts.

FIGURE 45: Electronmicrograph of the boundary tissue of a seminiferous tubule from the testis of a ram (x 5,500).

La	Inner non-cellular layer - lamellae.
Pc	Inner cellular layer - peritubular contractile cells.
Co	Outer non-cellular layer - collagen fibres.
Fc	Outer cellular layer - fibroblasts.

(Figures 44 and 45 kindly supplied by Professor B. Morris, Department of Immunology, John Curtin School of Medical Research, Australian National University, Canberra, Australia).

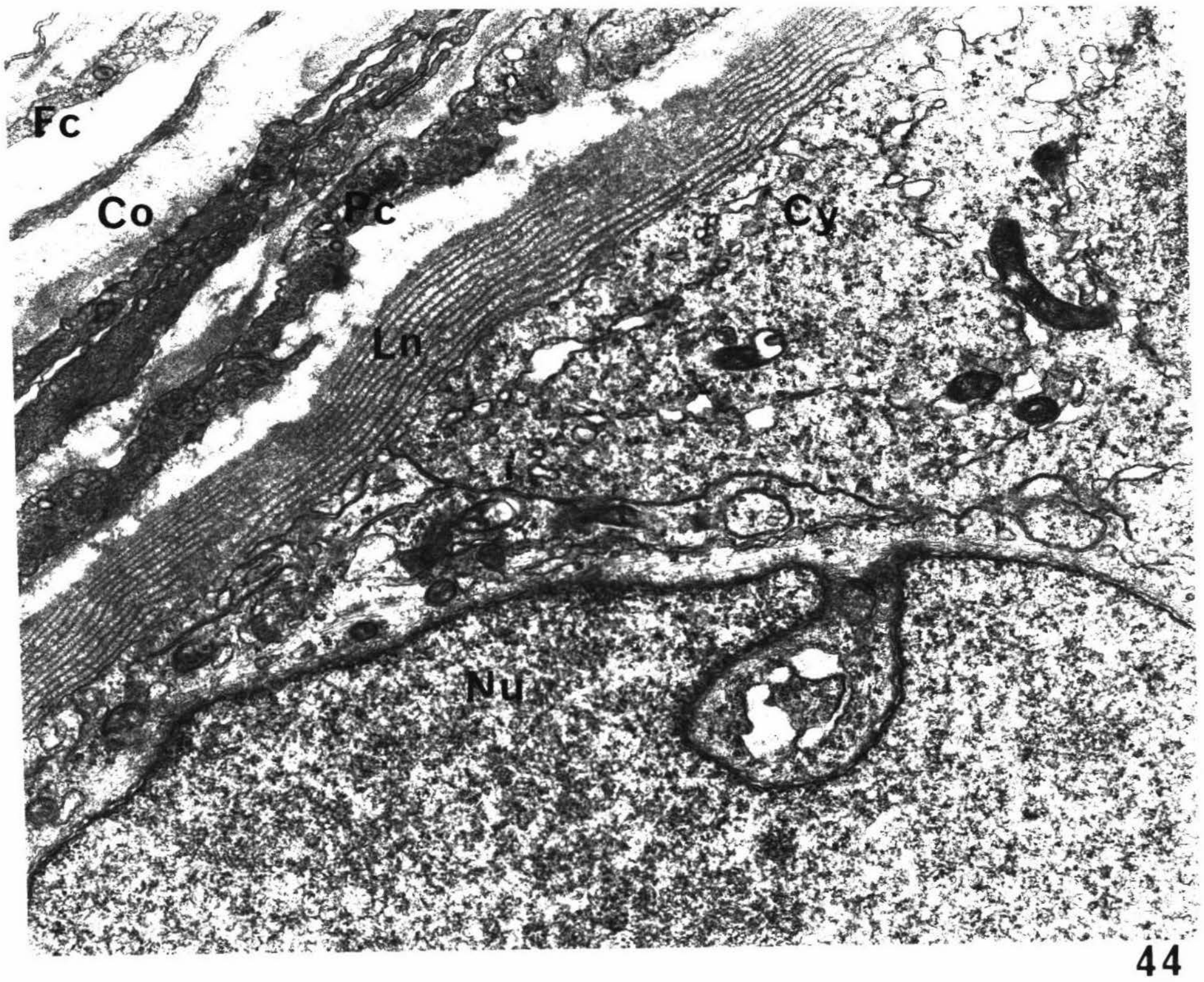

44

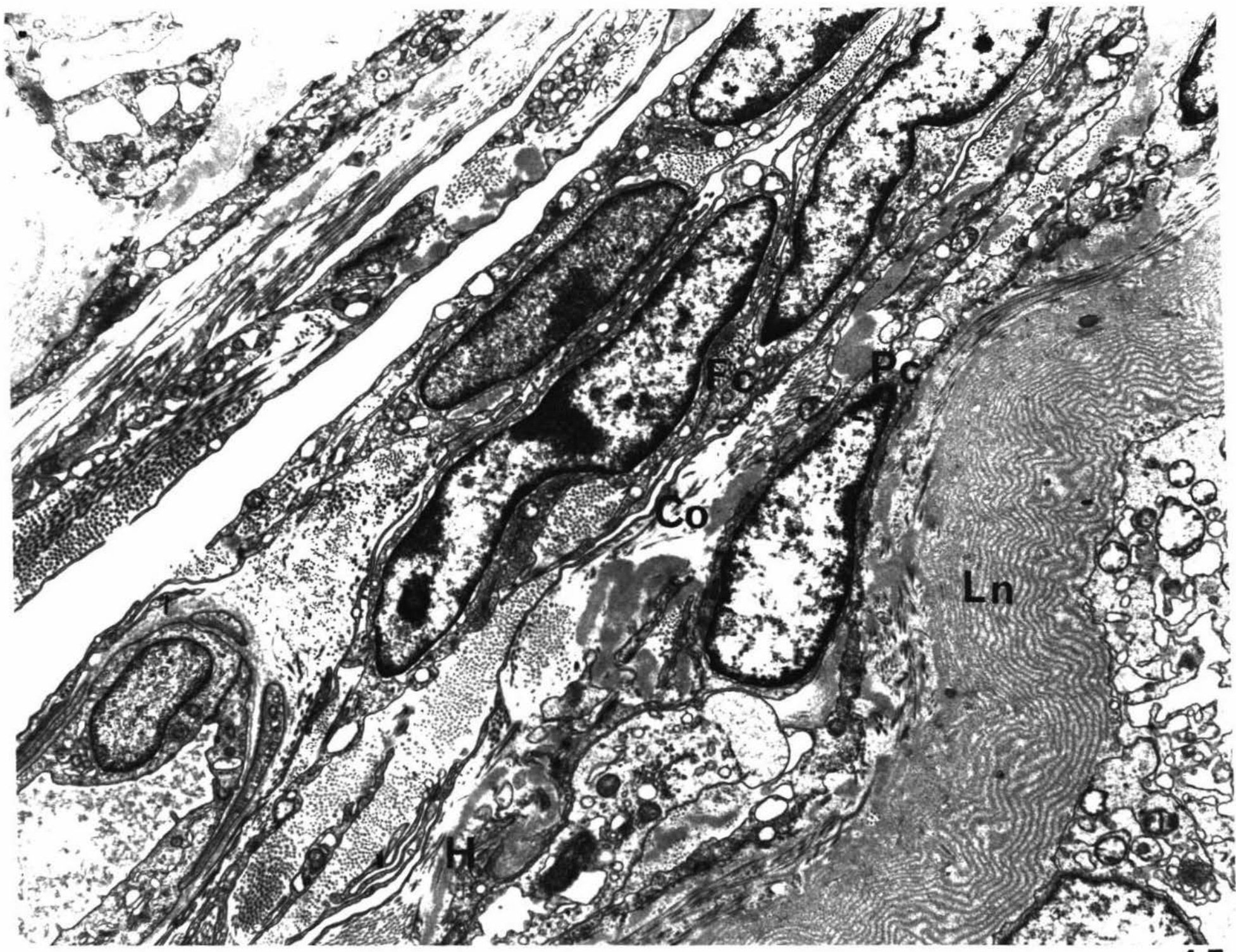

45

contractions could take place spontaneously at any stage of the cycle of the seminiferous epithelium (Suvanto and Kormano, 1968) and at the time the contractions first occurred no morphological alterations in the cells of the boundary tissue were apparent (Kormano and Niemi, 1966).

A definite pattern exists in the post natal development and differentiation of the boundary tissue of the seminiferous tubule. In the newborn rat and mouse this tissue appears as an indistinct mass of connective tissue cells and ill-defined basement membranes. During the puberal stages of growth the non-cellular and cellular layers become transformed to the definite structures seen in the adult. The inner non-cellular layer gradually thickens and the basement membrane becomes more distinct. A single layer of distinctive flattened cells with contractile elements differentiates next to this layer. At first the outer non-cellular layer is difficult to define but within a few days it has formed a definite barrier between the two cellular layers, enlarging and increasing in thickness as puberty is reached. The outer cellular layer is indefinite at birth, but the cytoplasmic processes of the cells become reduced as the cells elongate and in the mature state they have become clearly differentiated from the surrounding interstitial tissue (Baillie, 1962, 1964b; Leeson and Leeson, 1963; Ross, 1967). Development of the tubular wall in the human testis is similar. A homogeneous band-like tissue is seen before puberty and it does not differentiate until spermatogenesis commences. As puberty progresses the tubular wall thickens, particularly the outer non-cellular layer. The older cells become thinner, and the less mature rounder forms are found only in the peripheral layers (Sniffen, 1950;

Mancini et al., 1952; Balze et al., 1960). In the young calf of five and a half months of age the basement membrane has become reduced in thickness from about 1.5 microns at birth to about 0.5 microns. This is concurrent with the celluler differentiation of the seminiferous tubules (Nicander et al., 1961).

The elastic fibres in the tunica propria of the tubular wall of the human testis have been described by Nelson and Heller (1945), Sniffen (1950), Mancini et al. (1952), Balze et al. (1954), Balze et al. (1960), and Ross and Long (1966). They are absent in the newborn child, make their appearance during puberty (Sniffen, 1950; Balze et al., 1954; Balze et al., 1960) and increase in number and thickness in old age (Sniffen, 1950; Balze et al., 1954).

Elastic fibres are one of the two main types of fibrous tissue of the interstitial connective tissue and consist of protein elastin. Although they are difficult to distinguish morphologically they do stain characteristically with orcein and resorcin-fuchsin stains. Elastic tissue can be identified also by the use of enzymes called elastinases. The action of the latter depend on the site of the elastic tissue in the body (Balo and Banga, 1950).

Balze et al. (1954) showed that elastic fibres appeared simultaneously with the development of the germ cells, Sertoli cells and the mature Leydig cells. It was shown also that these fibres ran in different directions, some encircling and others extending along the seminiferous tubule. Changes in these elastic fibres are known to occur in various pathological conditions of man (Howard et al., 1950; Sniffen et al., 1950; Balze et al., 1954; Lacy, 1962). It is possible also that the state of elastic tissue determines whether or not some changes of testicular tissue have occurred before or after puberty (Balze et al., 1954). Elastic fibres in the boundary tissue of the seminiferous tubule have not been described in other species (Lacy and Rotblat, 1960) and no mention has been made previously of their existence in the boundary tissue of the seminiferous tubule in the ram testis.

Methods Used to Examine Boundary Tissue

The structure of the boundary tissue and in particular, the presence and the nature of elastic tissue within the boundary tissue, was investigated. Fibres were considered to be elastic tissue when they were seen to be homogeneous and take a dark blue-black stain with Weigert's resorcin-fuchsin stain, or a deep purple to violet stain with the fuchsin stain, or a deep purple stain with Gomori's aldehyde fuchsin stain (see Appendices I, II and III). The fibrillar characteristics of elastic fibres, as described for the human testis by Mancini et al. (1952) and Balze et al. (1954) were difficult to distinguish in the ram. The elastic tissue of the blood vessels, tunica albuginea or other components of the testis were not investigated.

Observations

a. General

In the ram the boundary tissue of the seminiferous tubules appeared at the same time as the sex cords were differentiating (Fig. 46). It underwent two phases of development which corresponded to the previously described prepuberal and maturation developmental phase of the seminiferous tubule. Development was gradual and very little differentiation of the components which were subsequently seen in the adult testis took place until after birth (Figs. 47, 48 and 49). The presence of a number of non-cellular and cellular layers were seen as the testis weight increased beyond 7.5 G (Fig. 51) and the characteristics of the mature testis were apparent during the maturation phase (Figs. 52 and 53).

b. Changes in the Prepuberal Phase

In the 53-day foetus the boundary tissue of the sex cord appeared as a definite, thin and homogeneous layer in contact with relatively few cells of the interstitial tissue (see Fig. 47 as an example). Until this stage the sex cord was not defined clearly and the boundary tissue was seen as a few irregular broken strands (Fig. 46). The tissue gradually thickened throughout the prepuberal phase (Fig. 48 and 49).

The basement membrane or inner non-cellular layer was arranged as a band-like homogeneous tissue, which gradually doubled in size in the period between 60 days and birth. It remained at its greatest width until the testis weighed 7.5 G at about 60 days of life (Figs. 50 and 51). From this point the inner non-cellular layer became thinner, as a distinctive outer layer became evident (Fig. 51).

The outer layer of the boundary tissue consisted of a number of connective tissue cells. These were in close contact with the other cells of the interstitial tissues and during foetal life were indistinguishable from them (Fig. 48). The connective tissue cells varied in appearance from one type with a round or oval nucleus containing few granules to another type with a very narrow elongated nucleus. From birth a number of these cells became arranged about the boundaries of the sex cords, in some instances overlapping each other to suggest a loosely layered formation (Fig. 49). During the remainder of the prepuberal phase a greater number of cells with narrow elongated nuclei came in closer contact with the tubular wall and appeared to become integrated as part of the boundary tissue. This was more pronounced in the 7.5 G testis and was concurrent with the appearance of an outer non-cellular layer and a distinct outer cellular layer (Fig. 51). In the inner cellular layer, the only connective tissue cells present had narrow elongated nuclei. By contrast, the outer cellular layer consisted of a number of cells of varying types. Cells containing the more rounded nuclei were present in the outer limits of the boundary tissue (Figs. 50 and 51). The outer non-cellular layer was initially an indistinct and fine fibrillar structure appearing at the transitional period near the end of the prepuberal phase of development (Fig. 51).

Fibres of elastic tissue appeared in the non-cellular layer of the boundary tissue soon after differentiation of the sex cords (Fig. 54). Initially, they were sparse and irregular, but became a constant constituent in the testis of the 100 day old foetus and older (Fig. 55). The elastic fibres took the elastic stains and appeared as homogeneous tissue occupying the whole of the inner non-cellular layer of the boundary tissue. As this layer thickened with the growth of the testis there was a concurrent increase of the elastic tissue.

Elastic tissue fibres appeared in the outer non-cellular layer of the boundary tissue at the time the layer was first recognised as a separate component. Initially the elastic fibres were sparse and irregularly placed within this tissue, and remained as thin fibres but stained more distinctly at the change from the prepuberal to the maturation phase (Figs. 56 and 57).

c. Changes in the Maturation Phase

The boundary tissue differentiated into the four distinct layers, two non-cellular and two cellular layers, during the transition to the maturation phase. Throughout this phase and in the young adult ram, increase in the thickness of the boundary tissue was gradual and continuous until full maturity was reached (Figs. 52 and 53).

The inner non-cellular layer showed little change or variation in thickness and it would appear that its adult size was reached early.

The outer non-cellular layer was initially a fine but then distinct layer between the two cellular layers of the boundary tissue. As the testis size increased from 14 G to 65 G this layer thickened rapidly to achieve adult proportions about the time spermatozoa were released (Fig. 53).

The inner cellular layer was clearly differentiated between the two non-cellular layers of the boundary tissue and morphologically appeared similar to that of the adult. Its cells with elongated narrow nuclei were spaced in a single layer around the seminiferous tubule (Figs. 52 and 53) and occasionally the cells appeared to overlap.

The outer cellular layer had less rigidly defined boundaries depending to some extent on the amount of contact between adjacent seminiferous tubules. Cells with elongated nuclei, similar to those seen in the inner cellular layer, predominated but a number of cells with oval nuclei were also present in a single layer or occasional multiple layers about the outer perimeter (Fig. 53).

Fibres of elastic tissue appeared to be dispersed evenly within the inner non-cellular layer. They stained as a homogeneous mass and were present throughout the maturation phase to maturity (Figs. 58 and 59). In a similar manner the outer non-cellular layer of the boundary tissue and the elastic tissue fibres within it grew at the same rate. The increases were rapid as the testis grew to a weight of 65 G, but thereafter the rate of increase was very much slower (Figs. 58 and 59).

Discussion

In the course of maturation the boundary tissue of the seminiferous tubules changed from an indistinct structure separating the cellular components of the sex cord and the interstitial tissue, to a distinct four layered structure suggesting that it plays an important part in testicular function. This tissue has been described as consisting of a basement membrane in close contact with the germinal epithelium, and tunica propria consisting of cellular layers interspersed with amorphous tissue which contain a few reticular and elastic fibres. Ultrastructural studies have indicated finer distinctions between the components and the nature of the contacts between them (Clermont, 1958; Burgos, 1960; Lacy and Rotblat, 1960;

Nicander et al., 1961; Lacy, 1962; Leeson and Leeson, 1963; Baillie, 1964b; Gardiner and Holyoke, 1964; Lacy and Rose, 1964; Ross and Long, 1966; Ross, 1967; Fawcett et al., 1969a; Fawcett et al., 1970). The boundary tissue in the foetal Romney ram was essentially a homogeneous band of tissue and no changes in morphology were seen until the early post natal period. This feature is probably similar in other animals at the same stage of development and is comparable to observations in man (Sniffen, 1950; Balse et al., 1960), rats (Leeson and Leeson, 1963) and mice (Baillie, 1962). In the rams of this study significant changes began to take place at the transitional period between the prepuberal and maturation phases of development and adult morphology was achieved when spermatozoa were first released within the seminiferous tubule.

The inner non-cellular layer gradually thickened reaching its maximum size at birth. Concurrently elastic tissue fibres seemed to disperse throughout this tissue and become more densely stained. During the period that the boundary tissue was developing into a multilayered structure the inner non-cellular layer was gradually reduced in thickness but still retained its elastic tissue density. Electronmicrographs of the tissue in the adult ram have indicated that this layer is not a homogeneous mass but consists of a series of twelve or more lamellae interspersed with collagen and reticulin fibres, and the whole surrounded by a wider band of collagen tissue (Lacy, 1962; Lacy and Rose, 1964; Morris, 1971). In this respect the boundary tissue has many similarities to the inner non-cellular layer of the young bull (Nicander et al., 1961), but differs from that of the rat (Clermont, 1958; Leeson and Leeson, 1963), the mouse (Baillie, 1962, 1964b; Gardiner and Holyoke, 1964; Ross, 1967), man (Burgos, 1960; Ross and Long, 1966), and the guinea pig and chinchilla (Fawcett et al., 1970). None of the latter exhibit extensive lamellae. Burgos' (1960) suggestion that the lamellae structure in man could be elastic as it stained deeply with orcein and aldehyde fuchsin stains could well apply to the ram.

The inner cellular layer became a distinctive structure following the appearance of the outer non-cellular layer. It is a layer of single cells with elongated nuclei. In man Balze et al. (1960) described these cells as mature forms of fibroblasts, but in the neonatal testis they varied from juvenile or type "a" fibroblasts to an intermediate form or type "C.1". Ultrastructural appearances of these interlamellar cells in the rat (Clermont, 1958; Leeson and Leeson, 1963) or peritubular cells in the mouse (Ross, 1967) and man (Ross and Long, 1966) have indicated that they are a contractile type cell with many features of the smooth muscle cell (Lacy and Rotblat, 1960; Straus and Kao, 1968; Fawcett et al., 1969a; Fawcett et al., 1970).

In this study the outer non-cellular layer was not identifiable at birth but appeared as a thick irregular layer with scattered fibrillar tissue over the period of transition to the maturation phase of development. There was an increase in the amount of tissue which became a homogeneous definite structure between the two cellular layers (Figs. 51, 52 and 53). Elastic tissue appeared simultaneously and differential staining for elastin indicated that it was present within the whole of this layer (Figs. 58 and 59).

In man, Balze et al. (1954) demonstrated that elastic tissue fibres developed in this layer of tissue during the maturation phase of development, and after puberty slowly thickened to the substantial amounts observed in older men. Likewise in the ram the elastic tissue in this layer increased and appeared as heavily stained thickened fibrillar tissue when the adult phase of development had been reached. It can be anticipated that in the older mature ram the elastic tissue of the outer non-cellular layer could approach similar proportions to that seen in man. Electronmicrographs have shown that collagen fibres as well as other fibrillar connective tissue are present in this tissue (Lacy, 1962; Lacy and Rose, 1964; Morris, 1971).

The fourth or outer layer of the boundary tissue was indefinite for some weeks following birth. It was not until after the outer non-cellular layer had separated the two cellular layers that it was possible to identify the cells of the boundary tissue as distinct from those of the interstitial tissue. Balse et al. (1960) described these cells as varying in type from a more mature form of fibroblast located at the periphery of the boundary tissue. In the rat Leeson and Leeson (1963) described this layer as consisting of mesenchyme cells, the cytoplasmic processes of which reduced with maturity to form elongated cells. Lacy and Rotblat (1960) described them as fibroblasts whereas Brokelman (1960) considered that they resembled endothelial cells. Unlike the rat which has a single layer of cells with some overlapping (Leeson and Leeson, 1963) the outer cellular layer in the ram appeared to be made up of one or more rows. Lacy and Rose (1964) noted that this layer was comparatively thin.

The morphology of the boundary tissue suggested that a functional role exists for the various components. Although little is known of this function the marked changes during the maturation phase of development must be related to the production of spermatozoa. A number of roles have been su gested including physical support to the seminiferous tubules, development of contractile properties of one or more layers and establishment of a regulatory function for the passage of fluids and nutrients to the cellular components and lumina of the seminiferous tubules. The exact nature of the pathways requires further investigation (Lacy and Rotblat, 1960; Leeson and Leeson, 1963; Lacy, 1967; Ross, 1967; Waites and Setchell, 1969).

The support of the tubules can be provided by both cellular and non-cellular components of the boundary tissue. The inner non-cellular layer consisting of elastin within lamellated connective tissue apparently allows fluctuations in pressures to be resisted from both within the tubule and the interstitial areas. A similar function probably exists for the tissue of the outer non-cellular layer. It develops later than the internal layer, and reaches mature size at the time spermatozoa are produced. Leeson and Leeson (1963) postulate that the loose formation of connective tissue in this layer allows for some degree of mobility between the two cellular layers. Possibly an increased resistance to this mobility is brought about by the laying down of elastic tissue in the ram compared with the rat which contains collagen and reticulin fibres only in the non-cellular layers (Lacy and Rotblat, 1960).

In the ram the cells in the inner cellular layer probably have a contractile action as has been established by electron-microscopy in the rat (Clermont, 1958; Lacy and Rotblat, 1960; Kormano and

Niemi, 1966), mouse (Ross, 1967), guinea pig and chinchilla (Fawcett *et al.*, 1969a; Fawcett *et al.*, 1970) and man (Ross and Long, 1966; Straus and Kao, 1968). In the newborn mouse, Ross (1967) saw evidence of the transformation of some fibroblasts to smooth muscle cells within this inner cellular layer.

Rete testis fluid is derived from active secretion as well as diffusion through the semipermeable barrier of the wall of the seminiferous tubule (Setchell, 1967a, 1967b, 1970; Setchell *et al.*, 1969). All layers of the boundary tissue provide a partial barrier to the movement of the extracellular fluid between the interstitial tissue and the seminiferous epithelium (Setchell *et al.*, 1969). Such a barrier to the larger protein molecules probably exists at the inner cellular layers as Fawcett *et al.* (1970) were unable to find precipitated protein deeper than this layer of tissue. Vesicles are present in the cells of both the inner and outer cellular layers of the boundary tissue providing evidence that these cells may function actively in the passage of nutrients and secretory products across the blood testis barrier (Lacy and Rotblat, 1960; Leeson and Leeson, 1963). A larger surface for metabolic interchange may also be provided by the invaginations of the inner non-cellular layer into the germinal epithelium (Burgos, 1960).

Collagen fibres have been observed in greater amounts between the inner non-cellular layer and the inner cellular layer in the mature testis of the mouse and Ross (1967) suggested that a possible additional role for the contractile-type cell is in the metabolism and transformation of connective tissue within the limits of the boundary tissue and the interstitium.

Although elastic tissue is known to be present in the boundary tissue of the seminiferous tubules of the ram and man (Balze _et al._, 1954) its significance in these species is uncertain.

In summary the whole pattern in the development of the boundary tissue in the seminiferous tubules of the ram as observed in this study agrees generally with that of the rat, the mouse and man (Balze _et al._, 1960; Leeson and Leeson, 1963; Ross, 1967).

FIGURE 46: Sex cords in testis of a 47-day foetus.

H. & E. stain. x 500.

C, sex cord.

BT, indefinite boundary tissue which does not completely surround the sex cords.

F, interstitial cells.

FIGURE 47: Sex cords in testis of a 58-day foetus.

H. & E. stain. x 500.

BT, one layer of homogeneous staining tissue forming boundary tissue.

F, fibroblastic cells associated with boundary tissue.

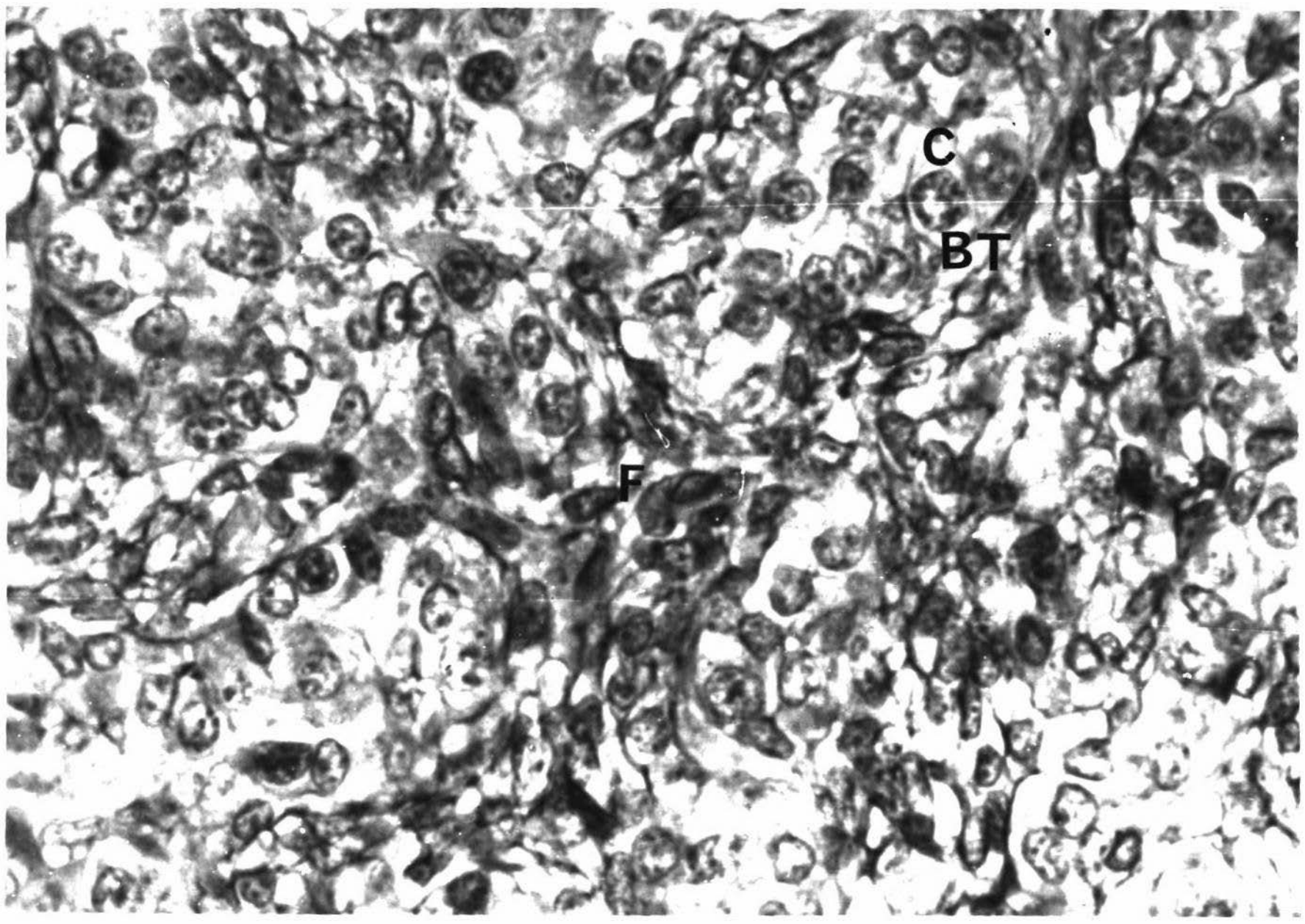
C
BT
F

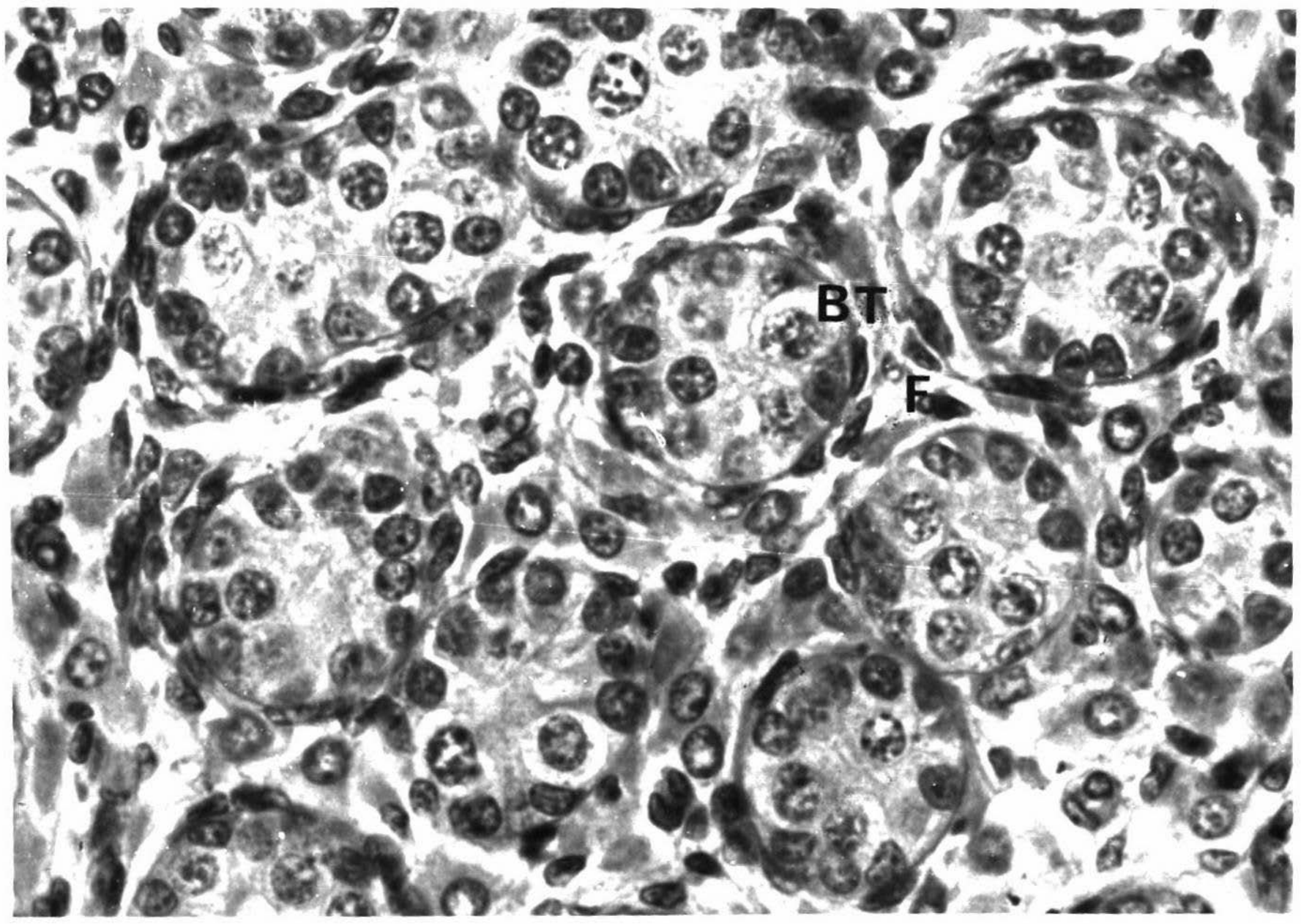
BT
F

FIGURE 48: Sex cords in testis of a 109-day foetus.

H. & E. stain. x 500.

C, sex cord.

F, fibroblastic cell associated with boundary tissue.

I, interstitial cell.

FIGURE 49: Sex cords in testis of a 28-day lamb.

H. & E. stain. x 500.

Boundary tissue showing a non-cellular layer, (Lm) and a cellular layer (Pi).

I, interstitial cell.

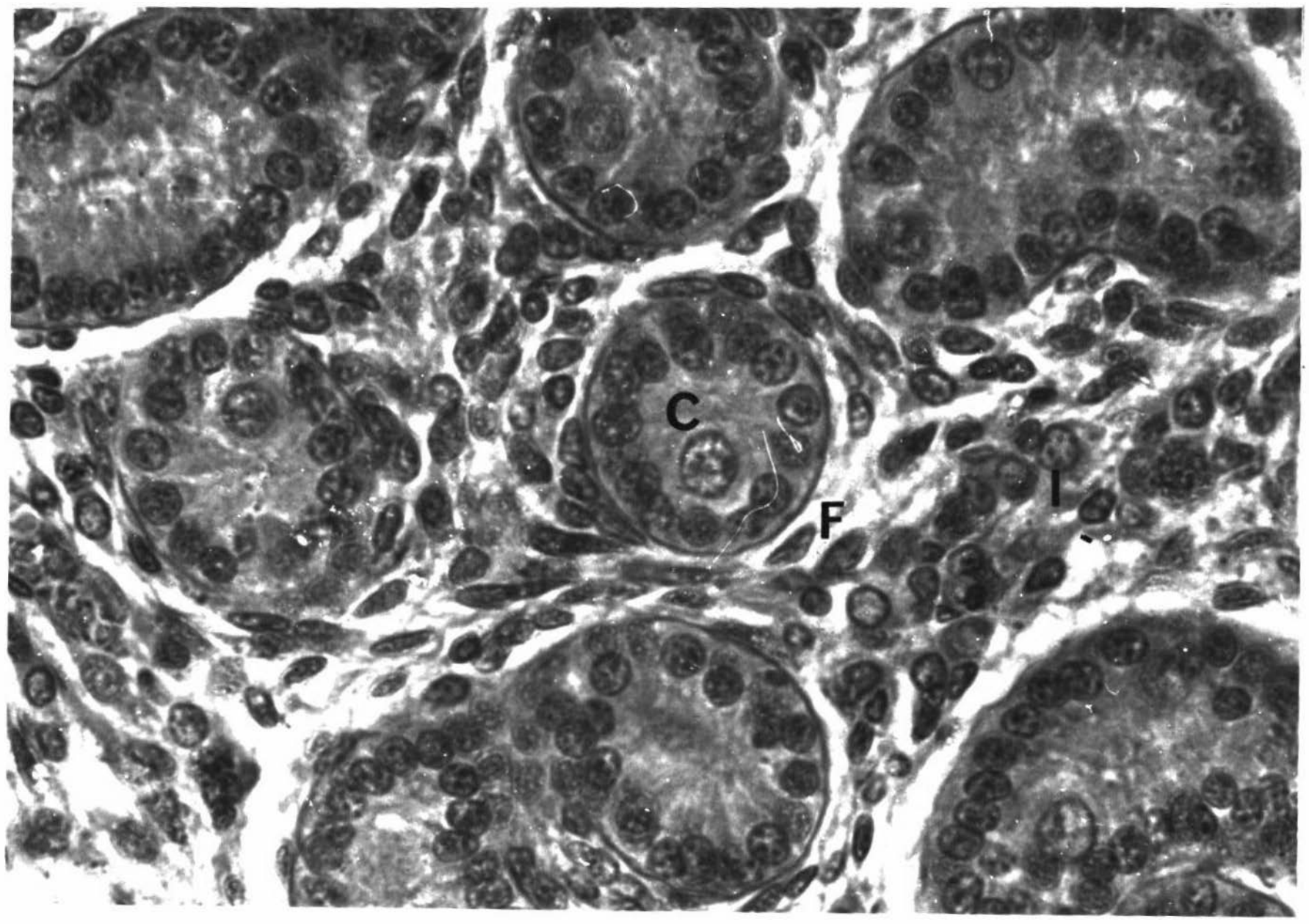
C
F
I

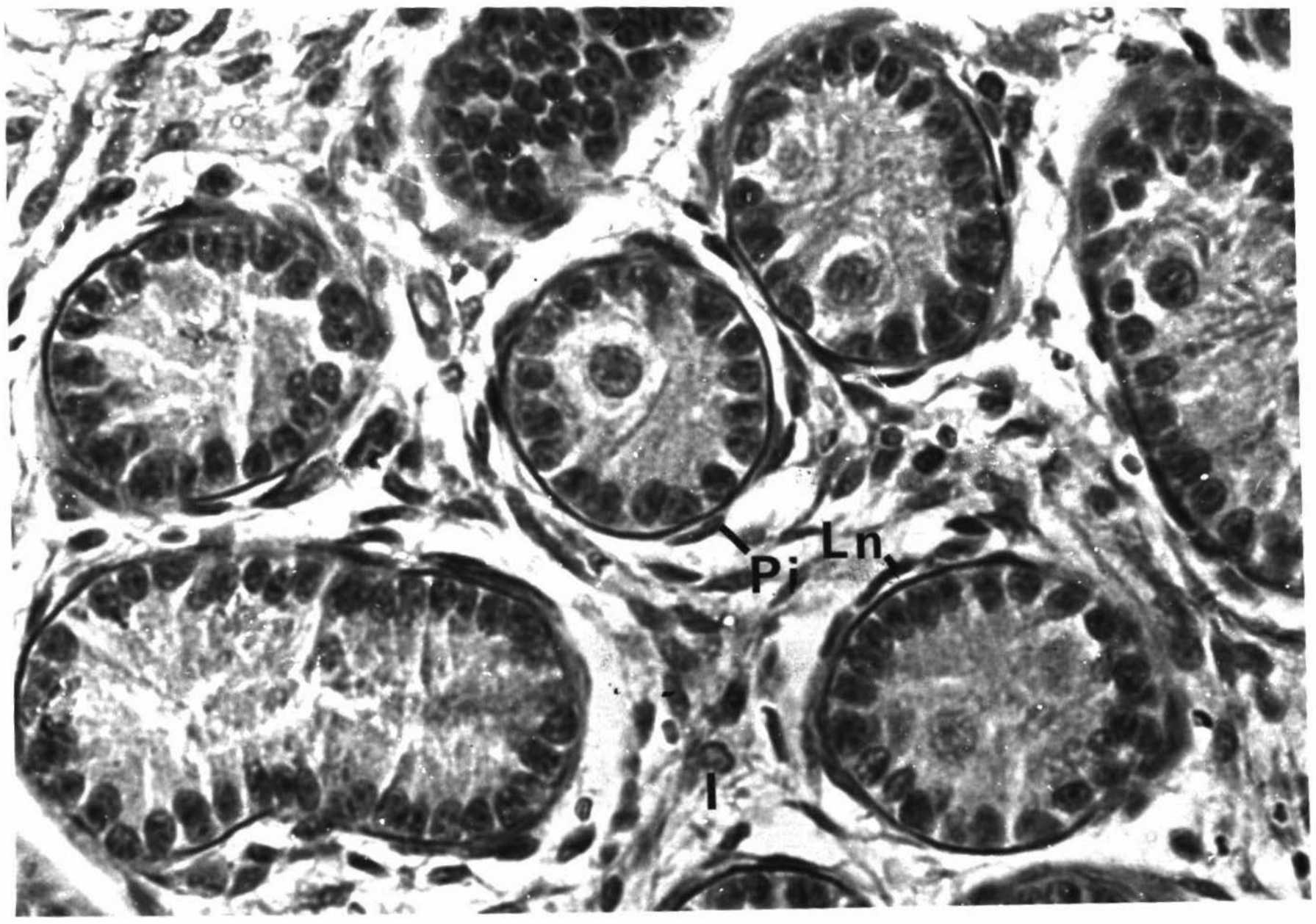
Pi
Ln
I

<u>FIGURE 50</u>: Sex cords in testis of a 45-day lamb.

H. & E. stain. x 500.

BT, boundary tissue, consisting of four layers, including an indistinct outer non-cellular layer.

I, interstitial cells.

<u>FIGURE 51</u>: Sex cord in testis of a 60-day lamb.

H. & E. stain. x 500.

The boundary tissue shows the inner non-cellular layer (Ln) the thin outer non-cellular layer (Ne), the inner cellular layer (Pi) and fibroblastic cells in the outer cellular layer (Ur).

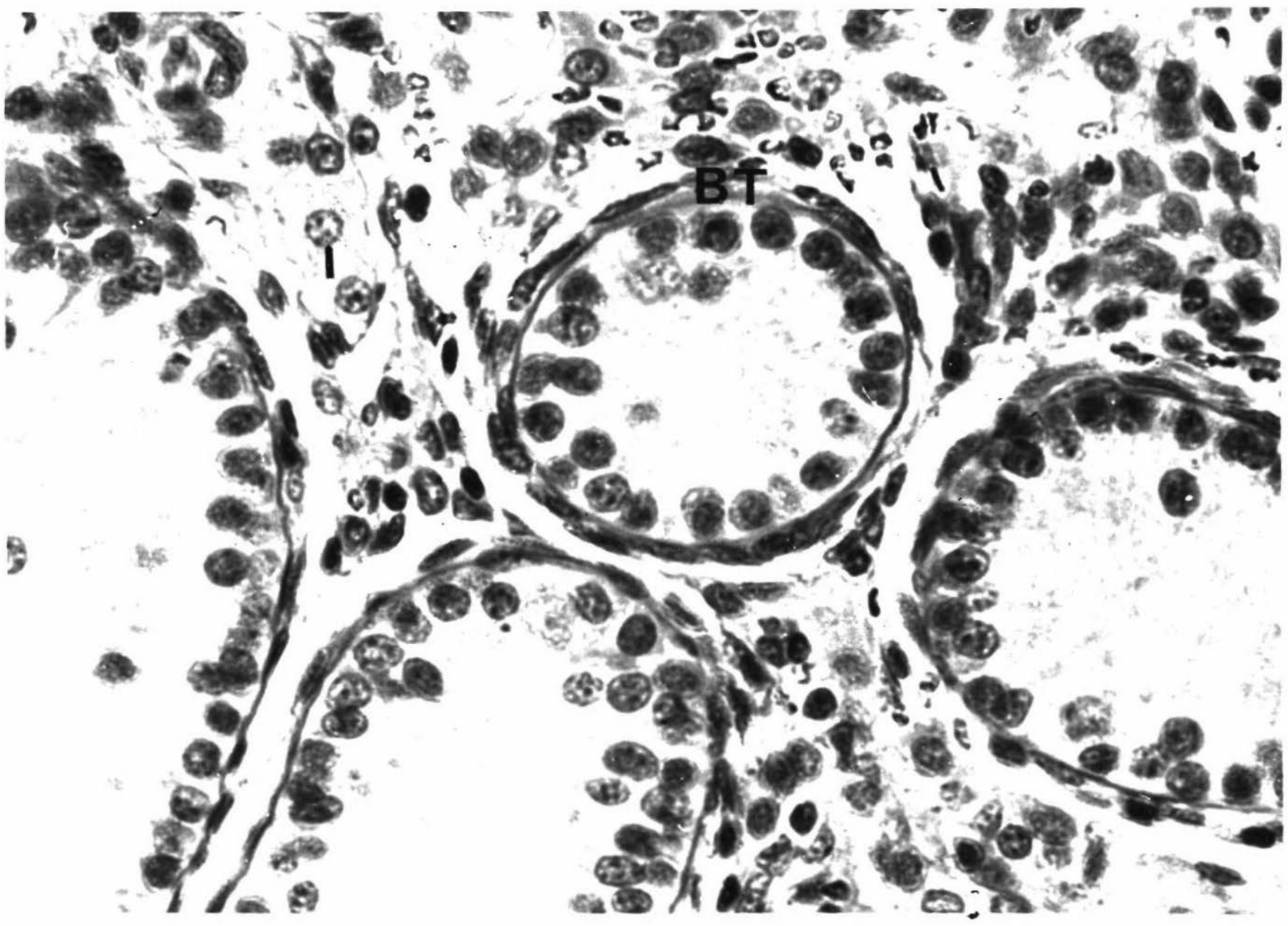
BT
I

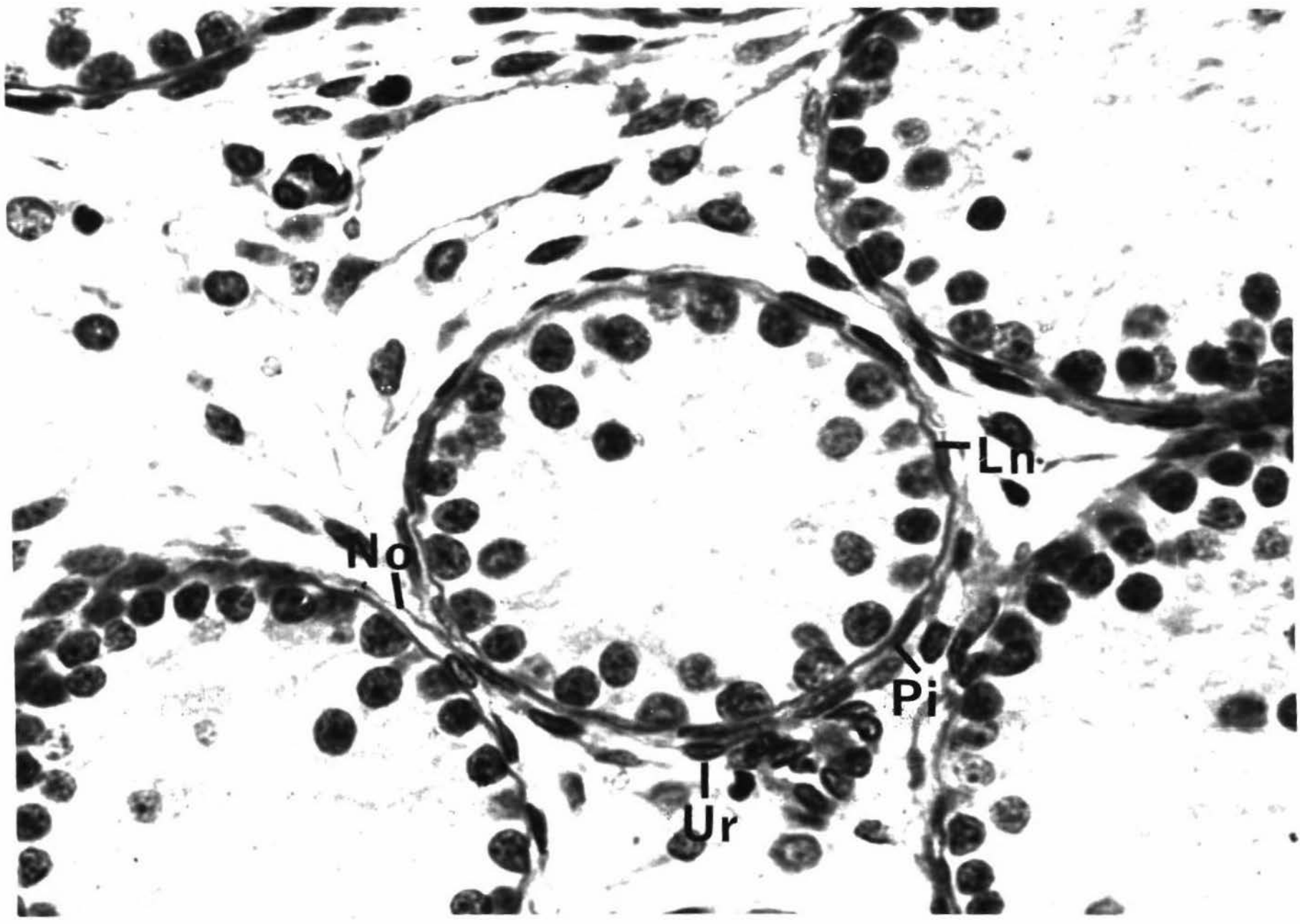
Ln
No
Pi
Ur

FIGURE 52: Seminiferous tubule in testis of a 84-day lamb.

H. & E. stain. x 500.

BT, boundary tissue of four distinctive layers.

lu, lumen of seminiferous tubule.

I, interstitial cells.

FIGURE 53: Boundary tissue of seminiferous tubule in testis of mature ram. H. & E. stain. x 500.

La, inner non-cellular layer.

Pi, inner cellular layer.

No, outer non-cellular layer.

Ur, outer cellular layer.

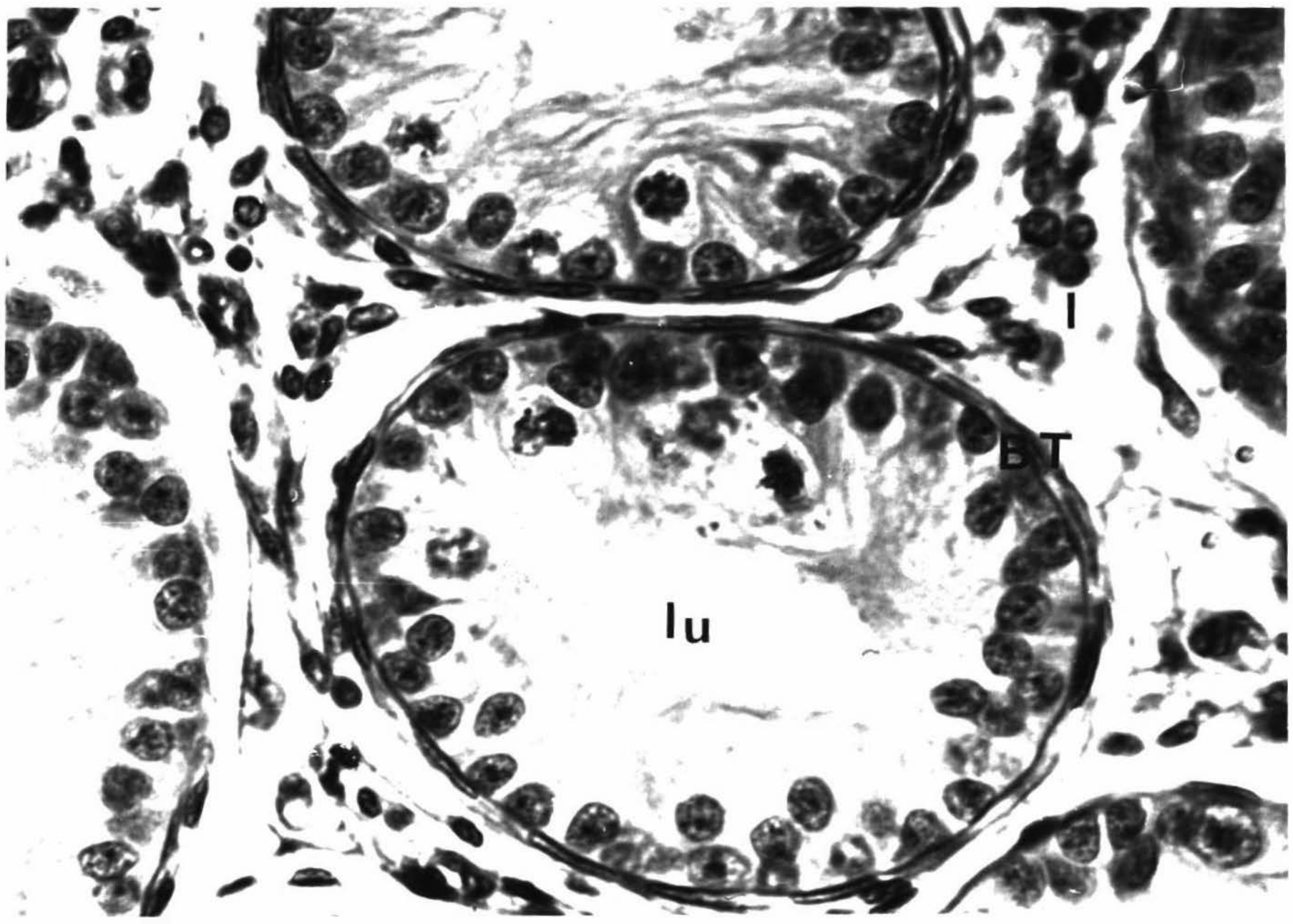
I
BT
lu

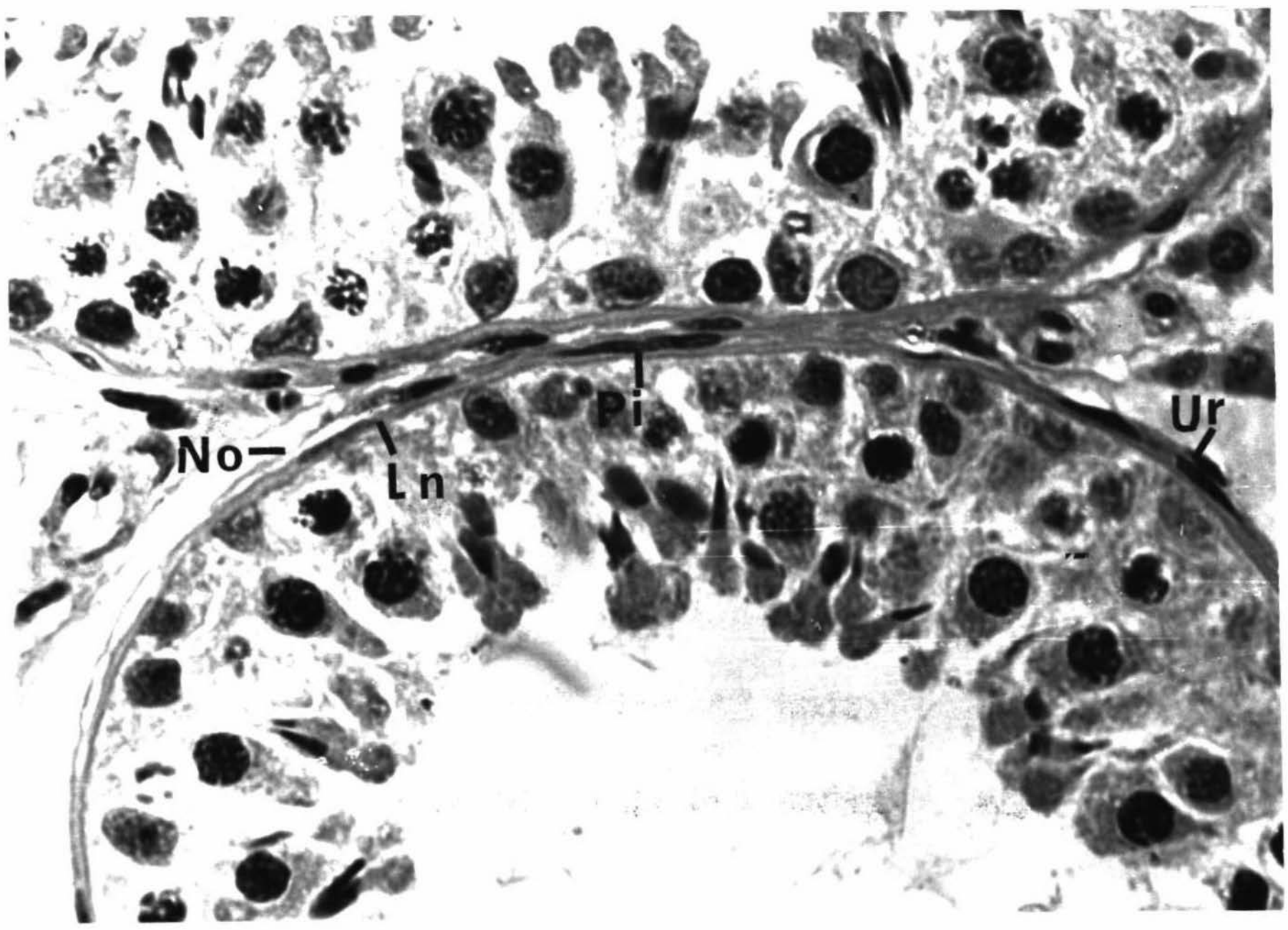
Pi
Ur
No
Ln

FIGURE 54: Elastin in boundary tissue of sex cord in testis of a 58-day foetus. Weigert's elastin stain. x 500.

C, sex cord.

EL, non-cellular layer of boundary tissue.

FIGURE 55: Elastin in boundary tissue of sex cord in testis of a 128-day foetus. Weigert's elastin stain. x 500.

C, sex cord.

EL, non-cellular layer of boundary tissue.

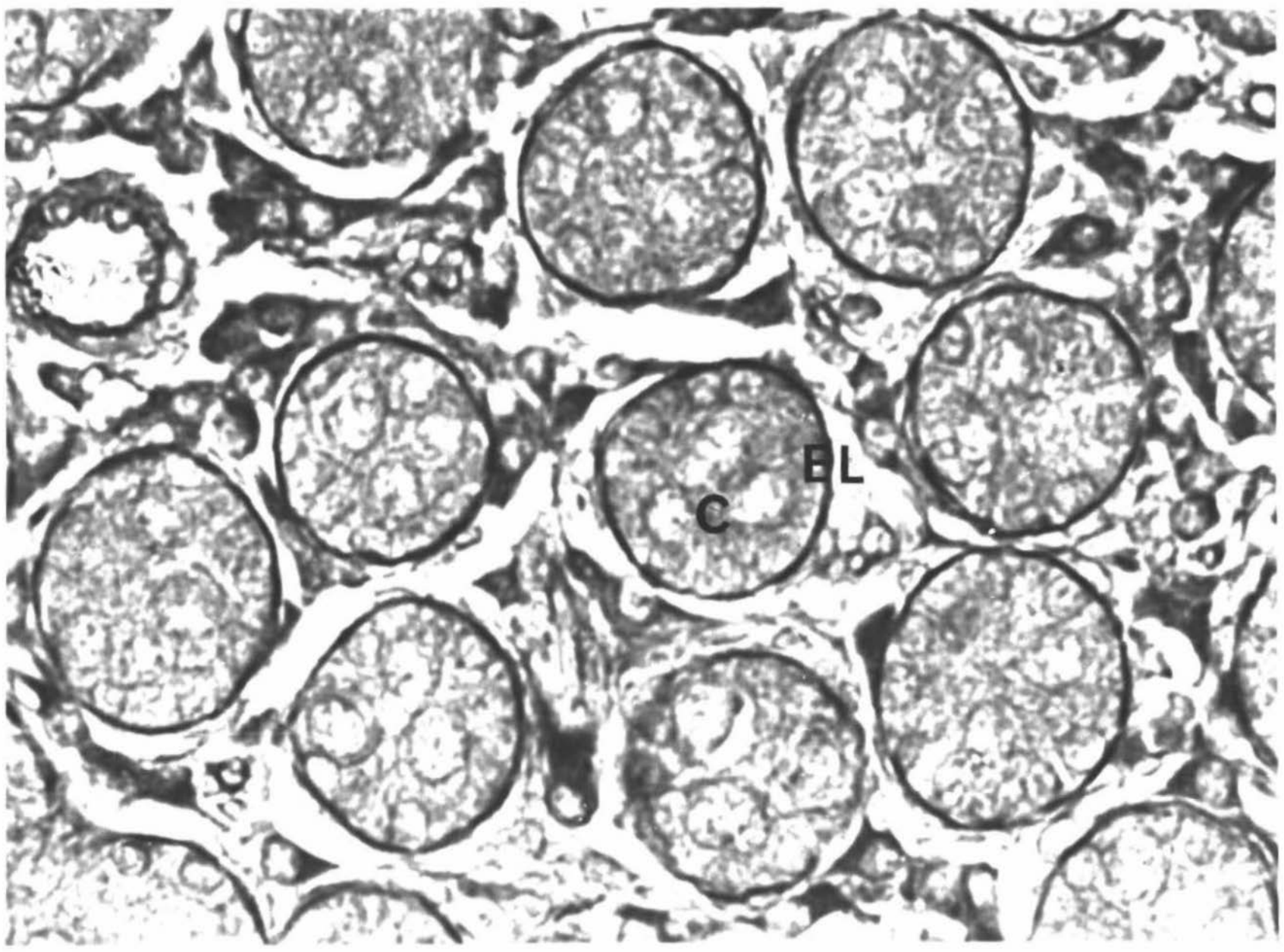
EL
C

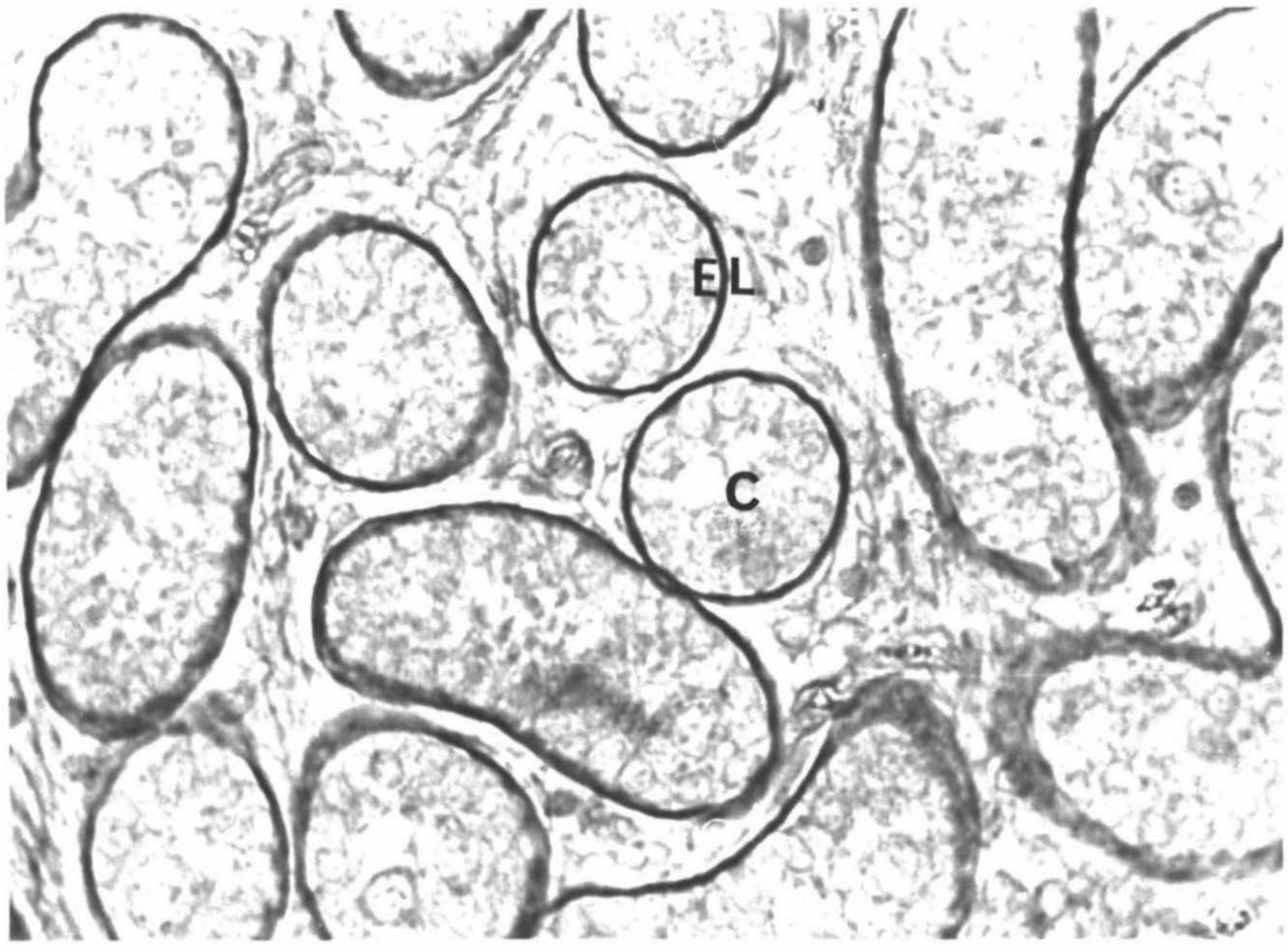
EL
C

FIGURE 56: Elastin in boundary tissue of sex cord in testis of a 45-day lamb. Weigert's elastin stain. x 500.

Ln, non-cellular layer of boundary tissue.

Pi, cellular layer of boundary tissue.

FIGURE 57: Elastin in boundary tissue of sex cord in testis of a 60-day lamb. Weigert's elastin stain. x 500.

Eln, elastin staining inner non-cellular layer of boundary tissue.

Eno, few elastic fibres in outer non-cellular layer of boundary tissue.

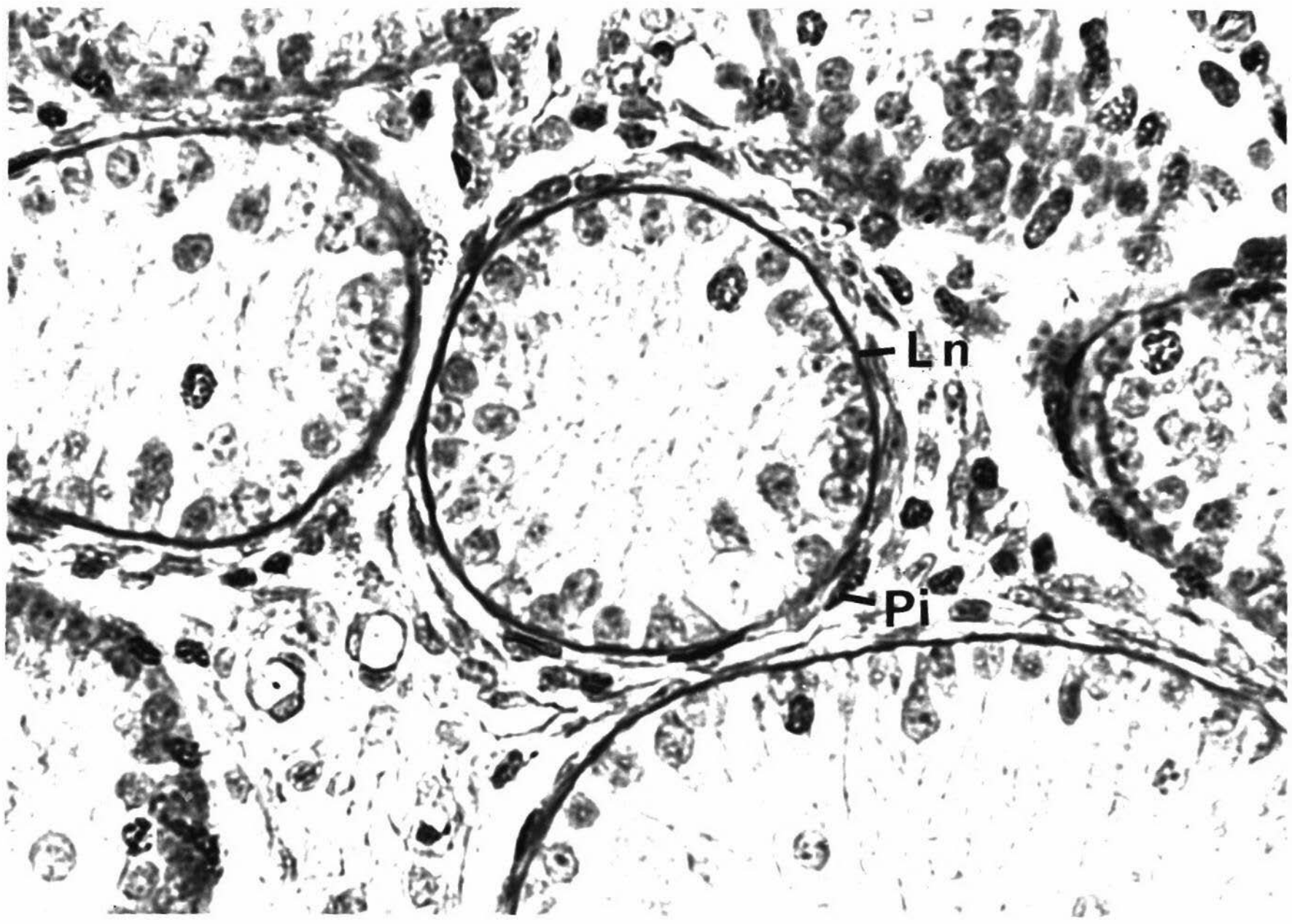
Ln
Pi

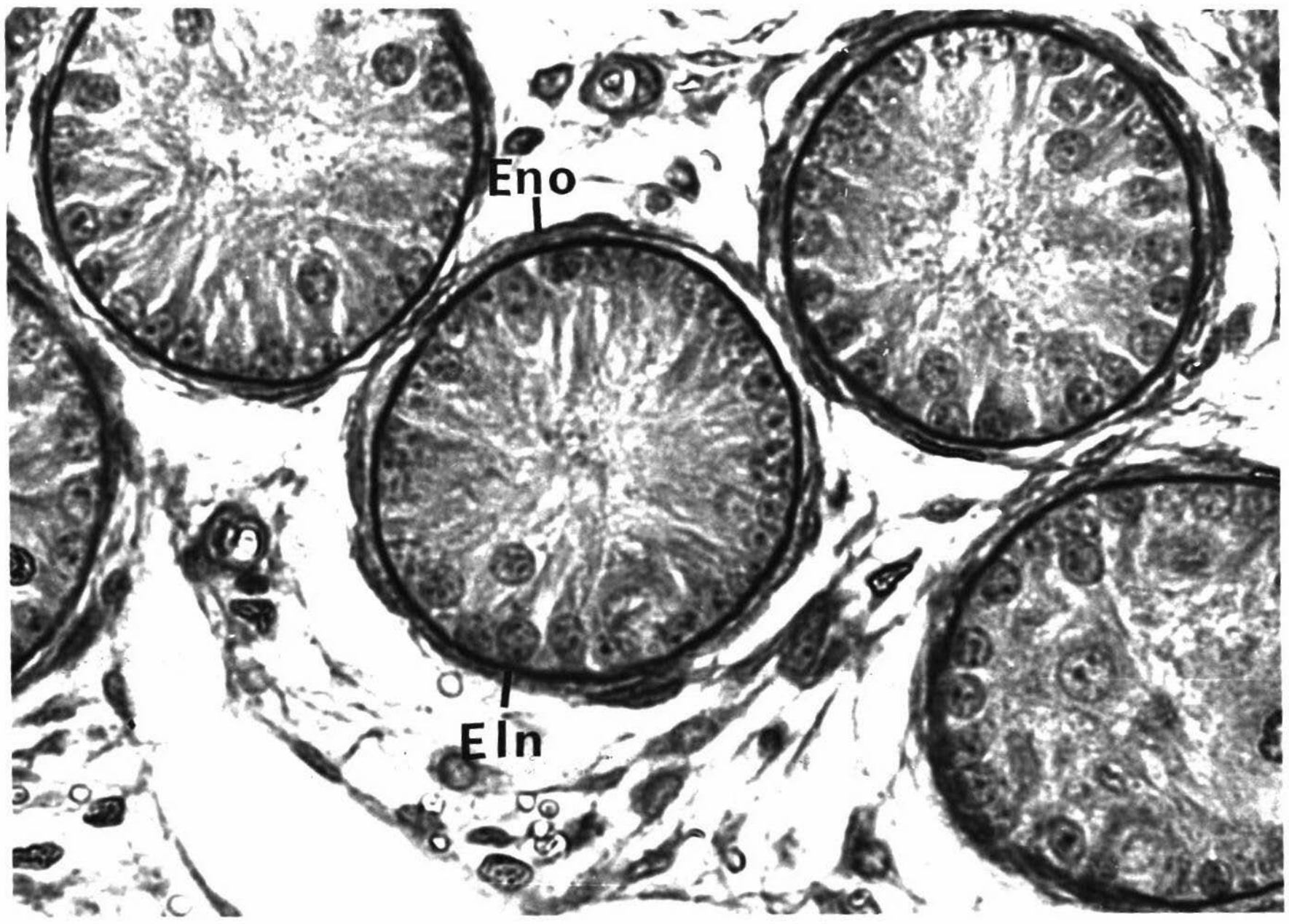
Eno
Eln

__FIGURE 58__: Elastin in boundary tissue of seminiferous tubule in testis of a 84-day lamb. Weigert's elastin stain. x 500.

EL, elastin staining layers of boundary tissue.

lu, lumen of seminiferous tubule.

__FIGURE 59__: Elastin in boundary tissue of seminiferous tubule in testis of a 154-day lamb. Weigert's elastin stain. x 500.

Eln, elastin staining inner non-cellular layer of boundary tissue.

Eno, elastin staining outer non-cellular layer of boundary tissue.

lu, lumen of seminiferous tubule.

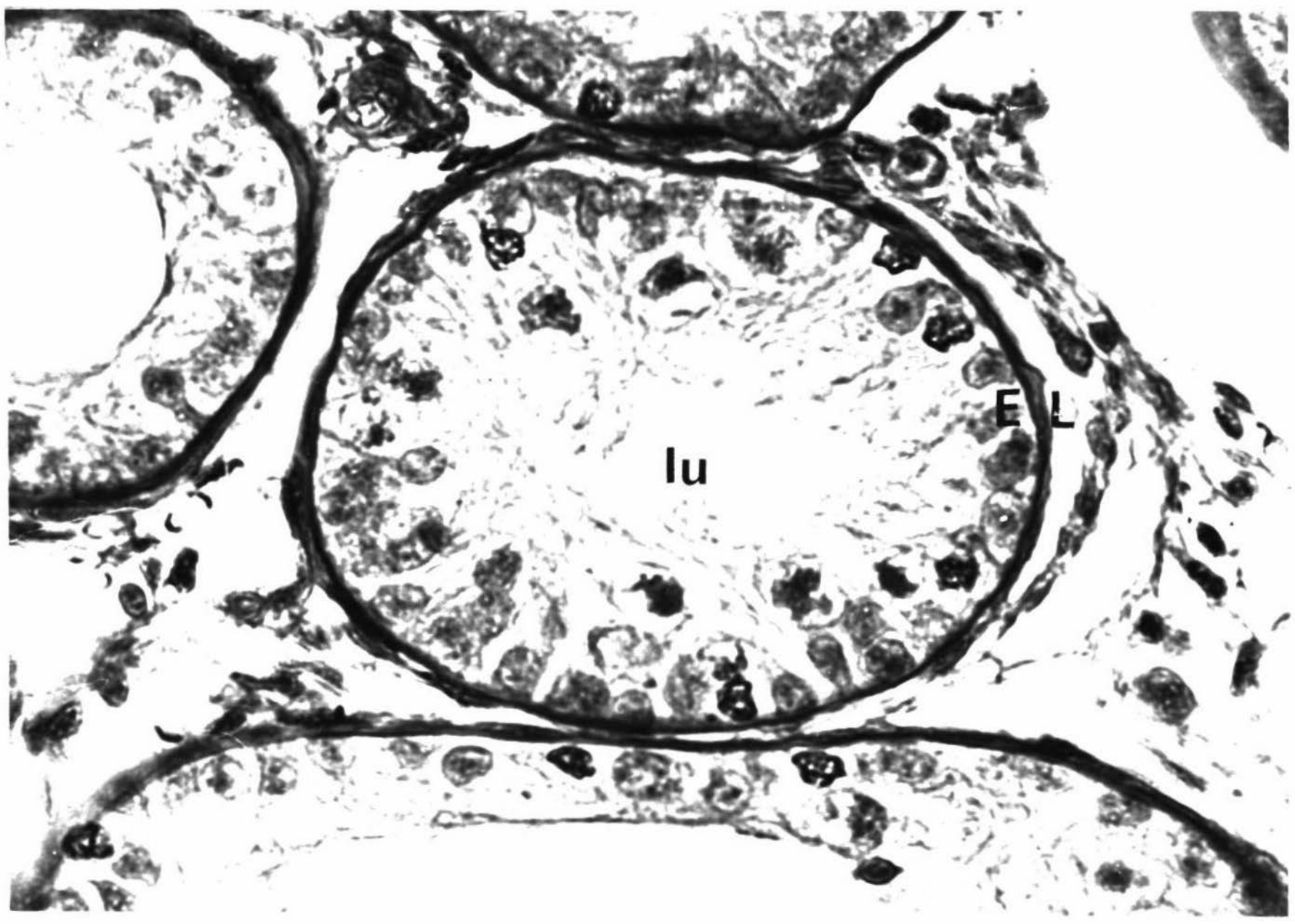
E
L
lu

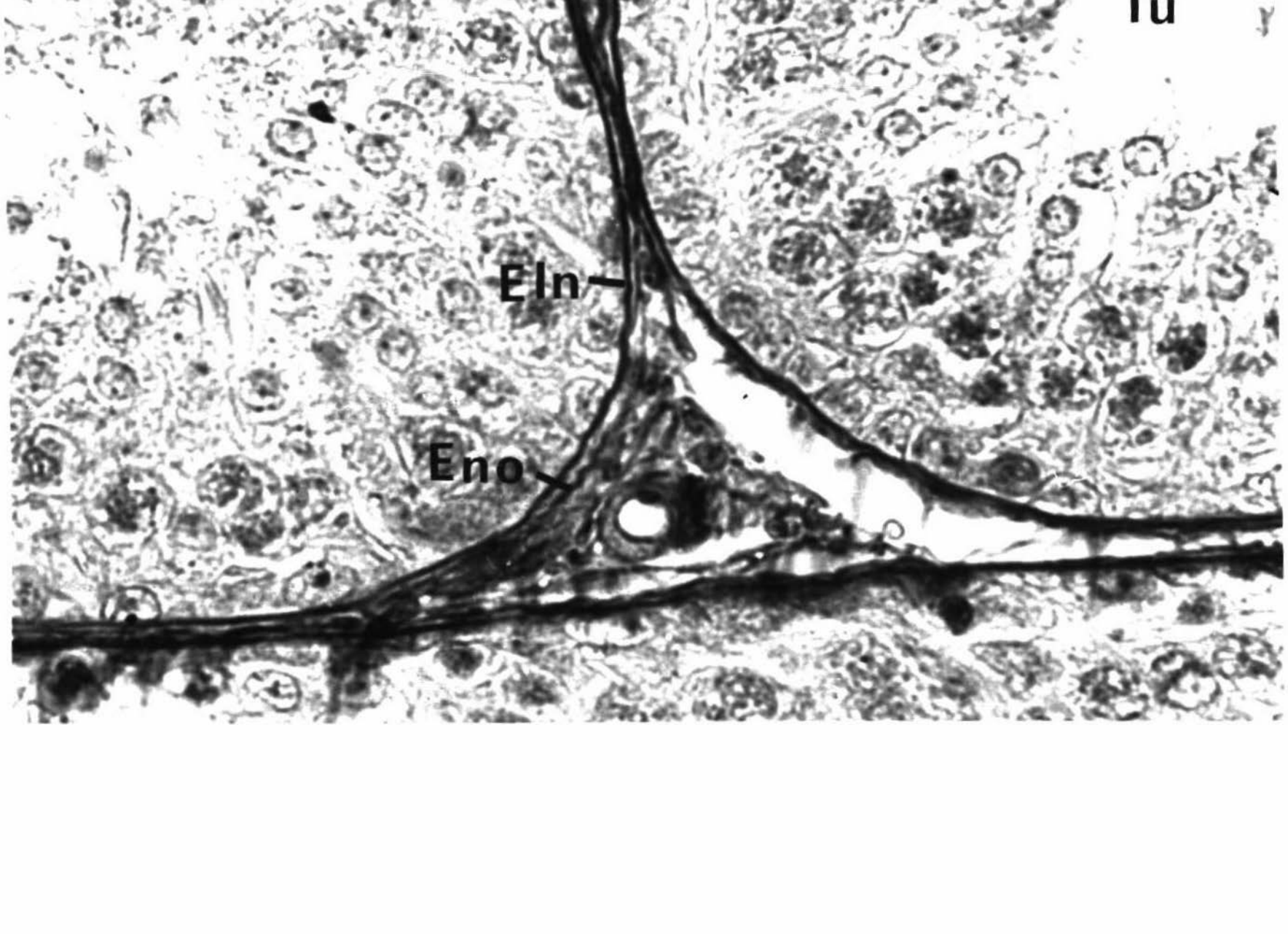
lu
Eln
Eno

CONCLUSIONS

The growth and developmental changes in the testes of the New Zealand Romney showed that qualitatively it functioned as in an adult ram by the twenty-second week after birth. The completion of the first cycle of spermatogenesis was also dependent on the attainment of a testis size of at least 34 G. The testis continued to grow after puberty, and would be expected to function at the capacity of an adult when the ram grew older and had gained a greater body weight. Although not measured in this study the extent of reproductive improvement during early adulthood could be determined by quantitative assessments of germ cell production (Courot, 1962; Skinner and Rowson, 1968).

Changes taking place in the testicular tissue, with development of the ram, are a function of the testis weight. These are directly related to the body weight which is a better indicator of the physiological development of the ram than the chronological age (Watson _et al_., 1956; Courot, 1962; Skinner _et al_., 1968). The body weight at any particular stage of development represents an interaction of the effects of the birth weight of the lamb and its subsequent nutrition, as well as age, and provides a means to compare the relative development of different rams. Nutrition has a particular _influence_ over the onset of spermatogenesis but after puberty, when the spermatogenic cycle has commenced, its influence on subsequent testicular development is less (Abdel-Raouf, 1960).

Histological changes in the testis are closely associated with the different phases of testes' growth. Similarly the appearance of the lumen in the developing seminiferous tubule is indicative of changes in growth rhythms of both the diameter and the length of the seminiferous tubules (Attal and Courot, 1963) and is concomitant with the completion of Sertoli cell development and the appearance of the older forms of primary spermatocytes and spermatids. From estimations of testes size the precise point at which the rate of testes growth changes can be determined and the time of commencement of spermatogenesis established.

Knowledge of the testes weight, body weight and age relationships in rams may allow some manipulation of the feed of young Romney lambs so that they can mature sexually by 22 weeks of age. Although in practice advancing the season of flock rams may not be feasible, the advantages to a progeny testing programme are obvious.

In the sex cords of rams, as in other species, the phase of testicular development before the onset of spermatogenesis proceeds with no noticeable variation. Quantitative studies show that the succession of germ cells is steady and that the adult combination of cell types seen at each stage of the cycle of the seminiferous epithelium is evident from the time spermatogenesis commences (Courot, 1962).

The boundary tissue of the seminiferous tubules has a functional part to play in the production of spermatozoa and although clarification is needed on the specific roles for the component tissues of the tubular wall in the ram, their functions in relation to the structure, metabolism and movement of the seminiferous tubules are probably the same as described for the rat, mouse and man

(Leeson and Leeson, 1963; Lacy, 1967; Ross, 1967). The inner non-cellular layer of the tubular wall becomes thinner between birth and maturity. This may enable an easier movement of metabolites from the interstitium to the rapidly dividing germ cells (Nicander et al., 1961). Conversely, thickening and alteration of one or more layers of the boundary tissue shown in some sterility conditions in man, may restrict the metabolism of the cellular components and the mobility of the tubule (Howard et al., 1950; Sniffen, 1950).

In the rat and mouse the contractile-type cells in the inner cellular layer induce movement of the seminiferous tubule, the release of spermatozoa and their progression to the rete testis (Leeson and Leeson, 1963; Ross, 1967). Greater significance may be placed on other roles yet to be determined. Initially these cells are like fibroblasts in the interstitium but they are possibly very different from the fibroblasts in other layers or in tissues beyond the testis (Balze et al., 1954).

The outer non-cellular layer of the boundary tissue is comparable to the connective tissue of the tunica propria in the wall of the seminiferous tubules of man (Sniffen, 1950; Balze et al., 1954; Balze et al., 1960). From the period of initial differentiation in both the ram and man elastic fibres are a regular component of this layer (Balze et al., 1954). The extent of elastin in similar boundary tissues of other species is not known. The appearance of this layer at puberty suggests that it is associated with mobility of the seminiferous tubules. In addition the elasticity of the wall of the seminiferous tubules may maintain intratubular pressures. The possibility of larger variations in diameter during movement of the tubules in the ram may be complimented by greater amounts of elastin, which is additional to or replaces the collagen tissue generally present in all species. Effects of the age of rams on the tubular boundary tissue is not known. In normal ageing processes elastic tissue does not disappear, but one may postulate that it may increase resulting in a thickening of the outer non-cellular layer as in man (Balze et al., 1954).

There are no reports on clinical and pathological conditions affecting the boundary tissue of the ram's testis. Studies of changes in this tissue, correlated with observations of the tubular components, could provide further evidence for the factors which synchronize the development of all tissues in the testis. In hypo-orchidism of ram's testes (Bruere, 1970) a detailed study on the boundary tissue of the tubular wall may assist differentiation and possibly determine the time at which the pathological changes took place. Klinefelter's syndrome in rams (Bruere et al., 1969) is an example. The inner non-cellular layer is thickened but there is no differentiation of the outer non-cellular layer (unpublished observations). This association with a number of undifferentiated supporting cells indicates that development has not proceeded beyond a stage normally observed in early post natal life.

The precise factors which control the development of the components of the seminiferous tubules remains to be determined. In the testis of the ram at the prepuberal phase, the supporting cells and possibly the gonocytes are dependent on gonadotrophins for the initiation of spermatogenesis, whereas in older rams some spermatogenetic activity once established can persist without gonadotrophic influence

(Courot, 1967; Ortavant et al., 1969). The same triggering mechanism may apply for the boundary tissue, or it may be a direct response to testicular androgens. Testosterone therapy has resulted in a thinning of the tubular wall in some pathological conditions of the testis in man (Howard et al., 1950). No doubt the evolution of the germ cells and supporting cells is intimately connected with the development of the tubular boundary tissue and the interstitium. More detailed studies of the boundary tissue in the ram, particularly its histochemistry and ultrastructure, may reveal unknown sequences in development. Similar studies of the seminiferous tubules in pathological conditions may determine whether the boundary tissue only is affected or whether changes here are secondary to changes in the germ cells, supporting cells or tissues of the interstitium. The functioning of all layers of the boundary tissue must be inter-related and changes in one tissue layer are likely to affect other layers as well as the cellular components of the tubules.

The demonstration of the relationship between the growth of the testes and the differentiation of the seminiferous tubules provides a pattern of normal development in the New Zealand Romney ram. From this it would now seem possible to describe more precisely pathological changes and degrees of immaturity of the testis tissue in both the growing and the adult ram.

APPENDIX I

WEIGERT'S RESORCIN - FUCHSIN STAIN FOR ELASTIC FIBRES

For staining of elastic tissues (in testis) after alcohol or formalin fixation. Best results obtained by fixation of the testis tissue in Carnoy's fluid.

Solutions Required.

A. Mallory's bleach. A solution of 0.25% potassium permanganate and 5% oxalic acid.

B. "Michrome" elastic stain (Weigert) No. 706. (Edward Gurr Ltd., London). Triturate 1 gram of Weigert Elastic stain with 5 grams clean silver sand, 100 ml absolute alcohol and 2 ml pure hydrochloric acid, until all the stain has gone into solution; filter.

C. Neutral red - 1% solution.

Method.

1. Bring sections to water.
2. Treat with Mallory's bleach.
3. Wash in 70% alcohol.
4. Stain in Weigert's elastic stain 8 - 24 hours.
5. Wash in 1% acid alcohol till elastic tissue only is stained.
6. Wash in water.
7. Counterstain in 1% neutral red for 4 minutes.
8. Wash in water.
9. Dehydrate, clear and mount.

Result.

Elastic fibres stain dark blue-black.

APPENDIX II

MODIFIED FUCHSIN METHOD

For the staining of elastic tissues and fibres in testis. Best results obtained by fixation of the testis tissue in Carnoy's fluid.

Solutions Required.

A. 1. Basic Fuchsin 0.5% in 96% alcohol 100 ml.

2. Resorcinol 2 gram.

3. Concentrated hydrochloric acid 0.5 ml.

4. Distilled water 1.5 ml.

B. 40% Formalin.

C. Mix equal parts of A and B. Solution should be freshly prepared as it will not keep.

D. Picric acid, saturated aqueous solution.

Method.

1. Take sections to absolute alcohol.
2. Stain in solution C for 60 minutes.
3. Wash in 96% alcohol for 20 - 25 seconds to remove excess stain.
4. Rinse in distilled water.
5. Counterstain in picric acid solution for 20 seconds.
6. Two rapid washes in absolute alcohol.
7. Clear and mount.

Result.

Elastic fibres stain deep purple to violet, nuclei pale red, cytoplasm yellow.

APPENDIX III

GOMORIS ALDEHYDE FUCHSIN METHOD

For the staining of elastic tissue and fibres in testis tissue. Although most fixatives are suitable, fixation in Carnoy's fluid or Davidson's solution (formol alcohol) give best results with testis tissue.

Solutions Required.

A. Aldehyde Fuchsin: (this solution must be stored in the refrigerator).

Basic Fuchsin 1 gram.

Let stand at room temperature for 2 or 3 days or until stain is deep purple in colour.

Alcohol 70% 200 ml.

Hydrochloric acid conc. 2 ml.

Paraldehyde 2 ml.

B. Mallory's bleach.

C. Counterstain 0.25% light green.

Method

1. Remove wax and treat with Mallory's bleach.
2. Bring to 70% alcohol.
3. Stain in solution A for 30 minutes. Older solution may require a longer period of one hour, and give a less selective result
4. Rinse in 70% alcohol.
5. Counterstain in light green (C) for 20 seconds.
6. Dehydrate, clear and mount.

Result.

Elastic fibres stain deep purple.

APPENDIX IV

HAEMATOXYLIN AND EOSIN STAIN FOR GENERAL MORPHOLOGY

For general differentiation of tissue in the testis. Although most fixatives are suitable, best results with testis tissue followed fixation in Bouin's fluid.

Solutions Required.

A. Ehrlich's Alum Haematoxylin.

B. 1% eosin solution.

Method.

1. Bring sections to 90% alcohol.
2. Stain in haematoxylin (A) for 10 minutes.
3. Stain in Mayer's haematoxylin for 5 minutes.
4. Differentiate with acid alcohol.
5. Wash in Scott's Tap Water for 2 minutes - until sections turn blue
6. Wash in water.
7. Counterstain in 1% eosin (B) for 30 seconds.
8. Remove excess eosin quickly by washing in water.
9. Dehydrate, clear and mount.

Results.

Nuclei stain blue; cytoplasm and connective tissue stain varying shades of pink and red.

APPENDIX V

REAGENTS USED FOR FIXATION OF TESTIS TISSUE (Culling, 1963)

10% FORMALIN

Formalin (40% formaldehyde)	10 ml.
Water to make up to	100 ml.

MERCURIC CHLORIDE SOLUTION

Mercuric chloride	7 grams
Sodium chloride	0.2 grams
40% formalin	10 ml
Acetic acid	0.5 ml
Distilled water to make up to	100 ml.

Fixation is rapid and sections must undergo iodine thiosulphate treatment to remove the mercuric chloride deposits before staining.

ZENKER'S FLUID

Mercuric chloride	5 grams
Potassium chromate	2.5 grams
Sodium sulphate	1 gram
Distilled water to	100 ml.

Add glacial acetic acid immediately before use - 5 ml.

Fixation usually complete in 12 hours.

BOUIN'S FLUID

Picric acid, saturated aqueous sol	75 ml
Formalin (40% formaldehyde)	25 ml
Glacial acetic acid	5 ml

Fixative keeps well, penetrates rapidly and evenly and causes little shrinkage. Fixation usually complete in 24 hours. When fixed the tissue is transferred from the fixative directly to 90% alcohol to render the water-soluble picrates which have formed, to an insoluble form before the tissue so treated comes in contact with water.

CARNOY'S FLUID

Absolute alcohol	60 ml
Chloroform	30 ml
Glacial acetic acid	10 ml

Fixative penetrates very quickly. It causes considerable shrinkage and destroys or dissolves most cytoplasmic elements.

Fixation is complete in 1 - 2 hours.

FORMOL ALCOHOL - DAVIDSON'S SOLUTION

10% Formalin	10 ml
90% Alcohol	90 ml
Glacial acetic acid	5 ml

Fixation is rapid and complete in 12 - 24 hours.

APPENDIX VI

GROWTH OF LAMBS - 1968/1969 SEASON

Age Group (Days)	No. in Each Group	Body Weights (kg) Mean ±	SE
Birth	18	4.6	.27
0 - 10	5	6.1	.41
10 - 20	8	9.2	.63
20 - 30	10	11.3	.74
30 - 40	16	12.1	.65
40 - 50	13	15.8	.61
50 - 60	9	16.6	1.65
60 - 70	2	17.4	
70 - 80	10	18.6	1.39
80 - 90	7	22.2	0.97
90 - 100	7	23.0	1.30
100 - 110	8	23.6	2.07
110 - 120	6	24.5	1.09
120 - 130	3	31.1	0.22
130 - 140	2	18.7	
140 - 150	2	20.5	
150 - 160	6	25.8	1.09
160 - 170	6	29.7	1.19
170 - 180	3	30.0	1.68
180 - 190	1	27.0	
190 - 200	3	32.1	2.53
200 - 210	2	30.4	
210 - 220	1	23.4	
220 - 230	2	31.5	
230 - 240	2	27.0	
240 - 250	-	-	
250 - 260	1	36.0	
260 - 270	1	26.1	

SE = Standard Error of the mean

REFERENCES

Abdel-Raouf, M. (1960):

The postnatal development of the reproductive organs in bulls with special reference to puberty.

Acta endocr., Copenh., 34 (suppl. 4): 1 - 109.

Abdel-Raouf, M. (1961):

The proliferation of germ cells in the testes of bull calves and young bulls.

Acta vet. scand., 2: 22 - 31.

Aitken, R.N.C. (1959):

Observations on the development of the seminal vesicles, prostate and bulbourethral glands in the ram.

J. Anat., 93: 43 - 51.

Attal, J.; Courot, M. (1963):

Developpement testiculaire et etablissement de la spermatogenese chez le taureau.

Annls. Biol. anim. Biochim. Biophys., 3: 219 - 241.

Baillie, A.H. (1960):

The interstitial cell in the testis of the foetal sheep.

Q. Jl microsc. Sci., 101: 475 - 480.

Baillie, A.H. (1961):

Observations on the growth and histochemistry of the Leydig tissue in the postnatal prepuberal mouse testis.

J. Anat., 95: 357 - 370.

Baillie, A.H. (1962):

Histochemical differentiation of the basement membrane of the mouse seminiferous tubule.

Q. Jl microsc. Sci., 103: 385 - 391.

Baillie, A.H. (1964a):

The histochemistry and ultrastructure of the genocyte.

J. Anat., 98: 641 - 645.

Baillie, A.H. (1964b):

Ultrastructural differentiation of the basement membrane of the mouse seminiferous tubules.

Q. Jl microsc. Sci., 105: 203 - 207.

Balo, J.; Banga, I. (1950):

The elastolytic activity of pancreatic extracts.

Biochem. J., 46: 384 - 387.

Balze, F.A. de la; Bur, G.E.; Scarpa-Smith, F.; Irazu, J. (1954):

Elastic fibres in the tunica propria of normal and pathologic human testes.

J. clin. Endocr. Metab., 14: 626 - 639.

Balze, F.A. de la; Mancini, R.A.; Arrillaga, F.; Andrada, J.A.; Vilar, O.; Gurtman, A.I.; Davidson, O.W. (1960):

Puberal maturation of the normal human testis. A histological study.

J. clin. Endocr. Metab., 20: 266 - 285.

Banks, E.M. (1964):

Some aspects of sexual behaviour in domestic sheep, *Ovis aries*.

Behaviour, 23: 249 - 279.

Beaumont, H.M.; Mandl, A.M. (1963):

A quantitative study of primordial germ cells in the male rat.

J. Embryol. exp. Morph., 11: 715 - 740.

Belonje, P.C. (1965):

Observations on the post natal development of the penis in Merino ram lambs and wethers: The possible relationship to the passage of urinary calculi.

Jl S. Afr. vet. med. Ass., 36: 381 - 383.

Bishop, M.W.H.; Walton, A. (1960):

Spermatogenesis and the structure of mammalian spermatozoa.

In Marshall's Physiology of Reproduction,

3rd Edn (A.S. Parkes, Ed.). Longmans Green, London. 1: part 2: 1-129.

Brambell, F.W.R. (1956):

Ovarian changes.

In Marshall's Physiology of Reproduction,

3rd Edn (A.S. Parkes, Ed.). Longmans Green, London. 1: part 1 : 397-542.

Bratton, R.W.; Musgrave, S.D.; Dunn, H.O.; Foote, R.H. (1959):

Causes and prevention of reproductive failures in dairy cattle.

II. Influence of underfeeding and overfeeding from birth to 80 weeks of age on growth, sexual development and semen production of Holstein bulls.

Bull. Cornell Univ. agric. Exp. Stn, 940: 1 - 45.

Brody, S. (1945):

Bioenergetics and Growth.

Reinhold, New York.

Brokelmann, J. (1960):

Limiting layers of seminiferous tubules in the albino rat.

- cited by Leeson, C.R.; Leeson, T.S. (1963):

Anat. Rec., 147: 243 - 249.

Bruere, A.N. (1970):

Some critical aspects of hypo-orchidism (small testes)

in the ram.

N.Z. vet. J., 18: 189 - 198.

Bruere, A.N.; Marshall, R.B.; Ward, D.P.J. (1969):

Testicular hypoplasia and XXY sex chromosome complement in

two rams: The ovine counterpart of Klinefelter's syndrome

in man.

J. Reprod. Fert., 19: 103 - 108.

Burgos, M.H. (1960):

Fine structure of the basement membrane of the human

seminiferous tubule.

Anat. Rec., 136: 312 (abstract).

Carmon, J.L.; Green, W.W. (1952):

Histological study of the development of the testis of the ram.

J. Anim. Sci., 11: 674 - 687.

Charny, C.W.; Conston, A.S.; Meranze, D.R. (1952a):

Testicular developmental histology.

Ann. N.Y. Acad. Sci., 55: 597 - 608.

Charny, C.W.; Conston, A.S.; Meranze, D.R. (1952b):

Development of the testis. A histology study from birth to

maturity with some notes on abnormal variations.

Fert. Steril., 3: 461 - 479.

Clegg, E.J. (1966):

Puberal growth in the Leydig cells and accessory reproductive organs of the rat.

J. Anat., 100: 369 - 379.

Clermont, Y. (1958):

Contractile elements in the limiting membrane of the seminiferous tubules of the rat.

Expl Cell Res., 15: 438 - 440.

Clermont, Y.; Huckins, C. (1961):

Microscopic anatomy of the sex cords and seminiferous tubules in growing and adult male albino rats.

Am. J. Anat., 108: 79 - 97.

Clermont, Y.; Leblond, C.P. (1955):

Spermiogenesis of man, monkey, ram and other mammals as shown by the "Periodic Acid-Schiff" technique.

Am. J. Anat., 96: 229 - 253.

Clermont, Y.; Perey, B. (1957):

Quantitative study of the cell population of the seminiferous tubules in immature rats.

Am. J. Anat., 100: 241 - 267.

Courot, M. (1961):

Etablissement de la spermatogenese chez l'agneau.

Proc. IVth Int. Congr. Anim. Reprod., The Hague 2: 216 - 221.

Courot, M. (1962):

Developpement du testicle chez l'agneau. Etablissement de la spermatogenese.

Annls. Biol. anim. Biochim. Biophys., 2: 25 - 41.

Courot, M. (1967):

Endocrine control of the supporting and germ cells of the impuberal testis.

J. Reprod. Fert., Suppl. 2: 89 - 101.

Culling, C.F.A. (1963):

Handbook of Histopathological Techniques. 2nd Edn. Butterworths, London.

Donovan, B.T.; Werff ten Bosch, J.J. van der (1965):

Physiology of Puberty. Edward Arnold, London.

Dun, R.B. (1955):

Puberty in Merino rams.

Aust. vet. J., 31: 104 - 106.

El Gohary, M. (1964):

Fine structure of developing testis cords in the golden hamster.

Anat. Rec., 148: 278 (abstract).

Everett, N.B. (1945):

The present status of the germ cell problem in vertebrates.

Biol. Rev., 20: 45 - 55.

Fawcott, D.W.; Burgos, M.H. (1956):

Observations on the cytomorphosis of the germinal and interstitial cells of the human testis.

Ciba Fdn Colloq. Ageing, (Wolstenhomle and Millar, Eds).

Churchill, London. 2: 86 - 99.

Fawcett, D.W.; Heidger, P.M.; Leak, L.V. (1969a):

Lymph vascular system of the interstitial tissue of the testis as revealed by electron microscope.

J. Reprod. Fert., 19: 109 - 119.

Fawcett, D.W.; Leak, L.V.; Heidger, P.M. (1970):

Electron microscopic observations on the structural components of the blood - testis barrier.

J. Reprod. Fert., Suppl. 10: 105 - 122.

Fawcett, D.W.; Long, J.A.; Jones, A.L. (1969b):

The ultrastructure of endocrine glands.

Recent Prog. Horm. Res., 25: 315 - 380.

Flickinger, C.; Fawcett, D.W. (1967):

The junctional specializations of Sertoli cells in the seminiferous epithelium.

Anat. Rec., 158: 207 - 222.

Foote, R.H. (1969):

Physiological aspects of artificial insemination. In Reproduction in Domestic Animals, 2nd Edn (Cole and Cupps, Eds).

Academic Press, New York. pp 313 - 355.

Fossland, R.G. (1954):

Histological development in the postnatal bovine testis.

J. Dairy Sci., 37: 669.

Fossland, R.G.; Schulze, A.B. (1961):

A histological study of the postnatal development of the bovine testis.

Res. Bull. Neb. agric. Exp. Stn. 199: 1 - 16.

Franchi, L.L.; Mandl, A.M. (1964):

The ultrastructure of germ cells in foetal and neonatal male rats.

J. Embryol. exp. Morph., 12: 289 - 308.

Galpin, N. (1935):

The prenatal development of the coat of the N.Z. Romney lamb.

J. agric. Sci., Camb., 25: 344 - 360.

Gardner, P.J.; Holyoke, E.A. (1964):

Fine structure of the seminiferous tubule of the Swiss mouse.
1. The limiting membrane, Sertoli cell, spermatogonia and spermatocytes.
Anat. Rec., 150: 391 - 404.

Gier, H.T.; Marion, G.B. (1969):

Development of mammalian testes and genital ducts.
Biol. Reprod., Suppl. 1: 1 - 23.

Green, W.W.; Winters, L.M. (1944):

Histological studies of boar testes.
J. Morph., 75: 291 - 301.

Hahn, J.; Foote, R.H.; Cranch, E.T. (1969):

Tonometer for measuring testicular consistency of bulls and to predict semen quality.
J. Anim. Sci., 29: 433 - 489.

Hammond, J.; Marshall, F.H.A. (1952):

The life cycle.
In Marshall's Physiology of Reproduction, 3rd Edn (A.S. Parkes, Ed.). Longmans Green, London. 2: 793 - 848.

Hansen, P.F.; With, T.K. (1952):

Clinical measurements of the testes in boys and men.
Acta med. scand., 142 (suppl 266): 457 - 465.

Hauser, E.R.; Dickerson, G.E.; Mayer, D.T. (1952):

Reproductive development and performance of inbred and crossbred boars.
Res. Bull. Mo. agric. Exp. Stn, 503: 1 - 56.

Hay, M.F.; Deane, H.W. (1966):

Attempts to demonstrate 3β - and 17β - hydroxysteroid dehydrogenases histochemically in the testes of the stallion, boar, ram and bull.

J. Reprod. Fert., 12: 551 - 560.

Hay, M.F.; Lindner, H.R.; Mann, T. (1961):

Morphology of bull testes and seminal vesicles in relation to testicular androgens.

Proc. R. Soc. B, 154: 433 - 448.

Hilscher, W.; Hilscher, B. (1968):

Dates of the prospermatogenesis and spermatogenesis of the rat. Determined by the method of labelled mitoses.

Proc. VIth Congr. Reprod. Anim Insem. Artif., Paris., 1, section 2: 145 - 147.

Hilscher, W.; Makoski, H.B. (1968):

Histologische und autoradiographische untersuchungen zur "Praspermatogenese" und "Spermatogenese" de ratte.

Z. Zellforsch. mikrosk. Anat., 86: 327 - 350.

Hooker, C.W. (1944):

The postnatal history and function of the interstitial cells of the testis of the bull.

Am. J. Anat., 74: 1 - 37.

Hooker, C.W. (1948):

The biology of the interstitial cells of the testis.

Recent Prog. Horm. Res., 3: 173 - 195.

Howard, R.P.; Sniffen, R.C.; Simmons, F.A.; Albright, F. (1950):

Testicular deficiency: a clinical and pathologic study.

J. clin. Endocr. Metab., 10: 121 - 186.

Huckins, C. (1963):

Changes in gonocytes at the time of initiation of spermatogenesis in the rat.

Anat. Rec., 145: 243 (abstract).

Johnstone, I.L. (1948):

The growth and development of the penis in sheep: their possible relationship to posthitis.

Aust. vet. J., 24: 86 - 88.

Knorr, D.W.; Vanha-Perttula, T.; Lipsett, M.B. (1970):

Structure and function of rat testis through pubescence.

Endocrinology, 86: 1298 - 1304.

Kormano, M.; Niemi, N. (1966):

Contractility of the seminiferous tubules of the rat testis.

Acta physiol. scand., 68 (suppl. 277): 112.

Lacy, D. (1962):

Certain aspects of testis structure and function.

Br. med. Bull., 18: 205 - 208.

Lacy, D. (1967):

The seminiferous tubule in mammals.

Endeavour, 26: 101 - 108.

Lacy, D.; Rose, A.J. (1964):

Fine structure of the boundary tissue of the seminiferous tubules and its environs in the ram.

3rd Eur. Region Conf. Electron Microsc., Prague Vol. B.: 447.

Lacy, D.; Rotblat, J. (1960):

Study of normal and irradiated boundary tissue of the seminiferous tubules of the rat.

Expl Cell Res., 21: 49 - 70.

Leblond, C.P.; Clermont, Y. (1952):

Definition of the stages of the cycle of the seminiferous epithelium in the rat.

Ann. N.Y. Acad. Sci., 55: 548 - 573.

Leeson, C.R.; Leeson, T.S. (1963):

The postnatal development and differentiation of the boundary tissue of the seminiferous tubule of the rat.

Anat. Rec., 147: 243 - 260.

Leik, J. (1968):

Junctional specialisations during lumen formation in the seminiferous tubules of the rat.

Anat. Rec., 160: 383 - 384 (abstract).

Louw, D.F.J.; Joubert, D.M. (1964):

Puberty in the male Dorper sheep and Boer goat.

S. Afr. J. agric. Sci., 7: 509 - 520.

McFee, A.F.; Eblen, J.R. (1967):

Testicular development in miniature swine.

J. Anim. Sci., 26: 772 - 776.

Macmillan, K.L.; Hafs, H.D. (1969):

Reproductive tract of Holstein bulls from birth through puberty.

J. Anim. Sci., 28: 233 - 239.

Mancini, R.E.; Narbaitz, R.; Lavieri, J.C. (1960):

Origin and development of the germinative epithelium and Sertoli cells in the human testis: cytological, cytochemical and quantitative study.

Anat. Rec., 136: 477 - 489.

Mancini, R.E.; Nolazco, J.; Balze, F.A. de la (1952):

Histochemical study of normal adult human testes.

Anat. Rec., 114: 127 - 147.

Matschke, G.H.; Erickson, B.H. (1969):

Developmental and radioresponse of the prenatal bovine testis.

Biol. Reprod., 1: 207 - 214

Mauleon, P. (1961):

Deroulement de l'ovogenese compare chez differentes mammiferes domestiques.

Proc. IVth Int. Congr. Anim. Reprod., The Hague 2: 348 - 354.

May, N.D.S. (1963):

The Anatomy of The Sheep.

2nd Edn. Univ. Qld Press, Brisbane.

Montagna, W. (1952a):

Some cytochemical observations on human testes and epididymides.

Ann. N.Y. Acad. Sci., 55: 629 - 642.

Montagna, W. (1952b):

The distribution of lipids, glycogen and phosphatases in the human testes.

Fert. Steril., 3: 27 - 34.

Morris, B. (1971):

Personal communication.

(Dept. Immunology, John Curtin Sch. Med. Res. Aust. Nat. Univ., Canberra City, A.C.T., Australia. 2601).

Nebel, B.R.; Amarose, P.; Hackett, E.M. (1961):

Calendar of gametogenic development in the prepuberal male mouse.

Science N.Y., 134: 832.

Nelson, W.O.; Heller, C.G. (1945):

Hyalinization of the seminiferous tubules associated with normal or failing Leydig cell function. Microscopic picture in the testis, and associated changes in the breast.

J. clin. Endocr. Metab., 5: 13 - 26.

Nicander, L; Abdel-Raouf, M.; Crabo, B. (1961):

On the ultra-structure of the seminiferous tubules in bull calves.
Acta morph. neerl. - scand., 4: 127 - 135.

Niemi, M; Ikonen, M. (1963):

Histochemistry of the Leydig cells in the postnatal prepuberal testis of the rat.
Endocrinology, 72: 443 - 448.

Niemi, M.; Ikonen, M.; Hervonen, A. (1967):

Histochemistry and fine structure of the interstitial tissue in the human foetal testis.
Ciba Fdn Colloq. Endocr. - Endocrinology of The Testis, (Wolstenholme and O'Connor, Eds). Churchill, London. 16: 31 - 55.

Novi, A.M.; Saba, P. (1968):

An electron microscopic study of the development of rat testis in the first ten postnatal days.
Z. Zellforsch. mikrosk. Anat., 86: 313 - 326.

Ortavant, R. (1959):

Deroulement et duree du cycle spermatogenetique chez le belier.
Annls. Zootech., 8: 183 - 244 and 271 - 321.

Ortavant, R.; Courot, M.; Hochereau, M.T. (1969):

Spermatogenesis and morphology of the spermatozoon. In Reproduction in Domestic Animals, 2nd Edn (Cole and Cupps, Eds).
Academic Press, New York. pp 251 - 276.

Phillips, R.W.; Andrews, F.N. (1936):

The development of the testes and scrotum of the ram, bull and boar.
Bull. Mass. agric. Exp. Stn, 331: 1 - 16.

Phillips, R.W.; Zeller, J.H. (1943):

Sexual development in small and large types of swine.
Anat. Rec., 85: 387 - 400.

Podany, J.; Setudarto, F. (1969):

Testikularni biometrie u beranu.

Vet. Med., Praha, 14: 505 - 510.

Prader, A. (1966):

Testicular size: assessment and clinical importance.

Triangle, 7: 240 - 243.

Pretorius, P.S.; Marincowitz, G. (1968):

Postnatal penis development, testes descent and puberty in Merino ram lambs on different planes of nutrition.

S. Afr. J. agric. Sci., 11: 319 - 334.

Roosen-Runge, E.C. (1951):

Motions of the seminiferous tubules of rat and dog.

Anat. Rec., 109: 413 (abstract).

Roosen-Runge, E.C.; Anderson, D. (1959):

The development of the interstitial cells in the testis of the albino rat.

Acta anat., 37: 125 - 137.

Roosen-Runge, E.C.; Leik, J. (1968):

Gonocyte degeneration in the postnatal male rat.

Am. J. Anat., 122: 275 - 300.

Ross, M.H. (1967):

The fine structure and development of the peritubular contractile cell component in the seminiferous tubules of the mouse.

Am. J. Anat., 121: 523 - 558.

Ross, M.H.; Long, I.R. (1966):

Contractile cells in human seminiferous tubules.

Science, N.Y., 153: 1271 - 1273.

Santamarina, E.; Reece, R.P. (1957):

Normal development of the germinal epithelium and seminiferous tubules in the bull.

Am. J. vet. Res., 18: 261 - 278.

Sapsford, C.S. (1957):

The development of the Sertoli cell.

J. Endocr., 15: lv.

Sapsford, C.S. (1962a):

The development of the testis of the Merino ram with special reference to the origin of the adult stem cells.

Aust. J. agric. Res., 13: 487 - 502.

Sapsford, C.S. (1962b):

Changes in the cells of the sex cords and seminiferous tubules during the development of the testis of the rat and mouse.

Aust. J. Zool., 10: 178 - 192.

Sapsford, C.S. (1964):

Changes in the size of germ cell nuclei during the development of the testis of the ram and rat.

Aust. J. Zool., 12: 127 - 149.

Setchell, B.P. (1967a):

The blood-testicular fluid barrier in sheep.

J. Physiol, Lond., 189: 63P - 65P.

Setchell, B.P. (1967b):

Fluid secretion by the testis.

J. Reprod. Fert., 14: 347 - 348.

Setchell, B.P. (1970):

The secretion of fluid by the testis of rats, rams, and goats with some observations on the effect of age, cryptorchidism and hypophysectomy. J. Reprod. Fert., 23: 79 - 85.

Setchell, B.P.; Scott, T.E.; Voglmayr, J.K.; Waites, G.M. (1969):

Characteristics of testicular spermatozoa and the fluid which transports them to the epididymis.

Biol. Reprod., Suppl. 1: 40 - 66.

Sisson, S.; Grossman, J.D. (1956):

The Anatomy of Domestic Animals.

4th Edn. Saunders, Philadelphia.

Skinner, J.D.; Booth, W.D.; Rowson, L.E.A.; Karg, H. (1968):

The postnatal development of the reproductive tract of the Suffolk ram, and changes in the gonadotrophin content of the pituitary.

J. Reprod. Fert., 16: 463 - 477.

Skinner, J.D.; Rowson, L.E.A. (1968):

Puberty in Suffolk and cross-bred rams.

J. Reprod. Fert., 16: 479 - 483.

Snedecor, G.W. (1956):

Statistical Methods.

5th Edn. Iowa State University Press, Ames, Iowa.

Sniffen, R.C. (1950):

The testis. 1. The normal testis.

Archs Path., 50: 259 - 284.

Sniffen, R.C. (1952):

Histology of the normal and abnormal testis at puberty.

Ann. N.Y. Acad. Sci., 55: 609 - 618.

Sniffen, R.C.; Howard, R.P.; Simmons, F.A. (1950):

The testis: II Abnormalities of spermatogenesis: atresia of the excretory ducts.

Archs Path., 50: 285 - 295.

Spencer, R.P. (1968):

Changes in testicular allometric growth curves.

Yale J. Biol. Med., 40: 313 - 319.

Stephenson, S.K. (1959):

Wool follicle development in the N.Z. Romney and N-type sheep.

IV Prenatal growth and changes in body proportions.

Aust. J. agric. Res., 10: 433 - 452.

Stephenson, S.K.; Lambourne, L.J. (1960):

Prenatal growth in Romney X Southdown cross and Australian Merino sheep. 1. Introduction and external growth patterns in the two breeds.

Aust. J. agric. Res., 11: 1044 - 1063.

Strauss, P.H.; Kao, V.C.Y. (1968):

Further evidence for a contractile element in the tunica propria of human seminiferous tubules.

Anat. Rec., 160: 434 (abstract).

Suvanto, O.; Kormano, M. (1968):

Spontaneous contractility of the rat seminiferous tubule in relation to the stage of the cycle of the seminiferous epithelium.

Scand. J. clin. Lab. Invest., 21 (suppl. 101): 66.

Symington, R.B. (1961):

Studies on the adaptability of three breeds of sheep to a tropical environment modified by altitude. VII Sexual activity in relation to age of ram.

J. agric. Sci., Camb., 56: 179 - 181.

Vilar, O.; Perez del Cerro, M.I.; Mancini, R.E. (1962):

The Sertoli cell as a 'Bridge Cell' between the basal membrane and the germinal cells.

Expl Cell Res., 27: 158 - 161.

Waites, G.M.H.; Setchell, B.P. (1969):

Physiology of the testis, epididymis and scrotum.

In Advances in Reproductive Physiology, (Anne McLaren, Ed.).

Lagos Press, London. 4: 1 - 53.

Watson, R.H.; Sapsford, C.S.; McCance, I. (1956):

The development of the testis, epididymis, and the penis in the young Merino ram.

Aust. J. agric. Res., 7: 574 - 590.

Wiggins, E.L.; Terrill, C.E. (1953):

Variation in penis development in ram lambs.

J. Anim. Sci., 12: 524 - 535.

Yao, T.S.; Eaton, O.N. (1954):

Postnatal growth and histological development of reproductive organs in male goats.

Am. J. Anat., 25: 401 - 431.