

Copyright is owned by the Author of the thesis. Permission is given for a copy to be downloaded by an individual for the purpose of research and private study only. The thesis may not be reproduced elsewhere without the permission of the Author.

Copper Nutrition in Pasture-Fed New Zealand Thoroughbreds, and its Role in Developmental Orthopaedic Disease

A thesis presented in partial fulfilment of the
requirements for the degree of Doctor of Philosophy at
Massey University, Palmerston North, New Zealand

Simon George Pearce

1997

ABSTRACT

This thesis reports studies to test the hypothesis that “dietary supplementation of pasture-fed New Zealand Thoroughbreds with copper will reduce the incidence and severity of developmental orthopaedic disease”. Thoroughbred foals were raised based on New Zealand Thoroughbred industry standards at AgResearch’s Equine Research Stud. Thus the first stage required the development of methods to define indices of copper status and growth plate development. Techniques were developed and evaluated for *in vivo* sampling of liver from the mare and neonatal foal and the distal radial physis of the neonatal foal.

Pregnant Thoroughbred mares (n=24) were divided into either copper supplemented or control groups. Live foals born to each group of mares were also divided into copper supplemented or control groups. Supplementation was administered orally with aqueous copper sulphate at a rate of 0.5 mg Cu/kg liveweight (LW), and controls received a placebo of equivalent fluid volume. Mares were supplemented for the final 13 to 25 weeks of gestation until parturition. Foals were supplemented from 21 days of age with 0.2 mg Cu/kg LW increasing to 0.5 mg Cu/kg LW by 49 days remaining at that level until euthanasia at approximately 150 days. All animals grazed tall fescue pasture containing 4.4 to 8.6 mg Cu/kg dry matter (DM) for the duration of the experiment. This experimental design allowed independent investigation of both the effect of mare treatment during gestation and foal treatment on the evidence of developmental orthopaedic disease in the foals. Randomisation was stratified based on mare age, sire of the foal, last date of service and in the case of the foals only, sex of the foal.

Indices of copper status were measured in both the mares and foals throughout the experiment, and at postmortem. The foals were examined regularly for evidence of developmental orthopaedic disease (DOD) which included clinical, conformational and radiological examinations. At euthanasia, an exhaustive postmortem examination was performed which included investigation of all limb and cervical spine articulations, and examination of the physes from the proximal humerus, proximal and distal radius and tibia, and distal femur, third metacarpus and third metatarsus. Physes were examined after cutting bone ends into slabs of approximately 6 mm widths using a bone saw. All abnormalities in cartilage or bone found at postmortem were submitted for histological examination. A histomorphometric study was also performed on the growth plate and metaphyseal primary spongiosa of standard sections cut through the distal radius.

Plasma copper concentration of mares declined throughout the final trimester, and was not affected by copper supplementation. There was a trend toward increased copper concentration in the livers of supplemented mares, and a significant increase in the liver copper concentration of foals born to supplemented mares as determined by liver biopsies of mares and foals shortly after parturition. Plasma and blood cell copper concentration, and plasma caeruloplasmin oxidase activity in the foals were not affected by copper supplementation, but liver copper concentration was significantly greater in copper-supplemented foals compared with controls.

There was no effect of copper supplementation on the evidence of DOD *in vivo*, in the physes examined at postmortem, or on the histomorphometry in the distal radius. However there was an effect of mare supplementation during gestation on indices of physitis in the foals assessed from postmortem radiographs and on mild abnormalities found in the articulations of foal limbs. Copper supplementation of the foal had no effect on these indices. The low incidence and severity of lesions found in foals grazing a pasture based diet containing 4.4 to 8.6 mg Cu/kg DM, combined with the failure to demonstrate an effect of foal copper supplementation on the evidence of DOD is contrary to published and anecdotal reports within New Zealand and internationally. This prompted the investigation of a possible dietary constituents which may affect the requirement for copper.

Molybdenum was identified as a possible antagonist which under certain circumstances may be found in high concentrations in a pasture diet. A pasture was prepared containing 8 to 15 mg Mo/kg DM. Weanlings were grazed on this pasture for 70 days and then supplemented with oral copper sulphate at a rate of 1.0 mg Cu/kg DM for a further 14 days (84 days total). There was no effect of high dietary molybdenum on plasma copper, trichloroacetic acid insoluble plasma copper, or blood cell copper concentration, or on the activities of caeruloplasmin oxidase or red blood cell superoxide dismutase. There was also no effect of dietary molybdenum on the liver copper concentration after 70 or 84 days. It was therefore concluded that at concentrations that might be expected in a pasture diet molybdenum is unlikely to increase copper requirements of horses.

The possible implications of this work to the New Zealand Thoroughbred industry, and suggestions for further research are discussed.

Acknowledgements

I am greatly in debt to the outstanding commitment of time and energy provided by my supervisors Elwyn Firth and Peter Fennessy. I am particularly thankful for the time Elwyn spent performing many integral functions related to the research and the preparation of manuscripts. Peter's rigorous, logical and creative approach to experimental design, data analysis and manuscript preparation also merits special mention. I would also like to thank my other supervisors, Jeff Wichtel, whose assistance with statistical analysis and manuscript preparation was particularly appreciated, and Sabina Holle.

I am particularly grateful to AgResearch's Neville Grace who taught me the basics of nutrition, was a major co-investigator in the studies described in this thesis, and was invaluable in the preparation of manuscripts including this thesis. Also at AgResearch I thank Warren Hunt who managed the research stud at Flock House, Bob Fletcher and Peter Johnstone, who provided advice on experimental design and statistical analysis and Willi Stiefel, who provided technical support for these studies.

In the Department of Veterinary Clinical Sciences at Massey University, I am thankful for the technical assistance of Simone Holmes, Michelle Hayes, Tracey Smith and Guy Hessel. Maureen Wichtel and Roz Machon anaesthetised foals for the technique development studies. Merv Birtles provided advice on histological techniques and took the photomicrographs in this thesis. Grant Guilford and Keith Thompson provided advice on different sections of this thesis, and Keith also assisted in the interpretation of histological sections. I would also like to thank the many other people in the department of Veterinary Clinical Science who offered advice, support and encouragement throughout.

The work in these studies was supported financially by AgResearch, the Foundation for Research, Science and Technology, the New Zealand Equine Research Foundation and Massey University. The New Zealand Equine Research Foundation also provided a travel scholarship which allowed me to present results of this work in North America.

Simon Pearce

Department of Veterinary Clinical Science

Massey University

April 1997

I dedicate this thesis to my parents, Pam and Martin,
with my love and respect.

Table of Contents

	page
Abstract	ii
Acknowledgements	iv
Table of Contents	vi
List of Figures	xii
List of Tables	xv
Chapter 1 Introduction	1
1.1 Experimental hypothesis	2
1.2 The New Zealand Thoroughbred	2
1.2.1 Brief history of the Thoroughbred racing horse	2
1.2.2 The Thoroughbred in New Zealand	4
1.2.3 The Thoroughbred management system in New Zealand	4
1.2.4 Wastage	5
1.3 Equine skeletal anatomy	6
1.3.1 Introduction	6
1.3.2 Anatomy of the growing long-bone	6
1.3.3 Physis	6
1.4 Developmental orthopaedic disease	7
1.4.1 Introduction	7
1.4.2 Osteochondrosis	8
1.4.3 Physitis	10
1.4.4 Cervical vertebral malformation	11
1.4.5 Limb deformities	12
1.4.5.1 Angular limb deformity	13
1.4.5.2 Flexural limb deformity	13
1.4.6 Proposed aetiologies for DOD	13
1.4.6.1 Growth rate	14
1.4.6.2 Trauma	15
1.4.6.3 Ischaemia	16
1.4.6.4 Genetics	17
1.4.6.5 Nutrition	19

1.4.6.6	Dexamethasone	26
1.4.6.7	Hypothyroidism	26
1.4.6.8	Infection	26
1.4.7	Conclusions from the review on DOD	27
1.5	Review on copper nutrition	28
1.5.1	Introduction	28
1.5.2	Copper content and distribution in the body	29
1.5.3	Copper metabolism	30
1.5.3.1	Absorption	30
1.5.3.2	Transport and storage	31
1.5.3.3	Excretion of copper	32
1.5.3.4	Effect of pregnancy on copper metabolism	33
1.5.3.5	Copper metabolism for the neonate	33
1.5.4	Cuproproteins	34
1.5.5	Measurement of copper status	38
1.5.6	Dietary copper sources and bioavailability	42
1.5.6.1	Copper content and availability in pasture	42
1.5.6.2	Copper supplements (bioavailability)	43
1.5.7	Copper dietary interactions	43
1.5.8	Copper metabolism studies and copper requirements in horses	46
1.5.9	Copper deficiency	48
1.5.10	Copper toxicity	49
1.5.11	Therapeutic applications for copper	51
1.6	Introduction to the objectives of the thesis	52
Chapter 2	Liver Biopsy Techniques for Adult Horses and Neonatal foals to Assess Copper Status	53
2.1	Abstract	54
2.2	Introduction	54
2.3	Materials and methods	56
2.3.1	Liver biopsy general details	56
2.3.2	Mare liver biopsy procedure	56

2.3.3	Foal liver biopsy procedure	57
2.3.4	Liver biopsy sample preparation and copper analysis	58
2.3.5	Site variation in liver copper concentration	59
2.4	Results	60
2.4.1	Mare liver biopsy procedure	60
2.4.2	Foal liver biopsy procedure	60
2.4.3	Liver biopsy copper concentration	61
2.4.4	Site variation in liver copper concentration	61
2.5	Discussion	63
Chapter 3	Biopsy of the Distal Radial Physis in Neonatal Foals	66
3.1	Abstract	67
3.2	Introduction	67
3.3	Materials and Methods	68
3.3.1	Animals	68
3.3.2	Biopsy technique	68
3.3.3	Conformation	70
3.3.4	Postmortem examination	70
3.4	Results	71
3.4.1	Surgery	71
3.4.2	Conformation	71
3.4.3	Postmortem	73
3.5	Discussion	76
Chapter 4	The Effect of Copper Supplementation on the Copper Status of Pregnant Thoroughbred Mares and their Neonates	79
4.1	Abstract	80
4.2	Introduction	80
4.3	Materials and methods	81
4.3.1	Animals	81
4.3.2	Sampling	82

4.3.3	Analytical	82
4.3.4	Statistical analysis	83
4.4	Results	83
4.4.1	Plasma copper concentration	83
4.4.2	Liver copper concentration	84
4.5	Discussion	86
Chapter 5	The Effect of Copper Supplementation on the Copper Status of Pasture-Fed Young Thoroughbreds	90
5.1	Abstract	91
5.2	Introduction	91
5.3	Materials and methods	93
5.3.1	Animals	93
5.3.2	Diet	94
5.3.3	Samples	94
5.3.4	Analytical	95
5.3.5	Statistical analysis	97
5.4	Results	98
5.4.1	Animals	98
5.4.2	Pasture mineral composition	98
5.4.3	Mare milk copper concentration	99
5.4.4	Foal plasma copper concentration, caeruloplasmin activity and blood cell copper concentration	99
5.4.5	Foal soft tissue copper concentration	103
5.4.6	Foal bone copper concentration	103
5.5	Discussion	104
Chapter 6	The Effect of Copper Supplementation on the Evidence of Developmental Orthopaedic Disease in Pasture-Fed Thoroughbreds	109
6.1	Abstract	110
6.2	Introduction	110

6.3	Materials and methods	112
6.3.1	Animals and diet	112
6.3.2	Clinical examination	112
6.3.3	Radiographic examination	112
6.3.4	Postmortem	114
6.3.5	Bone physical properties	114
6.3.6	Gross pathology	115
6.3.7	Histopathology	115
6.3.8	Statistical analysis	116
6.4	Results	116
6.4.1	Growth rate	116
6.4.2	Clinical examination	117
6.4.3	Radiographs	117
6.4.4	Bone physical properties	118
6.4.5	Pathology	119
6.5	Discussion	127
Chapter 7	The Effect of High Pasture Molybdenum Concentrations on the Copper Status of Grazing Horses	130
7.1	Abstract	131
7.2	Introduction	131
7.3	Materials and methods	133
7.3.1	Experimental design	133
7.3.2	Animals	133
7.3.3	Diets	133
7.3.4	Part 1: Molybdenum copper interaction	133
7.3.5	Part 2: Copper challenge	134
7.3.6	Analytical	134
7.3.7	Statistical analysis	135
7.4	Results	136
7.4.1	Pasture minerals	136
7.4.2	Part 1: Molybdenum copper interaction	136

7.4.3	Part 2. Copper challenge	139
7.5	Discussion	140
Chapter 8	General Discussion	143
8.1	Introduction	144
8.2	Experimental design	144
8.3	Development of surgical techniques	145
8.3.1	Liver biopsy technique	145
8.3.2	Physeal biopsy technique	146
8.4	The concept and measurement of adequate copper status	146
8.4.1	Plasma indices of copper status	146
8.4.2	Blood cell copper concentration and RBC Cu-Zn SOD as indices of copper status	147
8.4.3	Liver copper concentration as an index of copper status	147
8.5	The effect of copper supplementation of the mare and foal on indices of copper status	148
8.6	The effect of copper supplementation of the mare and foal on indices of bone and cartilage development	149
8.6.1	The influence of energy in the copper response experiments	152
8.6.2	The theory of an association between dietary copper requirements and energy source/level	152
8.6.3	The theory of copper as a therapeutic agent	153
8.7	Molybdenum as a copper antagonist for pasture-fed horses	154
8.8	Recommendations to the New Zealand Thoroughbred Industry	154
8.9	Further Research	155
Appendices		158
Appendix A	Pilot Studies on Circulating Copper Indices	159
References		170

List of Figures

		Page
Figure 2.1	Mean difference (mg/kg dry weight) between liver copper concentration at each site (30 to 60 mg fresh weight) and the total (homogenised) liver copper concentration for 3 mature Thoroughbred horses.	62
Figure 3.1	Stainless steel trephine, 9mm internal diameter, 11 mm external diameter, 24 mm trephine depth.	69
Figure 3.2	The difference (right subtracted from left) in carpus (valgus) angle as viewed from in front: a) 21 foals with time from the physeal biopsy procedure b) 6 age-matched, unoperated control foals with time from the median day of physeal biopsy (day 7) in operated foals; Angles were calculated using video image analysis	72
Figure 3.3	Thin section cabinet radiograph of a frontal section through the distal radius showing the effect of the biopsy on the physis laterally.	74
Figure 3.4	Low power view of the histological features of an epiphyseodesis at the biopsy site showing the trabeculae aligned perpendicular to the physis, extending into the physis.	75
Figure 4.1	The relationship between plasma copper concentration and time prepartum in the 21 mares.	84
Figure 4.2	The relationship between mare and foal liver copper concentration (mg Cu/kg DM) at 4 to 10 days postpartum from copper control and supplemented mares.	85
Figure 4.3	The relationship between mare age and foal liver copper concentration at birth for foals from control and copper supplemented mares.	86
Figure 5.1	Mean milk copper concentration (mg/l) of all lactating mares from birth to 150 days (n=21).	99
Figure 5.2	Mean plasma copper concentration (mg/l) and blood cell copper concentration (mg/kg fresh weight) of all foals (n=21) from birth to 150 days.	100

Figure 5.3	Mean plasma caeruloplasmin activity (U/l, 37°C) of all foals (n=21) from birth to 150 days.	101
Figure 5.4	Relationship between plasma copper concentration and caeruloplasmin activity of all foals (n=21) a) from birth to 21 days b) from 28 to 150 days.	102
Figure 6.1	Radiograph of distal third metatarsal bone showing metaphyseal shouldering, metaphyseal sclerosis, and widening of the physis.	113
Figure 6.2	An invaginated type lesion showing: a) the gross appearance in the articular and epiphyseal cartilage of the proximal humerus and distal scapula and, b) the histological appearance of cartilage invagination in the proximal radius, showing fibrocartilage adherent to the articular cartilage, chondrones, subjacent myelofibrosis, and a mature subchondral microfracture.	121- 122
Figure 6.3	A retained cartilage lesion showing: a) the gross appearance in the lateral trochlear ridge of the distal femur and, b) the histological appearance in the distal third metacarpal bone showing a widened zone of hypertrophic cartilage, a decrease in matrix staining, subjacent myelofibrosis, and a subchondral microfracture associated with fibrin and necrotic cartilage.	123
Figure 6.4	Low power micrograph of a retained cartilage lesion in a “trough” of the distal radial physis, showing retention of physeal hypertrophic chondrocytes protruding into the metaphysis.	125
Figure 6.5	Percentage trabecular covered area of the metaphyseal spongiosa 10 mm proximal to the physis, and width of the distal radial physis in control and copper supplemented foals, measured from medial to lateral in a standard section of the distal radii in 13 foals (150 days of age)	126

Figure 7.1	Copper indices in weanling Thoroughbred fillies grazing pasture with low (n=6) or high (n=6) molybdenum concentration. a) Plasma copper concentration. b) Plasma caeruloplasmin oxidase activity. c) Blood cell copper concentration. d) Red blood cell superoxide dismutase activity.	138
Figure 7.2	Mean liver copper concentration from weanling Thoroughbred fillies on high molybdenum (n=6) and low molybdenum (n=6) pastures.	139
Figure A1	Mean plasma copper concentration and caeruloplasmin activity of mares receiving a single dose of copper sulphate (500 mg) on day 0, and controls.	161
Figure A2	Plasma copper concentration of individual mares receiving a single dose of copper sulphate (500 mg) on day 0, and controls.	162
Figure A3	Caeruloplasmin activity of individual mares receiving a single dose of copper sulphate (500 mg) on day 0, and controls.	162
Figure A4	Plasma copper concentration of pasture-fed pregnant mares receiving different levels of copper supplementation.	165
Figure A5	Caeruloplasmin activity of pasture-fed pregnant mares receiving different levels of copper supplementation.	166
Figure A6	Plasma copper concentration of two foals following laparoscopic liver biopsy and growth plate biopsy performed under general anaesthesia.	168

List of Tables

		Page
Table 1.1	Studies on the influence and heritability of osteochondrosis (OC) from Scandinavian countries.	18
Table 2.1	Copper concentration (mg/kg dry weight) at six sites across the liver of six feral horses, with mean, standard deviation (sd) and coefficient of variation (cv).	61
Table 2.2	Liver copper concentration (mg Cu/kg dry weight) with standard deviation (sd) and coefficient of variation (cv) of 30-60 mg (fresh weight) samples taken at 12 sites within each liver, and the total liver (homogenised) copper concentration, from three mature horses.	62
Table 4.1	Effect of copper supplementation of mares on mare (n=16) and foal (n=21) liver copper concentration (mg Cu/kg DM) at 4 to 10 days postpartum.	85
Table 5.1	The mineral composition of the tall fescue pasture from May 1994 to March 1995 and tall fescue hay fed to the mares to supplement the pasture diet from May to July 1994.	98
Table 5.2	Effect of copper supplementation of the mare prepartum, and the foal from 21 to 150 days on the mean copper concentration (mg Cu/kg DM) of foal organs at 150 days.	103
Table 5.3	The mean ash, copper, zinc, iron, calcium and phosphorus concentration of the atlas and ilium from all foals (n=21).	104
Table 6.1	Mean physitis scores from radiographs of the distal metatarsus of all foals at 150 days of age.	118
Table 6.2	Pooled mean values (n=21) for physical properties of the foal bones at 150 days of age.	118
Table 6.3	Number of foal articular cartilage lesions by classification at 150 days of age according to mare and foal treatment.	119
Table 6.4	Number of foal physal cartilage lesions at 150 days of age according to bone and mare and foal treatment.	119
Table 6.5	Location of classified foal articular cartilage lesions at 150 days of age.	120
Table 7.1	Concentrations of sulphur, molybdenum and copper from the molybdenum treated and control paddocks.	136

Chapter 1

Introduction

1.1 Experimental hypothesis

Developmental orthopaedic disease (DOD) causes unacceptable wastage in the rearing of foals throughout the world. Dietary copper supplementation above National Research Council (NRC) (1989) recommendations (10 mg Cu/kg DM) in a small number of experiments resulted in a decrease in the incidence and severity of DOD in horses raised under North American management systems.

In the New Zealand Thoroughbred industry, pasture is the major part of the diet of pregnant mares and their offspring. However pasture provides dietary copper concentrations that are often below NRC (1989) recommendations. The dietary copper requirements of pasture-fed horses to provide adequate copper for healthy development of bone and cartilage, have not been studied. Therefore the work in this thesis is centred on the hypothesis that

“Dietary supplementation of pasture-fed New Zealand Thoroughbreds with copper reduces the incidence and severity of developmental orthopaedic disease.”

1.2 The New Zealand Thoroughbred

1.2.1 Brief history of the Thoroughbred racing horse

During the period of Imperial Rome, horse racing (usually in chariots) held great prestige. It was considered that in order to win races, it was necessary to have an Oriental horse. These horses were imported to Rome from North Africa (the Barbs), Turkey, Egypt and the Arabian Peninsula. The Romans contributed to the spread of these Oriental horses by using them in their invading armies and by breeding and trading them throughout Europe. By the time of the English invasion (55 BC) some Oriental blood was already noticeable in the Britons' horses, presumably having been traded across the Channel by the Belgians (Tesio 1958).

Under Roman rule came the inception of organised races on the British Isles (Tesio 1958; Edwards 1980). These races were very popular with the Britons, and they continued after the fall of the Roman Empire. Movements of the Crusaders (11th - 13th centuries), provided

great opportunity for further importation of the superior Oriental horses to the British Isles (Tesio 1958; Anonymous 1978).

Racing thrived during the periods of the Stuart and Tudor kings. In 1533 King Henry VIII, a great horse racing enthusiast, prohibited stallions from grazing on public lands. This was to improve the general quality of horses by encouraging judicious breeding with well bred stallions (Borton 1977; Tesio 1958). On two occasions, he was gifted “pure bred” oriental broodmares which figure prominently in the ancestry of Thoroughbreds (Tesio 1958).

In 1575, an eminent Italian horse breeder, Signor Prospero D’Osma was invited to the court of Queen Elizabeth, to rectify what was considered to be a deterioration in the quality of the royal racing stock. D’Osma was a firm believer in keeping blood lines pure, and in his records he comments that “ It is not advisable to mix two breeds of horses lest bastards be produced” (Tesio 1958). It is believed that during this period the foundation stock of oriental mares gifted to King Henry VIII were bred almost exclusively to Oriental sires (Tesio 1958).

The Puritans prohibited horse racing and betting, the royal studs were dispersed, and many horses were requisitioned by the state (Edwards 1980; Borton 1977). However, Cromwell himself was a keen horseman and there are records of him importing horses of pure oriental blood from Naples and the Orient (Tesio 1958). With the Restoration (1660) came the reopening of the racetracks, and racing thrived again (Edwards 1980). From the late 1600s until 1750, a number of Oriental sires were imported to the British Isles for the purpose of increasing speed in race-horses. Male lines survive in only three of these horses, namely the Byerly Turk, the Godolphin Barb (also called the Godolphin Arabian) and the Darley Arabian, from which all modern Thoroughbreds are said to be descended (Napier 1973; Borton 1977; Edwards 1980). The success of each stallion can be attributed to one stallion offspring, Godolphin Barb’s grandson Matchem (1748), Darley Arabian’s great great grandson Eclipse (1764), and Byerly Turk’s great great grandson Herod (1758), which were all outstandingly successful as racehorses and as sires.

The first stud book (1793), contained approximately one hundred broodmares and a similar number of sires (Tesio 1958). All were proven producers of winners and nearly all could be traced back to Oriental origins. From these horses came the term “Thoroughbred”, meaning carefully bred. This is an appropriate name for these horses which developed from a nucleus

of King Henry VIII purebred oriental stock, as they were carefully bred by D’Osma to imported Oriental stallions, and after many generations were selected on racing performance for entry into the studbook.

The Thoroughbred was bred primarily for speed at intermediate distances. The modern Thoroughbred differs from its antecedents which were nearly two hands (8 inches) smaller (Borton 1977) and were said to race with their heads and tails elevated in the fashion of Arabians (Napier 1973). Charles Darwin wrote about Thoroughbreds that, “By a process of careful selection and by careful training, the whole body of English racehorses has come to surpass in fleetness and size the parent stock.” (Anonymous 1978).

1.2.2 The Thoroughbred in New Zealand

Initially New Zealand relied on Australia for the importation of Thoroughbreds. The first Thoroughbred to be imported to Australia was the English-bred stallion Rockingham in 1799 (Edwards 1980) and the first Thoroughbred mare arrived in 1825. The yearling colt Figaro, which arrived in Wellington in 1840, was the first Thoroughbred to be imported to New Zealand (Redwood 1979).

The first New Zealand studbook, compiled in 1862, contained the pedigrees of 145 mares and 58 stallions (Redwood 1979). Since then New Zealand has become renowned as one of the world’s great Thoroughbred nurseries. An American horse buyer observed that “New Zealand enjoys the sunshine of California, the grass of Kentucky, and the rainfall of Ireland and there is not a more natural place to raise Thoroughbreds” (Bridewell 1993).

1.2.3 The Thoroughbred management system in New Zealand

The Thoroughbred industry in New Zealand is predominantly pasture based (Hunt 1994). High average rainfall and fertile soils along with a temperate climate allows for horses to graze pastures all year. The climate also allows for a longer growing season compared with many other countries (Hunt 1994), and minimises the requirements for supplementation.

Due to the imposition of the Thoroughbred horse’s birthday in the Southern Hemisphere on August 1, most foals are born in late August, September and October to give them the greatest opportunity to mature and therefore successfully compete in the sales ring and on

the race track with other horses of the same “age”. This imposed foaling season coincides with Spring pastures, which in general provide adequate feed for the late pregnant and lactating mare, and the neonatal foal. It is also during Spring that yearlings are being prepared for sale. To maximise growth rates, and body condition, yearlings may be fed supplements of high energy concentrates in addition to the highly digestible pasture feed available at that time.

Yearling value is of prime importance to horse studs (Bridewell 1993), because the majority of Thoroughbreds are intended for sale as yearlings. However, sale of weanlings produces a significant part of many studs’ revenue. Value at sale is determined jointly by pedigree and an individual’s type. Type consists of conformation, size, and the presence or absence of defects. No matter how good the pedigree of a particular individual, a conformational defect or the presence of a defect in bone and cartilage development is likely to significantly reduce sale value, or prevent sale.

1.2.4 Wastage

Yearlings and weanlings must be presented to sales in the best condition possible. Withdrawal from sales is considered a better option than presenting an animal to the sales in poor or an unsatisfactory condition. One significant cause of late withdrawal is DOD, which may manifest as having unacceptable conformation or an unsound gait with corresponding clinical abnormalities.

O’Donoghue *et al.* (1992) found that 70 % of foals born in Ireland exhibited some form of DOD. Of these, approximately 10 % required treatment and half of those foals receiving treatment failed to reach expected sale value. Alvarado *et al.* (1989) found that only 25 % of yearling standardbreds on one farm had no radiological evidence of DOD. However they also found that radiographic evidence of DOD had no relationship with future athletic performance based on prize winnings.

Nutrition of the horse in its first year of life is likely to affect its immediate future in the sale ring, but it may also affect its future racing career. There is no epidemiological information linking the occurrence of DOD with future lameness in racehorses, but several researchers have proposed that there is a significant relationship (Krook and Maylin 1988, Stover *et al.* 1992, Kaneko *et al.* 1993).

1.3 Equine skeletal anatomy

1.3.1 Introduction

The skeleton of the horse consists of 205 bones. There are 20 bones in each forelimb and hindlimb, forming the appendicular skeleton. The other bones are found in the axial skeleton and consist of the skull, ribs, vertebrae and sternum (Getty 1975). Equine bones can also be divided into long, cuboidal, irregular and flat bones. The long-bones of the limbs function as weight bearing bones, and as levers in the process of locomotion. The cuboidal bones are in complex joints such as the carpus and tarsus, and dissipate concussive forces (Deane and Davies 1995). In other animals they also allow for a greater range of motion such as pronation in carnivores, but this greater mobility has been sacrificed in the horse in favour of greater stability and a resultant increase in speed. The flat bones (skull, rib and scapula) provide large areas for the attachment of connective tissues, and protect vital organs. The irregular bones are in the vertebral column, and provide the semi-rigid framework of the body, and protect the central nervous system. The formation of bone requires a connective tissue model, which in the case of long-bones is hyaline cartilage.

1.3.2 Anatomy of the growing long-bone

The growing long-bone consists of a diaphyseal shaft which is formed from the primary ossification centre of the original cartilaginous model. Secondary ossification centres are present at the ends of the long-bone, in either compression or traction epiphyses. Endochondral ossification is the process whereby bone is formed from the physis and from the epiphyseal cartilage. The region of newly formed bone on the side toward the primary ossification centre is called the metaphysis. Remodelling of this metaphyseal bone forms the diaphysis and medullary cavity. The joint surfaces of bone are covered by articular cartilage which is continuous with growth cartilage of epiphyseal origin. This cartilage is sometimes referred to as the articular-epiphyseal (A-E) complex. Endochondral ossification of the cartilage surrounding the epiphysis ceases first, and bone trabeculae form a subchondral bone plate adjacent to articular and physeal cartilage.

1.3.3 Physis

There are various classifications of histological zones in the physis. This thesis refers to the three main zones described by Brighton (1978), namely the reserve, proliferative and hypertrophic cell zones. The reserve cell zone (also called the resting cell zone) consists of slowly dividing cells arranged in a haphazard array of collagen fibres. The proliferative or stacking cell layer consists of rapidly dividing chondrocytes in columns arranged parallel to the longitudinal axis of the bone. The hypertrophic zone adjoins the proliferative zone and consists of cells of increasing size. The hypertrophic zone can be subdivided into the hypertrophic zone closest to the proliferative zone, and the zone of calcifying cartilage adjacent to the metaphysis (Olsson 1982; Brighton 1978).

Endochondral ossification consists of chondrocyte differentiation, cartilage calcification and chondrocyte death, followed by blood vessel invasion, cartilage matrix removal and bone formation. This process occurs in an ordered fashion in normal bone and cartilage development. Disruption of part of this process results in a retention of cartilage. This can occur both on the metaphyseal side of the physis, and also in the cartilage of the A-E complex at either subarticular or 'subphyseal' sites. Disturbance of endochondral ossification, the resultant cartilage retention and the sequelae in this tissue result in a group of diseases in growing foals called developmental orthopaedic diseases (DOD).

1.4 Developmental orthopaedic disease (DOD)

1.4.1 Introduction

The literal definition of developmental orthopaedic disease is any orthopaedic disease occurring during skeletal development. However the term, first coined at a symposium in 1986 on growth disorders in horses, has become associated specifically with diseases caused by a failure of the normal conversion of the cartilaginous model to bone. Therefore a list of diseases was made to comprise this syndrome. These include osteochondrosis, cuboidal bone malformation, physitis (and primary spongiosa microfracture), wobbler syndrome (cervical vertebral malformation), and angular and flexural limb deformities (McIlwraith 1986). There has been some debate as to whether other diseases such as juvenile arthritis should be included (Watrous 1991). Gabel (1988) proposed that the term "metabolic bone disease" be used because it implies a common pathogenesis namely the disorder in the conversion of cartilage to bone. This has not achieved much support because of its usage in

orthopaedic diseases after development such as post menopausal osteoporosis, and because it implies a disease of the bone and not associated cartilage (Jeffcott 1991).

Further confusion arises because Palmer *et al.* (1993) considers that DOD represents the clinical manifestations and sequelae of osteochondrosis, namely the diseases listed above, and yet, Hurtig and Poole (1996) make a greater distinction between OC and DOD in a discussion of these diseases. In this thesis, DOD is used as a collective term to describe diseases, with or without clinical signs, which have been associated with a disorder in the normal progression of endochondral ossification.

1.4.2 Osteochondrosis (OC)

Osteochondrosis is defined as a disorder in endochondral ossification. Initial descriptions of the disease were based on radiological and postmortem examination of clinical cases and incidental findings. Rooney (1975a, 1975b) described osteochondrosis (OC) in horses based on gross and histological observations of postmortem specimens. Predilection sites were identified, at which lesions were often present bilaterally. Lesions were divided into those occurring at the margin of joint surfaces, and those in non-marginal areas. Grossly, marginal lesions had a pedunculated mass of cartilage at the site of the lesion, whereas the non-marginal lesion was characterised by a groove or infolding of the cartilage, often continuous with a cystic structure in the subchondral bone. The lesion types had similar histological changes including retention of cartilage, failure of vascular invasion of the hypertrophic cartilage, and cartilage necrosis in the hypertrophic zone. The relationship between the marginal lesions of OC and the non-marginal lesions which develop into subchondral bone cysts has been debated and is reviewed by Baxter (1996).

In their extensive radiological, clinical and pathological investigation of OC in the femoro-patellar and tarso-crural joints of the horse, Stromberg and Rejno (1978) and Rejno and Stromberg (1978) also found that OC was often bilaterally symmetrical, and occurred in predilection sites. Predilection sites were observed to be located near insertion of tendons and joint capsules. The morphologic description of articular lesions was similar to that of Rooney (1975a, 1975b), and to lesions in pigs (Reiland 1978) and cattle (Reiland *et al.* 1978; Jensen *et al.* 1981), with the exception that there was a greater tendency for articular osteochondral fragments to be mineralised. The four histological hallmarks for OC were thickening of cartilage, disturbance of endochondral ossification, cartilage degeneration and

cartilage necrosis. Stromberg (1979) re-iterated the classifications as described by Rooney (1975a, 1975b) for articular cartilage lesions and also included physeal lesions in the syndrome of equine OC.

Pool (1993) has recommended that OC be divided into an idiopathic form resulting from a constitutional defect in the cartilage model, and an acquired form. The idiopathic form causes lesions, commonly bilaterally, in recognised predilection sites, and it is proposed that excessive biomechanical forces on a normal structure, or normal forces on a weakened structure, may be responsible for these lesions. The acquired form is proposed to cause generalised lesions without bilateral symmetry in a range of sites simultaneously, and may be caused by a variety of factors including nutritional excess and deficiency.

OC is clearly intimately related to DOD, but whereas DOD was previously defined as a collective term for diseases associated with a failure of endochondral ossification, OC is specifically characterised by a subsequent retention of cartilage.

Retained cartilage has been investigated histologically and biochemically to better define the lesion morphology in osteochondrosis. Brown and MacCallum (1976) identified retained cartilage in the distal third metacarpal and metatarsal physes of foals in a survey of normal foals. The authors considered that these may be within normal variation, or may have been evidence of the presence of subclinical physitis. Similarly, Hill *et al.* (1985) found retention of hypertrophic chondrocytes in a high percentage of one day old pigs examined. It was proposed that these retentions may have been part of the normal growth pattern for these pigs.

Retained cartilage lesions in the distal radial growth plate of foals at 3 to 70 days of age contained one of three abnormalities: retention of cartilage, retention of cartilage with discontinuity of the primary spongiosa (with or without identification of microfracture), and microfracture without retained cartilage (Firth and Poulos 1984). It was proposed that microfracture may be the fore-runner to cartilage retention with discontinuity of primary spongiosa, as unlike primary retention, the retained cartilage had regular borders. However, primary retention followed by microfracture could not be excluded. The possibility of the different types of OC having different aetiologies was raised. In a study of calves reared on concrete and clay flooring, mild retention of cartilage with no obvious discontinuity in the primary spongiosa was not considered to be a lesion (White *et al.* 1984).

Biochemical abnormalities include decreased concentration and aggregations in pigs (Nakano *et al.* 1979, 1985; Nakano and Aherne 1995) and horses (Lillich *et al.* 1997) and a decrease in the amount, crosslinking and relative distribution of collagen types (Wardale and Duance 1994). Farnum and Wilsman (1986) identified a pericellular matrix macromolecular material which supposedly stabilised the interface between chondrocytes and their matrix, which was disturbed in osteochondrotic cartilage. Other abnormalities include increased intracellular lipid inclusions in osteochondrotic articular cartilage of dogs, particularly in the superficial chondrocytes (Kincaid *et al.* 1985b; Carlson *et al.* 1986) and decreased carbonic anhydrase activity in osteochondrotic cartilage of pigs (Ekman and Ridderstrale 1992).

Investigation of the pathogenesis of avian tibial dyschondroplasia has indicated that retained chondrocytes are not a result of increased chondrocyte proliferation or diminished activity of osteo/chondroclasts, and that oxygen is not limiting to these cells. Instead, a failure of chondrocyte differentiation, such that there is an accumulation of transitional chondrocytes, has been implicated (Thorp *et al.* 1993). Unlike the findings of Wardale and Duance (1994), Thorp *et al.* (1993) found no difference in collagen type II distribution, and therefore concluded that the failure of chondrocyte differentiation could be localised to the transitional chondrocytes.

1.4.3 Physitis

Physitis (also referred to as epiphysitis, physosis, physeal dysplasia and physeal dyschondroplasia) is a disease associated with rapidly growing well muscled animals on a high plane of nutrition (Thompson *et al.* 1988).

The physes of the distal third metacarpal/metatarsal bone, distal radius and distal tibia are the most commonly affected (Turner 1987), but other physes, including those in the vertebrae (Mayhew *et al.* 1978; Powers *et al.* 1986), may also be involved. Physitis is considered to be a self limiting disease occurring when growth plates are open (Turner 1987; Firth 1990). There are two peaks of incidence in growing horses, the first is between 4 and 8 months of age, when the distal third metacarpal/metatarsal bone is most affected, and the second is between one and two years, in the distal radius and tibia (Turner 1987). The onset of physitis has also been linked with the period of closure of growth plates, and it has

been proposed that this may be due to an increased susceptibility of the growth plates at this time to mechanical compression (Rooney 1963).

Mildly affected horses exhibit subtle pain free swelling of the physes, and appear otherwise normal. Severely affected horses have painful warm swellings at the level of the physes, and secondary problems such as contracted tendons (flexural deformities) and stress fractures may supervene (Fretz 1980; Auer 1983; Firth 1990).

Radiographic changes associated with physitis include angular limb deformities, metaphyseal flaring, broadening and asymmetry of the metaphysis, metaphyseal sclerosis, asymmetrical cortical thickness, regional flaring of the epiphysis, and a scalloping and wedging of the epiphysis (Turner 1987). Jeffcott (1991) considers that physitis is the clinical manifestation of physeal osteochondrosis, whereas McIlwraith (1996) disagrees and considers them separate entities. A distinction between physeal histological changes for physitis and the physeal form of osteochondrosis are not reported, but any differences are likely to be small (Firth 1990).

1.4.4 Cervical vertebral malformation (wobbler syndrome)

The two most common syndromes in cervical vertebral malformation (CVM) are cranial cervical vertebral instability most commonly present at the articulation between second and third cervical vertebrae (C2-3) to C4-5, and caudal cervical stenosis at C5-6 and C6-7 (Pool 1993). Cranial cervical instability occurs in young horses usually in their first year and is known as a dynamic instability, in which malformation of the dorsal facets results in stenosis that is exaggerated by flexion. Caudal cervical stenosis is a static stenosis, caused by enlargement of the articular process and/or soft tissue hypertrophy in horses usually between one and four years of age.

Mayhew *et al.* (1978) performed an extensive investigation of spinal cord disease and possible aetiologies. The authors found an association between CVM (which they called cervical stenotic myelopathy) and well grown horses. It was proposed that the risk of developing CVM was enhanced by performance based selection of horses for rapid growth and large size, and excessive nutrition to ensure that genetic potential for growth was met. Donawick *et al.* (1989) also made the association between CVM and overfeeding and included vigorous exercise. These authors found that feed and exercise restriction of

affected young horses could ameliorate the clinical signs. Powers *et al.* (1986) examined 25 horses with cervical static stenosis, and in one horse, found evidence of osteochondrosis in the articular facet. Based on the extensive examinations at postmortem, the authors concluded that biomechanical forces and osteochondrosis were the most likely factors involved.

Mayhew *et al.* (1978) found increased osteochondrotic lesions in the costochondral junction in animals with CVM, although an increase in OC lesions in other joints was not found. However Stewart *et al.* (1991) examined 11 Thoroughbreds with CVM and found an increase in the frequency and severity of OC lesions in the limbs and an increase in the severity but not frequency of lesions in the cervical vertebrae compared with seven age and breed matched controls. These authors came to the conclusion that they could not implicate OC as the cause of the CVM but that the aetiological factors responsible for the CVM were likely to also predispose horses to OC. This was supported by the finding that in some areas compression sites were found without any evidence of physeal or articular OC.

Wagner *et al.* (1985a) bred two stallions with cervical vertebral instability to 12 mares with the same condition. This study was unable to demonstrate an increased incidence of CVM in offspring. However, the offspring suffered a high level of osteochondrosis, physitis and flexural limb deformities, but the numbers of animals were too small to test the significance of this association.

Pool (1993) considers that the pathological changes seen in cases of cervical vertebral malformation are not consistent with osteochondrosis, but instead are manifestations of hyperflexion in the case of cervical vertebral instability and hyperextension in cervical vertebral stenosis. He believes that the articular cartilage lesions are consistent with a secondary degenerative joint disease as a result of biomechanically induced remodelling.

1.4.5 Limb deformities

Limb deformities or "bent legs" are a common problem in growing foals. Limbs can be deformed such that there is a deviation in the normal conformation when viewed from along the long axis of the horse (angular limb deformity) or from the lateral perspective (flexural limb deformity).

1.4.5.1 Angular limb deformity (ALD)

Angular limb deformities most often occur at the carpus and less frequently in the tarsus and distal third metacarpal/metatarsal bone. Fretz (1980) describes five classifications for ALD which include imbalanced epiphyseal growth and defects in endochondral ossification of the cuboidal bones of the carpus and tarsus. With the former condition growth plate lesions can have the same radiographic and histologic appearances as found in physitis (Hurtig and Pool 1996), and OC may be associated with the latter (Fretz 1980; Auer *et al.* 1983). In a study of six foals examined for ALD, four had OCD in either the third or fourth carpal bones (McLaughlin *et al.* 1981). Most foals are born with a mild angular limb deformity (5 to 10 degrees) which resolves within about four weeks (Auer *et al.* 1982).

1.4.5.2 Flexural limb deformity

A number of factors have been implicated in the aetiology of flexural limb deformities including malposition *in utero* (Mason 1981), rapid growth (Hintz 1996) and musculoskeletal lesions that may cause pain (Wagner *et al.* 1985b) such as osteochondrosis (Moore and McIlwraith 1976). Foals receiving diets deficient in copper (1.7 mg Cu/kg DM) showed clinical signs of musculoskeletal pain and developed flexural limb deformities (Bridges and Harris 1988). Rooney (1966) carried out postmortems on approximately 50 affected fetuses and foals with flexural deformities and found no evidence of abnormalities in endochondral ossification, but all foals had malformed distal third metacarpal/metatarsal bones. Based on these findings, Rooney (1966) proposed that flexural deformity is secondary to joint instability and subsequent innervation of the musculature due to “random uncoordinated proprioceptive impulses”. The impulses cause the contraction of all muscles, but joint flexion results because the flexor muscles are stronger than the extensors. Szczurek *et al.* (1988) attempted to investigate the effect of confinement, level of nutrition and foot conformation on flexural limb deformities, but the condition could not be induced.

1.4.6 Proposed aetiologies for DOD

As a result of the limited ability of bone and cartilage to respond to injury, different aetiologies of DOD may cause morphologically similar clinical signs and/or postmortem lesions, despite having different mechanisms. This situation has been recognised with tibial dyschondroplasia in birds (Orth and Cook 1994) in which analysis of dyschondroplastic cartilage caused by different aetiologies appears similar but has different ultrastructural

abnormalities. As a result of this, information gained regarding a particular model for DOD may not pertain to other forms.

1.4.6.1 Growth rate

Mature skeletal dimensions are genetically predetermined, with the foal being approximately 60% of mature skeletal size at birth. However, nutrition can have a marked effect on growth rates, which is primarily due to an increase in body weight rather than skeletal growth (Green 1969). Even with undernutrition, height is less affected than body weight (Green 1961).

There is a remarkable similarity in growth curves for different species of horses in different climates and under different management regimes (Green 1961). Growth rates are maximal in neonates, and decrease with age (Green 1961). However growth rates in yearlings are considered to be more a function of season than age (Pagan *et al.* 1996), and yearlings in training stables can exhibit irregular growth rates (Green 1976). Thoroughbreds retain the capability for rapid growth (increase in weight) until 15 to 16 months of age, and in the next 4 -5 months will increase their weight by only around 10 % (Jelan *et al.* 1996). However, dogs fed restricted diets grew slower and had significantly decreased skeletal dimensions (Dammrich 1991)., while dogs fed *ad libitum*, had more OC lesions, and thinner metaphyseal spongiosa. Weakened subchondral bone support combined with extra skeletal requirements for weight bearing were strongly implicated as the causes for the OC lesions.

In a study on overnutrition in Great Danes, puppies were fed diets rich in energy, protein, calcium and phosphorus from birth to weaning. Severe abnormalities in endochondral ossification were found in the costochondral junction, articular cartilage of the humeral head and the cervical vertebrae. Other abnormalities in bone were found, and the lesions were associated with excessive apposition of bone and retardation in osteocytic osteolysis and chondrolysis (Hedhammer *et al.* 1974). High calcium may also have had a significant role in the induction of lesions and will be discussed below.

Reiland (1978) found that restricting growth rates in domestic pigs greatly decreased the incidence of OC. Rapid growth rate up to 4 months of age followed by restricted growth rates did not greatly reduce the incidence of lesions, indicating that the growth rate of pigs in the first 4 months of life may be of great importance to the incidence of lesions in older pigs. Progeny of pigs bred to wild hogs grew slower than pure-bred domestic pigs and had

no lesions of osteochondrosis compared with domestic pigs, of which approximately 90 % were affected. The domestic pigs commonly had a marked inferior prognathism which is a common finding in humans with acromegaly, and thus growth hormone may have a significant role in the induction of OC.

Similar effects of rapid growth rates have been found with poultry (Poulos *et al.* 1978), and bulls (Reiland *et al.* 1978). The bulls were slaughtered at similar weights thus the rapidly growing animals were examined at a younger age than the bulls on the lower energy intensity diet. This may have influenced this study if lesions tended to resolve in older animals (Reiland *et al.* 1978).

Pagan and Jackson (1996) found a pattern of onset of osteochondrosis lesions in foals on a Thoroughbred farm in Kentucky which may implicate high growth rates at particular times in development. For example hock and stifle lesions were commonly diagnosed between 304 and 335 days in heavy foals that were growing rapidly, and so it was considered that rapid growth in heavy foals following weaning may predispose to the clinical expression of these lesions. However in a recent study no significant differences were found in body-weight or height between normal and DOD-affected horses (Jelan *et al.* 1996).

1.4.6.2 Trauma

Internal trauma, or trauma due to ground reaction forces in response to weight bearing has become a popular theory for the aetiology of DOD.

Stromberg and Rejno (1978) considered that the bilateral and symmetrical nature of lesions indicated that the aetiology for DOD probably included an underlying cause other than simply trauma such as a metabolic derangement. However Pool (1993) has argued that the location of predilection sites in the horse coincide with areas of high biomechanical loads, and the bilateral nature of the disease may be due to the effect of excessive loading in a particular window of vulnerability. McIlwraith (1993) found that while lesions were often symmetrical, it was rare for more than one set of joints to be affected, supporting the biomechanical aetiology operating in a window of vulnerability. Firth *et al.* (1988) proposed that altering hoof balance using wedges on the weight bearing surface of the hoof may predispose horses to OC, but this did not provide a model for OC and alterations to compressive forces and strain in the limb returned to normal over 10 days without any lasting side-effects.

Experimental evidence for the biomechanical aetiology was provided in pigs by inducing OC in a front leg by tying up the contralateral leg (Grondalen and Grondalen 1974). Olsson and Reiland (1978) proposed that the location of naturally occurring lesions in pigs at sites subjected to greater than normal biomechanical forces, suggests that weight-bearing or ground reaction forces may be an important triggering factor for OC, but not sufficient on its own. Nakano and Aherne (1988) found that the prevalence of OC dramatically increased after loading and unloading pigs on a transport vehicle, compared with control pigs. Trauma was considered to be an important factor in increasing the severity and prevalence of lesions found in calves raised on concrete floors compared with controls on clay (White *et al.* 1984). Pool (1993) has recognised the difficulty in differentiating between lesions caused by normal biomechanical activity on weakened connective tissue versus excessive biomechanical activity on normal connective tissue structures.

The presence of OC lesions in the costochondral junction of pigs (Reiland 1978), horses, (Rejno and Stromberg 1978) and calves (White *et al.* 1984) was considered to mitigate against biomechanical trauma being the primary cause. However, the costochondral junction probably experiences continual traction and compression forces due to respiratory movements, support of the vertebral column and support of thoracic and abdominal contents.

1.4.6.3 Ischaemia

A failure of vascular penetration of the zone of hypertrophic chondrocytes has been recognised as a consistent histological feature of osteochondrosis (Jeffcott 1991). Experimental disruption of the metaphyseal blood supply at the ossification front of physes will reproduce retained cartilage lesions (Trueta and Amato 1960).

The role of cartilage canals in the pathogenesis of OC has been investigated in swine (Kincaid and Lidvall 1982; Kincaid *et al.* 1985a; Woodard *et al.* 1987b; Visco *et al.* 1991), and more recently in horses (Carlson *et al.* 1995). Cartilage canals provide conduits for a capillary network in the “growth” cartilages, have been associated with the nutrition of these cartilages (Stockwell 1971), and are found in epiphyseal, but not articular cartilage (Carlson *et al.* 1989; Firth and Poulos 1983). Disruption of these canals may cause an ischaemic necrosis of the cartilage consistent with the earliest lesions of osteochondrosis (Kincaid *et al.* 1985a; Woodard *et al.* 1987b; Carlson *et al.* 1989). It has also been shown that large

forces applied to articular cartilages of dogs, that were insufficient to cause long bone fracture, caused chondrocyte necrosis (Donohue *et al.* 1983). These large *in vivo* forces may cause degeneration of cartilage canals, especially in anatomical locations where immature cartilage is excessively thick. Degeneration of cartilage canals might also be part of the normal process of cartilage maturation with age, but Woodard *et al.* (1987b) proposed that in OC, the associated cartilage necrosis and chondrolysis is excessive.

In a recent study, Carlson *et al.* (1995) found that cartilage canals in medial femoral condyles, lateral femoral trochlear ridge and distal ends of the tibia and proximal phalanx were evident only in horses less than 7 months of age, and that lesions of osteochondrosis found in horses between 3 weeks and 5 months of age were always associated with necrotic cartilage canal blood vessels. This strongly supports the role of cartilage canals in the early lesions of OC and suggests that the formation of lesions has a remarkably narrow time frame. This narrow “window” is supported by a radiographic survey performed on 77 standardbreds in Sweden (Carlsten *et al.* 1993), in which 19 (25 %) horses had radiographic lesions consistent with osteochondrosis of the tarsocrural or fetlock joints at 12 months of age. Four horses showed radiographic changes before 1 month of age, four before 3 months, and 11 before 5 months. Eighteen horses had early radiographic changes which had resolved before 8 months. No new lesions developed after 8 months of age. The conclusion was that osteochondrosis of the fetlock and tarsocrural joint develops early, and can be considered permanent in cases which persist until 12 months of age (Carlsten *et al.* 1993).

1.4.6.4 Genetics

In 91 cases of equine OC diagnosed at the Royal Veterinary College in Stockholm, Stromberg and Rejno (1978) found an over-representation of the progeny of two sires. One was an English Thoroughbred stallion renowned for having foals that became large horses, and the other a Swedish Thoroughbred stallion. The authors noted that, in general, animals affected with OC grew rapidly and were offspring of large parents.

Further studies have been performed in Scandinavia, using larger numbers of standardbred and warmblood horses. The detection of osteochondrosis was based on radiographic studies of certain predilection sites, and the true incidence of OC was probably greater than reported because of the difficulty in detecting mild cartilage lesions. The incidence varied from 10 to 26 % in different populations, with all studies showing a difference in the incidence of OC in the progeny from different stallions. The variable difference between stallions suggests

that the mode of inheritance is polygenic rather than due to a single gene pair (Philipsson *et al.* 1993; Philipsson 1996). Schougaard *et al.* (1990) examined the progeny from two cohorts of two standardbred stallions and found little difference in the incidence of OC in the progeny, between years, compared with the (large) difference in incidence between the two stallions. Therefore it was concluded that genetics appeared to be more important than environment in the incidence of OC in that population. Heritability estimates from these studies are summarised in Table 1.1. The heritability of OC in these populations appears to be quite high, suggesting that breeding policies to reduce the incidence of osteochondrosis would be successful. The observation that some sires are asymptomatic but produce progeny with a high incidence of OC suggests that progeny testing would be the most successful technique for selecting stallions.

Table 1.1 Studies on the incidence and heritability of osteochondrosis (OC) from Scandinavian countries

Author	Breed	Horse Numbers		Area examined	Incidence	Heritability
		Sire	Progeny			
Hoppe and Philipsson 1985	Standardbreds					
	Sweden	69	130	Hock	26.2	Not Done
	Gottland	60	208	Hock	10.1	Not Done
	Swedish Warmbloods	39	99	Hock	15.2	Not Done
Schougaard <i>et al.</i> 1990	Standardbreds	9	325	Hock	14.2	0.26
Grondahl and Dolvnik 1993	Standardbreds	39	753*	Hock	14.3	0.52
				Fetlocks	11.8	0.21
Philipsson <i>et al.</i> 1993	Standardbreds					
	Random	24	674	Hock	10.5	0.34
	With OC	4	119	Hock	16.8	(all horses)

* Only 644 horses were used for heritability calculations.

Pool (1993) considers that the identification of DOD caused by nutritional or other managerial causes is necessary before animals can be culled from the genetic pool. This assumes that animals showing DOD as a consequence of nutritional or managerial causes are not manifesting the disease because of a genetic predisposition. This assumption may not be valid.

There are likely to be differences in the incidence and heritability of OC in different populations of horses, and also on the effect of environment on the incidence of DOD. The incidence and heritability of OC in Australian and New Zealand Thoroughbreds have not been studied

1.4.6.5 Nutrition

Energy

Glade and Belling (1984) found that diets high in energy and protein caused a high, early peak in insulin and glucose, and relatively low T4 levels postprandially. It was proposed that the high, early insulin peak stimulated the conversion of T4 to T3, preventing the “normal”, transient, postprandial hyperthyroxemia. It was postulated that this hyperthyroxemia was important in the differentiation of hypertrophic chondrocytes. In a further experiment Glade and Belling (1986) found that high energy/protein diets fed to weanlings were associated with decreased hexosamine and hydroxyproline content and increased DNA content of physeal cartilage harvested *in vivo* from the distal radial growth plate. These findings indicated a decreased production of cartilage matrix by chondrocytes, and an increase in chondrocyte cellularity. It was proposed that these changes to the matrix may have been responsible for a failure of metaphyseal capillary invasion. Further support for the role of aberrations in endogenous hormones was provided by Ralston (1996) who found that postprandial glucose and insulin in four horses with OCD was significantly higher than in 15 controls.

Savage *et al.* (1993a) fed foals 129 % NRC (1989) energy recommendations for 16 to 18 weeks, and found a significantly greater incidence of dyschondroplasia (OC) than in controls fed 100 % NRC (1989) energy recommendations. No mechanism could be elucidated from this trial, and glucose, insulin and thyroid hormones were not measured. There was no significant effect of dietary energy level on average daily live weight gain, which would preclude a biomechanical aetiology unless high energy diets resulted in a greater degree of activity in their restricted pens. The source of supplemental energy was maize oil and maize starch (fat and complex carbohydrates) which was expected to have less effect on insulin and glucose than the soluble carbohydrates fed in the work of Glade and Belling (1986). However in the work of Savage *et al.* (1993a), the failure of an increased energy intake to increase live weight gain is surprising.

Variable results have been obtained from a number of experiments with pigs, investigating the relationship between dietary energy, growth rate and OC (Nakano *et al.* 1987). Carlson *et al.* (1988) recognised the difficulty in differentiating the effect of increased bodyweight from increased growth rate, and therefore they slaughtered gilts receiving different levels of dietary energy at the same weight, and found that at the same weight, the high dietary energy group had a higher incidence of OC.

Protein

Savage (1993a) fed foals on two different levels of dietary protein (100 and 129% NRC (1989) recommendations. None of the foals receiving the high protein diet had clinical or radiographic evidence of dyschondroplasia (OC), and at postmortem the incidence of lesions was not significantly different between the two diets. Schryver *et al.* (1987) found that protein diets at approximately 140 % of NRC recommendations had no skeletal effects in growing horses including calcium and phosphorus metabolism. Several investigators found that the dietary level of protein in pigs had no effect on the occurrence of skeletal lesions (Reiland 1978); Woodard *et al.* 1987a; Jorgensen 1995).

Calcium/Phosphorus/Vitamin D

Excessive dietary calcium can affect bone by increasing growth rate, increasing calcitonin production, decreasing trace mineral absorption and decreasing iodine uptake by the thyroid gland (Kronfeld *et al.* 1990). Krook and Maylin (1988) considered that high dietary calcium was a major factor in the presence of lesions associated with catastrophic racetrack fractures. Osteochondrotic lesions were often associated with osteoporosis, and the lesions were consistent with changes found with hypercalcitonism. However, Savage *et al.* (1993b) found no effect of feeding 1.95 % calcium to weanling foals which is greater than 3 times NRC (1989) recommended levels on the incidence or severity of OC lesions. Knight *et al.* (1985) performed an epidemiological study of the influence of dietary components on DOD on several farms in Kentucky and Ohio, and found that farms with the highest incidence of DOD had the lowest dietary calcium levels (other dietary associations were also reported).

Slater *et al.* (1992) performed a matched case control study in dogs and found that high dietary calcium was associated with an increased risk of having OC. In another study (Hazewinkel *et al.* 1985; Goedegebuure and Hazewinkel 1986), Great Dane puppies fed three times the recommended levels of calcium had an increase in lesions consistent with OC, including retention of articular and physeal cartilage, disturbances in endochondral

ossification, and retarded maturation and remodelling of trabecular and cortical bone. The authors postulated that hypercalcitoninism and hypoparathyroidism may have been responsible for the lesions although these changes were not supported by circulating levels of these hormones. High levels of dietary calcium have caused parafollicular cell hyperplasia in beagles (Stephens *et al.* 1985) and also in foetuses of ewes fed supplementary calcium (Corbellini *et al.* 1991). The high concentrations of calcitonin impair the normal process of osteoclastic and chondroclastic resorption resulting in osteopetrosis and impaired endochondral ossification. The dogs receiving high levels of dietary calcium had lower growth rates, and so it was concluded that the effect of calcium on lesions was independent of growth rate.

Diets high in phosphorus and low in calcium result in an increased production of parathyroid hormone which increases bone calcium resorption, causing nutritional secondary hyperparathyroidism. Diets high in phosphorus can also interfere with calcium absorption due to the formation of complexes which bind calcium. This dietary abnormality can be caused by grain based diets high in phosphorus and low in calcium, inadequate vitamin D, and pastures high in oxalates. Savage *et al.* (1993b) found that feeding foals diets containing 1.7 % phosphorus (388 % NRC 1989 recommendations) for 16 to 18 weeks significantly increased incidence of dyschondroplasia (osteochondrosis) compared with controls. The mechanism was not elucidated, but in poultry, high phosphorus diet are considered to cause an acidosis, by exhausting cationic buffering, which interferes with provisional calcification (Lilburn *et al.* 1989). However sodium bicarbonate fed to pigs did not reduce the incidence of skeletal disease (Van der Wal *et al.* 1986).

Vitamin D metabolites affect calcium and phosphorus metabolism by increasing their intestinal absorption, decreasing their urinary excretion, as well as increasing osteoclastic bone resorption. Vitamin D can also regulate the expression of osteoblast phenotype, demonstrating an ability to influence osteoblast differentiation and matrix competence (Owen *et al.* 1991). Inadequate vitamin D is unlikely to occur in horses at pasture because their dietary vitamin D requirement is low, as they obtain ample exposure to sunlight allowing the synthesis of Vitamin D in the skin.

Copper/Zinc/Molybdenum

There is a growing weight of evidence to support the role of copper deficiency in the aetiology of DOD, and in particular but not limited to physitis.

Copper deficiency in horses was first considered in 1949 when it was investigated whether supplementary copper fed to horses would decrease the prevalence of cartilage erosions found incidentally at necropsy (Cupps and Howell 1949). Numbers of animals were insufficient to test the significance of the relationship between copper nutrition and abnormalities in bone and cartilage development, but results from this study have formed the basis for the NRC copper requirements.

More recently copper deficiency has been induced experimentally in foals, by feeding diets containing 1.7 mg Cu/kg DM (Bridges and Harris 1988). The clinical signs that developed were predominantly related to disorders in endochondral ossification. The foals first developed intermittent diarrhoea which coincided with decreasing serum copper concentrations. Lameness, stilted gait and tendon contracture developed within 6 weeks of the decrease in serum copper concentrations, but there was no apparent change in common indices of copper deficiency in other species such as packed cell volume, white blood cell count, coat colour and growth rates. At necropsy, there were lesions in the articular and growth plate cartilages consisting of retention of viable cartilage beyond the ossification front, areas of necrotic cartilage with intracartilaginous fractures in the hypertrophic zone of articular-epiphyseal and physeal cartilage, and eosinophilic streaks. Cartilage flaps, and free cartilage separated from joint surfaces were also present within the joint. Collagen solubility was 3 to 6 fold greater in deficient than control foals. It was presumed that a reduction in lysyl oxidase activity was likely to be responsible for the clinical signs, although the enzyme was not assayed. A similar increase in collagen solubility, and also a decrease in lysyl oxidase (amine oxidase) activity has been found in the bones of chickens raised on copper-deficient diets (Rucker *et al.* 1969).

In a study of 19 farms in Ohio and Kentucky, Knight *et al.* (1985) found that there was a significant negative correlation between dietary copper concentration and the prevalence of DOD. After adjustment of dietary rations, there was a significant decrease in the prevalence of DOD (Gabel *et al.* 1987), and copper was the nutrient intake which changed most significantly. Epidemiological studies in Japan on pasture based weanlings also found a significant negative correlation between pasture copper concentrations and the clinical

evidence of physitis of the fetlock (Fujikawa *et al.* 1993; Asai *et al.* 1993), but not the distal radius (Asai *et al.* 1993).

There are reports of favourable clinical responses of fetlock physitis to copper supplementation in Ireland (Egan and Murrin 1973a), New Zealand (Carberry 1978) and North America (Hildebran and Hunt 1986). However these trials were poorly controlled with several factors changing simultaneously.

Copper supplementation trials have been performed on mixed breed foals in North America (Knight *et al.* 1990; Hurtig *et al.* 1990, 1993). Knight *et al.* (1990) fed mares and foals with 32 and 55 mg Cu/kg DM respectively compared with mare and foals receiving 13 and 15 mg Cu/kg DM respectively. Foals were euthanased at either 90 or 180 days. There was a significant effect of copper supplementation on decreasing the incidence of lesions at 180 days. Lesions consisted of thickening of articular and physeal cartilage, associated with a failure of vascular invasion, often with eosinophilic streaks, necrosis in the hypertrophic chondrocytes and subchondral fibrosis. Thinned cartilage and osteophytes were also scored as lesions. The effect of mare supplementation could not be separated from that of foal supplementation, and there was little information on the copper status of the animals. Hurtig *et al.* (1990, 1993) studied Quarter horse and Quarter horse x Thoroughbred foals, a number of which had pre-existing OC (in particular femoropatellar OCD). Copper supplemented foals received 25 mg Cu/kg DM versus 8 mg Cu/kg DM for controls. Both groups received 120 % NRC recommendations for energy and protein as this was considered to be normal husbandry practice. The 3 to 4 month old foals received the experimental diets for 5 months, after which time all foals were euthanased. Copper supplementation significantly decreased the incidence of DOD, and produced histomorphometric evidence of an increase in subchondral bone volume and more trabeculae in the primary spongiosa. However histomorphometry was performed on a subset of the foals, the selection of which may have been biased, being based on the presence of lesions in the low copper group. The lesions were categorised as cartilaginous flaps, osteochondral fragments that were undermined or free in the joint space, cartilage thinning with erosion and eburnation, and cartilage defects with subchondral cavitation. No foal in the copper treated group had clinically significant DOD, and it was considered that including foals with pre-existing disease in both groups demonstrated a palliative effect of high copper diets on OC. In this experiment liver copper concentration in the low copper group declined and was considerably lower than in the supplemented animals, but there was no difference in the serum copper concentration or

caeruloplasmin activity between groups. Biochemical studies of the articular cartilage of severely affected foals demonstrated a decrease in collagen crosslinking, and it was proposed that the effect of copper supplementation was to improve the biomechanical structure of the cartilage and subchondral bone matrix. Both of the above trials found a large number of lesions in the cervical vertebrae, and it was suggested (Hurtig *et al.* 1990) that this site may be a good location for occult joint lesions in foals suspected of having OC. It was further considered that the lesions created in the low dietary copper group occurred in multiple sites and the disease more resembled that found in copper deficient cattle than naturally occurring OC in horses.

A well-reported syndrome of lameness in cattle attributed to copper deficiency and often linked to high molybdenum intake (Suttle and Angus 1978), includes osteoporosis, beading of the ribs, spontaneous fractures and enlargement of the fetlock joints. The predominant histopathological and radiological changes include an irregular widening of the growth plates, with tongues of retained cartilage (Irwin *et al.* 1974; Mills *et al.* 1976; Suttle and Angus 1978). Calves raised on copper-deficient diets (1.5 mg Cu/kg DM) exhibit angular limb deformities, lameness, and swollen joints. The physis is focally thickened, with overgrown disorganised cartilage columns and some metaphyseal cartilage sequestration. Osteoblast numbers are depleted, but osteoclasts are numerous and mineralisation appears to be unaffected. Subchondral bone becomes rarefied with some cross trabeculation (Suttle and Angus 1978). Irwin *et al.* (1974) distinguished the changes seen with a molybdenum-induced copper deficiency, which caused a “rickets-like” physeal widening, from the focal retentions seen in primary copper deficiency.

Lambs raised on copper-deficient diets developed metaphyseal osteoporosis without widening of the growth plate, and was considered to be secondary to an inhibition of osteoblastic activity (Suttle *et al.* 1972). Copper deficient lambs also exhibit decreased growth rates, spontaneous fractures, periosteal and muscle insertion lifting and haemorrhage (Hogan *et al.* 1971).

OC associated with copper deficiency has been described in red deer in New Zealand (Thompson *et al.* 1994). The lesions which were similar to those found in the experimental copper deficiency of foals (Bridges and Harris 1988), included intracartilaginous fractures and flap formation in articular cartilage surfaces, as well as epiphyseolysis in severe cases.

Lesions occurred commonly in carpal, tarsal, femoropatellar and coxofemoral joints, and were usually bilateral.

The role of copper in DOD has been presumed to be due to a reduction in the activity of the cuproenzyme lysyl oxidase (Bridges *et al.* 1984; Bridges and Harris 1988). This is supported by the similarities of growth plate lesions seen with osteolathyrism and those induced experimentally in copper deficient rats fed thiomolybdates (Spence *et al.* 1980) in which the growth plate abnormalities included cartilage dysplasia resulting from a decrease in osteogenesis, which progressed to the cessation of osteogenesis. However the activity of lysyl oxidase on copper deficient diets has not been measured in horses.

There are a number of reports of skeletal abnormalities in horses fed excessive amounts of dietary zinc either experimentally (Willoughby *et al.* 1972; Bridges and Moffitt 1990) or by ingestion of polluted feed (Gunson *et al.* 1982; Eamans *et al.* 1984; Campbell-Beggs 1994). Clinical signs and pathological changes (severe generalised OC) were consistent with the changes found by Bridges and Harris (1988) in foals fed a copper deficient diet, and a zinc induced secondary copper deficiency was the most likely cause for the skeletal changes. Bridges and Moffitt (1990) found that foals fed over 1000 mg Zn/kg DM had significantly lower serum copper concentration, and at euthanasia after 9 to 22 weeks on the high zinc diets the serum copper concentration was less than 0.2 mg Cu/l.

Manganese

Manganese is important for the integrity of connective tissue matrices, through its role in the production of chondroitin sulphate, and also by its activation of alkaline phosphatase (Georgievskii *et al.* 1982; Lewis 1995). Manganese deficiency may have been responsible for a case of weak, brittle bones and lameness with joint pain in a neonatal foal on pasture polluted with smelter effluent which had been treated with high concentrations of lime to decrease soil pH, and consequently with decreased manganese availability (Cowgill *et al.* 1980).

Vitamin A

Vitamin A is a lipid soluble vitamin that induces the production of osteocalcin (Schule *et al.* 1990), and thereby regulates osteoblast activity. Reiland (1978) found no effect of supplemented vitamin A (3500 to 15000 IU/kg bodyweight/week) in a group of pigs with a high incidence of osteochondrosis. Vitamin A supplementation at very high levels (100 to 1000 times NRC (1989) recommendations) caused physitis and contracted tendons in a small number of fillies (Kronfeld *et al.* 1990). Supplementation with vitamin A was also associated with an increased incidence of DOD on farms in Kentucky and Ohio (Knight *et al.* 1985). Vitamin A may interact with trace element metabolism, and should therefore not be supplemented excessively (Kronfeld *et al.* 1990).

1.4.6.6 Dexamethasone

Glade *et al.* 1983 found macroscopic histological changes consistent with OC in the proximal femoral physis and articular/epiphyseal cartilage of pony foals treated with 0.5 mg dexamethasone/ 100 kg bodyweight/ day for 3, 8 or 11 months, and horse foals treated with 5.0 mg/ 100 kg bodyweight / day for 20 weeks. The changes consistently showed a decrease in chondrocyte activity, and a failure of epiphyseal or metaphyseal vessels to penetrate hypertrophic cartilage.

1.4.6.7 Hypothyroidism

Hypothyroidism has been investigated as a cause of DOD in Canada. A syndrome has been defined in animals diagnosed with hyperplastic goitre, secondary to excessive nitrate intake. The skeletal abnormalities include delayed ossification, stunted stature, cuboidal bone hypoplasia, angular and flexural limb deformities and mandibular prognathism (McLaughlin and Doige 1981). This condition is congenital, and without disruption of endochondral ossification, and it is not considered to be a DOD. However another foal was diagnosed with hypothyroid of unknown aetiology, and had severe OCD evident clinically and at postmortem, as well as physeal retained cartilage and transverse trabeculation in the metaphyses (Vivrette *et al.* 1984). This may indicate that hypothyroidism should be included as a possible cause of DOD.

1.4.6.8 Infection

The proposal that ischaemic necrosis of cartilage is important in the pathogenesis of DOD indicates that thrombogenic vascular occlusion due to haematogenous bacteria may be associated with osteochondrotic lesions. Firth and Goedegebuure (1988) have shown that

predilection sites for septic arthritis include locations in the epiphysis with the thickest cartilage. Growth plate lesions were found predominantly in sites of greatest inclination. These sites are also commonly affected with DOD. This association has not yet been investigated.

1.4.7 Conclusions from the review on DOD

The exact relationship between the different diseases comprising DOD remains contentious, and the nomenclature is potentially confusing due to different interpretations of definitions. For example these may refer to aetiological factors of a subtle intrinsic nature (for example organelle based abnormality), or to gross, non quantifiable extrinsic factors such as biomechanical forces acting on tissue. This is further confused because the term DOD is used to refer to abnormalities present, unseen and possibly undetectable by conventional pathological examination, as well as abnormalities that are present and identifiable but clinically silent, or lesion present and clinically evident.

The pathogenesis of a disruption in endochondral ossification is difficult to study due to the uniformity of the response of bone to a range of insults, the lack of pathognomonic changes in affected bone and cartilage, and the overriding effects of continued weight bearing on damaged tissue. Distribution of lesions has been suggested as a useful method of differentiating aetiologies, but this is based mainly on opinion and observations.

Tissue from retained cartilage lesions has been investigated in several species, including the horse, to define the nature of lesions. These are useful approaches to investigate abnormalities present in affected cartilage, and may be helpful in identifying potential aetiologies. However, it is impossible to differentiate between changes to tissue that cause lesions, or changes occurring due to the presence of lesions. There remains a need for controlled experimental studies to investigate possible aetiologies.

Several aetiologies are closely related. Excessive energy intake results in increased growth rate, which in turn increases trauma due to weight bearing, which may cause ischaemia by damage to cartilage canals. Other aetiologies such as excessive intakes of calcium, zinc and excessive dexamethasone administration all have the potential to influence copper availability, and further study may reveal a unified nutritional aetiology.

Excessive energy intake appears to be a reliable model for the induction of DOD, but the mechanism is still unresolved, especially issues regarding the effect of different energy sources. Copper deficiency is also a reliable model for the induction of DOD. Presently the dietary copper intakes that have been recommended by some authors are considerably higher than pasture diets can provide. Therefore copper may be an important factor in the high prevalence of DOD found in pasture-based horse raising systems, as utilised in New Zealand. It is evident that more information is required on copper metabolism in horses.

1.5 Review on copper nutrition

1.5.1 Introduction

Copper, discovered between 3000 and 6000 BC, was named after the Island of Cyprus, the location of the ancient copper mines (Wertime 1964). Since its discovery, it has had a great impact on humanity. Copper was valued as an ornamental metal, but it was also the first metal to be used for practical purposes in alloys with tin (bronze), zinc (brass) and nickel and zinc (nickel silver).

Copper was recognised as an essential nutrient in the 1920s, when rats fed copper-deficient diets developed an anaemia which would not respond to iron supplementation (McHargue 1926; Hart *et al.* 1928). Early work on copper requirements in horses was performed in 1949, when Cupps and Howell (1949) proposed that copper supplementation may prevent erosions found in articular cartilages. The horse numbers were too small to be conclusive, and the role of copper in bone and cartilage development of foals still remains a research priority.

Copper is a transitional metal with atomic number 29 and a mass of 63.5. There are two naturally occurring stable isotopes, ^{63}Cu and ^{65}Cu , in relative abundance of approximately 69 and 31 % respectively. There are 3 radioisotopes ^{61}Cu , ^{64}Cu , and ^{67}Cu , with half lives of approximately 3, 12 and 60 hours respectively. Copper ions exist as either the monovalent (cuprous) ion which forms tetrahedral complexes or the divalent (cupric) ion that forms square planar complexes and is a potent oxidising agent. In biological systems, copper is predominantly in the form of the cupric ion (Cu^{++}). However the cuprous ion (Cu^{+}) also exists, and the ready exchange of valencies accounts for copper's activity in oxidation-

reduction reactions and the scavenging of free radicals. At physiological pH, copper is almost completely bound, forming insoluble complexes. In acidic environments there are higher concentrations of free and chelated (protein-bound) copper.

1.5.2 Copper content and distribution in the body

There are little data on the distribution of copper in the body of horses, although Schryver *et al.* (1974) calculated the copper content of horses less than one year of age to be about 4 to 5 mg Cu/kg liveweight (LW) and Meyer and Ahlswede (1978) found the body copper concentration of neonates to be 5 mg Cu/kg LW. The high copper concentration in the neonate is largely due to the high liver copper store which accounted for approximately 60 % of the total body copper. The copper concentration in the neonatal liver varies widely, and in one survey liver copper concentration was found to vary from 181 to 874 mg Cu/kg DM at 1 to 2 weeks postpartum (Meyer and Tiegs 1995). Similar widely variable liver copper concentrations have been reported in horses up to eight months of age (Egan and Murrin 1973b). Schryver *et al.* (1974) found that liver copper accounted for approximately 2.5 to 5 percent of total body copper in horses from 12 to 24 months of age. This is very low compared with ruminants (Grace 1983a), and is contributed to by both a relatively low liver copper concentration (23 and 14 mg Cu/kg fat free DM respectively) and a high total body copper concentration. Cymbaluk and Christensen (1986) found a similar liver copper concentration in yearlings (approximately 20 mg Cu/kg DM), and slightly higher kidney copper concentrations (20 to 30 mg Cu/kg DM). Liver copper concentration is responsive to dietary copper intake, and was approximately 4300 mg Cu/kg DM in ponies fed a diet containing 790 mg Cu/kg DM (Smith *et al.* 1975). This ability of the liver copper concentration to vary widely according to dietary copper intakes is likely to cause large differences between studies on the copper distribution in horses, and any such study should include information on the dietary copper intake. It may also be helpful when presenting total body copper concentrations to separate values for the liver due to this wide variation, as is done in ruminants (Suttle 1979; Grace 1983a).

Schryver *et al.* (1974) found the total body copper concentration (excluding the liver) of more mature horses (24 months), to be approximately 3 mg Cu/kg LW. This is considerably greater than estimations of the copper content of man (Sass-Kortsak 1965) (with liver) and lambs and calves (Suttle 1979; Grace 1983a) (without liver), which are both approximately 1 mg Cu/kg DM.

1.5.3 Copper metabolism

There are few data on copper metabolism in horses and much information is extrapolated from studies on other species.

1.5.3.1 Absorption

The major site of copper absorption is the stomach and small intestine based on studies in which humans fed radioactive isotope (^{64}Cu) had rapid uptake of the isotope into systemic circulation (Bearn and Kunkel 1955). However it is believed that all segments of the intestine are able to absorb copper in ruminants (Grace 1975). The acid environment of the stomach is important in the dissociation of copper complexes, and constituents in the bile may improve absorption suggesting the importance of the jejunum and more distal intestine for copper absorption (Solomons 1988). One study on extensive large colon resection in horses found no decrease in copper absorption, although this may have been due to a wide variation in faecal excretion (Bertone *et al.* 1989).

Copper absorption is thought to require two distinct mechanisms. Copper in the intestinal lumen enters the mucosal cells by passive diffusion across an ionic gradient. Transport across the basolateral border of mucosal cells into interstitial fluids requires an energy dependent (ATPase) mechanism, which is saturable (Linder 1991). At high dietary copper intakes, additional transport mechanisms across the basolateral membrane are used. These additional mechanisms are the site for the competitive antagonism of other transitional metal ions (Linder 1991). The activity and abundance of the transport mechanisms are increased in cases of copper deficiency, pregnancy and cancer, and in humans they are decreased in the case of Menke's disease, a genetic disorder of copper absorption (Cohen *et al.* 1979; Linder 1991). Ionic copper in the mucosal cells is bound to a cytosolic protein called metallothionein. Metallothionein is likely to play an important regulatory role in the absorption of copper across the mucosal cells, and it is thought that with very high dietary copper, sloughing of mucosal cells laden with copper bound to metallothionein may be important in preventing toxicity (Bremner 1987).

Copper excretion via the bile results in large differences between apparent absorption and true absorption. Re-absorption of copper is negligible (Evans 1973). Studies with stable and radio-isotopes in humans estimate a copper absorption of between 40 and 70 % with wide

individual variation (King *et al.* 1978). Horses, ruminants, rats and humans demonstrate an ability to alter copper absorption relative to requirements with absorption increasing with low intakes, and decreasing with high intakes (Cymbaluk *et al.* 1981a; Woolliams *et al.* 1983; Turnlund *et al.* 1989; Linder 1991).

1.5.3.2 Transport and storage

After absorption, copper has two recognised distribution patterns. Absorbed copper, bound to plasma proteins, is taken to the liver which is the first phase of systemic copper distribution. In the liver, the copper is bound to caeruloplasmin and released into the circulation as the second phase of copper distribution. These distributions have been studied *in vivo* in rats and humans using radio and stable isotopes (Lee *et al.* 1993; Scott and Turnlund 1994).

Copper in the portal circulation is loosely bound to two plasma proteins, albumin and transcuprein. Copper is readily transferred between the two proteins *in vitro* (Linder *et al.* 1987). Albumin is abundant in plasma and can accommodate far more copper than is required for binding to absorbed copper in the portal circulation. Transcuprein is a larger protein than albumin, and the affinity of copper for transcuprein is considered to be greater than albumin as both proteins bind a similar amount of copper despite a much greater concentration of albumin in plasma (Weiss and Linder 1985; Tsai *et al.* 1992). A very small amount (0.5%) of absorbed copper is bound to small peptides and amino acids (Linder 1991). As the portal circulation delivers the copper complexes to the liver, they are transferred to metallothionein in the cytosol of hepatocytes. A small percentage of the copper complexes transported from the gut are not transferred to the liver, and enter the systemic circulation, and constitute the non-caeruloplasmin bound plasma copper (Linder 1991).

Metallothionein-bound copper in the liver is either stored bound to the metallothionein, excreted via the bile, combined with the transport protein caeruloplasmin or combined with other cuproproteins in the liver. Caeruloplasmin-bound copper enters the circulation and comprises the majority of circulating plasma copper.

1.5.3.3 Excretion of copper

Copper excretion is important in maintaining copper homeostasis. Copper is excreted predominantly in the bile, which has the highest copper concentration of all body fluids (Linder 1991). Copper in bile forms complexes that are poorly reabsorbed minimising enterohepatic recirculation. Copper is also excreted in salivary, gastric and intestinal secretions. Therefore fluids entering the digestive tract from bile and other secretions in humans contain 4 to 5 times as much copper as copper from dietary sources, indicating that there is significant reabsorption. However most of the copper which is reabsorbed comes from the non-biliary component of the secretions (Linder 1991). Cymbaluk *et al.* (1981a) recovered 70 % of parenterally administered dose of ^{64}Cu in the bile of bile duct cannulated ponies and only 3.6 % in the faeces, thus demonstrating the much greater contribution of biliary copper than gastric and intestinal secretions to copper excretion.

It is unclear how copper from other tissues is transported to the liver for biliary excretion (Linder and Hazegh-Azam 1996). It is possible that caeruloplasmin may return copper to the liver from other organs (a third phase of systemic copper distribution), and it has been proposed that, copper bound to caeruloplasmin destined for excretion is absorbed by hepatocytes and excreted in the bile. Caeruloplasmin is not readily degraded by digestive enzymes and may account for the lack of absorption of copper associated with biliary excretions (Linder and Hazegh-Azam 1996).

Urine is a minor route of copper excretion. This is probably due to the negligible concentration of free copper in the plasma, and the efficient reabsorption of low molecular weight copper complexes which do get filtered by the glomerulus (Linder and Hazegh-Azam 1996). Urinary copper excretion is not influenced by dietary copper intake, and has only a limited ability to increase in cases of biliary obstruction (Solomons 1988). However chelation therapy, as used with copper toxicity and more specifically in Wilson's disease, a disease in humans associated with increased copper retention due to an inherited abnormality in caeruloplasmin production, increases the plasma concentration of copper associated with low molecular weight ligands resulting in increased urinary copper excretion. This increase in urinary copper excretion is also found with horses that are injected subcutaneously with copper D-penicillamine (Auer 1989b).

1.5.3.4 Effect of pregnancy on copper metabolism

The pregnant mare transfers copper to the foetus trans-placentally, the mechanism of copper transfer is complex, and it is believed to be via di-histidine bound (transferable) copper (McArdle and Van den Berg 1991). The foetal liver accumulates copper bound to metallothionein which is located in the lysosomes (Ryden and Deutsch 1978). The foetal horse total body copper concentration is high (20 mg Cu/kg DM) with the hepatic copper containing 50 to 60 % of the total body copper. More than half of the total term copper is deposited in the foetus in the final two months of gestation (Meyer and Ahlswede 1978). In this respect, human prematurity is recognised as a risk factor for copper deficiency since the majority of foetal copper transfer and hepatic storage occurs in the last trimester (Lonnerdal 1996). A greater requirement for copper would be expected in pregnant mares, but has not yet been demonstrated. In rats, pregnancy increases copper absorption enabling them to retain up to 30 % more copper than non-pregnant rats in the final trimester (Davies and Williams 1976).

1.5.3.5 Copper metabolism for the neonate

Mare colostrum contains 0.8 to 1.0 mg Cu/l which decreases to approximately 0.3 mg Cu/l in mare milk (Ullrey *et al.* 1974; Schryver *et al.* 1986). It is thought that milk alone cannot provide adequate copper to meet neonatal needs, and that the liver copper store maintains the neonate in a copper-sufficient state until such time that it consumes diets richer in copper (Meyer and Tiegs 1995). Human infants may suffer from copper deficiency if they are weaned onto cow's milk at an early age. This is thought to be due to a lower copper concentration in bovine milk compared with human milk. Therefore, in humans at least, it is considered that lactational copper is an important source of dietary copper (Lonnerdal 1996).

Copper absorption in neonatal foals has not been investigated. In neonatal rats copper absorption is very high (about 75 %), and decreases with age (Mistilis and Mearrick 1969; Lonnerdal *et al.* 1985). This decrease in copper absorption can be induced by steroid administration (Mistilis and Mearrick 1969). A large proportion of the absorbed copper in neonates is retained in the gastro-intestinal mucosa. However as the induction of intestinal metallothioneins also increases with age, this suggests that metallothioneins are not responsible for the high copper retention in the neonatal intestine (Lonnerdal 1996). It appears that the absorption of copper in neonates is related in a linear manner to copper intake and is considered to be non-saturable (Varada *et al.* 1993). Balance data from human

infants have shown that despite efficient intestinal absorption, these individuals had a negative copper balance (Cavell and Widdowson 1964; Dauncey *et al.* 1977; Tyralla 1986). Copper absorption declines in lambs as they age, and after weaning. The decline is associated with the maturation of the intestine, as well as the development of a functional rumen (Suttle 1975).

In cattle, a critical foetal liver concentration of 300 mg Cu/kg DM has been proposed as the amount of stored liver copper that a calf requires to maintain it in a copper-adequate state over lactation until it ingests sufficient copper from non-milk sources to meet requirements. Calves born to cows receiving more than 10 mg Cu/kg DM are recommended as having a liver copper concentration above the critical level, but it is recommended that maternal copper liver levels should be 25 mg Cu/kg DM to ensure optimum function of copper-dependent processes (Gooneratne *et al.* 1989). No such data are available for horses.

1.5.4 Cuproproteins

Copper in mammals is associated with numerous intracellular and extracellular enzymes and proteins. These cuproproteins function predominantly as cofactors for enzymes and electron transport proteins in energy or antioxidant metabolism (Linder and Hazegh-Azam 1996). Cuproproteins contain copper as a part of their molecular structure, which does not dissociate on isolation of the protein. The numerous and varied functions of cuproproteins highlight the essentiality of copper in animals.

Caeruloplasmin

Caeruloplasmin in humans, is a 151 kDa α_2 glycoprotein (0.34 % Cu), which binds 8 copper atoms per molecule. In horses, unlike other species, caeruloplasmin is an α_1 glycoprotein (Okumura *et al.* 1991), and has an activity peak at a higher pH (6.6 - 6.8) than the α_2 glycoprotein (5.8 - 5.9) (Bingley and Dick 1969; Smith *et al.* 1983). Caeruloplasmin is synthesised in and secreted almost entirely from the liver, but lung and lymphocytes may also contribute (Linder 1991). Caeruloplasmin synthesis is regulated by hormones operating at the transcription level. These include hormones associated with inflammatory processes (short term regulation) and oestrogen which is mainly responsible for long term regulation probably by stabilisation of Cp-mRNA (Middleton and Linder 1993). Caeruloplasmin, in addition to being the main protein associated with copper transport, is also involved in free radical scavenging as well as an ability to catalyse the oxidation of ferrous (Fe^{++}) ion to the

ferric (Fe^{+++}) ion. Fe^{+++} is able to bind to the iron transport protein transferrin. The mechanism by which extracellular caeruloplasmin is able to act on the Fe^{+++} bound to the intracellular storage protein ferritin is unknown. A deficiency in caeruloplasmin results in the accumulation of stored iron in the liver and other organs including the brain (Linder and Hazegh-Azam 1996). The oxidase activity of caeruloplasmin is dependent on its copper content and copper is important in regulating the amount of caeruloplasmin produced as hepatic copper binds with the caeruloplasmin regulator gene and increases transcription. However copper is not required for caeruloplasmin synthesis and the copper atoms are added post-translationally (Linder *et al.* 1979). Copper antagonists are able to decrease caeruloplasmin activity in rats with silver being the strongest antagonist followed by cadmium, molybdenum, zinc and then sulphate. Copper deficiency decreases caeruloplasmin activity which can be restored by supplementary copper (Whanger and Weswig 1970). However toxic doses of copper injected into monkeys markedly decreased their serum caeruloplasmin concentration (Neifakh *et al.* 1969). Caeruloplasmin has both pro- and anti-inflammatory properties, as well as oxidase activities. Its antioxidant activities are important in preventing auto-oxidation of lipids and combined with its free radical scavenging properties are important in preventing host tissue from damage at a site of local tissue injury (Gutteridge 1978; Linder 1991). In the horse, plasma caeruloplasmin activity increased following intramuscular injection with Freund's adjuvant, peaking at 24 days, and was still significantly elevated 50 days after injection. Plasma copper and caeruloplasmin concentration were also elevated, but declined more rapidly (Auer 1989a).

Cytochrome c oxidase

Cytochrome c oxidase has a molecular weight of approximately 200 kDa in mammals and consists of 12 or more subunits, all of which are located in the mitochondrial wall. Cytochrome c oxidase functions as the terminal enzyme of the electron transport chain in mitochondria, and catalyses the production of two electrons from the Krebs's cycle, required for the reduction of respired oxygen ($2\text{H}^+ + \text{O}_2 \rightarrow \text{H}_2\text{O}$). Copper deficiency decreases cytochrome c oxidase activity, but due to the excess of respiratory enzymes in most cells, impaired mitochondrial function occurs only in severe copper deficiency. The mitochondria of the myocardial and hepatic cells appears to be more susceptible to copper deficiency than renal cells (Linder 1991). Cytochrome c oxidase is thought to play a role in axonal and neuronal integrity. CNS lesions including those of enzootic ataxia of sheep (swayback) are thought to be due to a lack of this enzyme in deficiency states (Fell *et al.* 1965). However

this is a contentious issue and the exact origin of the lesions seen in this condition has not been agreed upon.

Lysyl oxidase

Lysyl oxidase is an extracellular enzyme, and is widely distributed through body tissues and is particularly abundant in structures containing large amounts of connective tissue (skin, blood vessels, cartilage etc.). Lysyl oxidase catalyses the inter-molecular cross-linking of newly formed collagen and tropoelastin fibres by catalysing the deamination of lysine side-chains. The cross-links are an important factor for the tensile strength of these proteins. A decrease in lysyl oxidase activity is associated with skeletal abnormalities in young animals, and defective sheathing of blood vessels with elastin (Linder 1991). Bone formation may be retarded due to a decreased ability to mineralise less organised collagen fibres (Suttle and Angus 1978).

Superoxide dismutase (SOD)

SOD, also known as erythrocuprein, is a homodimer of approximately 32 kDa. Each dimer contains one copper and one zinc atom per molecule. Manganese and iron forms of the enzyme also exist in mitochondria. Cu-Zn SOD is found in the cytosol of most (if not all) cells, and it is particularly abundant in the liver, kidney, adrenal, and red blood cells and neurones (Paynter *et al.* 1979; Linder and Hazegh-Azam 1996). In the cytosol it catalyses the dismutation of superoxide radicals to hydrogen peroxide and oxygen ($2\text{HO}_2^- \rightarrow \text{H}_2\text{O}_2 + \text{O}_2$). The peroxide is then further disposed of by other enzymes including the selenoprotein glutathione peroxidase. Copper but not zinc appears to regulate the functional activity of Cu-Zn SOD. Dietary copper deficiencies reduces the enzyme's activity, which may be restored by copper supplementation (Paynter *et al.* 1979; Harris 1992).

Free radical damage has been associated with cellular senescence and therefore aging. The ratio of Cu-Zn SOD activity to glutathione peroxidase activity has been investigated, and an increase in this ratio results in increased production of H_2O_2 , and cellular senescence *in vitro* (de Haan *et al.* 1996). Transgenic mice bred with greater than normal concentrations of Cu-Zn SOD have an increased resistance to reperfusion injury (Yang *et al.* 1994). Decreased Cu-Zn SOD in endothelial cells and hepatocytes decreases the susceptibility of these cells to oxidant-induced damage (Beckman *et al.* 1988; Markey *et al.* 1990), however a similar decrease in susceptibility was not demonstrated in cardiac myocytes (Sarvazyan *et al.* 1995). The familial form of amyotrophic lateral sclerosis (ALS), a genetic CNS

degenerative disease has been associated with mutations of the Cu-Zn SOD gene (Rosen *et al.* 1993). It is considered that the mutation causes a gain of an adverse function of the Cu-Zn SOD enzyme rather than a decrease in enzyme activity (Rowland 1995). The relatively high proportion of Cu-Zn SOD in motor neurones are therefore hypothesised to put these neurones selectively at risk (Pardo *et al.* 1995). A comparison has been made between equine motor neuron disease (EMND) and ALS, although there is no evidence that EMND is heritable, and is therefore more likely to have similarities to the sporadic form of ALS than the familial form (Mayhew 1994).

Tyrosinase

Tyrosinase is found in the melanosomes of melanocytes and is involved in melanin pigmentation which protects against ultraviolet exposure and provides hair, skin and eye colour. Tyrosinase catalyses the conversion of tyrosine to dopaquinone, which readily polymerises to form melanin (Linder 1991). A lack of tyrosinase results in a decrease in the conversion of tyrosine to melanin, and a lighter than normal coat colour. This is a well recognised manifestation of copper deficiency in cattle (Poole 1982; Gooneratne *et al.* 1989).

Dopamine β -monooxygenase (Dopamine β -hydroxylase)

Dopamine β -monooxygenase is a tetrameric homoprotein found in noradrenergic neurones within norepinephrine storage granules near synapses and also in chromaffin granules of the adrenal glands. The nor-adrenergic neurones are concentrated in the locus ceruleus, brain stem and posterior hypothalamus (Linder and Hazegh-Azam 1996). Dopamine β -monooxygenase catalyses the hydroxylation of dihydroxyphenylamine (dopamine) to norepinephrine. This enzyme is therefore integral to nerve transmission in the central nervous system as well as the stress response mediated by the adrenal medulla. Deficiency of this enzyme activity impairs the function of the CNS and results in an accumulation of the substrate dopamine in the brain (Linder 1991).

Metallothioneins

Metallothioneins are small cysteine-rich polypeptides that are expressed in all cells exposed to divalent transitional metal ions (except Fe^{2+}). The cysteines confer metallothionein with metal binding properties, which are important in the storage and detoxification of these metal ions. As well as the ions themselves, metallothionein expression is regulated by stress (glucocorticoids), inflammatory hormones, and liver glucagon concentration (Linder 1991).

Of the metal ions commonly present in animals, copper has the greatest affinity for metallothioneins, and can displace other elements from metallothionein binding sites. Generally the amount of copper bound to metallothioneins is small because of the ready excretion of excess copper in the bile, preventing significant storage of copper in tissues (Linder 1991). As well as metallothionein's role in metal storage and detoxification, metallothionein is able to donate copper (and zinc) to apo forms of enzymes, and therefore may also play a role in copper deficiency, or when caeruloplasmin is lacking. There has also been recent interest in the free radical scavenging properties of copper-bound metallothioneins, and this activity may account for the regulation of metallothionein by inflammatory hormones (Linder and Hazegh-Azam 1996).

Others

Other cuproproteins are likely to perform numerous biological functions. In studies on severely copper deficient animals, a role has been ascribed for copper in the amidation of neuropeptides, dopamine synthesis, myelination, and activation of enkephalin proteins responsible for binding opiate receptors in response to pain (Linder and Hazegh-Azam 1996). There are also several amine oxidases, in addition to lysyl oxidase, in connective tissue, which probably serve to deaminate various cytokines (Mason 1979).

1.5.5 Measurement of copper status

Horses do not exhibit the typical signs of copper deficiency exhibited by ruminants grazing copper deficient pastures, and so it has been assumed that their dietary copper requirements are low. This may not be true, and elucidation of the role of copper dependent enzymes in immune function, connective tissue structure and function and in providing protection from oxidant induced injury may result in the identification of more copper-responsive diseases in horses. As a result, being able to accurately measure the copper status of a horses is likely to become clinically important.

An adequate copper status exists when tissue copper concentrations, and more particularly liver copper stores, are sufficient to ensure that copper is not limiting biochemical (eg enzyme activity) and physiological function (eg connective tissue integrity) and that animal performance and health are not improved by copper supplementation.

Liver copper concentration

The liver is important in copper homeostasis, being the major site for copper storage and excretion, as well as caeruloplasmin production. Hepatic copper concentration is used to determine copper status in cattle, with reference values established (Smart *et al.* 1992). In horses, hepatic copper concentration has been shown to reflect dietary copper intake (Cupps and Howell 1949; Smith *et al.* 1975; Hurtig *et al.* 1990). Suttle *et al.* (1996) have proposed liver copper reference values for horses based on combinations of horse and ruminant data, and Meyer and Tiegs (1995) have proposed recommended minimum liver copper concentrations for new born foals. However reference ranges for adult horses, based on amounts required for proper function of copper dependent processes, have not been developed.

Hepatic copper concentration varies with age, being very high in the foetus and the neonate (Egan and Murrin 1973b; Meyer and Tiegs 1995). Due to the varied functions of the liver in copper metabolism, including metal ion storage and detoxification, the availability of hepatic copper may not be certain, making interpretation hazardous. For example in zinc toxicity, Bridges and Moffitt (1990) found clinical copper deficiency including hypocupraemia and lameness with articular and growth plate cartilage fractures, without a decrease in liver copper concentrations. Therefore the interpretation of copper status from liver copper concentrations may be improved by determination of the subcellular compartmentalisation of the copper (Bremner 1991; Cymbaluk and Smart 1993). The relationship between plasma copper and liver copper concentration has been investigated in sheep (MacPherson *et al.* 1964), cattle (Claypool *et al.* 1975; Vermunt and West 1994) deer (Mackintosh *et al.* 1986) and horses (Cymbaluk and Christensen 1986; Suttle *et al.* 1996). In cattle and deer, a curvilinear relationship best fits the model (Vermunt and West 1994), but in horses, Suttle *et al.* (1996) found a linear relationship whereas Cymbaluk and Christensen (1986) found no relationship. No useful relationship was found in sheep in one study (MacPherson *et al.* 1964).

Blood copper status indices

Circulating copper is located in caeruloplasmin bound and non-caeruloplasmin (protein) bound fractions in the plasma and is predominantly bound to superoxide dismutase in red blood cells. The amount of circulating copper incorporated in caeruloplasmin is species specific, and in horses it is about 70 % of total plasma copper (Auer *et al.* 1988b). Plasma or serum copper concentration is often considered to be a useful indicator of copper status, as it

declines reliably in moderate and severe copper deficiency (Solomons 1979). However at higher dietary copper intakes, plasma copper does not follow changes in dietary copper intake. Plasma, serum and red blood cell copper concentrations are regarded as being roughly equivalent (Solomons 1979), and therefore haemolysis is not considered to greatly alter the interpretation of serum copper levels (this is not the case with zinc or iron). A diurnal variation has been reported in serum copper in humans, with the highest concentration in the mornings (Lifschitz and Henkin 1979). Serum copper concentrations and caeruloplasmin activity are affected by age, sex and pregnancy, and are increased in inflammatory or infectious conditions, with cancer and with the administration of anticonvulsant therapy or oestrogens. Conversely, copper concentrations are decreased by administration of corticosteroids and adrenocorticotrophic hormones (Fisher *et al.* 1990; Milne and Johnson 1993).

Seasonal variations in copper status of horses have been reported in horses in the UK and Australia (Stubley *et al.* 1983; Auer *et al.* 1988b), which the authors suggested were probably due to differences in dietary copper availability. Changes with age and pregnancy have also been reported, with serum or plasma copper concentrations increasing with pregnancy and decreasing with age in mature animals, but great individual variation reduced the significance of these relationships (Stowe 1968; Auer *et al.* 1988a; Auer *et al.* 1988b). At birth, foals have very low circulating copper concentrations and caeruloplasmin activity, which increases to adult levels by 3 to 4 weeks of age (Bell *et al.* 1987).

Cuproenzyme activity

Cuproenzymes may provide a more sensitive measure of copper status in mild copper deficiencies and are likely to reflect more closely the relationship between an animal's copper status and its clinical significance. For instance Glade (1986) suggested that caeruloplasmin is the most reliable indicator of copper status. Danks (1981) proposed a simple non-invasive technique for determining the adequacy of a diet with respect to copper by measuring the plasma cuproenzyme level, then adding copper to the diet. He proposed that the cuproenzyme activity should increase only if the diet was deficient. However a major problem with measuring caeruloplasmin activity is its variability which is apparently not related to dietary copper intake. For example caeruloplasmin activity may vary as a result of inflammatory states (Firth *et al.* 1987; Smith and Cipriano 1987; Auer 1989a). It is also increased by chronic infection and inflammation, and is decreased by malnutrition, nephrosis and chronic hepatitis. In humans, plasma copper concentration is higher in women

than men, and higher in pregnant women and in individuals on oral contraceptives (Milne 1994; Solomons 1979). Milne and Johnson (1993) also showed that in some cases of copper deficiency in humans, the concentration of caeruloplasmin is not decreased despite a reduction in enzyme activity due to the presence of the apo-enzyme (not bound with copper). It has therefore been proposed that the ratio of the enzymatic activity to caeruloplasmin concentration may be a better indicator of copper status, as this ratio is not greatly affected by other influences including hormones and sex.

Red blood cell copper-zinc superoxide dismutase (RBC Cu-Zn SOD) activity in humans and animals has been shown to decrease with copper deficiency, with the reduction in activity proportional to the magnitude of the deficiency (Bettger *et al.* 1978; Uauy *et al.* 1985). RBC Cu-Zn SOD appears not to be affected by age, sex or hormonal therapy (Saik *et al.* 1982; Fisher *et al.* 1990). In one study performed on copper-deficient humans, the activity of cytochrome c oxidase in platelets and leukocytes responded more quickly to copper deficiency than RBC Cu-Zn SOD activity (Milne *et al.* 1988). Milne (1994) also reported that platelet cytochrome c oxidase activity correlates well with liver copper concentration. Barry *et al.* (1983) found that sheep grazing kale (*Brassica oleracea*) depleted their liver copper stores, and reduced their serum copper concentrations and RBC Cu-Zn SOD activity. Copper supplementation of these sheep increased their heart cytochrome oxidase activity, and diminished the reduction in their RBC Cu-Zn SOD activity. Thus the available data suggest that parameters of cuproenzyme activity may provide valuable indicators of copper status in a variety of situations and hence merit further investigation.

Hair copper concentration

Hair copper has been found to reflect liver copper in rats (Jacob *et al.* 1978) and cattle (Kellaway *et al.* 1978), but doubt has been expressed as to its usefulness in humans (Olivares and Uauy 1996) because hair copper concentration is reduced only after prolonged copper deficiency and is subject to contamination from external sources (Solomons 1979; Danks 1988). In horses, variation of hair copper due to several factors including season, age and dexamethasone administration (Cape and Hintz 1982), as well as the possibility of contamination with environmental copper, may limit the usefulness of this measurement.

Urinary copper concentration

Urinary copper in horses is independent of intake at adequate dietary copper concentrations (Cymbaluk *et al.* 1981a). In humans, urinary copper has been reported to be normal in copper deficient states and elevated in disease states such as following burns (Carr and Wilkinson 1975). Consequently, urinary copper is not regarded as an accurate measure of copper status.

1.5.6 Dietary copper sources and bioavailability

The oral route is by far the most significant route of entry for copper, although it is possible that small amounts of copper may be absorbed dermally from applications of ointments rich in copper. Small amounts of copper have been reported to enter through the skin in humans wearing copper bracelets through the formation of glycine-copper complexes dissolved in sweat (Walker *et al.* 1982).

1.5.6.1 Copper content and availability in pasture

Factors influencing the copper composition of pasture plants include: pasture type, vegetation stage, fertilisers, soil type and pollution (Georgievskii *et al.* 1982).

Legumes and mixed herbs have higher copper concentrations than grasses, with the vegetative parts of the plants containing more copper than the reproductive parts. Therefore pasture copper concentration is at a maximum in young legume dominant pastures, and decreases as the plants age and flower (Georgievskii *et al.* 1982). The addition of copper in fertilisers increases copper content of pasture plants (Cunningham and Perrin 1946). Fertilisers containing zinc may reduce the absorption of copper as described above. Increased pH will decrease the absorption of copper by plants, and it increases molybdenum concentration of pasture plants (Grace 1994). Pasture copper concentrations vary considerably on different soil types (Cunningham 1956; Wells 1957). Low pasture copper concentrations are found on coastal sandy soils as well as marine and river silts and peat soils (Wells 1957; Grace 1994). Within New Zealand, topsoil copper concentrations can vary from 2 to over 120 mg Cu/kg DM, However topsoil copper concentration is poorly correlated with pasture copper concentration (Wells 1957; Grace 1994).

Copper is less likely to be a cause of pasture pollution from industry than some other trace elements, such as zinc which will adversely effect copper absorption.

1.5.6.2 Copper supplements (bioavailability)

Supplemental copper is available as inorganic salts (eg. cupric chloride, acetate, oxide, sulphate and carbonate), and as copper proteinates (or chelates). The bioavailability of supplemental copper can be assessed by various methods which are reviewed by Baker and Ammermann (1995). Suttle (1974) describes a method of assessing copper bioavailability by depleting ewes on a copper deficient diet and then repleting them with the copper supplement and using the increase in plasma copper concentration as a relative measure of bioavailability. Changes in liver copper concentration following supplementation has also been commonly used. Molybdenum supplementation has been used to ensure a low liver copper concentration prior to supplementation. More recently cupro-enzyme activities have also been used (Baker and Ammermann 1995).

Copper sulphate is often used as a reference to compare the bioavailability of other copper-compounds. *In vivo* studies in ruminants have found copper sulphate to have the greatest bioavailability of the metal salts (Ledoux *et al.* 1995) and little difference between the bioavailability of copper sulphate and the copper proteinate copper lysine (Kegley and Spears 1994). Copper histidine complexes have been used successfully for the treatment of copper deficiency in humans and has been given subcutaneously to treat patients suffering from Menke's disease (Sherwood *et al.* 1989), an inherited disorder of copper absorption.

1.5.7 Copper dietary interactions

Dietary components may affect copper absorption from the digestive tract. For example, dietary phytates, complexes with amino acids, reducing agents (eg ascorbic acid), the form of dietary carbohydrates, and other minerals influence bioavailability.

Zinc

Evidence regarding the role of zinc, as a dietary antagonist for copper is conflicting. Zinc, having the same electron configuration as copper, interacts with dietary copper at the site of absorption (Van Campen and Scaife 1967; Hall *et al.* 1979). Zinc is a potent inducer of metallothioneins, which have a greater affinity for binding with copper than zinc. High zinc intake by horses, both experimentally and due to ingestion of pasture with high zinc concentrations, has been reported to cause skeletal abnormalities consistent with copper deficiency, and decreases in blood copper concentrations (Willoughby *et al.* 1972; Gunson

et al. 1982; Eamens *et al.* 1984; Bridges and Moffitt 1990; Campbell Beggs *et al.* 1994). However the opposite was found in a study with pony foals, where a high zinc intake (1200 mg/kg DM) did not produce skeletal disease or reduce liver copper concentration (Coger *et al.* 1987). The inhibitory effects of zinc have been shown to increase in the presence of excess histidine (Wapnir and Lee 1993) and the balance between the chelating amino acids, and other trace elements and copper may be very important (Lonnerdal 1996).

Iron

Iron is also considered to decrease copper absorption, which, similar to ascorbic acid, may be due to the reduction of Cu^{++} to Cu^{+} in the intestine. High iron intakes in calves (Humphries *et al.* 1983), and goats (Schonewille *et al.* 1995), reduced plasma copper concentration, caeruloplasmin activity and liver copper concentration, and also markedly reduced the liver copper concentration in lambs (Grace and Lee 1990). Increased iron intake occurs often in winter/early spring when herbage iron intake increases due to soil contamination. High dietary iron intakes in human infants has also been associated with induced copper deficiency (Barclay *et al.* 1991; Lonnerdal 1996), and the combination of iron and ascorbate which is commonly supplemented in combination is thought to be synergistic on decreasing copper availability (Lonnerdal 1996).

Molybdenum/sulphur

Elevated dietary molybdenum and sulphur concentrations are the most important factors in secondary copper deficiency in ruminants (Dick *et al.* 1975; Gooneratne *et al.* 1989). Thiomolybdates appear to induce copper deficiency by forming insoluble complexes with copper in the digestive tract, and therefore limiting copper absorption. Absorbed thiomolybdates also alter copper ligand binding to proteins (ie albumin) decreasing copper bioavailability, and increasing copper biliary excretion (Gooneratne *et al.* 1989). However the effect of molybdenum in horses is considered to be less important than in the case of ruminants, and there have been no reports of an induced copper deficiency secondary to excess molybdenum intake in the horse (Cymbaluk and Smart 1993), although recently there has been a report of a case of molybdenum toxicity in horses grazing pastures contaminated with fly ash, with necropsy evidence of decreased liver copper stores (Ladefoged and Sturup 1995). A study on three ponies aged between 1 and 2 years demonstrated that increasing dietary molybdenum decreased the amount of copper absorption and increased excretion. There was no change in serum copper concentration, but there was a decrease in caeruloplasmin activity, and an increase in TCA insoluble copper

concentration (Cymbaluk *et al.* 1981b). Another study on six horses of mixed age, breed and pregnancy status, found that molybdenum supplementation had no effect on plasma copper levels, and there was no increase in TCA insoluble copper, suggesting that there was no significant absorption of thiomolybdenates (Strickland *et al.* 1987).

Cadmium/silver/nickel/tin

Cadmium and silver, like zinc, share the same three dimensional configuration as copper and therefore compete for binding sites in the intestine and on caeruloplasmin (Whanger and Weswig 1969), and increase metallothionein induction. High dietary intakes of nickel and tin reduce copper absorption and probably act either by antagonism of intestinal transport mechanisms, or by the reduction of Cu^{++} to Cu^+ (Yu and Beynen 1995; Gunson *et al.* 1982).

Selenium

Copper pretreatment of ponies attenuated the clinical signs of experimentally induced selenium toxicity. The copper did not appear to inhibit selenium absorption, but increased removal of selenium from the serum (Stowe 1980).

Phytates

Phytates have been shown to reduce the bioavailability of copper and other trace elements in rats (Davies and Nightingale 1975). However studies in humans have failed to show this effect (Turnlund *et al.* 1985) despite a decrease in zinc absorption (Turnlund *et al.* 1984). Unlike zinc-phytate complexes, copper-phytate complexes do not precipitate at intestinal pH (Vohra *et al.* 1965), and the phytate in soluble copper-phytate complexes is easily displaced by amino acid and polypeptide chelators, and therefore should not significantly decrease copper absorption (Jacobsen and Slotfeldt-Ellingsen 1983). Phytates could indirectly affect copper availability by this action on zinc.

Amino acids

Complexing of copper with amino acids affects intestinal copper absorption, and it is likely that the copper uptake is influenced by the absorptive properties of the bound amino acid (Linder and Hazegh-Azam 1996). Histidine forms complexes with copper with much greater affinity than with zinc (Ashmead *et al.* 1985) and enhances copper absorption (Wapnir and Balkman 1991). Cysteine has an inhibitory effect on copper absorption in chickens (Robbins and Baker 1980; Baker and Czarnecki-Maulden 1987) by increasing zinc antagonism at intestinal binding sites (Aoyagi and Baker 1994). However, complexes with other amino

acids, such as methionine and lysine may increase copper absorption in the presence of copper antagonists, as the copper in these complexes could be absorbed via the amino acid intestinal transport mechanism (Aoyagi and Baker 1994), bypassing the need to be absorbed at the antagonised sites.

Ascorbic acid

Ascorbic acid decreases copper absorption by reducing the cuprous ion to cupric ion, which is less well absorbed (Hill and Starcher 1965; van Campen and Gross 1968). Other reducing agents also depress copper absorption by the same mechanism (Hill and Starcher 1965). Ascorbic acid also affects copper metabolism post-absorption, and was shown to decrease copper utilisation in chicks injected with copper intraperitoneally (Disilvestro and Harris 1981). Ascorbic acid (or l-ascorbate) may also play an important role in the reduction of caeruloplasmin-bound copper to make it available intracellularly at target organs (Lonnerdal 1996), and it may also be required for the transport of copper from mucosal cells.

Carbohydrates

Dietary fructose (as compared with starch) decreases copper balance in copper-deficient rats (Fields *et al.* 1984). This effect may be specific to male rats. In humans, fructose appears to increase copper intake/retention compared with starch, but it decreases Cu-Zn SOD activity (Reiser *et al.* 1985) which returns to normal following copper supplementation. The effect of fructose on mineral balance is not specific to copper as similar changes were seen with Ca, Mg, Fe and Zn (Holbrook *et al.* 1989).

1.5.8 Copper metabolism studies and copper requirements in horses

There is a dearth of information on copper metabolism and requirements for horses. Cymbaluk *et al.* (1981a) performed a series of metabolism experiments on ponies using radio- and stable- copper isotope techniques as well as bile duct cannulation to measure copper absorption and endogenous losses. In the bile duct cannulated ponies it was observed that the apparent copper absorption coefficient was 0.27, and the true copper absorption coefficient was 0.46. Endogenous (obligatory) losses were calculated from the intercept of a regression between copper retention and dietary copper intake. Endogenous losses were also determined using isotope dilution techniques, and there was good agreement between the two methods. The copper requirement for maintenance was determined by dividing the daily endogenous loss by the true absorption coefficient (0.66). The values obtained were 3.5 mg

Cu/100 kg LW/day for endogenous loss and 5.3 mg Cu/100 kg LW/day as a minimum copper intake for maintenance. The true absorption coefficient obtained by the regression approach was 0.66 which is considerably higher than the true absorption coefficient of 0.47 determined using bile duct cannulated ponies.

A regression approach was also used by Pagan (1994) using 500 to 600 kg mixed breed horses on diets containing copper ranging from 7 to 38 mg Cu/kg DM. In this study it was determined that the true absorption coefficient was 0.40, endogenous losses were 7 mg Cu/100 kg LW/day and minimum dietary copper intake for maintenance was 17.5 mg Cu/100 kg LW/day.

A balance study performed on miniature ponies in metabolism stalls, calculated the apparent absorption coefficient of copper to be from 0.4 to 0.5 (Hoyt *et al.* 1995).

Clearly there is considerable variation in the measurement of absorption and endogenous losses of copper because:

1. small number of animals were used in these trials,
2. trace element balance studies can suffer from significant errors because they involve the measurement of small amounts of mineral element in large volumes of ingesta and excreta and
3. in horses copper absorption decreases with increasing dietary copper intakes (Cymbaluk *et al.* 1981a) indicating that the relationship is not linear.

Estimates of dietary copper requirements for maintenance, based on the studies of Cymbaluk *et al.* (1981a) and Pagan (1994) are 3.5 mg Cu/kg DM and 7 mg Cu/kg DM respectively. Both these dietary copper requirements are less than current NRC (1989) recommendations of 10 mg Cu/kg DM. However, the above maintenance requirements do not account for extra dietary copper that is required during growth, exercise, pregnancy or lactation.

1.5.9 Copper deficiency

Two forms of copper deficiency are normally described, namely primary deficiency due to an insufficient amount of copper present in the diet or secondary (or induced) deficiency due to a decrease in absorption or ability of tissues to utilise absorbed copper. Some causes of secondary copper deficiency include the presence of antagonistic ions, copper chelating agents and conditions causing malabsorption including diarrhoea. Menke's disease, a genetic disorders of copper metabolism causing copper deficiency has been recognised in humans (Danks 1995), but not in horses. Clinical signs of copper deficiency can be attributed to a reduction in the activity of copper enzymes, as well as decreasing amounts of free copper.

Copper deficiency in growing horses is primarily manifest as abnormalities in bone and cartilage development and has been discussed previously. Stowe (1968) made an association between copper deficiency and rupture of the uterine artery in foaling mares, which may be due to the reduction in the activity of lysyl oxidase in adult horses, and a consequent weakening of the connective tissue (elastin) which ensheaths major blood vessels.

Breed and species susceptibilities to copper deficiency have been reported in ruminants. Cattle are more susceptible to copper deficiency than sheep, and also are more susceptible to molybdenosis. Simmental cattle are more susceptible to copper deficiency than other breeds (Smart and Gudmudson 1980). This is probably because they excrete relatively more copper in the bile than other cattle (Gooneratne *et al.* 1989). The association between ruminant copper deficiency and abnormalities in bone development has been discussed previously. Other clinical signs of copper deficiency in cattle include anorexia, diarrhoea, depressed growth rates, decreased reproductive performance, microcytic hypochromic anaemia, achromotrichia, poor keratinisation of hair and hoof, nervous disorders, cardiovascular disorders, depressed immune status and death (Poole 1982; Gooneratne *et al.* 1989). Copper deficiency in pregnant sheep is associated with a nervous disorder of lambs (called enzootic ataxia or sway back) and is characterised by ataxia. It is considered to be caused by degeneration of neurones and a failure in myelination of neurones due to decreased cytochrome c oxidase activity (Fell *et al.* 1965; Jubb and Huxtable 1993). A similar condition affects deer on copper deficient diets, but unlike sheep, older animals rather than neonates are susceptible (Peet and Hepworth 1993).

Copper deficiency is not common in humans, but premature infants and individuals on total parenteral nutrition are at a higher risk. The most common clinical manifestations of copper deficiency in humans are anaemia, neutropaenia and bone abnormalities (Heller *et al.* 1978; Williams 1983; Danks 1988; Shaw 1992). The anaemia is usually a hypochromic, normocytic or macrocytic anaemia, but microcytic anaemias are also found (Williams 1983; Shaw 1992). The anaemias are considered to be due to defective iron mobilisation from tissues secondary to reduced caeruloplasmin activity, and the anaemias respond to copper but not iron supplementation. Abnormalities in bone include osteoporosis, fractures, epiphyseal separation, widening of growth plates with spur formation and the formation of sub-periosteal new bone (Danks 1988; Shaw 1992). Less frequent manifestations of copper deficiency include hypopigmentation of hair, reduced growth rates, and reduced resistance to infections (Danks 1988; Shaw 1992). Also abnormalities to glucose and cholesterol metabolism have been described, resulting in copper deficiency (as well as excessively high levels of copper) being considered to be a risk factor for atherosclerosis (Klevay 1990; Kenneth *et al.* 1994).

The role of copper deficiency in depressed immune function has been reported in humans (Kelley *et al.* 1995), ruminants (Jones and Suttle 1981; Woolliams *et al.* 1986; Xin *et al.* 1991 Stabel *et al.* 1993; Niederman *et al.* 1994) and rats (Mulhern and Koller 1988; Hopkins and Failla 1995). Typical findings include decreased resistance to infections, and decreased lymphocyte numbers and phagocytic ability. Copper deficiency decreases humoral and cell mediated immunity, as well as affecting non-specific immunity by decreasing the phagocytic activity of macrophages and neutrophils. Woolliams *et al.* (1986) found that lambs born from rams genetically selected for high copper status had a decreased mortality due to sway back and infection compared with lambs born to rams bred for low copper status. Mechanisms for the changes in immunity are still not clear, although it appears that there may be a failure of cellular differentiation, or a decreased cellular viability (Percival 1995).

1.5.10 Copper toxicity

The mechanism of copper toxicity is yet to be definitively established, but several theories have been proposed (Luza and Speisky 1996). For example, free copper may bind to proteins, changing their structure and preventing them from performing their normal enzymatic functions which are essential for cell metabolism (Nakamura and Yagasaki

1972). Alternatively free copper may interact with hydrogen peroxide and superoxide anions to form highly toxic hydroxyl radicals (Samuni *et al.* 1981; Goldstein and Csapsky 1986). These hydroxyl radicals cause oxidative degradation of proteins and lipid peroxidation of cell and organelle membranes.

Metallothioneins are likely to be important in the protection of cells from copper toxicity by efficiently binding and therefore sequestering any free ionic copper (Luza and Speisky 1996). Metallothionein may also have a significant cytoprotective role via its antioxidant activities, and it has the highest known reactivity towards free radicals of any protein (Thornalley and Vasak 1985). In addition, zinc may be displaced from metallothionein by copper and free zinc can also perform antioxidant and cytoprotective functions (McMillan and Schnell 1984).

Glutathione affects the ability of metallothionein to bind copper. Glutathione has a good affinity for Cu^+ and forms stable complexes which are then incorporated into apometallothionein (Freedman and Peisach 1989; Da Costa Ferreira *et al.* 1993). Glutathione also plays an important role in oxygen scavenging and as a cofactor for the seleno-protein glutathione peroxidase. Deficiency of glutathione may cause individuals to be more susceptible to copper cytotoxicity (Luza and Speisky 1996)

In grazing animals there is a species difference in susceptibility to copper toxicity with sheep being more susceptible than cattle which are more susceptible than horses. It is suggested that sheep may be more susceptible to toxicity because of their impaired ability to excrete excessive copper in bile (Gooneratne *et al.* 1989). In sheep a breed difference in susceptibility to copper toxicity has also been recognised, with British breeds of sheep more susceptible to copper toxicity than merinos. Clinical signs of copper toxicity include inappetence, increased respiratory rate and bilirubinaemia (Georgievskii *et al.* 1982). Copper toxicity is also common in Bedlington terrier dogs due to a genetic disorder of copper excretion, while Wilson's disease in humans is also a genetic disorder which results in impaired copper transport and excretion.

Horses are very resistant to excessive copper intakes, and a trial with horses fed up to 800 mg Cu/kg DM copper in the diet showed no adverse effects to the horse (Smith *et al.* 1975); one animal that had been on this highest level subsequently foaled normally 3 to 4 months after completion of the trial. However chronic copper toxicity was induced in horses fed a

diet containing 2800 mg Cu/kg DM for two months. The horses developed hepatic and renal damage and died four months after finishing the trial (Bauer 1975). A case of acute copper toxicity was reported in a standardbred injected subcutaneously with 4 mg Cu/kg LW of copper D-penicillamine. The horse became agitated and ataxic initially, and then later developed signs of abdominal pain. The horse made an apparent recovery after 36 hours (Auer 1989b).

1.5.11 Therapeutic applications for copper

Historically, copper has been used to treat a great variety of diseases with varying successes (Mason 1979). More recently the anti-inflammatory and anti-oxidant qualities of copper have been investigated, and therapeutic formulations containing copper have been manufactured. Sorenson (1982) found that copper complexed with anti inflammatory compounds were more effective at reducing inflammation than the compound alone. It has further been proposed that the anti-inflammatory activity of some therapeutic agents (including nonsteroidal anti-inflammatory drugs (NSAIDs) may rely on the drugs' ability to bind copper *in vivo* (Sorenson 1985). NSAIDs are commonly used to treat inflammatory conditions of the musculoskeletal system in the horse, and copper bound NSAIDs have been evaluated in horses, and found to be effective at inhibiting inflammatory oedema. A parallel experiment on rats found the copper-bound drugs had a greater efficacy than the NSAIDs alone (Auer 1990). Copper supplementation has also been investigated with respect to its ability to provide gastroprotection from NSAID induced lesions (Franco and Velo 1995), and research in neurosurgery has found that copper inhibitors (D-penicillamine) prevent tumour angiogenesis, and are therefore useful as adjunctive therapy in cancer patients (Yoshida *et al.* 1995).

The wide range of biological activities of copper containing compounds, as well as advancing research technology, especially in the field of molecular biology, is likely to result in an increase in the therapeutic applications for copper.

1.6 Introduction to the objectives

The following chapters describe experimental work performed to test the hypothesis.

Objectives for the experimental work include:

2. Investigate and evaluate *in vivo* liver biopsy techniques for mares and neonatal foals (Chapter 2).

1. Develop an *in vivo* technique for collecting physeal cartilage for histomorphometric analysis (Chapter 3).

3. Assess the effect of copper supplementation of mares on:

- i. measurable indices of their copper status (Chapter 4),
- ii. the copper status of their offspring (Chapters 4 and 5) and
- iii. the incidence and severity of DOD in their offspring. (Chapter 6).

4. Assess the effect of copper supplementation of growing foals on:

- i. measurable indices of their copper status (Chapter 5) and
- ii. the incidence and severity of DOD (Chapter 6).

5. Investigate the effect of high pasture molybdenum concentrations on the copper status of young horses grazing pasture (Chapter 7).

Conclusions from this work, including recommendations for industry and areas requiring further research, are presented in the general discussion (Chapter 8). Pilot trial studies are included in the appendices.

Chapter 2

Liver Biopsy Techniques for Adult Horses and Neonatal Foals to Assess Copper Status¹

¹ Published as: SG Pearce, EC Firth, ND Grace and PF Fennessy (1997) *Australian Veterinary Journal* **73**, 194-198.

2.1 Abstract

The objective of this study was to evaluate standing, percutaneous, ultrasound-guided, transthoracic liver biopsy in mares, and transabdominal, laparoscopically-guided, liver biopsy under general anaesthesia in foals, as techniques for obtaining tissue for assessment of copper status. The techniques were evaluated with respect to ease of use and effect on the animal.

Twenty of 24 Thoroughbred mares and 21 of their foals were biopsied. The animals were part of a larger study of the effect of copper supplementation on copper status and the prevalence of developmental orthopaedic disease. Livers were also collected from unrelated horses and sampled to investigate the variability in the distribution of copper in liver tissue.

The biopsy technique caused no lasting effect on the mares, but there was an increased risk of viscus penetration associated with taking multiple biopsy cores. The use of ultrasonography to scan the target area for the liver, identified four cases that were not appropriate candidates for liver biopsy, because of large intestine being located in the biopsy area. In the foals there were no serious postoperative adverse effects, nor was there any evidence of problems caused by the procedure when the abdomen was examined postmortem at five months of age. In livers collected to investigate the variability of copper concentration, copper appeared to be relatively evenly distributed through the liver.

Standing, percutaneous, ultrasound-guided, transthoracic liver biopsy in mares, and transabdominal, laparoscopically-guided, liver biopsy under general anaesthesia in foals are convenient procedures for obtaining liver tissue for assessing copper status in horses. The use of ultrasound to identify liver tissue is recommended, especially in older mares.

2.2 Introduction

The liver is a major storage organ for copper in domestic animals and therefore liver biopsy is routinely used in cattle and sheep to determine copper status (Chapman *et al.* 1963). In the horse, liver biopsy is less commonly used for the determination of mineral status, and instead is used mainly as an aid to diagnosis and prognosis in suspected hepatic disease.

Recently, the assessment of copper status in horses has become more important because of the suggestion that some diets for growing horses do not provide adequate dietary copper intakes for normal bone development. In particular, it has been proposed that inadequate dietary copper intakes may result in a disease characterised by flexural limb deformities, epiphysitis, joint swelling and radiographic and postmortem evidence of osteochondrosis (Knight *et al.* 1990; Hurtig *et al.* 1990).

For the adult horse there are several methods for liver biopsy (Gibbons 1964; Tennant *et al.* 1973; Pearson and Craig 1980; McIlwraith 1984; Milne 1992), which vary with respect to the site of insertion of the biopsy needle (between the 12th to 14th intercostal spaces) and the angle at which the needle should be inserted (90 degrees to skin or oriented cranio-ventrally). Traditionally, a line drawn between the tuber coxae and the point of the shoulder identified the target area for insertion of the biopsy needle (Gibbons 1964; Milne 1992). A modification of this technique is to replace this line by a triangle which includes the above two points and the proximal olecranon (McIlwraith 1984).

Standing laparoscopic procedures have been described in the horse for the purposes of investigating the reproductive tract (Wilson 1986; Fischer 1991), as a diagnostic aid in colic cases (Fio 1995) and other abdominal disorders (Fulton *et al.* 1990), and for guided biopsy of abdominal organs, including the liver (Fischer 1991). Laparoscopically-guided liver biopsy in anaesthetised sheep has been reported to cause no adverse effects (Hidioglou and Ivan 1993). There is less information on foal liver biopsy techniques. However, Hurtig *et al.* (1990) reported on serial, blind, percutaneous liver biopsies performed on sedated foals.

There is a concern about the validity of liver biopsy to determine liver copper stores because of the variation of copper concentration between sites in the liver (O'Cuill *et al.* 1970), possibly as a result of differences in portal blood flow to different parts of the liver, as observed in ruminants (Heath and Perkins 1985). Therefore, some biopsy procedures involve sampling at specific site(s) to reduce variation associated with such differences (Cymbaluk and Christensen 1986).

In a study to assess the effect of copper supplementation in pregnant mares and their foals, a safe technique was required that would permit sampling of the liver for copper concentration in young foals. Therefore, a laparoscopic technique was used to ensure the safe passage of the biopsy instrument across the abdomen and into the liver, and to assess

the effect of the biopsy procedure on the liver. When the foals were euthanased at five months of age the long term effect of the biopsy was also assessed. In the mares, standing, percutaneous, ultrasound-guided, transthoracic liver biopsy was used. This paper reports these techniques and also describes the variability of copper concentration with respect to site in the liver of 12 other horses obtained at necropsy or slaughter.

2.3 Materials and methods

2.3.1 Liver biopsy general details

Thoroughbred mares aged between 4 and 20 years (mean age 10 years) were subjects in a study to determine the effect of increasing copper intake (7 versus 30 mg Cu/kg dry matter (DM)) on the copper status of the young horse and the possible role of copper in developmental orthopaedic disease in pasture fed horses. Liver biopsy was attempted on 24 thoroughbred mares and on 21 of their foals. The biopsies of a mare and its foal were performed on the same day, 4 to 10 days after foaling.

The mare livers were biopsied using a 14 gauge 150 mm trucut needle (Baxter Healthcare Corporation, Deerfield, IL, USA), after scanning the liver with a 3.5 MHz linear ultrasound probe. The foal livers were biopsied using either a 14 gauge trucut biopsy needle (n=18) or the cannula of a Rhone Merieux liver biopsy needle (Rhone Merieux, Wellington, New Zealand 240 mm long, 4 mm diameter) attached to a 5 ml syringe (n = 3). The laparoscopy was performed using a CO₂ insufflator (Wisap®, Sauerlach, Germany), 12 mm by 100 mm disposable trocar and cannula (Ethicon Endo Surgery, Cincinnati, Ohio, USA), Verres needle (Ethicon Endo Surgery, Cincinnati, Ohio, USA) and a 10 mm rigid laparoscope (Olympus Winter & Ibe, Hamburg, Germany) attached to a 250 watt light source (Karl Storz GmbH and Co, Tuttlingen, Germany). The foals were anaesthetised using a small animal circle system with an out-of-circuit precision vapouriser.

2.3.2 Mare liver biopsy procedure

The mares were restrained without a twitch during this procedure in an open sheltered area. They were sedated with 200 mg of 10 % xylazine hydrochloride intravenously and 10 mg of butorphanol tartrate. Fractious mares received a further 100 mg of xylazine hydrochloride intravenously. A target site on the horse's right side was identified by considering a triangle

formed by joining the tuber coxae to the point of the olecranon and the scapulo-humeral joint, and then counting back from the last rib to identify the 12th to the 14th intercostal spaces. A 20 cm by 20 cm area was then clipped and washed, and a 3.5 MHz ultrasound probe used to identify liver parenchyma. The area with the greatest depth of liver parenchyma and a lack of large hepatic blood vessels was chosen as the site for the biopsy. Two ml of 2 % lignocaine hydrochloride was injected intradermally to mark the site, which was prepared aseptically. A further 5 to 8 ml of lignocaine was injected into subcutaneous tissue and intercostal muscles. A 5 mm stab incision was made with a No. 21 scalpel blade, and the biopsy needle was inserted, oriented cranio-ventrally towards the contralateral shoulder, and advanced. When the biopsy needle penetrated the diaphragm, which was evident by the oscillations of the needle corresponding to respiratory frequency, it was advanced a further 5 cm into the liver, and a biopsy was taken. The cannula was left in place while the trochar was removed and the biopsy core harvested. The trochar was then re-inserted and another biopsy taken. This procedure was repeated two or three times with the trucut needle to obtain 30 to 60 mg of liver tissue. Any mare showing signs of colic after biopsy was treated with flunixin meglumine intravenously. The mares and their foals were stabled and examined twice daily for 3 to 4 days, turned out into a small yard for 1 to 2 weeks and then returned to the herd.

2.3.3 Foal liver biopsy procedure

After sedation with xylazine hydrochloride (0.5 to 0.75 mg/kg), a naso-tracheal tube was inserted. Anaesthesia was induced, and then maintained via an endotracheal tube, using isoflurane and oxygen. A 16 gauge catheter was placed in the right jugular vein through which lactated Ringer's solution with 1 % dextrose was infused at 5 ml/kg/h. Blood pressure was monitored using a Doppler probe on the tail. The foal was placed in left lateral recumbency, rotated dorsally to about 20° from true lateral, so that the ventral midline was easily accessible, and the right lateral and ventral surfaces of the caudal abdomen prepared aseptically. The table was tilted about 15°, with the head raised, so that the intestines moved more caudally in the abdomen. A Verres needle was inserted into the abdomen through the ventral midline, attached to the insufflator, and the abdomen inflated with carbon dioxide. A stab incision was made through the skin, 5 cm caudal to the costochondral arch, at the level of the end of the 14th rib. The trochar and cannula were introduced through this incision into the abdomen. The trochar was removed, the laparoscope inserted through the cannula, the carbon dioxide insufflator removed from the Verres needle and attached to the cannula,

and the Verres needle removed from the ventral midline. Distension pressure was maintained at less than 16 mmHg.

The right ventral liver lobe was visualised, and a biopsy needle was inserted through a small skin incision (5mm) made with a No. 21 scalpel, and then into the right lateral body wall a few centimetres from the ventral midline, midway between the xiphoid and the umbilicus. The exact site was determined by digital pressure on the abdominal wall being visualised, along with the right liver lobe and other structures, through the laparoscope. The biopsy needle was then advanced across the abdomen, under visualisation by the laparoscope and passed into the right liver lobe. The biopsy needle approached the liver lobe almost parallel to the diaphragmatic surface of the lobe, and was inserted into the liver 4 to 5 cm from the liver margin. When the trucut needle was used repeat biopsies were required to obtain 30 to 60 mg of liver tissue. However, only one biopsy was required to obtain sufficient liver (150 mg) when the larger bore Rhone Merieux biopsy cannula was used. The biopsy instrument was removed and the abdomen was explored with the laparoscope. The liver was observed several times to check for haemorrhage at the biopsy site. After removing the laparoscope and cannula, the abdominal musculature and skin at these two sites were sutured with 2-0 PDS in three separate layers. The total anaesthesia time was 1.5 to 2 h, because a bone biopsy and a radiographic skeletal survey were also conducted. Procaine penicillin (1.5×10^6 IU, intramuscularly) and phenylbutazone (100 mg, intravenously) were administered intraoperatively. The foals were returned to their dams, stabled for 3 to 4 days, turned out into a small yard for 1 to 2 weeks and then returned to the herd.

At necropsy of the foals, at 5 months of age, the abdomen, with the liver *in situ*, was examined for adhesions. The liver was removed and examined for evidence of scarring and other lesions that might be associated with the biopsy.

2.3.4 Liver biopsy sample preparation and copper analysis

Acid washed glassware was used to collect and store the liver samples. All care was taken to prevent any contamination of the sample. The tissue samples (30 to 60 mg) were handled with stainless steel forceps, washed in deionised water to remove any blood and patted dry with a paper towel, sealed in a small plastic vial and stored at -20°C for analyses. The liver samples were freeze-dried, subsamples (6 to 10 mg) taken and 0.5 ml concentrated HNO₃ added before being wet-ashed in a closed system microwave furnace. The sample was made

up to 5 ml with deionised water and the copper determined by Zeeman graphite furnace atomic absorption. Samples were run with a liver standard produced by the National Bureau of Standards (USA) of known copper concentration (NBS bovine liver 1577-B). The limit of detection is 2 µg Cu/l.

2.3.5 Site variation in liver copper concentration

Six livers were collected at slaughter from feral horses that grazed pasture in the central plateau of New Zealand's North Island. Six sites were sampled (50 g each): the peripheral, lateral border of the left and right lobes, the peripheral, ventral border of the quadrate lobe and the centre of the right, left and quadrate lobes. Liver subsamples were homogenised, freeze-dried and 0.25 g of the subsample wet-ashed in 10 ml concentrated HNO₃, the residue taken up in 10 ml 2M HCl and the copper determined by inductively coupled plasma emission spectrophotometry (ICP) (Lee 1983). Analysis of variance was performed to test for a difference between sites within the liver.

Livers were also harvested from three mature horses that were euthanased at the Massey University Veterinary clinic for reasons unrelated to the present investigation. No liver disease was detected in these horses, and the dietary history of the horses was unknown. Twelve sites were identified, three evenly spaced across the diaphragmatic surface of each of the dorsal right lobe, ventral right lobe and quadrate lobe (from right to left), and the left lobe (from dorsal to ventral). The sites were biopsied with a trucut needle with 30 to 60 mg of fresh tissue being harvested. The livers were then homogenised and 5 subsamples of approximately 1 g of fresh tissue were collected from each homogenate. Liver copper concentrations were determined by ICP as described above. The mean concentration of the 5 subsamples of the homogenised liver was used to define the total liver copper concentration. The difference between the copper concentration at each of the 12 biopsy sites and the mean copper concentration of the homogenised liver was analysed using paired *t*-tests to determine if there was a systematic difference in copper concentration across the liver.

2.4 Results

2.4.1 Mare liver biopsy procedure

The mare procedure took approximately 15 minutes from sedation of the mare until completion. Of the 24 mares, four (17 %) were not biopsied, because liver tissue could not be visualised with the ultrasound scan over the target site. In all of these cases intestine was identified. In another two horses (8 %) the liver was identified, but on repeated biopsy, gut content was obtained and the biopsy was terminated before adequate liver was harvested for analysis. In both these cases the mares immediately received 30 000 IU/kg of procaine penicillin. Within 1 to 2 h, both of these mares showed signs of colic and became restless with an increase in temperature and heart rate and a decrease in gut sounds. One other mare also showed signs of colic after the biopsy. These three mares were treated with 10 ml of flunixin meglumine intravenously, and responded immediately; all recovered uneventfully. The mares not biopsied because of the ultrasonic identification of intestine over the target site were aged 11, 13, 13 and 18 years of age. Five other mares aged 11 or older were biopsied successfully.

2.4.2 Foal liver biopsy procedure

There was a small amount of bleeding from the liver after biopsy with the trucut needle, but seepage of blood from the needle track ceased within 3 to 4 min. There was more haemorrhage following biopsy with the Rhone Merieux cannula, which also stopped after 3 to 4 min in all cases. The foals showed no signs of ill effects attributable to the biopsy (including no disruption to appetite or body weight gain), except for one foal, which had mild subcutaneous emphysema due to a cannula being partly misplaced during insufflation. Two other foals became hypotensive during the anaesthesia (systolic pressure less than 90 mm Hg), but they responded to an increase in the flow rate of intravenous fluids and a decrease in the concentration of the inhalant anaesthetic.

At necropsy, liver scarring attributable to the biopsy could not be discerned, but there were occasional small, irregular pale white scars in the hepatic capsule. The distribution of these scars and their irregular shape were considered to be consistent with parasitic damage. There were no adhesions in the abdomen of any of the foals.

2.4.3 Liver biopsy copper concentrations

The liver biopsy concentrations in the mares ranged from 12.3 to 23.5 mg Cu/kg DM (mean 17.8 mg Cu/kg DM). The liver biopsy concentrations in the foals ranged from 134 to 805 mg Cu/kg DM (mean 351 µg Cu/g DM).

2.4.4 Site variation in liver copper concentration

The liver copper concentrations (mg Cu/kg DM) at the six sites in the six feral horses are presented in Table 2.1. The coefficient of variation for the six feral horses ranged 2.9 to 9.0 %. There was no significant difference ($P > 0.05$) between sites within the liver for the six feral horses, but there was a significant difference ($P < 0.05$) between horses.

Table 2.1 Copper concentration (mg/kg dry weight) at six sites across the liver of six feral horses, with mean, standard deviation (sd) and coefficient of variation (cv).

Horse	site 1	site 2	site 3	site 4	site 5	site 6	mean	sd	cv (%)
1	23.6	20.4	19.6	23.2	24.4	20.8	22.0	1.98	9.0
2	20.0	20.4	19.6	22.4	21.6	21.2	20.9	1.06	5.1
3	20.4	20.4	20.0	20.0	20.4	21.6	20.5	0.59	2.9
4	29.6	32.4	30.4	27.6	30.4	29.6	30.0	1.56	5.2
5	22.4	22.4	21.2	20.4	23.2	23.2	22.1	1.21	5.1
6	22.6	24.4	20.0	24.4	24.0	22.4	23.0	1.70	7.4
Lobe	Right	Right	Quadrate	Quadrate	Left	Left			
location	periphery	centre	periphery	centre	periphery	centre			

The coefficients of variation for the mean copper concentration for the 12 biopsy sized (30 to 60 mg fresh weight) samples were 12.3, 15.2 and 20.9 %. No site had a significantly different copper concentration from the mean of the homogenised liver Table 2.2.

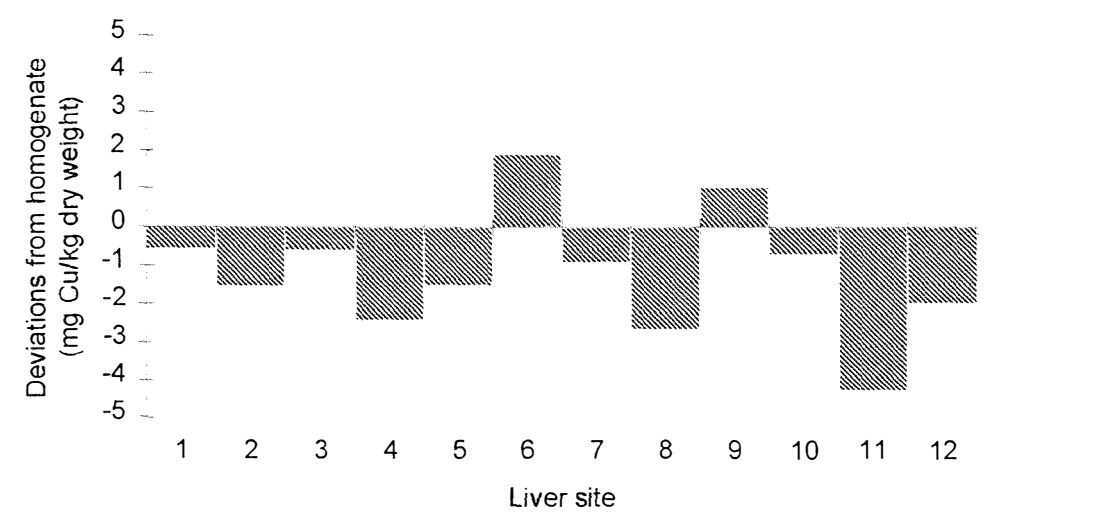
However there was a significant ($p < 0.05$), though minor bias, in that the concentration recorded in the total liver homogenate was higher (1.2 ± 0.05 , $n = 36$, $t = 2.12$) than that of the subsample. The mean difference between the copper concentration at each site and the copper concentration of the homogenised liver (total liver copper concentration) is presented in Figure 2.1.

Table 2.2 Liver copper concentration (mg/kg dry weight) with standard deviation (sd) and coefficient of variation (cv) of 30-60 mg (fresh weight) samples taken at 12 sites within each liver, and the total liver (homogenised) copper concentration, from three mature horses.

Site	Lobe	Location	Horse 1	Horse 2	Horse 3
1	Right	dorsal left	12.4	21.2	24.9
2	Right	dorsal middle	12.4	20.1	23.1
3	Right	dorsal right	11.6	21.3	25.5
4	Right	ventral left	12.8	20.9	19.3
5	Right	ventral middle	11.4	20.9	23.4
6	Right	ventral right	12.4	29.8	23.8
7	Quadrate	left	17.6	15.0	24.9
8	Quadrate	middle	10.7	19.8	21.8
9	Quadrate	right	12.8	30.9	19.7
10	Left	dorsal	15.2	21.1	21.8
11	Left	middle	12.4	18.5	16.6
12	Left	ventral	15.5	18.7	20.1
mean			13.1	21.5	22.1
sd			1.99	4.49	2.71
cv (%)			15.2	20.9	12.3
Homogenate of total liver ¹ (sd)			15.0 +/- 0.38	21.0 +/- 0.45	24.3 +/- 0.29

1. mean of 5 samples from the whole liver homogenate

Figure 2.1. Mean difference (mg/kg dry weight) between liver copper concentration at each site (30 to 60 mg fresh weight) and the total (homogenised) liver copper concentration for 3 mature Thoroughbred horses (refer to Table 2.2 for identification of sites). Differences were not statistically significant.



2.5 Discussion

In the mares, the liver biopsy technique was a short procedure and was performed with little difficulty. Occasionally, the mares reacted when the biopsy instrument penetrated the deep layers of the thoracic wall. Deep infiltration of lignocaine at the biopsy site helped diminish this response. The sedated mares required minimal restraint, and the biopsy procedure could easily be performed in the field. The mares were not fasted, because it is considered that fasting is not useful in large herbivores, as the gut content helps to hold the liver against the diaphragm (Pearson and Craig 1980).

The use of the ultrasound before biopsy identified situations when the right liver lobe was not present, ultrasonographically, in the target area. In these mares the presence of intestine in the biopsy area rendered them inappropriate candidates for performing standing, transthoracic, liver biopsies; they were re-scanned 1 to 2 weeks later and the situation had not changed. One mare (aged 18 years) was later necropsied for unrelated reasons and was found to have an atrophied right liver lobe. Atrophy of the liver is common in older horses and occurs more frequently on the right side because of pressure of the right dorsal colon and the caecal base (Dyce *et al.* 1987). The left side is not suitable for transthoracic biopsy in the horse, as the liver is asymmetrical with two thirds of the liver to the right of the midline, and the liver on the left does not extend beyond the caudal margin of the lungs.

The necessity of performing multiple passes with the trucut needle to obtain sufficient liver tissue (30 to 60 mg wet weight) for copper determination was a consequence of the low concentration of copper in mature equine livers (5 to 20 times less than ruminant livers). One pass with the trucut needle harvested 20 to 30 mg, hence the need for two to three passes. The trucut needles were re-used after sterilisation, but the more times they were re-sterilised, the less satisfactory was their performance. It was considered that the biopsy needles should only be re-used once or twice at best. Resharpening of the biopsy needles was not attempted, but may increase their performance when re-using them. It was helpful to make a bold stab incision with the scalpel through the skin, as this enabled the biopsy trochar to be manoeuvred more easily.

In this study, gut content was obtained on two occasions, and it was thought that in the course of doing repeated passes with the stylet, the biopsy needle exited the liver and penetrated a viscus. While the gut penetration was presumably the cause of the subsequent

mild to moderate colic, the horses recovered fully after simple symptomatic anti-inflammatory treatment. The most successful location for performing the liver biopsy was the 13th intercostal space, at about the level of the line between the tuber coxae and the point of the elbow, with the needle directed towards the contralateral elbow.

In the literature, standing, percutaneous liver biopsies are reported to be safe, and one study reported more than 200 liver biopsies from horses, cattle, sheep and goats without adverse effects (Pearson and Craig 1980). One adverse response to a liver biopsy in a horse was associated with a delayed prothrombin time, and therefore delayed coagulation is considered to be a contraindication for this technique (Tennant *et al.* 1973). Gibbons (1964) claimed that a branch of the hepatic or portal circulation is frequently encountered, but is rarely of consequence as hepatic blood clots very rapidly.

The foal biopsy procedure requires dedicated equipment, and is best performed where facilities and skilled staff are available. The procedure is costly and time consuming. Furthermore, foals in their first week of life may, in some situations, be an anaesthetic risk. The procedure, however, was straightforward and no major complication was encountered. At this young age, and with sufficient insufflation, visualisation of the organs in the abdomen was excellent, and there was no requirement to fast the foals, which could increase anaesthetic risk. Because of the importance of minimising morbidity with these animals, we used this laparoscopic technique to ensure that the biopsy was accurate and so that we could assess the amount of haemorrhage and other effects of the biopsy. Haemorrhage was minor, and the effects of the biopsy on the foals was minimal, which would suggest that an ultrasound-guided technique may be used successfully in the future on these animals.

The aftercare of the mares and foals described in this paper was more rigorous than required for the above procedures, but was necessary because of concurrent bone biopsies performed on the foals. The procedure appeared to be innocuous, since there were no post-operative complications attributable to the liver biopsy, nor was there any evidence of scarring or adhesions in the liver on gross examination at necropsy at five months of age. There were no adverse effects reported from blind, serial, percutaneous, liver biopsy in the work of Hurtig *et al.* (1990), and this technique is likely to be cheaper and avoids the anaesthetic risk associated with neonatal foals.

O’Cuill *et al.* (1970) indicated that the variability of copper concentration across the liver of horses (coefficient of variation up to 47 %) meant that an assessment of the liver copper stores from a liver biopsy could be subject to large error. However, our own investigation on liver copper concentration showed much less variability (coefficient of variation < 21%). In the case of the feral horses, the same number of sites per liver were taken as in the study of O’Cuill *et al.* (1970), and the coefficient of variation was considerably less (< 9 %). While it is difficult to explain the difference between studies, dietary and physiological factors may influence the distribution of copper in the liver. The study of O’Cuill *et al.* (1970), analysed 1 g samples from each liver site whereas we took 50 g samples; this may have influenced the variability detected, and both these samples are considerably greater than the amount harvested by the biopsy procedures (30 to 60 mg fresh weight). Therefore the study performed on the livers from the 3 mature horses was designed to determine the variability across the liver that may be expected when taking similar sized samples to the samples harvested by the described liver biopsy technique. Sites 1 to 6 were located in the right liver lobe which is the biopsy site in the standing (mare) technique. There was no systematic difference in copper concentration across the liver determined, and it can be expected that a liver biopsy of 30 to 60 mg (fresh weight) will give an estimation of total liver copper concentration with a coefficient of variation of 10 to 20 %. Whether this is accurate enough will be determined by the magnitude of difference from a reference value, or other animals, that needs to be established.

This study has shown liver biopsy to be an easy and reasonably accurate method for determining liver copper concentrations in neonatal and adult horses. The interpretation of liver copper concentration as a measure of dietary copper intake and relationships to plasma copper and caeruloplasmin oxidase activity are the subjects of continuing research.

Chapter 3

Biopsy of the Distal Radial Physis in Neonatal Foals²

.

² Submitted as: SG Pearce, EC Firth and WF Hunt (1997) *Veterinary Surgery*.

3.1 Abstract

A technique was devised for taking biopsies from the distal radial growth plate in neonatal foals for the purpose of studying physeal cartilage morphology. The biopsy of 21 Thoroughbred foals, 4 to 10 days of age, was performed under inhalant anaesthesia, using a trephine on a multi speed drill. Five foals (24%) developed excessive incisional granulation tissue, due to their exercise not being adequately restricted postoperatively. Nine foals (43%) developed some flexion of the carpus (over at the knee) and 15 (71%) developed outward rotation of the left limb. There was significantly greater carpal valgus in the left leg compared with the right ($p < 0.005$), which was not present in six age-matched, unoperated, control foals. There were no abnormalities in the congruency of the radiocarpal joint detected grossly at postmortem at 5 months of age. However there were gross and histological abnormalities of the distal radial growth plate. Postoperative morbidity, significant changes to conformation, and the unknown long term consequences of the disruption to the physis are likely to make this procedure inappropriate for clinical usage. However, the biopsy procedure was easily carried out and provided a suitable sample for histological and histomorphometric examination of the growth plate cartilage. Therefore this technique provides a useful research method for study of growth plate morphology in neonates.

3.2 Introduction

Abnormalities in the development of bone and cartilage present a significant problem to the equine industry worldwide, and there is some evidence that the incidence of the resulting diseases is on the increase (Jeffcott 1991). Developmental abnormalities of the growth plate, such as “physitis”, are a significant cause of morbidity in young foals (O’Donohue *et al.* 1992), and may result in undesirable conformational abnormalities (Fretz 1980; Auer *et al.* 1983).

Examination of growth plate morphology *in vivo* may help define early pathological changes. Pathological changes to cartilage canals, present in the early life of a foal, have recently been implicated in the development of articular osteochondrosis (Carlson *et al.* 1995). Biochemical abnormalities have also been reported in retained cartilage from cases of osteochondrosis of the intermediate ridge of the distal tibia (Lillich *et al.* 1997), and similar changes might also be present in retained cartilage of physes. Early changes to the

anatomical and biochemical structure of the growth plate may be associated with subsequent developmental abnormalities of the physis.

Biopsies from the wing of the ilium (Savage *et al* 1991) have been investigated for the early diagnosis of bone abnormalities. However, the histomorphometric parameters of biopsies from the wing of the ilium had little association with the incidence of dyschondroplastic lesions in a group of weanlings fed different levels of phosphorus and digestible energy (Savage *et al* 1993c). Misheff and Stover (1992) found that biopsies from the 12th rib, for the same purpose, were not suitable for histological or histomorphometric analysis. A technique for standing surgical growth plate (cartilage) biopsy has been described for the study of growth plate disorders in weanlings (Belling and Glade 1984). We required a technique for obtaining tissue for immunocytochemical studies of neonatal foal growth plates (Holle and Firth unpublished data). The purpose of this study is to describe and evaluate the biopsy technique we used and to indicate its usefulness for clinical and research purposes.

3.3 Materials and methods

3.3.1 Animals

A biopsy was performed on 21 mixed sex, healthy, 4 to 10 day old Thoroughbred foals which were subjects in a study of the effect of oral copper supplementation on copper status, and its possible role in developmental orthopaedic disease.

3.3.2 Biopsy technique

The foal was sedated with 0.5 to 0.75 mg/kg of xylazine, and anaesthesia was induced with isoflurane delivered through a nasotracheal tube. Anaesthesia was maintained with isoflurane using a small animal circle system with an out of circuit precision vapouriser. Lactated Ringer's solution with 1 % dextrose was infused at 10 ml/kg/h throughout the procedure. The foal was placed in left lateral recumbency, and the right carpus was prepared for sterile surgery and draped conventionally.

A 25 mm proximodistal curvilinear incision was made over the lateral aspect of the distal radial physis, and the skin and subcutis retracted. An 8 x 8 mm square of tissue from the

periosteal-perichondrial complex was either excised or hinged proximally, to reveal metaphyseal and epiphyseal bone. A trephine (Figure 3.1) (9 mm internal diameter, 11 mm external diameter), on a battery powered slow speed drill, was placed over the physis such that epiphyseal and metaphyseal tissue would be included in the core to be removed. The drill was directed slightly distally since the physis inclines in this direction. The burr penetrated 15 mm. When the burr was withdrawn, either it contained the excised core (to be removed with small needles) or the core remained attached at its base, and was removed by gentle leverage with a 20 gauge needle bent at right angles 3 mm from its end. Haemorrhage was controlled with surgical swabs using digital pressure. The periosteum was reapposed with simple interrupted sutures using 2-0 PDS, and the skin and subcutis were closed in two layers. A pressure bandage was placed on the limb, and the foal was hand recovered. The foals received 1.5×10^6 iu of procaine penicillin (im) and 100 mg of phenylbutazone (iv) intraoperatively.

Total anaesthetic time was 1.5 to 2 hours and included laparoscopically guided liver biopsy and radiological survey of the limbs. The recovered foals were returned to their dams, stabled and observed three times a day for three days and then placed in a small yard for 1 to 2 weeks before returning to the herd. The bandages were replaced every 3 to 4 days for 10 to 12 days.

Figure 3.1 Stainless steel trephine, 9 mm internal diameter, 11 mm external diameter, 24 mm trephine depth.



3.3.3 Conformation

The foals were assessed for conformational changes every one or two weeks until they were euthanased at 5 months. Conformation was recorded on a standard sheet, subjectively scoring the distal limb joints for angulation from in front, and for excessive flexion/extension from the side. Limb rotation, and joint distension were also scored. A scoring system from 0 to 3 was used ranging from normal to severe abnormalities. A mild abnormality (score = 1) was considered significant if it was present on two consecutive scoring occasions.

At the same time as the foals were scored, they were videoed, from in front and the right hand side, and the angulation of their carpus and front fetlocks was measured in both dimensions. The use of video-image analysis for conformation examination is described elsewhere (Hunt *et al.* in press).

The angulation of the biopsied (right) leg measured by video image analysis was subtracted from the left leg at each sampling occasion. The resulting values were analysed with time from biopsy by linear regression. Six age-matched, unoperated, clinically normal control foals were also videoed, and the difference between the angulation in their left and right legs were also calculated and analysed by linear regression. Linear regression of control foals was taken from the average day of biopsy in operated animals (day 6). A comparison of linear regressions for operated and unoperated foals was performed. Analyses were performed with Statistical Analysis System (SAS) version 6.11 (SAS Institute Inc. Cary, N.C., USA) using procedures for the general linear model.

3.3.4 Postmortem examination

Intravenous pentobarbitone injection was used to euthanase the foals at 5 months of age. The biopsy site was examined for gross abnormalities of the distal radius and the radiocarpal joint. The left and right radius from each foal was weighed, its length and mid diaphyseal circumference measured, and its volume estimated by water displacement. Differences were tested for significance by paired-t tests ($\alpha = 0.05$). In 20 of the 21 foals, the distal radius was sawn frontally into approximately 6 slabs 6 mm wide. The frontal slabs were examined grossly, and cabinet radiographs taken. A section through the biopsy site

was decalcified in formic acid/formate, paraffin embedded, sectioned at 6 μ m, and stained with haematoxylin, eosin and alcian blue.

3.4 Results

3.4.1 Surgery

Removal of a core of the distal radial physis was readily achieved. All foals recovered from anaesthesia uneventfully. Lameness was not evident when the foal was returned to the dam, nor during observations over the following 1-2 weeks. In a few cases, after-care instructions were not complied with and the foals were returned to the herd early. In one case, the surgical wound dehisced, developed excessive granulation tissue and lameness persisted for several weeks. In another 4 cases, the wound partially dehisced, and healed uneventfully by secondary intention after granulation tissue excision, bandaging, and confinement. Of these 4 cases, complete healing occurred within 4 weeks for 3 foals, and 12 weeks for 1 foal, with no residual lameness.

3.4.2 Conformation

Nine foals (43 %) developed mild flexion of the carpi following biopsy. In all cases the carpal flexion was bilateral. In 6 foals, the flexion had resolved after 5 to 6 weeks post surgery, while 2 took 8 weeks, and the foal that developed chronic lameness had a mild bilateral carpal flexion for the duration of the trial (5 months). Fifteen foals (71%) had mild outward rotation of the left forelimb that became evident from 2 to 9 weeks following surgery. Two foals (10 %) developed outward rotation of the right forelimb at 8 and 16 weeks postoperatively.

There was a significant relationship between the difference in carpus angle (left - right) in the operated foals ($p < 0.005$) with time (Figure 3.2a), but no such relationship existed for the control foals (Figure 3.2b). Separate linear regressions for both sets of data provided a significantly better model ($p < 0.05$) than a common regression relationship.

Figure 3.2 The difference (right subtracted from left) in carpus (valgus) angle as viewed from in front of:

- a) 21 foals with time from the physeal biopsy procedure.
- b) 6 age-matched, unoperated control foals with time from the median day of growth plate biopsy (day 7) in operated foals.

Angles were calculated using video image analysis.

Figure 3.2a

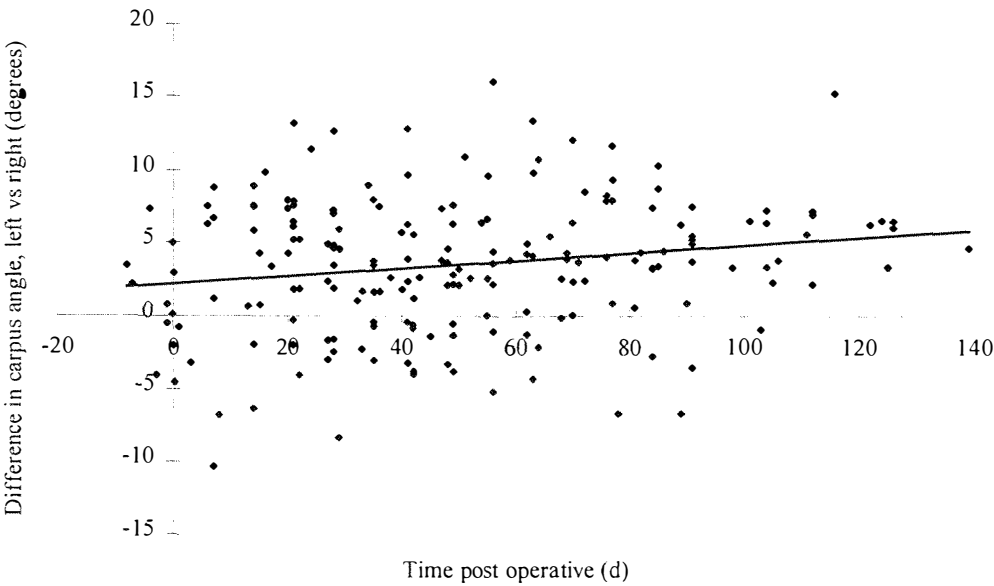
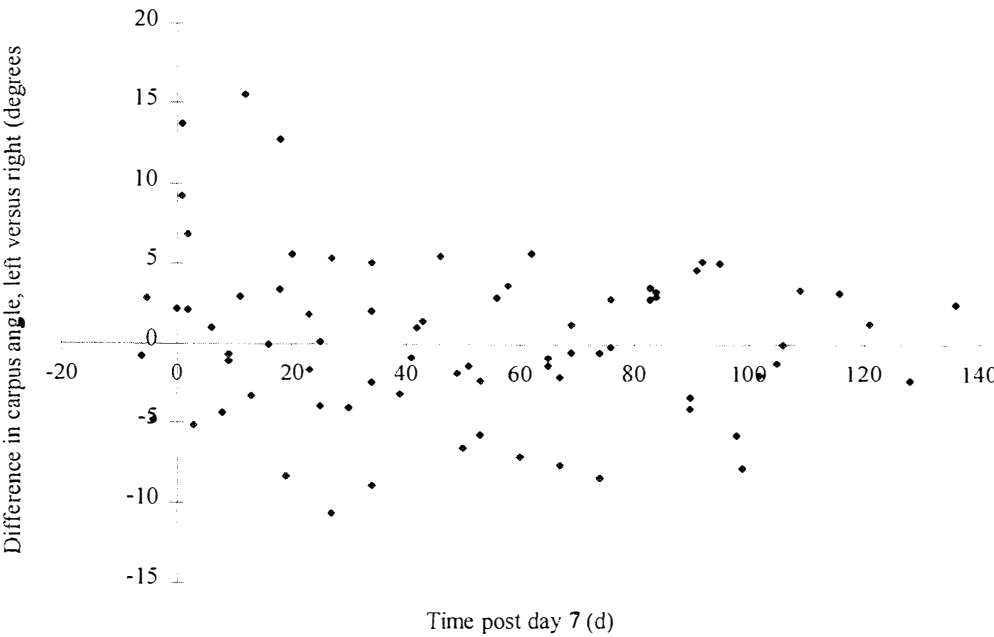


Figure 3.2b.



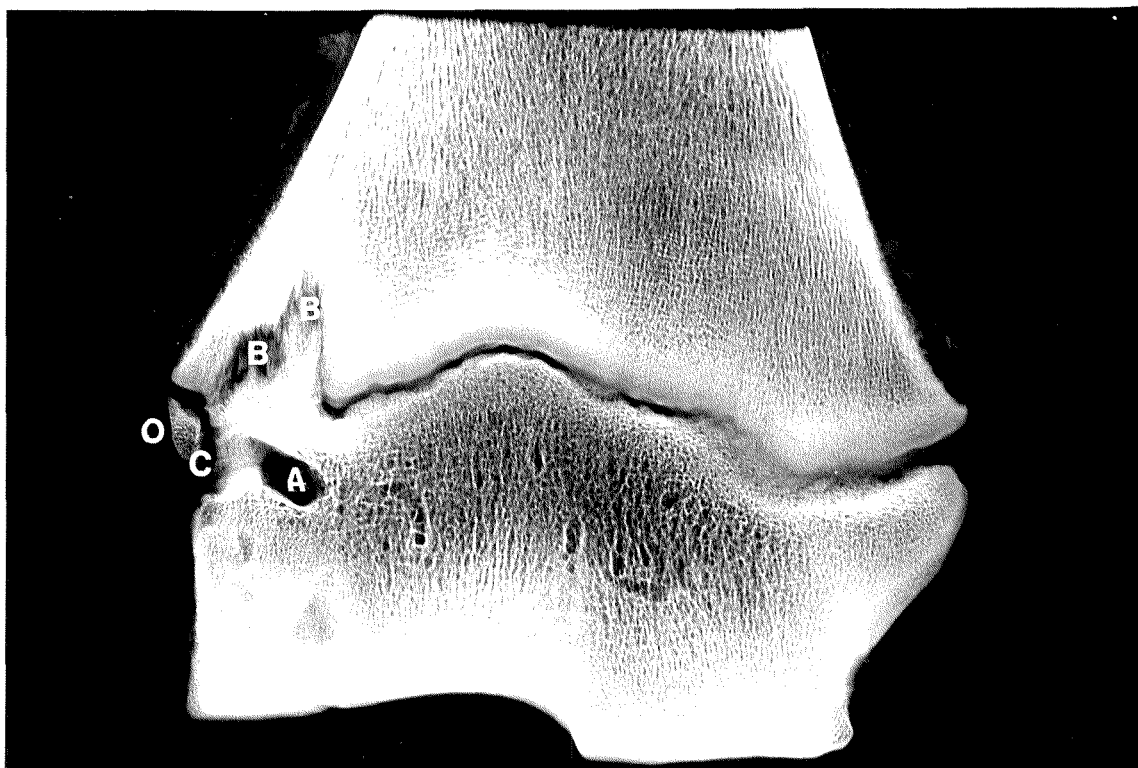
3.4.3 Postmortem

There was no significant difference ($p > 0.05$) between weights, lengths or densities of the left and right radii. The external morphology of the right distal radius did not appear grossly different to that of the left side, and there were no abnormalities detected in the radiocarpal joints. On frontal sections (6 mm thick) of the distal radius, the physeal disruption associated with the biopsy was apparent in all cases. The normal path of the lateral aspect of the physis was disrupted, with struts of bone passing through the physis and cartilage or fibrocartilage present in the metaphysis.

Radiographs of the slabs revealed 3 different morphological abnormalities in the area of the biopsy. These were classified A, B and C (Figure 3.3). “A” consisted of a curved, roughly parallel radiolucency in the epiphysis, approximately 3 mm from the physis on the lateral margin of the slab and curving distally toward the articular surface. “B” consisted of an irregular radiolucency, roughly triangular or rectangular shaped, continuous with the physis and extending into the metaphysis. “C” consisted of a tall, thin, roughly rectangular area of radiolucency on the lateral border of the frontal slab, at the level of the growth plate extending into both the epiphysis and metaphysis.

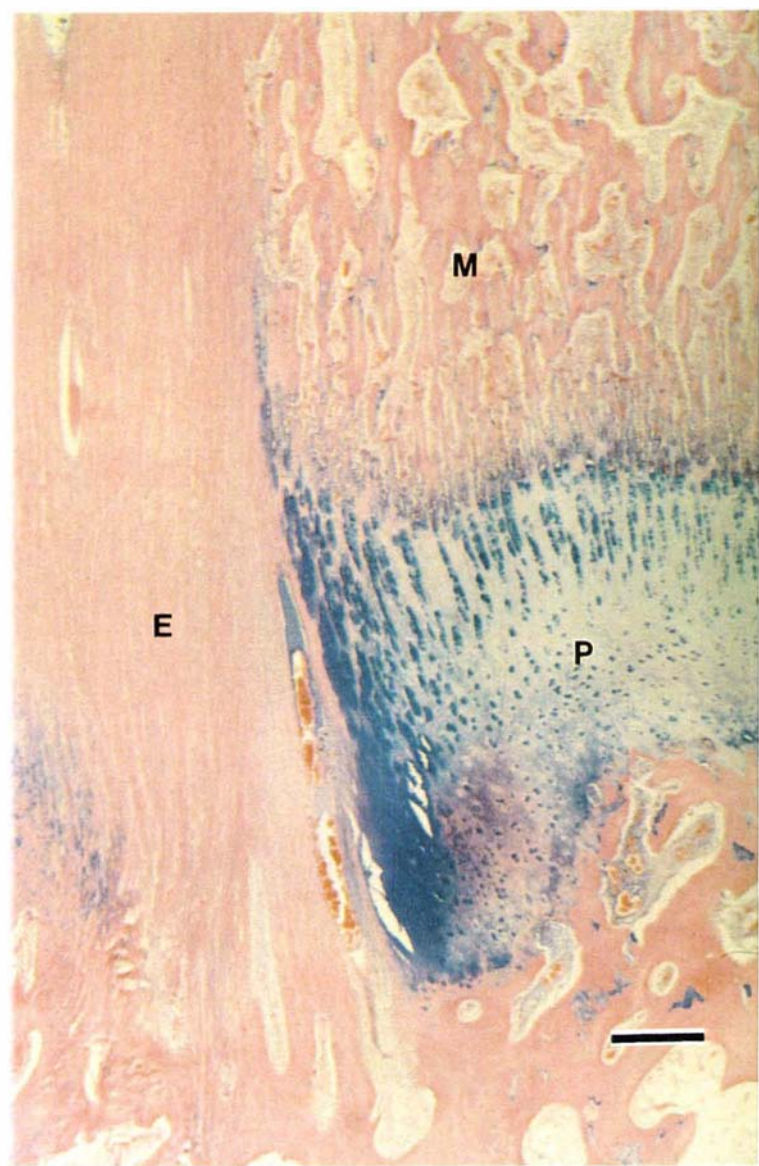Changes A, B and C were present in the radiographs of 15 foals (75%). Of the 5 remaining foals only B was seen in 2 foals, only C in 1 foal, A and B were seen in 1 foal, and in 1 foal, obvious epiphyseodesis, and periosteal reaction proximal to the growth plate on the lateral cortex could be seen, but the changes were not typical of A, B or C. In most cases the radiographic changes were evident on two or three of the 6 mm frontal slabs through the distal radius. In only 8 of the 15 foals with changes A, B and C, were these changes present on the radiograph of the same slab.

Figure 3.3 Thin section cabinet radiograph of a frontal section through the distal radius showing the effect of the biopsy on the physis laterally. Morphological changes A, B, and C as described in the text, are depicted. A small ossicle (O) is seen in the middle of change C on the lateral border of the radiograph, at the level of the physis.



Histological examination of the distal radial growth plate revealed no abnormalities medial to the site of the biopsy. Changes began abruptly about 15 mm from the lateral margin of the radius. A defect in the epiphysis, consistent with change A seen on cabinet radiographs, contained no trabecular bone and was filled with mature collagen, fat, and vascular tissue. The radiographic change B was consistent with an epiphyseodesis which consisted of areas of trabecular bone, and in places, bundles of collagen and rows of fibroblasts arranged parallel in the direction of longitudinal growth (Figure 3.4). The collagen bundles merged with trabecular bone surrounded by numerous active osteoblasts at both ends of the epiphyseodesis. Some fibrocartilage was also often seen continuous with the physis at the point of disruption, and was also seen occasionally at the periphery of the epiphyseal defect.

Figure 3.4 Low power view of the histological features of an epiphyseodesis (E) at the biopsy site showing the trabeculae aligned perpendicular to the physis (P), extending into the metaphysis (M). Stain: Alcian Blue, Haematoxylin and Eosin. Magnification: Bar = 500 μ m.



Histologically change C was evident as a thickening of the periosteal-perichondrial complex encroaching on the lateral margin of the distal radius at the level of the physis. The foal with the atypical radiographic appearance of the biopsied slab, appeared histologically to have a more mature epiphyseodesis containing less fibrous tissue, and more trabecular bone.

3.5 Discussion

The lateral aspect of the distal radius was chosen as a site for biopsy due to easy surgical access, and its predisposition for cartilage retention and possible role in physitis and angular limb deformities (Firth and Poulos 1984).

The surgical procedure was easily performed. The only problem encountered was the possibility of failing to obtain the complete thickness of physis in the biopsy core, due to the distal inclination of the growth plate from the lateral margin. Also, occasionally the biopsy core broke off inside the trephine, and removal of the core was difficult and could result in fracture of the biopsy core. These problems were minimised by preventing change in direction of the trephine. An adaptation to the burr such that the biopsied core could be expelled would be advantageous for this procedure.

The internal diameter of the trephine was chosen such that the biopsied core would contain full thickness of the physis connected to bone of the metaphysis and epiphysis. In a small number of cases, this objective was not achieved, and so a larger diameter burr may have been more suitable. However a larger diameter burr would result in a greater degree of physeal disruption, and greater chances of significant effects of epiphyseodesis. Prevention of epiphyseodesis, for instance by use of fat grafts, might then become important. Autogenous fat grafts, harvested from the flank, have been reported for the prevention of bony bridging after osteotomy in dogs (Craig 1981).

Postoperatively, 5 of the foals suffered some degree of wound dehiscence at 10 to 20 days after surgery. This may have been prevented if the after care of the foals involved a longer period of confinement. However, the foals were part of an experiment which required their consuming a pasture diet, and thus they were returned to pasture prematurely.

Most of the foals developed outward rotation of their non-operated (left) forelimb. Two foals had a mild right forelimb outward rotation. Outward rotation is described as being secondary to angular limb deviation which results in uneven weight bearing on the affected limb. The rotation decreased in severity as the foals aged, and there was no apparent need for intervention.

There was a significantly greater carpal valgus in the left limb than in the right. Data from control foals were analysed to document that the difference was abnormal in growing foals. Contralateral limb deformities have been produced in the hind limb of immature lambs by excisional femoral arthroplasty (Duff 1986). These animals developed an inward rotation of the limb and a varus deviation at the level of the distal tibia. It was also noted that a milder inward rotation of the tibia was a normal ageing process for control animals. Most foals in this study developed an outward rotation and valgus deformity in the unoperated forelimb. Mild valgus deformity was commonly found in all carpi including those of control foals. Therefore it is possible that extra weight bearing in the contralateral limb, as a result of the biopsy, exacerbated this normal conformation and caused an associated outward rotation. However there were no joint incongruities obvious, nor any gross morphological differences between the biopsied radius and the contralateral limb. There is little known about the normal age related changes to conformation at different sites in quadrupeds and the role of weight bearing on this (Duff 1986).

The cabinet radiographs of the frontal sections through the radius and the histology of the biopsy site demonstrated that the cavity remaining after biopsy was retained in the epiphysis, and the physis was disrupted by trabecular bone. There was also considerable bone remodelling into the metaphysis. The morphological change A was consistent with the site of the biopsy core. It had a curved appearance, presumably due to the uneven pattern of growth in the epiphysis from biopsy until postmortem. The radiolucency extending into the metaphysis (B) was consistent with the collagenous fibres laid down during the reparative process following biopsy. These fibres were oriented in the direction of longitudinal growth and merged with the trabecular bone in a similar manner to Sharpey fibres; the trabecular bone appeared to contain osteoblasts actively producing osteoid, and with time, the collagen fibres may have been replaced by trabecular bone.

Belling and Glade (1984) used a hammer and a curved 10 mm bone gouge to remove growth plate tissue in standing sedated yearling horses and claimed that after 4 weeks the site was healed sufficiently to repeat the biopsy in a neighbouring site. They also claimed that postmortem examination of 6 yearlings 4 weeks postoperatively revealed "no evidence of mechanical damage or persistent intracartilaginous or osseous wounds in any of the specimens". This differs from our postmortem results, and might reflect the fact that we biopsied neonatal foals rather than yearlings, and we performed necropsy much longer after surgery. There may also have been differences in the methods of postmortem examination.

In this study, the foals exhibited significant conformational changes, some postoperative morbidity, and obvious postmortem physeal changes. These effects might preclude this technique from clinical usage. However, better adherence to a stricter postoperative regime, the use of anti-inflammatory medication, and feet trimming to minimise morbidity and conformational abnormalities are expected to significantly decrease the adverse effects of this procedure which was conducted in a research environment which could not be completely regulated for investigation of the surgical technique. Thus the technique might be useful in clinical situations. At present the technique certainly provides a useful research tool for further studies on physeal morphology and the characterisation of early developmental lesions.

Chapter 4

The Effect of Copper Supplementation on the Copper Status of Pregnant Thoroughbred Mares and their Neonates³

³ Submitted as: SG Pearce, ND Grace, JJ Wichtel, EC Firth and PF Fennessy (1997) *Equine Veterinary Journal*.

4.1 Abstract

Pregnant Thoroughbred mares ($n = 21$) were grazed on tall fescue pasture containing 4.4 to 8.6 mg Cu/kg Dry matter (DM). Twelve mares were supplemented with approximately 0.5 mg Cu/kg liveweight (LW)/day as copper sulphate for the final 13 to 25 weeks of gestation. Plasma copper concentration declined during the third trimester for all mares and was not affected by copper supplementation. Liver copper concentration of mares and foals was determined when the foals were 4 to 10 days old. Copper supplementation of the mares tended to increase mare liver copper concentration ($p < 0.08$), and increased foal liver copper concentration ($p < 0.01$). There was a significant relationship between mare and foal liver copper concentration ($p < 0.001$, $r^2 = 0.7$). Increasing the copper intake of mares is effective in enhancing the copper status of foals.

4.2 Introduction

There has been considerable interest in the copper requirements of growing horses, with the dietary copper requirements recommended by the NRC (1989) being challenged (Hurtig *et al.* 1993; Lewis 1995). Maternal and foetal copper metabolism are intimately linked (Mason 1979, Hidioglou and Knipfel 1981), although little is known about this relationship in horses. A greater understanding would allow more informed recommendations of copper requirements of the dam during pregnancy, and offer the possibility of influencing the copper status of the neonate for either treatment of congenital copper deficiencies, or as a prophylaxis for putative copper-responsive conditions of the growing foal.

Dietary copper requirements for pregnant and lactating mares are considered to be the same as for other classes of horses (NRC 1989). However copper metabolism in pregnant mares might be expected to be different to non-pregnant horses, because of changes in appetite and intake in the mare, and the extra nutritional requirements of the foetus. In this respect, peak daily deposition of copper in the foetus (10th month of gestation) has been estimated at around 4 mg Cu (Meyer and Ahlswede 1978). In ruminants, foetal demand for copper increases throughout gestation, with up to 50 % of the newborn lamb's total copper being stored in the liver (Pryor 1964; Grace *et al.* 1985).

Copper deficiency in calves is considered to be evident postnatally, whereas symptoms of copper deficiency in sheep and goats may be evident *in utero* (Hidioglou and Knipfel

1981). The relatively lower foetal copper accumulation in sheep compared with cattle may account for the higher incidence of congenital copper deficiency syndromes in sheep (Gooneratne *et al.* 1989). In sheep and goats, copper deficiency late in gestation may result in an inadequate supply of copper to the foetal central nervous system, resulting in a disease characterised by motor disturbances (Jubb and Huxtable 1993). Some ewes are relatively resistant to the effects of low copper diets and may produce normal lambs because of increased copper transfer across the placenta in these animals (Hidiroglou and Knipfel 1981). Transplacental copper transport in the final part of the third trimester is important to provide adequate copper for human neonates, and premature birth is considered a risk factor for copper deficiency in the infant (Tyrala 1986; Solomons 1988). This can appear clinically as osteoporosis, oedema, ataxia, anaemia, neutropenia, and apnoea in the neonate (Sutton *et al.* 1985; Solomons 1988). The effect of copper deficiency on foals *in utero* has not been described.

In mares, increased maternal copper intake may also be important as low copper status during pregnancy has been associated with fatal rupture of the uterine artery during foaling (Stowe 1968).

The objectives of this study were to determine the effect of two levels of dietary copper intake of pregnant pasture fed mares on their plasma copper concentration in the final trimester, and on mare and foal liver copper concentration shortly after parturition.

4.3 Materials and methods

4.3.1 Animals

Pregnant Thoroughbred mares ($n = 24$, 4 to 20 years of age) were purchased, and grazed on tall fescue pasture from May 1994 for the duration of the experiment at AgResearch's Flock House Research Centre near Bulls on the North Island of New Zealand. When pasture availability was inadequate to meet requirements from May to July, the mares received supplementary tall fescue hay, produced from the same property. The copper concentration of the pasture ranged from 4.4 to 8.6 mg Cu/kg DM, and the hay contained 11 mg Cu/kg DM.

The mares were randomly allocated to either a control or copper supplemented group, matched for mare age, date of last service and the sire of the pregnancy. Copper supplementation began in June and continued until parturition. Mares foaled from 30th August to 24th November, so that at the start of supplementation they were 13 to 25 weeks from foaling. The copper supplemented group received a drench three times a week which contained copper sulphate (equivalent to 0.5 mg Cu/kg LW/day), as well as zinc sulphate (0.5 mg Zn/kg LW/day) and sodium selenate (0.02 mg Se/kg LW/day). The control animals received zinc and selenium only. Zinc and selenium were supplemented to ensure that all trace elements except copper were above NRC (1989) recommendations throughout the trial. Three foals died at birth leaving 21 mare-foal pairs (9 control and 12 copper-supplemented mares)

4.3.2 Sampling

Jugular venous blood was collected into trace element, sodium heparin vacutainers (Becton Dickinson, #367735). Samples were taken monthly during the final trimester and analysed for plasma copper concentration.

A laparoscopically-guided, transabdominal, liver biopsy (Chapter 2) was performed on each foal, at 4 to 10 days postpartum. On the same day, a standing, ultrasound-guided, transthoracic, liver biopsy was attempted on each mare on the same day. However only 16 of the 21 mares were successfully biopsied (6 control and 9 supplemented); failure was due to the presence of large intestine in the biopsy target site (Chapter 2).

4.3.3 Chemical analysis

Plasma copper concentration

Plasma (1 ml) and concentrated HNO_3 (1 ml) were placed in a 15 ml tube and left overnight. The mixture was incubated in a water bath at 70°C for 3 hours, 1 ml of 30 % H_2O_2 was added and then the mixture was incubated again at 70°C for a further 2 hours. The sample was made up to a volume of 6.5 ml with 2M HCl and the copper concentration determined using an inductively coupled plasma emission spectrometer (ICP) (Lee 1983).

Liver copper concentration:

The biopsy sample was prepared and analysed as described in Chapter 2. The copper concentration was determined using a Zeeman graphite furnace atomic absorption spectrometer. Concentrations were expressed on a dry matter basis.

4.3.4 Statistical analysis

All analyses were performed on the 21 mare-foal pairs. The effect of copper supplementation on mare prepartum plasma copper concentration and mare and foal liver copper concentration at 4 to 10 days postpartum was analysed by analysis of variance (ANOVA). Regression analyses were performed to investigate the relationship between plasma copper concentration and stage of gestation and also between mare and foal liver copper concentration.

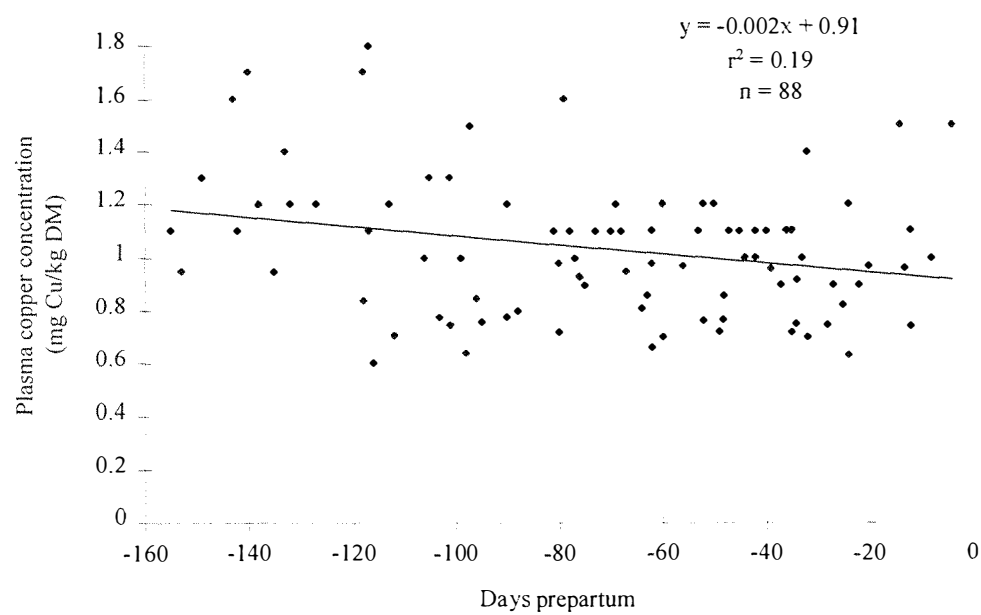
The regression models for ANOVA included mare age and foaling date as covariates, while the model for foal liver copper concentration also included gestational length as a covariate. All analyses were performed with Statistical Analysis System (SAS) version 6.11 for Windows (SAS Institute Inc., Cary, N.C., USA).

4.4 Results

4.4.1 Plasma copper concentration

Changes in plasma copper concentrations for the 150 days prior to parturition are presented in Figure 4.1. There was a significant ($p < 0.001$) decrease in the plasma copper concentration during this period, with foaling date significant ($p < 0.001$) as a covariate. These two factors accounted for approximately 20% of the variation. There was no significant difference in the relationship between control and copper supplemented mares and the stage of gestation.

Figure 4.1 The relationship between plasma copper concentration and time prepartum in the 21 mares.



4.4.2 Liver copper concentration

Mare

The mean (+/- standard error of the mean (SEM)) copper concentration for control and copper supplemented mares was 16.6 +/- 1.01 and 18.5 +/- 1.28 mg Cu/kg DM respectively (Table 4.1). Although copper supplementation did not have a significant effect on mare liver copper concentration there was a trend toward increased liver copper concentration in the supplemented mares ($p < 0.08$).

Foal

The mean (+/- SEM) copper concentration for foals, at 4 to 10 days of age, from control and copper supplemented mares was 253.9 +/- 20.2 and 423.8 +/- 71.3 mg Cu/kg DM respectively (Table 4.1), and the foal liver copper concentrations ranged from 134 to 805 mg Cu/kg DM. Mare supplementation had a significant effect on liver copper concentration of the foals ($p < 0.05$).

Table 4.1 Effect of copper supplementation of mares on mare (n = 16) and foal (n= 21) liver copper concentration (mg Cu/kg DM +/- SEM) at 4 to 10 days postpartum.

	Mare Liver	Foal Liver
Control Mare	16.6 (1.01)	253.9 (20.2)
Supplemented Mare	18.5 (1.28)	423.8 (71.3)

There was a significant ($p < 0.005$) positive linear relationship between mare and foal liver copper concentration (Figure 4.2). The quadratic term for the relationship was investigated, but was not significant. Age of the mare ($p < 0.01$), but not parity, was significant as a covariate. Liver copper concentration of foals from supplemented mares increased with the age of their dam (Figure 4.3).

Figure 4.2 The relationship between mare and foal liver copper concentration (mg Cu/kg DM) at 4 to 10 days postpartum from copper control (□) and supplemented (■) mares.

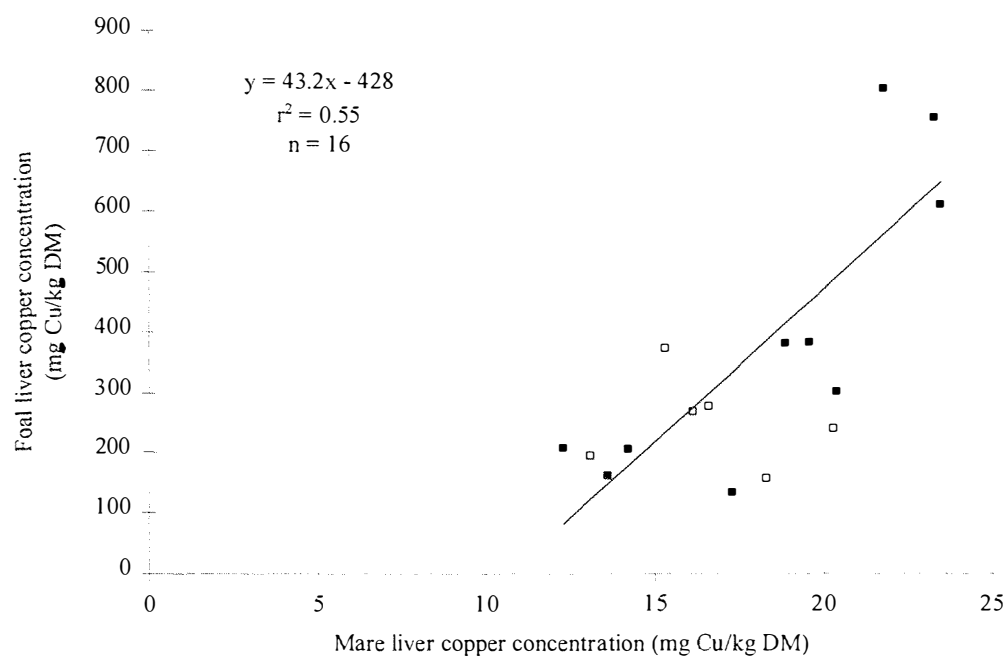
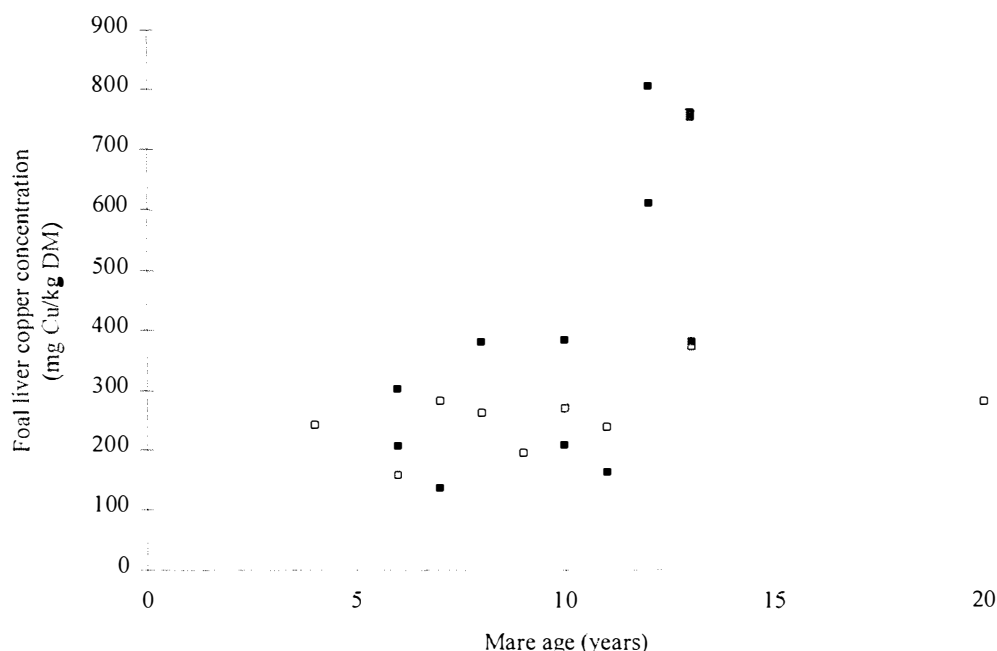


Figure 4.3 The relationship between mare age and foal liver copper concentration at birth for foals from control (□) and copper supplemented (■) mares.



4.5 Discussion

The decrease in plasma copper concentration of the pregnant mares in their final trimester suggested possible negative copper balance during this period. However, supplementation of the pasture diet with copper sulphate did not increase the copper status of the mare during this period. This suggests a possible physiological cause for the decrease in the plasma copper concentration. There was a trend, however, toward increased liver copper concentration in the copper supplemented mares ($p < 0.08$). Neonatal foal liver copper concentration was significantly increased by mare dietary copper supplementation, and there was also a strong relationship between mare and foal liver copper concentration measured soon after parturition.

The New Zealand Thoroughbred industry is predominantly pasture based, and the copper concentration for most pasture diets is similar to our control diet (4.4 to 8.6 mg Cu/kg DM). The dietary copper intake of the supplemented mares was approximately 3 to 4 times that of the control animals (8 vs 30 mg Cu/kg DM).

The decreasing plasma copper concentration in the final trimester is contrary to the study of Stowe (1968), who found a small increase in serum copper concentrations during gestation. Auer *et al.* (1988a) found that pregnant mares had similar plasma copper to their non-pregnant pasture mates with no apparent effects of stage of gestation, but a second study (Auer *et al.* 1988b) found a significantly higher plasma copper concentration in pregnant mares than in lactating mares. Our results are not in agreement with these studies, and may reflect differences in genetic composition, or in management regimes. Foaling date was used as a covariate in our analyses to account for the likely confounding effect of season.

Increasing plasma copper concentration with increasing gestation occurs in women (Mason 1979) where plasma copper concentration can increase to up to 2.5 times that in non-pregnant women (Widdowson *et al.* 1974). Some theories explaining the increase in plasma copper in women (reviewed by Mason 1979), include: alterations in the competitive binding of copper and zinc with metallothioneins, a response to the continual inflammatory stimulus of the foetus, and an association between plasma copper concentration and oestrogen, which may also explain the higher plasma copper concentration in women compared with men. Increased dietary copper intakes in pregnant women (from 2.5 to 4.6 mg Cu/day) does not alter serum copper concentration or caeruloplasmin oxidase activity (King and Wright 1985).

For horses, ruminants might be a more appropriate comparison species than humans in respect to their dietary and management conditions. In one experiment (Butler 1963), housed pregnant ewes were fed either half estimated dietary copper requirements (2 mg/day) or a high copper diet (approximately 15 mg/day). Plasma copper indices including whole blood, plasma, erythrocyte, and caeruloplasmin-bound copper concentrations all declined throughout gestation in both treatment groups. The blood copper concentration continued to decline for another month postpartum, and then increased to pre-mating levels shortly afterwards. This pattern of change occurred in both dietary groups, but did not occur in a group of barren ewes used as controls. The decline in blood copper indices was not as marked in the high dietary copper group, but was still significant.

Dietary copper intake has been shown to be reflected in the liver copper concentration of young horses receiving 8 to 108 mg Cu/kg DM and mature ponies receiving 8 to 790 mg Cu/kg DM (Cupps and Howell 1949, Smith *et al.* 1975), but this relationship was not so obvious in the pregnant mares of this study (8 or 30 mg Cu/kg DM). This may be a result of

differences in copper metabolism associated with pregnancy. The liver copper concentration of our neonatal foals was influenced by the dietary copper intake of the mares suggesting preferential storage of the supplementary dietary copper in the foetal liver. A similar relationship between dietary copper intake and foetal liver copper concentration has been observed in cattle (Smart *et al.* 1992). In a region with a high prevalence of hypocuprosis, the copper status of calves was related to the copper status of their dams, and maternal liver copper concentration and foetal age were determined to be good predictors of foetal liver copper concentration (Gooneratne and Christensen 1989).

There was considerable individual variation in liver copper concentration of foals from supplemented mares, and the distribution of the data was bimodal. Of these 12 foals from supplemented mares, 4 had liver copper concentrations greater than 600 mg Cu/kg DM, and the remaining 8 were less than 400 mg Cu/kg DM. The higher liver copper concentrations might indicate the ability of some foals to accumulate copper *in utero* to a greater extent than others. The variation in the liver copper concentrations of foals from control mares was relatively small and the sample distribution was normal. The effect of mare age on foal liver copper stores at parturition is of interest, as all foals with liver copper concentrations greater than 600 mg Cu/kg DM came from supplemented mares aged 12 or greater. This is possibly due to an age related difference in the copper metabolism of pregnant mares, which does not seem to be related to parity. However the numbers were too small to make definitive conclusions.

The liver biopsy, as a technique for estimating liver copper concentration has been criticised due to the variation of the copper concentration within the liver (O’Cuill *et al.* 1970). However, much smaller variation was found in a recent study of New Zealand horses (coefficient of variation of 10 to 20 %) (Chapter 2). The variation and magnitude of the liver copper concentration from our neonatal foals was consistent with two other reports of neonatal liver copper concentrations from mares of unknown dietary history (Egan and Murrin 1973b; Meyer and Tiegs 1995).

The lack of a copper transport protein (caeruloplasmin) *in utero* enables high levels of copper to accumulate in the foetal liver (Chang *et al.* 1975; Widdowson 1974). The role of these liver copper stores at birth is uncertain. Copper absorption of young ruminants (Suttle 1975) and neonatal rats during ingestion of milk diets is very high due to the pinocytosis of copper complexes, which enables the resorption of copper excreted in the bile (Mistilis and

Mearrick 1969). Biliary excretion is also reduced in these animals, thereby enhancing copper conservation. This decreases dietary copper requirements while on milk, a diet containing low copper concentrations (0.2 to 0.3 mg Cu/l). Therefore stored liver copper at birth may reflect the inability of the foetal liver to excrete copper rather than foetal supply of copper for early life (Bremner 1991; Cymbaluk and Smart 1993). However Meyer and Tiegs (1995) claim that despite this high copper absorption, there is a shortfall between daily copper requirements and absorbed copper, which can be met by mobilisation of copper from the liver copper stores accumulated *in utero*.

Increased copper intake of the mare provided increased copper storage in the foetal liver, which may be of importance for the growing foal. However, there was considerable variability in foal liver copper concentration in foals from supplemented mares, and the relationship between mare dietary copper intake and foetal copper stores appears to be complex. The effect of mare age on foetal copper stores needs further investigation.

Chapter 5

The Effect of Copper Supplementation on the Copper Status of Pasture-Fed Young Thoroughbreds⁴

⁴ Submitted as: SG Pearce, ND Grace, EC Firth, JJ Wichtel, SA Holle and PF Fennessy (1997) *Equine Veterinary Journal*.

5.1 Abstract

The effect of copper supplementation of pasture fed mares and foals on the copper status of the foals, in terms of plasma, soft tissue and bone copper concentrations and caeruloplasmin activity, was investigated. Twenty one Thoroughbred foals from either control mares (n = 9), or copper-supplemented mares (n = 12) were randomly divided into control (pasture only, n = 10) or supplemented (pasture and oral copper sulphate, n = 11) groups. The pasture diet was grazed by all animals, and contained 4.4 to 8.6 mg Cu/kg dry matter (DM). The copper supplement for the mares contained copper sulphate equivalent to 0.5 mg Cu/kg liveweight (LW)/day, and was administered three times a week for 13 to 25 weeks prior to foaling. The supplemented foals, also dosed three times a week, received 0.2 mg Cu/kg LW/day at 21 days of age, which was increased to 0.5 mg Cu/kg LW/day at 49 days and was continued at this level until euthanasia at 150 days. Foal plasma copper concentration and caeruloplasmin activity increased from birth to 21 days postpartum and then plateaued at a concentration similar to the mare, but the rise in these indices was not affected by copper supplementation of the mare or foal. Copper supplementation of the foal increased foal liver copper concentration at 150 days ($p < 0.03$). Copper intake of diets containing approximately 8 to 30 mg Cu/kg DM is well reflected by liver copper concentration, but is poorly reflected by bone, other soft tissue copper concentrations and circulating copper status indices.

5.2 Introduction

Copper is an essential trace element, associated with a variety of metalloenzymes responsible for many biologically important functions, and there is growing interest in the role of copper deficiency in certain clinical conditions. Recent work has suggested a relationship between dietary copper intake and abnormalities of bone and cartilage development in the young growing horse (Knight *et al.* 1985; Gabel *et al.* 1987; Asai *et al.* 1993), and has resulted in some concern regarding the adequacy of dietary copper requirements recommended by the NRC (1989).

Many factors influence the effect of dietary copper intake on copper status in animals. Much of the work has involved ruminants and includes factors such as the post-weaning development of the rumen (Suttle 1975) and mineral antagonists such as molybdenum, sulphur, iron and zinc, that affect copper absorption and metabolism (Gooneratne *et al.*

1994; Suttle 1994). Less information is available for the horse, and differences in copper requirements for horses of different age, sex, breed and pregnancy status have not been well defined. Cymbaluk *et al.* (1981a) studied copper metabolism in a small number of mature ponies using isotope techniques, and from calculations of obligatory (endogenous) losses, estimated dietary copper requirements to be 3.5 mg Cu/kg DM. Isotope kinetic studies provide accurate information on mineral metabolism, but generally involve only small numbers, and breed differences may limit extrapolation. For instance, breed differences in copper absorption and metabolism on various copper diets have been demonstrated in sheep (Woolliams *et al.* 1983) and cattle (Ward *et al.* 1995). Two other commonly used approaches for determining mineral requirements are factorial modelling techniques and dose response trials.

The factorial model (Grace and Clark 1991) is a mathematical approach which determines mineral requirements from information obtained from isotope kinetic studies, nutrition balance trials and slaughter experiments. This approach is limited by the lack of information on copper metabolism in the horse. For example, there are very wide ranges reported for the apparent absorption of copper from various feeds (Cymbaluk and Smart 1993) and for faecal endogenous losses (Cymbaluk *et al.* 1981a; Pagan 1994). Changing growth rates, interactions with other minerals, and substitution of milk with solid feed further complicate the model.

Cupps and Howell (1949) performed a dose response trial (8, 18 and 108 mg Cu/kg DM) in Percheron foals (aged 103 to 185 days), to determine dietary copper requirements. No differences in growth rate, plasma copper, packed cell volume, blood cell count and haemoglobin concentration were detected, and so it was concluded that copper requirements were less than 8 mg Cu/kg DM. It was also noted that the role of higher dietary levels of copper on the incidence of cartilage erosions needed to be further investigated. This study was influential in establishing the NRC (1989) dietary copper requirements for horses.

The relationship between dietary copper intake and bone disease in growing horses has recently been reviewed (Cymbaluk and Smart 1993). Knight *et al.* (1990) and Hurtig *et al.* (1993) performed dose response trials specifically investigating abnormalities of bone and cartilage development. Both groups found that increases in dietary copper above the NRC (1989) requirements (10 mg Cu/kg DM) resulted in a lower incidence of developmental orthopaedic disease (DOD). The increased dietary copper levels did not abolish DOD, as

might be expected with a multifactorial disease. These studies resulted in recommendations to increase dietary copper intake. For instance Hurtig *et al.* (1993) suggests a diet containing 20 to 25 mg Cu/kg DM for all growing horses, and Lewis (1995) suggests 50 mg Cu/kg DM for creep feeds, and 25 mg Cu/kg DM for weanlings. These copper concentrations are considerably greater than can be supplied by pasture alone.

Despite the proposed beneficial effect of increased copper intake on bone and cartilage development, the relationship between dietary copper intake, copper status and bone and cartilage development in foals is still unclear. The work described here was part of a larger study investigating this relationship. The objective of this study was to assess the effect on foals of oral copper supplementation of their pregnant dams and, of oral copper supplementation of the foals from 21 to 150 days of age, in terms of changes in copper concentration of plasma, soft tissue and bone, and caeruloplasmin activity.

5.3 Materials and methods

5.3.1 Animals

Mares

Pregnant Thoroughbred mares (n = 24, 4 to 20 years of age) were purchased, and grazed on tall fescue pasture from May 1994 for the duration of the experiment at AgResearch's Flock House Research Centre near Bulls on the North Island of New Zealand. The mares were randomly allocated to either a control or copper supplemented group, matched for mare age, date of last service and the sire of the pregnancy. Copper supplementation began in June when the mares were 13 to 25 weeks prior to foaling.

Foals

Nine foals from the control mares and 12 foals from the copper supplemented mares were then randomly divided again, into control and copper supplemented groups. Three of the 24 foals died in the perinatal period. Copper supplementation of the foals began 21 days postpartum. Foals were weighed weekly until January 1995 (foals aged 2 to 5 months), and thereafter were weighed fortnightly.

5.3.2 Diet

Pasture

The mares were grazed tall fescue pasture, and when pasture availability was inadequate to meet requirements (from May to July), they received supplementary tall fescue hay produced from the same property. Hay constituted less than 25 % of the total daily dry matter intake of the mares during peak hay consumption.

Copper supplementation

The mares and foals were supplemented orally, three times a week, with an aqueous solution of copper sulphate administered using a feeding syringe or a drench gun. The control groups received a placebo consisting of an equivalent amount of water and the basic mineral supplement of zinc and selenium. Supplementation of the mares ceased at term. The mares were dosed at a rate of 0.5 mg Cu/kg LW/day (equivalent to approximately 30 mg Cu/kg DM of the diet). At 21 days the foals were dosed at 0.2 mg Cu/kg LW/day which was increased to 0.5 mg Cu/kg LW/day by 49 days. The foals were then dosed at that rate until euthanasia. Dosages were adjusted weekly according to liveweight gain. Both the placebo and the copper sulphate supplement contained the equivalent of 0.02 mg/kg LW/day Se and 0.5 mg/kg LW/day Zn to ensure that these trace elements remained above NRC (1989) recommended levels throughout the trial.

5.3.3 Samples

Pasture and hay

Pasture was collected at 10 to 14 day intervals and bulked to give monthly samples. Subsamples of hay fed over winter were also collected. Samples were stored at -20°C prior to mineral determination.

Blood

Jugular venous blood from the foals was collected into trace element, sodium heparin vacutainers (Becton Dickinson, #367735), on days 0, 3, 7, 14, 21 and 28 postpartum, for determination of plasma and blood cell copper concentrations and plasma caeruloplasmin activity. The animals were then placed in similar aged cohorts and sampled at approximately 60, 90 and 150 days. The vacutainers were placed on ice for transport to the laboratory, and then the plasma and blood cells were separated by centrifugation, and stored

at -20°C until analysis. Plasma samples for determination of caeruloplasmin activity were stored at 4°C and analyses were performed within 2 to 3 days from sampling. Plasma copper concentration and caeruloplasmin activity were used in preference to serum because of the possibility of caeruloplasmin bound copper being incorporated into the blood clot resulting in erroneously low values (Paynter 1982).

Milk

Milk samples (20 to 50 ml) were collected at the same time periods as the blood samples, by manual expression, after excluding the foal for a short period.

Soft tissues

The foals were euthanased at 146 to 161 days (20 foals) while one foal was euthanased earlier (112 days) as a result of a traumatic injury sustained in the paddock. Following sedation with xylazine, the foals were euthanased with a lethal injection of barbiturate and placed on a postmortem table. The brachial vessels were opened and the blood collected. The internal organs were excised, weighed and subsampled. The gastrointestinal tract was removed, emptied of ingesta, and tissue subsamples were taken from the stomach, small intestine and large intestine and homogenised. The carcass was skinned and the integument (not including the hooves) subsampled. A muscle subsample was taken from the *m. semitendinosus*, *m. semimembranosus* and *m. biceps femoris*.

Bones

The atlas was dissected and defleshed, and a 15 mm wide by 80 mm long section was cut, in a frontal plane, through the wing of the ilium, midway between the tuber coxae and the tuber sacrale.

5.3.4 Analytical

All glassware used was acid washed, and all care was taken to prevent contamination from external sources.

Pasture and hay

Samples were dried in an oven at 60°C for 16 h, and then ground until the sample could pass through a 1 mm sieve. The pasture was weighed out accurately (0.5 g) and wet digested. Five ml of concentrated HNO₃ was added to the sample and left overnight. The mixture was then refluxed at 120°C for 1 hour, heated at 200°C for 3 to 4 hours to evaporate the acid, and the residue was reconstituted in 10 ml of 2M HCl and the copper concentration determined using inductively coupled plasma emission spectrometry (ICP) (Lee 1983).

Plasma copper concentration

Analyses were performed by ICP, as presented in Chapter 4.

Blood cell copper concentration

The blood cells were separated by centrifugation, washed twice with isotonic saline and then after centrifugation at 2000 rpm for 10 minutes, approximately 1 g of the blood cells was weighed out accurately and wet digested as for the pasture samples, and the copper concentration determined using ICP. The concentration was expressed as mg Cu/kg blood cells wet weight.

Caeruloplasmin activity

Plasma caeruloplasmin oxidase activity was measured using a colorimetric method (Ravin 1961). Caeruloplasmin catalyses the oxidation of P-phenylenediamine-dihydrochloride (PPD), a white crystal (Holmberg and Laurell 1951). A spectrophotometer was used to measure the optical density after incubation of PPD with caeruloplasmin at a pH of 5.4 to 5.5 and a temperature of 37°C. The results are expressed as absorbance units at 530 nm (37°C) per litre of plasma.

Milk

Three ml of concentrated HNO₃ and 1.5 ml 30 % H₂O₂ were added to 3 ml of milk, from a thoroughly mixed whole milk sample, in a 25 ml conical flask. Wet digestion was performed, evaporating the acid and H₂O₂. The digest was made up to 5 ml with 2 M HCl and the mineral element concentration was determined by ICP.

Soft tissue

A sample of fresh tissue (approximately 1.0 g) was weighed accurately into a 50 ml conical flask and desiccated in a dry matter oven at 100°C for 16 hours, and the dry matter determined. Concentrated HNO₃ (10 ml) was added and left overnight. The sample was refluxed for 4 to 5 hours and the acid evaporated. The sample was made up to 10 ml with 2M HCl and the concentration of mineral elements determined using the ICP.

Bone

Subsamples of bone (100 to 250g), dried at 60°C for 24 h, were ashed at 480°C for 16 h to determine dry matter and ash content. The ashed bone was then ground to a fine powder and a 0.2 g sample was dissolved in 10 ml of 1.6 M HNO₃. The copper was determined using Zeeman flameless atomic absorption spectrometer by the method of additions. Standards were made up in a synthetic bone solution prepared from calcium phosphate.

5.3.5 Statistical analysis

The plasma copper concentration, blood cell copper concentration, caeruloplasmin activity and milk copper concentration were analysed by analysis of variance (ANOVA) with repeated measures over time, according to mare treatment up until 21 days postpartum and then (except milk copper concentration data), as four groups according to foal and mare treatment. Soft tissue and bone data were analysed by ANOVA according to treatments. The bone copper concentrations were log transformed prior to analysis to standardise the variance.

The regression relationship between plasma copper parameters and time were generated for each foal over the 5 samplings from day 0 to 21. A separate pooled regression was established for the foals from control mares and copper-supplemented mares and compared. The relationship between caeruloplasmin activity and plasma copper concentration was determined for the whole time period and for the periods from day 0 to 21 and day 28 to 150.

The standard model used included sex of the foal, foaling date, post-conceptual age and age at euthanasia (postmortem samples), as covariates. Analyses were performed with Statistical Analysis System (SAS) version 6.11 (SAS Institute Inc. Cary, N.C., USA) using proc glm for ANOVAs, and proc mixed for ANOVAs with repeated measures over time.

5.4 Results

5.4.1 Animals

The mares remained healthy throughout the experiment and were maintained at a condition score above 5 on a 1 to 9 scale (Henneke *et al.* 1983). Likewise, all foals remained healthy throughout the trial, except for one foal that developed complications following a biopsy of the distal radial growth plate, but continued to grow well, and at euthanasia at 142 days it weighed 200 kg with an average growth rate of 1.09 kg/day. Another foal developed an acute non-weight bearing left hind limb lameness of traumatic origin, and was euthanased prematurely at 112 days. Its growth rate to that stage was 1.39 kg/day. The remainder of the foals grew well and at euthanasia their growth rates from birth ranged from 0.99 to 1.22 kg/day. There was no effect of either mare or foal copper supplementation on growth rate.

5.4.2 Pasture mineral composition

The tall fescue copper concentrations ranged from 4.4 to 8.6 mg Cu/kg DM. The concentrations of the pasture minerals, and mineral analysis of the hay which supplemented the pasture diet of the mares from May to July 1994 are presented in Table 5.1.

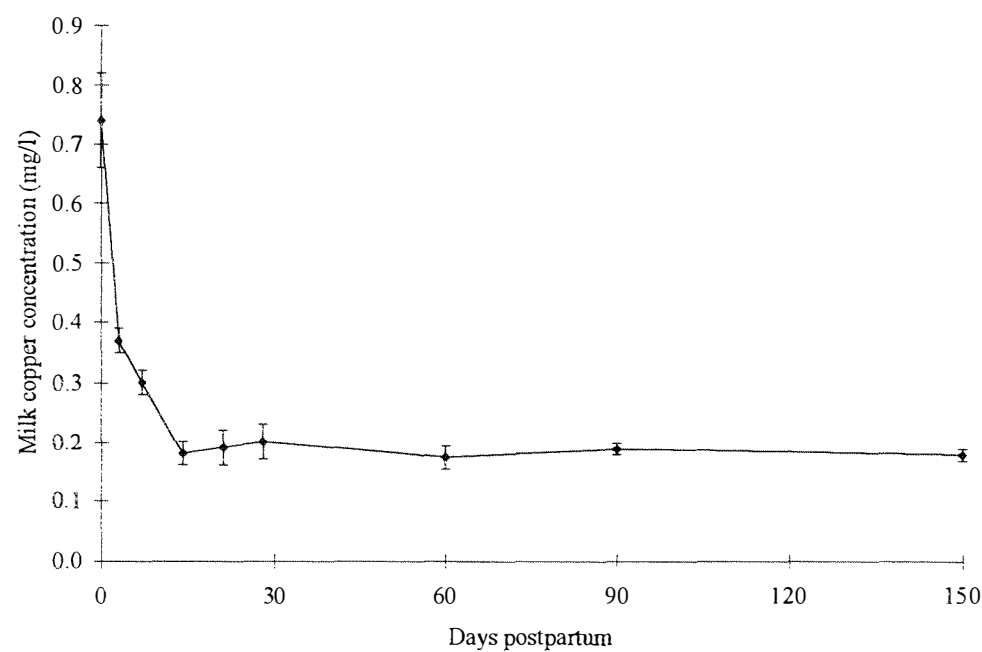
Table 5.1 Mineral composition of tall fescue pasture from May 1994 to March 1995 and tall fescue hay fed to the mares to supplement the pasture diet from May to July 1994.

	Na	K	Ca	P	Mg	S	Cu	Fe	Zn	Mn	Mo
	g/kg DM						mg/kg DM				
May	1.9	29	2.9	3.6	1.7	2.8	5.6	110	21	55	1.0
June	1.7	47	3.1	4.3	1.6	4.4	8.6	74	25	40	2.8
July	1.2	44	3.2	3.4	1.5	4.4	6.5	83	29	37	1.5
Aug	1.5	46	2.8	3.1	1.5	3.6	7.9	95	20	53	0.7
Sept	1.7	69	2.8	3.6	1.5	4.4	7.7	69	25	53	1.5
Oct	1.7	28	3.8	2.7	1.2	3.4	5.5	48	20	56	1.2
Nov	1.3	35	2.5	2.6	1.5	4.0	6.1	106	20	50	1.1
Dec	1.8	34	2.8	2.8	1.3	2.8	8.1	132	20	57	0.9
Jan	1.4	30	2.7	2.3	1.3	3.2	4.5	106	19	40	1.5
Feb	0.7	31	3.1	2.4	2.2	3.1	4.4	290	19	68	0.9
Mar	1.2	33	3.6	2.8	2.1	3.2	4.8	340	22	95	1.3
Hay	1.5	30	4.8	3.9	2.4	3.1	10.9	239	33	66	1.7

5.4.3 Mare milk copper concentration

The mare’s milk copper concentration was highest on the first day postpartum, ranging from 0.32 to 1.7 mg Cu/l milk. The milk copper concentrations decreased, plateauing after the 14 day sample at approximately 0.2 mg Cu/l (Figure 5.1). There was a significant effect of time on copper concentration but there was no effect of prepartum mare copper supplementation on the milk copper concentration.

Figure 5.1 Mean milk copper concentration (mg/l, +/- SEM) of all lactating mares from birth to 150 days (n = 21).



5.4.4 Foal plasma copper concentration, caeruloplasmin activity and blood cell copper concentration

There was no effect of copper supplementation of the prepartum mare on foal plasma copper concentration and caeruloplasmin activity, nor was there an effect of copper supplementation of the foal on these plasma indices from days 28 to 150.

The foal plasma copper concentration was initially low compared to adult values, ranging from 0.15 to 0.29 mg Cu/l, and increased over the first 21 days and plateaued at a level of 1.0 to 1.4 mg Cu/l (Figure 5.2). Plasma caeruloplasmin activity was also low on the first day after birth (4 to 11 U/l) and increased, reaching a plateau at 21 to 28 days. There was considerable individual and sample variation in the caeruloplasmin activity with values ranging from 36 to 108 U/l in the period from 28 to 150 days (Figure 5.3). From day 0 to 21, there was a significant effect of time ($p < 0.001$) on both plasma copper concentration and caeruloplasmin activity. Analysis of regression equations for individual foals for both plasma copper concentration and caeruloplasmin activity from day 0 to 21 found no significant difference due to mare copper supplementation on the rate of increase of these indices over this period.

Figure 5.2 Mean plasma copper concentration (■, mg/l, +/-SEM) and blood cell copper concentration (◆, mg/kg fresh weight, +/-SEM) of all foals (n= 21) from birth to 150 days.

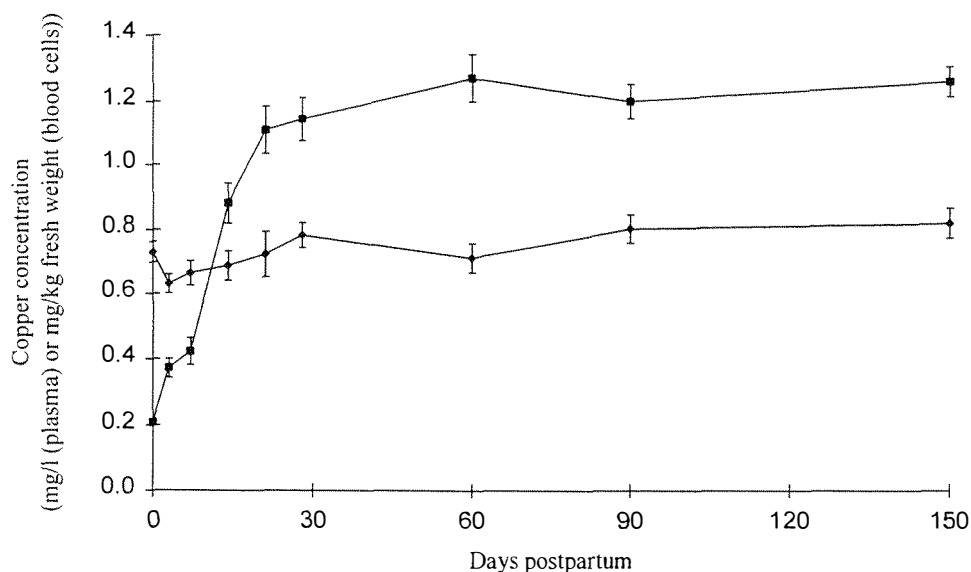
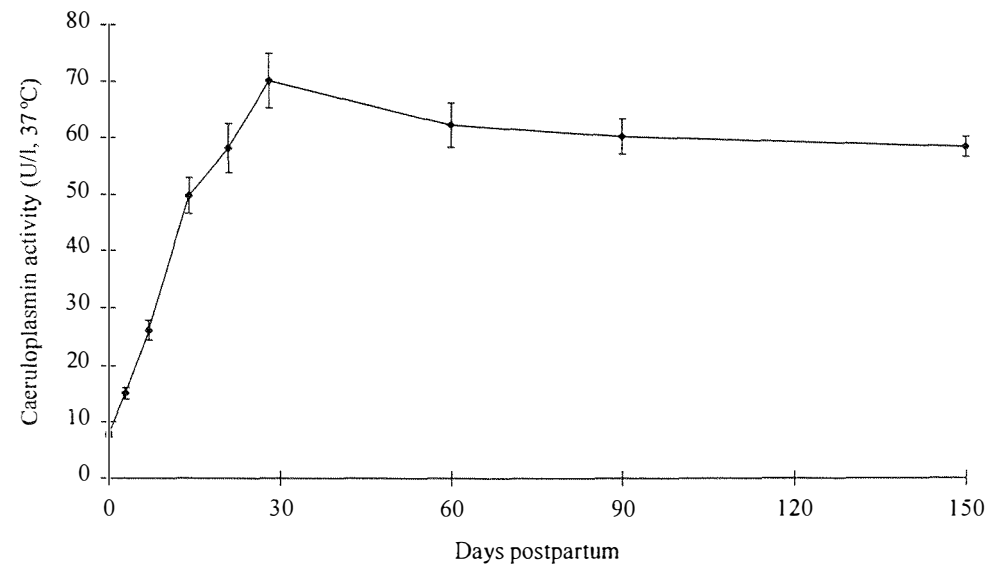


Figure 5.3 Mean plasma caeruloplasmin activity (U/l, 37°C, +/- SEM) of all foals (n = 21) from birth to 150 days.



Overall there was a significant relationship between plasma copper concentration and caeruloplasmin activity ($p < 0.001$, $r^2 = 0.69$). From 0 to 21 days, plasma copper concentration and caeruloplasmin activity were highly correlated ($r^2 = 0.73$) (Figure 5.4a), whereas in the period from day 28 these two indices were less well correlated ($r^2 = 0.23$) (Figure 5.4b).

The mean foal blood cell copper concentration ranged from 0.63 to 0.82 mg Cu/l (Figure 5.2), and there was no effect of time or of copper supplementation of either mare or foal on blood cell copper concentration in either time period (0 to 21 or 28 to 150 days).

Figure 5.4a Relationship between plasma copper concentration and caeruloplasmin activity of all foals (n = 21) from:
a) birth to 21 days, and
b) 28 to 150 days.

Figure 5.4a.

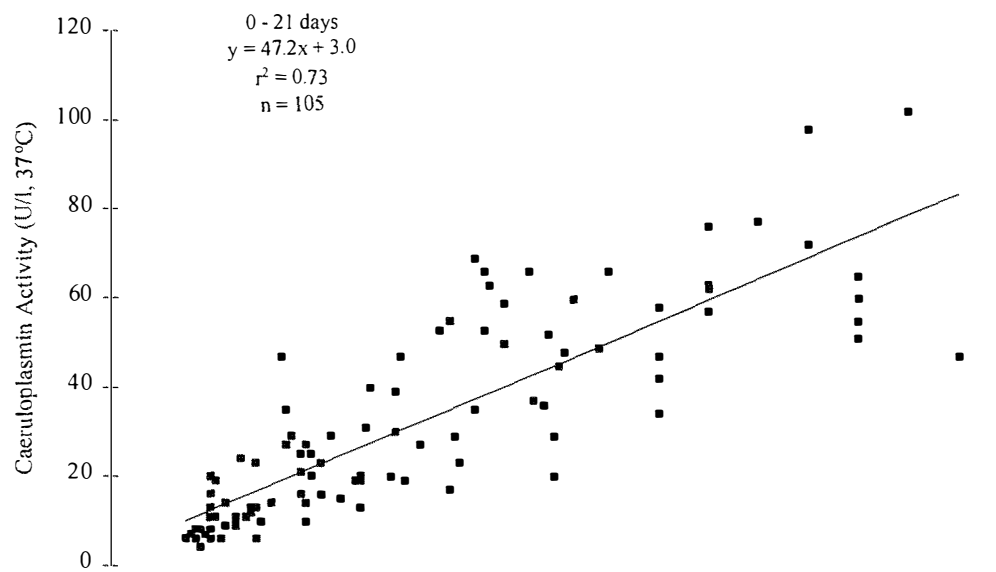
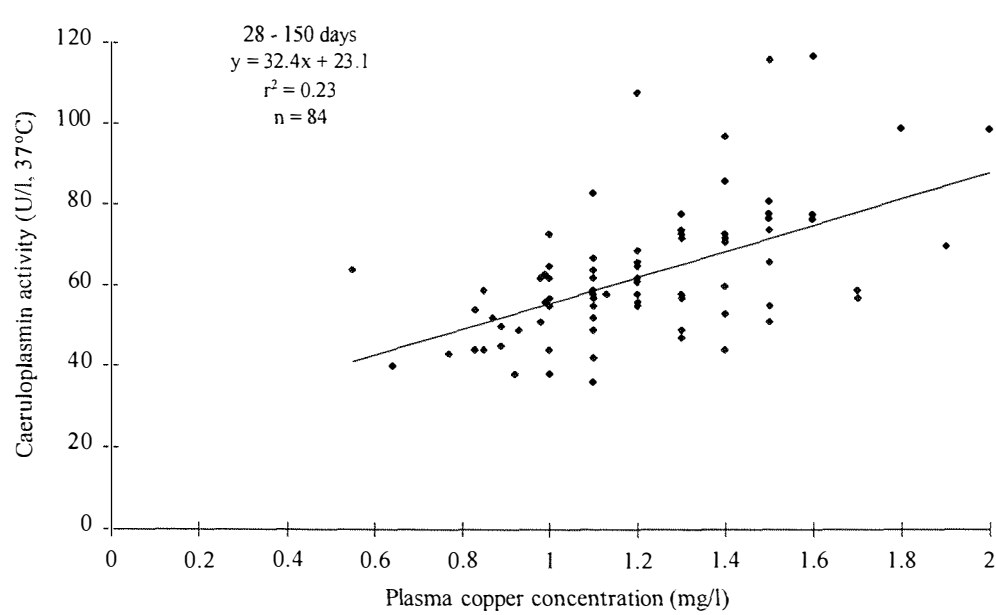


Figure 5.4b.



5.4.5 Foal soft tissue copper concentration

The mean organ copper concentrations for the 4 treatment groups, at 5 months of age are presented in Table 5.2. Mare supplementation, foal supplementation and the interaction of the two treatments had no effect on any organ except liver. Foal treatment had a significant effect ($p < 0.03$) on liver copper concentration. The liver copper concentration at 5 months (mean \pm SEM) was 25.1 \pm 2.4 and 68.8 \pm 15.3 mg Cu/kg DM for control and copper supplemented foals respectively.

Table 5.2 Effect of copper supplementation of the mare prepartum, and the foal from 21 to 150 days on the mean (\pm standard error of the difference (SED)) copper concentration (mg Cu/kg DM) of foal organs at 150 days.

<u>Organ</u>	Mare	treatment	Foal treatment		SED	Effect of copper	
	(MT)		(FT)			supplementation ¹	
	control	+ Cu	control	+ Cu		MT	FT
	mg Cu/kg DM						
Brain	9.3	9.7	9.2	9.8	0.8	NS	0.079
Gut	7.8	7.1	7.2	7.7	1.2	NS	NS
Heart	17.2	18.1	17.6	17.8	1.2	NS	NS
Kidney	37.8	45.3	43.2	39.8	8.3	0.057	NS
Liver	45.8	48.1	25.1	68.8	39.2	NS	0.022
Lung	7.6	8.7	8.2	8.0	1.5	NS	NS
Muscle	7.4	7.1	7.2	7.3	2.1	NS	NS
Skin	1.4	1.4	1.3	1.5	0.4	NS	NS
Spleen	4.0	4.0	4.0	4.0	0.5	NS	NS

¹ NS, $P > 0.10$

5.4.6 Foal bone copper concentration

There was no effect of copper supplementation of the mare or foal on the percentage of ash, copper, iron, zinc, calcium or phosphorus concentration of the atlas and ilium. The mean (\pm SEM) bone copper concentration for the atlas and ilium were 0.63 \pm 0.024 mg Cu/kg DM and 1.00 \pm 0.088 mg Cu/kg DM (Table 5.3).

Table 5.3 The mean (+/- SEM) ash, copper, zinc, iron, calcium and phosphorus concentration of the atlas and ilium from all foals (n = 21) at 150 days of age.

	Ash	Cu	Zn	Fe	Ca	P
	g/100g DM		mg/kg DM			g/kg DM
Atlas	42 (0.4)	0.6 (0.02)	53 (2.6)	129 (7.7)	153 (7.2)	75 (3.2)
Ilium	35 (0.8)	1.0 (0.09)	37 (2.8)	115 (13.0)	89 (6.8)	45 (3.5)

5.5 Discussion

Increasing the foal's average daily copper intake 3 to 4 fold, by oral copper supplementation (8 vs 30 mg Cu/kg DM), increased the liver copper stores of the foal (measured at euthanasia at approximately 150 days). However there was no effect of mare or foal treatment on plasma copper concentration, blood cell copper concentration and plasma caeruloplasmin activity or copper concentration of bone and organs, other than the liver. The observed changes in plasma copper concentration and caeruloplasmin activity with time are consistent with the study of Bell *et al.* (1987), and rose more slowly than in sheep, which reach adult levels by 3 to 4 days postpartum (McCosker 1968).

Oral copper sulphate was chosen as the source of supplementary copper. An oral formulation was required because our primary interest was to determine the effect of an increase in dietary copper on copper status. Injectable copper formulations are available, and have been reported to alleviate apparent copper deficiency syndromes in horses (Egan and Murrin 1973a). However they can cause considerable local tissue reaction in some individuals (SG Pearce and EC Firth, unpublished data), and there has been one report of induced copper toxicity in a mature horse after injection with copper D-penicillamine (4 mg/kg) (Auer *et al.* 1989b). For these reasons, some authors do not recommend the use of copper injections in horses (Cymbaluk and Smart 1993).

An investigation on the bioavailability of cupric chloride, acetate, oxide, sulphate and carbonate, by measuring the hepatic copper uptake in sheep, showed that copper sulphate had the highest biological availability (Ledoux *et al.* 1995). In another experiment in cattle with experimentally-induced copper deficiency, the bioavailability of copper sulphate and copper lysine was similar and superior to copper oxide, as assessed by plasma copper concentration and caeruloplasmin activity (Kegley and Spears 1994). Recent work suggests that copper amino acid complexes may be absorbed via a different route or pathway than

inorganic copper (Du *et al.* 1996). There may also be species and breed differences in copper absorption and availability from different sources of supplemental copper.

Milk and plasma copper concentrations recorded in the present experiment were similar to those in mares fed diets with copper concentrations of 7 and 12 mg Cu/kg DM/day (Breedveld *et al.* 1988). However, the milk copper concentrations reported by Ullrey *et al.* (1974) are a little higher (0.99 mg/l at parturition, plateauing at 0.29 mg/l after 3 weeks), and those of Schryver *et al.* (1986) are considerably higher (0.85, 0.55 and plateauing at 0.29 mg/l at 1, 4 and 8 weeks respectively). All analyses were performed using atomic absorption spectrometry and we are unable to explain the differences in these results, but they may be due to unknown interactions in with other dietary constituents, and, although unlikely, differences in laboratory technique. There was no relationship between mare liver copper stores (determined in Chapter 4) and milk copper concentration, and there was no residual effect of copper supplementation of the prepartum mares on the milk copper concentration. Several other studies have also found that copper supplementation of mares does not alter their milk copper concentration (Breedveld *et al.* 1988, Baucus *et al.* 1989, Asai *et al.* 1995).

Dietary copper intake is thought to account for some of the variability in plasma and serum copper concentration in horses (Auer *et al.* 1988a; Stublely *et al.* 1983; Mee and McLaughlin 1995), but this was not evident in this study. In another study, horses fed diets containing either 7 or 30 mg Cu/kg DM did not exhibit detectable differences in serum copper concentration despite large increases in liver copper and fewer bone and cartilage lesions in the high copper intake group (Hurtig *et al.* 1990). In a further study, high levels of dietary copper (791 mg Cu/kg DM) fed for 6 months, did not affect whole blood or plasma copper concentration in ponies (Smith *et al.* 1975). In ruminants, if liver copper stores are adequate, increasing copper intakes will not usually alter blood copper concentration but will continue to increase copper accumulation in the liver (Woolliams *et al.* 1983). This appears also to be true with horses in this study.

Caeruloplasmin being acute phase protein (Gutteridge 1978), is sensitive to many factors other than dietary copper intake. It is increased by chronic infection and inflammation, and is decreased by malnutrition, nephrosis and chronic hepatitis. In humans, plasma copper concentration is higher in women than men, and higher in pregnant women and in individuals on oral contraceptives (Milne 1994; Solomons 1979). There is some evidence

that procedures that provoke an inflammatory response may affect circulating copper indices in horses. For example, Smith and Cipriano (1987) found that caeruloplasmin activity increased following intramuscular injection of ponies with turpentine oil, Firth *et al.* (1987) found an increase in serum copper following intra-articular lipopolysaccharide administration in ponies, and Auer *et al.* (1989a) found an increase in plasma copper concentration, caeruloplasmin concentration and caeruloplasmin activity following intramuscular injection of Freund's adjuvant into horses. In the present experiment, foals underwent laparoscopic liver biopsy and a biopsy of the distal radial growth plate in one surgical procedure performed 4 to 10 days after parturition. The surgical procedures performed on our foals might have been a sufficiently inflammatory stimulus to alter the pattern of change of plasma copper concentration and caeruloplasmin activity. However in a separate experiment, foals of the same age and under similar conditions, but without surgery, showed similar changes in copper concentration and caeruloplasmin activity over days 0 to 28 as presented here (SG Pearce and EC Firth, unpublished data).

Caeruloplasmin is also a transport enzyme (Gutteridge 1978) for plasma copper and accounts for approximately 70 % of circulating copper in horses (Auer *et al.* 1988b). Shortly after birth there is a very low concentration of caeruloplasmin due to an inability of the foetal liver to produce the active enzyme (Chang *et al.* 1975; Milne 1994). Thus at very low but increasing levels of caeruloplasmin activity soon after birth, it is expected that the caeruloplasmin and plasma copper concentration will be highly correlated. After 28 days, by which time the caeruloplasmin activity had reached adult levels and was probably no longer limiting plasma copper concentration, there was a poorer correlation. A similar situation has been demonstrated in rats, whereby supplementation of copper deficient rats with copper will increase caeruloplasmin activity, but in rats with adequate copper stores, copper supplementation does not alter caeruloplasmin activity (Linder *et al.* 1979).

Blood cell copper concentration was not affected by age of the foal nor by copper supplementation of the mare or foal. Intracellular copper concentration has been suggested to be a better indicator of copper status than plasma copper concentration as it is less labile, and therefore less responsive to non-dietary factors (Milne 1994).

There was no significant relationship between neonatal liver copper concentration (determined in Chapter 4) and liver copper concentration at euthanasia (150 days). However, copper supplementation of the foal significantly attenuated the decline in liver

copper concentration over the 150 days. There was a decline of approximately 92% and 82% of liver copper concentration, from birth (ie at 4 to 10 days of age), of control and copper supplemented foals respectively. Therefore at euthanasia, the liver copper concentration from copper supplemented foals was nearly 3 fold higher than control foals. This suggests that liver copper concentration equilibrates to levels that reflect the dietary copper intake in sucking foals. Liver copper concentration has been shown to not reflect copper availability in situations of zinc-induced hypocuprosis (Bridges and Moffitt 1990), and therefore other information regarding the diet and other indices of copper status must be taken into account along with liver copper concentration when assessing an animal's copper status (Cymbaluk and Smart 1993).

Copper supplementation of the mare, foal, or both mare and foal had no significant effect on the copper concentration in any organ except the liver. However in other studies, brain copper concentration has been reported to be sensitive to marginal copper deficiency in rats (Hopkins and Failla 1995), and kidney copper concentration has been reported to vary with different diets in yearling horses (Cymbaluk and Christensen 1986). There was some evidence of such effects in this study with a trend toward increased brain copper concentration in supplemented foals ($p < 0.08$), and increased kidney copper concentration in foals born to copper supplemented mares ($p < 0.06$).

Two predominantly cancellous bones (ilium and atlas) were chosen to examine the effect of copper supplementation on bone percent ash content and mineral concentration. In sheep, increased copper intake (8 vs 17 mg Cu/day) of pasture fed sheep resulted in a significant increase in calcium and phosphorus content of the skeleton (Grace and Lee 1988). Another study found an increase in bone ash copper concentration in sheep receiving copper supplementation (Hogan *et al.* 1971). In cattle, copper supplementation did not increase bone copper concentration, but copper depletion significantly reduced the organic matter content of bones (Suttle and Angus 1978). Copper-depleted rats had increased bone zinc concentration and decreased iron concentration (Tsai and Lei 1979). In the present study, there was no effect of copper supplementation of the mare or foal on bone mineral concentration or bone ash content. This might be due to the copper intake levels of the animals in this trial not being extreme enough to detect a difference, although the difficulties of accurate analysis may also be important. For example, a sample from the ilium was relatively easy to collect from a fixed, standard site, and the whole the atlas was taken, both of which minimised any bias due to variations in the sampling site. However the

determination of bone copper concentration was difficult as there was only a small amount of copper in the presence of large amounts of calcium and phosphorus. The variation between animals in the bone copper concentrations was also substantial. These factors would seem to mitigate against the use of bone copper concentrations as useful indices of copper status.

Oral copper supplementation of mares in late gestation and nursing foals altered the copper balance in these horses, resulting in an increase in the foal's liver copper stores at birth and at 5 months of age respectively. The liver copper concentration of weanling foals appears to be a good indicator of their dietary copper intake. Increased liver copper stores of the neonate may be important for ensuring healthy development of the skeleton during the period of maximum post-natal growth.

Chapter 6

The Effect of Copper Supplementation on the Evidence of Developmental Orthopaedic Disease in Pasture-Fed Thoroughbreds⁵

⁵ Submitted as: SG Pearce, EC Firth, ND Grace and PF Fennessy (1997) *Equine Veterinary Journal*.

6.1 Abstract

The effect of copper status on the evidence of bone and cartilage lesions was investigated in 21 Thoroughbred foals. The foals, and their dams, were grazed on pasture containing 4.4 to 8.6 mg Cu/kg dry matter (DM). Four treatment groups were created by randomly allocating mares and their foals to either copper supplemented (0.5 mg Cu/kg liveweight (LW)/day), or control (pasture only) groups. This experimental design allowed the effect of copper supplementation of mare and foal to be examined independently. Parameters of bone and cartilage development were assessed in the foals both *in vivo*, and at postmortem at approximately 150 days of age. Mare copper supplementation significantly ($p < 0.01$) decreased radiographic indices of physitis in the distal third metatarsal bone of the foals at 150 days, and the prevalence of articular cartilage lesions ($p < 0.05$). Articular cartilage lesions were minor in all foals, with no evidence of clinical developmental orthopaedic disease (DOD) *in vivo*, with the exception of minor radiographic changes assessed at postmortem. Copper supplementation of the foal had no effect on any of the bone and cartilage parameters. Copper supplementation of the mares did not abolish DOD in the growing foals, emphasising the likely multifactorial nature of this condition. However, mare supplementation may be a useful treatment regime on a farm where the incidence and severity of DOD are of concern.

6.2 Introduction

Developmental orthopaedic disease (DOD) is a term used for a group of diseases in growing foals that are caused by abnormalities in the development and maturation of cartilage and bone. This group includes: osteochondrosis, subchondral bone cysts, physitis, acquired angular limb deformities, flexural limb deformities and cuboidal bone malformation (Beeman and McIlwraith 1986). Cervical vertebral malformation and juvenile arthritis have also been proposed to be included in this group because of their putative relationship with osteochondrosis (Reed *et al.* 1987; Watrous *et al.* 1991). The aetiology for these diseases is likely to be multifactorial, and one particular aetiology may only be associated with a subset of the group of diseases (Palmer 1993; Pool 1993; Hurtig and Pool 1996).

DOD is considered to contribute to major economic wastage in the horse industries worldwide. In New Zealand, a relationship between copper status and DOD was recognised clinically over 20 years ago, when exostoses above and below the fetlock responded to

copper supplementation (Carberry 1978). Other similar clinical observations of copper responsive DOD have been reported in America (Hildebran and Hunt 1986) and Ireland (Egan and Murrin 1973a). Similarly, in New Zealand, deer grazing copper-deficient pasture developed lameness, angular limb deformities and swollen joints (Thompson *et al.* 1994). Lesions described were similar to those found in copper-deficient foals (Bridges and Harris 1988).

Bridges and Harris (1988) fed diets containing very low concentrations of copper (1 to 2 mg Cu/kg DM) to foals and found that the outstanding manifestations of copper deficiency were abnormalities of bone and cartilage development. All foals became lame, and developed flexural limb deformities. At postmortem, there was a generalised distribution of articular and physeal cartilage lesions. Lesions consisted of intracartilaginous fractures, areas of focal chondrocyte retention and chondrocyte necrosis. The suggested underlying mechanism was a decrease in the activity of the copper metalloenzyme lysyl oxidase, which catalyses the formation of inter-molecular bonds of collagen fibrils. This was supported by the greatly increased collagen solubility of a sample of the aorta and selected articular cartilages compared with control foals. Similar pathological changes have been found in foals after long term dexamethasone administration (Glade *et al.* 1983), zinc toxicosis (Gunson *et al.* 1982; Eamens *et al.* 1984) and in early cases of osteochondritis dissecans of unknown cause (Bridges *et al.* 1984).

Studies performed on farms in America (Knight *et al.* 1985; Gabel *et al.* 1987) and Japan (Fujikawa *et al.* 1993; Asai *et al.* 1993) have found an inverse relationship between dietary copper concentration and the prevalence of DOD. Two North American dose-response trials examining the effect of increased dietary copper intakes on bone and cartilage abnormalities (Knight *et al.* 1990; Hurtig *et al.* 1993) found that the incidence of DOD lesions was decreased by increasing the copper content of the diet above NRC (1989) recommendations. Dietary copper intake at NRC (1989) recommendations (10 mg Cu/kg DM) is considered to be associated with mild copper deficiency resulting in an increase in tissue fragility (Hurtig and Pool 1996), predisposing subchondral bone and the hypertrophic chondrocyte zone to micro-fractures. As a result, dietary levels of 50 mg Cu/kg dry matter (DM) for creep feeds and 30 mg Cu/kg DM for weanlings have now been recommended (Lewis 1995).

The New Zealand horse industry is essentially pasture-based, in that pasture constitutes the major part of the diet of mares and foals. New Zealand pastures contain a dietary copper

concentration ranging from 3.5 to 18 mg Cu/kg DM (Grace 1994), and therefore, a shortfall in copper intake might be expected in foals raised under this management system. This paper describes the effect of increased copper intake on the evidence of developmental orthopaedic diseases of pasture-fed young Thoroughbreds.

6.3 Materials and methods

6.3.1 Animals and diet

Mixed sex Thoroughbred foals ($n = 21$) were used. For the 13 to 25 weeks prior to foaling, their dams had been treated, with either oral copper sulphate at a rate of 0.5 mg Cu/kg liveweight (LW)/day, or a placebo of equivalent fluid volume. The foals at 21 days of age were randomly allocated to either a copper-control or supplemented group, taking into account sex, sire foaling date and mare treatment. The supplemented foals received oral copper sulphate at a rate increasing from 0.2 to 0.5 mg Cu/kg LW/day from 21 to 49 days of age, and then 0.5 mg Cu/kg LW/day from 49 days of age until euthanasia at approximately 150 days of age. Control foals received a placebo. All animals received supplementary zinc (0.5 mg Zn/kg LW/day) and selenium (0.02 mg Se/kg LW/day). Details of the mineral content of the pasture diet, and of the mares' milk are presented in Chapter 5. Laparoscopically-guided liver biopsy and unilateral distal radial growth plate biopsy, described in Chapters 2 and 3, were conducted at 4 to 10 days of age.

6.3.2 Clinical examination

Foals were weighed and examined at one or two week intervals throughout the experiment. All limbs were scored for the presence of joint effusion and angularities as viewed from lateral and frontal aspects. All parameters were scored on a scale from 0 to 3, where 0 was normal and 1, 2 and 3 indicated the presence of mild, moderate and severe abnormalities. Phytitis was not scored clinically, but was assessed on radiographic examination of postmortem samples.

6.3.3 Radiographic examination

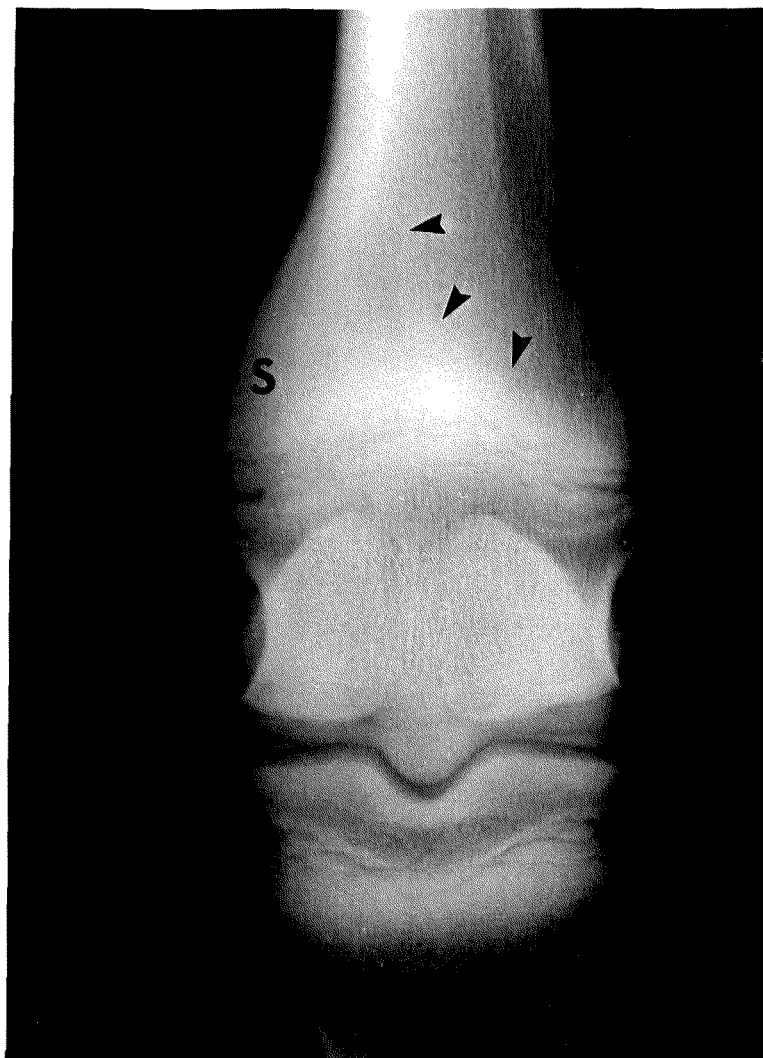
Survey radiographs of all foals were performed from 4 to 10 days of age, under general anaesthesia, and on the legs of foals following euthanasia at 150 days. Views included

dorso-palmar/plantar (dp) and lateral views of the metacarpo/tarso-phalangeal joints and carpi, and dorso-plantar and dorso-lateral plantero-medial oblique views of the tarsi and dorso-medial plantero-lateral oblique views of the stifles.

All radiographs were examined for abnormalities by two investigators. The postmortem dp radiograph of the metatarso-phalangeal joint of both hind legs, taken at 5 months, was also scored by four observers for morphological abnormalities consistent with phytitis of the distal metatarsal bone. The scores were summed to give a “phytitis” score for each hind leg.

The radiographs were scored in random (shuffled) order with the observer blinded to treatment groups. Radiographs were scored for the following categories: presence of beaking, physeal flaring, sclerosis medially or laterally, metaphyseal shouldering medially or laterally, epiphyseal scalloping medially or laterally, and epiphyseal wedging (Figure 6.1).

Figure 6.1 Radiograph of distal third metatarsal bone showing metaphyseal shouldering (S), metaphyseal sclerosis (arrow heads), and widening of the physis.



Beaking and physeal flaring were scored as 1 or 0, if present or absent respectively, regardless of whether medial or lateral or both. A beak was defined as a concavity in the contour of both the metaphysis and epiphysis adjacent to the physis, such that the physis appeared to protrude outward. Small beaks that could be clearly viewed only with a hot light were scored as 0. Physeal flaring was defined as a local widening of the physis at the medial or lateral extremities, that was inconsistent with the width of the rest of the physis.

Metaphyseal sclerosis, shouldering and epiphyseal scalloping were scored from 0 to 3, scores of 1, 2 and 3 representing mild, moderate and severe abnormalities respectively. Medial and lateral aspects were scored independently. Sclerosis was defined as an increase in metaphyseal radio-density proximal to the physis. Metaphyseal shouldering was defined as an abnormality of the normal contour of the metaphyseal cortex, resulting in a convex metaphyseal “shoulder” proximal to the physis. Epiphyseal scalloping was defined as an increase in the concavity of the medial or lateral contour of the epiphysis.

Epiphyseal wedging was scored from 0 to 3, a single score covering both medial and lateral aspects. Wedging was defined as being present when a line joining medial and lateral margins of the physis was not parallel to the joint surface.

6.3.4 Postmortem

Twenty of the foals were euthanased at 146 to 161 days and one at 112 days following a traumatic injury sustained in the paddock. Foals were sedated with 250 mg xylazine and euthanased with intravenous barbiturate. The legs and cervical spine were removed, defleshed and disarticulated.

6.3.5 Bone physical properties

The left and right humerus, femur, radius, tibia, third metacarpal and third metatarsal bone were weighed, and their length, and mid-shaft circumference measured. The volume of the bones was measured using a water-displacement technique, and the density calculated. The bones were subsampled and ash content determined as described in Chapter 5.

6.3.6 Gross pathology

All cervical vertebral and limb joint surfaces were examined, after disarticulation, for the presence of lesions. Lesions were counted but not scored for severity.

After examination of the articular surfaces, the ends of the long bones were sawn into slabs about 6 mm thick for examination of the articular-epiphyseal complex and the physeal cartilage. The proximal humerus, distal femur and proximal radius were slabbed in sagittal section. The distal tibia and talus were slabbed in the plane of the intermediate ridge and the talar ridges respectively. The distal radius and 3rd metacarpal/metatarsal bone were slabbed frontally. Lesions were characterised, described, and their location given by slab number (counting from medial or dorsal), bone-end, foal and leg. All bone slabs containing lesions were radiographed and formalin fixed.

6.3.7 Histopathology

Slabs submitted for histology were decalcified in formic acid/formate, followed by vacuum embedding in paraffin wax. Sections (6 µm thick) were prepared and stained with alcian blue, haematoxylin and eosin, and selected sections were stained with Lendrum's acid Picric Mallory.

Categorisation of lesions

Lesions were categorised as occurring in either articular or physeal cartilage. Articular cartilage lesions were divided into three categories: invaginated cartilage (Figure 6.2), thickened cartilage (Figure 6.3), and lesions on the medial trochlear ridge of the talus. Articular cartilage wear lines were categorised separately. Physeal cartilage lesions were categorised as either retained cartilage (Figure 6.4), or interruptions to the physis.

Histomorphology

The left and right distal radii from 7 supplemented foals and 6 control foals (5 of the foals were from control mares and 8 from supplemented mares) were examined histomorphologically. A standard frontal cross-section of the distal radius was located by measuring the midpoint between dorsal and palmar aspects of the lateral styloid process, and extending a line from lateral to medial, parallel to the palmar surface of the interprocess area (Firth and Hartman 1983). Histological sections were prepared, and a line was drawn

from the medial to lateral border of the physis. Beginning medially, a series of parallel perpendicular intersections of this line 5 mm apart, defined histomorphological measurement sites along the physis. The slides were projected at a known magnification, and at each measurement site, the width of the total physis and the combined hypertrophic and proliferative cell layer were measured. Also at each measurement site, 1 mm proximal to the physis, the metaphyseal trabecular area in a 1 mm by 1 mm square was determined by tracing the trabeculae of the projected image. The tracings were then digitised (sigma scanner), and the percentage trabecular area for each site determined.

6.3.8 Statistical analysis

All data were analysed for the effect of mare and foal treatment using analysis of variance (ANOVA) procedures. They included growth rate, weight at euthanasia, (adjusted to 150 days of age), radiographic distal radial “physitis” scores (the mean for the four observers), and articular and cartilage lesions by ranks of the scores. The scores were also analysed for inter-observer variation. The histomorphometric data were analysed as a repeated measures analysis according to site. Analyses were performed with Statistical Analysis System (SAS) version 6.11 (SAS Institute Inc. Cary, N.C., USA) using proc glm for ANOVAs, and proc mixed for repeated measures analyses.

6.4 Results

6.4.1 Growth rate

There was no effect of foal or mare copper supplementation on growth rates, birth weights or final weights (adjusted to 150 days), of the foals. The growth rates for the individual foals from birth to euthanasia ranged from 0.9 to 1.4 kg/day, with foal weights at euthanasia ranging from 184 to 234 kg liveweight. The mean growth rate (+/- standard error of means) for all foals was 1.1 +/- 0.03 kg/day.

6.4.2 Clinical examinations

All but one of the foals remained healthy, the one foal became lame following laparoscopic liver biopsy and biopsy of the distal radial growth plate performed under general anaesthesia on day 5. The foal appeared lethargic and was often recumbent. However this foal continued to grow well and was 200 kg when euthanased at 142 days (growth rate 1.4 kg/day). She had a mild flexural deformity of the right carpus that persisted throughout, and at euthanasia had evidence of degenerative joint disease of the right radio-carpal joint, severe physitis in both distal metatarsi and calcification of the suspensory ligament distal to the sesamoids. It was considered that the degenerative joint disease and other clinical signs were associated with complications following the growth plate biopsy. Inclusion of this foal did not alter the statistical significance of the parameters examined.

Conformational abnormalities caused by the biopsy of the distal radial growth plate, are described in Chapter 3. Fifteen (71 %) of the foals developed an outward rotation of the left (unoperated) forelimb and a mild valgus conformation of the left leg, centred at the carpus. There was no evidence of joint effusion in the foals, nor lameness in any of the foals excluding the one previously described. Conformation was not different in copper-supplemented foals compared with control foals.

6.4.3 Radiographs

Small cartilage retentions were evident on the survey radiographs in the lateral trochlear ridge of the distal femur in one foal, and in the distal physis of the 3rd metacarpal bone in another foal.

Copper supplementation of mares was associated with a significant reduction in the physitis scores ($p < 0.01$), assessed radiographically, of the foals at 150 days of age (Table 6.1). A relationship between the foal or mare liver copper concentration (from Chapter 4) and the radiographic scores was also investigated, but was not significant. There was no significant effect of copper supplementation of the foals on radiographic scores. There were no significant differences in radiographic scores between observers ($p > 0.05$).

Table 6.1 Mean physitis scores from radiographs of the distal metatarsus of all foals at 150 days of age (C = control, S = copper supplemented).

	<u>Mare Treatment</u>		<u>Foal Treatment</u>		SED	<u>F value</u>	
	C	S	C	S		Mare	Foal
Number of foals	9	12	10	11			
<u>Observer</u>							
1	6.7	4.8	5.8	5.7	2.0	9.4**	0
2	5.5	3.3	4.3	4.6	2.6	7.4**	0.2
3	6.6	4.4	5.5	5.6	2.6	7.2*	0
4	5.8	3.4	4.6	4.6	2.8	7.5**	0
mean	6.0	3.7	4.8	4.9	2.4	9.1***	0

* p < 0.05

** p < 0.01

*** p < 0.005

6.4.4 Bone physical properties

There was no effect of mare or foal copper supplementation on any of the bone physical parameters. Pooled mean values for the foal bone physical properties are presented in Table 6.2.

Table 6.2 Pooled mean values (+/- SEM, n = 21) for physical properties of the foal bones at 150 days of age.

Bone	Weight	Volume	Length	Circumference	Density	Ash
	(g)	(ml)	(mm)	(mm)	(g/ml)	(% fresh wt)
Humerus	1029 (33.0)	794 (17.0)	280 (1.8)	12.3 (0.13)	1.3 (0.03)	39.4 (0.99)
Radius	927 (17.8)	664 (14.3)	406 (2.8)	11.3 (0.12)	1.4 (0.02)	42.3 (0.71)
Metacarpus	391 (8.0)	243 (5.8)	268 (1.7)	10.0 (0.06)	1.6 (0.04)	40.4 (0.31)
Femur	1585 (32.2)	1226 (29.8)	364 (2.0)	14.3 (0.16)	1.3 (0.01)	38.2 (0.52)
Tibia	999 (16.7)	712 (15.7)	348 (1.9)	11.7 (0.12)	1.4 (0.02)	42.7 (0.54)
Metatarsus	499 (35.9)	308 (21.7)	313 (2.5)	10.5 (0.74)	1.6 (0.12)	40.2 (2.88)

6.4.5 Pathology

The prevalence and severity of lesions at postmortem was considered to be minor. There was a significantly lower ($p < 0.05$) incidence of articular cartilage lesions in foals from supplemented mares (Table 6.3). However there was no significant effect of copper supplementation of the foals on articular and physeal cartilage (Table 6.4) lesions or wear lines.

Table 6.3 Number of foal articular cartilage lesions by classification at 150 days of age according to mare and foal treatment (c = control, s = copper supplemented).

	Mare treatment/Foal treatment			
	c/c	c/s	s/c	s/s
Number of foals	4	5	6	6
<u>Lesion classification</u>				
Invaginated	6	6	2	4
Thickened	4	5	1	2
Talus	3	5	4	6
Mean (lesions/foal)	3.3	3.2	1.2	2.0
Mean (mare treatment)*	3.3		1.6	

* Values significantly different ($p < 0.05$).

Table 6.4 Number of foal physeal cartilage lesions at 150 days of age according to bone and mare and foal treatment (c = control, s = copper supplemented).

	Mare treatment/Foal treatment			
	c/c	c/s	s/c	s/s
Number of foals	4	5	6	6
<u>Location</u>				
Proximal humerus	1	0	1	2
Proximal radius	1	0	0	2
Distal radius	7	1	3	4
Distal metacarpus	2	0	0	2
Distal femur	1	0	3	0
Proximal tibia	0	0	0	1
Distal tibia	1	2	2	3
Distal metatarsus	4	5	2	2
mean (lesions/foal)	4.3	1.6	1.8	2.7

Table 6.5 Location of classified foal articular cartilage lesions at 150 days of age.

Location	<u>Lesion Classification</u>		<u>Symmetry</u>		Total	Site
	Invaginated	Thick	Unilateral	Bilateral		
Proximal humerus	1		1		1	middle articulating surface (head)
Distal humerus		1	1		1	lateral condyle
Proximal radius	8		4	2	8	medial/lateral articulating facet
3rd Carpal bone	2			1	2	junction articulation of radial and intermediate carpal bones
Distal metacarpus*		5	1	1	3	medial/lateral condyle
Front phalanges	4		2	1	4	median sagittal groove/dorsal eminence (P1)
Distal femur	1	3	3	0	3	medial condyle/lateral trochlear ridge
Distal metatarsus		3	1	1	3	median sagittal ridge
Hind phalanges	2		2		2	median sagittal groove/dorsal eminence (P1)
Talus†			8	5	18	medial trochlear ridge

* Multiple lesions at one site

† Talus lesion type classified separately

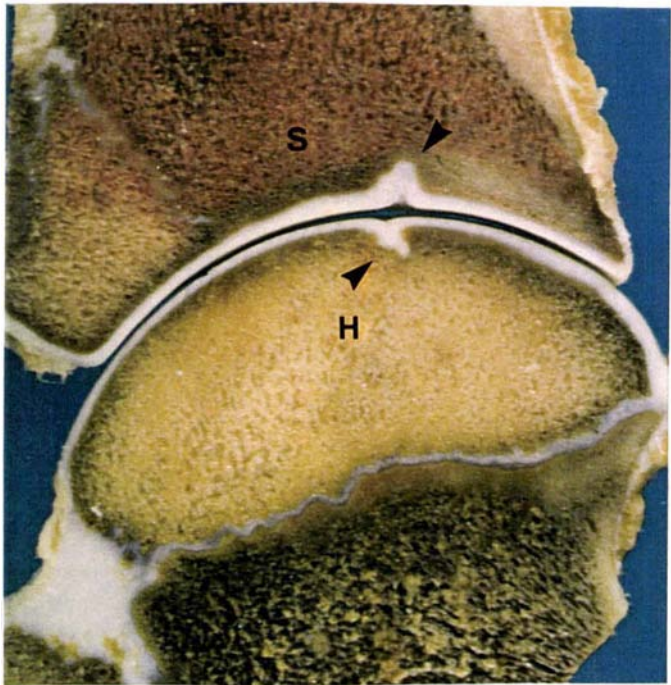
Articular cartilage

Invaginated cartilage lesions were found on the proximal humerus (Figure 6.2a), proximal radius, distal femur, front and hind proximal and middle phalanges and 3rd carpal bone (Table 6.5). Histologically, these lesions appeared as an inward folding or cleft of the articular cartilage into the subchondral bone, often with some retention of predominantly hypertrophic chondrocytes. There was usually disruption to the organisation of the tangential cell layer, which was occasionally missing altogether, and a decrease in matrix staining intensity. Chondrones, subchondral fibrosis and subchondral sclerosis surrounding these areas of fibrosis were commonly present. Occasionally there were areas of necrotic articular cartilage at the chondro-osseous junction and fibrocartilage adherent to the surface of the invaginated articular cartilage. In one lesion there a cleft in the subchondral trabeculae entered the region of hypertrophic chondrocytes in the invaginated cartilage (Figure 6.2b). The cleft was associated with necrotic chondrocytes and numerous chondrones, its contents stained positive for fibrin by Lendrum's acid Picric Mallory method, and was interpreted as being a mature micro-fracture.

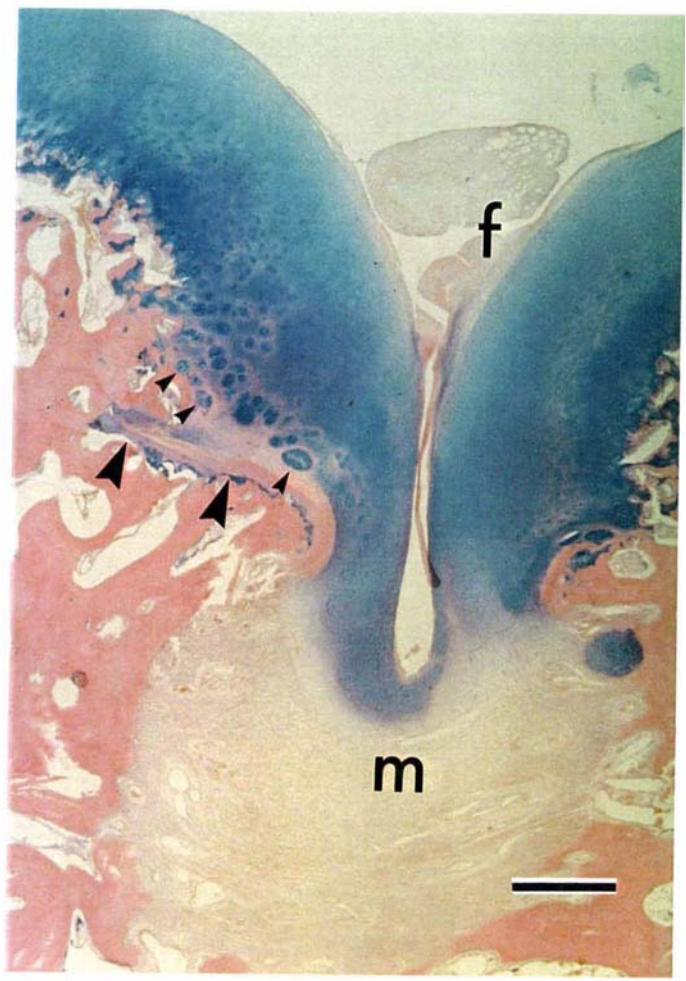
Figure 6.2 An invaginated type lesion showing:

- a) the gross appearance in the articular and epiphyseal cartilage (arrow heads) of the proximal humerus (h) and distal scapula (s), and
- b) the histological appearance of cartilage invagination in the proximal radius, showing fibrocartilage (f) adherent to the articular cartilage, chondrones (small arrow heads), subjacent myelofibrosis (m), and a mature subchondral microfracture (large arrow heads). Stain: Alcian blue, Haematoxylin and Eosin. Magnification bar: 500 μ m.

a



b)



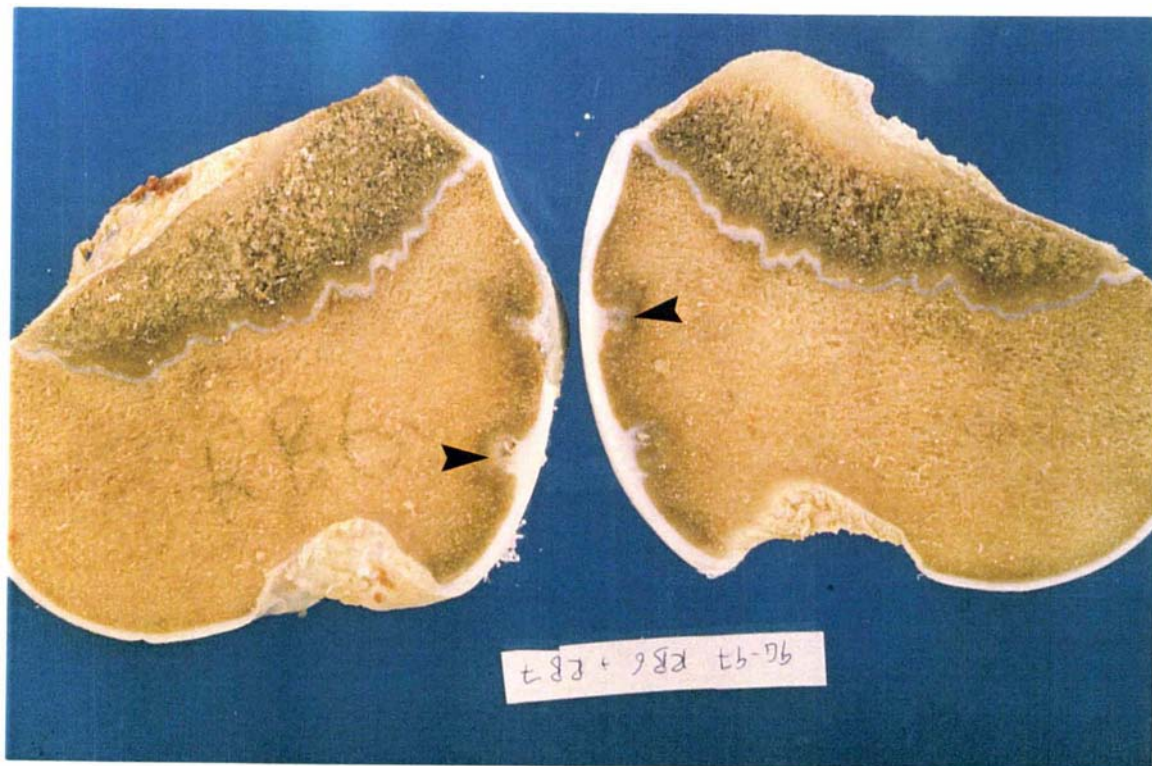
Thickened articular cartilage lesions were most clearly evident on examination of slabbed sections and on cabinet radiographs of slabs, and were found on the distal femur (Figure 6.3a), humerus, metacarpus (Figure 6.3b) and metatarsus. The histological appearance of these lesions was the same as for invaginated cartilage except that the cartilage was more obviously thickened, with most of the thickening in the hypertrophic cell layer. Also the degree of depression of the articular cartilage was usually mild. One such lesion had a fissure extending to the articular surface, which was evident on gross examination, and histologically there was a subchondral trabecular microfracture at the chondro-osseous junction (Figure 6.3b). It was not apparent histologically whether or not the microfracture communicated with the dissecting fissure.

Thirteen (62 %) foals had lesions on the medial trochlear ridge of the talus. These lesions were bilateral in 5 (24 %) cases. Lesions appeared grossly as a depression in the contour of the articular cartilage, with occasionally a linear invagination of cartilage. Lesions were located midway along the axis of the medial trochlear ridge, either on the apex of the ridge, or 2 to 4 mm medial to the apex. A variation of the lesion was a string of small punctate depressions in the cartilage, running parallel to the long axis of the ridge. Histologically these lesions showed one or more of: thickened cartilage, deep retention of cartilage, chondronecrosis, eosinophilic streaks, myelofibrosis, and surrounding osteosclerosis. Most had chondrones in or adjacent to the cartilage abnormalities. There was no significant effect of copper supplementation of mares or foals on the incidence of these lesions.

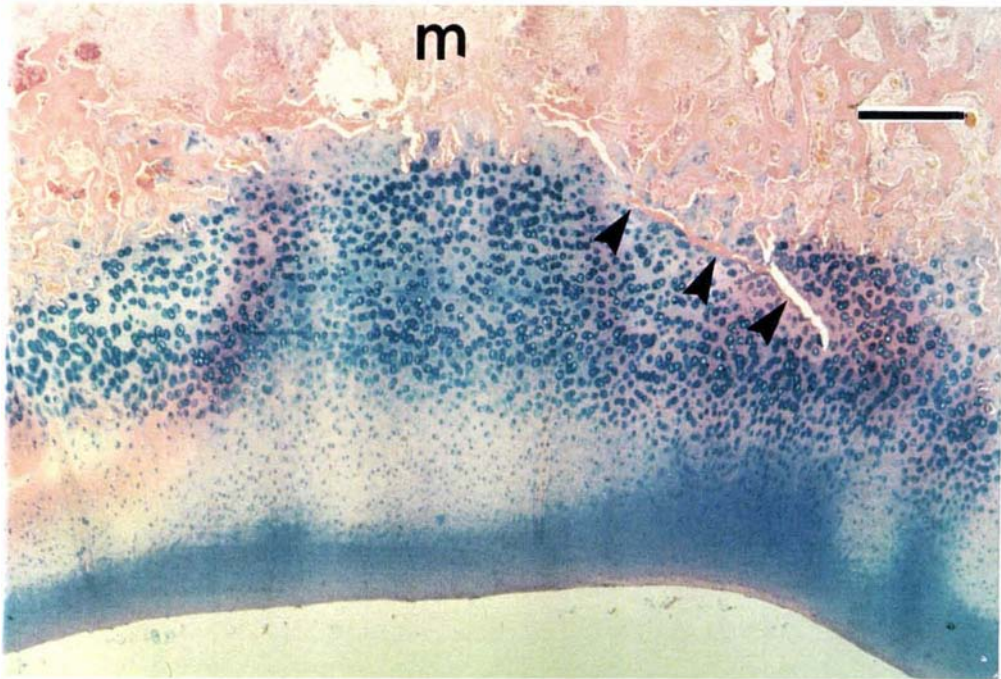
Figure 6.3 A retained cartilage lesion showing:

- a) the gross appearance in the lateral trochlear ridge of the distal femur (arrow heads) and,
- b) the histological appearance in the distal third metacarpal bone showing a widened zone of hypertrophic cartilage, a decrease in matrix staining, subjacent myelofibrosis (m), and a subchondral microfracture (arrow heads) associated with fibrin and necrotic cartilage. Stain: Alcian blue, Haematoxylin and Eosin. Magnification bar: 500 μ m.

a)



b)



Wear lines

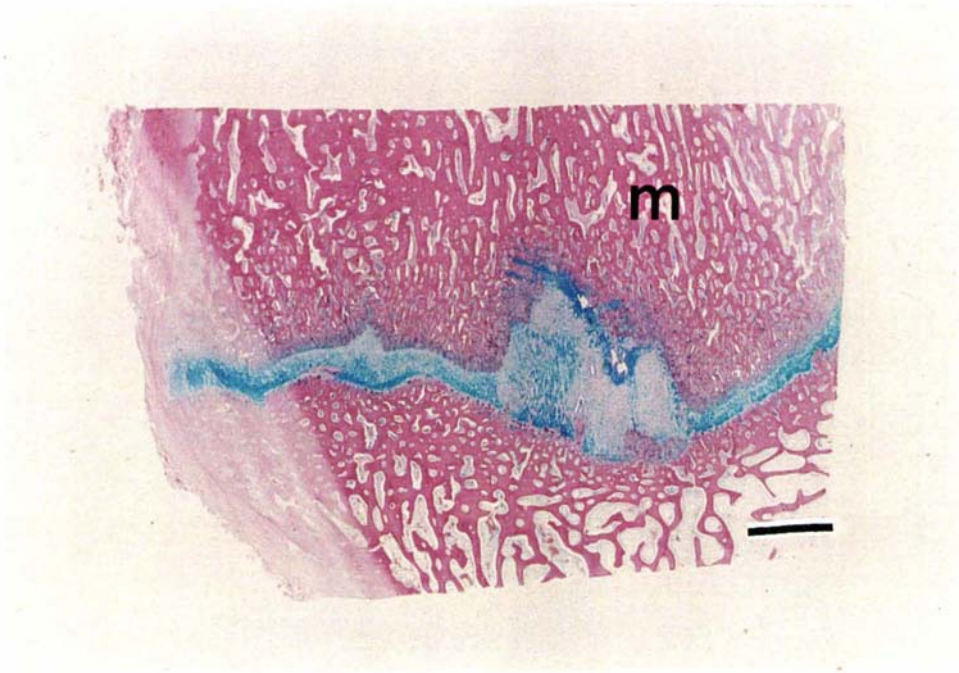
Wear lines were present in the humero-radial joint of 11 (52 %) foals and the femoro-tibial joint of 3 (14 %) foals. Histologically they appeared as a disruption in the tangential layer, along with a decrease in the number of chondrocytes superficially, and a decrease in the matrix staining intensity. There were no abnormalities evident in the subchondral bone associated with the wear lines.

Physeal cartilage

Lesions were categorised grossly as either physal disruption or retention of cartilage. Disruption was most commonly present on steeply inclined segments of the physis. Grossly these disruptions appeared as small (2 to 5 mm wide) epiphyseodeses, which histologically were either complete or partial (probably due to the plane of the section), consisting of trabeculae aligned perpendicular to the physis, and often accompanied by some thickening and disorganisation of the adjacent physis and fibrosis on the metaphyseal side of the epiphyseodesis. Disruptions to the physis in the distal metacarpus and metatarsus were considered part of the normal process of closure when there were other indications that the physis was beginning to close, such as considerable narrowing of the more central physal cartilage, especially the reserve cell zone, and complete closure beginning centrally and extending to the lateral and medial margins.

Retained cartilage lesions, most common in the distal troughs of the distal radial (Figure 6.4) and third metatarsal physes, were 4 to 10 mm high, and consisted primarily of retained hypertrophic cells and usually were associated with eosinophilic streaks. Usually the retentions were cone-shaped extensions into the metaphysis with disruption to the endochondral ossification on one or both sides of the cone. When endochondral ossification was occurring, the primary spongiosa in the area of the retained cartilage was shortened and often not aligned parallel to the direction of growth. Occasionally there appeared to be active endochondral ossification on the epiphyseal side of retained cartilage lesions, despite the presence of a subchondral bone plate in other areas.

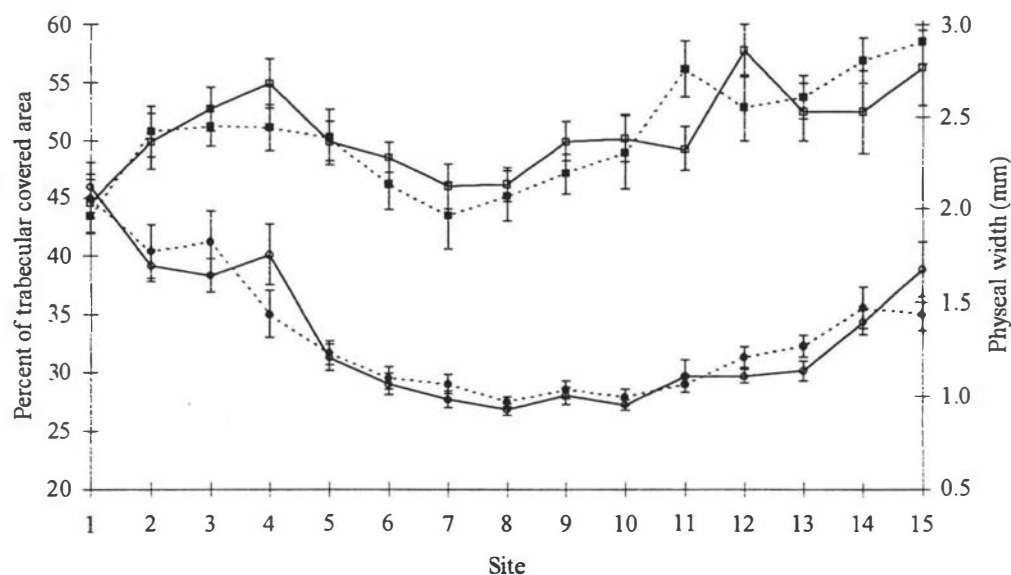
Figure 6.4 Low power micrograph of a retained cartilage lesion in a “trough” of the distal radial physis, showing retention of physcal hypertrophic chondrocytes protruding into the metaphysis (m). Stain: Alcian blue, Haematoxylin and Eosin. Magnification bar: 2.0 mm.



Histomorphology

Copper supplementation of the mare or foal had no significant effect on the histomorphometric parameters measured from the distal radii of foals (Figures 6.5). The physal depth was greatest at the periphery and significantly greater medially than laterally ($p < 0.001$). The physis consisted predominantly of reserve cells at the periphery, but approximately 80 % hypertrophic and proliferative cells in the central region. The percentage trabecular covered area was significantly different ($p < 0.001$) at different sites along the physis, being low at the medial edge, and in the centre of the physis, and having a peak close to the medial edge and being greatest at the lateral edge.

Figure 6.5 Percentage trabecular covered area of the metaphyseal spongiosa 10 mm proximal to the physis in control (□) and copper supplemented (■) foals, and width of the distal radial physis (mm) in control (○) and copper supplemented (●) foals measured from medial to lateral in a standard section of the distal radii in 13 foals (150 days of age).



6.5 Discussion

The dietary copper intake of control foals in the present study was within the range considered by Hurtig and Pool (1996) to be mildly deficient. However, there was no histomorphometric evidence of tissue fragility in the primary spongiosa of the distal radius of these foals compared with supplemented foals. The articular cartilage lesions were similar to the lesions found in the studies of Knight *et al.* (1990) and Hurtig *et al.* (1993). Pool (1993) has argued that bone and cartilage lesions occurring as a result of nutritional excesses or deficiencies are likely to be a different entity to the commonly recognised form of equine osteochondrosis. He considers that the distribution of lesions may differentiate the two forms, as the nutritional form tends to be generalised, often not bilateral, nor in predilection sites. It was also suggested that interpretation of nutritional trials can be complicated by the occurrence of both forms of osteochondrosis simultaneously.

Physeal lesions commonly consisted of an increase in the width of the zone of hypertrophic cells, and disruptions to the physis. Lesions occurred commonly in well defined areas particularly in the distal inclinations of the distal radius medially, and the distal 3rd metacarpal and metatarsal bones medially and laterally. These lesions were not clinically apparent, except for radiographic evidence of physitis and retained cartilage seen on survey radiographs in two foals. The histological morphology and gross distribution of these lesions were similar to the physeal abnormalities described by Brown and MacCallum (1976) in clinically normal foals.

The low incidence and severity of lesions in our foals differs from the findings of Knight *et al.* (1990) and Hurtig *et al.* (1993) who found significant DOD lesions in foals fed on diets containing 15 and 8 mg Cu/kg DM respectively, and an inverse relationship between copper supplementation and bone and cartilage lesions. It is possible that foals under North American management systems, commonly receiving high energy diets (130 % NRC (1989) recommendations) (Hurtig *et al.* 1990), may have a greater dietary copper requirement than pasture-fed foals. Glade *et al.* (1984) and Glade and Belling (1984) proposed that high energy diets interfere with the normal process of chondrocyte differentiation and maturation. Savage *et al.* (1993a) found an increase in the incidence of osteochondrosis lesions in foals fed 129 % NRC (1989) energy recommendations, compared with controls fed 100 % NRC (1989) energy recommendations. The high energy diets were achieved by adding maize oil to the ration which increased starch and fat intake. The copper concentration in the diets of both groups was 11 mg Cu/kg DM, and it was considered that due to the low incidence of lesions in the control

animals, high energy diets may be a more significant cause of osteochondrosis than copper at that dietary copper concentration. However, the effect of copper supplementation of the high energy diets on the incidence of lesions was not tested. An association between energy intake and copper requirements has been proposed by Glade (1986) who suggested that it may be mediated by insulin like growth factor. It is not known what the energy intake of our foals was, but they were well grown compared to NRC (1989) estimations for liveweights at 5 months, and compared with the average daily gains and final live weights of the foals in the study of Hurtig *et al.* (1993) as reported by Burton and Hurtig (1991) suggesting that our foals also received a high energy diet. Savage *et al.* (1993a) found no effect of increased energy intake on average daily gain, which is perplexing.

The source of carbohydrates may be important in the induction of DOD, and in particular soluble carbohydrates have been implicated (NRC 1989). A relationship between dietary carbohydrate source and copper bioavailability in male rats was described in a review by O'Dell (1990). However this effect described in male rats has not been demonstrated in other species; in addition, simple sugars decreased copper bioavailability relative to the effect of starch. In this respect, the effect in rats was due to fructose and sucrose, whereas starch was the major carbohydrate supplemented to foals receiving high energy diets in the work of Savage *et al.* (1993a).

The experiments of Knight *et al.* (1990) and Hurtig *et al.* (1993) found a high incidence of cervical vertebral lesions, suggesting that this may be a predisposition site for copper responsive articular cartilage lesions. However, we examined all vertebral facets and found no evidence of articular cartilage lesions in any of the foals. This is consistent with the low overall incidence and severity of DOD in our foals.

In our study, copper supplementation of the mare, and not the foal, decreased articular cartilage lesions and the radiographic indices of physitis in foals at 150 days. However there was no relationship between neonatal liver copper stores and either radiographic physitis scores or articular cartilage lesions. Therefore mare supplementation probably had an effect on the foal skeletal development *in utero* rather than through the provision of greater copper stores in the liver of neonates. This possible *in utero* effect needs to be investigated further. Osteoblasts in lambs are thought to be particularly sensitive to copper deficiency *in utero* and in early life, as the effects of reduced osteoblastic activity have been observed before other clinical or pathological signs of copper deficiency (Suttle *et al.* 1972). Treatment of the dam presents a

convenient approach for increasing copper status of foals *in utero*, and of new born foals (Chapter 4). In this respect, treating hinds with copper has been used to decrease the incidence of articular cartilage lesions in growing deer grazing New Zealand pastures (Thompson *et al.* 1994).

There are few data concerning the prevalence of DOD in pasture-fed New Zealand Thoroughbreds, but there are anecdotal reports of farms with very high incidence of clinical signs which in some years have considerable economic consequences. There is a great variety of supplementary nutritional regimes on pasture based production systems, as well as differences in climate, pasture and soil types throughout New Zealand. Thoroughbred farms with higher prevalence and severity of DOD than found in our trial may use greater amounts of supplementary feeding. Unknown constituents of these feeds may interact with copper metabolism, or increased foal growth rates may increase copper requirements of horses on these farms. There also may be a variation in copper supply between seasons. In our study, all horses were supplemented with zinc and selenium to ensure that they were not limiting, and it is uncertain whether deficiencies of these minerals may contribute to the nutritional aetiology of DOD on some farms. Animals in this study had low calcium and phosphorus intakes (2.5 to 3.8 g Ca/kg DM and 2.3 to 4.3 g P/kg DM) as well as a low calcium to phosphorus ratio (ranging from 0.72 to 1.4, and below 1.0 for 6 of the 11 months of the trial), compared with NRC (1989) recommendations. Low calcium to phosphorus ratios have been proposed as an important cause of DOD (Savage *et al.* 1993b), but this is not supported by our findings.

In conclusion, copper intake of foals grazing pastures containing 4.4 to 8.6 mg Cu/kg DM, is adequate for healthy development of bone and cartilage. However copper supplementation of mares in the final half of gestation did reduce the evidence of abnormalities in bone and cartilage development of their foals at 150 days of age, although the clinical significance of this evidence was minor. Copper supplementation of mares may provide a convenient treatment regime on farms experiencing a greater incidence and severity of developmental orthopaedic diseases.

Chapter 7

The Effect of High Pasture Molybdenum Concentrations on the Copper Status of Grazing Horses⁶

⁶ Submitted as: SG Pearce, EC Firth, ND Grace and PF Fennessy (1997) *American Journal of Veterinary Research*.

7.1 Abstract

Inconsistencies exist in the recommendations on the copper requirements of horses. The objective of this study was to determine whether molybdenum could act as an antagonist causing secondary copper deficiency in pasture-fed horses. Twelve Thoroughbred weanling fillies were divided into two groups and fed either on a pasture containing 8 to 15 mg Mo/kg DM, or on a control pasture containing 0.6 to 1.2 mg Mo/kg DM for 84 days. Both pastures contained 6 to 9 mg Cu/kg DM. The animals were challenged with copper over the last 14 days to determine their response to supplemental copper (1.0 mg/kg liveweight) given orally three times a week. Copper status indices included liver, plasma, blood cell and plasma trichloroacetic acid insoluble copper concentration as well as the enzyme activities of caeruloplasmin oxidase and red blood cell superoxide dismutase. None of these indices were affected by the level of molybdenum intake. Horses grazing pasture high in molybdenum did not respond differently to a copper challenge when compared to controls. The results of this study suggest that molybdenum is unlikely to increase copper requirements by causing a secondary copper deficiency at copper and molybdenum concentrations normally found in the diet of New Zealand pasture-fed Thoroughbreds.

7.2 Introduction

It is considered that copper (Cu) deficiency may contribute to abnormal skeletal development of foals (Lewis 1995; Hurtig and Poole 1996). There are reported cases of copper-responsive orthopaedic disease in foals on pasture (Egan and Murrin 1973a, Carberry 1978), with evidence of a high dietary molybdenum (Mo) intake in one case (Egan and Murrin 1973a). Similarly, studies in North America have found beneficial effects of copper supplementation of foals on diets of 8 to 15 mg Cu/kg DM prior to supplementation (Knight *et al.* 1990; Hurtig *et al.* 1993). However, a supplementation trial performed on horses grazing pasture containing 4.4 to 8.6 mg Cu/kg DM showed only minor benefits of foal copper supplementation (0.5 mg Cu/kg Liveweight) on indices of bone and cartilage development (Chapter 6). Therefore we propose that a dietary copper antagonist such as molybdenum might explain these apparent inconsistencies.

Walsh and O'Moore (1953) suggested that molybdenum might be a cause of osteodystrophy in horses. Two studies in which horses were fed molybdenum had contrasting results. In one study, aqueous ammonium molybdate was fed at increasing concentrations (1, 27 and 107 mg

Mo/kg DM), for 2 to 3 weeks at each level, to bile duct cannulated ponies. The ponies had increased biliary copper excretion, decreased caeruloplasmin activity and increased trichloroacetic acid (TCA) insoluble copper which was suggestive of the presence of systemic thiomolybdates (Cymbaluk *et al.* 1981b). In the other study, aqueous ammonium molybdate was fed at a rate of 20 mg Mo/kg DM for 4.5 months to horses of mixed breeding, and there was no apparent change in plasma copper or TCA insoluble copper concentrations (Strickland *et al.* 1987). In addition, excess molybdenum due to industrial pollution has been reported to cause death in horses associated with decreased liver copper stores (Ladefoged and Sturup 1995).

In ruminants, molybdenum (associated with sulphur) interferes with copper metabolism by the formation of thiomolybdates in the reductive environment of the rumen (Dick *et al.* 1975, Price *et al.* 1987). Thiomolybdates interfere with copper absorption in the small intestine, and alter the protein ligand binding of absorbed copper. This increases the concentration of copper in the TCA insoluble fraction of the blood, which is less readily available. There is also an increase in biliary excretion of copper as demonstrated in horses (Cymbaluk *et al.* 1981b) and cattle (Gooneratne *et al.* 1994). In ruminants, diets high in molybdenum cause a depletion of liver copper stores (Van Ryssen 1994), and are used as models for copper deficiency in ruminants (Ledoux *et al.* 1995). Intravenous administration of thiomolybdates has also been recommended for the treatment of copper poisoning in sheep (Gooneratne *et al.* 1981; Humphries *et al.* 1988).

In the absence of a rumen, the hindgut might be a site in horses suitable for the formation of thiomolybdates. Since significant copper absorption occurs in the small intestine, any effect of hindgut thiomolybdate formation on copper absorption is unlikely, and any influence of the Cu-Mo interaction would therefore be associated with systemic thiomolybdates. However, Strickland *et al.* (1987) concluded that insufficient molybdenum entered the large intestine to form significant amounts of thiomolybdates because of the rapid absorption of molybdenum from the small intestine and its subsequent urinary excretion.

In the experiments of both Cymbaluk *et al.* (1981b) and Strickland *et al.* (1987) aqueous solutions of molybdenum were used as a supplement. This form of molybdenum may be more readily available than molybdenum contained in pasture plants, and therefore grazing pasture plants with high molybdenum concentrations may allow sufficient molybdenum to reach the large intestine leading to the formation of sufficient amounts of thiomolybdates to antagonise

copper metabolism systemically. This study reports on the influence of grazing pasture containing high molybdenum concentrations on the copper status of horses

7.3 Materials and methods

7.3.1 Experimental design

There were two treatments (low and high molybdenum pasture), with six horses per treatment. The horses grazed the experimental paddocks for a total of 84 days from the 13th May to the 5th August 1996 (Winter). The experiment was run in two parts. In part 1 (day 0 to 70), the horses grazed the pasture without any supplementation, and in part 2 (day 70 to day 84), all horses received a thrice weekly supplement of copper sulphate orally at a rate of 1.0 mg Cu/kg liveweight (LW)/day.

7.3.2 Animals

The 12 weanling Thoroughbred fillies were aged 170 to 260 days and were assigned to either a treatment or a control group by stratified randomisation. The fillies were allocated to groups based on their sire, age and caeruloplasmin oxidase activity, which was determined 7 days prior to the start of the experiment. The two groups were grazed on low endophyte ryegrass (*Lolium perenne* L.) in adjacent paddocks.

7.3.3 Diets

The pasture for the treatment group was sprayed with an aqueous solution of Na_2MoO_4 at a rate of 500g Mo/ha, 5 weeks prior to day 0, while the pasture for the control group was not treated. The pasture for both groups was not grazed for a period of 5 weeks following application of the fertilisers, to allow uptake of the molybdenum by the plants and to provide adequate pasture for the duration of the experiment. Pasture samples were collected for mineral analysis every 2 weeks after topdressing for the duration of the trial.

7.3.4 Part 1: Molybdenum copper interaction

A standing, ultrasound-guided liver biopsy (Chapter 2) was performed on all animals on day -4 and 67, for the assessment of liver copper concentration. The biopsied liver tissue was frozen

at -20°C until analysis. Animals were examined clinically at the same time as the liver biopsies were taken. Plasma copper and 5% TCA insoluble plasma copper concentrations and the plasma caeruloplasmin activity, were measured on days -7, -4, 0, 7, 14, 28, 42, 56, and 67. Blood cell copper concentration was also analysed on days 42, 56 and 67. Red blood cell copper-zinc superoxide dismutase (RBC Cu-Zn SOD) activity was determined on day 67.

7.3.5 Part 2: Copper challenge

In the event of molybdenum depleting liver copper stores, and influencing blood copper indices, the copper challenge was designed to measure the rate of liver copper repletion, and the influence on circulating copper indices.

On day 70, all animals were weighed and given oral copper sulphate supplementation at a rate of 1.0 mg/kg LW/day. The supplementation was given orally as 3 doses per week. Plasma and blood cell copper concentration and caeruloplasmin and RBC Cu-Zn SOD activity were monitored on days 77, 84 and 87 after the onset of copper supplementation. A third liver biopsy was performed on day 84.

7.3.6 Analytical

Plasma and blood cell copper were measured using inductively coupled plasma emission spectrometry (ICP) (Lee 1983). TCA insoluble copper was measured by calculating TCA soluble copper and subtracting from total plasma copper concentration. TCA soluble copper was measured by mixing plasma with an equal volume of 10 % trichloroacetic acid (w/v) for 30 s and then centrifuged at 2400 g for 15 min. The supernatant was harvested, and the precipitate was reconstituted in 5 % TCA, and the procedure repeated (Mason *et al.* 1979). The supernatants were pooled and the copper concentration determined via ICP.

Plasma caeruloplasmin activity was measured using a colorimetric method (Ravin 1961) to measure the oxidation of the substrate *p*-phenylenediamine-dihydrochloride (PPD). The results are expressed as absorbance units at 530 nm (37°C) per litre of plasma.

The Cu-Zn SOD activity of lysed red blood cells was determined spectrophotometrically using a kit (Crumlin, Northern Ireland) based on the method of Podczasy and Wei (1988).

Analysis of caeruloplasmin oxidase activity was performed within 3 days after each sampling occasion. Analysis of RBC Cu-Zn SOD activity and pasture copper concentrations were performed in one batch at the end of the trial. All other samples were analysed in four batches following the day 7, 28, 67 and 84 day samples.

Liver copper concentration was analysed by Zeeman graphite furnace atomic absorption. Samples were run with a liver standard of known copper concentration produced by the National Bureau of Standards, USA (NBS, bovine liver 1577-B). All liver samples were analysed in one batch after completion of the experiment.

7.3.7 Statistical analysis

Blood copper status indices were compared between groups by analysis of variance (ANOVA) with repeated measures on time. The effect of molybdenum intake on liver copper concentration and the response of the liver copper concentration to the copper challenge, was analysed by ANOVA, using the initial liver copper concentration as a covariate. Analyses were performed with Statistical Analysis System (SAS) version 6.11 (SAS Institute Inc. Cary, N.C., USA) using proc glm for ANOVAs, and proc mixed for ANOVAs with repeated measures over time.

7.4 Results

7.4.1 Pasture minerals

Mean pasture mineral concentrations for the molybdenum treated and control paddocks were: 4.7 and 3.9 g calcium/kg DM, 3.6 and 3.5 g phosphorus/kg DM, 1.9 and 1.9 g magnesium/kg DM, 32 and 32 g potassium/kg DM, 2.0 and 2.1 g sodium/kg DM, 577 and 438 mg iron/kg DM, 76 and 72 mg manganese/kg DM, and 24 and 25 mg zinc/kg DM. The pasture concentrations of sulphur, molybdenum and copper for the control and molybdenum treated paddocks, over the period of the experiment, are presented in Table 7.1

Table 7.1 Concentrations of sulphur, molybdenum and copper from the molybdenum treated and control paddocks.

Trial day	Molybdenum treated paddock			Control paddock		
	S	Mo	Cu	S	Mo	Cu
	g/kg DM	mg/kg DM		g/kg DM	mg Cu/kg DM	
0	4.2	16.1	8.5	3.5	0.8	8.2
28	3.9	13.2	8.9	3.6	1.0	8.4
42	3.3	9.9	7.5	3.5	1.2	7.4
56	2.8	9.5	6.8	3.8	0.7	8.0
77	2.4	8.6	6.9	2.4	2.0	7.0
84	3.2	7.2	7.1	3.0	2.6	6.4

7.4.2 Part 1: Molybdenum copper interaction

Clinical examinations

Clinical examinations revealed no differences in conformation or clinically evident musculo-skeletal disease between high molybdenum and control groups.

Blood copper indices

There were no significant differences between high molybdenum and control groups, for any of the blood copper status indices, but there was a significant effect of time for all indices. The plasma copper concentration of both groups declined until day 56 (Figure 7.1a), so that the level was significantly lower than the initial plasma copper concentration ($p < 0.005$). The caeruloplasmin activity did not show a similar decrease in the day 56 sample (Figure 7.1b).

There was no difference between treatment groups in TCA insoluble copper concentration, which remained below 0.1 mg Cu/kg DM for both groups.

Liver copper

There was a large variation in the initial liver copper concentrations with the high molybdenum group having a mean liver copper concentration (61.1 mg Cu/kg DM) approximately twice that of the low molybdenum animals (34.6 mg Cu/kg DM) prior to the start of the trial. However the differences were not significant due to the wide variation among individuals. The variation between groups was greatly diminished at the 67 day liver biopsy, with mean liver copper concentrations of 20.9 and 14.9 mg Cu/kg DM for high molybdenum and control groups respectively; the difference was not significant (Figure 7.2).

Figure 7.1 (on following page) Copper indices in weanling Thoroughbred fillies grazing pasture with low (□, n=6) or high (■, n=6) molybdenum concentration. Error bars represent standard error of means, arrow heads indicate the start of the copper challenge.

- a) Plasma copper concentration.
- b) Plasma caeruloplasmin oxidase activity.
- c) Blood cell copper concentration.
- d) Red blood cell superoxide dismutase activity.

Figure 7.1a

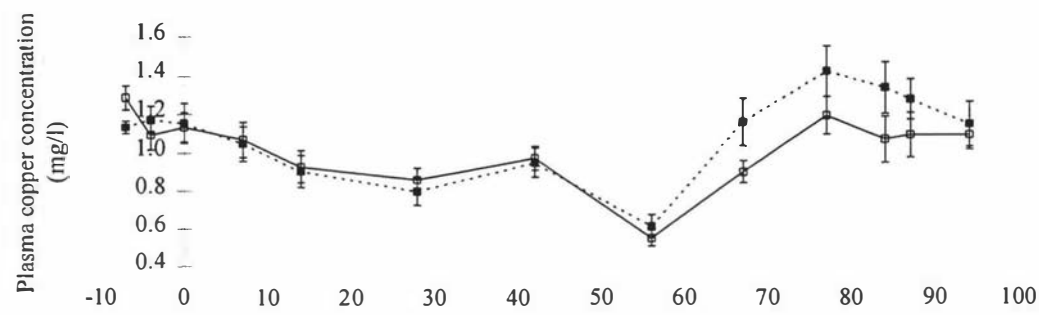


Figure 7.1b

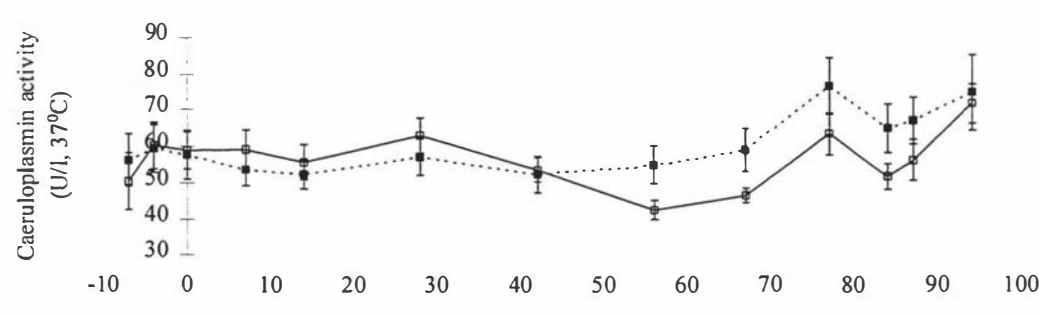


Figure 7.1c

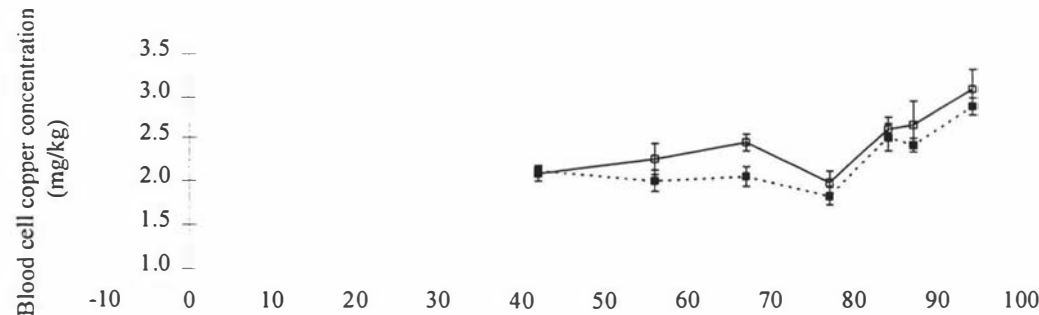


Figure 7.1d

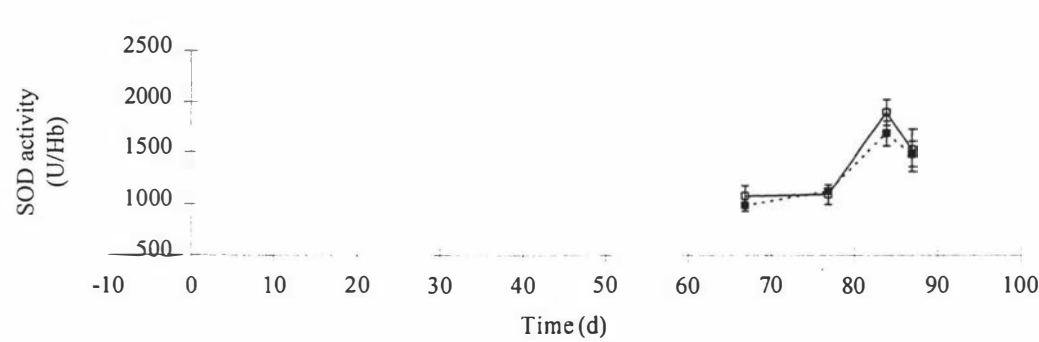
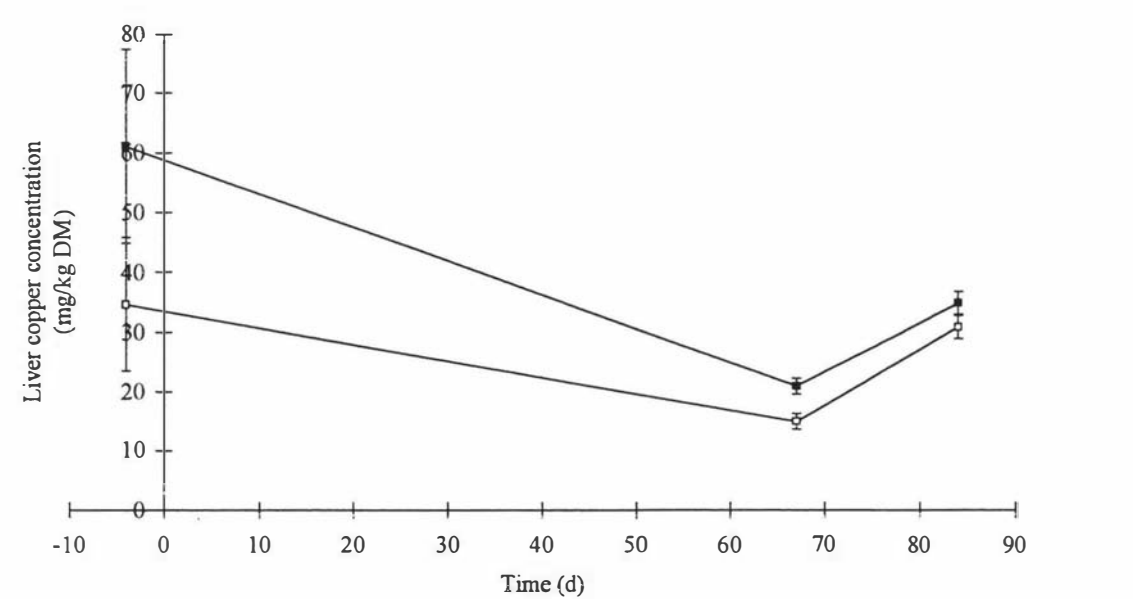


Figure 7.2 Mean liver copper concentration from weanling Thoroughbred fillies on high molybdenum (■, n=6) or control (□, n=6) pastures. Error bars represent standard error of means.



7.4.3 Part 2: Copper challenge

Blood copper indices

There was no significant difference between high and low molybdenum groups of any of the blood copper status indices measured. The mean plasma copper concentration peaked on day 77 (7 days after the onset of the copper challenge) and then declined on the day 84 and 87 samples. Following onset of the copper challenge, blood cell copper concentration decreased to a minimum at day 77 and then increased, with the day 84 and 87 samples being greater than the day 77 sample (Figure 7.1c). The RBC Cu-Zn SOD activity increased significantly between day 77 and a peak at day 84 (Figure 7.1d).

Liver copper

The liver copper concentration after the copper challenge (84 days) was significantly greater than at day 67 in both groups, but there was no significant difference between treatment groups in the rate of change of the liver copper concentration between the two samples.

7.5 Discussion

There was no effect of the high molybdenum pasture diet on blood copper indices, or on the liver copper concentration of the horses, including TCA insoluble copper which is considered to be an early, sensitive indicator of mild molybdenosis in ruminants (Lamand *et al.* 1980). This suggests that there was no significant absorption of thiomolybdates in the horses, and is in agreement with the study of Strickland *et al.* (1987) but contrasts with the study of Cymbaluk *et al.* (1981b). Changes to blood copper indices in ruminants on high molybdenum intakes include an increase in plasma copper concentration, and a decline in caeruloplasmin activity. Similar changes were described in horses by Cymbaluk *et al.* (1981b).

The liver copper concentrations of the horses at the beginning of the experiment varied widely, with the animals in the high molybdenum group having a mean liver copper concentration almost twice that of the control animals. The differences in liver copper concentration between groups was not significant because of the wide variation. The liver copper concentrations of the horses after 67 days on the experimental pasture had decreased, and using the initial liver copper concentrations as a covariate, the difference between treatment groups was not significant. It was unfortunate and unexpected that the initial mean liver copper concentrations of the two groups was so different, and the reason for this was not known. All liver biopsies were analysed together after completion of the experiment.

There is no ready explanation for the changes in the plasma copper concentration which declined to a minimum at 56 days and then increased. Venipuncture was taken at approximately the same time each day to minimise any diurnal variation, as has been reported in human plasma copper concentrations (Lifschitz and Henkin 1971). The increase in plasma copper concentration could not be attributed to the copper challenge because the increase began before the challenge. Previous work with copper supplementation has also suggested no relationship between dietary copper intake and plasma copper concentration at mean pasture dietary copper intakes of 6 to 7 mg Cu/kg DM) and greater (Smith *et al.* 1975; Chapter 5). The caeruloplasmin activity increased significantly from day 67 to 77, mimicking the increase in the plasma copper concentration. The changes to the blood cell copper concentration also mimicked the changes to the plasma copper concentration, but they occurred 3 weeks later. RBC Cu-Zn SOD activity also increased when the blood cell copper concentration increased. The ready response of the RBC Cu-Zn SOD may indicate reconstitution of an apoenzyme in

circulating blood cells. There were less data for RBC Cu-Zn SOD than the other indices, as the assay was being developed during the trial.

The plasma copper concentration showed two distinct patterns of change. There was a downward trend to day 56 followed by a rise as well as transient changes between sampling days which were consistent for all foals. Possible causes for the general trends include changes in diet, excluding copper and molybdenum, or seasonal changes such as temperature or photoperiod. There was a very high concentration of iron in the pasture analyses, which was most likely due to soil contamination as the pastures became quite muddy during the experiment. This is likely to reflect an increase in iron intake by the horses, which may have affected copper status. The effects of photoperiod on homeostatic regulation have been well described with reproductive and growth hormones in a number of domestic species, and it is possible that this may have influenced copper status in this trial as the shortest day of the year was on day 39. Seasonal effects on copper status in horses have been reported by Auer *et al.* (1988a), and were considered to be most likely due to changes in dietary copper intake or availability.

Causes for the transient changes in plasma copper concentration may include daily climatic changes such as temperature or rainfall as well as inflammatory episodes such as viral respiratory infection as plasma copper and caeruloplasmin activity are known to be responsive to inflammation (Auer 1989a). However, there was no evidence of disease in the fillies during or preceding the trial. The liver biopsy procedure had no apparent effect on plasma copper status following the first liver biopsy (day -4), and was not considered to be a significant cause of the variability of the indices.

The inability of pasture containing 7 to 18 mg Mo/kg DM to deplete copper stores in Thoroughbred weanlings compared with control animals, is consistent with previous observations that horses are able to graze "teart" pasture that cause secondary copper deficiency in cattle, without clinical signs of disease (Underwood 1977). Presumably differences between horses and ruminants in molybdenum metabolism relate to the greater ability of the rumen compared with the hindgut of horses, to produce thiomolybdates, and the location of the rumen, preceding the site of copper oxidation and absorption. Further research is required to determine the manner in which horses are "protected" from the effects of high molybdenum intakes. Whether molybdenum is prevented from reaching the large intestine in sufficient amounts, or the large intestine is not a suitable environment for the production and

subsequent absorption of thiomolybdates, or whether absorbed thiomolybdates are prevented from interacting with tissue copper is not known.

It is possible that a greater amount of molybdenum than fed to the horses in this trial may result in greater formation and absorption of thiomolybdates. However since the pasture molybdenum concentration in this trial was very high compared with New Zealand pastures which can contain 0.2 to 10 mg Mo/kg DM (Grace 1983b), this would preclude molybdenum as a likely cause of secondary copper deficiency responsible for copper responsive developmental orthopaedic disease in foals.

Chapter 8

General Discussion

8.1 Introduction

The original hypothesis for the studies described in this thesis was to determine whether dietary supplementation of pasture-fed New Zealand Thoroughbreds with copper would reduce the incidence and severity of DOD, and to identify suitable indices related to copper status and features of bone and cartilage development in order to better define the relationship between dietary copper, copper status and DOD. This was achieved by a copper supplementation trial and investigation of changes in copper status and bone and cartilage development. These studies found that mare copper supplementation increased neonatal foal liver copper concentrations and was associated with a reduction in the (mild) evidence of DOD in foals up to 5 months of age. Foal copper supplementation increased liver copper concentrations but had no effect on any index of bone or cartilage development.

8.2 Experimental design

The rationale for this investigation was based on the concerns of the New Zealand Thoroughbred industry regarding the amount of wastage, largely in terms of decreased sale value, of animals with DOD. These concerns were documented in a survey produced by the New Zealand Equine Research Foundation for the Racing Industry Board. Many aetiologies have been proposed for DOD but copper seemed the most appropriate factor for immediate study because recent work had suggested that the copper requirements for growing horses (20 to 30 mg Cu/kg DM) were greater than can be provided by a pasture diet (5 to 10 mg Cu/kg DM) (Knight *et al.* 1990; Hurtig *et al.* 1993) which has already lead to a widespread practice of copper supplementation.

The studies were performed at the AgResearch Flock House equine research facility, a new facility which had not run horses previously. Therefore the level of DOD that might be expected was not known. The pasture copper concentration (4.4 to 8.6 mg Cu/kg DM) was below NRC (1989) recommended levels (10 mg Cu/kg DM) and at similar levels to the foals fed low copper diets in the studies of Knight *et al.* (1990) and Hurtig *et al.* (1993), in which copper supplementation was found to reduce the incidence of DOD. Our supplemented animals received 0.5 mg Cu/kg LW/day, a similar dietary copper concentration to the high copper treatments in the previous studies (30 mg Cu/kg DM). However, the literature on factors affecting copper bioavailability in horses is sparse, which makes comparison between

measured dietary copper levels in different diets problematic as unknown factors may influence copper absorption.

Copper sulphate is often used as the benchmark for comparing the bioavailability of other copper containing compounds (Baker and Ammermann 1995). Copper-containing compounds, other than copper sulphate, and in particular copper proteinates, might have a greater bioavailability in horses, but this has not yet been documented. In horses satisfactory methods of long term copper supplementation have not been reported, and so we resorted to frequent oral dosing. An alternative could be the feeding of a small quantity of copper “spiked” supplement, a method which may still not be satisfactory for herds of horses on pasture where the intake of supplements by individuals cannot be regulated. Therefore there is a need for the development of depot formulations. In our work, copper sulphate doses were administered three times per week. Whether more or less frequent dosing at the same dose rate would have had a different effect on copper bioavailability is not known.

8.3 Development of surgical techniques

8.3.1 Liver biopsy technique

The liver biopsy technique described in this thesis was developed to obtain samples to determine liver copper concentration. The morbidity and adverse effects of the techniques were also investigated so that their usefulness for further studies could be assessed. The transabdominal, laparoscopically-guided technique performed on the neonatal foals under anaesthesia was considerably more involved than the standing, percutaneous, ultrasound-guided, transthoracic technique which was easily performed. The latter procedure was performed on the mares in the main study, and on the weanlings in the investigation of high dietary molybdenum. In the case of 4 mares the liver could not be visualised ultrasonographically, presumably due to atrophy of the liver in these horses. Liver biopsies performed by these techniques provide an estimate of the liver copper concentration with a coefficient of variation of 10 to 20 percent. Both procedures had few adverse effects on the horses.

8.3.2 Physeal biopsy technique

The physeal biopsy technique was developed to obtain tissue for the investigation of bone and cartilage development in neonatal foals. The tissue sample was adequate for histological examination, and was used in a separate study on immunohistochemistry of the growth plate (SA Holle and EC Firth, unpublished data). There were some problems with the foals following this procedure including wound breakdown, excessive granulation tissue formation and conformational abnormalities. These problems might preclude the clinical usefulness of this technique, but more rigorous aftercare and the use of anti-inflammatory medication may attenuate the adverse effects. The time the foals spent confined postoperatively was minimised because the main study required them to be grazing a pasture diet, and anti-inflammatories were not administered lest they interfere with copper metabolism and status. The physeal biopsy is a useful technique as it provides adequate sample for examination of physeal composition and structure, and morbidity need not be significant.

8.4 The concept and measurement of adequate copper status

Adequate copper status was defined (Chapter 1) as existing when tissue copper concentrations, and more particularly liver copper stores, are sufficient to ensure that copper is not limiting biochemical and physiological function and that animal performance and health are not improved by copper supplementation. When copper intake is inadequate we would first expect a depletion of tissue copper stores, which would progress to a state of deficiency whereby there is a decrease in plasma copper concentration and insufficient copper for the copper containing enzymes. The resultant decline in cupro-enzyme activity will result in a dysfunction in their biological activity which will then progress to copper deficient disease which is well defined in ruminants, but is not commonly recognised in horses.

8.4.1 Plasma indices of copper status

Plasma and serum copper concentrations consistently fall below normal in cases of experimental copper deficiency (Bridges and Harris 1988) in which case a threshold is presumably reached whereby tissue reserves are depleted and normal blood copper concentrations can no longer be maintained.

The measurement of plasma copper and caeruloplasmin oxidase activity can be influenced by various factors and conditions discussed in Chapter 1. The data in this thesis also present the normal postpartum changes in these parameters. Pasture-fed Thoroughbred foals are initially hypocupraemic with low activities of caeruloplasmin, and these parameters increase to adult levels by approximately 3 weeks of age. This corroborates the data of Bell *et al.* (1987).

If a dietary copper threshold for maintenance of plasma indices exists, then the pasture diet of both mares and foals in our experimental work was above this level, as there was no effect of copper supplementation on plasma and blood cell copper concentration and plasma caeruloplasmin activity. However, according to the above definition, copper supplementation of the mare reduced the evidence of DOD in their foals indicating that these animals were responsive to copper supplementation, and therefore not of an adequate copper status. This apparent contradiction is considered later and indicates that indices may differ in sensitivity.

8.4.2 Blood cell copper concentration and RBC Cu-Zn SOD as indices of copper status

Blood cell copper represents a tissue copper pool that can be readily easily sampled. A large proportion of blood cell copper is associated with the cupro-enzyme superoxide dismutase although there is no apparent correlation between total blood cell copper concentration and RBC Cu-Zn SOD activity (Scudder *et al.* 1976). Blood cell copper in these studies was not affected by dietary copper levels and showed little change postpartum. The activity of Cu-Zn SOD may be a more useful index of copper status than plasma copper concentration as it is less responsive to inflammation and other such factors (Milne 1994).

8.4.3 Liver copper concentration as an index of copper status

The liver is considered a copper storage organ in ruminants, because increased copper intake results in increased liver copper concentration (Woolliams *et al.* 1983). A similar relationship between copper intake and liver copper concentration was found in our horses, and has also been reported in other studies (Cupps and Howell 1949; Smith *et al.* 1975; Hurtig *et al.* 1990). This contrasts with the situation in humans, in which it is considered that copper is not stored in the body to any great extent as excess copper is readily excreted via the bile (Linder and Hazegh-Azam 1996).

At present the limitation of liver copper concentration as a measure of copper status in horses is that the liver copper concentration at which copper inadequacy occurs, that is decreases in plasma copper and retardation of copper-dependent processes is not known. Therefore the liver copper concentration may be used to compare different individuals or treatments, but there are no data to define whether a horse has an adequate copper status based on its liver copper concentration. In this respect, plasma copper concentration and cuproenzyme activities are likely to be more useful as they reflect the availability of copper to copper-dependent processes.

8.5 The effect of copper supplementation of the mare and foal on indices of copper status

Copper supplementation of pregnant mares did not influence their plasma copper concentration, which decreased over the final stages of gestation (Chapter 4). This decline was presumably physiological and was not responsive to dietary intake. However the relationship with stage of pregnancy was low ($r^2 = 0.2$) indicating that the effect of pregnancy explained only a minor part of the total variation. Large general trends and smaller transient changes in plasma copper concentration and caeruloplasmin activity were often detected and could not be explained, but these indices never showed a response to copper supplementation. Changes in copper indices are discussed in more detail in Chapter 7.

Copper supplementation of pregnant mares increased the liver copper concentration of their foals, and there was a trend toward increased liver copper concentrations in the mare. It is considered that the high liver copper concentration of new born foals is required to provide copper during nursing when dietary copper intake (from milk) is low (Meyer and Tiegs 1995). The apparent preferential storage of copper in the foetal liver rather than the mare may support the theory that the copper stored in the neonatal liver performs an important function in the neonatal period. However, there was no relationship between liver copper concentration at 4 to 10 days of age and any of the blood copper status indices. Other suggestions to explain the high neonatal liver copper concentrations include storage of copper for chromosomal function (Leighton *et al.* 1990) and a consequence of the failure of foetal liver to excrete accumulated copper (Cymbaluk and Smart 1993). More information is required on copper requirements of the foal as well as the increased absorption of dietary copper by neonates, as described in sheep (Suttle 1975) and rats (Mistilis and Mearrick 1969), which may compensate for low dietary copper concentrations during nursing.

Copper supplementation of pasture-fed foals from birth to weaning at 5 months of age significantly increased their liver copper concentration measured at postmortem at 5 months of age. There was no residual effect of mare copper supplementation on the foal's liver copper concentration at 5 months of age. The rate at which the high neonatal liver copper concentration falls, and the effect of dietary copper intake on this decline, would help determine the importance of the neonatal liver copper stores. None of the other organs appeared to store significant amounts of copper although there was a trend toward increased brain copper concentration in copper-supplemented foals.

8.6 The effect of copper supplementation of the mare and foal on indices of bone and cartilage development

No study has yet identified the mechanism by which supplementary copper may reduce abnormalities in bone and cartilage development in horses. A decrease in the cupro-enzyme lysyl oxidase activity was strongly implicated in copper-depleted foals because of the concurrent increase in collagen solubility (Bridges and Harris 1988). A decrease in lysyl oxidase (amine oxidase) activity was accompanied by increased collagen solubility in chickens raised on copper deficient diets (Rucker *et al.* 1969).

It may be expected that lysyl oxidase activity in our animals, and also with the animals in the study of Hurtig *et al.* (1993) were adequate because plasma and blood cell copper concentrations and plasma caeruloplasmin activity were not influenced by copper supplementation. However lysyl oxidase levels were not measured in either study, and it is unlikely, that a decrease in lysyl oxidase activity preceded a depletion of caeruloplasmin activity or a decline in plasma copper concentration. Plasma and tissue copper concentrations or cupro-enzyme activity were not measured in the study of Knight *et al.* (1990). Connective tissue was collected and stored for the determination of lysyl oxidase in our study, but due to the lack of significant bone and cartilage lesions, it was decided not to perform these assays.

However, the situation where horses responded to copper supplementation despite being above the threshold required for the maintenance of normal blood copper indices was reported in the experiment of Hurtig *et al.* (1993) where copper decreased the incidence of bone and cartilage abnormalities, but had no effect on blood copper concentrations or caeruloplasmin activity.

Copper supplementation of our foals had no effect on indices of bone and cartilage development, but supplementation of the mare resulted in a decrease in the radiographic indices of physitis and a decrease in abnormalities detected at postmortem (at 5 months of age) in the cartilage and subchondral bone of limb joints.

The bone and cartilage abnormalities present were minor. In the articular cartilage they consisted of either small retentions of cartilage, usually in commonly described locations such as the lateral and medial condyles of the distal third metacarpal/metatarsal bone and lateral trochlear ridge of the distal femur, or small invaginations of cartilage in locations where subchondral bone cysts have been described such as the medial condyle of the distal femur, the proximal radius, the proximal humerus and the proximal and distal articular surfaces of the proximal phalanges.

A number of mild lesions consisting of retained cartilage with irregular pitting of the surface of the articular cartilage were found on the medial trochlear ridge of the talus which is not considered a predilection site for OC lesions, nor other clinically evident skeletal disease. Other sites in the hock commonly associated with OC (intermediate ridge of distal tibia and lateral trochlear ridge of the talus) were not affected, and therefore, while the significance of the lesions on the medial trochlear ridge was not known they were considered to be minor.

There was no effect of mare copper supplementation on retentions of cartilage in the physis, but there was an effect on radiographic indices of physitis in the distal third metatarsal bone. This might be because only the distal third metacarpal/metatarsal physes were affected at the time of euthanasia, and as the growth plates were closing, it was not possible to evaluate them accurately by gross or histological examination, whereas the radiographic features of physitis were still evident. Radiographs might be better for assessing features of physitis, as the plane of section is not important as for gross and histological examinations, and it is easier to assess bone remodelling radiographically. The technique used for assessing features of physitis described in Chapter 6 had a very good repeatability between observers and might be a very useful clinical tool, but there would be obvious advantages to an automated image analysis procedure. The presence of physitis in only the metacarpal/tarsal growth plates is an illustration of the proposed “window of vulnerability” (Pool 1993).

No lesions appeared to be clinically significant at the time of euthanasia and only two cases of retained cartilage (distal third metacarpal bone and lateral trochlear ridge of the distal femur) were seen on the radiographs taken at postmortem at 5 months of age.

The fact that mare but not foal copper supplementation affected bone and cartilage development of foals may either reflect a greater requirement for copper *in utero* and/or a greater susceptibility of the skeleton *in utero* to lesions which may be attenuated by copper supplementation of the mare. In particular it suggests that articular and physeal cartilage abnormalities may originate *in utero*, which can be influenced post-natally by environmental and managemental factors. The *in utero* effect which we observed at 5 months of age might have been caused by abnormalities in conformation at birth which would suggest a role of copper on skeletal conformation *in utero*. In this case, the abnormalities that we scored would have been a result of normal weight bearing on an abnormal conformation. Treatment effects on conformation were not detected on clinical examinations of the foals, but they might not have been sufficiently sensitive. Alternately copper supplementation of the mares might have affected the integrity of the foetal connective tissue matrices and therefore the abnormalities detected might have been due to normal weight bearing forces on structurally weakened tissue. These two possibilities might be associated. Further research is required to determine a mechanism for the effect of supplemental copper on developing connective tissue in the absence of other indices of copper deficiency.

Whether high liver copper stores *in utero* and during the neonatal period play a role in cartilage and bone development is not known. The liver copper concentrations at birth were highly variable but there was no relationship between liver copper concentrations at birth and any evidence of DOD in this study.

Differences between our results and those of Knight *et al.* (1990) and Hurtig *et al.* (1993) are curious. Both these North American studies found considerable differences in lesion severity and frequency between copper-supplemented and control foals. Hurtig *et al.* (1993) even considered that the copper may have been palliative, as a number of the foals were affected with femoropatellar OCD when they started the trial at 3 months of age, but after completion of the trial there was no clinically evident sign of OCD in supplemented animals. Differences between the North American studies and our results may be explained if the North American foals have a greater frequency and severity of DOD due to managemental causes or genetic constitution, which is attenuated by supplemental copper. Alternately, if the level of DOD seen

in the untreated animals is a reflection of inadequate dietary copper, then other dietary factors must either increase the requirement of those foals for copper, or must decrease the bioavailability of copper compared to pasture-fed foals, because our foals with confirmed low dietary copper levels had scant evidence of DOD lesions.

8.6.1 The influence of energy in the copper response experiments

The foals in the study of Hurtig *et al.* (1993) were fed 120 % of NRC recommendations as this was considered to be standard North American management practice at the time (Hurtig *et al.* 1990). These animals were fed controlled diets on dry-lots. The energy intake of our foals on an *ad libitum* pasture-diet was not known. However as discussed in Chapter 6, the liveweight gains of our foals were greater than those of Hurtig *et al.* (1993) as reported by Burton and Hurtig (1991). This may indicate that the energy intake of our foals was at least as high as the North American foals, unless breed differences accounted for large differences in body weight.

The source of energy, rather than just the level of energy intake, may be of importance, and Glade *et al.* (1984) has proposed that soluble carbohydrates may be primarily responsible via a postprandial hyperinsulinaemia, and a consequent transient hypothyroxemia. For example, Glade and Belling (1986) studied the effect of increased intakes of soluble carbohydrates in horses and found histologically evident abnormalities in endochondral ossification and biochemical changes in growth plate cartilage. The issue regarding energy intake/source of energy is largely unresolved as Savage *et al.* (1993a) found an effect of energy (using maize oil) on the incidence of DOD, scored as clinically evident disease as well as gross and histological abnormalities present at postmortem, but not on liveweight or liveweight gain. The increased energy was contributed by complex carbohydrate (maize starch) and lipids (maize oil), which may not have had the same effect on endogenous postprandial hormones, but these were not measured.

8.6.2 The theory of an association between dietary copper requirements and energy source/level

If energy source can explain differences between the incidence and severity of lesions between North American studies and those found in our foals, then it follows that there is a link between dietary copper and energy source/level. The proposal has been studied in humans and rodents because of the concern that Western diets, and especially fast foods, are high in soluble

carbohydrates and low in dietary copper. In addition low copper diets are being investigated as a possible risk factor for human cardiovascular disease (Wapnir and Devas 1995). However the results have been confusing; an effect of soluble carbohydrates versus starch on copper availability has been identified, but seems to be limited to male rats (O'Dell 1990), while other studies have found that in humans, soluble carbohydrates increase copper balance but decrease the activity of the tissue cupro-enzyme Cu-Zn SOD, compared with starch (Lonnerdal 1996). As well high fat diets aggravate the effect of soluble carbohydrates (fructose) on the expression of copper deficiency in rats (Wapnir and Devas 1995).

The practice of meal feedings as opposed to continual grazing may be important in increasing the incidence and severity of DOD, and may support Glade's observations of the involvement of aberrations in normal endogenous hormones associated with feeding. Ralston (1996) has given further support to this by showing that horses affected with OCD had significantly higher postprandial glucose and insulin peaks compared with controls.

8.6.3 The theory of copper as a therapeutic agent

An alternative scenario is that dietary copper might reduce DOD caused by other aetiological factors. This is supported by the normal plasma copper concentration and caeruloplasmin activity in unsupplemented foals with a high incidence of DOD (Hurtig *et al.* 1990). An effect of copper supplementation on tibial dyschondroplasia in birds, in the absence of copper deficiency has been reported (Orth and Cook 1994), and may be due to the complexing of other dietary aetiological agents, reducing their absorption. Similarly in horses and other species in which there are anecdotal or reported observations of clinical responses of DOD in some animals to supplementary copper, a mechanism other than a primary copper deficiency cannot be excluded. For example Davies *et al.* (1996) found a direct effect of copper on the connective tissue matrix *in vitro*, including increased proteoglycan production and decreased production of cartilage degrading enzymes.

A response in foals to copper supplementation without being copper deficient would be analogous to the situation where zinc is fed to sheep for the prevention of facial eczema despite no nutritional deficiency of zinc existing in these animals. The zinc ameliorates the effect of the mycotoxin sporidesmin. Based on these examples, the definition of adequate copper status may need to take into account a possible pharmacological effect of supplementation on animal

performance and health especially in cases where other indices of deficiency can not be demonstrated.

8.7 Molybdenum as a copper antagonist for pasture-fed horses

Molybdenum has been largely discarded as a possible copper antagonist in equine nutrition following the study of Strickland *et al.* (1987) in which it was found that oral aqueous sodium molybdate was rapidly absorbed from the small intestine and excreted in the urine. There was no effect on the measured copper status indices and it was concluded that there was little opportunity for the formation of thiomolybdates in the hindgut, and that any thiomolybdates formed were not interfering significantly with copper absorption. Another study found that molybdenum significantly affected indices of copper status, including a decrease in copper balance in ponies fed molybdenum for short periods (Cymbaluk *et al.* 1981b).

We hypothesised that molybdenum incorporated in forage plants might be less readily absorbed because of its association with plant constituents, allowing greater quantities of molybdenum to reach the hindgut for the formation of thiomolybdates which once absorbed may interfere with tissue copper metabolism. The treated pasture contained 8 to 15 mg Mo/kg DM, and was considered very high but within possible pasture concentrations in certain situations (Grace 1983b). At these concentrations we were unable to observe any effect on indices of copper status including plasma copper concentration, blood cell copper concentration, TCA insoluble plasma copper concentration, caeruloplasmin activity, superoxide dismutase activity and liver copper concentration. This does not preclude higher concentrations of pasture molybdenum from inducing a copper deficiency, but it rules out molybdenum as being a likely cause for increased copper requirements of horses raised on New Zealand pasture.

8.8 Recommendations to the New Zealand Thoroughbred Industry

At present we have little evidence to support recommendations, based on North American studies, to supplement pasture-based diets with copper for nursing animals (up to 5 months of age). However, the effect of copper supplementation of the mare on DOD lesions in the foal may reflect an increased requirement of copper in mares during gestation. Although the bone and cartilage lesions found may be considered minor, the possibility of their becoming clinically significant could not be excluded, and thus supplementation of the mare is justified.

Our postmortem findings did not reflect the degree of industry concern regarding DOD. This is likely to be due to the stage at which the lesions were examined, and to unknown factors that control the expression of the disease, which resulted in evidence of very mild DOD lesions on our research farm yet severe, clinically evident DOD elsewhere. The incorporation of zinc and selenium in the supplement used in the main experimental work may have contributed to the low incidence encountered. However it is clear from these studies, that a dietary copper intake between 4.4 to 8.6 mg Cu/kg DM, low by most standards, for growing foals up to 5 months of age, is not an important factor in the expression of DOD. This may be due to the absence of dietary constituents that antagonise copper bioavailability on this farm.

From our findings of the influence of copper supplementation of mares on the radiological and postmortem evidence of mild DOD in foals, copper supplementation can be recommended, especially on farms suffering significant incidence and severity of DOD. In this respect, supplementation of mares appears to be an appropriate way of increasing the copper status of the foetus and the neonate.

8.9 Further research

These studies raised a number of questions including the need to study further aspects of copper metabolism and its role in the aetiology of DOD.

1. Measure indices of copper status in copper depleted animals to determine the relationship of changes in dietary copper intake and blood and liver copper concentration at which various cupro-enzymes (especially lysyl oxidase) become limiting.
2. Determine the size, fate, and rate of depletion of liver copper stores in neonates, and the impact of these copper stores on copper metabolism of the neonate.
3. Determine factors affecting copper bioavailability in horses (iron, energy source, others not yet identified).
4. Develop a long term remedy for copper deficiency based on depot copper administration.
5. Determine the prevalence of DOD in New Zealand and develop detailed case descriptions.

6. Evaluate the effect of copper supplementation on farms suffering a high incidence and severity of DOD and develop a model of copper responsive DOD (identify a farm).

7. Investigate the mechanism of action of copper supplementation in cases of copper responsive DOD.

Appendices

Appendix A: Pilot Studies on Circulating Copper Indices.

General introduction

Prior to the commencement of the main project, a small pilot project was carried out to develop techniques and evaluate procedures. These covered the measurement of plasma copper concentration and caeruloplasmin activity, and the development of techniques for sampling liver tissue and growth plate tissue *in vivo*. The liver and growth plate biopsy techniques are described in Chapter 2 and 3. This chapter describes three pilot trials: a spike trial, a copper dose response trial and a trial investigating the effect of surgery on plasma copper concentrations.

Spike Trial

Introduction

The literature is ambiguous as to whether dietary copper intake influences blood indices of copper status. Changes in dietary copper levels had no influence on serum copper concentration in some trials (Smith *et al.* 1975; Hurtig *et al.* 1990), while some authors consider that variations in serum and plasma copper concentrations between horses from different stables, and in different seasons are most likely due to changes in dietary copper intake (Stubley *et al.* 1983; Auer *et al.* 1988a).

Therefore, for the present study, it was important to accurately characterise the copper status of both control horses and horses receiving oral copper supplementation. If oral copper supplementation resulted in a transient increase in plasma copper concentration and caeruloplasmin oxidase activity, then the time of sampling following supplementation could influence the value of these indices. Thus this study investigated the nature of any rise in circulating copper indices following a single large dose of oral copper sulphate.

Materials and methods

Eight mature mares in the second trimester of gestation were randomly divided into copper supplemented and control groups based on age and date of last service. All animals were kept in a small paddock and fed pasture for the duration of the trial.

Copper supplemented animals received 500 mg of copper sulphate given per os using a drench gun. Control groups received a water placebo of equivalent fluid volume.

Animals were sampled by jugular venepuncture, and the blood was collected into blue top sodium heparin trace element tubes (Becton Dickinson # 367735). Tubes were placed on ice for transport to the laboratory. Plasma was then separated and the sample split for analysis of plasma copper concentration and caeruloplasmin oxidase activity. Plasma copper concentration was analysed by inductively coupled plasma emission spectrometry (Lee 1983), and caeruloplasmin oxidase activity was analysed by the colorimetric measurement of the oxidation of the substrate *p*-phenylenediamine (Ravin 1961).

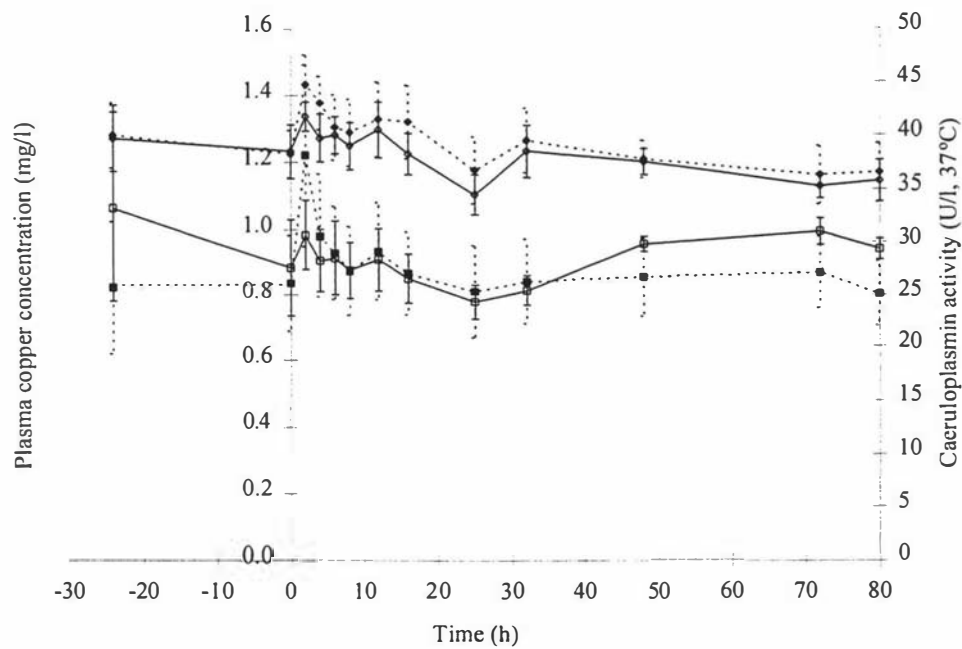
Samples were collected at -24, 0, 2, 4, 6, 8, 12, 16, 25, 32, 48, 72 and 80 hours after oral supplementation. All samples were analysed as one batch.

The results were analysed by analysis of variation with repeated measures on time to test for a significant effect of treatment, and changes with time. Analyses were performed using Statistical Analysis System (SAS) version 6.11 for windows (SAS Institute Inc., Cary, N.C., USA).

Results and discussion

There was no significant effect of time or copper supplementation on the plasma copper concentration or caeruloplasmin activity (Figure A1).

Figure A1 Mean plasma copper concentration (boxes) and caeruloplasmin activity (diamonds) of mares receiving a single dose of copper sulphate (500 mg) on day 0 (complete lines), and controls (incomplete lines).



There was a remarkable similarity in the trends in the plasma copper concentration and caeruloplasmin activity of both control and supplemented horses.

Figure A2 and A3 shows the pattern of change of the individual animals plasma copper concentration and caeruloplasmin activity. All animals had a peak in caeruloplasmin at the 2 hour sample and a trough at the 25 hour sample, with another smaller peak at the 32 hour sample.

Figure A2 Plasma copper concentration of individual mares receiving a single dose of copper sulphate (500 mg) on day 0 (complete lines, open boxes), and controls (incomplete lines, closed boxes).

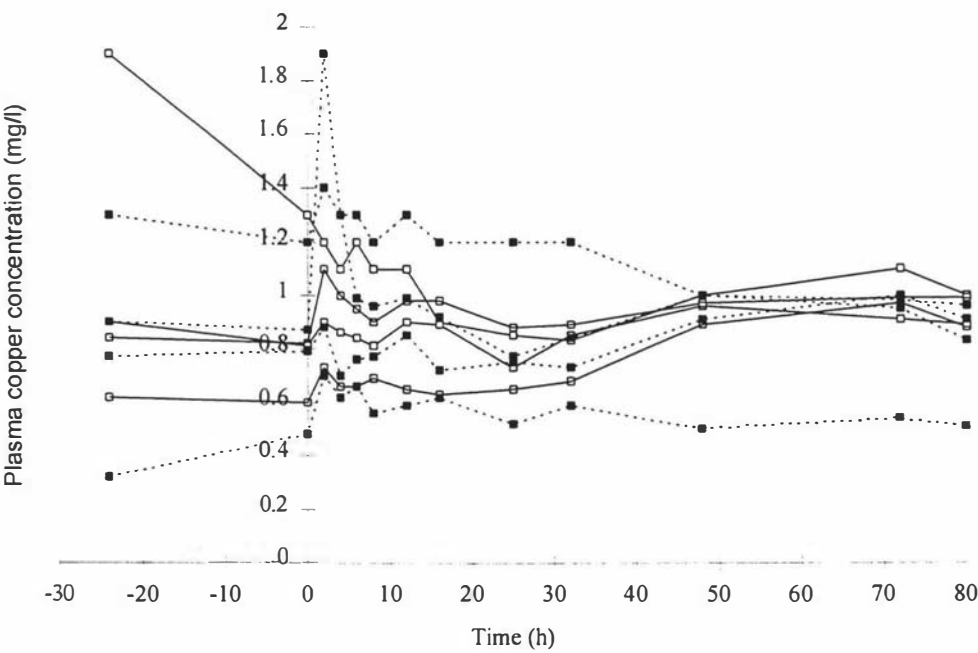
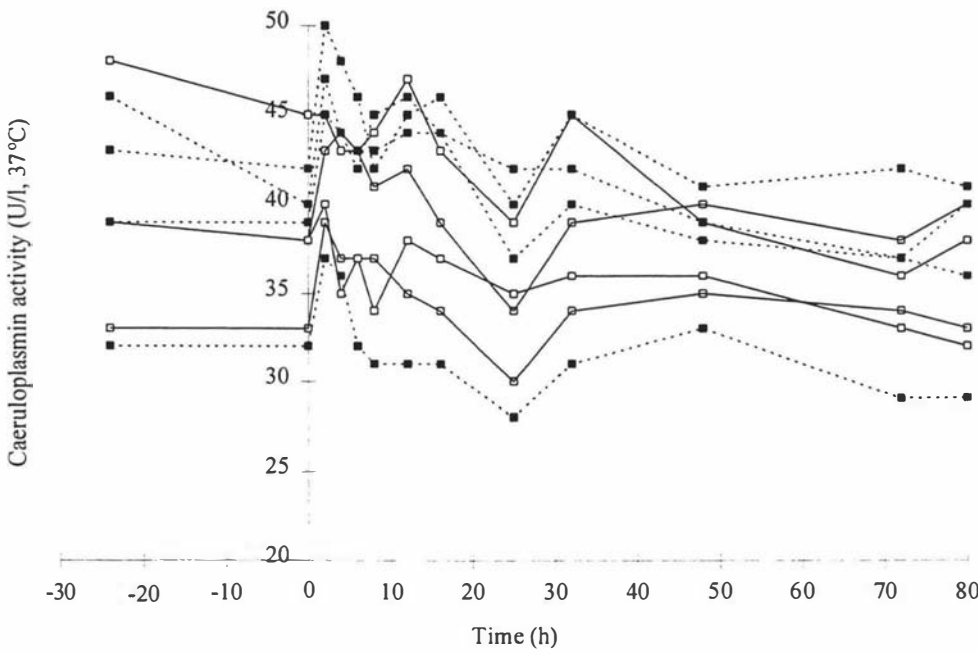


Figure A3 Caeruloplasmin activity of individual mares receiving a single dose of copper sulphate (500 mg) on day 0 (complete lines, open boxes), and controls (incomplete lines, closed boxes).



Plasma copper concentration shows a similar pattern of change, but with greater variability between individuals. This pattern of change is unlikely to be explained by a diurnal effect as the peak at 2 hours is only one hour different when corrected for the time of day with the trough at the 25 hour sample. It is also clearly not related to dietary copper intake as both controls and supplemented mares showed the same pattern of change, with the greatest peak occurring in the control mares. It is possible that the peak at the 2 hour sample was related to the stress involved with yarding, drenching and bleeding the mares. Copper and caeruloplasmin activity has been shown to increase in horses in response to inflammatory stimuli (Firth *et al.* 1987; Smith and Cipriano 1987). However, Auer *et al.* (1989a) found that caeruloplasmin activity peaked after 24 days and was still significantly elevated after 50 days, but the inflammatory stimuli used in that study (intramuscular injection of Freund's adjuvant) was far more severe than the stimuli in the present project. These transient changes in circulating indices, which are consistent between animals, are discussed further in Chapter 7.

The ranking of the individuals with respect to their plasma copper indices, stayed reasonably consistent throughout the trial. This indicates that individuals may have different homeostatic levels, possibly under strong genetic control.

There also appeared to be a good relationship between plasma copper concentration and caeruloplasmin activity. This relationship is further explored in Chapter 5.

Time of sampling after oral copper supplementation is unlikely to bias plasma copper concentration and caeruloplasmin activity data collected to determine copper status of horses. There was no effect of supplementation, and despite significant changes between sampling occasions, all individuals showed similar changes.

Copper Dose Response

Introduction

Danks (1981) proposed that a useful way of diagnosing dietary copper adequacy was to measure caeruloplasmin activity, then supplement the diet with copper and remeasure the caeruloplasmin activity. If the caeruloplasmin activity increased, the initial diet was inadequate in dietary copper. According to Matusda *et al.* (1974), the resultant increase in caeruloplasmin activity after copper supplementation of copper-deficient humans begins after 4 hours and is at a maximum 2 days following supplementation. In copper deficient rats, restoration of caeruloplasmin activity occurred 6 to 8 hours after intubation and 14 to 16 hours after feeding supplementary copper sulphate (Linder *et al.* 1979).

Neifakh *et al.* (1969) found that excessive supplementation of copper (parenterally) in monkeys resulted in an inhibition of caeruloplasmin activity.

It has been suggested that dietary copper levels of 8 to 15 mg Cu/kg DM, which is in the high range of pasture copper concentrations, is not adequate for growing horses (Knight *et al.* 1990; Hurtig *et al.* 1993). Burton *et al.* (1990) found that caeruloplasmin activity reflected copper intake in pregnant and barren mares at dietary copper concentrations of 4, 10, 20 and 30 mg Cu/kg. Caeruloplasmin activity was suppressed at the higher dietary copper concentrations.

The objective of this trial was to feed horses on different planes of dietary copper and to measure any changes in plasma copper concentration and caeruloplasmin activity, to ensure that the copper supplemented horses in the experimental part of this thesis received adequate copper supplementation for maximum cuproenzyme activity, but not an excessive amount.

Materials and methods

Nineteen mature Thoroughbred mares in the second trimester of gestation were randomly assigned to one of ten dietary copper supplementation levels (0, 50, 100, 150, 200, 250, 300, 350, 400, and 500 mg Cu/day). Two horses received each dose, except only one horse received 350 mg Cu/day.

Horses were grazing pasture containing approximately 7 mg Cu/kg DM throughout the trial. Assuming a dietary dry matter intake of 14 kg/day, the dietary copper intake from the pasture would be about 100 mg/day.

Horses were supplemented daily for 4 days by oral drenching. Blood samples were collected on day 0, before the first supplementation and then daily for a further 4 days. The samples were collected and analysed as described for the previous trial. Samples were taken at approximately the same time each day, and before copper supplementation on that day.

Samples were analysed by analysis of variance with repeated measures over time. The effect of treatment level, and of time were investigated. Analyses were performed using SAS as above.

Results and discussion

A family of curves for the plasma copper concentration and caeruloplasmin activity were created for each level of treatment group and are presented as 3 dimensional surfaces in Figures A4 and A5. Mean values were taken for each treatment level. Standard errors are not presented.

Figure A4 Plasma copper concentration of pasture-fed pregnant mares receiving different levels of copper supplementation.

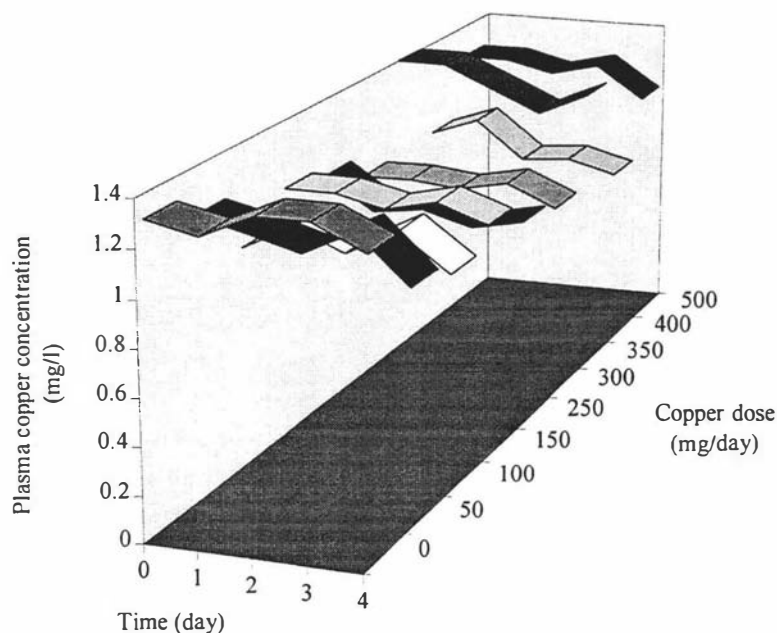
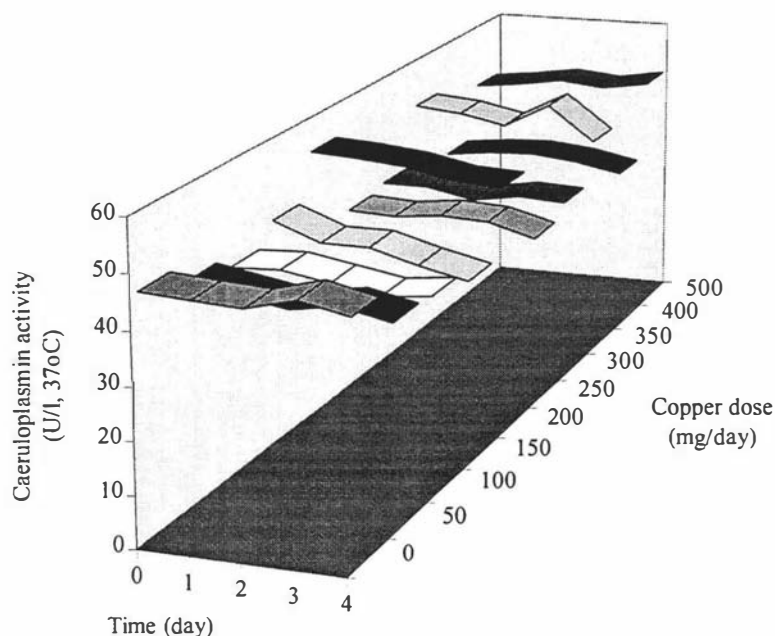


Figure A5 Caeruloplasmin activity of pasture-fed pregnant mares receiving different levels of copper supplementation.



There was no significant effect of the level of copper supplementation, or on the time after copper supplementation on either plasma copper concentration or caeruloplasmin activity.

This indicates that the mares in their second month of gestation and grazing pasture are receiving adequate copper for optimal caeruloplasmin activity. In addition, assuming the proposal of Danks (1981) is valid for pregnant mares, pasture provides adequate dietary copper for mares in their second trimester of gestation. However, the requirements for copper may increase in the third trimester and also for foals experiencing high growth rates.

This trial did not corroborate the findings of Burton *et al.* (1990), in that caeruloplasmin activity did not reflect dietary copper intake and we failed to demonstrate any adverse effect of excessive copper supplementation on caeruloplasmin activity. This supports previous work which found a resistance of horses to copper toxicity on very high dietary copper intakes (Smith *et al.* 1975).

The Effect of Surgery

Introduction

Neonatal foals in the experimental work of this thesis underwent growth plate and laparoscopic liver biopsies under general anaesthesia as described in Chapters 2 and 3.

Inflammatory procedures increase plasma copper concentration (Firth *et al.* 1987; Smith and Cipriano 1987; Auer *et al.* 1989a). The objective of this trial was to define the effects of the surgical procedures (described in Chapters 2 and 3) in terms of post-operative changes to plasma copper concentration.

Materials and methods

Two nursing foals aged approximately 3 months of age underwent growth plate and laparoscopic liver biopsies under general anaesthesia for the purpose of technique development. The foals and their dams were confined to stalls following the surgery for the duration of this trial. Blood was collected and analysed for plasma copper concentration as described in the pilot trials above.

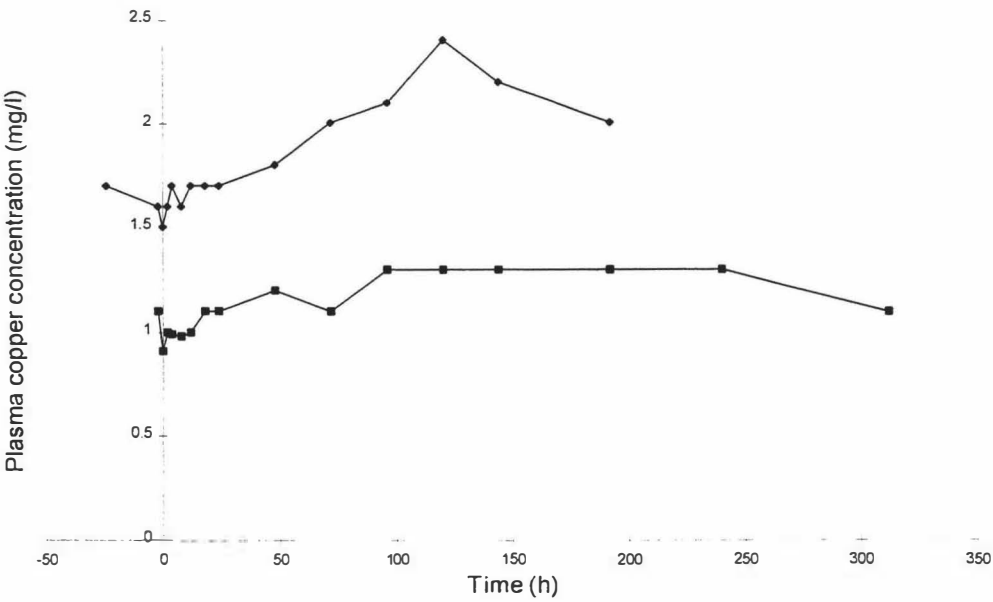
No statistical analyses were performed due to the small number of animals and lack of controls.

Results and discussion

There were no control foals, and the two foals were operated on different occasions. Therefore there was no way of confirming that any changes to blood copper concentration were due to the surgical procedures. Therefore the results were interpreted cautiously, and were used only to describe the changes observed following the surgical procedures.

The plasma copper concentration of one foal increased for 5 days following the surgical procedures, and then declined. The plasma copper concentration of the second foals showed a smaller increase in plasma copper which plateaued for approximately 10 days following surgery (Figure A6).

Figure A6 Plasma copper concentration of two foals following laparoscopic liver biopsy and growth plate biopsy performed under general anaesthesia.



There was a considerable difference between the two individuals in the response of their plasma copper concentrations following the surgical procedures. This may reflect a difference in the foals response to inflammation, their previous copper status, or differences in the amount of surgical inflammation between the two procedures. Auer (1989a) reported that changes to plasma copper concentrations were a good measure of the degree of inflammation, and that the decrease in the elevated plasma copper concentration may be useful in monitoring the resolution of an inflammatory processes.

Four mature horses in the study of Auer *et al.* (1989a) received intramuscular injections with Freund's adjuvant. Their mean plasma copper concentration rose from approximately 1.2 mg Cu/l to peak after 24 days at approximately 2.3 mg Cu/l. The mean plasma copper concentration was still significantly elevated after 36 days.

The resolution of the increase in plasma copper over a relatively short period indicates that the surgical procedures performed were not highly inflammatory stimuli. However the age of the foals in this pilot trial were older than the age of the foals undergoing these surgical procedures in the experimental work of this thesis.

General conclusion of pilot trials

Plasma copper concentration and caeruloplasmin activity have a wide variation between samples which is not able to be explained by dietary copper intake, and is consistent between animals. There appear to be similarities in the changes in plasma copper and caeruloplasmin activity most likely due to the large percentage (73 %) of circulating copper that is bound to caeruloplasmin (Auer 1988b).

There is no evidence from circulating plasma copper status indices of an inadequacy of dietary copper in pasture-fed mares in their second semester of gestation. Hurtig *et al.* (1990, 1993) also found no difference between copper supplemented and control foals in their serum copper concentrations or caeruloplasmin activity despite increased bone and cartilage lesions in control foals.

Surgery and other inflammatory procedures are likely to influence circulating copper status indices. However in the main experimental work of this thesis, all foals were supplemented, and therefore surgery should not affect the comparison in copper status between copper-supplemented and control foals.

References

- Alvarado AF, Marcoux M, Breton L (1989) The incidence of osteochondrosis on a Standardbred breeding farm in Quebec. *Proc Am Assoc Equine Pract* **35**, 293-307.
- Anonymous (1978) Equine Genetics and Selection Procedures. Wagoner DM (ed). Equine Research Publication, Dallas.
- Aoyagi S, Baker DH (1994) Copper-amino acid complexes are partially protected against inhibitory effects of L-cysteine and L-ascorbic acid on copper absorption in chicks. *J Nutr* **124**, 388-395.
- Asai Y, Mizuno Y, Yamamoto O, Fujikawa H (1993) Requirements of copper and zinc for foals in connection with the incidence of epiphysitis. *Anim Sci Tech* **64**, 1193-1200.
- Asai Y, Katsuki R, Matsui A, Nanbo Y (1995) Effects of rations and age on mineral concentrations of thoroughbred mare's colostrum. *J Equine Sci* **6**, 21-24.
- Ashmead HD, Graff DJ, Ashmead HH (1985) Intestinal absorption of metal ions and chelates. Charles C Thomas, Springfield, USA.
- Auer DE, Ng JC, Steele DP, Seawright AA (1988a) Monthly variation in the plasma copper and zinc concentration of pregnant and non-pregnant mares. *Aust Vet J* **65**, 61-62.
- Auer DE, Ng JC, Seawright AA (1988b) Assessment of copper and zinc status of farm horses and training Thoroughbreds in South-East Queensland. *Aust Vet J* **65**, 317-320.
- Auer DE, Ng JC, Thompson HL, Inglis S, Seawright AA (1989a) Acute phase response in horses: changes in plasma cation concentrations after localised tissue injury. *Vet Rec* **124**, 235-239.
- Auer DE, Ng JC, Seawright AA (1989b) A suspected case of acute copper toxicity in a horse. *Aust Vet J* **66**, 191-192.
- Auer DE, Ng JC, Seawright AA (1990) Copper salicylate and copper phenylbutazone as topically applied anti-inflammatory agents in the rat and horse. *J Vet Pharmacol Therap* **13**, 67-75.

Auer JA, Martens RJ, Morris EL (1982) Angular limb deformities in foals part I. congenital factors. *Compend Contin Educ Pract Vet* **4**, S330-S338.

Auer JA, Martens RJ, Morris EL (1983) Angular limb deformities in foals part II. developmental factors. *Compend Contin Educ Pract Vet* **5**, S27-S35.

Baker DH, Ammerman CB (1995) Copper bioavailability. In: Ammerman CB, Baker DH, Lewis AJ (eds) *Bioavailability of Nutrients for Animals*. Academic Press, San Diego. pp 127-155.

Baker DH, Czarnecki-Maulden GL (1987) Pharmacologic role of cysteine in ameliorating or exacerbating mineral toxicities. *J Nutr* **117**, 1003-1010.

Barclay SM, Aggett PJ, Lloyd DJ, Duffy P (1991) Reduced erythrocyte superoxide dismutase activity in low birth weight infants given iron supplements. *Pediatr Res* **29**, 297-301.

Barry TN, Millar KR, Bond G, Duncan SJ (1983) Copper metabolism in growing sheep given kale (*Brassica oleracea*) and ryegrass (*Lolium perenne*)-clover (*Trifolium repens*) fresh forage diets. *Br J Nutr* **50**, 281-289.

Baucus KL, Ralston SL, Rich GA, Squires EL (1989) The effect of copper and zinc supplementation on mineral content of mare's milk. *Equine Vet Sci* **9**, 206-209.

Bauer M (1975) Copper sulfate poisoning in horses. *Vet Archiv* **45**, 257.

Baxter GM (1996) Subchondral cystic lesions in horses. In McIlwraith CW, Trotter GW (eds) *Joint Disease in the Horse*. WB Saunders Company, Philadelphia. pp 384-397.

Bearn AG, Kunkel HG (1955) Metabolism studies in Wilson's disease using ⁶⁴Cu. *J Lab Clin Med* **45**, 623-631.

Beckman JS, Minor RL, White CW, et al. (1988) Superoxide dismutase and catalase conjugated to polyethylene glycol increases endothelial enzyme activity and oxidant resistance. *J Biol Chem* **263**, 6884-6892.

Beeman GM, McIlwraith CW (1986) Summary of panel findings. In: McIlwraith CW (ed) AQHA Developmental Orthopaedic Disease Symposium. American Quarter Horse Association, Amarillo. pp 55-63.

Bell JU, Lopez JM, Bartos KD (1987) The postnatal development of serum zinc, copper and ceruloplasmin in the horse. *Comp Biochem Physiol* **87A**, 561-564.

Belling TH, Glade MJ (1984) A nondestructive biopsy method allowing the rapid removal of live growth-plate cartilage. *Vet Med* 528-531.

Bertone AL, van Soest PJ, Stashak TS (1989) Digestion, fecal, and blood variables associated with extensive large colon resection in the horse. *Am J Vet Res* **50**, 253-258.

Bettger WJ, Fish TJ, O'Dell BL (1978) Effects of copper and zinc status of rats on erythrocyte stability and superoxide dismutase activity. *Proc Soc Exp Biol Med* **158**, 279-282.

Bingley JB, Dick AT (1969) The pH optimum for ceruloplasmin oxidase activity in the plasma of several species of animal. *Clin Chim Acta* **25**, 480-482.

Borton JW, Borton A, Hintz HF, Van Vleck LD (1979) *The Horse*. WH Freeman and Company, San Francisco.

Breedveld L, Jackson SG, Baker JP, (1988) The determination of a relationship between the copper, zinc and selenium levels in mares and those in their foals. *Equine Vet Sci* **9**, 206-209.

Bremner I (1987) Interactions between metallothionein and trace elements. *Prog Food Nutr Sci* **2**, 1-37.

Bremner I (1991) Metallothionein and copper metabolism in the liver. *Methods Enzymol* **205**, 584-591.

Bridewell S (1993) *An Investigation into the Valuation of Thoroughbred Stallions in New Zealand*. Masterate thesis, Massey University, Palmerston North, New Zealand.

- Bridges CH, Harris ED (1988) Cartilaginous fractures ("osteochondritis dissecans") induced experimentally in foals with low copper diets. *J Am Vet Med Assoc* **193**, 215-221.
- Bridges CH, Moffitt PG (1990) Influence of variable content of dietary zinc on copper metabolism of weanling foals. *Am J Vet Res* **51**, 275-280.
- Bridges CH, Womack JE, Harris ED (1984) Considerations of copper metabolism in osteochondrosis of suckling foals. *J Am Vet Med Assoc* **185**, 173-178.
- Brighton CT (1978) Structure and function of the growth plate. *Clin Orthop Rel Res* **136**, 22-32.
- Brown MP, MacCallum FJ (1976) Observations on growth plates in limbs of foals. *Vet Rec* **98**, 443-446.
- Burton JH, Hurtig MB (1991) Dietary copper intake and bone lesions in foals. *Proc Symp Equine Nutr Phys* **12**, 67-68.
- Burton JH, DeMontigny LS, Hurtig MB (1990) Copper concentrations in horse diets. *Can J Anim Sci* **70**, 1188.
- Butler EJ (1963) The influence of pregnancy on the blood, plasma and caeruloplasmin copper levels of sheep. *Comp Biochem Physiol* **9**, 1-12.
- Byars TD (1987) Chronic liver disease. In: Robinson NE (ed) *Current Therapy in Equine Medicine* 2nd Edn. WB Saunders Company, Philadelphia. pp 112-113.
- Campbell-Beggs CL, Johnson PJ, Messer NT, et al. (1994) Osteochondritis dissecans in an Appaloosa foal associated with zinc toxicosis. *J Equine Vet Sci* **14**, 546-550.
- Cape L, Hintz HF (1982) Influence of month, colour, age, corticosteroids, and dietary molybdenum on mineral concentration of equine hair. *Am J Vet Res* **43**, 1132-1136.
- Carberry JT (1978) Osteodysgenesis in a foal associated with copper deficiency. *NZ Vet J* **26**, 279-280.

Carlson CS, Cullins LD, Meutens DJ (1995) Osteochondrosis of the articular-epiphyseal cartilage complex in young horses: evidence for a defect in cartilage canal blood supply. *Vet Pathol* **32**, 641-647.

Carlson CS, Hilley HD, Henrickson CK, Meutens DJ (1986) The ultrastructure of osteochondrosis of the articular-epiphyseal cartilage complex in growing swine. *Calcif Tiss Int* **38**, 44-51.

Carlson CS, Hilley HD, Meutens DJ, et al. (1988) Effect of reduced growth rate on the prevalence and severity of osteochondrosis in gilts. *Am J Vet Res* **49**, 396-402.

Carlson CS, Hilley HD, Meutens DJ (1989) Degeneration of cartilage canal vessels associated with lesions of osteochondrosis in swine. *Vet Pathol* **26**, 47-54.

Carlsten J, Sandgren B, Dalin G (1993) Development of osteochondrosis in the tarsocrural joint and osteochondral fragments in the fetlock joints of standardbred trotters: I. A radiological study. *Equine Vet J Suppl* **16**, 42-47.

Carr G, Wilkinson AW (1975) Zinc and copper urinary excretion in children with burns and scalds. *Clin Chim Acta* **61**, 199-204.

Cavell PA, Widdowson EM (1964) Intakes and excretions of iron, copper, and zinc in the neonatal period. *Arch Dis Child* **39**, 496-501.

Chang IC, Lee TP, Matrone G (1975) Development of ceruloplasmin in pigs during the neonatal period. *J Nutr* **105**, 624-630.

Chapman HL, Cox DH, Haines CE, Davis GK (1963) Evaluation of the liver biopsy technique for mineral nutrition studies with beef cattle. *J Anim Sci* **22**, 733-737.

Claypool DW, Adams FW, Pendell HW, et al. (1975) Relationship between the level of copper in the blood plasma and liver of cattle. *J Anim Sci* **41**, 911-914.

- Coger LS, Hintz HF, Schryver HF, Lowe JE (1987) The effect of high zinc intake on copper metabolism and bone development in growing horses. *Proc Equine Nutr Physiol Symp* **10**, 173-177.
- Cohen NL, Illowsky B, Linder MC (1979) Altered copper absorption in tumour bearing and estrogen treated rats. *Am J Physiol* **236**, E309-E315.
- Corbellini CN, Krook L, Nathanielsz PW, Kallfelz FA (1991) Osteochondrosis in fetuses of ewes overfed calcium. *Calcif Tiss Int* **48**, 37-45.
- Cowgill VM, States SJ, Marburged JE (1980) Smelter smoke syndrome in farm animals and manganese deficiency in Northern Oklahoma USA. *Environ Pollution (Series A)* **22**, 259-271.
- Craig E (1981) Autogenous fat grafts to prevent recurrence following surgical correction of growth deformities of the radius and ulna in the dog. *Vet Surg* **10**, 69-73.
- Cunningham IJ, Perrin (1946) Copper compounds as fertilisers for pastures deficient in copper. *NZ J Sci Tech* **28**, 252-265.
- Cunningham IJ, Hogan KG, Breen JN (1956) The copper and molybdenum contents of pastures grown on the different soils of New Zealand. *NZ J Sci Tech* **38A**, 225-
- Cupps PJ, Howell CE (1949) The effects of feeding supplemental copper to growing foals. *J Anim Sci* **8**, 286-289.
- Cymbaluk NF, Christensen DA (1986) Copper, zinc and manganese concentrations in equine liver, kidney and plasma. *Can Vet J* **27**, 206-210.
- Cymbaluk NF, Smart ME (1993) A review of possible metabolic relationships of copper to equine bone disease. *Equine Vet J Suppl* **16**, 19-26.
- Cymbaluk NF, Schryver HF, Hintz HF (1981a) Copper metabolism and requirement in mature ponies. *J Nutr* **111**, 87-95.

Cymbaluk NF, Schryver HF, Hintz HF, et al. (1981b) Influence of dietary molybdenum on copper metabolism in ponies. *J Nutr* **111**, 96-106.

Da Costa Ferreira AM, Ciriolo MR, Marcocci L, Rotilio G (1993) Copper (I) transfer into metallothionein mediated by glutathione. *Biochem J* **191**, 673-676.

Dammrich K (1991) Relationship between nutrition and bone growth in large and giant dogs. *J Nutr* **121**, S114-S121.

Danks DM (1981) Diagnosis of trace metal deficiency-with emphasis on copper and zinc. *Am J Clin Nutr* **34**, 278-280.

Danks DM (1988) Copper deficiency in humans. *Annu Rev Nutr* **8**, 235-257.

Danks DM (1995) Disorders of copper transport. In: Scriver CL, Beaudet AL, Sly WS, Valle D (eds) *The Metabolic and Molecular Bases of Inherited Disease*. McGraw-Hill, New York. pp 2211-2235.

Dauncey MJ, Shaw JCL, Urman J (1977) The absorption and retention of magnesium, zinc and copper by low birth weight infants fed pasteurized human breast milk. *Pediatr Res* **11**, 991-997.

Davies ME, Pasqualicchio M, Henson F, Hernandez-Vidal G (1996) Effects of copper and zinc on chondrocyte behaviour and matrix turnover. *Pferdheilkunde* **12**, 367-370.

Davies NT, Nightingale R (1975) The effect of phytate on intestinal absorption and secretion of zinc, and whole-body retention of zinc, copper, iron, and manganese in rats. *Br J Nutr* **34**, 243-258.

Davies NT, Williams RB (1976) The effects of pregnancy on uptake and distribution of copper in the rat. *Nutr Soc Proc* **35**, 4A-5A.

de Haan JB, Cristiano F, Ianello R, et al. (1996) Elevation in the ratio of Cu/Zn-superoxide dismutase to glutathione peroxidase activity induces features of cellular senescence and this effect is mediated by hydrogen peroxide. *Human Mol Gen* **5**, 283-292.

Deane NJ, Davies AS (1995) The function of the equine carpal joint: A review. *NZ Vet J* **43**, 45-47.

Di Silvestro RA, Harris ED (1981) A postabsorption effect of L-ascorbic acid on copper metabolism in chicks. *J Nutr* **111**, 1964-1968.

Dick AT, Dewey DW, Gawthorne JM (1975) Thiomolybdates and the copper-molybdenum-sulphur interaction in ruminant nutrition. *J Agric Sci Camb* **85**, 567-568.

Donawick WJ, Mayhew I, Galligan DT, et al. (1989) Early diagnosis of cervical vertebral malformation in young Thoroughbred horses and successful treatment with restricted, paced diet and confinement. *Proc Am Assoc Equine Pract* **35**, 525-528.

Donohue MJ, Buss D, Oegena TR, et al. (1983) The effects of indirect blunt trauma on adult canine articular cartilage. *J Bone Joint Surg [Am]* **65**, 948-957.

Du Z, Hemken RW, Jackson JA, Trammell DS (1996) Utilization of copper in copper proteinate, copper lysine, and cupric sulphate using the rat as an experimental model. *J Anim Sci* **74**, 1657-1663.

Duff SRI (1986) Morphological and radiological findings in induced abnormal bone growth in lambs. *J Comp Path* **96**, 3-13.

Dyce KM, Sack WO, Wensing CJG (1987) Textbook of Veterinary Anatomy. WB Saunders Company, Philadelphia.

Eamens GJ, Macadam JF, Laing EA (1984) Skeletal abnormalities in young horses associated with zinc toxicity and hypocuprosis. *Aust Vet J* **61**, 205-207.

Edwards EH (1980) A standard guide to horse and pony breeds, Trewin Copplestone publishing Ltd., London.

Egan DA, Murrin MP (1973a) Copper-responsive osteodysgenesis in a Thoroughbred foal. *Ir Vet J* **27**, 61-62.

Egan DA, Murrin MP (1973b) Copper concentration and distribution in the livers of equine fetuses, neonates and foals. *Res Vet Sci* **15**, 147-148.

Ekman S, Ridderstrale Y (1992) Carbonic anhydrase localization in normal and osteochondrotic joint cartilage of growing pigs. *Vet Pathol* **29**, 308-315.

Evans GW (1973) Copper homeostasis in the mammalian system. *Physiol Rev* **53**, 535-570.

Farnum CE, Wilsman NJ (1986) Ultrastructure histochemical evaluation of growth plate cartilage matrix from healthy and osteochondrotic swine. *Am J Vet Res* **47**, 1105-1115.

Fell BF, Mills CF, Boyne R (1965) Cytochrome oxidase deficiency in the motor neurones of copper-deficient lambs: a histochemical study. *Res Vet Sci* **6**, 170-177.

Fields M, Ferreti RJ, Smith JC, Reiser S (1984) The interaction of type of dietary carbohydrates with copper deficiency. *Am J Clin Nutr* **39**, 289-295.

Fio L (1995) Equine laparoscopy. *J Equine Vet Sci* **15**, 218-219.

Firth EC (1990) Physitis. In: White NA, Moore JN (eds) *Current Practice of Equine Surgery*. JB Lippincott Company, Philadelphia. pp 534-536.

Firth EC, Goedegebuure SA (1988) The site of focal osteomyelitis lesions in foals. *Vet Quarterly* **10**, 99-108.

Firth EC, Hartman W (1983) An *in vitro* study on joint fitting and cartilage thickness in the radiocarpal joint of foals. *Res Vet Sci* **34**, 320-326.

Firth EC, Poulos PW (1983) Microangiographic studies of metaphyseal vessels in young foals. *Res Vet Sci* **34**, 231-235.

Firth EC, Poulos PW (1984) Retained cartilage in the distal radial physis of foals. *Vet Pathol* **21**, 10-17.

Firth EC, Schamhardt HC, Hartman W (1988) Measurements of bone strain in foals with altered foot balance. *Am J Vet Res* **49**, 261-265.

Firth EC, Wensing T, Seuren F (1987) An induced synovitis disease model in ponies. *Cornell Vet* **77**, 107-118.

Fischer AT (1991) Standing laparoscopic surgery. *Vet Clin North Am* **7**, 641-647.

Fisher PWF, L'Abbe MR, Giroux A (1990) Effects of age, smoking, drinking, exercise and oestrogen use on indices of copper status in healthy adults. *Nutr Res* **10**, 1081-1090.

Franco L, Velo GP (1995) Eicosanoid and gastroprotection by copper derivatives and NDGA. *Inflamm Res* **44**, 139-142.

Freedman JH, Peisach J (1989) Intracellular copper transport in cultured hepatoma cells. *Biochem Biophys Res Commun* **164**, 134-140.

Fretz PB (1982) Angular limb deformities in foals. *Vet Clin Nth Am* **2**, 125-150.

Fujikawa H, Asai Y, Mizuno Y, Yamamoto O (1993) The survey of calcium, copper and zinc contents in the pasture grass and epiphysitis of foals on breeding farms. *Bull Equine Res Inst* **30**, 1-4.

Fulton IC, Brown CM, Yamini B (1990) Adenocarcinoma of intestinal origin in a horse: diagnosis by abdominocentesis and laparoscopy. *Equine Vet J* **22**, 447-448.

Gabel AA (1988) Metabolic bone disease: problems of terminology. *Equine Vet J* **20**, 4-6.

Gabel AA, Knight DA, Reed SM, et al. (1987) Comparison of incidence and severity of developmental orthopaedic disease on 17 farms before and after adjustment of ration. *Proc Am Assoc Equine Pract* **33**, 163-169.

Georgievskii VI, Annenkov BN, Samokhin VI (1982) Mineral Nutrition of Animals. Butterworths, London.

Getty R (1975) Equine Osteology. In: Getty R (ed) Sisson and Grossman's The Anatomy of the Domestic Animals 5th Edn. WB Saunders Company, Philadelphia. pp 255-348.

Gibbons WJ (1964) Liver biopsy technic. *Mod Vet Pract* **45**, 72-73.

Glade MJ (1986) The control of cartilage growth: a review. *Equine Vet Sci* **6**, 175-187.

Glade MJ, Belling TH (1984) Growth plate cartilage metabolism, morphology and biochemical composition in over- and underfed horses. *Growth* **48**, 473-482.

Glade MJ, Belling TH (1986) A dietary etiology for osteochondrotic cartilage. *Equine Vet Sci* **6**, 151-155.

Glade MJ, Gupta S, Reimers TJ (1984) Hormonal responses to high and low planes of nutrition in weanling Thoroughbreds. *J Anim Sci* **59**, 658-665

Glade MJ, Krook L, Schryver HF, Hintz HF (1983) Morphologic and biochemical changes in cartilage of foals treated with dexametasone. *Cornell Vet* **73**, 170-192.

Goedegebuure SA, Hazewinkel HAW (1986) Morphological findings in young dogs chronically fed a diet containing excess calcium. *Vet Pathol* **23**, 594-605.

Goldstein S, Csapsky G (1986) The role and mechanism of metal ions and their complexes in enhancing damage in biological systems or in protecting these systems from the toxicity of O_2^- . *J Free Radic Biol Med* **2**, 3-11.

Gooneratne SR, Christensen DA (1989) A survey of maternal copper status and fetal tissue copper concentrations in Saskatchewan bovine. *Can J Anim Sci* **69**, 141-150.

Gooneratne SR, Buckley WT, Christensen DA (1989) Review of copper deficiency and metabolism in ruminants. *Can J Anim Sci* **69**, 819-845.

Gooneratne SR, Howell J McC, Gawthorne JM (1981) Intravenous administration of thiomolybdate for the prevention and treatment of chronic copper poisoning in sheep. *Br J Nutr* **46**, 457-467.

Gooneratne SR, Symonds HW, Bailey JV, Christensen DA (1994) Effects of dietary copper, molybdenum and sulfur on biliary copper excretion in Simmental and Angus cattle. *Can J Anim Sci* **74**, 315-325.

Grace ND (1975) Studies on the flow of zinc, cobalt and manganese along the digestive tract of sheep given fresh perennial ryegrass, or white or red clover. *Br J Nutr* **34**, 73-82.

Grace ND (1983a) The distribution of and the amounts of Na, K, Mg, Ca, P, Zn, Fe, Cu and Mn associated with fleece free empty body weight gains in grazing sheep. *NZ J Agric Res* **26**, 59-70.

Grace ND (1983b) Molybdenum (Mo). In: Grace ND (ed) *The Mineral Requirements of Grazing Ruminants*. New Zealand Society of Animal Production. Occasional Publication No. 9. pp 71-75.

Grace ND (1994) Copper. In: *Managing Trace Element Deficiencies*. AgResearch, Grasslands, Palmerston North. pp 35-52.

Grace ND, Clark RG (1991) Trace element requirements, diagnosis and prevention of deficiencies in sheep and cattle. In: Tsuda T, Sasaki Y, Kawashima R (eds) *Physiological Aspects of Digestion and Metabolism in Ruminants. Proc 7th Int Symp Ruminant Physiol* pp 321-346.

Grace ND, Lee J (1988) The effect of increasing copper intake on the bone mineral content of the growing lamb. *Proc NZ Trace Elements Gp Conf*. pp 201-205.

Grace ND, Lee J (1990) Effect of increasing Fe intake on the Fe and Cu content of tissues in grazing sheep. *Proc NZ Soc Anim Prod* **50**, 265-268.

Grace ND, Watkinson JH, Martinson PL (1985) Accumulation of minerals by the foetus(es) and conceptus of single- and twin-bearing ewes. *NZ J Agric Res* **29**, 207-222.

Green DA (1961) A review of studies on the growth rate of the horse. *Br Vet J* **117**, 181-191.

Green DA (1969) A study of growth rate in Thoroughbred foals. *Br Vet J* **125**, 539-545.

Green DA (1976) Growth rate in Thoroughbred yearlings and two year olds. *Equine Vet J* **8**, 133-134.

Grondahl AM, Dolvnik NI (1993) Heritability estimations of osteochondrosis in the tibiotarsal joint and of bony fragments in the palmar/plantar portion of the metacarpo- and metatarsophalangeal joints of horses. *J Am Vet Med Assoc* **203**, 101-104.

Grondalen T, Grondalen J (1974) Osteochondrosis and arthrosis in pigs. IV. Effect of overloading of the distal epiphyseal plate of the ulna. *Acta Vet Scand* **15**, 53-60.

Gunson DE, Kowalczyk DF, Shoop CR, Ramberg CF (1982) Environmental zinc and cadmium pollution associated with generalized osteochondrosis, osteoporosis, and nephrocalcinosis in horses. *J Am Vet Med Assoc* **180**, 295-299.

Gutteridge JMC (1978) Caeruloplasmin: a plasma protein, enzyme, and antioxidant. *Annals Clin Biochem* **15**, 293-296.

Hall AC, Young BW, Bremner I (1979) Intestinal metallothionein and the mutual antagonism between copper and zinc in the rat. *J Inorg Biochem* **11**, 66-67.

Harris ED (1992) Copper as a cofactor and regulator of copper, zinc superoxide dismutase. *J Nutr* **122**, 636-640.

Hart EB, Steenbock H, Waddell J, Elvehjem CA (1928) Iron in nutrition. VII. Copper as a supplement to iron for hemoglobin building in the rat. *J Biol Chem* **77**, 797-812.

Hazewinkel HAW, Goedegebuure SA, Poulos PW, Wolverkamp WThC (1985) Influences of chronic calcium excess on the skeletal development of growing Great Danes. *J Am Anim Hosp Assoc* **21**, 377-391.

Heath TJ, Perkins NR (1985) Effect of development of the ovine forestomachs on the anatomy of portal vessels and on the intrahepatic distribution of portal blood. *Res Vet Sci* **39**, 216-221.

- Hedhammar A, Fu-ming W, Krook L, et al. (1974) Overnutrition and skeletal disease. An experimental study in growing Great Dane dogs. *Cornell Vet Suppl* **5** **64**, 11-160.
- Heller RM, Kirchner SG, O'Neill JA, et al. (1978) Skeletal changes of copper deficiency in infants receiving prolonged total parenteral nutrition. *J Pediatr* **92**, 947-949.
- Henneke DR, Potter GD, Kreider JL, Yeates BF (1983) Relationship between condition score, physical measurements and body fat percentage in mares. *Equine Vet J* **15**, 371-372.
- Hidiroglou M, Ivan M (1993) Liver biopsy in sheep. *Vet Res* **24**, 260-265.
- Hidiroglou M, Knipfel JE (1981) Maternal-fetal relationship of copper, manganese, and sulfur in ruminants. A review. *J Dairy Sci* **64**, 1637-1647.
- Hildebran S, Hunt J (1986) Copper responsive epiphysitis and tendon contracture in a foal. *Mod Vet Pract* **3**, 268-270.
- Hill CH, Starcher B (1965) Effects of reducing agents on copper deficiency in the chick. *J Nutr* **85**, 271-274.
- Hill MA, Ruth GR, Hilley HD, et al. (1985) Dyschondroplasias of growth cartilages (osteochondrosis) in crossbred commercial pigs at one and 15 days of age: Radiologica, angiomicrographical and histological findings. *Vet Rec* **116**, 40-47.
- Hintz HF (1996) Influence of feeding on contracted tendons. *Pferdheilkunde* **12**, 343-344.
- Hogan KG, Money DFK, White DA, Walker R (1971) Weight responses of young sheep to copper, and connective tissue lesions associated with the grazing of pasture of high molybdenum content. *NZ J Agric Res* **14**, 697-701.
- Holbrook JT, Smith JC, Reiser S (1989) Dietary fructose or starch: effects on copper, zinc, iron, manganese, calcium, and manganese balances in humans. *Am J Clin Nutr* **49**, 1290-1294.
- Holmberg CG, Laurell CB (1951) Investigations in serum copper III: Coeruloplasmin as an enzyme. *Acta Chemica Scand* **5**, 476-480.

Hopkins RG, Failla ML (1995) Chronic intake of a marginally low copper diet impairs *in vitro* activities of lymphocytes and neutrophils from male rats despite minimal impact on conventional indicators of copper status. *J Nutr* **125**, 2658-2688.

Hoppe F, Philipsson J (1985) A genetic study of osteochondrosis dissecans in Swedish horses. *Equine Pract* **7**, 7-15.

Hoyt JK, Potter GD, Greene LW, Anderson JG (1995) Copper balance in miniature horses fed varying amounts of zinc. *J Equine Vet Sci* **15**, 357-359

Humphries WR, Morrice PC, Bremner I (1988) A convenient method for treatment of chronic copper poisoning in sheep using subcutaneous ammonium tetrathiomolybdate. *Vet Rec* **123**, 51-53.

Humphries WR, Phillippo M, Young BW, Bremner I (1983) The influence of dietary iron and molybdenum on copper metabolism in calves. *Br J Nutr* **49**, 77-86.

Hunt WF (1994) Pastures For Horses. New Zealand Equine Research Foundation.

Hunt WF, Thomas VG, Stiefel W (in preparation) Video camera recorded image analysis to determine linear and angular dimensions in the growing horse.

Hurtig MB, Pool RR (1996) Pathogenesis of equine osteochondrosis. In: McIlwraith CW Trotter GW (eds) Joint Disease in the Horse. WB Saunders Company, Philadelphia. pp 335-358.

Hurtig MB, Green SL, Dobson H, Burton J (1990) Defective bone and cartilage in foals fed a low-copper diet, *Proc Am Assoc Equine Pract* **36**, 637-643.

Hurtig MB, Green SL, Dobson H, et al. (1993) Correlative study of defective cartilage and bone growth in foals fed a low-copper diet, *Equine Vet J Suppl* **16**, 66-73.

Irwin MR, Poulos PW, Smith BP, Fisher GI (1974) Radiology and histopathology of lameness in young cattle with secondary copper deficiency. *J Comp Path* **84**, 611-621.

Jacob RA, Klevay LM, Logan GM (1978) Hair as a biopsy material. V. Hair metal as an index of hepatic metal in rats: copper and zinc. *Am J Clin Nutr* **31**, 477-480.

Jacobsen T, Slotfeldt-Ellingsen D (1983) Phytic acid and metal availability: a study of Ca and Cu binding. *Cereal Chem* **60**, 392-395.

Jeffcott LB (1991) Osteochondrosis in the horse - searching for the key to pathogenesis. *Equine Vet J* **23**, 331-338.

Jelan ZA, Jeffcott LB, Lundeheim N, Osborne M (1996) Growth rates in Thoroughbred foals. *Pferdheilkunde* **12**, 291-295.

Jensen R, Park RD, Lauerman PM, et al. (1981) Osteochondrosis in feedlot cattle. *Vet Pathol* **18**, 529-535.

Jones DG, Suttle NF (1981) Some effects of copper deficiency on leucocyte function in sheep and cattle. *Res Vet Sci* **31**, 151-156.

Jorgensen B (1995) Effect of different energy and protein levels on leg weakness and osteochondrosis in pigs. *Livestock Prod Sci* **41**, 171-181.

Jubb KVF, Huxtable CR (1993) The Nervous System. In: Jubb KVF, Kennedy PC, Palmer N (eds) *Pathology of Domestic Animals*, 4th Edn. Academic Press Inc., San Diego. pp 360-362.

Kaneko M, Oikawa M, Yoshihara T (1993) Pathological analysis of bone fractures in race horses. *J Vet Med Sci* **55**, 181-183.

Kegley EB, Spears JW (1994) Bioavailability of feed-grade copper sources (oxide, sulphate, or lysine) in growing cattle. *J Anim Sci* **72**, 2728-2734.

Kellaway RC, Sitorus P, Leibholz JML (1978) The use of copper levels in hair to diagnose hypocuprosis. *Res Vet Sci* **24**, 352-357.

Kelley DS, Daudu PA, Taylor PC, et al. (1995) Effects of low-copper diets on human immune response. *Am J Clin Nutr* **62**, 412-416.

Kenneth GD, Klevay A, Klevay LM (1994) Copper: an antioxidant nutrient for cardiovascular health. *Curr opin Lipidol* **5**, 22-28.

Kincaid SA, Lidvall ER (1982) Communicating cartilage canals of the physis of the distal part of the ulna of growing swine and their potential role in healing of metaphyseal dysplasia of osteochondrosis. *Am J Vet Res* **43**, 938-944.

Kincaid SA, Allhands RV, Pijanowski GJ (1985a) Chondrolysis associated with cartilage canals of the epiphyseal cartilage of the distal humerus of growing pigs. *Am J Vet Res* **46**, 726-732.

Kincaid SA, Rudd RG, Evander SA (1985b) Lipids of normal and osteochondrotic cartilage of the immature canine humeral head. *Am J Vet Res* **46**, 1060-1065.

King JC, Wright AL (1985) Copper utilization in pregnant and nonpregnant women. In: Mills CS, Bremner I, Chesters JK (eds) Trace Elements in Man and Animals Vol 5. Commonwealth Agriculture Bureau, Farnham Royal, UK. pp 318-320.

King JC, Raynolds WL, Margen S (1978) Absorption of stable isotopes of iron, copper and zinc during oral contraceptive use. *Am J Clin Nutr* **31**, 1198-1203.

Klevay LM (1990) Ischemic heart disease: toward a unified theory. In: Lei KY, Carr TP (eds) Role of Copper in Lipid Metabolism. CRC Press, Boca Raton. pp 234-267.

Knight DA, Gabel AA, Reed SM, et al. (1985) Correlation of dietary mineral to incidence and severity of metabolic bone disease in Ohio and Kentucky. *Proc Am Assoc Equine Pract* **31**, 445-461.

Knight DA, Weisbrode SE, Schmall LM, et al. (1990) The effects of copper supplementation on the prevalence of cartilage lesions in foals. *Equine Vet J* **22**, 426-432.

Kronfeld DS, Meacham TN, Donoghue S (1990) Dietary aspects of developmental orthopaedic disease in young horses. *Vet Clin Nth Am: Equine Pract* **6**, 451-465.

Krook L, Maylin GA (1988) Fractures in Thoroughbred race horses, *Cornell Vet (Suppl II)* **78**, 1-133.

Ladefoged O, Sturup S (1995) Copper deficiency in cattle, sheep and horses caused by excess molybdenum from fly ash: a case report. *Vet Human Toxicol* **37**, 63-65.

Lamand M, Lab C, Tressol JC, Mason J (1980) Biochemical parameters useful for the diagnosis of mild molybdenosis in sheep. *Ann Rec Vet* **11**, 577-586.

Ledoux DR, Pott EB, Henry MS, et al. (1995) Estimation of the relative bioavailability of inorganic copper sources for sheep. *Nutr Res* **15**, 1803-1813.

Lee J (1983) Multi-element analysis of animal tissues by inductively coupled plasma emission spectrometry. *ICP Inf Newsl* **8**, 553-561.

Lee SH, Lancey R, Montaser A, et al. (1993) Ceruloplasmin and copper transport during the latter part of gestation in the rat. *Proc Soc Exp Biol Med* **203**, 428-439.

Leighton MJ, Peters TJ, Hill R, et al. (1990) Subcellular distribution of copper in the liver of fetal deer in the last month of gestation. *Res Vet Sci* **49**, 298-305.

Lewis LD (1995) *Equine Clinical Nutrition: Feeding and Care*. Williams and Wilkins, Baltimore.

Lifschitz MD, Henkin RJ (1971) Circadian variation in copper and zinc in man. *J Appl Physiol* **31**, 88-92.

Lilburn MS, Lauterio TJ, Ngiam-Rilling K, Smith JM (1989) Relationship among mineral balances in the diet, early growth manipulation and incidence of tibial dyschondroplasia in different type of meat strain chickens. *Poultry Sci* **68**, 1263-1273.

Lillich JD, Bertone AL, Malemud CJ, et al. (1997) Biochemical, histochemical, and immunohistochemical characterization of distal tibial osteochondrosis in horses. *Am J Vet Res* **58**, 89-98.

Linder MC (1991) *The Biochemistry of Copper*. Plenum, New York.

Linder MC, Hazegh-Azam M (1996) Copper biochemistry and molecular biology. *Am J Clin Nutr* **63**, 797S-811S.

Linder MC, Houle PA, Isaacs E, et al. (1979) Copper regulation of ceruloplasmin in copper-deficient rats. *Enzyme* **24**, 23-35.

Linder MC, Weiss KC, Vu HM, Rucker BB (1987) Structure and function of transcuprein in transport of copper by mammalian blood plasma. In: Hurley LC, Lonnerdal B, Keen C (eds) *Trace Elements in Man and Animals (TEMA-6)*. Plenum, New York. pp 141-144.

Lonnerdal B (1996) Bioavailability of copper. *Am J Clin Nutr* **63**, 821S-829S.

Lonnerdal B, Bell JG, Keen CL (1985) Copper absorption from human milk, cow's milk and infant formulas using a suckling rat model. *Am J Clin Nutr* **42**, 836-844.

Luza SC, Speisky HC (1996) Liver copper storage and transport during development: implications for cytotoxicity. *Am J Clin Nutr* **63**, 812S-820S.

McArdle HJ, Van den Berg GJ (1991) The accumulation of copper by microvillar vesicles isolated from human placenta. *J Nutr* **122**, 1260-1265.

McCosker PJ (1968) Observations on blood copper in the sheep: I.-Normal copper status and variations induced by different conditions. *Res Vet Sci* **9**, 91-101.

McHargue JS (1926) Further evidence that small quantities of copper, manganese and zinc are factors in the metabolism of animals. *Am J Physiol* **77**, 245-255.

McIlwraith CW (1984) Equine digestive system. In: Jennings PB (ed) *The Practice of Large Animal Surgery*. WB Saunders Company, Philadelphia. pp.554-663.

McIlwraith CW (1986) Developmental Orthopaedic Disease Symposium, American Quarter Horse Association, Amarillo, Texas.

McIlwraith CW (1993) Inferences from referred clinical cases of osteochondritis dissecans. *Equine Vet J Suppl* **16**, 27-30.

McIlwraith CW (1996) The equine skeleton: how does bone grow and how do abnormalities in the developmental process affect soundness ? In: Proc Kentucky Equine Res Inc Short Course: Focus on Equine Nutrition: Mineral Requirements and Management of the Growing Horse. pp 71-107.

Mackintosh CG, Wilson PR, Beatson NS, et al. (1986) Preliminary report of the liver: serum copper concentration in red deer. *Proc Deer Branch NZ Vet Assoc, Deer Course for Veterinarians* **3**, 156-164.

McLaughlin BG, Doige CE (1981) Musculoskeletal lesions and hyperplastic goitre in newborn foals. *Can Vet J* **22**, 130-133.

McLaughlin BG, Doige CE, Fretz PB, Pharr JW (1981) Carpal bone lesions associated with angular limb deformities in foals. *J Am Vet Med Assoc* **178**, 224-230.

McMillan DA, Schnell RC (1984) Zinc protection against bromobenzene induced hepatotoxicity in the rat. *Toxicologist* **4**, 45.

MacPherson A, Brown NA, Hemingway RG (1964) The relationship between the concentration of copper in the blood and livers of sheep. *Vet Rec* **76**, 643-645.

Markey BA, Phan SH, Varani, J, et al. (1990) Inhibition of cytotoxicity by intracellular superoxide supplementation. *Free Rad Biol Med* **9**, 307-314.

Mason KE (1979) A conspectus of research on copper metabolism and requirements of man. *J Nutr* **109**, 1979-2066.

Mason TA (1981) A high incidence of congenital angular limb deformities in a group of foals. *Vet Rec* **109**, 93-94.

Matusda I, Pearson T, Holtzman NA (1974) Determination of apoceruloplasmin by radioimmunoassay in nutritional copper deficiency, Menkes' kinky hair syndrome, Wilson's disease and umbilical cord blood. *Pediatr Res* **8**, 821-824.

Mayhew IG (1994) Odds and SODs of equine motor neurone disease. *Equine Vet J* **26**, 342-343.

Mayhew IG, deLahunta A, Whitlock RH, et al. (1978) Spinal cord disease in the horse. *Cornell Vet (Suppl 6)* **68**, 1-207.

Mee JF, McLaughlin J (1995) 'Normal' blood copper levels in horses. *Vet Rec* **136**, 275.

Meyer H, Ahlswede L (1978) The intra-uterine growth and body composition of foals and the nutrient requirements of pregnant mares. *Anim Res Dev* **8**, 86-112.

Meyer H, Tiegs W (1995) Liver Cu-concentration in the fetus and newly born foal. *Proc Equine Nutr Physiol Soc* **14**, 8-12.

Middleton RB, Linder MC (1993) Synthesis and turnover of ceruloplasmin in rats treated with 17- β -estradiol. *Arch Biochem Biophys* **302**, 362-368.

Misheff MM, Stover SM, Pool RR (1992) Corticocancellous bone biopsy from the 12th rib of standing horses. *Vet Surg* **21**, 133-138.

Mills CF, Dalgarno AC, Wenham G (1976) Biochemical and pathological changes in tissues of Friesian cattle during the experimental induction of copper deficiency. *Br J Nutr* **35**, 309-333.

Milne DB (1994) Assessment of copper nutritional status. *Clin Chem* **40**, 1479-1484.

Milne DB, Johnson PE (1993) Assessment of copper status: effect of age and gender on reference ranges in healthy adults. *Clin Chem* **39**, 883-887.

- Milne DB, Klevay LM, Hunt JR (1988) Effects of ascorbic acid supplements and a diet marginal in copper on indices of copper nutriture in women. *Nutr Res* **8**, 865-873.
- Milne EA (1992) Diagnosis of equine liver disease. *Vet Annu* **32**, 220-226.
- Mistilis SP, Mearrick PT (1969) The absorption of ionic, biliary, and plasma radiocopper in neonatal rats. *Scand J Gastroent* **4**, 691-696.
- Moore JN, McIlwraith CW (1976) Osteochondrosis of the equine stifle. *Vet Rec* **100**, 133-136.
- Mulhern SA, Koller LD (1988) Severe or marginal copper deficiency results in a graded reduction in immune status in mice. *J Nutr* **118**, 1041-1047.
- Nakamura M, Yagasaki I (1972) One-electron transfer reaction biochemical systems. VI. Changes in electron transfer mechanism of lipoamidedehydrogenase by modification of sulfhydryl groups. *Biochem Biophys Acta* **267**, 249-257.
- Nakano T, Aherne FX (1988) Involvement of trauma in the pathogenesis of osteochondritis in swine. *Can J Vet Res* **52**, 154-155.
- Nakano T, Aherne FX (1995) A histochemical and immunohistochemical study of proteoglycans in normal and osteochondrotic joint cartilage of swine. *Can J Anim Sci* **75**, 477-480.
- Nakano T, Aherne FX, Thompson JR (1979) Changes in swine knee articular cartilage during growth. *Can J Anim Sci* **59**, 167-179.
- Nakano T, Aherne FX, Thompson JR (1985) Cartilage proteoglycans from normal and osteochondrotic porcine joints. *Can J Comp Med* **49**, 219-226.
- Nakano T, Brennan JJ, Aherne FX (1987) Leg weakness and osteochondrosis in swine: a review. *Can J Anim Sci* **67**, 883-901.
- Napier M (1973) *Thoroughbred Pedigrees Simplified*. JA Allen and Company, London.

National Research Council (1989) The Nutrient Requirements of Horses, 5th Rev. National Academy Press, Washington D.C.

Neifakh SA, Monakhov NK, Shaposhnikov AM, Zubzhitski YN (1969) Localization of ceruloplasmin biosynthesis in human and monkey liver cells and its copper regulation. *Experientia* **25**, 337-344.

Niederman CN, Blodgett D, Eversole D, et al. (1994) Effect of copper and iron on neutrophil function and humoral immunity of gestating beef cattle. *J Am Vet Med Assoc* **204**, 1796-1800.

O'Cuill T, Hamilton AF, Egan DA (1970) Copper distribution in the liver. *Ir Vet J* **27**, 21-25.

O'Dell BL (1990) Dietary carbohydrate source and copper bioavailability. *Nutr Rev* **48**, 425-434.

O'Donohue DD, Smith FH, Strickland KL (1992) The incidence of abnormal limb development in the Irish Thoroughbred from birth to 18 months. *Equine Vet J* **24**, 305-309.

Okumura M, Fujinaga T, Yamashita K, et al. (1991) Isolation, characterization, and quantitative analysis of ceruloplasmin from horses. *Am J Vet Res* **52**, 1979-1985.

Olivares M, Uauy R (1996) Copper as an essential nutrient. *Am J Clin Nutr* **63**, 791S-796S.

Olsson SE (1982) Morphology and physiology of the growth cartilage under normal and pathologic conditions. In: Sumner-Smith G (ed) Bone in Clinical Orthopaedics. WB Saunders Company, Philadelphia. pp 159-196.

Olsson SE, Reiland S (1978) The nature of osteochondrosis in animals: summary and conclusions with comparative aspects on osteochondritis dissecans in man. *Acta Radiol Suppl* **358**, 229-275.

Orth MW, Cook ME (1994) Avian tibial dyschondroplasia: a morphological and biochemical review of the growth plate lesion and its causes. *Vet Pathol* **31**, 403-414.

Owen TA, Aronow MS, Barone LM, et al. (1991) Pleiotropic effects of vitamin D on osteoblast gene expression are related to the proliferative and differentiated state of the bone cell phenotype: Dependency upon basal levels of gene expression, duration of exposure, and bone matrix competency in normal rat osteoblast cultures. *Endocrinol* **128**, 1496-1504.

Pagan JD (1994) Nutrient digestibility in horses. In: Proc Kentucky Equine Res Inc Short Course: Feeding the Performance Horse pp 127-136.

Pagan JD, Jackson SG (1996) The incidence of developmental orthopedic disease on a Kentucky Thoroughbred farm. *Pferheilkunde* **12**, 351-354.

Pagan JD, Jackson SG, Cadel S (1996) A summary of growth rates of Thoroughbreds in Kentucky. *Pferheilkunde* **12**, 285-289.

Palmer N (1993) Bones and joints. In: Jubb KVF, Kennedy PC, Palmer N (eds) Pathology of Domestic Animals 4th Edn. Academic Press Inc, New York. pp 1-182.

Pardo CA, Zuoshang X, Borchelt DR, et al. (1995) Superoxide dismutase is an abundant component in cell bodies, dendrites, and axons of motor neurons and in a subset of other neurons. *Proc Natl Acad Sci* **92**, 954-958.

Paynter DI (1982) Differences between serum and plasma ceruloplasmin activity and copper concentrations: investigation of possible contributing factors. *Aust J Biol Sci* **35**, 353-361.

Paynter DI, Moir RJ, Underwood EJ (1979) Changes in activity of the Cu-Zn superoxide dismutase enzyme in tissues of the rat with changes in dietary copper. *J Nutr* **109**, 1570-1576.

Pearson EG, Craig AM (1980) The diagnosis of liver disease in equine and food animals. *Mod Vet Pract* **61**, 233-237.

Peet RL, Hepworth K (1993) Enzootic ataxia in red deer, *Cervus elaphus*. *Aust Vet J* **70**, 395-396.

Percival SS (1995) Neutropenia caused by copper deficiency: possible mechanism of action. *Nutr Rev* **53**, 59-66

Philipsson J (1996) Pathogenesis of osteochondrosis-genetic implications. In: McIlwraith CW Trotter GW (eds) *Joint Disease in the Horse*. WB Saunders Company, Philadelphia. pp 359-362.

Philipsson J, Andreasson E, Sandgren B, et al. (1993) Osteochondrosis in the tarsocrural joint and osteochondral fragments in the fetlock joints in Standardbred Trotters: II. heritability. *Equine Vet J Suppl* **16**, 38-41.

Podczasy JJ, Wei R (1988) Reduction of iodonitrotetrazolium violet by superoxide radicals. *Biochem Biophys Res Commun* **150**, 1294-1301.

Pool RR (1993) Difficulties in definition of equine osteochondrosis; differentiation of developmental and acquired lesions. *Equine Vet J Suppl* **16**, 5-12, 1993

Poole DBR (1982) Bovine copper deficiency in Ireland - the clinical disease. *Ir Vet J* **36**, 169-173.

Poulos PW, Reiland S, Elwinger K (1978) Skeletal lesions in the broiler, with special reference to dyschondroplasia (osteochondrosis). *Acta Radiol Suppl* **358**, 277-298.

Powers BE, Stashak TS, Nixon AJ, et al. (1986) Pathology of the vertebral column of horses with cervical static stenosis. *Vet Pathol* **23**, 392-399.

Price J, Will AM, Paschaleris G, Chesters JK (1987) Identification of thiomolybdates in digesta and plasma from sheep after administration of ⁹⁹Mo-labelled compounds into the rumen. *Br J Nutr* **58**, 127-138.

Pryor WJ (1964) The distribution of copper in bovine and ovine fetuses, with reference to their age and maternal liver copper concentration. *Res Vet Sci* **5**, 123-137

Ralston S (1996) Hyperglycemia/hyperinsulinemia after feeding a meal of grain to young horses with osteochondritis dissecans (OCD) lesions. *Pferheilkunde* **12**, 320-322.

Ravin HA (1961) An improved colorimetric enzymatic assay of caeruloplasmin. *J Lab Clin Med* **58**, 161-168.

Redwood MM (1979) Proud silk - a New Zealand racing history. AH & AW Reed Ltd, Wellington.

Reed SM, Knight DE, Weisbrode SE, Stewart RH (1987) The relationship of cervical vertebral malformation to developmental orthopedic disease. *Proc Am Assoc Equine Pract* **33**, 139-142.

Reiland S (1978) Morphology of osteochondrosis and sequelae in the pig. *Acta Radiol Suppl* **358**, 45-90.

Reiland S, Stromberg B, Olsson S-E, et al. (1978) Osteochondrosis in growing bulls. *Acta Radiol Suppl* **358**, 179-196.

Reiser S, Smith JC, Mertz W, et al. (1985) Indices of copper status in humans consuming a typical American diet containing either fructose or starch. *Am J Clin Nutr* **42**, 242-251.

Rejno S, Stromberg B (1978) Osteochondrosis in the horse: Pathology. *Acta Radiol Suppl* **358**, 153-178.

Robbins KR, Baker DH (1980) Effect of sulfur amino acid level and source on the performance on chicks fed high levels of copper. *Poult Sci* **59**, 1246-1253.

Rooney JR (1963) Epiphyseal compression in young horses. *Cornell Vet* **53**, 568-574.

Rooney JR (1966) Contracted foals. *Cornell Vet* **56**, 172-197.

Rooney JR (1975a) Osteochondrosis in the horse. *Mod Vet Pract* 41-43.

Rooney JR (1975b) Osteochondrosis in the horse. *Mod Vet Pract* 113-116.

Rosen DR, Siddique T, Patterson D, et al. (1993) Mutations in Cu/Zn superoxide dismutase gene are associated with familial amyotrophic lateral sclerosis. *Nature* **362**, 59-62.

Rowland LP (1995) Amyotrophic lateral sclerosis: human challenge for neuroscience. *Proc Natl Acad Sci* **92**, 1251-1253.

Rucker RB, Parker HE, Rogler JC (1969) Effect of copper deficiency on chick bone collagen and selected bone enzymes. *J Nutr* **98**, 57-63.

Ryden L, Deutsch H.F (1978) Preparation and properties of the major copper binding component of human fetal liver: its identification as metallothionein. *J Biol Chem* **253**, 519-524.

Saik LA, Hseih HL, Baricos WH, et al. (1982) Enzymatic and immunologic quantitation of erythrocyte superoxide dismutase in adults and neonates at different gestational ages. *Pediatr Res* **16**, 933-937.

Sarvazyan N, Askari A, Klevay LM, et al. (1995) Role of intracellular SOD in oxidant-induced injury to normal and copper-deficient cardiac myocytes. *Am J Physiol* **268**, H1115-H1121.

Sass-Kortsak A (1965) Copper metabolism. *Adv Clin Chem* **8**, 1-67.

Savage CJ, Jeffcott LB, Melsen F et al. (1991) Bone biopsy in the horse 1. method using the wing of the ilium. *J Vet Med* **38**, 776-783.

Savage CJ, McCarthy RN, Jeffcott LB (1993a) Effects of dietary energy and protein on induction of dyschondroplasia in foals. *Equine Vet J Suppl* **16**, 74-79.

Savage CJ, McCarthy RN, Jeffcott LB (1993b) Effects of dietary phosphorus and calcium on induction of dyschondroplasia in foals. *Equine Vet J Suppl* **16**, 80-83.

Savage CJ, McCarthy RN, Jeffcott LB (1993c) Histomorphometric assessment of bone biopsies from foals fed diets high in phosphorus and digestible energy. *Equine Vet J suppl* **16**, 89-93.

Schougaard H, Ronne JF, Philipsson J (1990) A radiographic survey of tibiotarsal osteochondrosis in a selected population of trotting horses in Denmark and its possible genetic significance. *Equine Vet J* **22**, 288-289.

- Schryver HF, Hintz HF, Lowe JE, et al. (1974) Mineral composition of the whole body liver and bone of young horses. *J Nutr* **104**, 126-132.
- Schryver HF, Oftedal OT, Williams J, et al. (1986) Lactation in the horse: the mineral composition of mare milk. *J Nutr* **116**, 2142-2147.
- Schryver HF, Meakim DW, Lowe JE, et al. (1987) Growth and calcium metabolism in horses fed varying levels of protein. *Equine Vet J* **19**, 280-187.
- Schonewille JTh, Yu S, Beynen AC (1995) High iron intake depresses hepatic copper content in goats. *Vet Quarterly* **17**, 14-17.
- Schule R, Umesono K, Mangelsdorf DJ, et al. (1990) Jun-Fos and receptors for vitamin A and D recognize a common response element in the human osteocalcin gene. *Cell* **61**, 497-504.
- Scott KC, Turnlund JR (1994) Compartment model of copper metabolism in adult men. *J Nutr Biochem* **5**, 342-350.
- Scudder P, Stocks J, Dormandy TL (1976) The relationship between erythrocyte superoxide dismutase activity and erythrocyte copper levels in normal subjects and in patients with rheumatoid arthritis. *Clin Chim Acta* **69**, 397-403.
- Shaw JCL (1992) Copper deficiency in term and preterm infants. In: Fomon SJ, Zlotkin S, eds. Nutritional Anaemias. Nestle Nutrition Workshop Series, Vol 30. New York, Raven Press. pp 105-119.
- Sherwood G, Sarkar B, Sass-Kortsak A (1989) Copper histidinate therapy in Menkes disease-prevention of progressive neurodegeneration. *J Inherit Metab Dis Suppl* **2** **12**, 393-396.
- Slater MR, Scarlett JM, Donoghue S, et al. (1992) Diet and exercise as potential risk factors for osteochondritis dissecans in dogs. *Am J Vet Res* **53**, 2119-2124.
- Smart ME, Gudmundson J (1980) Copper deficiency on Simmental calves. *Calif Vet* **34**, 22-24.

Smart ME, Cymbaluk NF, Christensen DA (1992) A review of copper status of cattle in Canada and recommendations for supplementation. *Can Vet J* **33**, 163-170.

Smith JD, Jordan RM, Nelson ML (1975) Tolerance of ponies to high levels of dietary copper. *J Anim Sci* **41**, 1645-1649.

Smith JE, Cipriano JE (1987) Inflammation-induced changes in serum iron analytes and ceruloplasmin of Shetland ponies. *Vet Pathol* **24**, 354-356.

Smith P, Stubley D, Blackmore DJ (1983) Measurement of superoxide dismutase, diamine oxidase and caeruloplasmin oxidase in blood of Thoroughbreds. *Res Vet Sci* **35**, 160-164.

Solomons NW (1979) On the assessment of zinc and copper nutriture in man. *Am J Clin Nutr* **32**, 856-871.

Solomons NW (1988) Zinc and Copper. In: Shils ME, Young VR (eds) *Modern Nutrition in Health and Disease* 7th Edn. Lea Febiger, Philadelphia. pp 238-262.

Sorenson JRJ (1982) Copper complexes as the active metabolites of the anti-inflammatory agents. In Sorenson JRJ (ed) *Inflammatory Diseases and Copper*. Humana Press, Clifton. pp 289-301.

Sorenson JRJ (1985) Copper complexes: a physiologic approach to treatment of chronic diseases. *Compre Therap* **11**, 49-64.

Spence JA, Suttle NF, Wenham G, et al. (1980) A sequential study of the skeletal abnormalities which develop in rats given a small dietary supplement of ammonium tetrathiomolybdate. *J Comp Pathol* **90**, 139-153.

Stabel JR, Spears JW, Brown TT (1993) Effect of copper deficiency on tissue, blood characteristics, and immune function of calves challenged with infectious bovine rhinotracheitis virus and *Pasteurella hemolytica*. *J Anim Sci* **71**, 1247-1255.

Stephens LC, Norrdin RW, Benjamin SA (1985) Effects of calcium supplementation and sunlight exposure on growing beagle dogs. *Am J Vet Res* **46**, 2037-2042.

Stewart RH, Reed SM, Weisbrode SE (1991) Frequency and severity of osteochondrosis in horses with cervical stenotic myelopathy. *Am J Vet Res* **52**, 873-879.

Stockwell RA (1971) The ultrastructure of cartilage canals and the surrounding cartilage in the sheep fetus. *J Anat* **3**, 397-410.

Stover SM, Johnson BJ, Daft BM, et al. (1992) An Association between complete and incomplete stress fractures of the humerus in racehorses. *Equine Vet J* **24**, 260-263.

Stowe HD (1968) Effects of age and impending parturition upon serum copper of Thoroughbred mares, *J Nutr* **95**, 179-183.

Stowe HD (1980) Effects of copper pretreatment upon the toxicity of selenium in ponies. *Am J Vet Res* **41**, 1925-1928.

Strickland K, Smith F, Woods M, Mason J (1987) Dietary molybdenum as a putative copper antagonist in the horse. *Equine Vet J* **19**, 50-54

Stromberg B (1979) A review of the salient features of osteochondrosis in the horse. *Equine Vet J* **11**, 211-214.

Stromberg B, Rejno S (1978) Osteochondrosis in the horse: a clinical and radiologic investigation of osteochondritis dissecans of the knee and hock joint. *Acta Radiol Suppl* **358**, 139-152.

Stubley D, Campbell C, Dant C, et al. (1983) Copper and zinc levels in the blood of Thoroughbreds in training in the United Kingdom. *Equine Vet J* **15**, 253-256.

Suttle (1974) A technique for measuring the biological availability of copper to sheep, using hypocupraemic ewes. *Br J Nutr* **32**, 395-405.

Suttle NF (1975) Changes in the availability of dietary copper to young lambs associated with age and weaning. *J Agric Sci Camb* **84**, 255-261.

Suttle NF (1979) Copper, iron, manganese and zinc concentrations in the carcasses of lambs and calves and the relationship to trace element requirements for growth. *Br J Nutr* **42**, 89-96.

Suttle NF (1994) Meeting the copper requirements of ruminants. In: Garnsworthy PC, Cole DJA (eds) *Recent Advances in Animal Nutrition*. Nottingham University Press. pp 173-187.

Suttle NF, Angus KW (1978) Effects of experimental copper deficiency on the skeleton of the calf. *J Comp Pathol* **88**, 137-148.

Suttle NF, Angus KW, Nisbet DI, Field AC (1972) Osteoporosis in copper depleted lambs. *J Comp Pathol* **82**, 93-97.

Suttle NF, Small JNW, Collins EA, et al. (1996) Serum and hepatic copper concentrations used to define normal, marginal and deficient copper status in horses. *Equine Vet J* **28**, 497-499.

Sutton AM, Harvie A, Cockburn F, et al. (1985) Copper deficiency in the preterm infant of very low birthweight. Four cases and a reference range for plasma copper. *Arch Dis Childhood* **60**, 644-651.

Szczurek EM, Jackson SG, Rooney JR, Baker JP (1988) Influence of confinement, plane of nutrition and low heel on the occurrence of acquired forelimb contracture in weanling horses. *Equine Vet Sci.* **8**, 386-394.

Tennant B, Evans CD, Schwartz LW (1973) Equine hepatic insufficiency. *Vet Clin North Am* **3**, 279-289.

Tesio F (1958) *Breeding the Racehorse*. JA Allen & Company

Thompson KG, Audige L, Arthur DG, et al. (1994) Osteochondrosis associated with copper deficiency in young farmed red deer and wapiti x red deer hybrids. *NZ Vet J* **42**, 137-143.

Thompson KN, Jackson SG, Rooney JR (1988) The effect of above average weight gains on the incidence of radiographic bone aberrations and epiphysitis in growing horses. *Equine Vet Sci* **8**, 383-385.

- Thornalley PJ, Vasak M (1985) Possible role for metallothionein in protection against radiation-induced oxidative stress. Kinetics and mechanism of its reaction with superoxide and hydroxyl radicals. *Biochim Biophys Acta* **827**, 36-44.
- Thorp BH, Farquharson C, Kwan APL, Loveridge N (1993) Osteochondrosis/dyschondroplasia: a failure of chondrocyte differentiation. *Equine Vet J Suppl* **16**, 13-18.
- Trueta J, Amato VP (1960) The vascular contribution to osteogenesis. III. Changes in the growth cartilage caused by experimentally induced ischaemia. *J Bone Joint Surg [Br]* **42**, 571-587.
- Tsai PCV, Lei KY (1979) Dietary cellulose, zinc and copper: Effect on tissue levels of trace elements in the rat. *J Nutr* **107**, 1117-1122.
- Tsai MT, Dinh CT, Linder MC (1992) Interactions of transcuprein and albumin in copper transport. *FASEB J* **6**, A1095.
- Turner S (1987) Diseases of bones and related structures. In: Stashak TS (ed) *Adam's Lameness in Horses* 4th Edn. Lea & Febiger, Philadelphia. pp 317-320.
- Turnlund JR, Keyes WR, Anderson HL, Acord LL (1989) Copper absorption and retention in young men at three levels of dietary copper using the stable isotope, ^{65}Cu . *Am J Clin Nutr* **49**, 870-878.
- Turnlund JR, King JC, Keyes WR, et al. (1984) A stable isotope study of zinc absorption in young men: effects of phytate and α -cellulose. *Am J Clin Nutr* **40**, 1071-1077.
- Turnlund JR, King JC, Gong B, et al. (1985) A stable isotope study of copper absorption in young men: effects of phytate and α -cellulose. *Am J Clin Nutr* **42**, 18-23.
- Tyrala E (1986) Zinc and copper balances in preterm infants. *Pediatrics* **77**, 513-517.
- Uauy R, Castillo-Duran C, Fisberg M, et al. (1985) Red cell superoxide dismutase activity as an index of human copper nutrition. *J Nutr* **115**, 1650-1655.

Ullrey DE, Ely WT, Covert RL (1974) Iron, Zinc and copper in mare's milk. *J Anim Sci* **38**, 1276-1277.

Underwood EJ (1977) Trace Elements in Human and Animal Nutrition, 4th Edn. Academic Press. New York.

Van Campen D, Gross E (1968) Influence of ascorbic acid on the absorption of copper by rats. *J Nutr* **95**, 617-622.

Van Campen D, Scaife PU (1967) Zinc interference with copper absorption in rats. *J Nutr* **91**, 473-476.

Van der Wal PG, Hemminga H, Goedegebuure SA, Van der Valk PC (1986) The effect of replacement of 0.3% sodium chloride by 0.43% sodium bicarbonate in rations of fattening pigs on leg weakness, osteochondrosis and growth. *Vet Quarterly* **8**, 136-144.

Van Ryssen JBJ (1994) The effectiveness of using supplementary zinc and molybdenum to reduce the copper content in the liver of hypercuprotic sheep. *J S Afr Vet Assoc* **65**, 59-63.

Varada KR, Harper RG, Wapnir RA (1993) Development of copper intestinal absorption in the rat. *Biochem Med Metab Biol* **50**, 277-283.

Vermunt JJ, West DM (1994) Predicting copper status in beef cattle using serum copper concentrations. *NZ Vet J* **42**, 194-195.

Visco DM, Hill MA, Van Sickle DC, Kincaid SA (1991) Cartilage canals and lesions typical of osteochondrosis in growth cartilages from the distal part of the humerus of newborn pigs. *Vet Rec* **128**, 221-228.

Vivrette SL, Reimers TJ, Krook L (1984) Skeletal disease in a hypothyroid foal. *Cornell Vet* **74**, 373-386.

Vohra P, Gray GA, Kratzer FH (1965) Phytic acid-metal complexes. *Proc Soc Exp Biol Med* **120**, 447-449.

Wagner PC, Grant BD, Watrous BJ, et al. (1985a) A study of the heritability of cervical malformation in horses. *Proc Am Assoc Equine Pract* **31**, 43-50.

Wagner PC, Shires GMH, Watrous BJ, et al. (1985b) Management of acquired flexural deformity of the metacarpophalangeal joint in Equidae. *J Am Vet Med Assoc* **187**, 915-918.

Walker WR (1982) The results of a copper bracelet clinical trial and subsequent studies. In: Sorenson JRJ (ed) *Inflammatory Diseases and Copper*. Humana Press, Clifton. pp 469-478.

Walsh T, O'Moore LB (1953) Excess of molybdenum in herbage as a possible contributing factor in equine osteodystrophia. *Nature* **171**, 1166.

Wapnir RA, Balkman C (1991) Inhibition of copper absorption by zinc. Effect of histidine. *Biol Trace Elem Res* **29**, 193-202.

Wapnir RA, Devas G (1995) Copper deficiency: interaction with high-fructose and high-fat diets in rats. *Am J Clin Nutr* **61**, 105-110.

Wapnir RA, Lee SY (1993) Dietary regulation of copper absorption and storage in rats: effects of sodium, zinc and histidine-zinc. *J Am Coll Nutr* **12**, 714-719.

Ward JD, Spears JW, Gengelbach GP (1995) Differences in copper status and copper metabolism among Angus, Simmental, and Charolais cattle. *J Anim Sci* **73**, 571-577.

Wardale RJ, Duance VC (1994) Characterisation of articular cartilage and growth plate collagens in porcine osteochondrosis. *J Cell Sci* **107**, 47-59.

Watrous BJ, Hultgren BD, Wagner PC (1991) Juvenile spavin as a manifestation of osteochondrosis. *Am J Vet Res* **52**, 607-612.

Weiss KC, Linder MC (1985) Copper transport in rats involving a new plasma protein. *Am J Physiol* **249**, E77-E88.

Wells N (1957) Soil studies using sweet vernal to assess element availability. Part 3-Copper in New Zealand soil sequences. *NZ J Sci Tech* **38**, 884-902.

Wertime TA (1964) Man's first encounter with metallurgy. *Science* **146**, 1257-1267.

Whanger PD, Weswig PH (1970) Effect of some copper antagonists on induction of ceruloplasmin in the rat. *J Nutr* **100**, 341-348.

White SL, Rowland GN, Whitlock RH (1984) Radiographic, macroscopic, and microscopic changes in growth plates of calves raised on hard flooring. *Am J Vet Res* **45**, 633-639.

Widdowson EM, Dauncey J, Shaw JCL (1974) Trace elements in foetal and early postnatal development, *Proc Nutr Soc* **33**, 275-284.

Williams DM (1983) Copper deficiency in humans. *Semin Hematol* **20**, 118-128.

Willoughby RA, MacDonald E, McSherry BJ, Brown G (1972) Lead and zinc poisoning and the interaction between Pb and Zn poisoning in the foal. *Can J Comp Med* **36**, 348-359.

Wilson GL (1986) Laparoscopic examination of the reproductive tract of the mare. In: Morrow DA (ed) *Current Therapy in Theriogenology 2*. WB Saunders Company, Philadelphia. 779-781.

Woodard JC, Becker HN, Poulos PW (1987a) Effect of diet on longitudinal bone growth and osteochondrosis in swine. *Vet Pathol* **24**, 109-117.

Woodard JC, Becker HN, Poulos PW (1987b) Articular cartilage blood vessels in swine osteochondrosis *Vet Pathol* **24**, 118-123.

Woolliams JA, Suttle NF, Wiener G, et al. (1983) The long term accumulation and depletion of copper in the liver of different breeds of sheep fed diets of differing copper content. *J Agric Sci Camb* **100**, 441-449.

Woolliams C, Suttle NF, Woolliams JA, et al. (1986) Studies on lambs from lines genetically selected for low and high plasma copper status. 1. Differences in mortality. *Anim Prod* **43**, 293-301.

Xin Z, Waterman DF, Hemken RW, Harmon RJ (1991) Effects of copper status on neutrophil function, superoxide dismutase, and copper distribution in steers. *J Dairy Sci* 74, 3078-3085.

Yang G, Chan PH, Chen J, et al. (1994) Human copper-zinc superoxide dismutase transgenic mice are highly resistant to reperfusion injury after focal cerebral ischaemia. *Stroke* 25, 165-170.

Yoshida D, Ikeda Y, Nakazawa S (1995) Copper chelation inhibits tumour angiogenesis in the experimental 9L gliosarcoma model. *Neurosurgery* 37, 287-293.

Yu S, Beynen AC (1995) High tin intake reduces copper status in rats through inhibition of copper absorption. *Br J Nutr* 73, 863-869.