

Copyright is owned by the Author of the thesis. Permission is given for a copy to be downloaded by an individual for the purpose of research and private study only. The thesis may not be reproduced elsewhere without the permission of the Author.

RADIOGRAPHIC ANATOMY OF THE EQUINE LUNG

A thesis presented in partial
fulfilment of the requirements for the degree
of Master of Veterinary Science.

GARRY NEIL SANDERSON

Massey University

February 1982

Abstract of a thesis presented in partial
fulfilment of the requirements for the degree of
Master of Veterinary Science.

RADIOGRAPHIC ANATOMY OF THE EQUINE LUNG

GARRY NEIL SANDERSON

This research project was instigated in an attempt to provide information on the radiographic anatomy of equine thorax which would enable specific interpretative criteria to be developed in the diagnosis of equine pulmonary conditions. In order to accurately characterise the structures in the thorax a number of existing investigative techniques had to be modified for use in equine subjects.

In the absence of an existing method at the time, a simple method of performing bronchograms on standing conscious horses was developed. The technique involved insufflation of 100 - 200gms of finely powdered Barium Sulphate mixed with 3-7gms of powdered methyl cellulose from an ether vapouriser connected to an intra tracheal tube and supplied with compressed air from a gas cylinder. Good visualisation of bronchial branches down to the seventh and eighth generations were obtained in all but the most dorsal bronchial branches. Elimination of residual contrast agent was rapid and inflammatory response determined by serial histological studies was minimal.

Attempts at pulmonary arterial angiography in the standing horse were abandoned owing to adverse patient reaction in favour of a similar technique in anaesthetised animals, however as a result of difficulties encountered with this technique only a small series of angiograms was performed with mixed results.

Fume fixation of the equine lung was performed utilising the hot formalin vapour technique of Wright et.al., (1974) resulting in the successful production of several sets of "phantom" lungs on which extensive radiological and gross anatomical studies were performed in an attempt to relate the "in vitro" appearances with those of plain radiographs of the thorax of standing horses.

Careful examination of the resultant radiographs and correlation of differing appearances provided by the contrast techniques demonstrated a number of important diagnostic points. On the plain radiograph a greater number of generations of pulmonary arteries, veins and bronchi can be accurately identified in the horse compared to other species. In addition, despite a similar subgross and superficial radiographic anatomy to man, the horse demonstrates an arterial and venous branching pattern exactly the reverse in appearance. Thus monopodal branching is a feature of the pulmonary arterial system whereas dichotomous smooth branching is the norm for equine pulmonary veins.

Marked between animal variation in the pattern of bronchial branching was also noted however it was not determined if this was a true variation in anatomical branching or the result of widely varying degrees of bronchoconstriction. The latter effect was very marked

in some bronchograms when atropine sulphate was not used prior to barium sulphate insufflation during bronchography. Perhaps the most important result of the correlative study was the ability to accurately identify bronchial and vascular branches over the greater part of the lung fields as a result of prior knowledge of their branching patterns obtained from the contrast studies.

No attempt was made in this study to relate the radioanatomical findings to known clinically apparent pulmonary conditions. Such research was held to be appropriate for a follow up study.

ACKNOWLEDGEMENTS

I would like to record my gratitude to the Equine Research Foundation and to the trustees of the Norman Cunningham Fellowship for financial assistance throughout the period of this study.

I am grateful to Dr. Mike O'Callaghan, my supervisor, for his guidance and encouragement during this study, and to my co-supervisors Drs. B.E.Goulden and H.G.Pearce for their support. Without the technical expertise and considerable patience of Kirsty Caro, the veterinary clinic radiographer, this thesis could not have been produced.

I thank Rex Faulding for his technical assistance and Tom Law for his fine photography, also the staff of the Massey Veterinary Clinic for their assistance.

To my wife, Rebecca, thank you for your understanding and constant encouragement for the period of study.

TABLE OF CONTENTS

	Page No.
List of figures	
List of tables	
Introduction	
Chapter I : Literature Review	3
Thoracic Radiology (A) General	3
(B) Plain Radiology	3
(i)small animal species	3
(ii)large animal species	5
(C) Bronchography	6
(i)Human bronchography	7
(ii)Canine bronchography	9
(iii)Large animal species	13
Anatomy of the Lung	
(A) Gross Anatomy	14
(B) Subgross Anatomy	14
Interpretation of Pulmonary Radiographs Based on Pattern Recognition	20
(A) Vascular pattern	20
(B) Bronchial pattern	23
(C) Interstitial pattern	24
(D) Alveolar pattern	27
Lung Fixation	29
Chapter II : Materials and Methods	32
Plain Radiography of the Equine Thorax	32
Correlative Study of the Equine Thorax involving Special Procedures	33
(A) Pulmonary Angiography	33
(B) Bronchography	35

	Page No.
Morphological Study of Isolated Equine Lungs	42
(A) Embalming Equine Lungs	42
(B) Investigations on Embalmed Lungs	43
(i) Plain Radiography	43
(ii) Use of Contrast Agents in Embalmed Lungs	44
(iii) Histological Analyses	44
Chapter III : Bronchography in the Horse	45
Results (i) Bronchograms	45
(ii) Elimination of Barium	54
(iii) Histological Response	55
Discussion	56
Chapter IV : Pulmonary Vasculature in the Horse	61
Results (A) Pulmonary Arteriography	61
(B) Radiography of Dissected Equine Lungs	72
(i) Without contrast agents	72
(ii) With contrast agents	73
Discussion	73
Chapter V : Radiographical Anatomy of the Equine Thorax	80
Results (i) Bony Structures	80
(ii) Heart and Great Vessels (a)Aorta	80
(b)Pulmonary arteries	81
(c)Pulmonary veins	83
(d)Caudal vena cava	83
(e)Peripheral vasculature	83
(iii) Airways	84
Discussion	90
Conclusion	93
References	97

LIST OF FIGURES

	Page No.
(1) Diagrammatic representation of bronchograms, both normal and abnormal (Adapted from Douglas,1970)	12
(2) Characteristics of pulmonary vessels as seen on human chest radiographs	22
(3) Diagram of the system for delivering powdered barium sulphate to the lungs	40
(4) Diagram of a system for embalming equine lungs	42
(5) Plain, left lateral radiograph of diaphragmatic area of a normal horse	46
(6) Bronchogram of an adult horse	47
(7) Difficulties encountered with equine bronchograms	48
(8) Demonstration of the marked variation of bronchial patterns from different horses	49
(9) Bronchogram of a 24 year old mare with a history of chronic cough	50
(10) Radiographs taken to illustrate the rapid (a,b,c) elimination of barium sulphate from the airways	51 & 52
(11) Bronchogram taken 10 minutes post-insufflation to illustrate bolus of contrast material within the oesophagus	53
(12) Exposure to check position of intra-arterial catheter prior to angiography	64
(13) Pulmonary arteriogram of six-month pony foal	65
(14) Plain radiograph of thorax of yearling Thoroughbred colt	66
(15) Pulmonary arteriogram of yearling Thoroughbred colt	67
(16) Pulmonary venogram in yearling Thoroughbred colt	68
(17) Control exposure of yearling Thoroughbred colt	69
(18) Pulmonary arteriogram of yearling Thoroughbred colt	70
(19) Pulmonary arteriogram of yearling Thoroughbred colt	71
(20) Dorsoventral radiograph of isolated right lung of 18-month Thoroughbred gelding	74
(21) Dorsoventral radiograph of isolated right lung of 2 year old Thoroughbred filly	75

LIST OF FIGURES

Page No.

- | | |
|-------------------------------------------------------------------------------------------------------------------------------------------------------------------------------|----|
| (22) Photographs of sections of fixed lung from
2 year old Thoroughbred filly | 76 |
| (23) Dorsoventral radiograph of the isolated left lung
of a horse following fume fixation and infusion
of aqueous barium sulphate into the pulmonary
arterial system | 77 |
| (24) An enlarged view of a section of Fig.23 showing a
comparison of arterial and venous branching patterns | 78 |
| (25) Lateral radiograph of horse's lung field demonstrating
main anatomical features | 85 |
| (26) Cardiac area of lung demonstrating perihilar details | 86 |
| (27) Demonstration of position of carina relative to
aorta and pulmonary artery by bronchography | 87 |
| (28) Radiograph highlighting the position and course
of the main pulmonary arteries | 88 |
| (29) Demonstration of position of pulmonary veins on
the thoracic radiograph | 89 |

LIST OF TABLES

	Page No.
(1) Subgross Morphology of Horse Lung compared with that of seven other species Adapted from Tyler <u>et.al.</u> ,(1971)	17
(2) Summary of Bronchographic Technique and Results	36-38

RADIOGRAPHIC ANATOMY OF THE EQUINE LUNG

INTRODUCTION

Radiological examination of the horse's thorax is currently performed in veterinary practice as an aid to diagnosis in the various respiratory and cardiovascular disorders affecting this species. In the past, interpretation of these radiographs has relied heavily on operator experience, rather than radiological criteria established through scientific investigation, this being substantiated by the lack of literature on the subject (Kangstrom, 1968; King, 1980).

It is the aim of this study to characterise as accurately as possible the anatomy of the heart, lungs and pulmonary vasculature routinely visible on equine thoracic radiographs. It is hoped that some of the principles established here will be of value in the development of specific interpretative criteria, essential if objective universal appraisal of equine thoracic radiographs is to be achieved.

It was evident from an examination of the current literature at the outset of this study that adaptations to a number of standard radiographic techniques would be needed to establish these criteria in the horse. Consequently, modifications to the techniques of bronchography, angiography and fume fixation of horse lungs were developed to provide the basic information on anatomy and spatial relationships of structure within the lung

so that correlations could be made with routine thoracic radiographs.

From this information a set of radiographic anatomical criteria was established including a detailed description of the various elements present on thoracic radiographs. A clear understanding of the anatomical associations between the various structures visible in the normal situation was considered essential to enable accurate extraction of information from thoracic radiographs of horses with respiratory conditions. However no attempt was made to correlate the "signs" of respiratory disorders recognised on human, canine and even equine thoracic radiographs with the described patterns of radiographic anatomy since such a study was felt to be beyond the scope of a Master's thesis.

CHAPTER I - LITERATURE REVIEW

Thoracic Radiology

A. General

Thoracic radiology is a major diagnostic tool used extensively in human medicine and by the veterinary profession on the small domestic animal species.

Much information is available on the radiographic recognition of disease patterns in humans and small animals. There appears, however to be a lack of knowledge regarding understanding of anatomical, physiological and pathological changes associated with thoracic radiography in large animals. In order to achieve accurate diagnosis of lung disorders using radiology as the diagnostic method, a better understanding of the fundamental anatomy and associated radiological patterns is essential. Once the fundamental features of pattern change have been determined, disease processes and their associated radiological changes should become easier to identify.

B. Plain Radiology

(i) Small Animal Species

Thoracic radiography has been performed in cats and dogs for many years resulting in an abundance of literature on technique and interpretation. The normal radiographic profile in the healthy dog has been clearly described (Douglas, 1970), whereas morphological changes associated with age, as detected by radiography, were reported by Reif and Rhodes (1956).

Suter (1966) attempts to enhance the reader's understanding of both lower airway disease and pulmonary parenchymal disease as they are manifest on thoracic radiographs. In another report, a system of identifying changes in disseminated densities characteristic of certain basic disease patterns in small animal thoracic radiographs is described (Suter and Chan, 1968). The four structural units affected within the lung form the basis of this classification, i.e. -

1. Alveolar
2. Interstitial
3. Bronchial
4. Vascular

Recognition of these patterns aids in the eventual diagnosis of disseminated pulmonary diseases in small animals as the majority of these disorders in dogs and cats can be accurately grouped to the radiological pattern they exhibit.

In human medicine such groups of diseases, exhibiting a particular pattern when viewed radiographically have been designated as "gamuts" (Felson, 1961). This grouping of diseases based on radiographic patterns can also be applied to the interpretation of canine and thoracic radiographs (Suter, 1966).

Feline thoracic radiographs have been accepted as being anatomically similar to those of the dog with the exception of some minor variations, such as the bronchial walls which, owing to their thinness in the cat, are difficult to visualise on thoracic radiographs (Suter and Chan, 1968; Lord, 1976).

(ii) Large Animal Species

The literature contains few reports of thoracic radiography in cattle. A technique has been described for lateral thoracic radiography in standing adult cattle (Lee,1974). A resume of the normal radiological anatomy of the bovine lung field and a description of the radiological features of several cattle respiratory diseases including parasitic bronchitis, bovine farmers lung, bronchopneumonia and chronic pneumonia was also given. A similar radiographic technique has been used to diagnose tuberculosis, traumatic pericarditis, pneumonia and pulmonary oedema in cattle and buffalo (Bhargava and Tyagi,1975).

A literature search revealed few relevant articles on the use of thoracic radiography in the horse. Difficulties involving restraint, equipment demands, lack of follow up information and cost are probably responsible for this void. A paper presented by Boltz (1936) describes the radiographic anatomy of the equine lung, including a description of the technique for standing lateral thoracic radiography in the horse as well as the interpretation of the spatial relationships of the vessels, airways and associated anatomical structures. A primitive method for equine bronchography also appears, The radiographic appearance of aspiration pneumonia, gangrenous pneumonia and carcinoma of the pleura in large animals was described by Gruner and Siegert (1955). The radiographic technique adopted by Boltz was utilised by these authors.

Williams et. al.,(1965) reported a technique for studying the equine heart in the lateral standing view. In this report, a high

KV, low exposure time technique was employed in conjunction with a synchronised tube-cassette system. Adoption of this method in thoracic radiographs of 28 horses and one donkey enabled pneumonia to be diagnosed in all animals examined (Kangstrom, 1968). Two radiographically distinct forms of pneumonia in horses were described.

- (a) Pneumonia without abscesses; with diffuse areas of tissue consolidation in the ventrocaudal lung area, often accompanied by increased vascularity and thickened bronchial walls.
- (b) Pneumonia with well delineated abscesses spread throughout the lungs, seen radiographically as dense, often consolidated areas of parenchyma.

Rendando et.al., (1979), in a brief resume of the normal radiographic anatomy of the equine chest described the spatial relationship of the major thoracic structures. A series of four case histories were presented with associated radiographs and discussion aimed at improving diagnostic efficiency from thoracic radiographs.

In many instances, general references to the usefulness of radiography are made by authors writing articles on respiratory diseases in the horse, but seldom are specific examples of technique or results cited (Cook,1976; Beech, 1979).

C. Bronchography

Bronchography is a technique by which the airways of the lung can be highlighted by the infiltration of radiopaque contrast media.

This method not only facilitates clinical diagnosis but enhances appreciation of the anatomical and spatial relationships of bronchial structures visible on radiographs.

(i) Human Bronchography

Early reports on bronchography in the human patient using dry Bismuth powder as the contrast agent (Jackson, 1918) preceded the use of iodinated poppyseed oil which was to become the medium of choice with the development of techniques. Iodinated poppyseed oils were not without problems and these agents were shown to induce anaphylactic reactions and acute iodism when utilised for bronchography (Sumner, 1951).

Difficulties were encountered with ensuring adequate deposition of bronchographic contrast agents into the airways. Carboxymethyl-cellulose (CMC) was found to possess a low surface tension which when combined with radiographic contrast agents as a transport medium, considerably enhanced penetration of the contrast materials within the airways (Morales et.al., 1948). A later study of the tissue reaction to the most commonly used bronchographic materials namely CMC, poppyseed oil and peanut oil concluded that none of these materials induced chronic changes in rabbit lung tissue (Christifordis et.al., 1967).

Barium sulphate solutions containing CMC were found to be excellent contrast agents for the purpose of bronchography and had the advantages of low cost, rapid clearance from the lungs following administration and no obvious inflammatory reaction occurred with their use (Teixiera et.al., 1959; Nelson et.al., 1959; Willson et.al., 1959; Nelson, 1964).

Bronchography was later attempted utilising an inhaled nebulised solution of barium sulphate and CMC (Shook et.al., 1970). Inhalation bronchography has the advantage that the airways are only lined with contrast material rather than being filled, thus facilitating rapid elimination of the radiopaque material, as well as inducing less respiratory distress during the entire procedure. The radiographic detail obtained by this method is as good, if not superior, to liquid bronchography because a double contrast effect is produced owing to the presence of the air in the bronchial lumen.

More recently inhalation bronchography using powdered Tantalum as the contrast agent has become more widely accepted. This element is approximately 25 times more radiopaque than the iodinated compounds and the minor amount necessary for good bronchographic visualisation does not affect pulmonary function (Schlesinger et. al., 1975). Tantalum is biologically inert so stimulates no inflammatory response at the mucosa, and is eliminated rapidly from the lungs. Its disadvantages however include cost and tendency towards spontaneous combustion when agitated in the presence of oxygen (Nadel et.al., 1968; Llamas, 1969; Pickard et.al., 1970; Gamsu et.al., 1971; Friedman, 1972; Bianco, 1974; Schlesinger, 1975; Dilley and Nadel, 1976).

Trapnell and Gregg (1969), in a retrospective study on at least 100 human bronchograms described several important interpretative criteria. The normal bronchus was described as being a tubular shadow with its walls being coated with contrast material while its lumen is filled with air. The bronchial walls are approximately

parallel although they taper slightly towards the periphery.

Bronchography may highlight three signs suggestive of bronchial obstruction, these being; incomplete or absent peripheral filling of bronchi with contrast material; a "solid" bronchial shadow; or bubbles of air in the bronchus. Loss of parallelism of bronchial walls indicates abnormality, for instance bronchiectasis .

Bronchography proves an invaluable aid to the early diagnosis of human pulmonary carcinoma. Signs indicative of abnormal bronchi which may be due to neoplastic invasion include bronchial amputation; stretched or bent bronchi; asymmetrical narrowing of a bronchus; or indentation of the airway (Rinker et. al., 1968).

(ii) Canine Bronchography

Bronchography was used as a diagnostic technique in the dog as early as 1959. Douglas and Hall (1959) reported a method of performing bronchography in the anaesthetised dog using propylidone solution as the contrast medium, but little interpretive material was presented.

Inhalation bronchography in the dog involving the introduction of dry micronised barium sulphate into the airways of an anaesthetised patient was described by Meyers and Nice (1963). Good quality bronchograms were obtained using this method especially when dry "Methocel" (CMC), was introduced to the airways prior to the administration of the contrast agent. The barium sulphate appeared to be rapidly cleared from the lungs as post bronchographic films taken at 24 and 48 hours revealed no residual contrast material. This was substantiated by post-mortem histological examination.

One dog received approximately 50 times the recommended dose of barium sulphate but showed no ill effects and clearance time was approximately 48 hours.

The coating effect of the various inhaled radiopaque materials on the airways of dogs was compared and it was reported that insufficient contrast was obtained with powdered barium sulphate, dionosil oily, lipiodol, and various water soluble contrast materials (Johnson and Howland, 1968). However when a barium sulphate, Methocell and saline suspension was delivered as an aerosol, satisfactory bronchograms were produced. No adverse reactions to this method were recorded. The following year Clement (1969) substantiated this work by demonstrating that satisfactory bronchograms could be produced in the dog by using powdered methylcellulose and barium sulphate suspension delivered by a nebulizer coupled to a positive pressure respirator. The contrast agents were cleared rapidly from the airways if CMC was used to prepare the mucosa. Conversely if this agent was not utilised, the quality of the bronchogram was poor and clearance of contrast material slower.

The use of the bronchographic agents propylidone (Dionosil oily) and aqueous barium sulphate suspension (Redi-FLOW) in the dog was reported by Meyers et.al., (1974). These authors concluded that the quality of the bronchogram was superior when barium sulphate was used to that obtained with Propylidone. Clinically, a mild cough persisted for 24 - 48 hours following bronchography, with both materials. Propylidone appeared to be cleared more rapidly from the airways than barium sulphate and little significant residual contrast material remained after 12 hours when further radiographs

were taken. Histological examination of post mortem sections two months following bronchography showed retention of barium sulphate to be greater than that of propyliodone but pulmonary reaction to the former was less severe.

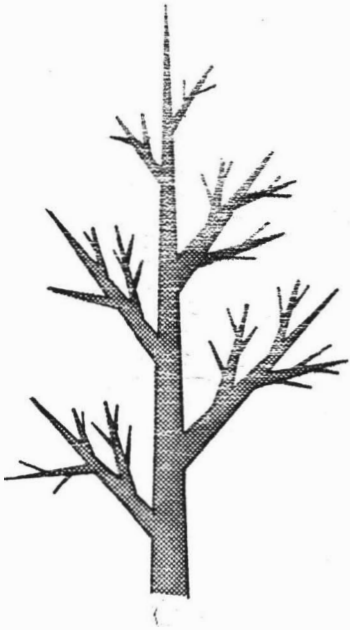
The quality of bronchograms obtained following administration of aqueous propyliodone in the dog under various anaesthetic regimes was documented by Clarke and Webbon (1977). They concluded that anaesthetic techniques involving neuromuscular blocking agents, with intermittent positive pressure ventilation being applied, produced superior quality bronchograms in the dog when compared with other anaesthetic techniques.

The same authors reviewed bronchography in normal healthy dogs. Using their previously described anaesthetic technique they concluded that gross changes in airway structure such as bronchiectasis or stenosis were the only constantly reliable signs of bronchographic abnormality. These correlated with features seen in human bronchography associated with early bronchial disease.

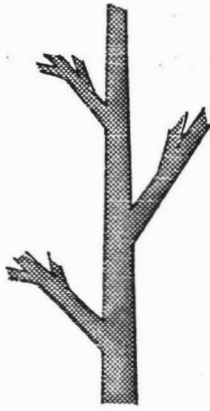
Interpretation of normal canine bronchograms was revised by Douglas (1970). He attempted to outline those criteria which may differentiate between faulty techniques and findings which may correlate with clinical disease.

The normal bronchus when outlined by contrast material appears to have a lumen with a tubular shadow due to the coating of the bronchial wall with contrast. The bronchial walls although gradually tapering, are approximately parallel (Fig.1.).

FIGURE 1 : Diagrammatic Representation of Bronchograms
both normal and abnormal (Adapted from Douglas,1970)



a. The ideal bronchogram. Bronchi have smooth tapering walls with a hollow lumen.



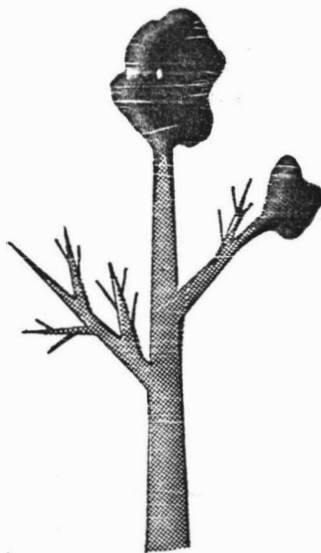
b. Insufficient contrast agent. No peripheral spread of contrast. No accumulation within lumen.



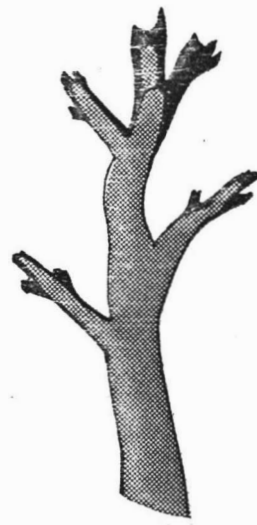c. Blockage of bronchi by inflammatory exudate. With or without the presence of air bubbles



d. Alveolar filling. Rare phenomena associated with prolonged anaesthesia



e. Gross bronchiectasis.



f. The irregular dilation and blockage seen in severe chronic bronchitis.

The appearance of the bronchi in various forms of lung pathology and in poor bronchograms was well illustrated.

The captions on the diagram are adapted from this paper and outline the basic qualities of a good bronchogram along with the common reasons for failure to obtain a satisfactory bronchogram.

(iii) Large Animal Species

The use of bronchography in the larger animal species including horses and cattle appears to have been minimal. A literature search revealed little significant information on the subject. However Boltz (1936) described a method of introducing liquid bronchographic agents via a tracheotomy tube to a conscious horse, with apparent enhanced visualisation of the main airways and little retained contrast on subsequent radiographs.

More recently however bronchography was attempted in four adult mixed breed horses (Walker et.al., 1980). The horses, having been immobilised with intravenous succinyl choline were intubated and were positioned obliquely in dorsal recumbency. Approximately 100-130ml of 100% w/v premixed barium sulphate suspension was insufflated into the caudo dorsal aspect of one lung. The horses recovered quickly allowing a standing lateral radiograph to be made. Excellent bronchograms were obtained with bronchial visualisation being possible to the level of the 6th generation. Elimination of barium from the lung was rapid as noted by serial radiographs following the procedure, and histological examination of lung tissue following post-mortem six weeks later indicated a very mild inflammatory response.

2. Anatomy of the Lung

a) Gross Anatomy

In order to develop an understanding of spatial relationships between vessels, airways and other structures depicted in thoracic radiographs, a basic understanding of the gross and subgross pulmonary anatomy is essential. Since this study is mainly concerned with the horse, the gross pulmonary anatomy of this species will be described.

Hare (1975), gives an anatomical description of the equine lung. Unlike lungs of other species, notably the dog, horse lungs are not subdivided into distinct lobes by fissures. Instead they are divided bilaterally, into diaphragmatic and cardiac (apical) areas, with an accessory lobe on the right side. In the horse, the lung occupies only a small proportion of the area between the ribs. The abdominal organs are situated well forward, with the diaphragm having a prominent concave curvature projecting cranially into the thoracic cavity. This is an important feature to be considered when radiographing the horse thorax as it tends to limit the field of view to the immediate perihilar area while obscuring detail in the periphery.

b) Subgross Anatomy

The primary function of the mammalian lung is to effect respiratory exchange. To perform this task adequately it possesses multiple thin walled distensible air sacs connected by a series of relatively rigid passages to the exterior. The large conducting tubes or bronchi lie outside the lung parenchyma but enclosed within interstitial tissues.

Horsfield et.al., (1968) reported the results of an investigation into the branching system of the bronchial tree in man. The authors concluded that in human airways the branching system in successive generations down to 0.7mm diameter is one of asymmetrical dichotomy. This system is one in which there is variation in the lengths or diameters of the branches in a given generation or a variation in the number of divisions down to the end branches, or a combination of these two.

Distal to this, as far as and including the respiratory bronchioles, branching is by symmetrical dichotomy, where the number of branches in successive orders doubles. Respiratory bronchioles give rise to alveolar ducts by further dichotomous branching, terminating in alveolar sacs. The branching pattern in this region is basically asymmetrical dichotomy but becoming more irregular in the distal area of the alveolar sac, probably because morphology is influenced by the need for space filling of the respiratory exchange units (Parker et.al.,1971).

The same authors, postulate that the reason for the change in morphology of the airways is related to respiratory function. As one progresses distally from the primary bronchi, mass flow becomes less important and molecular diffusion more significant as the means of gas flow. Distally there becomes an increase in cross sectional area as a combined result of the rapid increase in number of branches and their less rapid decrease in diameter, facilitating gas movement by molecular diffusion.

McLaughlin et al., (1961) in a review of subgross lung structure in seven mammalian species showed marked species variation in vasculature and parenchymal arrangement within the lung. These authors questioned the validity of much of the earlier work on respiratory anatomy in humans, which by extrapolation presumed human lung structure to be similar to various animal models. Using latex injection specimens and vinylite corrosion casts as models, the seven species were grouped into three basic types based on pleural structure and the amount of supportive connective tissue within the lung (Table 1). (Adapted from Tyler et al., (1971).)

Type I (cow, sheep and pig) have a pulmonary structure characterised by very thick pleura and intrapulmonary connective tissue septa extending almost continuously from the pleura to the hilar region. This feature, in effect, divides the lung into well demarcated secondary lobules. The terminal air passages are mostly classified as terminal bronchioles with few respiratory bronchioles being present. As the degree of secondary lobulation is considerable in these species (communication between lobules is minimal) a pronounced effect on pulmonary disease patterns is produced.

Study of the general bronchovascular relationship within the lungs of the species examined demonstrated that in animals of the type I group, because of the well developed connective tissue structures, the airways, arteries and veins are confluent throughout their course to the distal regions of the lung.

Table 1 : Subgross morphology of horse lung compared with seven other species

Species	Lobules	Pleura	Typical Distal Airway	Structures supplied by the Bronchial Artery
I. Cattle Sheep Swine	Completely separated Extensive interlobular connective tissue	Thick	Terminal bronchiole Respiratory bronchioles are rare	Bronchi, vasa vasorum of PA & P Pleura and interlobular tissue
II. Dogs Cats R.Monkey	Very poorly defined Little interlobular connective tissue	Thin	Respiratory bronchiole Terminal bronchioles are short.	Bronchi, vasa vasorum of PA & P
III. Horse Man	Incompletely separated Extensive interlobular connective tissue	Thick	Terminal bronchiole Respiratory bronchioles are rare and poorly developed	Bronchi, vasa Vasorum of PA & P Pleura and interalveolar tissue Some interalveolar septa

The monkey, dog and cat show a different pattern of subgross pulmonary anatomy, Type II. Lungs of these species have thin pleural lining with absence of septal structures and reduced supportive tissue structure. Consequently, lobulation of the lung is not noticeable to the degree seen in Type I lungs.

Another contrasting feature between type I and II groups is that of the pattern exhibited by the distal airways. There appear to be no terminal bronchioles in group II species but there are well developed and numerous respiratory bronchioles leading into larger alveolar ducts. In contrast to the type II pattern, the bronchi and pulmonary artery follow a parallel route throughout the tissue whereas the pulmonary vein appears to follow a more direct route to the hilus.

Several differences in the vascular supply to the lung extremities were described by McLaughlin et.al., (1961). In the lungs of types I and III, the pleura and interlobular septa, which are thick, derive their arterial supply from the bronchial artery. In the lungs of type II, the pleura is thin and the arterial supply is provided by the pulmonary artery. The airways of all three types are supplied by the bronchial artery which in turn terminates at the level of the distal bronchiole. Group I vessels show some degree of bronchial artery - pulmonary artery anastomoses whereas this feature is not seen in species included in group II.

The horse and the human lung which form the third classification, Type III, occupy an intermediate position when compared to the other

species in the study. This type is characterised by possessing a moderately thick vascular pleura hence giving an incomplete lobular septal pattern.

In both man and horse the distal airways appear to be related closely to group I possessing both terminal bronchioles and poorly developed respiratory bronchioles. The vascular arrangement in these species appears to be a composite of group I and II patterns with the bronchial artery supplying the pleura, distal airways and alveoli, and also forming anastomoses with the pulmonary artery.

Krahl (1959) reports on the occurrence of alveola pores (pores of Kohn) in man and laboratory animals, and the presence of bronchiolar - alveolar communications in cats and humans. These structures play an important role in the development of pulmonary disease as they allow both the spread of microorganisms and the existence of collateral ventilation. From the interpretation of the subgross anatomy of the lungs in the species studied, the human and equine pulmonary structures seem to be closely related. Horses, therefore, would seem to be the animal of choice for respiratory experiments if any inference or extrapolation to the human were to be made (McLaughlin et.al., 1961).

For example, Thurlbeck (1964) in his paper entitled "Heaves in Horses", made many comparisons with this classical syndrome in the horse to diseases in man with similar clinical and pathological features. Asthma, farmers lung, and eosinophilic pneumonitis

all appear to be very closely related to "Heaves". In other species, similar conditions seem to be less frequent, perhaps a feature related to the functional anatomy of the structures.

3. The Interpretation of Pulmonary Radiographs based on Pattern Recognition.

In human radiology several authors have devised a diagnostic approach based on radiographic patterns of the lung (Felson, 1973). Various authors have applied this approach to the interpretation of pulmonary disease in small animals (Suter et.al., 1968; 1974). The basic principles are simple and might be suitable for extrapolation to interpretation of equine thoracic radiographs.

Disseminated pulmonary densities can be divided into four basic patterns, bronchial, vascular, alveolar and interstitial. This assumes that all changes in pulmonary density on radiographs are due to an increase or decrease in air, blood or parenchymal tissue.

(a) The vascular pattern:

The vascular structures are the most easily discernible densities visible on the normal chest radiograph, but whether they are of venous or arterial origin is often difficult to determine, particularly towards the periphery of the lung lobes.

On plain radiographs the veins appear less radiopaque (Milne, 1973). The vessels can be differentiated on the basis of orientation and characteristic appearance. On small animal thoracic radiographs,

vessels leading to the atrium are identifiable as veins (Suter et.al., 1968). The left pulmonary artery and its branches are readily recognisable, in lateral radiographs. In dorso-ventral plates the large vessels lateral to the bronchi are predominantly arteries.

In the peripheral lung field it is very difficult to differentiate between arteries and veins on plain radiographs because the vessels are so small and follow parallel paths. Peripheral vasculature will become more discernible if the area has a higher than normal flow rate, for example, in the case of secondary hypervascularity following damage elsewhere in the lung.

Another feature which aids in differentiation between pulmonary arteries and veins in humans is the fact that the arteries run a sinuous course towards the periphery, tapering as they progress distally and having an irregular dichotomous type branching. In contrast, veins show a somewhat "blocky" appearance, i.e. the walls appear to be parallel rather than tapering. The diameter of the veins appears to increase more abruptly as branches join the main vessel in essentially a monopodal fashion (Fig.2) (Milne, 1973).

Felson (1973) states that in human chest radiographs, the pulmonary arteries have more branches than the veins and follow the bronchi more closely, the sum of the diameters of the branches being always greater than the diameter of the parent artery.

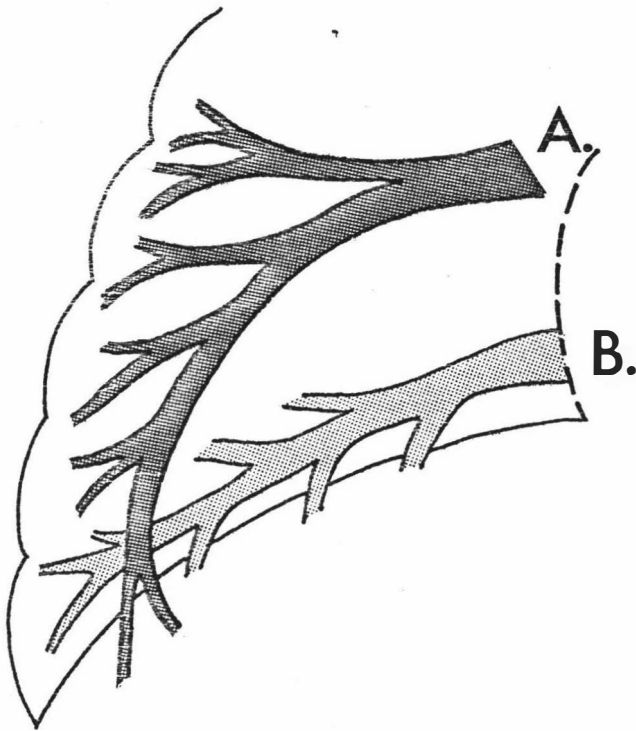


FIGURE 2 : (From Milne, 1973)

- A. Arterial characteristics : Smooth tapering walls
with dichotomous branching
- B. Venous characteristics : Parallel sides with tendency
to monopodal branching

Milne (1973) has documented radiographical anatomical features which aid in differentiation of arteries and veins in the human, but he relates vascular densities to rib shadows on radiographs. Extrapolation of this work to animal radiography is not possible because of the basic anatomical differences and the effect of posture on circulation.

There are two major factors to be considered when analysing vascular patterns on pulmonary radiographs. Firstly one should ascertain whether the arterial or venous component is involved or perhaps both. Secondly one should also be able to gauge whether the vascularity is normal, increased or decreased.

(b) The Bronchial Pattern :

Although the bronchial system is best visualised by means of bronchography, the radiolucency provided by the air in the lumina of the larger bronchi and the radiodensity of their walls are often recognisable amidst the profusion of shadows at the lung hilus. This is true for the horse and dog, but in cats and humans the relative thinness of the bronchial wall makes identification of the bronchi difficult in normal lungs (Lord, 1976).

Dense, thin, parallel lines or ring-like structures mark the appearance of the bronchi in the hilar area of the equine and canine lung (King, 1980). In all other regions of the lungs the radiolucency of the air in the alveoli and the radiodensity of the interstitial tissue and vascular markings obscure the bronchial shadows on the radiograph. However, if there is gross

pathology present in the bronchi or parenchyma the airways may become more visible (Suter and Lord, 1974).

An increase in the thickness of the wall and calcification of the cartilagenous portions of the bronchi in older dogs, particularly the so-called chondrodystrophic breeds further enhances visibility of these structures (Reif, et.al., 1966). Plain radiographs of dogs with bronchiectasis may show bronchial walls which have become thickened and irregular with saccular dilatations and possibly exudates. Bronchography provides a better diagnostic tool in these cases.

Thickening of the bronchial markings and loss of their distinctness on plain radiographs are manifestations of bronchial and peribronchial disease (Suter, et.al., 1974). These workers also proposed a correlation between the intensity of bronchial changes and chronicity and severity of clinical signs. The bronchial lumen may be dilated or irregular in diameter, with the term bronchiectasis only being designated to the permanent abnormal tubular or saccular dilations which are associated with chronic lung disease.

(c) The Interstitial Pattern :

The architectural framework of the lungs is the interstitial tissue which forms the supporting structure for the bronchi, lymphatics, blood vessels and alveoli. Interstitial diseases enhance the visibility of these densities by the deposition of collagenous or fibrous material or by increasing their fluid content. Although blood vessels and bronchial structures form part of the interstitial framework they possess their own recognisable radiographic patterns.

The interstitial pattern is the least definite of all the patterns seen on thoracic radiographs. Extensive and clinically serious involvement of the interstitial tissues may occur in the presence of radiographically normal lungs or there may be considerable interstitial involvement evident on radiography but no clinical manifestation (Felson, 1973).

Suter et al., (1974) state that there are two types of interstitial radiographic patterns to be differentiated in dogs. The first consists of an increase of pulmonary density lacking a definite structure. This type is associated with abnormalities in interstitial structures which cannot be detected individually (unstructured diffuse pattern).

Type I or unstructured interstitial density is distinguished by the following radiographic changes : (Suter et al., 1974).

- (a) decreased radiolucency of the parenchymal area of the lung field, usually showing generalised or perihilar distribution
- (b) the bronchial lumina show increased lucency ("air bronchograms")
- (c) diminished contrast between parenchyma and vascular structures or "vascular smudging"
- (d) small reticular or nodular densities dispersed throughout the parenchyma between the vascular structures.

The contrast of the lung field is decreased in this pattern due to the increase in the ratio of interstitial tissue to alveoli, hence giving an increased pulmonary density overall. A reticular linear pattern with intensified fine granular nodules and a general

Lack of distinctness may be the manifestation of an acute massive involvement of the lymphatics during neoplastic metastasis (Suter et.al.,1968).

The second type of interstitial pattern is characterised by radiographic changes of the interstitial tissue which are manifest as nodular or short linear structures, although both types are due to the summation of abnormal densities within the lung parenchyma.

The type II interstitial pattern is characterised by discrete changes within the architecture of the parenchyma and may show some of the following features on plain radiographs (Suter et.al., 1974).

- (1) Many evenly distributed, poorly demarcated nodular densities (2-5mm diameter) or commonly called miliary nodules (e.g. fungal diseases, tuberculosis, neoplastic metastasis).
- (2) Variable numbers of well to discreetly delineated, rounded nodules (3-30mm diameter) (e.g. primary or metastatic neoplasms, fungal diseases).
- (3) Reticulonodular density manifest as small irregular opacities, consisting of short, linear or reticular densities which may be illdefined, (e.g. lymphosarcomas, primary disseminated lung tumors, pulmonary fibrosis).
- (4) Radiolucent areas surrounded by strands of interstitial tissue giving the impression of a honeycomb. This sign is rare in small animals (e.g. associated with bronchiectasis and focal pneumonias, fibrosis after various types of chronic lung disease (bronchopneumonia, bronchitis)).

The pattern of miliary nodulation is often a characteristic sign that haemic spread of disease has occurred within the lung parenchyma. Differential diagnosis must be made between the nodular densities of interstitial disease and dilated vasculature seen end on (e.g. dirofilariasis) or the presence of bronchiectasis with fluid accumulation. The correlation of small irregular opacities with lung disease should be made with caution as similar patterns are commonly seen as part of the normal ageing process in small animals (Reif, 1966).

(d) The Alveolar Pattern :

In the normal lung, the air filled alveoli provide the contrast medium or background against which the vascular tree may be seen on the thoracic radiograph. When the alveoli are involved in disease processes their lumens may either become filled with transudates, exudates, cellular material or in the case of atelectasis, the alveolar sacs collapse. In this situation the inherent air contrast is absent so a change is seen on pulmonary radiographs. There are several characteristics which enable the radiologist to differentiate this alveolar pattern from those patterns associated with bronchial, vascular and interstitial disease. The following features may be present either alone or in combination : (Suter et.al., 1968; Felson, 1973; Suter et.al., 1974; Lord, 1976)

- (1) As the alveoli become filled with cells or liquid, their radiolucency is diminished due to air displacement. Consequently the area of affected alveoli appears on the radiograph as a patch of increased density against the normal radiolucency of the remaining pulmonary tissue. Other structures, for

example the vasculature, become obscured by the increased alveolar density in contrast to the interstitial pattern in which the increase in lung density is not usually sufficient to mask the vessels as the background alveoli still contain air. The typical radiographical appearance of alveolar disease is that of homogenous, mottled pulmonary density with illdefined fluffy margins.

- (2) There is a tendency for these "blotchy densities" to coalesce with adjacent lesions, due to the high degree of permeability of the lung tissue.
- (3) With alveolar flooding, the normal pulmonary structures become obscured due to the overlying densities. The air in the bronchi however, becomes visible against the dense background as well defined radiolucent branching stripes, the so-called "air bronchogram". One must be careful not to misinterpret the lucent air space between vessels on normal radiographs as being "air bronchograms".
- (4) A similar principle occurs in which groups of relatively normal air-filled alveoli stand out in contrast to surrounding radiodense diseased tissue giving the typical "air alveologram".
- (5) There are some patterns of distribution of pulmonary infiltrates which may suggest alveolar disease.
 - (a) The alveolar pattern is often noticeable on a segmental or lobar basis with tendency of the lower margins to become more visible as they present a barrier to disease spread.
 - (b) In some cases of bronchopneumonia, small alveolar nodules may appear adjacent to a bronchus. This is because there

is involvement of a respiratory bronchiole and its associated alveolar ducts and alveoli. These must be differentiated from neoplastic nodules which do not show peribronchiolar distribution nor do they coalesce (Lord, 1976).

(c) In human pulmonary oedema, there is commonly a bilaterally symmetrical pattern involving the hilar and middle zones of the lung field, a feature which is markedly evident on dorsoventral thoracic radiographs as the so-called "butterfly" pattern (Felson, 1973).

(6) The majority of alveolar diseases are of an acute nature, appearing rapidly and disappearing equally rapidly. This is in part due to the nature of the infiltrates involved. Alveolar infiltration by blood, transudates and exudates is common whereas interstitial tissue infiltration is usually fibrous and cellular hence more chronic in development.

Confusion may arise between the hazy or "smudgy" interstitial pattern and the alveolar pattern. The former may be differentiated by its lesser density and visualisation of the major vasculature. Frequently though, the two patterns may occur concurrently.

4. Lung Fixation

In order to study functional anatomy of the lung both grossly and microscopically it is desirable to compare the in vivo and in vitro situation.

If one attempts to examine the collapsed lung either grossly or histologically, a very unnatural situation is produced. It is also difficult to compare post mortem radiographs of lungs with those seen in the living animals as the inherent natural contrast of the air in the bronchial tree is lost. It is hence desirable to examine the postmortem specimens in a more natural situation, i.e. inflated.

Radiographs of inflated lungs following careful dissection provide useful information on airway and vascular distribution and relationships. Such information can then be correlated with radiographs obtained from the living animal, enabling more accurate anatomical assessment.

A recent study by Wright et.al., (1974) outlines the limitations of the methods of fume fixation of human lungs. These are briefly :

1. Injured lungs will not stay inflated due to the passage of gas through the perforation.
2. If hot formalin vapour is passed into cold lung tissue,(Weibel and Vidone, 1961) the steam will condense within the lung, hence producing a wet fixation technique possibly resulting in unsatisfactory fixation of the upper parts of the lung.
3. If the lung is not fixed externally, the tissue may decompose before the formalin diffuses to the extremities.

Wright et.al., (1974) therefore developed a technique of fixing the lungs in a closed box containing heated 40% formaldehyde. The

atmosphere inside the container is always saturated with formalin vapour thus preventing tissue drying. An external circuit is used to draw saturated hot vapour from inside the container via a pump and back into the cannulated bronchus. The atmosphere reaching the lungs is saturated with water vapour at lung temperature so the lung neither dehydrates or becomes water-logged.

The pump is regulated to deliver vapour to the lungs at regular intervals i.e. the lungs are actually required to breathe in the vapour, then allowed to deflate naturally, resulting in better penetration of the gas. As the lungs fix, the ventilation amplitude decreases so adjustments need to be made in the pumping cycle.

Satisfactory radiographs can be taken of the gross lung structure as well as from sliced specimens mounted on perspex. Comparison of both antemortem and postmortem radiographs allow lesions and anatomical structures to be localised within the parenchyma.

This method seems to produce rapid fixation with the minimum of distortion, yet enabling both radiological and histological studies to be undertaken adequately.

CHAPTER II - MATERIALS AND METHODS

1. Plain Radiography of the Thorax

In order to utilise a minimum exposure time technique for thoracic radiography, horses were sedated beforehand. Acetyl Promazine* (0.1 mg/kg intramuscularly 15 minutes prior to radiography) or Xylazine** (3-5ml/100kg intravenously 5 minutes prior to radiography) were utilised. The tranquillised horses were then placed beside a wall on which was mounted an adjustable cassette holder.

An Elema-Shonander Triplex Optimatic 1023 D.E. Xray apparatus with a 200 Kv, 1,000 mA, three phase generator was used for this study together with Agfa Gevaert Curix RP2 fast film and Dupont Quanta II Screens (35cm x 43cm). To prevent scatter, a focussed grid (grid ratio 12:1, 40 lines per cm) was positioned at a film/focus distance of two meters. For most adult horses (400-500kg live weight) the range of exposure was : 75 - 90 kV delivered at 20 - 40 mAs for 0.05 - 0.13 seconds, depending on age, body condition and thoracic thickness. Every attempt was made to coincide the exposure with maximum inspiration to enhance the benefit provided by the natural inherent contrast within the thorax.

* Acepromazine 10% solution for injection

**Rompun(Bayer) 2% solution for injection

Accurate positioning of the Xray tube was essential in order to obtain adequate exposure of the thorax. No attempt was made to radiograph the most cranial portion of the lung field owing to the extra difficulties of positioning. Neither was any attempt made to obtain dorsoventral projections of the thorax. Exposures were taken from both sides, with at least two exposures on each side to encompass the majority of the lung field caudal to the heart. For cardiac (cranioventral) exposure the Xray tube, mounted on a telescopic ceiling crane, was focussed on a point over the sixth rib, directly caudal to the olecranon. The diaphragmatic (caudodorsal) exposure was taken with the tube focussed at the level of ribs 9-10 approximately 15-20cm below the withers.

2. Correlative Study involving Special Procedures

A) Pulmonary Angiography

Pulmonary angiography was attempted in six foals all of which were less than one year old, thus enabling a single exposure for the whole thoracic area.

Initially, attempts were made to obtain pulmonary angiograms in the conscious standing animal utilising a lateral thoracic exposure. The horse was tranquilised as previously described, and the skin over the extended jugular vein desensitised with Xylocaine 2%. A polythene catheter approximately 2 metres long with internal diameter 5mm was introduced into the external jugular vein via a metal cannula. The catheter was fed into the vein as far as the heart where it was manoeuvred into the right ventricle

(ascertained by a pressure change of 3-4" of blood in the external catheter when held vertically). With some difficulty the catheter was then manipulated into the pulmonary artery.

A plain thoracic radiograph was taken with the patient in a standing position (film/focal distance two metres) as a control exposure. A standard pressure injector which had been modified to hold 120 mls of contrast agent was used. Approximately 120 mls of Sodium Iothalamate* was injected under pressure into the pulmonary artery via the catheter in a time span of 0.5 sec. An electronic timer enabled radiographs to be taken one second following introduction of contrast.

The patient reacted so violently to the contrast entering the pulmonary circulation that this method was abandoned in favour of a similar technique in anaesthetised animals.

Anaesthesia was induced using a combination of glycerol guaiacolate (100mg/kg) and Thiopentone (5 mg/kg) intravenously following premedication with Acetylpromazine (0.1mg/kg). Maintenance of anaesthetic was with Halothane delivered via a to and fro semiclosed anaesthetic apparatus.

* Conray 420, Sodium Iothalamate inj. 70% W/V, May and Baker, equivalent to 420 mg. iodine per ml.

A catheter was introduced into the pulmonary artery as previously described and exposures taken with the cassette placed beneath the foal's thorax. Successive exposures were taken at 0.5, 1, 2 and 4 seconds following contrast injection.

B) Bronchography

A total of 26 horses (Table 2) were subjected to the experimental procedure, several of these animals undergoing the procedure two or three times. To fulfill the criteria outlined, the method chosen required insufflation of the bronchial tree with a dry radiopaque powder.

Initially powdered tantalum metal was tested as the contrast medium, however this proved unsatisfactory in the form supplied by the manufacturers owing to the very small particle size, resulting in poor mucosal retention of the particles. Satisfactory results were then obtained by substituting finely powdered barium sulphate for the tantalum metal.

After testing several techniques the following was deemed satisfactory. Firstly, the trachea was intubated by passing a stomach tube via the nose and ventral nasal meatus, and with a little manipulation passing the tube the "wrong way" down the trachea to some 10 to 12cm above the carina. For an adult horse of approximately 500kg, 120-160gms of barium sulphate powder* mixed with 5-7gms of powdered methyl

* Micropaque powder - Nicholas Laboratories, Ltd., Slough, SL1, 4AU, England

TABLE 2 - Summary of Bronchographic Technique and Results

Horse	Clinical Condition	Age (Yrs)	Sex	Approx Weight(Kg)	BaSO ₄	Methyl Cellulose	Local Anaesthetic	Atropine ^b	Result	Max.No. ^c Bronchial Generations Visible	Mean No. ^c Bronchial Generations Visible	Comments on Bronchograms.
1	Chronic coughing	24	F	450	120gm	12gm	No	No	Good	7-8	5-6	Good ventrally (Bronchitis) Dyspnoea following bronchography.
2	Contracted tendons	2	F	300+	110gm	4gm	No	No	Good	10-11	7-8	Dorsally poor filling.
3	Wobbler	2	MC	400	130gm	4gm	No	No	Moderate	9-10	8-9	Coughed - good peripherally poor centrally.
4	Polyarthritis	1	M	250	100gm	2gm	No	No	Good	12-13	7-8	Upper zones poorly outlined
5	Wobbler	1	F	200	100gm	2gm	No	No	Poor	6-7	4-5	Poor dorsally. "Alveolar" retention at P.
6 ^a	Ethmoid haematoma	7	MC	600	120gm	3gm	No	No	Moderate	7-8	6-7	Very thin coating - Insufficient BaSO ₄ .
8	Fracture of tibia	1	F	200	100gm	3gm	No	No	Excellent	10-11	8-9	Incomplete dorsal filling. "Alveolar" retention at P.
9 ^a	Wobbler	1	M	380	120gm	3gm	No	No	Moderate	5-7	4-5	Poor peripheral filling. Insufficient BaSO ₄ .

Horse	Clinical Condition	Age (Yrs)	Sex	Approx Weight(Kg)	BaSO ₄	Methyl Cellulose	Local Anaesthetic	Atropine ^b	Result	Max.No. ^c Bronchial Generations Visible	Mean No. ^c Bronchial Generations Visible	Comments on Broncho-grams
10 ^a	Neurological disorder	4	MC	500	120gm	3gm	Yes	No	Moderate	8-9	6-8	Good ventrally poor peripherally.
11 ^a	Ringbone	16	MC	550	120gm	4gm	No	No	Moderate	5-7	4-5	Good filling but flocculation from delay.
12 ^a	Normal	4	M	450	120gm	4gm	No	No	Poor	4-5	3-4	Insufficient BaSO ₄ - poor retention.
13	Wobbler	1yr 6mth	MC	380	80gm	6gm	No	No	Poor	10-12	8-9	Coughed - good peripherally but poor centrally.
14	Fractured cerv.spine	4	MC	450	120gm	6gm	Yes	Yes	Good	7-8	5-6	Insufficient BaSO ₄ .
15	Septic Arthritis	Aged	F	350	120gm	4gm	Yes	No	Poor	4-5	3-4	Coughed - Insufficient BaSO ₄ .
16	Navicular Disease	9	MC	300	120gm	6gm	Yes	No	Good	9-10	7-8	Thin even coating - poor dorsally.
17	Fractured scapula	10+	MC	500	160gm	5gm	Yes	No	V.Good	12-15	10-11	Marked Broncho-constriction.
18	Ringbone	6	MC	450	150gm	6gm	No	No	Good	10-11	7-8	Very good ventrally-poor dorsally -some flocculation.

Horse	Clinical Condition	Age (Yrs)	Sex	Approx Weight(Kg)	BaSO ₄	Methyl Cellulose	Local Anaesthetic	Atropine ^b	Result	Max.No. ^c Bronchial Generations Visible	Mean No. ^c Bronchial Generations Visible	Comments on Broncho-grams.
19	Fracture Fetlock	8mth	M	150+	80gm	3gm	Yes	No	Mod-Poor	8-10	6-8	Extreme broncho-constriction.
20	Spine injury	9	MC	450	200gm	4gm	Yes	no	Poor	5-6	4-5	Flocculation and contrast loss from cough.
21	O.C.D.	1	M	380	160gm	8gm	No	Yes	Good	10-11	6-8	Good ventral detail - no constriction.
22	Navicular disease	15	MC	500	160gm	7gm	No	Yes	Mod-Good	8-10	5-6	Insufficient BaSO ₄ -coughed-Flocculation.
23	Normal	2	MC	400	120gm	6gm	No	Yes	Excellent	12-13	10-11	Very even coating except dorsally.
24	Experimental brood mare	Aged	F	450	200gm	6gm	No	Yes	Good	10-11	8-9	Very good ventrally-some flocculation.
25	Experimental brood mare	Aged	F	500	200gm	6gm	No	Yes	Good	15-16	10-12	Some "Alveolorization" of contrast.
26 ^a	Mitral regurgitation	Aged	MC	450	160gm	6gm	Yes	Yes	Good	8-10	7-8	Marked bronchodilatation-thin coat only.

a - Histology performed

b - 15mg Atropine Sulphate I.V.

c - Approximate visual assessment only.

cellulose, was delivered to the lungs from an ether vaporizer* connected to a compressed air supply (Fig.3). Air pressure was adjusted to produce a continuous cloud of powder in the vaporizer which then passed via the stomach tube to the lungs. Agitation of the vaporizer during insufflation improved the density of the cloud.

Attempts were made to co-ordinate the shaking with the inspiratory effort in those horses in which this phase of respiration was readily apparent. On average the barium sulphate/methyl cellulose mixture could be instilled over the period of 50 to 100 spontaneous respiratory efforts.

Radiographs of the thorax were taken immediately. Delays of even five minutes reduced the quality of the bronchograms obtained as a result of presumed muco-ciliary activity in the bronchi.

Attempts to anaesthetise the bronchial mucosa using a 10% aqueous solution of Xylocaine administered by atomizer** via the tracheal tube proved unsatisfactory as the degree of anaesthesia obtained was insufficient to prevent coughing when the tube was removed. In addition the Xylocaine appeared to induce bronchospasm as measured by the diameters of the bronchi in the resultant bronchograms. The incorporation of 5mg of isoprenaline in the anaesthetic solution was ineffective in preventing this complication.

* N.Z.Industrial Gasses, Private Bag, Wellington, New Zealand.

**Bennett Twin 2814 Nebulizer, Bennett Respiration Products Ltd., 1265 Beatrice Street, Los Angeles, California, USA.

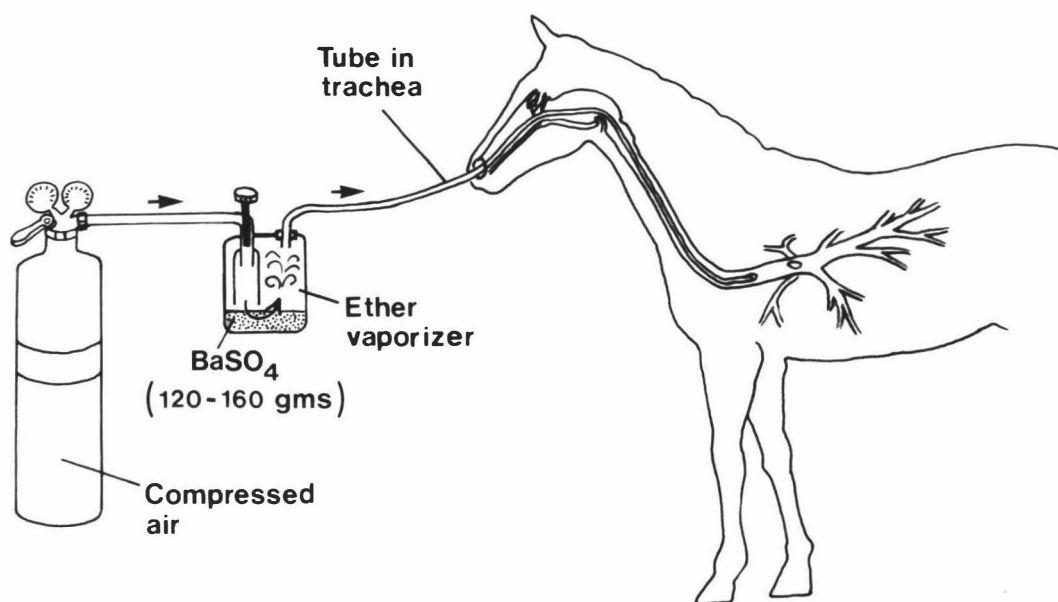


Fig. 3 Diagram of the system for delivering powdered barium sulphate to the lungs. Air delivered under pressure from the cylinder causes agitation of the powder in the ether vaporizer creating a cloud of contrast material which is blown down the intra tracheal tube under pressure. Agitation of the vaporizer during inspiration helps to improve the density of the contrast suspension in the container.

Atropine sulphate, the standard human premedication for bronchography, although indicated because of its bronchodilatory effect, was not used in the early stages of these experiments as potential drying of the bronchial mucosa was felt to be a disadvantage with powder insufflation, since this method relies on the adherence of the contrast material to the bronchial walls. However, later in the study an intravenous injection of 15mg of atropine sulphate after intubation and immediately prior to insufflation markedly increased bronchial diameters improving the definition and perception of the bronchial branching pattern but decreasing the amount of the barium coating adhered to the mucosa.

Immediately following insufflation the tube was removed and two left lateral thoracic radiographs were taken (diaphragmatic area, cardiac area). In some animals a further pair of right lateral radiographs were also taken to enable identification of right and left structures. Horses were then radiographed hourly for three to five hours or until no further contrast material was visible in the lung area. Further radiographs were taken at 24 hours and some animals were followed radiographically for up to two weeks in order to evaluate any pulmonary sequelae. Immediately following the procedure and over the total period of observation all horses were boxed and closely observed for changes in clinical condition, particularly those referable to the respiratory system.

Autopsies were performed on all animals at periods ranging from 24 hours to two weeks following the last procedure, however,

attention was focussed mainly on six horses undergoing only a single bronchogram. Selected areas from these lungs were submitted for histology, after preservation in the inflated state by a modification of the formalin gas method of Wright et.al., (1974).

3. Morphological Study of Isolated Equine Lungs

A) Embalming of Lungs

An enlarged simplified device similar to that used by Wright et.al., (1974) by which hot formalin vapour is used to fix whole isolated lungs was constructed.

The lungs from several normal horses were isolated carefully at necropsy ensuring no damage occurred to the thin pleural envelope. Approximately three inches of trachea was left attached to the lungs at necropsy, following removal of the heart and its attachments.

The isolated lungs were then firmly fixed to a cannula mounted on the perspex lid of a large stainless steel embalming vat (Fig.4). The cannula was connected by a wide bore metal tube within the vat to a water trap which was located beneath the surface of the embalming fluid. The wide bore tube had an external connection to a circulating air pump, (diaphragm pump designed to operate in wet corrosive conditions) calibrated to an automatic timer to deliver vapour for a set time interval to simulate breathing. The isolated lungs were suspended over a solution of warmed

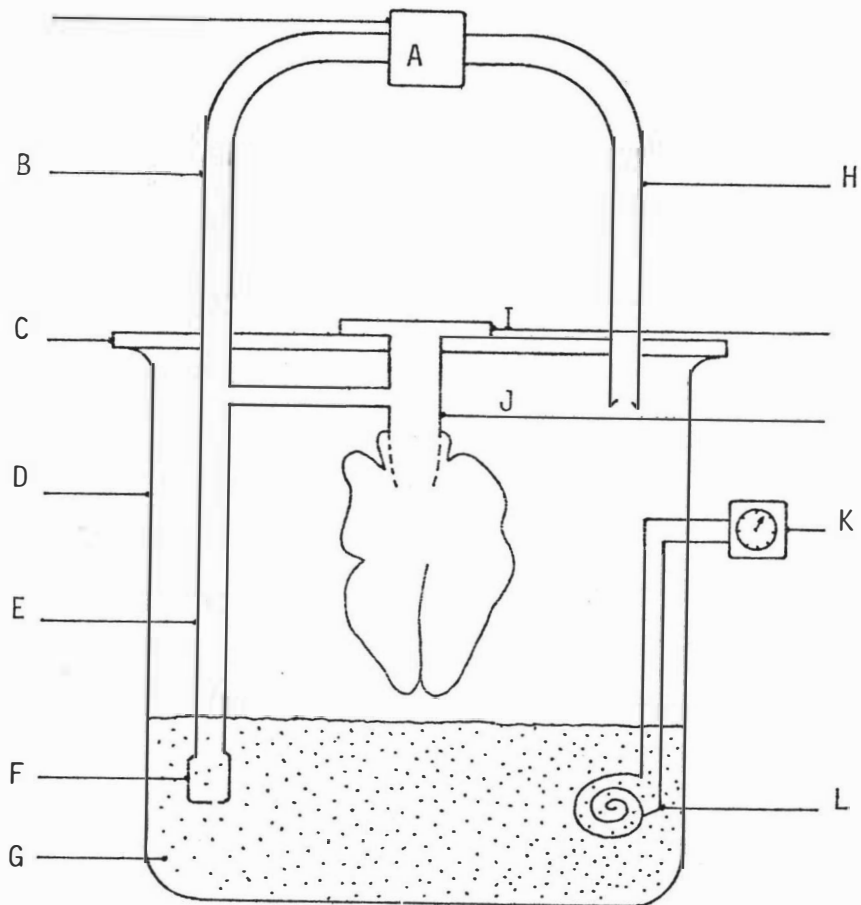


FIG. 4. Diagram of System for Embalming Equine Lungs.

- A. Circulating air pump
- B. Vapour inlet tube
- C. Perspex lid
- D. Stainless steel vat
- E. Wide bore metal tube
- F. Water trap
- G. Formalin liquid (40% aqueous)
- H. Vapour outlet tube
- I. Strengthened metal suspension plate
- J. Cannula
- K. Thermostat
- L. Heating element.

aqueous 40% formaldehyde solution within the sealed vat with an internal temperature maintained at 45⁰C.

Heated formalin saturated vapour was drawn from the vat and subsequently delivered to the lungs via the pump and wide bore tube described above in a cycle designed to simulate breathing.

Internal fixation of the lung tissue was thus facilitated by the introduction of saturated formaldehyde vapour via the airways. External tissue fixation also occurred due to the penetration of formaldehyde vapour within the vat. Water vapour condensing in the circuit is removed in the air trap so the airways remain essentially dry as they are fixed. The degree of inflation was monitored visually and pressure maintained at a constant level by way of a pressure valve coupled to a manometer in the circuit.

As fixation of the lung tissues occurs, the amplitude of inflation decreases and excess vapour escapes via the water trap.

Approximately 3-5 days was necessary for complete fixation of all lung tissue, at which time the inflated lungs had the consistency of a hard sponge.

B. Investigations on Embalmed Lungs

(i) Plain Radiography

Exposures were made on Agfa Gevaert Curix RP1 film in Dupont Quanta II rare earth screens at a film focus distance of 105cm.

(a) Dorsoventral exposure : The embalmed lungs were laid on a protected cassette and with foam blocks held in a position

approximating the in vivo situation. Each half of the lung was exposed separately on a 35 x 43cm film, using exposure factors of 40 kV, 250 mA for 0.1 seconds.

(b) Lateral exposure : Each lung was radiographed separately in a horizontal lateral position following dissection into right and left segments. Exposure factors of 40kV, 320 mA for 0.1 seconds were utilised to approximate the exposure obtained during a normal lateral thoracic radiograph.

(ii) Use of Contrast Agents in Embalmed Lungs

A mixture of bariumsulphate solution* and gelatin was poured via a cannula into either the bronchi, pulmonary arteries or pulmonary veins with the lungs held in a vertical position. The gelatin/contrast mixture was given time to set in the vessel or airway lumens and radiographs were taken using exposures previously described for isolated lungs.

(iii) Histological Analyses

Preserved inflated lungs were sliced into sections approximately 1cm thick using a sharp knife, and subsequently analysed for anatomical purposes.

Tissue blocks were sectioned from these slices for histological examination. Such blocks were further fixed in 10% formalin for 72 hours before histological processing in the usual manner.

* Micropaque

CHAPTER III - BRONCHOGRAPHY IN THE HORSERESULTS

Bronchograms were considered satisfactory when bronchi down to the seventh or eighth generation were visible over two-thirds of the lung area. This degree of success was obtained in 80% of the procedures attempted (Table 2, p.36) (Fig.6). The major cause of failure to obtain satisfactory bronchograms was coughing, resulting in loss of contrast from the main bronchi, but leaving adequate contrast material in the more peripheral branches (Fig.7). Unsatisfactory bronchograms were also produced by delay in taking the exposure, either as a result of slow insufflation or difficulty in positioning a horse for the thoracic radiograph. In these cases flocculation of the contrast material occurred in the bronchi probably as a result of early muco-ciliary activity. Conversely, the best bronchograms were produced when insufflation of the barium sulphate was most rapid and delays minimal, i.e. less than ten minutes from the beginning of insufflation until exposure.

The bronchograms produced exhibited satisfactory double contrast with little entire filling of bronchi except in the most ventral portions of the lung. In many cases the dorsal branches of the diaphragmatic lobe were poorly outlined owing to gravitational effects (Figs. 6, 8, 9, 11). In some animals there was evidence of severe broncho-constriction as evidenced by the very thin thread-like bronchial branches radiating away from the main bronchi (Fig. 7). The intravenous injection of 15mg of atropine immediately

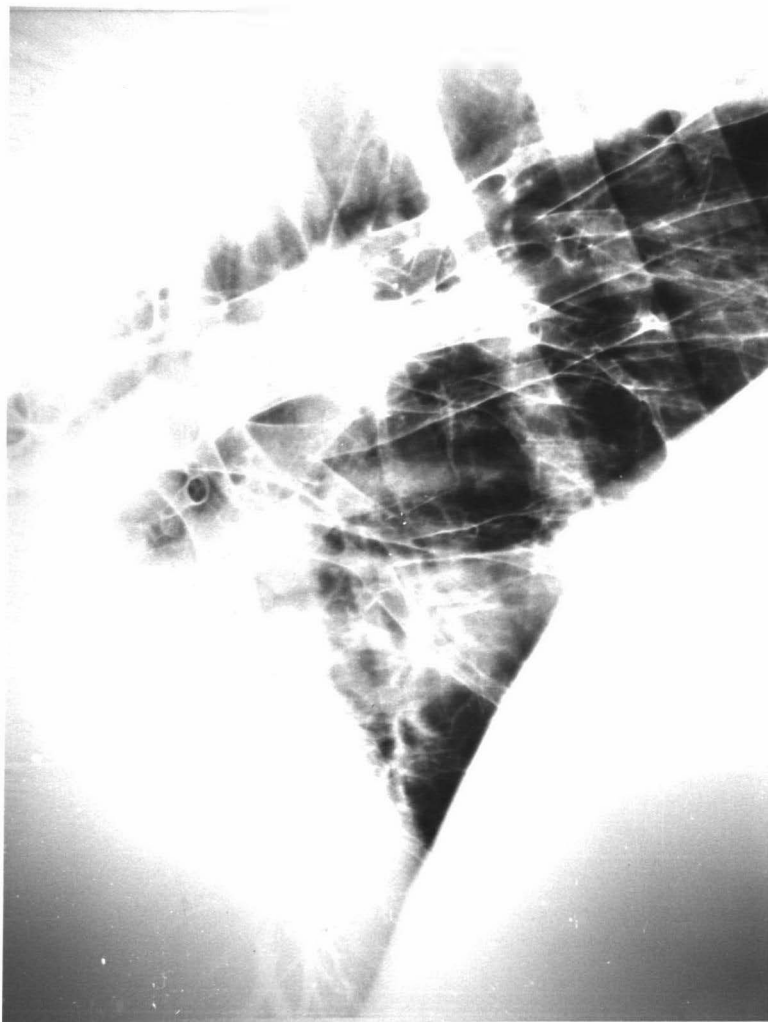


Fig. 6 Bronchogram in an adult horse demonstrating good bronchial detail down to the seventh generation in the ventral part of the diaphragmatic area. Note that in this case there has been poor filling of the dorsal branches of the diaphragmatic bronchi.

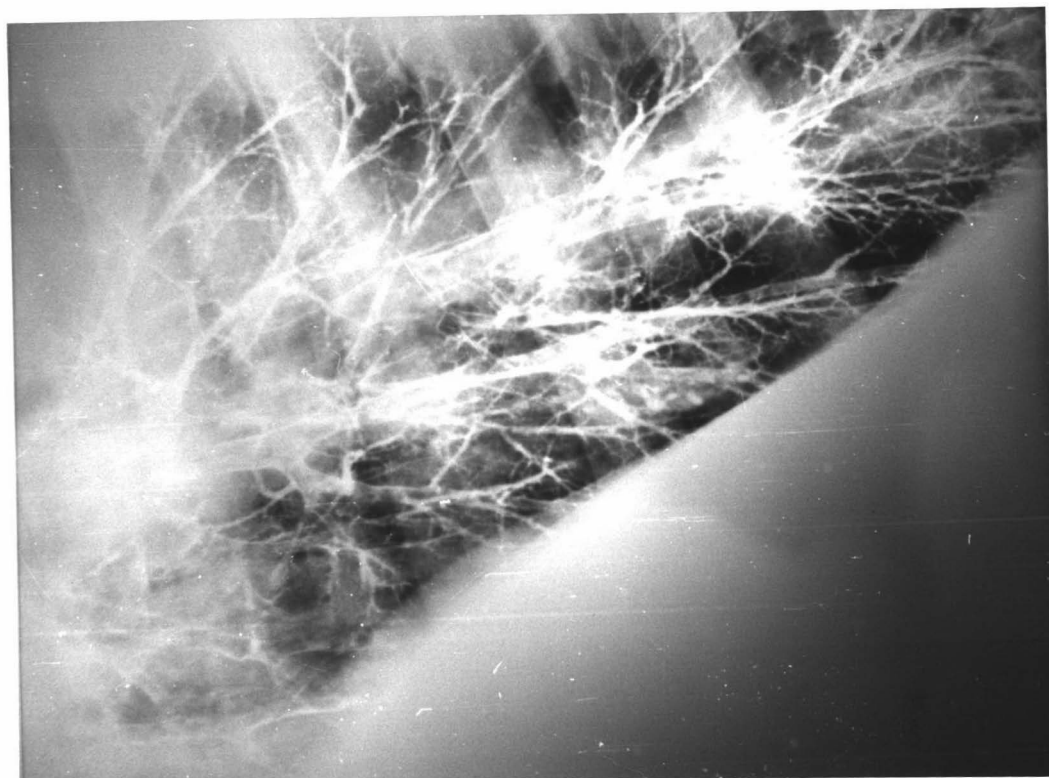


Fig. 7 Bronchogram demonstrating the two major difficulties encountered with the dry powder technique (a) marked broncho-constriction which has not impaired bronchial filling to the seventh and eighth generations and (b) poor opacification of the main bronchi as a result of coughing prior to the exposure.

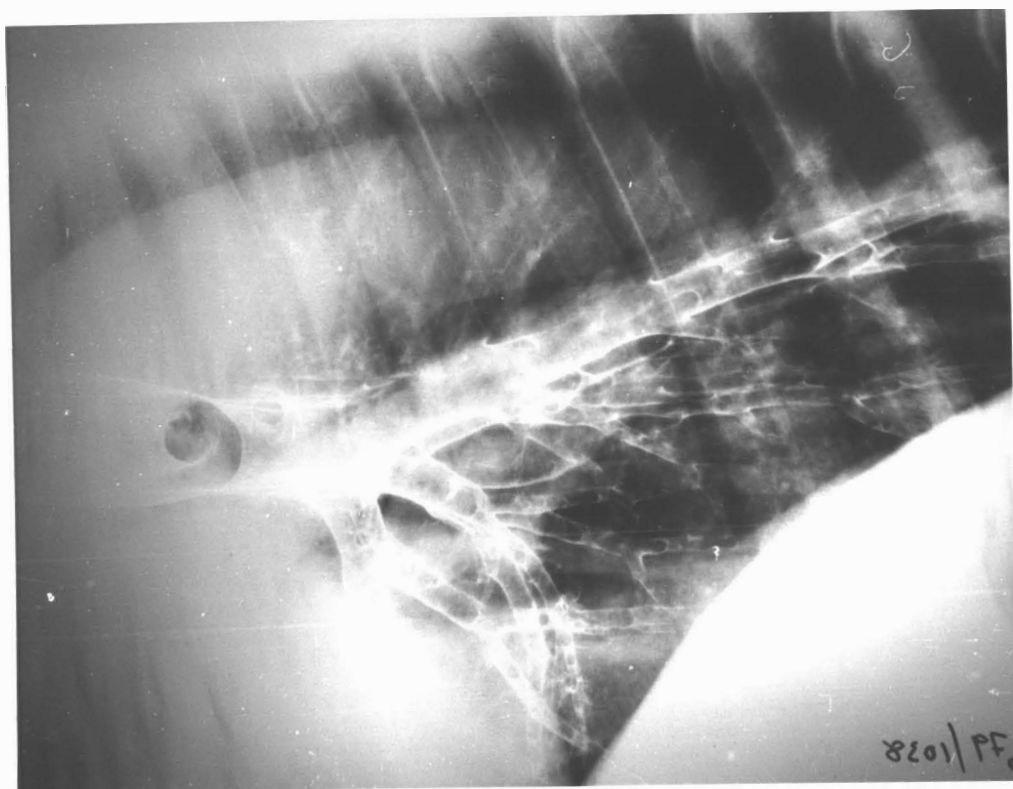
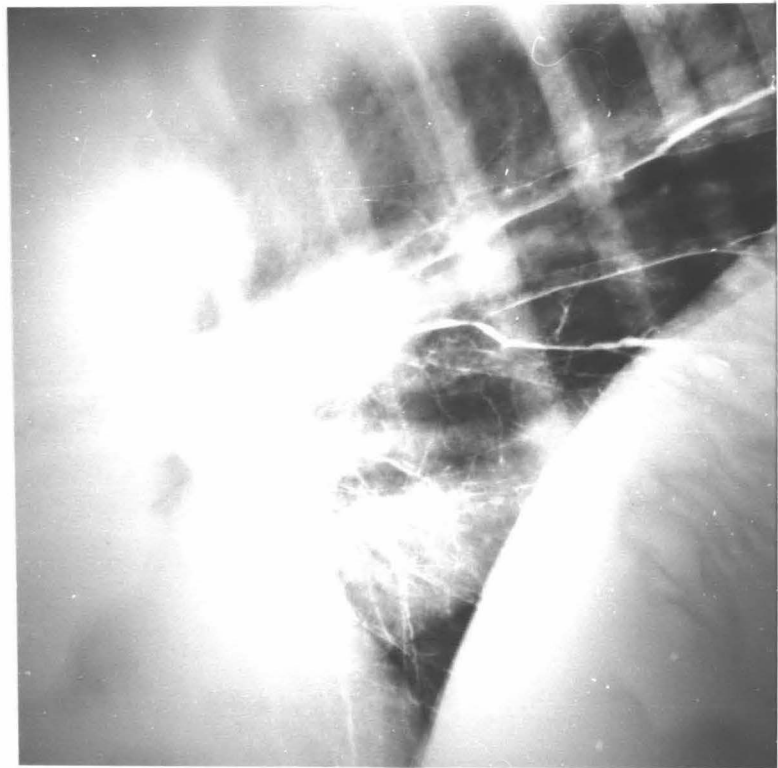
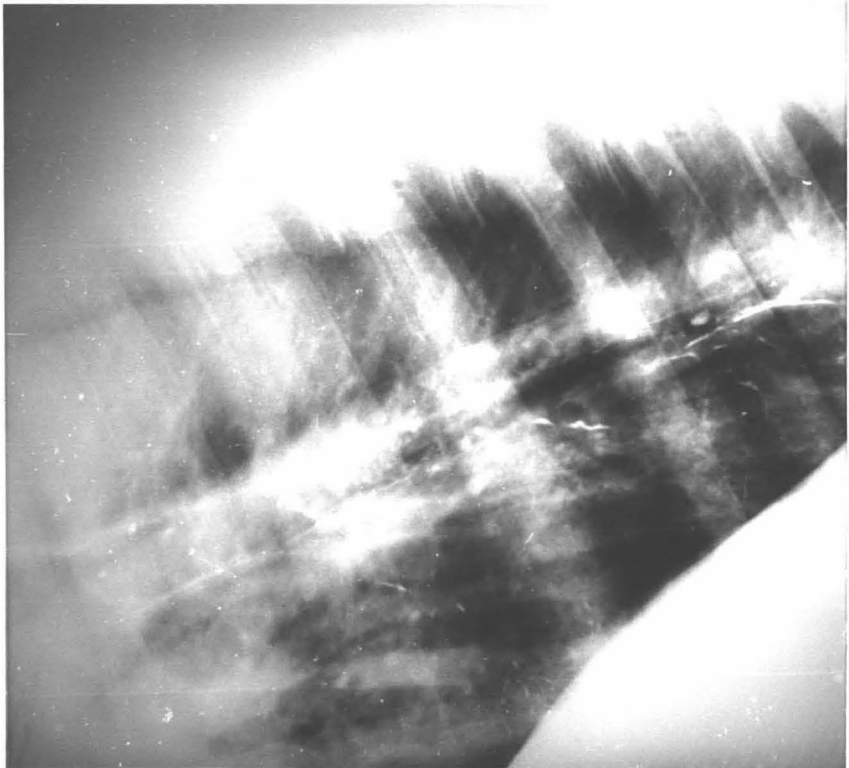


Fig. 9 Bronchogram of a 24 year old mare with a history of chronic cough. This radiograph demonstrates one of the more important signs of chronic bronchitis, namely "loss of parallelism" and slight ballooning of the bronchial walls between branches.

A.



B.



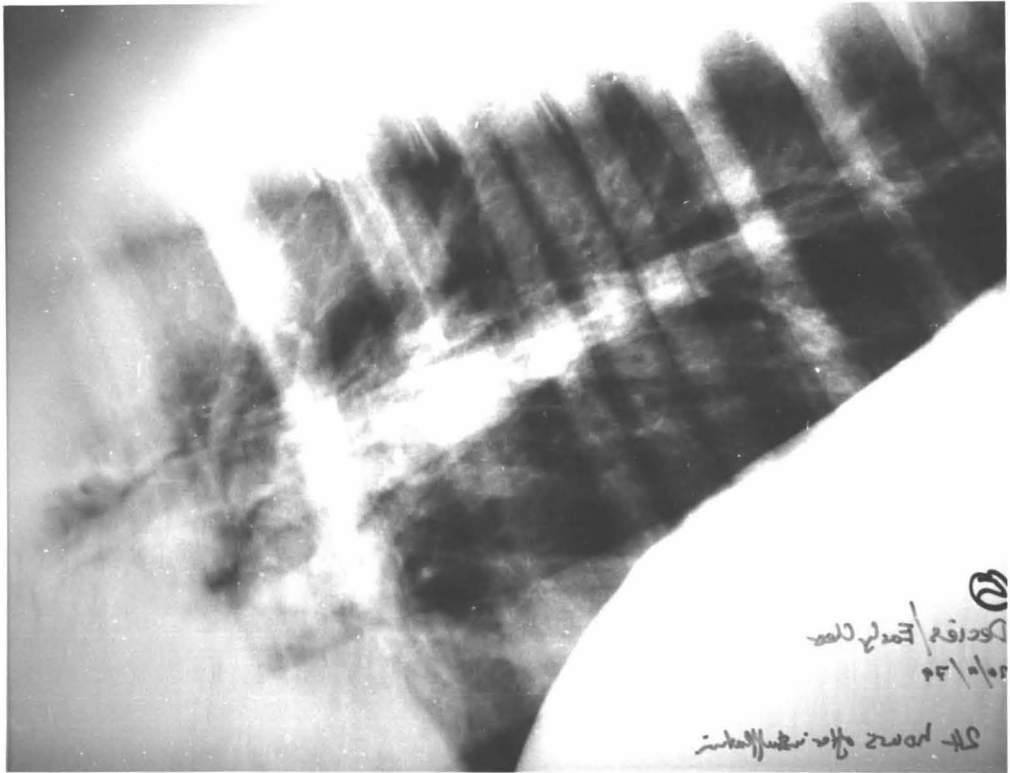


Fig.10

A.B.& C. Radiographs taken at 20 minutes, 3 hours, and 24 hours post bronchogram in a two-year old gelding with no history of respiratory disease.

In A, the barium sulphate can be seen accumulated on the ventral floor of the upper diaphragmatic bronchi while more ventrally the double contrast effect remains.

In B, at three hours virtually all the barium has been eliminated and bronchial walls are becoming difficult to distinguish.

In C, at 24 hours barium is no longer evident and apart from marginal perivascular haze these lungs appear relatively normal.

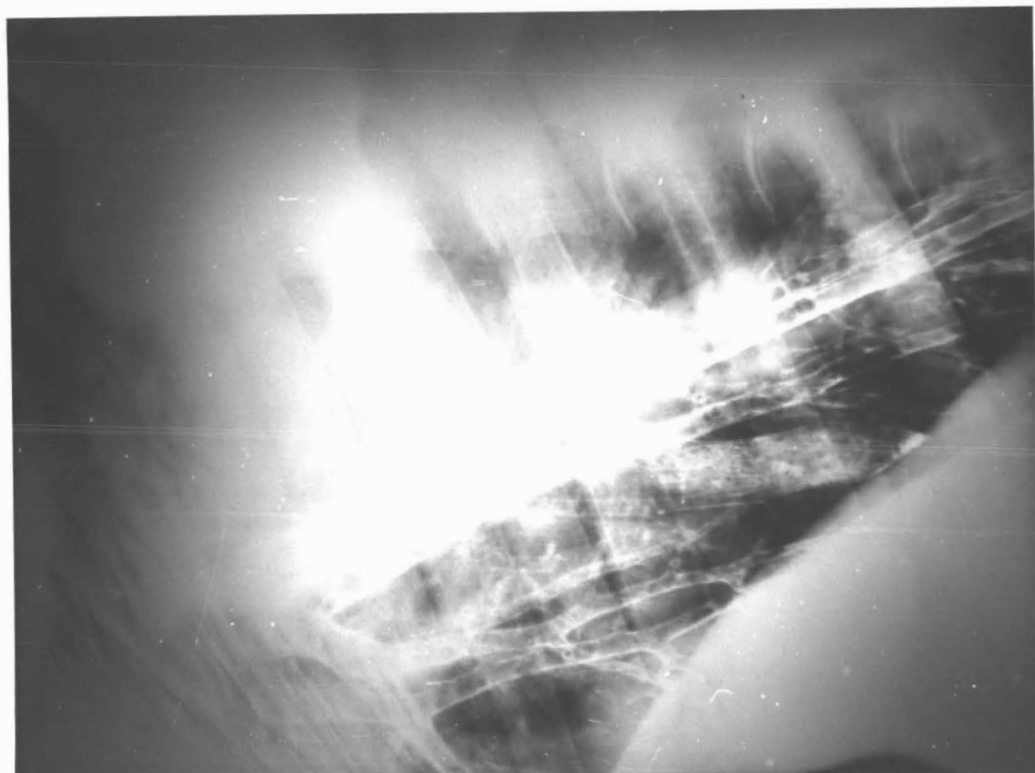


Fig. 11 In this bronchogram taken 10 minutes post insufflation a large bolus of barium sulphate can be observed in the thoracic oesophagus adjacent to the diaphragm.

prior to insufflation alleviated this problem.

The pattern of bronchial branching appeared to vary considerably more in this essentially normal group of horses than appears to be the case in other species (Fig. 8(A) and (B)). In the one clinical case examined, a 24 year old mare with a history of a chronic cough of several years duration, the major signs of chronic bronchitis were evident. These included distinct loss of parallelism of the bronchial walls and moderate dilatation of the bronchi between bronchial intersections (Fig.9) (Nelson and Christofordis, 1973). However, other signs of bronchitis seen with liquid bronchographic techniques such as bubbles in the bronchi (Douglas, 1974) were not observed using the double contrast technique. According to more recent work (Webbon and Clarke, 1977) these gross structural changes may be the only reliable signs of bronchographic abnormality, at least in dogs.

Elimination of Barium

Elimination of the contrast material was extremely rapid. No barium was detected radiographically in the bronchi of any horse after five hours and in the majority of cases it was virtually all eliminated after three hours (Fig. 10 (A) (B) and (C)). Elimination appeared to begin very early and the combination of muco-ciliary transport and active coughing was thought to account for the rapid loss of contrast material. Even in the earliest taken exposures there was often a substantial amount of contrast material in the thoracic oesophagus (Fig.11).

In only one horse (No.25), given 200 gms of barium sulphate a small area of "alveolar" retention was observed on the initial radiograph. In two other sets of lungs radiographed at post mortem small quantities of barium were seen in the alveoli of the lung peripheries which were not detected on radiographs taken prior to euthanasia.

Histological Response

Histologically there appeared to be a very mild response to the barium sulphate, similar to the reaction reported in humans (Nelson, Christofordis and Pratt, 1964) and other experimental animals (Clements, 1959). The cellular response appeared to be even milder than that described by Walker and Goble (1980) for a group of four horses undergoing barium sulphate suspension bronchograms. In the one animal sacrificed after 24 hours congestive changes predominated. After three days vacuolated bronchial epithelial cells were apparent lining 50% of the bronchioles which also contained a mucoid protein-like substance, presumed to be retained methyl cellulose. Macrophages were seen free in this substance. After 7-8 days slight peribronchial lymphoid hyperplasia was noted in one animal while in another a moderate foreign body macrophage reaction was seen in the peribronchiolar alveolar spaces. These spaces contained foamy macrophages and a crystalline material which was probably barium sulphate. By two weeks post bronchography there remained areas of focal thickening of the alveolar walls and small numbers of foamy macrophages containing foreign material. No evidence of pulmonary fibrosis was noted.

None of the histological specimens examined revealed cellular reactions likely to induce clinical signs or produce permanent sequelae.

DISCUSSION

Inhaled barium sulphate powder proved a most satisfactory contrast medium for the production of diagnostic bronchograms in the horse. Previous workers have encountered major technical difficulties in performing bronchography in man and the dog using either aqueous or oil suspensions of organic iodides (Rinker et.al., 1968; Trapnell and Gregg, 1969; Douglas, 1974; Clarke and Webbon, 1977). In this study satisfactory bronchograms were produced with a minimum of effort, an absence of detectable sequelae and without the need for immobilisation and special positioning as in the study of Walker and Goble (1980). Noxious effects were confined to only one animal. Transient dyspnoea of about 40 minutes duration followed the procedure in the very first animal subjected to the bronchographic procedure, as a result of giving 12gms of methyl cellulose instead of the later dose of 5-7gms. In some cases animals coughed when the tube was introduced or removed from the trachea, the latter response causing some loss of contrast in the main central bronchi. Within ten minutes of the procedure horses could be seen to swallow continuously and barium was visibly obvious in the oesophagus in even the earliest thoracic radiographs. Some animals coughed strongly from 15 to 30 minutes following the procedure, this being most noticeable after the use of local anaesthetic. However, between bouts of coughing, which appeared to dislodge large quantities of barium, there was no

evidence of increase in respiratory rate or signs of dyspnoea. During insufflation the majority of animals remained calm and unreactive although most moved or coughed on the first inhalation of the air/barium mixture.

The safety of barium sulphate for bronchography has been closely investigated in humans (Nelson, Christofordis and Pratt, 1964; Shook and Felson, 1970) and dogs (Clement, 1969; Myer, Burt and Davis, 1974). Early prejudice against barium sulphate inhalation into the lungs appears to have stemmed from accidents arising as a result of the inclusion of toxic salts of barium in poorly refined barium sulphate mixtures (Nelson, et.al., 1964) and fear that inspissated bronchial casts might mechanically block the airways as occasionally occurs in the human colon. The latter complication would hardly seem likely to occur in an organ such as a bronchus lacking the dehydrating function of the colon. Finally, the induction of pulmonary fibrosis as a result of alveolar retention would seem a reasonable fear. Whereas this potentially serious complication has been reported following the alveolisation of various oils used in conventional bronchographic media (Christoforidis, et.al., 1967) numerous investigators have been unable to find evidence of fibrosis following the use of barium sulphate (Huston, Wallach and Cunningham, 1952; Dunbar et.al., 1959, Willson, Rubin and McGee, 1959). In addition clinical evidence from bronchographic trials comparing barium sulphate with other contrast materials suggests that barium sulphate induces less acute and long term cellular reaction and has certain diagnostic advantages, in terms of radiographic density (Teixiera and Teixeira, 1959; Nelson et.al.,

1965; Nice, Waring and Killelea, 1964; Shook and Felson, 1970). The results of histological examination of the lungs from two horses sacrificed after six weeks in the study of Walker and Goble (1980) support the view that barium sulphate produces only a minimal inflammatory response in the lung. The present study supports these findings and suggests that powdered barium sulphate induces even less cellular response than the same material in suspension.

In the present small series of horses there was evidence that virtually all the inhaled barium had been eliminated from the lungs within five hours of the procedure. The apparent rapid elimination of the barium sulphate from the lung field in horses compared to other species (Clements, 1969) may be the result of the natural postural drainage (Cook, 1974). Thus when the horse lowers its head there is continuous downhill path from the distal diaphragmatic bronchi to the nares. Furthermore, inhalation of powdered material substantially reduces the total quantity of contrast material used as only the walls of the bronchi are coated and bronchi are not flooded with barium. This could account for the more rapid elimination of contrast material in this series compared with the findings of Walker and Goble (1980) who used liquid barium sulphate suspension. Human studies (Shook and Felson, 1970) have noted similar more rapid elimination of inhaled contrast material compared to conventional flood techniques.

The diagnostic value of bronchography in the horse remains to be proven. In human medicine bronchography is an important diagnostic

procedure and is recommended in cases of known or suspected bronchiectasis with chronic coughing, hemoptysis of an unexplained nature, localised obstruction or displacement of bronchi on the plain radiograph, cytology of sputum positive for malignant cells and suspected congenital abnormalities (Brumer et.al., 1970).

While malignancy and congenital abnormalities have rarely been observed in the lungs of horses and therefore merit only minor consideration, chronic coughing (often associated with C.O.P.D.) and epistaxis as a result of lung haemorrhage are extremely common conditions and at present the cause of much speculative comment and research interest (Cook, 1974; McPherson and Lawson, 1974; Robinson, 1979).

Bronchography can serve positively in this area in two ways. Firstly, the accurate identification and characterisation of the bronchial tree provided by the bronchogram is an extremely useful adjunct to plain thoracic radiographs, particularly as the lateral view with the resultant superposition of both lungs is the only practical technique available in the horse. Accurate identification of the superimposed bronchi, especially in the diaphragmatic area, has been important in the identification of artifacts and understanding the normal radiographic anatomy of the thorax in the present continuing study. The powder insufflation technique has the disadvantage of outlining the bronchial system bilaterally, however recourse to radiography of both sides of the thorax and the distinctive bronchial anatomy of each lung obviate the greater part of this difficulty. Secondly, bronchography will enable a more objective assessment

of pulmonary conditions in horses by allowing visualisation of the bronchi in animals with more subtle lesions which have only occasionally been examined at post mortem in the past. Conditions such as chronic bronchitis and bronchiolitis are common in the horse, however accurate assessment of permanent changes is only possible through a series of technically exacting pulmonary function tests specifically adapted to the equine subject (Muyllle and Oyaert, 1974; McPherson and Lawson, 1974; Robinson, 1979; McDonnell, Hall and Jeffcott, 1979; Willoughby and McDonnell, 1979). Bronchography provides the means of assessing the normality or otherwise of the bronchial walls down to the seventh or eighth generation. In the case of chronic bronchitis well documented changes become evident in other species (Nelson and Christofordis, 1973; Douglas, 1974; Webbon and Clarke, 1977). Whether similar changes occur in conditions such as C.O.P.D. is purely speculative and can only be evaluated through a clinical trial of bronchography.

The method may also improve our understanding of "bleeders". The area of the lung from which haemorrhage has occurred may become identifiable and some of the changes responsible for similar bleeding in humans such as bronchiectasis may become evident. The latter condition has not been identified in horses as few animals with chronic bronchitis are post mortemed. However, the existence of bronchiectasis is highly probable in the horse and may prove to be the basis of epistaxis in a certain proportion of cases.

CHAPTER IV - PULMONARY VASCULATURE IN THE HORSE;
SOME ASPECTS OF ITS RADIOGRAPHIC APPEARANCE

RESULTS

A. Pulmonary Arteriography

In three of the six horses on which pulmonary arteriograms were attempted, sufficient contrast filled the major pulmonary arteries to enable adequate visualisation of the proximal arterial tree. Only some segments of the peripheral arterial circuit were outlined satisfactorily by this method. Failure to obtain satisfactory arteriograms in the remaining three horses was probably due to a combination of incorrect positioning of the catheter, poor synchronisation of exposures and delivery of insufficient contrast material.

In lateral recumbency the diaphragmatic outline was displaced cranially, resulting in compression of lungs and an increase in lung density with subsequent loss of detail, in particular that of the aorta, pulmonary vessels and caudal vena cava (Fig. 17, 14) (McDonnel et.al., 1979). Care was therefore exercised in extrapolating results from this series of arteriograms to plain radiographs of horses in the standing position.

The most detailed pulmonary arteriogram was obtained from a six-month old pony foal (150kg). The position of the catheter in the pulmonary arterial trunk was obvious in the control radiograph following the injection of a small quantity of

contrast agent as a marker (Fig.12). In the arterial phase of the arteriogram, peripheral arteries down to the 5th generation could be visualised (Fig.13). The primary pulmonary arteries appear to directly overlie one another in the lateral projection. Ventrally a large branch (a) can be seen to originate 4-5cm distal to the cardiac origin of the pulmonary arteries. This secondary branch courses horizontally towards the diaphragmatic shadow. Another secondary branch (a') originates ventrally from the pulmonary artery a further 5cm distal to the first branch. Tertiary branching is not clearly visible on those ventral vessels. Also clearly visible is a large secondary branch (b) which originates from the dorsal border of the primary pulmonary artery and courses cranially, crossing the origin of the aorta. This vessel leaves the parent artery from a position slightly below and cranial to the bifurcation of the trachea and is occasionally seen on plain radiograph. Immediately caudal to the origin of this secondary branch a tertiary branch (b') can be seen coursing in a dorsal direction. The first of these tertiary branches (b') demonstrates an interesting arterial branching pattern. Initially this branch seems to originate from the secondary artery in a somewhat monopodal fashion. Similarly, the secondary branch (b) appears monopodal as it originates from the dorsal edge of the main pulmonary artery. If however the dorsally directed tertiary vessel (b') is traced distally, it appears to undergo further branching into two equal sized daughter vessels (arrows). This pattern represents symmetrical dichotomous branching as described by Parker et.al., (1971). The quaternary generation of arteries then appears to branch again in a dichotomous

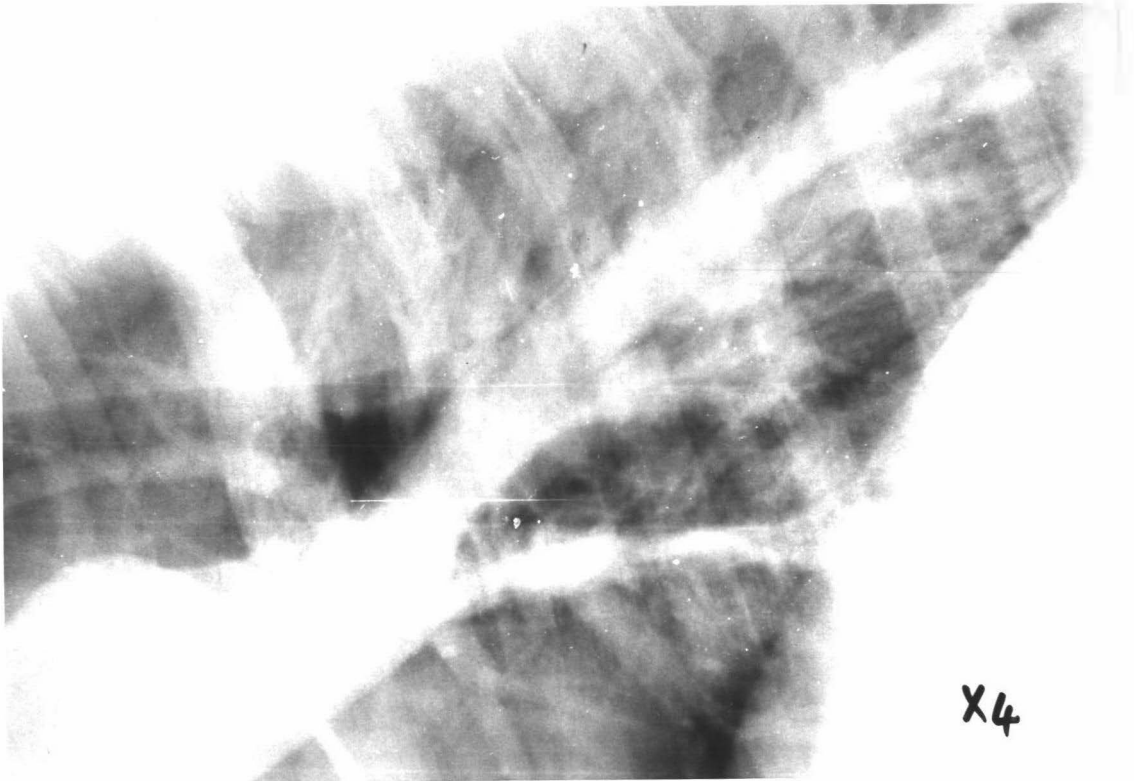


Fig. 12 Six month pony foal (150kg).

Exposure following injection of small quantity of contrast agent to check catheter positioning within pulmonary artery.

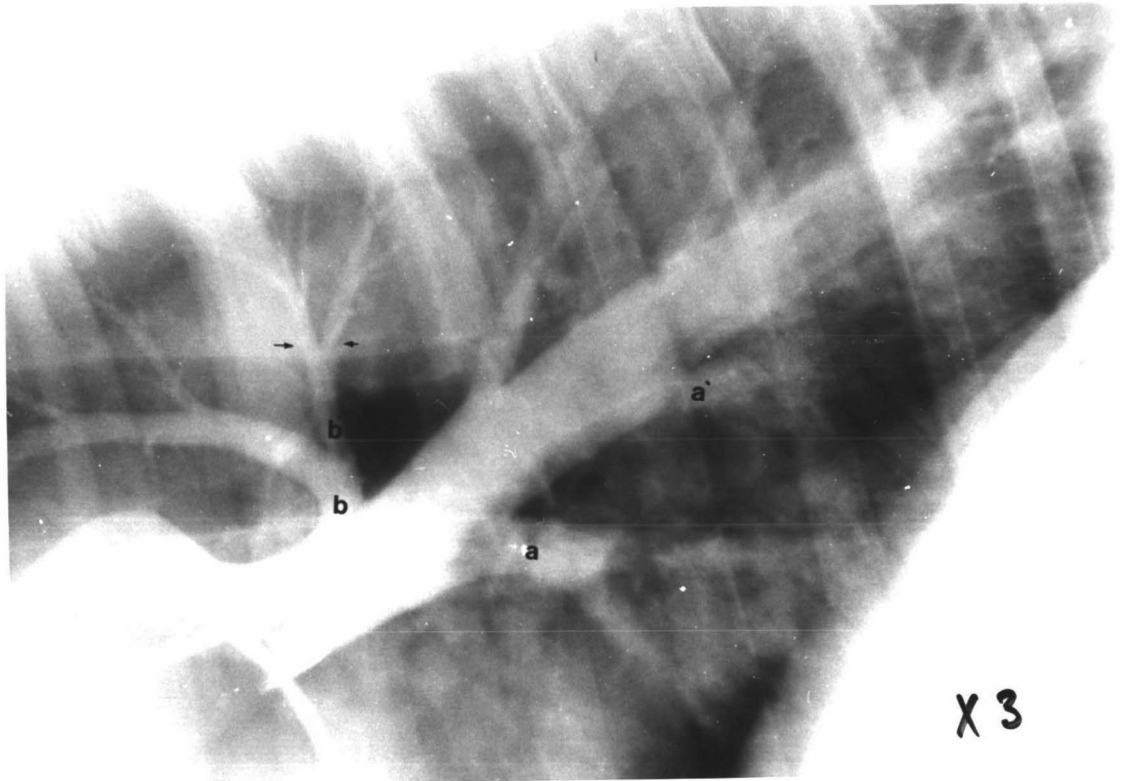


Fig. 13 Six month pony foal (150kg)

Exposure taken two seconds following injection of 120 mls contrast (Conray 420). Pulmonary arterial tree outlined.

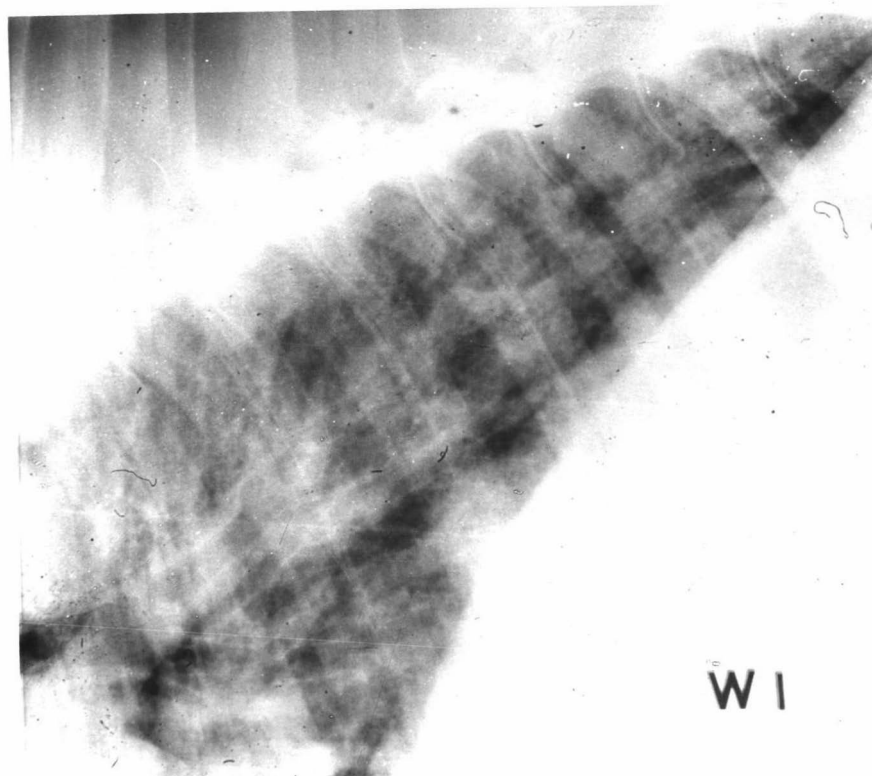


Fig. 14 One year old Thoroughbred Colt (300kg).

Control exposure taken in lateral recumbency with no contrast present in pulmonary vasculature. Note overall loss of detail of pulmonary structures.

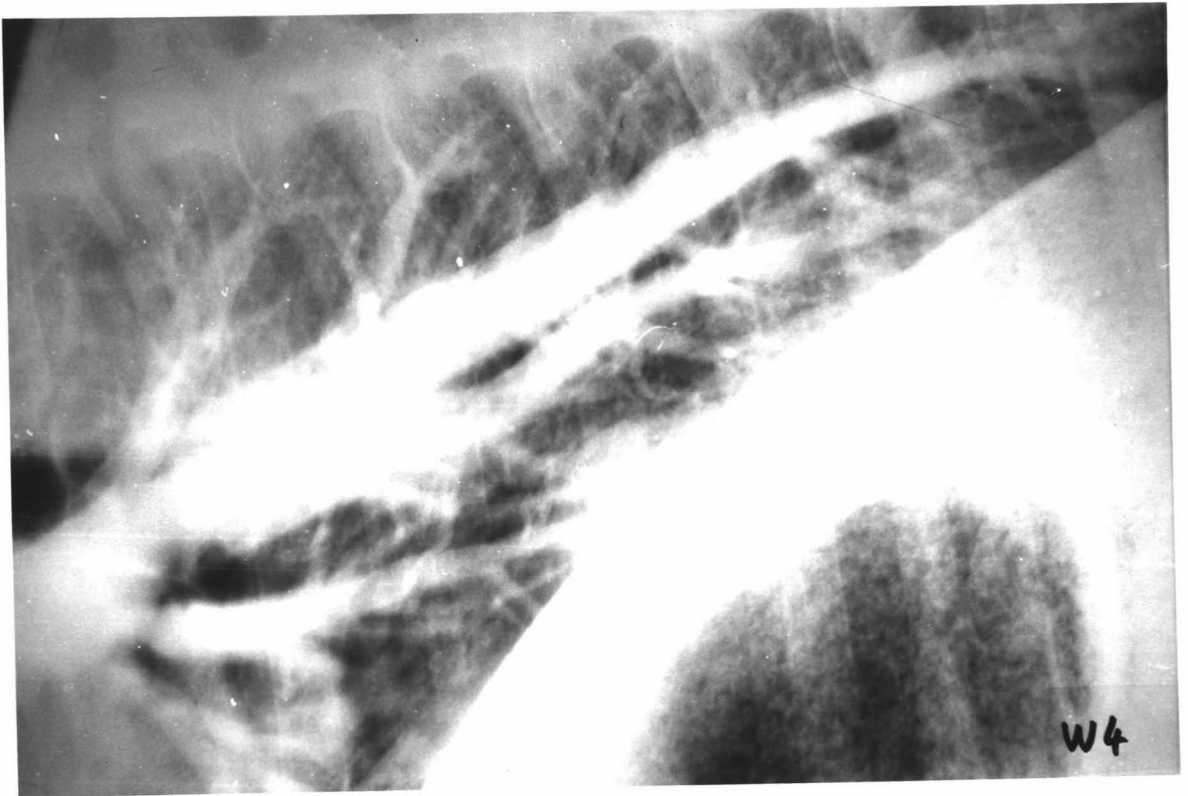


Fig. 15 One year old Thoroughbred Colt (300kg)

Exposure taken two seconds following injection of 120 mls Conray 420. The pulmonary arterial tree is well outlined but appears considerably compressed, hence giving a distorted appearance to the branching pattern.

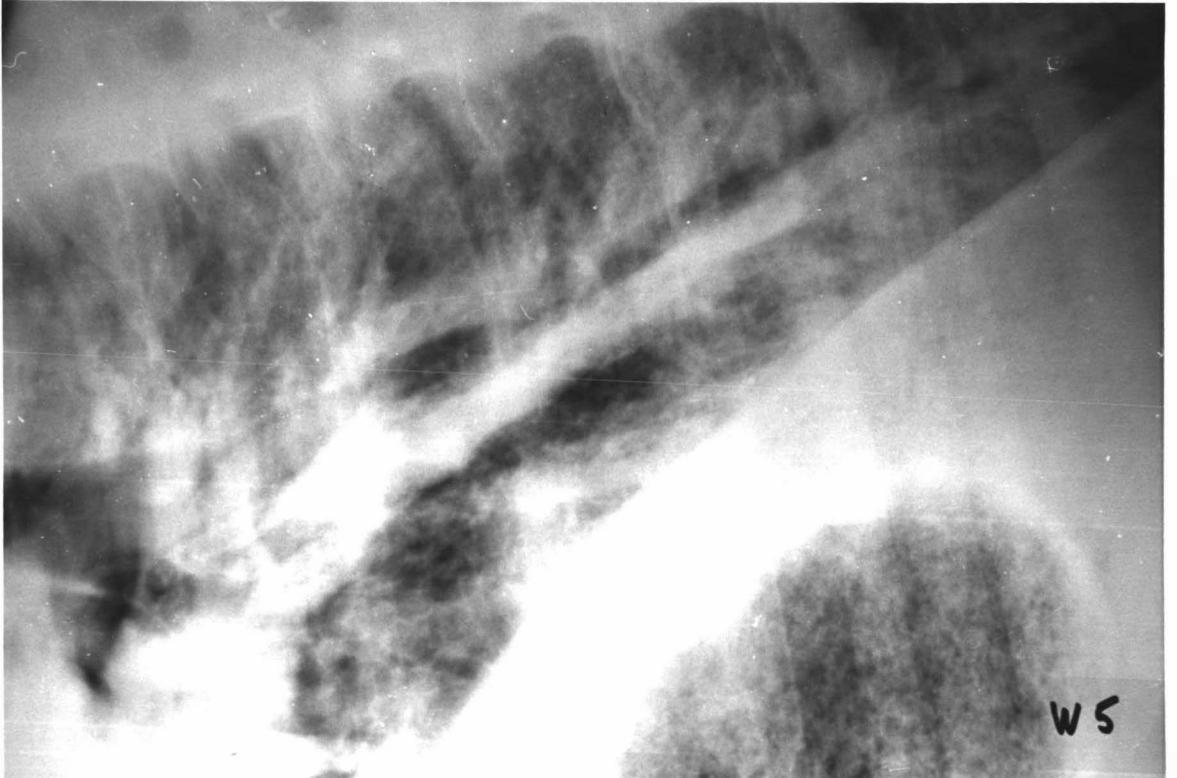


Fig. 16 One year old Thoroughbred Colt (300kg).

Exposure taken four seconds following injection of 120 mls Conray 420. The pulmonary venous system and left atrium are filled with diluted contrast material, but very little detail of branching systems is apparent.



Fig. 17 One year old Thoroughbred Colt (300kg).
Control exposure with no contrast agent used.
Note the overall loss of detail.

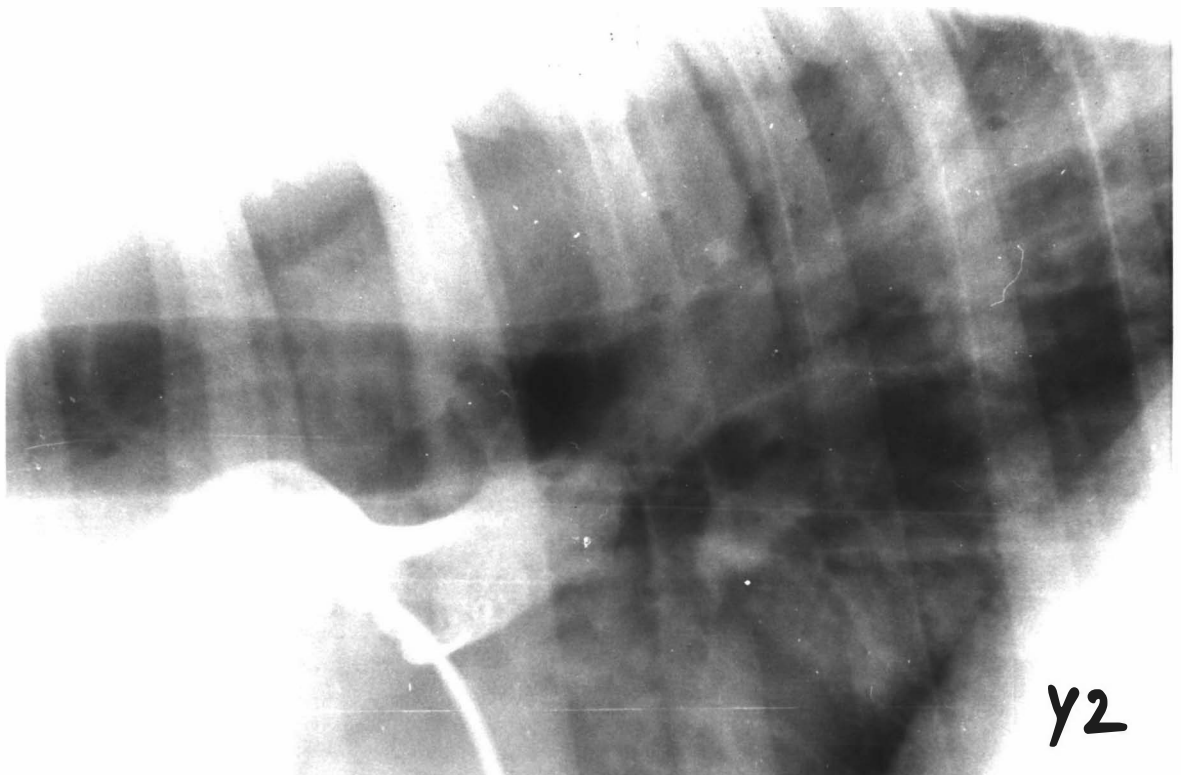


Fig. 18

One year old Thoroughbred Colt (300kg)

Exposure taken immediately following the injection of 20 mls Conray 420 to ascertain correct positioning of catheter in pulmonary arterial trunk. Note the large dorsal bulge visible in the dorsal aspect of the proximal arterial trunk.

B. Radiography of Dissected Equine Lungs

Results

i) Without Contrast Materials : Several sets of equine lungs were dissected clear of the thorax and radiographed in order to highlight some of the bronchial and vascular relationships without the added complication of superimposed rib shadows. Radiographs of two examples (Fig. 20, totally exsanguinated, and Fig.21 with blood remaining in the vessels) serve to illustrate the main features derived from this study.

In Fig.20, a dorsoventral view of the right lung of an adult horse, the branching pattern of the airways (thick walls) and pulmonary artery tree demonstrate a pronounced similarity in juxtaposition and distribution whereas the veins are difficult to visualise as they lie beneath the shadow of the airways.

In Fig.21 the venous system appears to be nearly filled with residual blood (labelled) and the arterial tree only partially so. However the relationships of the major vessels with relation to the airways in the dorsoventral view is quite clear, with the arteries lying lateral and the veins medial to the bronchi. In addition, Fig.21 demonstrates a difference in the branching characteristics of pulmonary arteries and veins. The pulmonary veins appear to have retained more blood and show what appears to be even dichotomous branching, i.e. each division is essentially symmetrical with daughter branches of equal size slightly greater than half the diameter of the parent branch. The arteries although not so clearly visualised, demonstrate a pattern varying

between dichotomous and monopodal in distribution.

Fig. 22, photographs of the lungs seen in Fig.21 following formalin fixation and slicing, demonstrate the close relationship of the three major vascular and bronchial structures through the lung parenchyma, with the pulmonary artery lying dorsal and lateral to the bronchi and the pulmonary vein ventromedial in position.

ii) With Contrast Agents : The use of contrast agents to outline the pulmonary vasculature highlights the features discussed in the preceding section with respect to branching patterns. In Fig. 23, a dorsoventral radiograph of the left lung of a horse following contrast infusion into the pulmonary arteries, the branching pattern of these vessels appear to be abrupt and somewhat blocky in appearance. The peripheral venous tree has also been filled with contrast agent passing through the capillaries via the arterial tree and can be seen to possess essentially an even dichotomous type branching pattern with few interspersed monopodal branches. An enlargement of a section of the peripheral area highlights the comparison between branching patterns of the two vascular systems (Fig.24).

DISCUSSION

1) Branching Pattern : It is interesting to note that most of the proximal secondary branches of the pulmonary artery appear to be derived in a monopodal fashion with dichotomous branching not becoming a feature until at least the tertiary generation. This

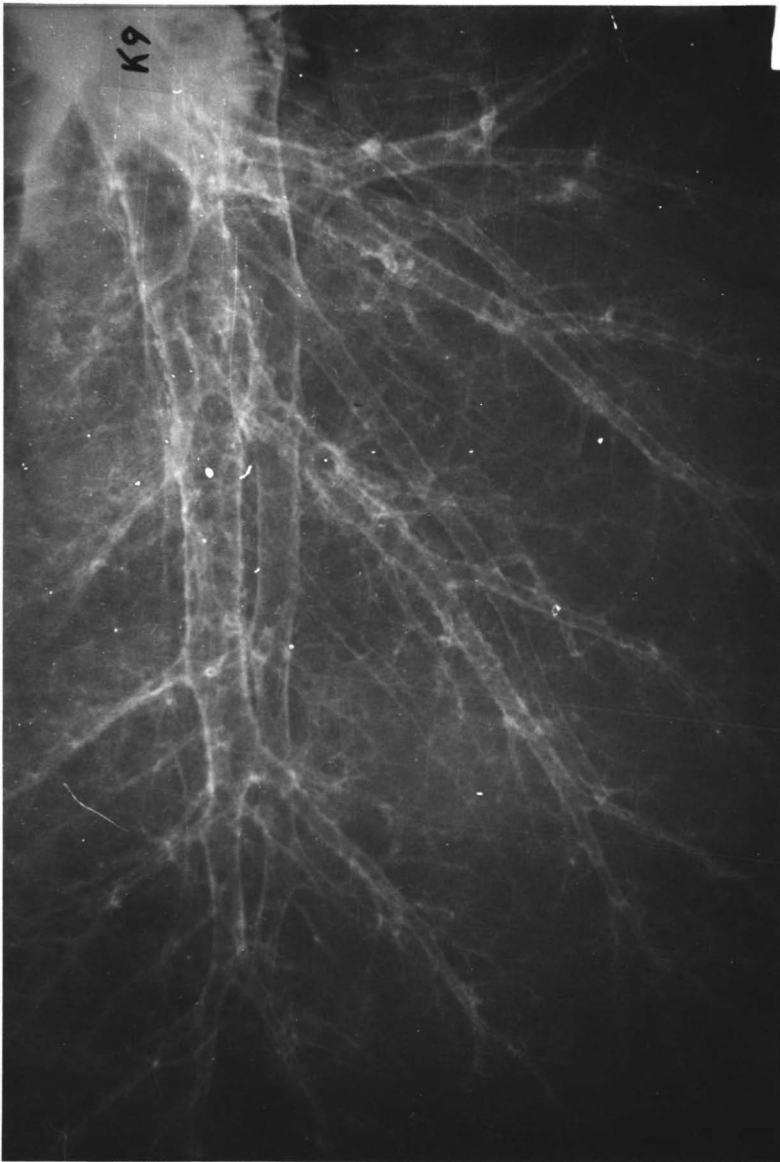


Fig. 20 D.V.radiograph of isolated right lung of 18 month Thoroughbred gelding.

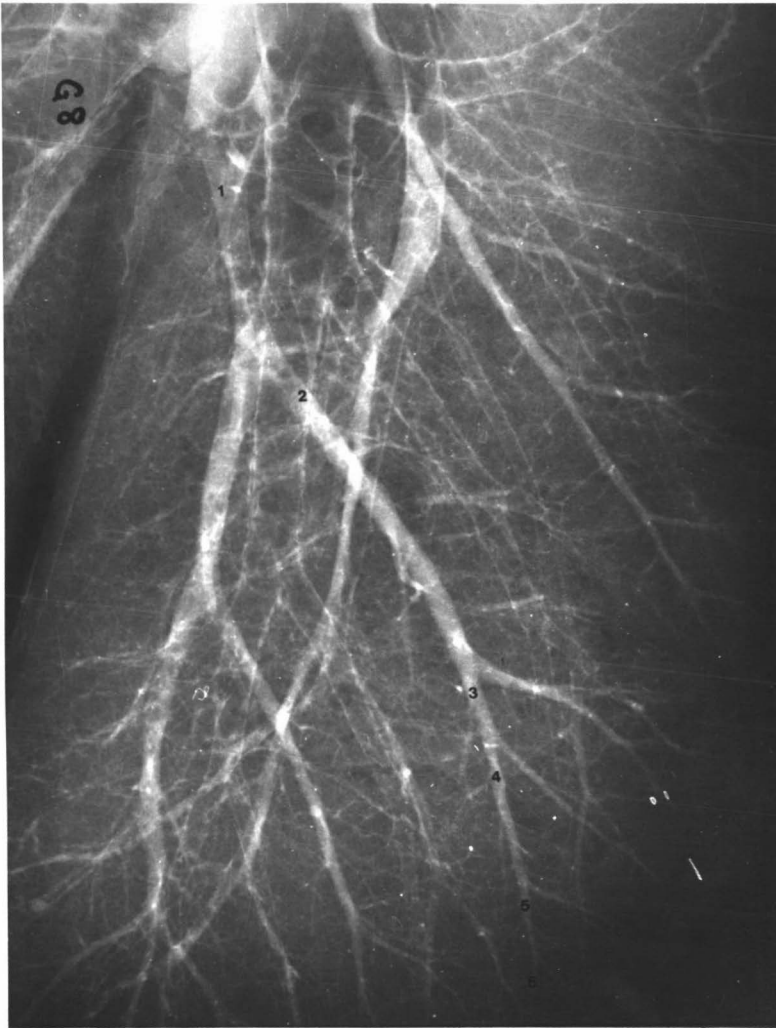


Fig. 21 D.V.radiograph of isolated right lung of two year old Thoroughbred filly. Branching of the venous vasculature has been labelled to the level of the 6th generation. The arterial tree is incompletely filled with residual blood.




Fig. 22

Photographs of the lung seen in Fig. 21 following fumefixation in formalin gas and subsequent slicing into 3cm thick portions to demonstrate the relationships of the vessels and airways within the lung. The three large hollow structures within the parenchyma represent the major bronchus (centre), the primary pulmonary vein (below bronchus, i.e. ventromedial) and the primary pulmonary artery (above bronchus, i.e. dorsolateral).

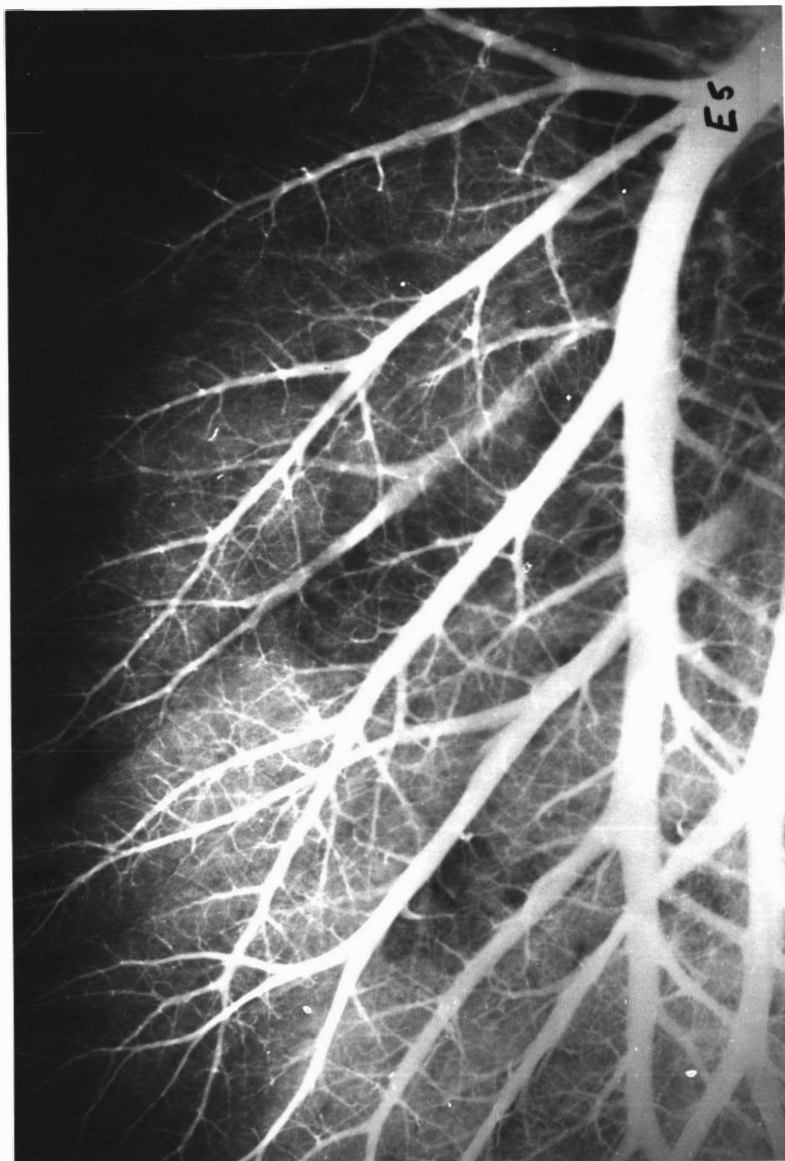

Fig. 23 A dorsoventral radiograph of the isolated left lung of a horse following fume fixation and infusion of aqueous barium sulphate into the pulmonary arterial system (left) with some capillary overflow into the venous system (right, incompletely filled).

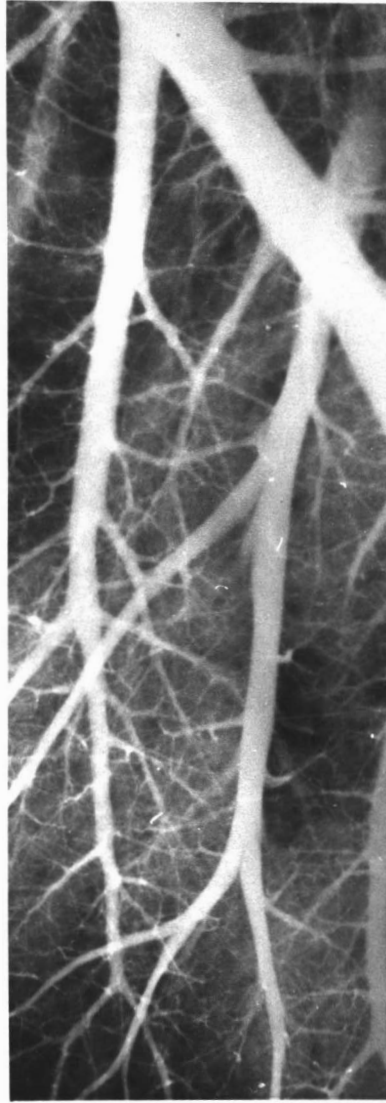

Fig. 24

An enlargement of a juxtaposed pulmonary artery (left) and pulmonary vein (right) segment from the peripheral area of the equine lung radiographed in Fig.23. Note the branching patterns obtained in this comparative study which appear to contrast directly with similar observations in human subjects.

feature appears to be in contrast with observations on human pulmonary artery branching made by Milne (1973), in which smoothly tapering dichotomous branching appears to predominate.

Knowledge of the characteristics of branching patterns and appearance of vessels in the normal situation is essential in order that interpretation of abnormalities in size, shape or branching pattern of vasculature within the lung may be related accurately and be used as an aid to diagnosis of disease processes. For instance it is essential to be able to differentiate grossly distended pulmonary vessels into either arterial or venous depending on their radiographic appearance as a completely different aetiology may be responsible.

2) Vascular/Airway Relationships : A comparison of the branching pattern of the pulmonary arteries revealed by arteriography and the bronchi outlined by bronchography demonstrates a close association between two systems particularly in the proximal lung fields. This is important because recognition of any irregularity of this juxtaposition may aid in early diagnosis of pulmonary disorders.

CHAPTER V - RADIOGRAPHIC ANATOMY OF THE THORAX

RESULTS

1) Bony Structures : The ventral borders of the vertebral bodies are usually well delineated dorsally in the diaphragmatic exposure whereas these structures are generally not visible on the cardiac projection (Fig.25). Depending on exposure factors and degree of inspiration, the ribs are usually seen as nearly vertical, parallel, radiodense shadows originating above the vertebral bodies, and descending ventrally to merge with the diaphragmatic shadow. Under penetration (insufficient K.V.) results in increased density of rib shadows obscuring underlying lung detail.

2) Heart and Great Vessels : The left atrium is visible in the "cardiac" area as the most caudal limit of the heart shadow interposed between the pulmonary artery and the caudal vena cava (Fig. 26). When the heart size is normal, the shadows of ribs 6 and 7 are superimposed on the caudal border of the left atrium. Beneath the vena cava the caudal border of the left ventricle merges with the shadow of the diaphragm.

The caudo-dorsal border of the heart shadow is dominated by the entry and emergence of four major vascular structures.

(a) Aorta : Cranially, the aorta emerges from the left ventricle at the level of the 4th rib and follows a caudo-dorsal course beneath the thoracic vertebral bodies (Fig. 26). Measured from the

radiograph the cardiac origin of the aorta in an adult horse measures approximately 5-7cms in diameter. As the aorta curves caudo-dorsally away from the heart shadow it passes over the carina (bifurcation of the trachea) one of the major landmarks in any examination of the thoracic radiograph (Fig.27). Further caudally as it is superimposed on the vertebral bodies the outline becomes less distinct owing to the increase in overlying densities of musculature and pulmonary vessels particularly caudal to T9-T10.

(b) The Pulmonary Arteries : Immediately ventral to the carina the prominent vascular shadow of the pulmonary arteries emerges from the cardiac shadow. The paired arteries are visible as a cylindrical soft tissue density, 3-4cm wide at its origin, following a nearly straight course dorsocaudally (Fig.28). It is difficult to visualise the individual main arteries as separate entities because in the true lateral projection the vessels are superimposed.

The aorta and pulmonary arteries are separated by a radioluscent band of lung tissue approximately 2-3cms in depth beginning cranial to the carina and tapering progressively away caudally. The major diaphragmatic branches of the pulmonary arteries form the ventral border of this radioluscent area, running ventral to the aorta proximally, but tending to obscure the aortic shadow as they become superimposed on it caudal to T8-9. The walls of the major branches of the pulmonary arteries appear to taper smoothly towards the periphery of the lung field. Several dorsal branches can be visualised in the lateral standing thoracic radiograph (Fig.25). These secondary branches appear to be derived in a monopodal

fashion (i.e. the vessel gives off a branch of smaller diameter than the parent vessel). Occasionally the branch of the pulmonary artery which supplies the cranial lobe of the lungs can be seen to emerge from the dorsal border of the major pulmonary artery near its origin and course dorsocranially (Fig. 26).

In the cardiac area, a major pulmonary arterial branch arises ventrally almost within the overlying shadow of the left atrium (Fig.26). This vessel courses caudoventrally in a straight path to overlie the caudal vena cava and diaphragmatic shadow peripherally. Several other major secondary arterial branches arise from the ventral border of the primary pulmonary artery. These can be identified as cylindrical soft tissue densities following a nearly horizontal course through the lung parenchyma (Fig. 25). Peripherally, visualisation of individual arterial branching becomes difficult owing to the haze created by the increasing multiplicity of overlying supportive tissue structures, the major component of which is fine vasculature.

(c) Pulmonary Veins : A diffuse cylindrical shadow entering the left atrium at the level of ribs 6-7 represent the pulmonary veins. The venous system draining the lung is not as radiographically distinct as the pulmonary arterial system. Nevertheless the major pulmonary veins are readily visible as they enter the left atrium (Fig. 26, 29), where they appear to have a combined diameter of 6-8cm on the radiograph. Overlying densities make it difficult to accurately identify the branching pattern of the venous system, especially in the diaphragmatic or dorsal extremities of the lung field.

(d) Caudal Vena Cava : In the V-shaped radiolucent area of lung parenchyma between the ventral diaphragmatic shadow and caudal border of the heart, a horizontal cylindrical soft tissue density is visible (Fig. 26, 29). This shadow represents the caudal vena cava which appears to originate from the midventral diaphragm and course horizontally into the caudal cardiac margin where it is masked by the left atrial shadow. As this vessel traverses the thorax, its radiographic image is approximately 4-6cm in diameter. Beneath the caudal vena cava, the triangular radiolucent area represents the accessory lobe of the right lung.

(e) Peripheral Vasculature : The greatest proportion of peripheral lung density in the horse is composed of vascular densities, however unlike the dog there is also a fine reticular pattern attributable to the interstitial parenchyma. In the dorsal half of the lung fields the branches of the pulmonary arteries and veins are particularly evident and well defined especially as they overlie the aortic shadow (Fig. 25). It is not possible to predict with accuracy whether a particular vessel in this area is artery or vein on its calibre alone as geometric distortion from overlapping of the two lungs magnifies those vessels from the lung nearest to the X-ray tube. However, the course of these vessels to either the main diaphragmatic branch of the corresponding pulmonary artery or vein is usually obvious and readily determined. Ventrally only the major branches can be distinguished in this way.

3) Airways : The trachea is visible radiographically as a pair of dense linear markings separated by approximately 4cms situated in a horizontal position immediately overlying the base of the heart. The tracheal bifurcation, or carina is located in the area bounded by the aorta dorsally, pulmonary artery ventrally, and rostro-caudally by ribs 5 and 6. In this area, it is possible to visualise either 2,3 or 4 circular radiolucent shadows which represent the "end on" view through the bronchi which supply the cranial and middle lung lobes (Fig. 27). In the horse, unlike cattle and dogs, the bronchi to the cranial and medial lung lobes on each side arise from a common trunk (Suzuki and Ohkubo, 1977). Distal to the carina there is some variation between animals in the degree of visibility of the lobar and more distal bronchi. In the normal animal pairs of fine linear densities representing primary, secondary or tertiary branches of the lobar bronchi can often be seen irradiating away from the carina (Fig. 28). These bronchial shadows are progressively and intermittently obscured by the increasing multitude of overlying vascular and interstitial densities as they near the periphery of the visible lung fields. These fine linear densities are often separated by a zone of increased radiolucency representing the bronchial lumen (Fig. 28). Throughout the visible lung fields, projections of end-on bronchi can be seen as fine ring-like radiodense structures with dark centres (Fig. 29). Occasionally juxtaposed to these visible end-on bronchi are one or two diffuse circular or oblong densities produced by the accompanying artery and vein. If both are present the artery is smaller, closer and normally slightly more clearly defined than the vein (Fig. 29).

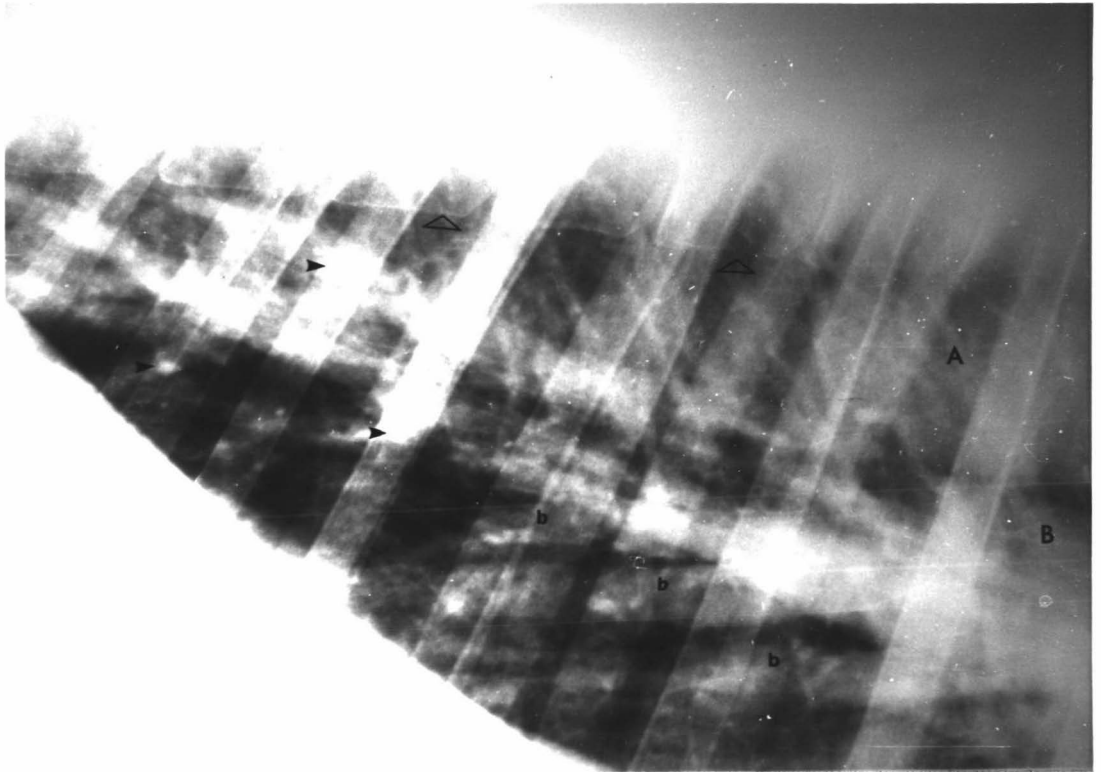


Figure 25 : Lateral radiograph of the diaphragmatic area of the lungs of an adult horse. The lung area is bordered dorsally by the ventral borders of the thoracic vertebral bodies (open arrows) and ventrally by the diaphragm. The aorta (A) is seen as a wide band of radiodensity passing cranio-dorsally, immediately beneath the vertebral bodies. Further ventral the paired diaphragmatic branches of the main pulmonary artery (B) course caudally and dorsally to become superimposed on the aortic shadow. Beneath the branches of the pulmonary artery and running parallel to them are the paired pulmonary veins into which drain several large horizontally disposed tertiary branches (b). Several end on vessels are also visible in this view (solid arrow heads).

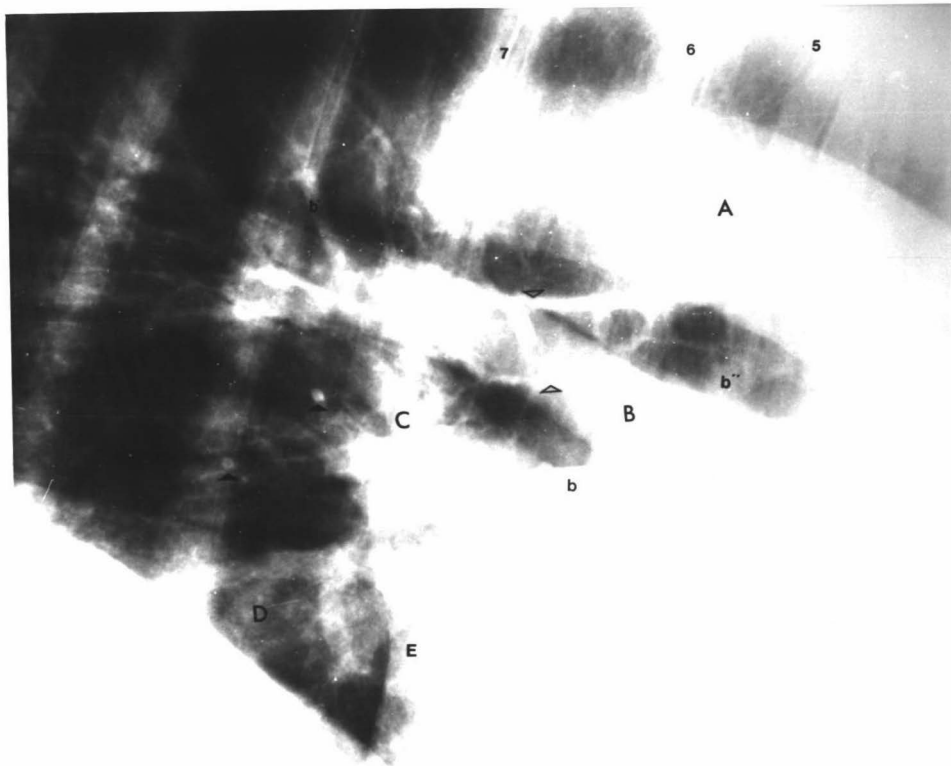


Figure 26 : The cardiac area of an adult horse's lung field. Ribs 5, 6 and 7 are labelled dorsally. The major vascular structures entering the heart shadow ventrally are the aorta (A), the pulmonary arteries (B), the pulmonary veins (C) and the caudal vena cava (D). The caudal border of the left ventricle at the atrio ventricular ring is evident at (E). Between the aorta and the pulmonary arteries several radiolucent rings (b'') indicate the carina and origins of the middle lobe bronchi. The main diaphragmatic bronchi are seen between the two open arrows. Further ventrally at (b) a large branch of the pulmonary artery runs a horizontal course caudally. Several end on vessels are also evident (solid arrow heads).

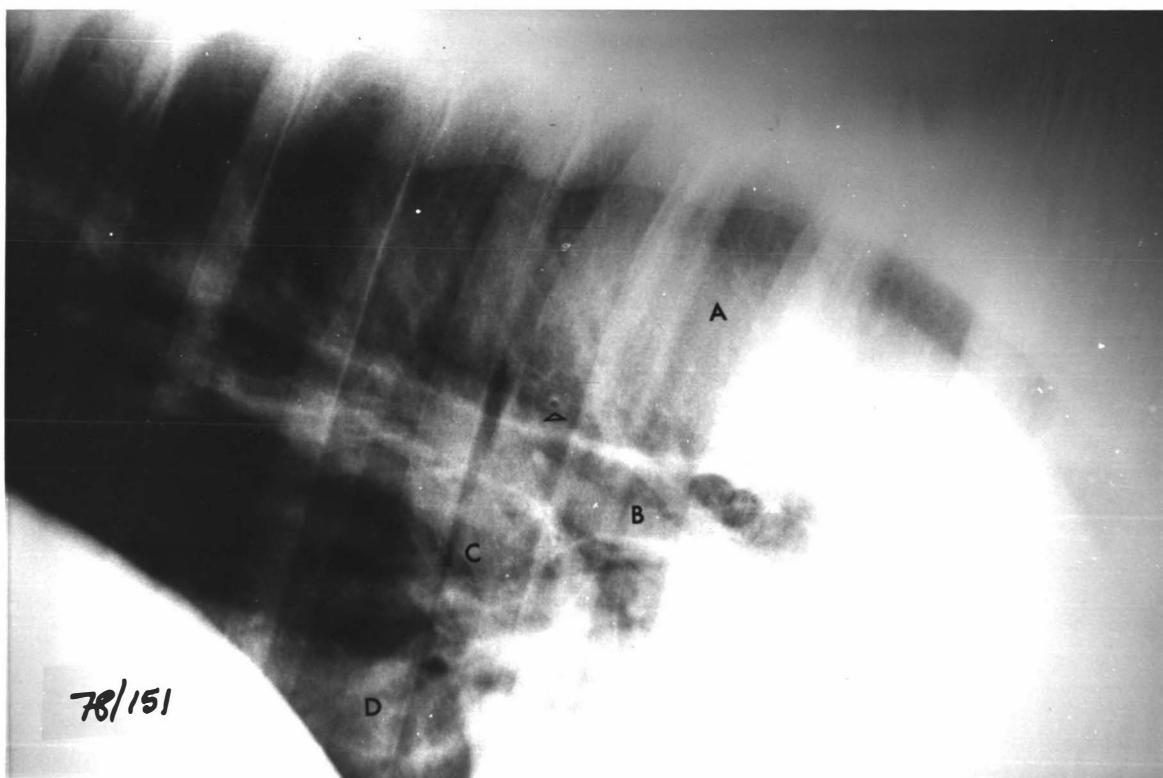


Figure 29 : Radiograph of thorax demonstrating quite clearly the position of the main pulmonary veins (C) as they enter the left atrium. The aorta is seen at (A) and the main pulmonary arteries at (B). Further ventrally the caudal vena cava is visible (D). An end on small bronchus with an accompanying artery on its dorsal surface is evident as a signet-ring shaped area of density, immediately dorsal to the main pulmonary artery branches (open arrowhead).

DISCUSSION

The ability of the eye to recognise a pattern or departure from normality in a radiograph is largely dependant upon prior knowledge that such a pattern or departure can exist (Milne, 1973). Anatomical descriptions of radiographically visible structures, although potentially important in formulating radiological diagnostic criteria, must also be considered with some caution in the light of technical limitations of equine thoracic radiography. Because it is only possible to obtain radiographs in a single plane without resorting to anaesthesia and special positioning, confusion may arise in interpretation of thoracic radiographs. It may be possible to isolate areas of abnormalities by taking radiographs from both sides of the thorax and relying on the geometric distortion and magnification of the structures in the lung nearest to the X-ray tube to isolate the affected areas rather than resorting to ventro-dorsal projections.

Species differences must not be overlooked when considering equine thoracic radiographs. In particular, the large cupola shaped diaphragm of the horse reduces the lung area visible on the lateral radiograph, emphasising the need to take exposures of maximal inspiration. McDonelli et.al., (1979) have demonstrated that a significant proportion of the diaphragmatic periphery of the lungs is unable to be visualised since it overlies the abdominal contents caudal and ventral to the diaphragmatic arch.

It is also important to recognise that a far greater number of

generations of vascular structures are visible in the horse's lung when compared to dog or human chest X-rays. This is due to almost equivalent detail being possible with the film, screen combinations coupled with the much greater size of the same structures in the horse. Similarly owing to the physical thickness of the bronchial walls these structures are easily visible down to the 4th or 5th generation in the normal horse, and may only be obscured in cases of mild increase in lung density before the well known changes associated with peribronchial cuffing became evident. Visibility of the same structures in human and canine lungs is rare with the exception of pathological processes or age changes such as "old dog lung" (Suter and Lord, 1974).

The relative importance of the vascular and interstitial parenchyma in producing the diffuse peripheral density of the lung remains to be accurately resolved. Superimposition of the two lungs increases the difficulties in deciding the relative importance of the two components. Careful scrutiny of the peripheral areas away from obvious vessels demonstrates a fine reticulo-nodular pattern not seen in canine thoracic radiographs but sometimes alluded to in the human literature. Ruminant lungs by contrast demonstrate a very distinctive reticular pattern often sufficiently obvious to obscure even relatively large vascular branches. This variation in parenchymal pattern obvious on the radiographs appears to parallel closely the anatomical and histological characteristics of the lungs of various species studied by McLaughlin et.al., (1961) who placed human and horse lungs in an intermediate group between carnivores and ruminants

when considering the supporting structures of the lung parenchyma.

Alternatively, superimposition of fine vasculature in the lateral projection may be sufficient to explain the reticular pattern observed in the lung parenchyma. Further study is required to resolve this question, since it has some bearing on the interpretation of the early stages of diffuse increases in lung density.

CONCLUSION

The techniques described for radiographic examination of the equine thorax in this thesis assume the availability of Xray equipment of sufficient generator and tube capacity to perform lateral thoracic radiographs in adult horses. Plain thoracic radiography and bronchography in the horse are relatively simple to perform and provided adequate patient restraint is applied, good quality radiographs can be obtained.

By contrast, pulmonary angiography, to highlight the pulmonary arterial system in the conscious horse, proved extremely difficult to perform and cannot be recommended. Similarly, fume fixation of equine lungs was a slow difficult process, owing to the large volume of formalin necessary and the problems encountered in controlling inflation of adult equine lungs.

Morphologically, the equine lung appears similar to its human counterpart in subgross structure which tends to lead to the false assumption of absolute similarity. Radiographs of equine lungs following post mortem fume fixation and vascular infiltration with contrast agents demonstrated that the vascular branching pattern seen in human pulmonary vessels cannot be directly compared to the equine pulmonary vascular bed. In fact, an anomalous situation is apparent in which the equine arterial and venous branching systems demonstrate the opposite branching patterns to their human counterparts. Thus in the horse the arterial pattern is predominantly monopodal and blocky in

appearance while the venous system is distinctly dichotomous and smoothly tapering, similar to the human arterial system.

Equine pulmonary vasculature does however seem to follow, with respect to the airways, a course similar to that of other species, i.e. the major vessels and bronchi form a triad as they extend peripherally from the carina. The major bronchus is centrally located with the pulmonary vein ventromedial and the pulmonary artery dorsolateral to the airway. This feature is important when interpreting thoracic radiographs of certain horses in which all three structures mentioned seem to be extremely closely related and difficult to isolate individually.

The method of performing bronchography in the conscious horse, developed for this study, proved extremely simple and reliable. The technique was economic and appeared to be safe for multiple use in the same animal, producing bronchograms of satisfactory detail and resolution. Problems of delayed exposure time and coughing following contrast insufflation could be eliminated as operator experience improved. The adoption of barium sulphate in powder form obviated many of the technical difficulties encountered with aqueous solutions such as pooling of contrast agents in the alveoli and potential toxicity resulting from the use of iodinated materials. The quality and diagnostic usefulness of bronchograms thus obtained appeared equal to those recorded in the only other study on equine bronchography with the added advantage of not requiring anaesthesia of the animal. The problem of

poor filling of the dorsal airways, owing to gravitational effects, is however acknowledged. Marked improvement can however be expected as modifications to the present techniques are made in future clinical applications.

Serial radiographs following bronchographic examination, and subsequent histological examination of post bronchographic lung sections indicated that the contrast agent is eliminated rapidly with little or no residual material remaining to evoke an inflammatory response.

Apart from enabling accurate characterisation of the bronchial tree, bronchography revealed what appeared to be a major variation between animals in bronchial size and branching patterns especially in the smaller generation of airways. Whether this reflects an actual difference in anatomical branching pattern or was the result of widely varying degrees of broncho-constriction in response to the barium sulphate was not resolved in this study. Clearly, more research into these factors is necessary before conclusions can be drawn.

The identification and appreciation of the disposition of soft tissue and bony structures requires an accurate prior knowledge of thoracic radiographic anatomy. The essential links in providing this anatomical and structural detail were the correlative studies of bronchography and pulmonary arteriography. This study has shown that a greater number of generations of pulmonary arteries, veins and bronchi

can be accurately identified in the horse than the corresponding features in other species on the plain lateral projection of the thorax. This knowledge has important implications in the development of radiological interpretative criteria.

The scope of this study has through practical necessity been restricted to the normal equine thorax with no attempt to digress into radiographic features associated with lung disorders.

It would however be pertinent for a further study to be made into the radiography of diseased horse lungs, using the material presented here as a basis for anatomical detail, with special emphasis being centred on the comparison of radiological "signs" or "patterns" associated with respiratory disease in the horse with that of other species.

REFERENCES

- Beech, J., (1979) : Evaluation of the horse with pulmonary disease. Vet.Clinics N.A. Large Animal Practice 1(1) :43-58.
- Bhargara, A.K. and Tyagi, R.P.S.(1975) : The first report on the radiological diagnosis of thoracic diseases in large animals A review of 140 Clinical Cases. Indian Vet.J. 52 : 722.
- Bianco, A; Gibb, F.R.; Kilpper, R.W.; Landman, S. and Morrow, P.E. (1974) : Studies of Tantalum dust in the lungs. Radiology 112 : 549.
- Boltz, W. (1936) : Die Rontgenologische Differenzierung des Lungenbildes beim Pferde. Dtsch. Tierarztl. Wschr. 44:394
- Brummer, D.L.; Chaves, A.D.; Cugell, D.W.; Marks, C.F.; Pierce, A.K., Ross, J.C.1 Utz, J.P.; Young, R.C. and Ziskind, M.M.(1970) : Bronchography : A statement by the committee on therapy(Am.Thoracic Society). Am.Rev. Resp. Dis. 101 (5) : 815.
- Christifordis, A.J.; Nelson, S.W. and Pratt, P.C. (1967) : An experimental study of the tissue reaction to the vehicles commonly used in bronchography. Am.Rev.Resp. Dis. 96 : 249.
- Clarke, K.W. and Webborn, P.M. (1977) : The influence of anaesthesia on bronchography in dogs. J.Small.An.Pract. 18 : 333.
- Clement, J.G.(1969) : Inhalation bronchography. Methods and results in the experimental animal. J.Ass.Canad.Radiol. 20 : 106.

- Cook, W.R.(1974) : Epistaxis in the racehorse. Equine Vet.J.
61 (2): 45.
- Cook, W.R.(1976) : Chronic bronchitis and alveolar emphysema
in the horse. Vet.Rec. 99 : 448.
- Dilley, R.B. and Nadel, J.A.(1976) : Powdered Tantalum. Its use
as a roentgenographic contrast medium. Ann. Otol.Rhinol.
Laryngol. 79 : 945.
- Douglas, S.W. and Hall, L.W.(1959) : Bronchography in the dog.
Vet.Rec. 72 : 901.
- Douglas, S.W. (1970): Radiology of the normal canine thorax.
J.Sm.An.Pract. 11 : 669.
- Douglas, S.W.(1974) : The interpretation of canine bronchograms.
J.An.Vet.Radiol.Soc. 15 : 18
- Dunbar, J.S.; Skinner, G.B.; Wartzman, G. and Stuart, J.R.(1959):
An investigation of effects of opaque media on the lungs
with comparison of Barium Sulphate, Lipiodol and Dionosil.
Am.J.Roent. 82 : 902.
- Felson, B.(1961) : Fundamentals of chest roentgenology.
W.B.Saunders Co. Philadelphia.
- Felson, B. (1973) : Chest Reontgenology. W.B.Saunders Co.,
Philadelphia.
- Friedman, P.J. and Tisi, G.M.(1972) : "Alveolarization" of
Tantalum powder in experimental bronchography and the
clearance of inhaled particles from the lung. Radiology.
104 : 523.
- Gamsu, G.; Thurlbeck, W.M.; Macklem, P.T. and Fraser, R.G.(1971):
Invest. Radiol. 6 : 161.
- Gregg, I. and Trapnell, D.H.(1969) : The bronchographic
appearances of early chronic bronchitis. Br. J.Radiol.42 : 132.

- Gruner, J. and Siegert, H. (1955): Zur Rontgendiagnostik am Thorax des Grosstieres. *Tieraerztl. Umschau*. 10 : 356.
- Hare, W.C.D. (1975) : Respiratory system. In *Sisson and Grossman The Anatomy of the domestic animals*. 5th Ed. Getty : Saunders Co.Philadelphia. 498-523.
- Horsfield, K. and Cumming, G. (1968) : Morphology of the bronchial tree in man. *J.Appl.Physiol*. 24 : 373.
- Hurston, J.; Wallach, D.P. and Cunningham, G.J.(1952) : Pulmonary reaction to Barium Sulphate in rats. *Arch.Path*. 54 : 430.
- Jackson, D.C.(1918) : The bronchial tree. Its study by insufflation of opaque substances in the living. *Am.J.Roentgenol*. 5 : 454.
- Johnson, T.H. and Howland, W.J.(1968) : Aerosol Bronchography - a preliminary report. *Am.J.Roentgenol*. 104 : 787.
- Kangstrom, L.E.(1968) : The radiological diagnosis of equine pneumonia. *J.Am.Vet.Radiol. Soc*. 9 : 80.
- King, G.K.(1980) : Evaluation of a new method of equine thoracic radiography. Masters Thesis.
- Krahl, V.E.(1959) : Macroscopic anatomy of the lungs. *J.Am.Rev.Resp.Dis*. 80 : 24.
- Lee, R. (1974) : Bovine respiratory disease. Its radiological diagnosis. *J.Am.Vet.Rad*. 15 : 41.
- Llamas, R.; Ortiz, J. and Perez, A.R.(1969) : Experimental bronchography by Tantalum insufflation. *Dis.Chest*. 56 : 75.
- Lord, P.F. (1976) : Alveolar lung diseases in small animals and their radiographic diagnosis. *J.Sm.An.Pract*. 17 (5): 283.

- McDonell, W.N.; Hall, L.W. and Jeffcott, L.B.(1979) : Radiographic evidence of impaired pulmonary function in laterally recumbent anaesthetized horses. *Equine Vet.J.* 11 (1) : 24.
- McLaughlin, R.F.; Tyler, W.S. and Canada, R.O.(1961) : A study of the subgross pulmonary anatomy in various mammals. *Amer. J.Anat.* 108 : 149.
- McPherson, E.A. and Lawson, G.H.K.(1974) : Some aspects of chronic pulmonary diseases of horses and methods used in their investigation. *Equine Vet.J.* 6 (1) : 1.
- Milne, E.N.C. (1973) : Correlation of physiologic findings with chest roentgenology. *Radiol. Clin.Nth.Amer.* 11 : 17.
- Morales, O. and Helwinkel, H. (1948) : Viscous water soluble contrast preparation. A preliminary report. *Acta. Radiol.* 30 : 257.
- Murphy, J.R.; Breeze, R.G. and McPherson, E.A.(1978) : Myxoma of the equine respiratory tract. *Mod.Vet.Pract.* 59 : 529.
- Muyllle, E. and Oyaert, W. (1973) : Lung function tests in obstructive pulmonary disease in horses. *Equine Vet.J.* 5 : 37.
- Myer, W.; Burt, K.J. and Davis, G.W.(1974) : A comparative study of propylidone and barium bronchography in the dog. *J.Am.Vet.Rad.Soc.* 15 (2) : 44.
- Myers, P.H. and Nice, C.M. (1963) : An experimental approach in developing an inhalation bronchogram. *Radiology.* 81 : 624.
- Nadel, J.A., Wolfe, W.G. and Graf, P.D.(1968) : Powdered Tantalum as a medium for bronchography in canine and human lungs. *Invest.Radiol.* 3 : 229.

- Nelson, S.W. and Christifordis, A. (1959) : Barium Sulphate and Bismuth Subcarbonate suspensions as bronchographic contrast media. *Radiology*. 72 : 829.
- Nelson, S.W.; Christifordis, A.J. and Pratt, P.C.(1964) : Further experience with Barium Sulphate as a bronchographic contrast medium. *Am.J.Roentgenol*. 92 (3) : 595.
- Nelson, S.W. and Christifordis, A.J.(1973) : Bronchography in diseases of the adult chest. *Radiol. Clinics N.A.*11 (1) : 125.
- Nice, C.M.; Waring, W.W. and Killelea, D.E.(1964) : Bronchography in infants and children: Barium Sulphate as a contrast agent. *Am. J.Roent.* 91 : 564.
- Parker, H.;Horsfield,K. and Cumming, G. (1971) : Morphology of distal airways in the human lung. *J.Appl.Physiol*. 31 (3) : 386.
- Pickard, R.E. and Llamas, R.(1970) : Tantalum radiography of the respiratory tract in dogs. *Arch. Otolaryng.* 91 : 85.
- Reif, J.S. and Rhodes, W.H.(1966) : The lungs of aged dogs : A radiographic-morphologic correlation. *J.Am.Vet.Radiol.Soc.* 7 : 5.
- Rendano, V.T. and Quick, C.B.(1979) : Equine Radiology - The thorax. *Mod. Vet.Pract.*60 (4) : 323.
- Rinker, C.T.; Garrotto, L.J.; Lee, K.R. and Templeton, A.W.(1968) : Bronchography : Diagnostic signs and accuracy in pulmonary carcinoma. *Am.J.Roent.* 104 : 802.
- Robinson, N.E.(1979) : Functional abnormalities caused by upper airway obstruction in horses. Their relationship to the etiology of epistaxis. *Vet.Clinics. N.A. Large An.Pract.* 1 (1): 17.

- Schlesinger, R.B.; Schweizer, R.D.; Chan, T.L.; Keegan, A.F. and Lippman, M.(1975) : Controlled deposition of Tantalum powder in a cast of the human airways. Applications for aerosol bronchography. *Invest. Radiol.* 10 : 115.
- Shook, D.C. and Felson, B.(1970) : Inhalation bronchography. *Chest.* 58 : 333.
- Sumner, J.; Lichter, A.I. and Nassau, E. (1951) : Fatal acute iodism after bronchography. *Thorax.* 6 : 193.
- Suter, P.F.(1977) : Interpretation of pulmonary radiographs. In *Current Veterinary Therapy. VI.* Kirk, pp 298-309.
- Suter, P.F. and Chan. K.F.(1968) : Disseminated pulmonary diseases in small animals : a radiographic approach to diagnosis. *J.Am.Vet.Radiol.Soc.* 9 : 67.
- Suter, P.F. and Lord, P.F.(1974) : Radiographic differentiation of disseminated pulmonary parenchymal diseases in dogs and cats. *Vet.Clinics. N.A.* 4 (4) : 687.
- Suter, P.F.; Carrig, C.B.; O'Brien, T.E. and Koller, D. (1974) : Radiographic interpretation of primary and secondary metastatic pulmonary neoplasms of cats and dogs. *J.Am.Vet. Radiol.Soc.* 15 (2) : 3-25.
- Suzuki, T. and Ohkubo, M. (1977) : Lobation of the lungs of domestic animals, especially dog, cattle and horse. *Jap. J.Vet.Science.* 39 : 59-67.
- Teixiera, J. and Teixeira, L.C.V.(1959) : Bronchography without oil and iodine. The use of barium as a contrast medium. *Dis.Chest.* 36 : 256.

Thurlbeck, W.M. and Lowell, F.C.(1964) : Heaves in horses.

Am.Rev.Resp.Dis. 89 : 82.

Trapnell, D.H. and Gregg, I. (1969) : Some principles of interpretation of bronchograms. Br.J.Radiol. 42 : 125.

Tyler, W.S.; Gillespie, J.R. and Nowell, J.A.(1971) : Symposium on pulmonary and cardiac function. (1) Modern functional morphology of the equine lungs. Eq.Vet.J. 3 (3) : 84.

Walker, M. and Goble, D. (1980) : Barium Sulphate bronchography in horses. Vet.Radiol. 21 (2) : 85.

Webbon, P.M. and Clarke, K.W.(1977) : Bronchography in normal dogs. J.Sm.An.Pract. 18 : 327.

Weibel, E.R. and Vidone, R.A.(1961) : Fixation of the lung by formalin steam in a controlled state of air inflation. Am.Rev. Resp. Dis. 84 : 856.

Williams, D.J.; Kangstrom, L.E. and Olsson, S.E. (1965) : A radiological technique for the equine heart. Proc. 11th An.Conv. Eq.Pract. 243.

Willoughby, R.A. and McDonell, W.N.(1979) : Pulmonary function testing in horses. Vet.Clinics N.A. Large An.Pract. 1 (1) :171-196.

Willson, J.K.V.; Rubin, P.S. and McGee, T.M. (1959) : The effects of barium sulphate on the lungs. Am.J.Roent. 82:84.

Wright, B.M.; Slavin, G.; Kreef, L.; Calln, K. and Sandin, B(1974) : Post mortem inflation and fixation of human lungs. Thorax. 29 : 189.