

Copyright is owned by the Author of the thesis. Permission is given for a copy to be downloaded by an individual for the purpose of research and private study only. The thesis may not be reproduced elsewhere without the permission of the Author.

THE BRACHYCEPHALIC HEREFORD

DWARF

A thesis presented in partial fulfilment
of the requirements for the degree of
Master of Veterinary Science at
Massey University

Janice Marguerite Jones

1979

ABSTRACT

The present study was undertaken to define the type or types of dwarfism occurring in the Hereford breed of cattle in New Zealand as a basis to further work on the biochemical anomalies involved.

The mating of 13 cows that had previously given birth to dwarf calves with a bull that had allegedly sired dwarf calves resulted in both dwarf and phenotypically normal calves in proportions compatible with an autosomal recessive type of inheritance. Dwarf foetuses produced from dwarf with dwarf matings were similar to a foetus of carrier with carrier mating. This observation helped confirm that the mode of inheritance was autosomal recessive.

Selected morphological measurements of 45 dwarfs of various ages, and five dwarf foetuses were compared with those of phenotypically normal cattle and with published measurements of dwarfs and normal cattle from North America. It was concluded that the measurements were compatible with those expected from a single mutant and that the type of dwarf found in New Zealand was similar to the most common form of brachycephalic dwarf described in the Hereford breed in North America. This was in accord with expectations inasmuch as available evidence indicates that dwarfism was imported into New Zealand via four bulls who were from dwarf carrying families.

Histological examination of bone growth plates of 29 dwarf animals of various ages up to maturity and from five dwarf foetuses showed that columns of proliferating cells

tended to be shorter and more irregular than those of normal animals and that there was a reduced number of hypertrophied cells. Electron microscopy showed normal appearing matrix and chondrocytes, except for more apparent dilations of endoplasmic reticulum in the latter. The histology of other tissues was normal.

Urinary mucopolysaccharides of three dwarf animals and three matched controls were similar. This and the essentially normal histology led to the conclusion that this form of dwarfism was not a mucopolysaccharidosis.

ACKNOWLEDGEMENTS

This study was made possible by the assistance and encouragement of a number of people. It was carried out within the Department of Pathology and Public Health at Massey University and I am grateful for the opportunity to work towards a masterate degree in this Department. I would like to thank my supervisors, Mr. R.S. Wyburn, and Professor B.W. Manktelow, and especially Dr. R.D. Jolly, for his help and encouragement throughout the entire project.

A number of farmers made animals available for examination during the project and I would like to thank them for their contribution.

Preparation of tissues for light microscopy was carried out by Mr. C. Fletcher and others in the Department of Veterinary Pathology and Public Health, and Mr. D. Hopcroft of the electron microscope unit of the Department of Scientific and Industrial Research gave assistance with electron microscopy sections. Their help is most appreciated.

I am also grateful to Mr. N. Van-de-Water for advice and assistance with biochemical estimations, and to Mr. T. Law for printing the photographs. Figures in the text were prepared by the Massey University illustrator, Mrs. A. Larsen.

Finally, I would like to thank Mr. A.T. DeCleene for his cheerful assistance with the animals throughout this study, Mrs. E. Bristol for typing the draft copies of this thesis, and Mrs. A. TeHiwi for the final copy.

This research was funded by the New Zealand Hereford Cattle Breeders' Association and I am also grateful to W. & R. Fletcher N.Z. Ltd. who generously provided a scholarship for part of the study.

TABLE OF CONTENTS

	<u>Page</u>
LIST OF FIGURES	
INTRODUCTION	1
CHAPTER I : Review- dwarfism in man and animals.	2
CHAPTER II : Genetics.	47
CHAPTER III : Morphology of the Hereford brachycephalic dwarf in New Zealand.	52
CHAPTER IV : Histology	92
CHAPTER V : Biochemistry- analysis of mucopolysaccharides excreted by the Hereford snorter dwarf.	127
CHAPTER VI : General discussion	141
REFERENCES	145

LIST OF FIGURES

<u>Figure</u>		<u>Page</u>
3.0	Diagram of a dwarf metacarpus showing the measurements of total length (TL), diaphyseal length (DL) and diaphyseal diameter (DD).	55
3.1	An eighteen month old dwarf steer showing the typical short head, dished face, bulging forehead, pot belly, and short legs.	58
3.2	Head length to head width ratio values for 30 dwarf, 14 carrier, and 48 normal animals.	63
3.3	Metacarpal ratio value total length to diaphyseal diameter in 31 dwarf, 3 carrier, and 44 normal animals.	67
3.4	Metacarpal ratio value diaphyseal length to diaphyseal diameter in 30 dwarf, 3 carrier, and 7 normal animals.	68
3.5	Metacarpal ratio value total length to diaphyseal length in 31 dwarf, 3 carrier, and 12 normal animals.	68
3.6	Diagram of a midline sagittal section of the base of the skull in (a) dwarf and (b) normal animals comparing the measurement of length.	72
3.7	Head profiles taken with a profilometer, showing the variation between normal, carrier and dwarf profiles.	74

<u>Figure</u>		<u>Page</u>
3.8	Lateral radiograph from a 6 month old dwarf calf, showing concavity in dorsal body profile, lipping of epiphyses, irregularity and flattening of ventral vertebral body profile.	75
3.9	Lateral radiograph of the lumbar spine from a normal adult cattle beast.	75
3.10	Dorso-ventral radiograph of lumbar spine from a dwarf cattle beast, showing shortening of the transverse processes and forward hooking of the ends of the processes.	76
3.11	Dorso-ventral radiograph of lumbar spine from a normal cattle beast.	76
3.12	Lateral radiograph of the lumbar spine from an adult dwarf cow, showing the features seen in Figure 3.8, but with less pronounced irregularity of the ventral vertebral body surface.	77
3.13	Lateral radiographs of lumbar vertebrae from (a) dwarf, (b) suspected carrier, and (c) normal animal.	79
4.1	Epiphyseal plate from the distal radius of an 18 month old normal control animal. Note the long regular columns of chondrocytes.	98

<u>Figure</u>		<u>Page</u>
4.2	Epiphyseal plate from the distal metacarpus of (a) nine month old dwarf, and (b) eight month old normal control animal. The length of columns is shorter in the dwarf animal.	100
4.3	Epiphyseal plate from the distal metacarpus of (a) dwarf, and (b) normal control foetus at estimated 180 days gestation. Capillary ingrowth is not so regular in the dwarf foetal cartilage; there are fewer hypertrophied cells per column, and the cells appear smaller than in the normal foetal cartilage.	101
4.4	Epiphyseal plate from the distal metacarpus of (a) 18 month old normal control animal compared with that from (b) 2 year old normal control animal. The hypertrophied cells are fewer per column in the older animal and the regularity of the columns has been lost.	103
4.5	Epiphyseal plate from the distal metacarpus of (1) 18 month old dwarf compared with that from (b) 2 year old dwarf. Note the irregularity in both sections, with fewer hypertrophied cells in the older animal.	104

<u>Figure</u>		<u>Page</u>
4.6	Iliac crest from (a) nine month old dwarf compared with that from (b) eight month old control animal, showing the reduced number of hypertrophied cells in the cartilage from the dwarf animal.	105
4.7	Spheno-occipital synchondrosis from (a) dwarf foetus compared with that from (b) normal control foetus, at estimated 180 days gestation. The dwarf synchondrosis shows fewer proliferating cells at the base of the columns, less regular arrangement of columns, and fewer hypertrophied cells.	106
4.8	Chondrocytes from (a) dwarf cartilage, and (b) normal cartilage, showing the increased metachromatic staining substance within dwarf chondrocytes.	110
4.9	Proliferating zone of epiphyseal plate from dwarf cartilage showing metachromatic staining around some chondrocytes.	111
4.10	Resting chondrocyte in cartilage from an 18 month old dwarf animal, showing scalloped outline, large nucleus, vesicles and lamellae of golgi complex, and the endoplasmic reticulum. Glycogen (G) has been leached out during processing.	114
4.11	Detail of chondrocyte from dwarf cartilage showing vesicles and lamellae of the golgi complex.	115

<u>Figure</u>		<u>Page</u>
4.12	Chondrocyte from an 18 month old dwarf. (a) Note numerous fibrils in cell. (b) Detail of fibrils.	116
4.13	Chondrocyte from foetal dwarf cartilage showing essentially normal ultrastructural features.	117
4.14	Chondrocyte from a 10 month old dwarf animal showing dilatation of the endoplasmic reticulum.	118
4.15	Chondrocytes from dwarf foetal cartilage showing dilated endoplasmic reticulum.	119
4.16	Matrix of cartilage fixed in Karnovsky's fixative. (a) normal animal (b) dwarf animal.	120
4.17	Matrix of cartilage, fixed in Karnovsky's fixative but including toluidine blue in the fixing process. Note electron dense network extending from the end of the chondrocyte. No collagen fibres are visible. (a) normal animal (b) dwarf animal.	122
5.1	Profiles of mucopolysaccharides excreted in the urine of 3 normal and 3 dwarf cattle.	137

INTRODUCTION

From the late 1940's to the early 1960's, a large volume of literature was written concerning the problem of dwarfism in beef cattle, and in particular that occurring in the Hereford breed. Conflicting reports, and the occurrence of more than one type of dwarf, has led to some confusion.

The present project was undertaken to define the type or types of dwarf occurring in the Hereford breed in New Zealand and thus facilitate comparisons with those described from North America. It is thought that dwarfism in Herefords was introduced into New Zealand by the importation of four sires from the United States of America in the late 1950's. As it is likely that these were carriers of the most common type of dwarfism the New Zealand disease probably represents a single mutant. It was also needed to establish whether there was uniformity in the disease in this country as collaboration with other groups working on collagen structure was planned, and a representative sample from affected individuals was required.

Research into human dwarfism has increased greatly in recent years and much work has been published concerning biochemical defects and the histology of cartilage from various types of dwarfs. Light and electron microscopy therefore formed an important part of this study as there are very few reports in the literature concerning this aspect of bovine dwarfism.

CHAPTER IREVIEW - DWARFISM IN MAN AND ANIMALS

I. HISTORY OF DWARFISM IN NORTH AMERICA AND NEW ZEALAND

Brachycephalic dwarfism in Hereford cattle was first recorded in the literature by Johnson et al. (1950) but the problem had been recognised previously by breeders and the breed association. At the same time, dwarf calves were also occurring in other beef breeds such as the Aberdeen Angus and Shorthorn, but not in the proportions occurring in Herefords (Bone, 1963). The reason for the apparent increased incidence of dwarf calves in the pedigree herds has not been clearly established. McCann (1974), in a history of the dwarfism problem in the Hereford breed in North America, states that much of the problem arose because of the insidious build up of the dwarfism gene in a few of the popular herds of the time, including one herd in particular which commanded sale prices well above the average. This herd had one dwarf calf born in 1939 but its significance was not recognised at the time. Because of the strict outbreeding practised by the manager, no further dwarfs were born in the home herd for another 10 years. In the meantime, the highly regarded sire of this dwarf had left progeny which were sold into many of the pedigree herds in the country. Johnson et al. (1950), Gregory et al. (1951) and Emmerson et al. (1956) considered that the build up of the gene occurred because breeders were unconsciously selecting for carriers of the gene. Heterozygous animals

tend to be shorter in the leg and at the withers than normal cattle, but there is an overlap between the two groups (Bovard and Hazel, 1963). At that time the favoured build for beef breeds was a short stocky build, with a well muscled appearance, so heterozygotes could have had selection advantage.

In contrast, McCann (1974) in conducting experiments to see whether breeders and research workers were able to select carrier animals out of a group, found that although they tended to select short-legged, short-bodied bulls with "good heads" as carriers, and plain headed upstanding narrow bodied bulls were more often selected as being non-dwarf producers, the records of the bulls did not bear out conclusions of this kind, i.e. these trials did not demonstrate any correlation between phenotype and genotype.

In North America some progeny testing was carried out in the early 1950's in order to help breeders determine whether a particular bull was a carrier of dwarfism or not, but as this was expensive and time consuming it was replaced gradually by a system of pedigree checking. Stigma against certain recognised dwarf carrier lines built up and selling animals from these pedigree lines became almost impossible, even though many animals would have been normal. In 1955 the American Hereford Association requested information from breeders concerning the dwarf status of their herds. This resulted in a file of more than 50,000 pedigrees of dwarf producing animals from 47 states. In 1957 the first "clean pedigree" sale of Herefords was held.

It was not until the 1960's that the disease was recognised as a problem in New Zealand and investigations implied that the genotype arrived when cattle were imported from North America in the late 1950's. In 1969, the names of four imported bulls that were believed to be heterozygotes were made known to members of the New Zealand Hereford Cattle Breeders Association. There followed stringent culling of animals whose pedigree contained any of these sires, in an effort to reduce the prevalence of heterozygotes and the occurrence of dwarfs. However the genotype has remained, as indicated by a number of dwarfs born within this breed in recent years. Control measures initiated by the Association have encouraged breeders to cull animals descended from these four bulls. Breeders were allowed to retain and register such animals but these registrations could not be transferred. These animals, which could be sold to grade herds, or animals from herds not affiliated with the breed society, are probably the main source of the dwarf genotype in New Zealand, although it is also possible that the genotype remains in registered and transferable cattle.

II. INHERITANCE OF BOVINE DWARFISM

Prior to the first report in the literature concerning brachycephalic dwarfism in Hereford cattle (Johnson et al. 1950) it had been suggested that dwarfs were produced due to a nutritional or glandular defect. A few breeders only considered heredity may play a part. However, Johnson and his colleagues recorded dwarfism in a single herd where dwarfs first occurred when a single bull was mated to related cows. Furthermore, occurrence of dwarfs in related matings at two separate localities suggested that a nutritional cause was not likely. They suggested from the number and sex of dwarfs produced that dwarfism was inherited as a simple monofactorial autosomal recessive. Gregory et al. (1951) in an initial study which involved several herds and several hundred animals, agreed with this hypothesis concerning the inheritance of bovine dwarfism. When examining the long-headed dwarf Aberdeen Angus cattle, Baker et al. (1951) considered that this was the most likely mode of inheritance of the disease in this breed.

As dwarfed animals were reported which were not phenotypically the same as the snorter dwarf, it was suggested that the mode of inheritance may not be so simple. The so-called 'comprest' animals complicated the picture, as early reports suggested that this condition, which was thought to be a form of dwarfism, was inherited as an incompletely dominant gene.

In an attempt to clarify the situation several workers made a variety of crosses between different dwarf phenotypes and between and within different breeds (Gregory 1956 Abstr.; Gregory and Carroll, 1956; Dollahon et al. 1957 Abstr.; Gregory et al. 1957). It became evident that dwarfs of the shorthheaded variety in the Hereford and Angus breed were produced in numbers to confirm a recessive mode of inheritance. In contrast matings between compest animals, and carriers of various other types of dwarfism within various breeds, produced a variety of phenotypes which could not be accounted for by this mode of inheritance. It was suggested therefore, that bovine dwarfism was a complex of several components and that modifying genes were responsible for the different dwarf phenotypes (Gregory, 1955 Abstr.; Gregory, 1956 Abstr.; Gregory et al. 1957 Abstr.).

Gregory et al. (1964) later suggested that there might be confusion as to whether a calf was classified as a dwarf or not, and therefore progeny testing was carried out under controlled laboratory conditions, with each animal being checked anatomically for the criteria which established the "achondroplastic" condition. This method identified a large proportion of animals which would have been classified visually as non-dwarfs, but which showed diagnostic characteristics of mild achondroplasia such as an intermediate closure time of the spheno-occipital synchondrosis. Still later, he and his colleagues attempted to show a relationship between Dexter cattle and the various dwarf types, and also between the Telemark lethal and the achondroplastic dwarf (Gregory et al. 1966; Gregory et al. 1967).

From the results of these breeding trials it was postulated that the Dexter, Telemark, compest and compact cattle each possessed the same major recessive achondroplastic-conditioning gene, but the modifiers they possessed caused them to be larger than the brachycephalic, dolichocephalic and other dwarf types, which were all part of the same genetic complex.

Despite some conflicting reports in the later literature there appears little doubt that classical Hereford brachycephalic dwarfism is inherited as an autosomal recessive disease. Confusion has arisen in the literature due to different genes conditioning similar phenotypic forms segregating simultaneously in a population, the possibility of which was postulated by Gregory et al. in 1953.

III. MORPHOLOGY OF THE HEREFORD BRACHYCEPHALIC DWARF

The classical Hereford brachycephalic dwarf was described by Johnson et al. (1950) and Gregory et al. (1951) as having a short broad head with a low head length/head width index, a bulging forehead, and a "dished" face. There was frequently malocclusion of the incisors due to a shortened upper jaw and the tongue sometimes protruded. The body was wide in proportion to length and the legs were shorter than normal. Many dwarfs developed a pot belly early in life and were prone to develop ruminal tympany which sometimes caused an early death.

Gregory et al. (1951, 1953) emphasised the bulging mid-forehead region which was present in dwarfs. This region of the skull remained higher than the frontal eminence throughout the dwarf's life, whereas in normal cattle the mid-forehead region was slightly higher at birth, but this was lost with maturity.

Several authors observed a varying degree of hydrocephalus in dwarf animals (Johnson et al. 1950; Julian et al. 1956 Abstr.; Emmerson and Hazel, 1956; Hafez and Rupnow, 1960). It was noted by Julian et al. (1957) that the nuchal surface of the skull of the Hereford dwarf sloped downward and forward, rather than being perpendicular to the long axis of the skull. It was suspected that this may have been due to a shortness of the base of the skull. The time of closure of the spheno-occipital synchondrosis in the base of the skull was examined in 31 phenotypically normal Hereford cattle, and 47 shortheaded dwarfs. Closure occurred in the dwarfs as early as 1 day of age and in all dwarfs over the age of 5½ months this synchondrosis was found to be closed. In normal cattle with the exception of two animals, there was no evidence of the synchondrosis starting to close until after 2 years. In human achondroplastic dwarfs it has been established that early fusion of the spheno-occipital synchondrosis occurs and because of this analogy, it was suggested that the shortheaded Hereford dwarf was an example of achondroplasia.

Projections from the wing of the orbito-sphenoid bone and from the posterior intra-occipital synchondrosis were reported by Tyler et al. (1959) in a group of cattle examined. These cattle included dwarfs, obligate heterozygotes, and phenotypically normal cattle, although all animals came from herds with a history of dwarfism. These projections were found more frequently in the dwarf group and they also tended to be more severe in this group. A group of slaughter house cattle examined did not show any evidence of these projections. It was suggested that the projections occurred due to differential growth of the sphenoid and occipital bones, which are formed by endochondral ossification, compared with the bones of the remainder of the cranium, which form by intramembranous ossification.

Hafez and Rupnow (1960) studied carcass characteristics of dwarf cattle and compared them with normal animals. They found a disproportionality in development, particularly in measurements related to body length. Measurements of width were closer to those for normal animals. Dwarfs were found to have less body fat, heavier feet and smaller loin 'eye muscle' area at the twelfth rib. Palatability tests were also conducted, but no difference between dwarf and normal meat was detected. Anatomical measurements of internal organs showed there was little difference from those of normal controls (Hafez and Rupnow, 1960) but an ovoid heart shape was noted by some (Eveleth et al. 1956; Dinkel et al. 1960).

Tyler et al. (1957) examined the appendicular skeletons of 32 Hereford dwarfs of various ages and compared them with 32 normal control animals. They found no significant changes in the times of fusion of the epiphyses studied. Measurements of diaphyseal length, epiphyseal length and diaphyseal diameter of the limb bones indicated that dwarf long bones were disproportionate particularly in regard to diaphyseal length. Epiphyseal length and diaphyseal diameter were relatively normal. It was also found that the distal limb bones such as the metacarpus, were more severely affected than proximal bones such as the humerus. The authors considered the disproportionality was more severe in the young dwarfs and that this therefore indicated that the process was initiated in utero. It was pointed out by the authors that since the diaphysis lengthens mainly by interstitial growth, whereas appositional growth may also contribute to the length of the epiphysis, this was consistent with a diagnosis of hypoplastic achondroplasia.

Criteria for the diagnosis of the brachycephalic dwarf was published by Tyler et al. (1961), developed from the studies of disproportionate growth of the appendicular skeleton. A range of values for diaphyseal length, diaphyseal diameter and total length of the metacarpus, within which the majority of dwarf animals fall was given (see Table 1.I). There was less than 3% overlap between dwarf and normal animals.

TABLE 1.I

Ratio values for the metacarpus
(Tyler et al.)

	Total Length/ Diaphyseal Length	Total Length/ Diaphyseal Diameter	Diaphyseal Length/ Diaphyseal Diameter
Brachycephalic Dwarfs	1.21 - 1.29	3.3 - 4.4	2.7 - 3.8
Control Cattle	1.14 - 1.19	4.7 - 7.5	4.1 - 6.4

The authors stated that age, breed and sex had only minor influences on these indices and did not require corrective factors.

Emmerson and Hazel (1956) showed characteristic radiographic changes in the lumbar vertebrae in this brachycephalic dwarf. There was a flattening of the ventral profile with undulations on the ventral surface. The epiphyses did not appear to completely cover the metaphyses, and there was anterior hooking of the transverse processes. Changes intermediate between dwarfs and normals were described in carrier animals. They suggested that compression of the vertebral body occurred in the latter stages of gestation due to contraction of the longissimus dorsi and psoas major muscles. In contrast Julian et al. (1956 Abstr.) considered that the vertebral changes were due to a basic growth deficiency of the primary centres of ossification of the vertebrae, consistent with the achondroplastic nature of the dwarfing process.

Dwarf fetuses aged 60 and 90 days were examined by Patton et al. (1966). A number of loci of ossification were present in the 60 day fetuses, but the authors did not mention any difference in the number present between dwarf and normal fetuses. Measurements taken from 90 day fetuses showed a reduction in length for all bones measured from dwarf fetuses compared with the normals. Abortion of dwarf fetuses, not associated with any of the common infectious causal agents was reported by Bolin et al. (1957).

IV. HISTOLOGY OF THE HEREFORD BRACHYCEPHALIC DWARF

There has been little published concerning the histology of the Hereford brachycephalic dwarf. Most work concentrated on the histology of endocrine glands (Johnson et al. 1950; Lindley, 1951); and these were generally described as of normal appearance, although Lindley noted cystic pituitary glands. Jubb and McEntee (1955) examined pituitary glands from dwarf cattle using histochemical techniques, and they found an increase in the number of acidophiles, with no abnormality in beta or delta cells.

Tyler et al. (1956 Abstr.) examined the ephiphyseal plates from the metacarpal bones of dwarfs under two months of age, and concluded that the changes seen were most similar to those reported in mild hypoplastic achondroplasia of humans. Julian et al. (1951) examined the spheno-occipital synchondrosis from two dwarf animals showing partial fusion, but no histological differences to those changes occurring during normal closure were noted.

Both Johnson et al. and Lindley found the testicles to have reduced spermatogenesis.

Xallahan and Lorincz (1967) found no evidence of polysaccharide or glycoprotein storage in an ultrastructural study of foetal dwarf livers.

V. PATHO-PHYSIOLOGICAL INVESTIGATIONS OF THE HEREFORD BRACHYCEPHALIC DWARF

Clinical Pathology

A number of physiological parameters were measured in the Hereford dwarf (Hafez et al. 1959). No significant difference from normal was found in rectal temperature, pulse rate, red cell count, sedimentation rate, prothrombin time, electrophoretic pattern of serum proteins, serum creatine and creatinine, or calcium/phosphorus ratio in hair samples. However it was found that dwarfs had a slower respiration rate and lower blood haemoglobin, haematocrit and white cell count compared with normal controls. Cornelius et al. (1956) found all haematological values to be normal except for a change in the differential white cell count, in which lymphocytes were high and neutrophils low.

Haematological values in dwarf carrier animals were examined by Temple and Hazel (1961) in comparison with normal animals, but dwarf animals were not studied. There was a large variation between individuals and no association with a particular genotype was found.

Various authors have examined the response to stress in dwarf animals by the intravenous injection of insulin. Foley et al. (1956) and Deyoe et al. (1957) produced conflicting results when the white blood cell count was measured as a response to stress. Measurements of blood glucose levels after the injection of insulin indicated that dwarf animals were more sensitive to the insulin and responded with a significantly greater drop in blood glucose levels than that which occurred in normal animals (Foley, 1956; Taylor and Turman, 1959; Foley and Lasley, 1959).

Hormones

Since Gregory et al. (1951) drew attention to the similarity between brachycephalic dwarfism and thyroid deficient states in other animals, a number of conflicting reports have appeared concerned with the thyroid activity of these dwarfs. Carroll et al. (1951) compared the effect on the thyroid weight of chicks of dwarf pituitary glands, with those obtained from normal cattle. They found that while the dwarf pituitary caused some increase in weight compared with untreated controls, that from the normal cattle caused a much larger increase in weight. They concluded therefore that the dwarf pituitaries were deficient in thyrotropic hormone. Further studies showed that the dwarf pituitary did contain some growth hormone and also that stimulation of gonads occurred as normal.

Marlowe (1960) compared the effects of pituitary gland material from dwarf and normal calves on the growth of the tibia of hypophysectomised rats. Four trials were

conducted, the pituitary glands being prepared by different methods in each trial. Three trials showed a significant difference between dwarf and normal, indicating that there was less growth hormone per unit of glandular powder in the dwarf pituitaries, however the fourth trial showed no difference between the two groups.

In contrast, a bioassay conducted by Fransen and Andrews (1954) using pituitaries from 66 dwarf calves showed normal thyrotropic hormone activity. Gonadotropic hormone activity was also normal. In examining the glands, 9 animals were found to have cystic pituitaries and 21 animals had cystic adrenals; in some instances the same animal had both cystic adrenal and pituitary glands. The potency of pituitary suspensions from both dwarf and normal calves was tested by Marlowe and Chambers (1954). They found that there was normal activity of thyrotropic and gonadotropic hormones in the dwarf pituitaries, while there was higher potency of growth hormone from dwarf pituitaries than from normals.

The level of blood cholesterol was examined by Fransen and Andrews (1958a), because of the suggested association between blood cholesterol levels and thyroid activity; low thyroid levels being associated with an increase in cholesterol. Dwarf cattle were found to have significantly lower blood cholesterol levels than the normal controls, and it was concluded on this basis that thyroid activity in the dwarfs was relatively normal. Cornelius et al. (1956) suggested that serum cholesterol values may not be a reliable indicator of thyroid activity, however their measurements of protein bound iodine also confirmed that the shortheaded

bovine dwarf was not a primary thyroid cretin. The histochemical investigations of Jubb and McEntee (1955) which showed an increase in size and granulation of acidophiles, indicated there was unlikely to be a deficiency of thyrotropic hormone.

The effect of hormone injections on dwarf cattle was investigated by Andrews and Fransen (1958). Thyroprotein, androgen or oestrogen was injected, with three animals receiving a combination of these hormones, and their growth rate compared with untreated dwarfs. In most of the hormone treated animals, there was a faster rate of growth and a slight increase in height at the withers, but although results were not analysed statistically, it was considered that there was no evidence to suggest that dwarfism could be corrected by endocrine therapy.

Further evidence that a hormonal imbalance was not responsible was provided by Tyler et al. (1957). While performing anatomical studies on Hereford dwarfs, they observed a case of dizygotic twins, a dwarf male and a normal female. The animals had erythrocyte mosaicism, indicating an admixture of blood in utero. The authors concluded therefore that neither hormonal dysfunctions nor the intra-uterine environment could have been responsible for the dwarfing process.

Cerebro-spinal fluid pressure

Because of the reported occurrence of hydrocephalus in snorter dwarfs, several workers have measured cerebro-spinal fluid pressures. Fransen and Andrews (1958b) made measurements in dwarf and normal cattle, at the atlanto-occipital articulation, and at the junction of the last lumbar vertebra and the sacrum. High pressures were recorded for dwarfs whereas no pressure could be recorded for normal animals. Dollahon et al. (1959) stated that it was necessary to anaesthetise the animal before an accurate measurement could be made. They compared normal animals with dwarf carrier animals and found a difference in pressure measured between the axis and atlas, however there was considerable overlap between the two groups.

Cytology

Studies of cytochemistry and cytogenetics of bovine dwarfs have yielded varying results. Leuchtenberger et al. (1956) found that the DNA content of nuclei of sperm cells had a much greater variability than that of sperm cells from normal cattle, however this could not be accounted for by a change in chromosome number, as cytogenetic studies revealed a normal number. This normality was confirmed by Bruere (1969). Gluhovschi et al. (1972) found an additional chromosome belonging to pair 23, and also involution of the alpha cells of the pituitary gland in the dwarfs they studied, but a photograph of one of the subjects did not appear typical of the Hereford snorter dwarf and they may have been dealing with a different type of dwarfism.

VI. DETECTION OF HETEROZYGOTES

It was postulated by Johnson et al. in 1950 that animals heterozygous for the dwarf genotype were of an intermediate phenotype and that selection policies in the herd they studied would have led to more heterozygotes being retained in that herd. A large part of the research into dwarfism since that time has been concerned with the development of a simple and reliable method of determining heterozygotes so that the incidence of dwarfism could be reduced more rapidly.

Because it had been shown that dwarf animals possessed bulging foreheads which were not present in homozygous normal animals, Gregory et al. (1953) measured median head profiles of proven heterozygous animals to determine whether or not there was any expression of this characteristic in them. An instrument called a profilometer was developed for this purpose (Gregory and Brown, 1952). Several distinct head profile patterns were found and there were also differences in profiles associated with sex. From the graph of the head profiles of bulls, measurements were made and a key constructed, whereby individual bulls were classified as dwarf, heterozygote or normal. Gregory considered that the errors made in classifying an animal by its head profile would be between 2% and 4%. The basic head form of cows tended to mask the effects of the dwarf gene, and so recordings of profiles were limited to bulls. The authors also agreed with Johnson et al. that the dwarf gene contributed features to a heterozygote animal thought desirable by cattle judges and breeders.

It has been shown by several workers that the abnormalities which occurred in the lumbar vertebrae in the dwarf animal could be identified readily on radiographs of the live animal, especially if taken at less than 10 days of age (Emmerson and Hazel, 1956; Hazel et al. 1956; High et al. 1959; Rankin et al. 1959). These authors also found that carrier animals tended to have similar changes in the lumbar vertebrae although to a much lesser degree. Despite this Hazel et al. in performing limited progeny testing in association with radiographic testing, found that some vertebral classifications did not agree with genotype and High et al. found that although the accuracy of the radiographic method was nearly 100% in detecting dwarf animals, there was considerable overlap between carrier and normal animals in the range of morphology exhibited by the lumbar vertebrae. He suggested that radiographs of a bull's progeny could be used as a general method of predicting his dwarfism status, but the X-ray method was not recommended for the prediction of an individual animal's genotype.

Progeny testing of bulls although time-consuming, was regarded as the most accurate method of detecting heterozygotes. Despite this Gregory et al. (1964) found that a number of breeders reported a disproportionate number of bulls which were assumed dwarf-free at the $<.01$ level of probability but which eventually produced a dwarf calf. From their own experimental progeny testing they found that a "significant percentage" of progeny which would not have been visually classified as dwarfs, did in fact show on closer examination one or more characteristics of dwarfism. These progeny

were a number of smaller than average animals initially classified with the non-dwarf progeny of test bulls mated to carrier or compest type animals. Some of these animals were found to have one or more metacarpal indices in the dwarf range, and some were found to have spheno-occipital synchondrosis closure times between eight and twenty-three months. This was intermediate between that recorded for normal and dwarf animals. These findings suggested that there may be a range of expression of the dwarf gene and that some cases were missed on visual examination.

A number of studies have shown that there are differences in specific body measurements between normal and carrier animals. Arthaud et al. (1957) found that not only was the cannon shorter in carrier calves than in normals, but that its width and circumference were also greater. However the overlap between the two groups was so large that it could not provide an accurate basis for distinguishing the two groups.

Bovard and Hazel (1963) showed that the dwarf gene had a small but real effect on growth patterns of phenotypically normal calves heterozygous for the dwarf gene, this effect being significantly greater in males than females. The large and significant variation in growth rates among normal calves of both sexes would however, obscure the effects of the dwarf gene and preclude the use of the measurements studied as a means of determining heterozygote animals.

These results were in general confirmed by Marlowe (1964), who also found that calves from carrier parents tended to grade higher than calves from normal parents, and

to have a higher subjective score for masculinity. These characteristics may have led breeders and show judges to favour the heterozygote animal.

VII. OTHER TYPES OF DWARF CATTLE

Several reports of dwarf cattle occur in the literature prior to 1950. Crew reported a case of dwarfism in 1923. He recognised the Dexter breed as being a mild form of achondroplasia and the Dexter "bulldog" lethal as an extreme form of achondroplasia.

Telemark chondrodystrophic calves were originally described by Mohr (1926). They represented a recessive lethal form of dwarfism and exhibited hydrocephalus, brachygnathism, cleft palate, and very short limbs.

Gregory et al. (1942) reported a recessive achondroplastic condition in Jersey cattle which had a rather variable phenotypic expression. The bones of the skull and jaws were most often affected, there being little difference in leg length from normal. Calves had a short broad head and a prominent forehead.

Mead et al. (1942) described an example of proportionate dwarfism in Jersey cattle. These calves could not be distinguished at birth, but their growth rate was slower than normal so that by the age of 12 months they were about four inches shorter at the withers than normal animals. More recently achondroplasia in Holstein-Friesian cattle was described by Bowden (1970). These cattle were similar to

those occurring in Jersey cattle and described by Gregory et al. (1942). The condition was apparently recessive and affected chiefly the skull and maxilla, there being only occasional leg involvement. Calves showed a protruding tongue and in some the eyes were affected.

Compact Shorthorns were described by Stonaker and Tom (1944). These animals could be identified at birth, and were shorter in the head, neck, body and legs than standard shorthorns. They appeared to be well muscled and because their beef conformation was highly regarded at the time, several breeders favoured them for the production of fat show steers.

Baker et al. (1950) reported the occurrence of stumpy shorthorns, animals which had a curly coat, and thus could be distinguished at birth. Changes in the forelegs were the most obvious, there being enlargement of the knees, twisted cannon bones which gave the animal a bow-legged appearance, and the foot was often turned outward. The body length appeared to be normal and no deformities of the head were noted. It was suggested that there was a metabolic disturbance, because most animals were thin and failed to put on the normal amount of fat.

The occurrence of an apparently dominantly inherited type of achondroplasia was reported in Swedish Red and White cattle (Johansson, 1953). These animals had a short broad head, a moderately bulging forehead and the upper jaw was shorter than the lower jaw. The legs were comparatively short, particularly below the knee and hock and there was slight metaphyseal flaring of the metacarpals. A single

bull produced 25 of the malformed calves and 28 normal calves, in two different herds, in unrelated matings.

In Angus cattle two or three different types of dwarf have been described. Brachycephalic Angus calves were described by Baker et al. (1951). At birth they were not always readily distinguished from normal calves, but by the age of 2 - 3 months such calves exhibited compact low-set, thick bodies with short wide heads, though with age the head became longer and narrower. They did not usually grow or fatten normally. Long headed Angus were similar to snorter Herefords in general body conformation, but the head tended to be long and narrow without the mid-forehead bulge. Breathing was normal (Koger et al. 1955). Anteater Angus cattle were characterised by a long pointed nose and were phenotypically distinct from the long-headed type. Although it was an inherited condition it was considered that environmental influences may play a part (Koger et al. 1955).

Koger et al. (1955) reviewed the different types of dwarfism found in cattle and include the following in their list:- snorter Herefords; Angus dwarfs similar to snorter Herefords; long-headed Angus (dolicocephalic); compressed Herefords; Anteater Angus; long-headed Herefords and Shorthorns; stumpy Shorthorns; Midget Brahmans; Guinea crossbred and Florida native cattle.

The Long-headed Hereford and Shorthorn dwarfs were considered by Koger and his colleagues to be distinct from the long-headed Angus, but they were similar phenotypically. Midget Brahman cattle were small compact animals, the inheritance of the condition being apparently recessive or

incomplete dominance. Guinea-crossbred and Florida native cattle were similar to compressed Herefords and midget Brahms.

Although they have not been adequately defined, the type of Hereford known as "Comprest" confused the situation of Hereford dwarfism. They were relatively short, wide and low set, being about 90% of the normal height and 77% of the normal weight of other Herefords (Gregory et al. 1964).

VIII. TYPES OF DWARF IN MAN WITH PARTICULAR REFERENCE TO ACHONDROPLASIA AND THE MUCOPOLYSACCHARIDOSES

A recent publication (Felson, 1973) brought together, and briefly discussed, over one hundred syndromes in man in which a degree of dwarfism was a feature. However Saldino (1973) considered achondroplasia was the most common and best known skeletal dysplasia.

Achondroplasia has been known as an entity in humans for thousands of years. Two of the deities of ancient Egypt were depicted as disproportionate dwarfs, one showing typical features of achondroplasia. While it was recognised early in the century that several different types of dwarfism existed, later attempts to simplify classification led to confusion and differing conditions were classified for example as variants of typical achondroplasia. With improved techniques and more thorough examinations, it is now recognised that the condition of achondroplasia in humans is well defined and relatively simple to diagnose clinically.

Individuals with achondroplasia are rarely misdiagnosed, but other types of short limbed dwarfs may be wrongly diagnosed as having achondroplasia.

The condition is inherited as an autosomal dominant, and approximately 75% of achondroplasts occur as the result of a new mutation. Gardner (1977) on the basis of several surveys of births calculated the incidence of mutant achondroplasia to be $2.9 \times 10^{-5} \pm 1.1 \times 10^{-5}$. Homozygous achondroplasia has been reported but is very rare (Saldino, 1973). The condition results from the mating of two achondroplastic dwarfs, and is lethal, the affected child being usually born alive but dying within the first few days or weeks of life. Roentgenological features similar to those seen in achondroplasia have been observed although to a more severe degree.

The roentgenological features of achondroplasia in humans have been well documented in the literature (Langer et al. 1967; Rubin, 1963; Caffey, 1958; Saldino, 1973).

These may be summarised as follows: The most valuable areas to examine for a diagnosis of achondroplasia included the skull, lumbar vertebrae, pelvis and limbs. The skull showed an enlarged cranium relative to the face, a prominent frontal bone, and a small chondrocranium. The foramen magnum was small. Lateral radiographs of the lumbar vertebrae showed shortening of the pedicles. There was increased concavity of the posterior surface of the vertebral bodies, increase in the intervertebral disc spaces and an older child could show pronounced lumbar lordosis. Antero-posterior radiographs showed constriction of the spinal canal

(narrowed interpediculate distances) which was progressive from above downward. All parts of the pelvis were smaller in achondroplasts at all ages, however the reduction was more in length than in breadth. The ilium was more reduced in size than the ischium or pubis. The greater sciatic notch was flattened to a narrow and relatively deep cleft; the lower tapered segment failed to develop and the base of the ilium was almost as wide as its top. The thoracic cage was relatively small, particularly in the antero-posterior diameter.

There was a rhizomelic shortening of the arms (i.e. shortening was manifested more proximally), but a significant proportion of achondroplasts did not show this pattern in the legs; all the long bones however showed a degree of shortening in length with the diameter of the diaphysis being of approximately normal size. In the hands the metacarpals and distal phalanges were not strikingly abnormal, but the proximal and middle phalanges were broad and relatively short. Rubin (1963) considered that an amplification factor was involved in the production of the rhizomelic dwarfing; the long tubular bones had a greater growth potential and they were therefore more affected by the dwarfing process than the distal bones.

The biochemical defect in achondroplasia has not yet been defined. However, children with achondroplasia have been found to have glucose intolerance and also elevated plasma free fatty acids; it was suggested that these findings indicated a metabolic defect in carbohydrate metabolism (Collipp et al. 1972), as well as a cartilage defect.

Ponseti (1970) showed that extraction of a protein-polysaccharide complex was more difficult from human achondroplastic cartilage than from normal cartilage, and that it also had an altered hydroxyproline : hexosamine ratio. Possibly the more fibrous cartilage was not resorbed so readily.

Until recent years the histological findings in achondroplasia have varied between reports but it was generally considered that achondroplasia was associated with markedly disorganised endochondral ossification. The literature was confused as to what was typical of this condition and this was because most of the histology was done on cases of 'achondroplasia' which died at birth or shortly after. It has since been realised that these cases were not achondroplasia at all but represented cases of thanatophoric dwarfism, achondrogenesis, the Kniest syndrome or metatropic dwarfism (Rimoin, 1976).

Cartilage from the iliac crest of nine achondroplastic children was examined by Ponseti (1970). It appeared essentially the same as samples from normal children. Samples of epiphyseal plate from the fibular head however had a narrow hypertrophic zone with cells of an uneven size. Vascular invasion of the zone appeared to be uneven and in some places the hypertrophied cells were separated from the invading vascular channels by a zone of partially calcified cartilage matrix often covered by a layer of bone. The cartilage cell columns were separated by wide cartilaginous septa rich in collagen fibres. Partially calcified cartilage masses persisted in the metaphyseal bone trabeculae.

The authors considered that there was a different type of calcification and ossification occurring in the iliac crest, from that occurring in the long bones, and that this explained why growth of the wings of the ilium was nearly normal in their achondroplastic patients compared with the short bones of the extremities.

In contrast, Rimoin (1974, Rimoin et al. 1976) found the cartilage histology in cases of achondroplasia to be basically normal. There were regular columns of cells with normal appearing matrix comparable to that of age matched controls. The cellular columns appeared as individual rows of cells or as clusters of cells, as in the normal controls. The number of cells per column did not differ significantly from normal, but the primary trabeculae were sometimes slightly wider. There was overgrowth of the periosteal bone, which extended into the perichondrium of the resting cartilage. Ultrastructural studies by this author showed that the chondrocytes appeared normal as did the matrix. The only apparent abnormality was an increase in the number of dead cells which were surrounded by microscars containing aggregations of collagen fibrils.

In homozygous achondroplasia, the resting cartilage appeared normal, but there was a generalised absence of regular column formation with a short growth zone (Rimoin et al. 1976).

There are several other forms of short limbed dwarfism which must be differentiated from achondroplasia. Silverman (1968, 1973) considered thanatophoric dwarfism in the newborn, and hypochondroplasia and pseudoachondroplasia in later life

could be confused with achondroplasia. The histology of the epiphyseal plate in hypochondroplasia appeared normal, and the disease was less severe than achondroplasia.

Thanatophoric dwarfism was previously confused with achondroplasia, however the histology has been found to be distinctive (Rimoin et al. 1976). Resting cartilage appeared normal, but the growth plate was completely disrupted. In most areas there was no attempt at column formation, although short columns did occur in a few patches. Vascular invasion of the growth plate was irregular and the trabeculae were uneven and sometimes formed horizontal bony spicules.

Pseudoachondroplastic dwarfism was studied by Cooper et al. (1973a). With light microscopy large chondrocytes were noted and there was some disorganisation of column formation. Ultrastructurally most of the chondrocytes were seen to contain curvilamellar bodies within distended rough surfaced endoplasmic reticulum.

Dilated endoplasmic reticulum in the chondrocytes was also seen in the Kniest syndrome (Siggers et al. 1974) and in metaphyseal dysostosis (Cooper et al. 1973b).

The mucopolysaccharidoses are a further group of diseases characterised by dwarfism. They are well documented in the literature, and recent reviews include those by Neufeld et al. (1975) and Dorfman and Matalon (1976). There are seven different entities described, designated by numbers I - VII, and these are also known by eponymic names. A summary of the enzymic defects in the mucopolysaccharidoses is given in Table 1.II.

TABLE 1.II

Summary of enzymic defects in mucopolysaccharidoses
(from Dorfman and Matalon, 1976)

Name	Accumulated product	Enzyme deficiency
Mucopolysaccharidosis IH Hurler	Heparan sulfate Dermatan sulfate	α -L-Iduronidase
Mucopolysaccharidosis IS Scheie	Heparan sulfate Dermatan sulfate	α -L-Iduronidase
Mucopolysaccharidosis II Hunter	Heparan sulfate Dermatan sulfate	L-Iduronosulfate sulfatase
Mucopolysaccharidosis IIIA Sanfilippo A	Heparan sulfate	Sulfamidase
Mucopolysaccharidosis IIIB Sanfilippo B	Heparan sulfate	α -N-Acetylglucosaminidase
Mucopolysaccharidosis IIIC Sanfilippo C	Heparan sulfate	α -Glucosaminidase (?)
Mucopolysaccharidosis IV Morquio	Keratan sulfate Chondroitin sulfate	N-Acetylhexosaminidase 4-SO ₄ sulfatase
Mucopolysaccharidosis VI Maroteaux-Lamy	Dermatan sulfate	N-Acetylhexosaminidase 6-SO ₄ sulfatase Arylsulfatase B
Mucopolysaccharidosis VII	Dermatan sulfate Heparan sulfate Chondroitin sulfate	β -Glucuronidase

The clinical features of Hurler's syndrome include dwarfism, grotesque facies and skeletal malformations involving the skull, vertebral column, (kyphosis with gibbus) and the extremities (short broad hands, stubby fingers). Deformities of the thoracic cage together with abnormalities of the bronchial cartilages may give rise to dyspnoea. There is also clouding of the cornea after the first year of life. Occasionally there is hydrocephalus. Valvular changes occur in the cardiovascular system and there may be a protruberant abdomen due to hepatosplenomegaly. Involvement of other connective tissues causes a limitation in the extensibility of the joints (Bornstein, 1974).

The other mucopolysaccharidoses, i.e. Hunter syndrome, San Filippo syndrome, Morquio syndrome, Schie syndrome and Maroteaux-Lamy syndrome, have similar clinical features, but differ in degree and the presence or absence of mental retardation.

The characteristic histopathological findings in the mucopolysaccharide disorders in man is the presence of large cells in which the lysosomes are distended with mucopolysaccharides. These are termed clear cells or gargoye cells. They originate as fibroblasts or macrophages. Because of the solubility of mucopolysaccharides in aqueous solutions, most of the compound is lost in the processing of the tissues and the cells appear to contain empty vacuoles. Vacuolated cells are found in the liver, heart valves, blood vessels, meninges, cornea, periosteum, cartilage and tendons.

IX. MUCOPOLYSACCHARIDE STUDIES IN SNORTER

DWARF CATTLE

Characteristics shown by a typical snorter Hereford dwarf that appeared analagous to the dwarfism which occurred in Hurler's syndrome, were observed by Lorincz (1960, 1961). Isolation and identification of urinary acid mucopolysaccharide excretion was carried out in snorter dwarfs, known carriers, and normal cattle, and it was found the dwarf animals excreted 20 - 30 times as much mucopolysaccharide as the normal animals. Carriers appeared to excrete intermediate amounts. Histological and chemical analyses of liver and other tissues demonstrated that abnormally large amounts of acid mucopolysaccharides occurred in the tissues of the affected animals. Lorincz concluded that the snorter dwarf provided an animal model for the study of altered acid mucopolysaccharide metabolism. McIlwain and Eveleth (1962) confirmed Lorincz's results of a higher excretion of these compounds in the urine of dwarf cattle. In contrast Tyler et al. (1962) determined the mucopolysaccharide content of the urine from two established brachycephalic dwarfs. They found the concentration of total urinary polysaccharides was 28.5 mg/l for one calf and 3.2 mg/l for the other. No control measurements were made. The concentration of total mucopolysaccharides in the urine in Hurler's patients ranges from 33 - 245 mg/l.

Mayes et al. (1964) examined mucopolysaccharide excretion in the urine of 19 brachycephalic dwarfs, 19 dwarf controls (i.e. other types of dwarfed cattle) and 20 normal controls. At the same time they also examined urine from

normal humans and from patients with Hurler's disease. The total mucopolysaccharide excreted was similar in the 3 groups of cattle, whereas it was high in the Hurler's patients. The cattle were as closely matched as possible in terms of age and sex. The authors showed very significant changes in levels of mucopolysaccharide and creatinine in the urine with age of the cattle, both dwarf and normal values decreasing between 6 - 12 months of age. Histological examination of the liver failed to reveal any Hurler's cells.

Lorincz (1964) reviewed some of the literature concerning Hurler's disease and then compared the clinical picture of Hurler's disease with that of snorter dwarf cattle. He stated that the signs in Hurler's disease which did not occur in the cattle included: Corneal clouding, significant hepatosplenomegaly, characteristic radiological changes in the long bones and the typical gargoye cells in the liver and other tissues. Also lacking were the bone marrow histiocytes with metachromatic granules and alterations from normal histology in bone and cartilage. An examination of bovine dwarf skin culture cells by Thompson et al. (1969), did not reveal any metachromasia when they were stained with toluidine blue. In contrast metachromasia was demonstrated by Lorincz in liver tissue from dwarf animals when stained with toluidine blue. There was also increased feathering of the cytoplasm in hepatic parenchymal cells which was not observed in normal animals. Electron microscopic examination revealed distention of the endoplasmic reticulum.

Hurst et al. (1975) re-examined Lorincz's original material, and isolated and characterised the urinary glycosaminoglycans present. Eight dwarf animals were used, 6 months of age or older and two control cattle, ages not stated. A 30 fold increase in the amount of uronic acid in the dwarf urine as compared with that from the control animals was found. Analysis showed that the predominant glycosaminoglycan present was chondroitin 4-sulphate. Hurst and his colleagues compared this with human cases of excess chondroitin 4-sulphate excretion (Sly et al. 1973). They also suggested that perhaps animals of a different genotype had been used by the previous workers who had disputed their earlier results.

X. SOME FORMS OF DWARFISM IN OTHER ANIMALS

A number of different forms of dwarfism have been described in several animal species, but in some cases the classifications are misleading as they were based on human dwarfism research and the incorrect concept that achondroplasia in humans had disorganised endochondral ossification (Rimoin, 1976). Some of the less recent references should therefore be re-evaluated in the terms of the present knowledge.

In discussing the use of animal models for studies into the human chondrodystrophies, Rimoin stated that there should be a tight correlation in terms of the clinical disease, extraskelatal abnormalities, mode of inheritance, radiographic skeletal abnormalities, and the histological and ultra-structural appearance of cartilage.

Dogs

Pituitary dwarfism has been described in the German Shepherd dog (Andresen et al. 1974, Willeberg, et al. 1975). These dogs had low levels of growth hormone, and the authors considered that the condition could be inherited as a simple autosomal recessive or that there may be a genetic predisposition to the condition.

Gardner (1959) described a condition in oodles which he called chondrodystrophia foetalis or achondroplasia. Pups affected with this condition, which appeared to be inherited as a simple recessive, showed difficulty in walking, had short limbs, a wide broad snout with widely set eyes and had difficulty with feeding because of defective posture. Radiologically there was enlargement of the ends of the long bones, which was due to excess cartilage. The calcified ends of the diaphyses were splayed out, and the vertebral bodies were small and misshapen.

Histologically, columns of cartilage cells at the growing ends of the long bones were abbreviated and irregular, but this was not extreme. The bony trabeculae appeared small and irregular. Rimoin (1974) examined chondro-osseous tissue from examples of this disease and described irregular endochondral ossification and inclusion bodies in the chondrocytes. He considered that the case was more typical of human pseudoachondroplastic dysplasia, rather than achondroplasia.

Other breeds of dog have been assigned as chondrodystrophoid, as they showed features of chondrodystrophy but had normal endochondral ossification, e.g. the Basset hound,

Pekingese and Bulldog. These dwarfed breeds of dog which inherit their dwarfism as dominant traits and have normal endochondral ossification may thus be models of human achondroplasia (Rimoin, 1975). Braund et al. (1975) compared the histology of the epiphyseal plate of the femur and the intervertebral disc in greyhounds, beagles and dachshunds. There was regular endochondral ossification in the greyhound, but the proliferative zone in the beagle and dachshund was disoriented, the maturation zone was abbreviated and there was an irregular ossification line. The authors concluded that the beagle and dachshund should be considered achondroplastic.

A chondrodysplastic condition inherited as a mendelian recessive has been described in the Alaskan Malamute dog (Fletch et al. 1973; Fletch and Pinkerton, 1972). All bones formed by endochondral ossification were shortened, with wide growth plates, although the distal ulnar growth plate showed the most striking changes. Histologically the columns of hypertrophied cartilage cells were increased in length, although the arrangement was orderly. Supplementation with calcium, phosphorus and vitamin D did not have any effect on the skeletal development (Fletch et al. 1973) nor did measurements of the concentration of bone mineral indicate that it was a vitamin D-resistant rickets (Hoag et al. 1976 a). Fletch et al. (1973) classified the disease as canine chondrodysplasia, but it was not a model for achondroplasia in man.

..... Hoag et al. (1976 a) found a difference in the extractability of the bone mineral although the reason for this was not clear. Because normal mineralisation depends on the matrix being normal, it was suggested that collagen and mucopolysaccharide fractions should be examined. In a later report Hoag (1976 b) found that there was no difference in the hydroxyproline extraction rate or pattern between the dwarf Alaskan Malamute and the normal animal. Excretion of mucopolysaccharides was the same in both groups at the age of six weeks, but the dwarf animals excreted four times the level of the normal animals at 6 months of age. It was suggested that this was unlikely to indicate the disease was a mucopolysaccharidosis, but rather that the increased levels were due to delayed bone maturation and increased amounts of cartilage present in the long bones. Histological studies confirmed that there were increased amounts of cartilage and mucopolysaccharide. They concluded that the changes in the mucopolysaccharide excretion may be secondary to some as yet unknown primary lesion. Affected dogs were shown to have high levels of copper and iron in the tissues (Brown et al. 1977 a) and there was some alteration in collagen synthesis (Brown et al. 1977 b).

Sheep

The Ancon mutation in sheep was described by Chang (1949a, 1949b). It represented an autosomal recessive disease with disproportionate development. There was a broad, short skull, a relatively wide scapula, narrow vertebrae and short leg bones, of which the cannon bone was the most

severely affected. The leg bones were wider, relative to length, than normal. Histologically the epiphyseal plate was hypoplastic and canals containing blood vessels tended to form a network which isolated the proliferating column cells into conical clumps. There was intensified periosteal ossification. The authors found that the epiphyseal plate of the newborn Ancon resembled that found in skeletons of ageing mice and rats. Staining with toluidine blue indicated no difference in matrix between Ancon and normal sheep. It was considered that the Ancon mutant represented a mild type of hypoplastic chondrodystrophy.

A preliminary report described a chondrodystrophy in lambs (Duffel, 1977). Of 27 dwarfs born from 100 ewes mated to two rams, most were born alive, but died immediately after birth. Compared with the phenotypically normal lambs they had a low birth weight, reduced length, domed skull, short limbs, a narrow thorax, pot belly and a hairy coat. As the ewes were of mixed breeds, and as two rams were used, it would seem more likely that this condition was due to a teratogen, rather than to an inherited defect.

Rabbit

There have been four chondrodystrophies recorded. In the 'Pelger' form (Gruneberg, 1963) the homozygous affected animals (Pg/Pg) generally died at birth, had micromelic limbs and thickened cartilaginous ribs, but the axial skeleton was less affected. Heterozygotes were normal except that the heterophils had reduced segmentation.

A second lethal chondrodystrophy (cd/cd) in the rabbit inherited as a simple recessive, had disproportionately shortened limbs, a short broad head with a prominent calvarium and a flat face (Gruneberg, 1963). Fox (1975) compared the gross finding in this mutant with the condition of metatropic dwarfism in the human. Histologically there was an absence of regular columns of cartilage cells in the growth zone.

In contrast, the Dachs rabbit (Da/Da) was viable and able to breed. It was characterised by reduced size and micromelia (Gruneberg, 1963). Disproportionate shortening of the long limb bones was seen in the 21 day old foetus, to the same degree as in the adult. Affected rabbits later showed severe crippling. Closure of the spheno-occipital synchondrosis is very variable in the normal rabbit, and in fact usually only partial closure occurs even in rabbits 5 years old. In the Dachs rabbit there may be complete closure at birth (Sawin, 1959).

The fourth type, the achondroplastic rabbit (ac/ac), was characterised by shortened long bones with an irregular metaphyseal line, and a slightly enlarged skull. Affected rabbits died shortly after birth, although with artificial respiration and feeding, Shepard et al. (1969) were able to maintain them for three days. These authors found an increased number of dead cells in the resting cartilage of achondroplastic rabbits. There was less cartilage matrix in the dwarfs compared with controls, and nuclei were larger, although the cytoplasmic area was the same. There was irregularity of cartilage columns. Ultrastructurally no

differences between dwarf and normal were noted. The central avascular portions of dwarf cartilage appeared to show more abnormalities than the peripheral areas. The authors hypothesised that the central cartilage area may need to utilise an alternative metabolic system and that in the dwarf, part of this system is missing. While the syndrome resembled that of thanatophoric dwarfism in humans, Rimoin (1975) did not consider the histology typical of this condition, although he pointed out that as the histology of normal rabbit cartilage differs from that of the human, comparisons were difficult.

Shepard (1971) grew organ cultures of cartilage from the achondroplastic rabbit. He found that there was significantly higher incorporation of ^{14}C from glucose in the dwarf cartilage, indicating an alteration in glucose metabolism. Similar experiments using dwarf kidney and heart indicated that the glucose metabolism in these organs was the same in the dwarf and the normal. Because of its relatively anaerobic environment, cartilage relies more on anaerobic glycolysis than do other tissues, and glucose is necessary for the production of both acid mucopolysaccharide and collagen. The uptake of ^{35}S however was found to be the same in the dwarf and the normal, which suggested that acid mucopolysaccharide production was normal in the achondroplastic rabbit.

Mice

A number of different dwarf types have been reported in mice.

Gruneberg (1963) reporting on pituitary dwarfism in the mouse stated that the anterior lobe of the pituitary lacked typical acidophil cells and failed to produce growth hormone.

This resulted in proportionate dwarfism; growth could be restored by administration of suitable hormone preparations. Other proportionate dwarfs occur in both the rat and mouse which are not due to endocrine dysfunctions.

Miller and Flynn-Miller (1976) discussed the pathology found in three types of disproportionately dwarfed mice : achondroplastic (cn/cn), brachymorphic (bm/bm) and stubby (stb/stb). They were characterised by a shortening of the long bones and vertebrae, which was most severe in the achondroplastic homozygotes and least severe in stubby. Achondroplastic mice had a distended abdomen. Histologically the basisphenoid - presphenoid and basisphenoid - occipital synchondroses in the base of the skull of cn/cn were severely disturbed and prematurely closed. The stubby mutant was similar but to a lesser degree. Epiphyseal plates were reduced in thickness, but appeared well organised. The brachymorphic mouse showed quite distinct histology. The chondrocyte columns were irregular and zones were not so well defined. Silberberg et al. (1977) showed histologically that endochondral ossification in the brachymorphic mouse was characterised by an absence of hypertrophic cells and disorientation of the cartilage closest to the metaphysis.

Histological studies by Orkin et al. (1977) on cartilage from the brachymorphic mouse showed that there was reduced staining for sulphated glycosaminoglycans. Ultrastructurally the granules of proteoglycan aggregates appeared smaller than normal and reduced in numbers, especially in the proliferating and hypertrophic zones. Collagen fibrils appeared normal. Other experiments (Orkin et al. 1976) indicated that there

were normal levels of proteoglycan as judged by uronic acid content in the brachymorphic mouse, but the sulphate level and the incorporation of labelled sulphate in the mutant cartilage was lower than normal. The authors concluded that there was undersulphation of the chondroitin sulphate in the mutant cartilage. Dyes used to stain for proteoglycans bind primarily to the sulphate groups and therefore undersulphation would explain the reduced staining noticed histologically.

Another type of dwarf mouse, designated chondrodysplasia (cho/cho) was distinct from the achondroplastic mutant, and was characterised by short limbs, cleft palate and death by asphyxia. Histologically there was an absence of columns in the proliferation and hypertrophic zones. The matrix had reduced metachromatic staining and collagen fibrils of wide diameter up to 2000A which tapered or anastomosed (Seegmiller et al. 1971). Rimoin (1975) considered that this mutant was unlike any form of human chondrodystrophy so far examined.

Biochemical analysis of cartilage from cho/cho mice was performed by Stephens and Seegmiller (1976). They found normal uptake of ^{35}S , glucosamine, glucose and glycosaminoglycan content. However it was found that glycosaminoglycan diffused more readily from mutant cartilage into water than did normal cartilage. It was suggested that the defect may be in the interaction between proteoglycan and collagen.

A further chondrodystrophy in mice, cartilage anomaly (can/can) was reported by Johnson and Wise (1971). Affected mice died at about 10 days of age, they were small at birth and gained weight slowly. They had shortened domed skulls and short limbs, and the defect could be detected in 17 day

embryos. Histologically, the chondrocytes were more closely packed than normal but the proliferating and hypertrophic zones were reduced. The matrix was poorly staining. Ultrastructurally, differences were noted in the nucleus and in glycogen deposits, and well-formed collagen fibres were embedded in a reduced interfibrillar matrix. Rimoin (1975) considered that this may represent a model for human achondrogenesis.

A further mutant, stumpy (*stm/stm*) was described by Johnson (1977). Histologically there was a wide zone of hypertrophy, a slightly higher mitotic rate, and close approximation of chondrocytes.

The achondroplastic mutant (*cn/cn*) in the mouse was studied by Silberberg et al. (1976) and Bonucci et al. (1976, 1977). Ultrastructurally there was little difference in the chondrocytes from those of their normal litter mates, except that there was an increase in glycogen deposited. Histologically there was a rapid reduction of the height of the cell columns with age, and early loss of interterritorial staining with Alcian blue, although there was normal distribution of proteoglycans.

Cat

A case of dwarfism in a Siamese cat was described by Cowell et al. 1976. This cat, the result of a mother-son mating, showed dwarfism, facial abnormalities, severe skeletal deformities, multifocal neurologic deficits and retinal atrophy. Metachromatic inclusion bodies were demonstrated in circulating leucocytes and cetylpyridium chloride

precipitated mucopolysaccharide was 17 times that of a normal Siamese cat. Further examination of this case (Jezyk et al. 1977) showed that the increased level of glycosaminoglycan in the urine consisted almost entirely of dermatan sulphate. Polymorphonuclear leucocytes were found to contain many membrane-bound lamellar inclusion bodies, and the activity of arylsulfatase B was 10% that of normal cells. The authors suggested therefore that this case represented a model of Maroteaux-Lamy syndrome in humans.

A condition which resembled mucopolipidosis in man has been recorded in cats (Hegreberg et al. 1974). The cats at an early age exhibited retarded growth, a depressed nasal bridge with forehead prominence, and muscle weakness. A number of tissue enzymes were elevated while serum enzymes were depressed.

XI. COLLAGEN DYSPLASIAS

Collagen is the main structural protein occurring in all connective tissues. In cartilage, collagen forms a fibrillar network to supply rigidity and optimal resiliency to the protein polysaccharide component (Bornstein, 1974). A recent review (Kivirikko and Risteli, 1976) details the structure and biosynthesis of collagen. Despite the importance of collagen in cartilage, there has to date been no definite report of a defective collagen occurring in any of the chondrodystrophies. Collagen dysplasias have been reported in the Ehlers-Danlos syndrome, of which seven types are recognised and patients with Type VII are described as

being of short stature, along with the characteristic fragile skin and hyperextensible joints (Pope et al. 1975; Kivirikko and Risteli, 1976). Conditions resembling Ehlers-Danlos syndrome have been described in dogs (Gething, 1972; Hegreberg, 1975) and a cat (Scott, 1974).

Dermatosparaxis, a recessive hereditary disorder of cattle, was due to a deficiency of procollagen peptidase, and resulted in the formation of structurally and functionally defective collagen fibres (Bornstein, 1974). O'Hara et al. (1970) reported a collagenous tissue dysplasia of calves, in which the electron microscopic appearance of the collagen fibres was abnormal.

A defect in collagen metabolism is possible in two chondrodystrophies. Rimoin (1975), in discussing the Kniest syndrome (which is characterised by disproportionate dwarfism and kyphoscoliosis) described the ultrastructural appearance of cartilage. In patients with this syndrome, chondrocytes were filled with dilated cisternae of endoplasmic reticulum, suggesting that there may be a defect in collagen synthesis or secretion.

Cooper et al. (1973b) described a case of metaphyseal dysostosis in which iliac crest cartilage was examined ultrastructurally. The chondrocytes were distended by cisternae of the rough endoplasmic reticulum. The accumulated product appeared to be precipitated protein, the specific nature of which was not determined, but it was suggested it might represent a normal collagen precursor, or alternatively a non-collagenous protein, or an abnormal protein.

Another form of metaphyseal chondrodysplasia, known as cartilage - hair hypoplasia, showed very fibrillar resting cartilage and Rimoin (1975) suggested that this condition may also involve an abnormality in cartilage collagen.

CHAPTER IIGENETICS

INTRODUCTION

While early reports in the literature indicated that brachycephalic dwarfism in Hereford cattle was inherited as an autosomal recessive condition, later reports confused the issue. Although only small numbers of cattle were available for this present study, they were mated in an attempt to establish the mode of inheritance of brachycephalic dwarfism in New Zealand. In a disease such as achondroplasia in humans which is inherited as an autosomal dominant, matings between two affected individuals result in homozygous offspring much more severely affected than heterozygous individuals. Therefore it was decided to mate dwarf cows with dwarf bulls and observe the offspring at varying stages of development.

MATERIALS AND METHODS

In 1975 a bull (C5) alleged to have sired dwarf calves was mated with seven cows; two of these cows were reported by their owners as having had dwarf calves on the home property, the other five came into the project with young calves at foot which were later confirmed as typical brachycephalic dwarfs.

In 1976 a second bull (C11) was used as doubts were held as to the dwarfism status of the first bull. The second bull was reported to have sired two dwarf calves by

two cows, which were acquired with him. He was mated with six of the cows used in 1975, and with another six cows acquired after that date and alleged to have had dwarf calves. Of these, one also gave birth to a dwarf calf soon after its arrival in 1975.

Four dwarf cows were each mated with one or other of three young dwarf bulls with which they were run. These four cows were autopsied at different stages of pregnancy and the foetuses examined.

RESULTS

The results of various matings are summarised in Table 2.I.

Of the seven cows mated with C5, one cow died early in pregnancy, two cows were empty, and four cows produced calves which were phenotypically normal.

Of the 13 cows mated with C11, one cow was empty, one cow aborted in August and post mortem examination of the foetus showed it to be a dwarf. Of the 11 remaining cows, eight produced live calves which appeared phenotypically normal, one produced a dead calf which was phenotypically normal, one produced a live calf phenotypically a dwarf, and one produced a dead calf which was shown on post mortem to be a dwarf. Examination of the foetuses removed from the four dwarf cows showed them all to be dwarfs, of similar phenotype to those born from the matings of phenotypically normal but dwarf producing animals. (Chapter III)

TABLE 2.I

Results of matings within the experimental herd

Season	Progeny	Sex	Date of Birth	Sire	Dam	Phenotype
1975	P5	M	9. 8.75	C5	C7	Normal
	P6	F	23. 8.75	C5	C8	"
	P7	M	2.10.75	C11	C9	"
	P8	M	3.10.75	C5	C4	"
	P9	F	6.10.75	C5	C2	"
1976	P10	M	26. 8.76	C11	C4	Normal
	P11	F	30. 8.76	C11	C7	"
	P12	M	1. 9.76	C11	C8	"
	P13	M	9.76	C11	C1	"
	P14	-	9.76	C11	C13	"
	P15	F	7. 9.76	C11	C2	"
	P16	F	14. 9.76	C11	C9	"
	P17	M	8.10.76	C11	C12	Dwarf
	P18	-	.11.76	C11	C10	Normal (born dead)
	P19	F	28.11.76	C11	C15	Dwarf (born dead)
	Cf14	-	2. 7.76	C11	C14	Dwarf (aborted)
	Df8	F	-	YD*	D8	Dwarf
	Df24	M	-	"	D24	"
Df10	F	-	"	D10	"	
Df23	-	-	"	D23	"	

*Young Dwarf Bulls

DISCUSSION

Of the 13 cows that became pregnant to C11, three produced dwarfs, and these included calves of both sexes. The four dwarf foetuses from the dwarf x dwarf matings were phenotypically similar to those of the presumed heterozygous matings. These results are in accord with those expected on theoretical grounds if the disease was inherited as an autosomal recessive. Although the number mated is small the findings clearly help confirm the early reports on inheritance (Chapter 1, P.5). Although there was doubt concerning the status of bull C5, inclusion of these four normal calves sired by him does not effect the overall conclusion reached above.

It seems likely that much of the confusion in the literature concerning the mode of inheritance of bovine dwarfism arose through attempts to clarify the situation, in which cattle of different breeds and/or slightly different phenotypes were inter-mated. The resulting progeny were then classified if possible, and several theories of inheritance put forward. Because of the probability of different genes causing different basic defects, which may however affect the animal in a similar manner phenotypically, an estimate of genotype may not always be made with certainty from the phenotype of the animal.

It is not necessary to postulate one gene with 'modifiers' to account for the slightly different types of dwarfism seen in cattle. A parallel can be drawn with the human situation in which previously many dwarfs were classified

as achondroplasts, whereas today over one hundred different causes of dwarfism are recognised.

CHAPTER IIIMORPHOLOGY OF THE HEREFORD BRACHYCEPHALIC DWARF
IN NEW ZEALAND

INTRODUCTION

The gross morphology of dwarf Hereford cattle was studied in order to see whether all individuals conformed to the one phenotype, which would then indicate the probability of a single mutant being responsible for the disease in this country. Results were compared with published reports from North America in the belief that the dwarf genotype was introduced from there, and therefore dwarfs in New Zealand should conform to the same pattern.

MATERIALS AND METHODS

Animals

A total of 45 dwarfed animals of various ages was examined. Of these, 32 were from commercial herds and were donated by farmers concerned about the problem of dwarfism in the Hereford breed; three were born on the University property from prospective matings of carrier cows and bull; five were dwarf foetuses of varying lengths of gestation, and were obtained from a carrier x carrier mating and four dwarf x dwarf matings. A further two Angus calves, two Hereford calves and one Jersey/Hereford calf were examined, in lesser detail, on home properties. For comparative purposes, five phenotypically normal cattle aged between

1 and 2.5 years were autopsied. Body measurements of 13 normal Hereford cattle aged from 1 to 3 years and from two properties were taken, and head measurements and metacarpal bones were also obtained from a line of 32 Hereford cows and one Hereford bull at an abattoir. A small number of other normal cattle provided some body or metacarpal measurements. Three carrier cows were autopsied. Nineteen progeny from the carrier herd were examined alive, including two dwarfs, and these dwarfs plus three phenotypically normal progeny were autopsied.

Measurements of live animals

The general appearance of each animal was noted and various anatomical measurements made according to a standard procedure as follows:

- (i) body weight
- (ii) crown-rump length - from the poll to the second coccygeal vertebra
- (iii) height at withers
- (iv) girth - chest circumference immediately distal to the shoulders
- (v) width of hips - between the wings of the ilium
- (vi) length of head - from the poll to the hairline of the muzzle
- (vii) wide of head - between the zygomatic arches

Measurements of bones

Total length (TL), diaphyseal diameter (DD), and where possible diaphyseal length (DL), were recorded using the method described by Tyler et al. (1957), as shown in Fig.3.0. Similar measurements were taken from radiographs. Ratio values of these measurements were calculated for all metacarpal bones.

Morphology of the skull

After skinning, the majority of heads were sectioned longitudinally with a bandsaw, and examined following removal of the brain. Three dwarf skulls were opened by removing the sections of bone overlying the brain so as to allow its removal in entirety, and each of these brains was then sectioned transversely to assess whether or not hydrocephalus was present. All skulls were examined to assess the degree of closure of the sphenoid-occipital synchondrosis, for the presence or absence of projections from the wing of the orbito-sphenoid and/or the posterior intra-occipital synchondrosis, and for the presence of spicules within the cranium.

The following measurements were recorded:

- (i) length of base of skull - from the most anterior part of sphenoid bone to the occipital condyles
- (ii) cranium height - from the ventral sphenoid bone to the poll
- (iii) dorso-ventral distance between the occipital condyles.

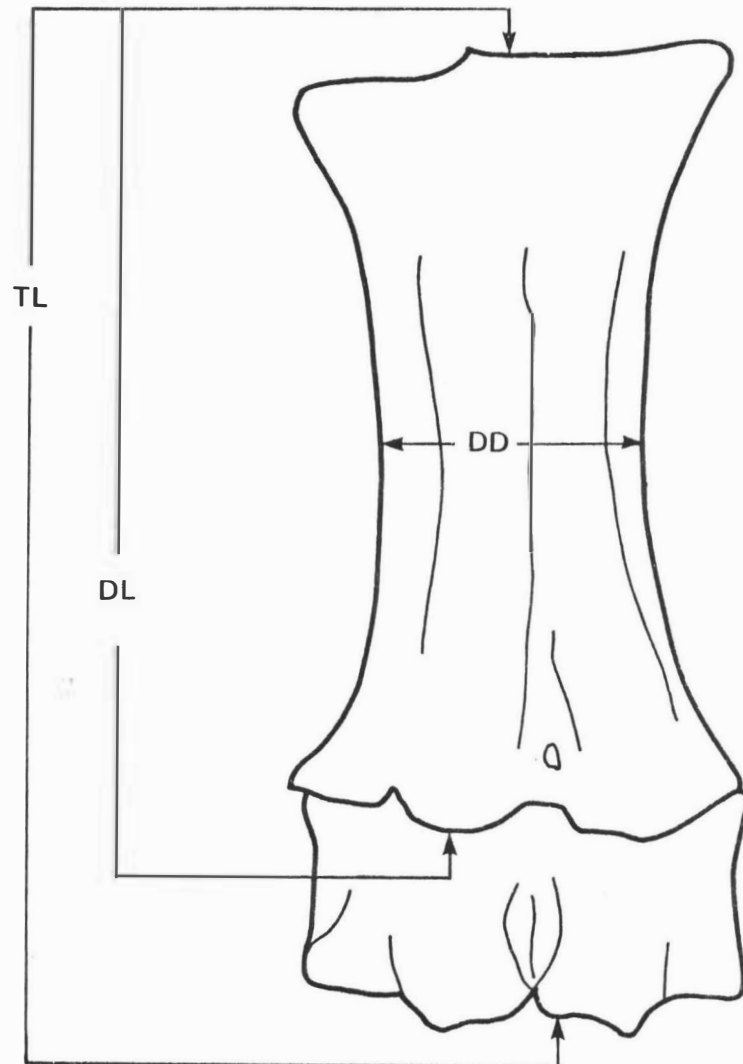


FIGURE 3.0 DIAGRAM OF A DWARF METACARPUS SHOWING THE MEASUREMENTS OF TOTAL LENGTH (TL), DIAPHYSEAL LENGTH (DL) AND DIAPHYSEAL DIAMETER (DD)

Profilometer studies

A profilometer was constructed as described by Gregory and Brown (1951) and used to trace head profiles of 22 bulls on a property experiencing a problem with dwarfism. Of these bulls, five were young stock less than 2 years of age, the progeny of the same sire, and four older bulls similarly had a common sire. At least two profiles of each beast were made and genotype was diagnosed according to criteria of Gregory et al. (1953).

Radiography

The lumbar vertebral column from each animal autopsied was dissected out, and lateral and dorso-ventral radiographs taken.

Radiographs were taken of the lumbar region and the lower foreleg of all progeny from the carrier herd, between the age of 2 and 10 days. From these, attempts were made to classify the progeny into dwarf, normal and carrier animals. Lumbar vertebrae were subjectively classified from 1 to 5, indicating a range from normal to abnormal. Metacarpal ratios were calculated from the foreleg radiographs.

The feasibility of examining the state of closure of the spheno-occipital synchondrosis was examined by taking radiographs of skulls at various angles.

Foetal studies

Four mature female Hereford dwarfs were allowed to run with three 18 month old Hereford dwarf bulls for 2 months. No attempt was made to record mating times. These female dwarfs were then autopsied later in the year.

The following measurements were recorded from the foetuses:

- (i) crown-rump length
- (ii) coronary band of hoof to elbow
- (iii) coronary band of hoof to hock
- (iv) coronary band of hoof to stifle
- (v) depth of chest immediately distal to the shoulders
- (vi) head length
- (vii) head width

Radiographs were taken of the whole foetus. The age of the foetus was estimated both by measuring the crown-rump length (Evans and Sack, 1973) and by examining loci of ossification present on radiographs (Lindsay, 1969). The ages of normal beef breed foetuses obtained from an abattoir were estimated in the same way. Close age matches between groups were not always achieved. The method of measuring each bone was based on that for post-natal bones, even though the ratio values would not be expected to correspond exactly in the early foetuses where the bone shape was still being formed.

RESULTS

Measurements of live animals

Animals were classified as normal or dwarf on the basis of general appearance and anatomical measurements (Tables 3.I, 3.VI, 3.VII, 3.VIII). The appearance of a typical dwarf is shown in Fig.3.1. The Hereford dwarf in New Zealand appeared very similar to the Hereford brachycephalic




Figure 3.1 An eighteen month old dwarf steer showing the typical short head, dished face, bulging forehead, pot belly, and short legs. (Height of top railing from ground 95.5 cm)

TABLE 3.1

Measurements of live dwarf and normal animals

Age	Weight (Kg)		Length (cm)		Height (cm)		Girth (cm)	
	D.	N.	D.	N.	D.	N.	D.	N.
Newborn	26 (2)*	31 (13)	73 (2)	80 (16)	57 (2)	69 (17)	71 (2)	80 (15)
<10mths	110 (5)	121 (3)	98 (8)	130 (3)	75 (8)	90 (3)	105 (6)	120 (3)
12-16mths	148 (9)	229 (7)	126 (8)	152 (6)	80 (8)	107 (7)	127 (8)	146 (7)
18-24mths	222 (5)	326 (3)	142 (5)	174 (2)	90 (5)	115 (3)	144 (6)	174 (3)
>2 years	304 (7)	459 (9)	144 (8)	205 (9)	97 (9)	131 (9)	155 (7)	197 (9)

Age	Head Length (cm)		Head Width (cm)		HL/HW		Hips (cm)	
	D.	N.	D.	N.	D.	N.	D.	N.
Newborn	19 (2)	22 (17)	12 (2)	12 (17)	1.67	1.84	16 (2)	17 (17)
<10mths	17 (9)	32 (3)	16 (9)	17 (3)	1.68	1.88	21 (5)	28 (3)
12-16mths	31 (8)	38 (7)	18 (8)	19 (7)	1.68	1.95	23 (6)	35 (7)
18-24mths	34 (7)	42 (3)	20 (7)	21 (3)	1.66	2.00	33 (5)	42 (3)
>2 years	36 (10)	48 (9)	23 (10)	23 (9)	1.57	2.06	36 (10)	48 (9)

Key: *Number of animals recorded is bracketed; D. Dwarf N. Normal; HL/HW Head length to head width ratio.

dwarf described and photographed from the United States. Measurements from live animals are tabulated in Table 3.I.

Dwarf values expressed as a percentage of normal for each age group were calculated from the above data, and are recorded in Table 3.II.

TABLE 3,II

Measurements of dwarf animals expressed as a percentage of normal

Age	Weight	Length	Height	Girth	Head Length	Head Width	HL/ HW	Hips
Newborn	84	91	83	89	86	100	91	94
< 10 mths	91	75	83	88	84	94	89	75
12-16 mths	65	82	75	87	82	95	86	66
18-24 mths	68	81	76	83	81	95	83	79
> 24 mths	66	70	74	79	75	100	76	76

From inspection it can be seen that with the exception of head width, the relative differences in measurements between dwarf and normal became greater with age.

This trend is also shown in Table 3.III in which the same measurements in dwarf and normal animals at birth are stated as a percentage of those recorded in animals over two years of age.

TABLE 3.III

Measurements of newborn animals expressed as a percentage of animals over two years of age.

	Weight	Length	Height	Girth	HL	HW	Hips
Dwarf	8.5	50.6	58.7	45.8	52.7	52.1	44.4
Normal	6.7	39.0	52.6	40.6	45.8	52.1	35.4

Measurements of live animals taken from carrier cows showed that these animals on average tended to be slightly smaller than normal animals of the same age (Table 3.I). However, the difference was insufficient to allow positive identification of carrier animals (Tables 3.IV, 3.V).

TABLE 3.IV

Measurements of live carrier animals over 2 years of age

	Length (cm)	Height (cm)	Girth (cm)	HL (cm)	HW (cm)	HW/HL
Carrier > 2 yrs	176 (4)	115 (11)	170 (9)	43 (14)	22.5	1.9

TABLE 3.V

Measurements of carrier animals expressed as a percentage of normal

	Length	Height	Girth	HL	HW	HL/HW
> 2 yrs	85.9	87.9	86.3	89.9	97.8	92.2

A comparison of the head length/head width ratio value between dwarf and normal animals suggested that this may be of value in distinguishing phenotypes. The distribution for dwarf, carrier and normal populations is shown in Fig.3.2 and whereas two populations are seen corresponding to dwarf and normal ratio values, there is an overlap between the two. The ratio values for obligate heterozygotes (Table 3.IV) fall between those of dwarf and normal but this parameter cannot be used to accurately distinguish carrier from normal animals.

Measurements of bones

Post mortem measurements taken from the femur, tibia, metatarsal, humerus, radius and metacarpal bones, are shown in Table 3.VI. From inspection it can be seen that the difference between measurements of dwarf and normal animals tended to become more pronounced with age, although this was not shown in all bones, particularly the humerus and metacarpus. Numbers of animals within some groups were too small to record a definite pattern. Distal bones were more severely affected by the dwarfing process than proximal bones. Within age groups the diaphyseal length was slightly more dwarfed than the total length, in the metacarpal and metatarsal bones.

The measurements in Table 3.VI indicate that in dwarfed animals there was a reduction in both length and width of the radius, humerus and tibia, but the reduction in length was relatively greater. In the femur and metatarsus there was a reduction in length but little if any change from normal in width, and the metacarpal measurements show that at several stages this bone maybe actually wider than the normal bones at a similar age.

Key to Figures 3.2, 3.3, 3.4, and 3.5

- Dwarf
- ⊙ Carrier
- Normal

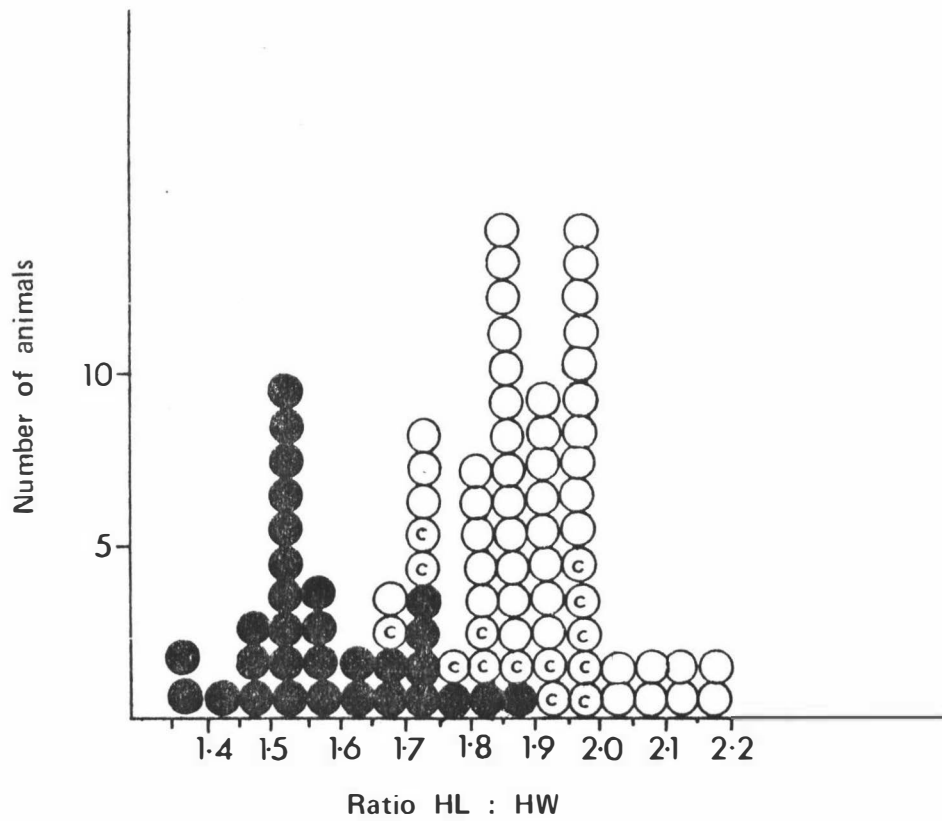


FIGURE 3.2 HEAD LENGTH TO HEAD WIDTH RATIO VALUES FOR 30 DWARF, 14 CARRIER, AND 48 NORMAL ANIMALS

TABLE 3.VI

Length and width measurements of femur, tibia, metatarsus, humerus,
radius and metacarpus from dwarf and normal animals

	Total length (cm)			Diaphyseal length (cm)			Diaphyseal diameter (cm)		
	D.	N.	D./N.%	D.	N.	D./N.%	D.	N.	D./N.%
<u>Femur</u>									
Newborn	15.5 (1)	-					2.3	-	
<10 mths	22.6 (5)	25.5 (2)	88.6				2.9	2.7	107.4
12-16 mths	25.1 (2)	30.3 (3)	82.8				3.5	3.5	100.0
18-24 mths	25.7 (1)	31.9 (1)	80.6				3.6	4.1	87.8
>2 years	28.4 (8)	35.1 (2)	80.9				4.1	4.0	97.6
<u>Tibia</u>									
Newborn	13.5 (1)	16.1 (1)	83.8				2.5	2.7	92.6
<10 mths	19.5 (1)	-					4.0	-	
12-16 mths	21.3 (2)	27.6 (3)	77.2				3.8	4.3	88.4
18-24 mths	21.8 (3)	28.2 (1)	77.3				4.3	4.7	91.5
>2 years	26.4 (9)	33.4 (2)	79.0				4.7	4.9	95.9
<u>Metatarsal</u>									
Newborn	11.0 (1)	14.4 (2)	76.4	8.1	-		2.1	2.0	105
<10 mths	13.9 (2)	-		11.7	-		2.6	-	
12-16 mths	14.2 (1)	20.3 (2)	70	11.7	17.1	68.4	2.7	2.9	93
18-24 mths	14.7 (3)	21 (1)	70	12.2	18	67.8	3.0	3.0	100
>2 years	15.4 (8)	22.3 (4)	69	12.9	19.4	66.5	3.2	3.2	100

TABLE 3.VI (contd.)

	Total length (cm)			Diaphyseal length (cm)			Diaphyseal diameter (cm)			
	D.	N.	D./N.%	D.	N.	D./N.%	D.	N.	D./N.%	
<u>Humerus</u>										
Newborn	12.8	(1)	-				2.2	-		
< 10 mths	17.3	(5)	-				2.9	-		
12-16 mths	18.6	(2)	21.8 (2)	85.4			3.0	3.4	88.2	
18-24 mths	19.3	(3)	23.2 (1)	83.2			3.7	4.1	90.2	
> 2 years	21.1	(8)	25.5 (1)	82.7			4.0	4.2	95.2	
<u>Radius</u>										
Newborn	11.7	(1)	14.1 (1)	82.9			2.4	2.5	96	
< 10 mths	16.0	(2)	-				3.4	-		
12-16 mths	17.5	(2)	22.9 (2)	76.4			3.5	3.9	89.7	
18-24 mths	18.5	(4)	24.8 (1)	74.5			3.9	5.0	77.2	
> 2 years	20.1	(11)	28.0 (1)	71.8			4.3	4.8	88.7	
<u>Metacarpus</u>										
Newborn	10.0	(3)	13.7 (14)	72.9	7.8	11.4	68.4	2.7	2.4	112.5
< 10 mths	11.8	(7)	16.3 (7)	72.4	9.5	13.7	69.3	3.0	2.7	111.1
12-16 mths	12.6	(5)	18.4 (5)	68.5	10.0	15.6	64.1	3.3	3.5	94.3
18-24 mths	13.0	(6)	19.2 (3)	67.7	10.5	16.3	64.4	3.9	3.6	108.3
> 2 years	13.8	(10)	19.0 (35)	72.6	11.1	17.0	65.3	3.9	3.9	100

Metacarpal ratio values of total length to diaphyseal length (TL/DL), total length to diaphyseal diameter (TL/DD), and diaphyseal length to diaphyseal diameter (DL/DD) (Fig.3.0) are shown in Table 3.VII.

TABLE 3.VII

Metacarpal ratio values for dwarf and normal cattle

Age	TL/DD		TL/DL		DL/DD			
	D.	N.	D.	N.	D.	N.		
Newborn	3.7	(3)	5.7	(14)	1.28	1.20	2.88	4.75
<10 mths	3.93	(7)	6.03	(7)	1.24	1.18	3.16	5.07
12-16 mths	3.82	(5)	5.25	(5)	1.26	1.17	3.03	4.45
18-24 mths	3.33	(6)	5.33	(3)	1.23	1.17	2.69	4.52
>2 years	3.53	(10)	4.87	(35)	1.24	1.11	2.84	4.35

The distribution of the ratio values in the dwarf and normal populations concurred with that published by Tyler et al. (1961) as reviewed in Chapter I, page 11.

These ratio values for dwarf and normal animals are also shown in Figs. 3.3, 3.4 and 3.5.

Morphology of the skull

A mild degree of hydrocephalus was noted in the three brains from dwarf animals examined.

A comparison of the state of closure of the sphenoccipital-synchondrosis between dwarf and normal cattle within age groups is shown in Table 3.VIII.

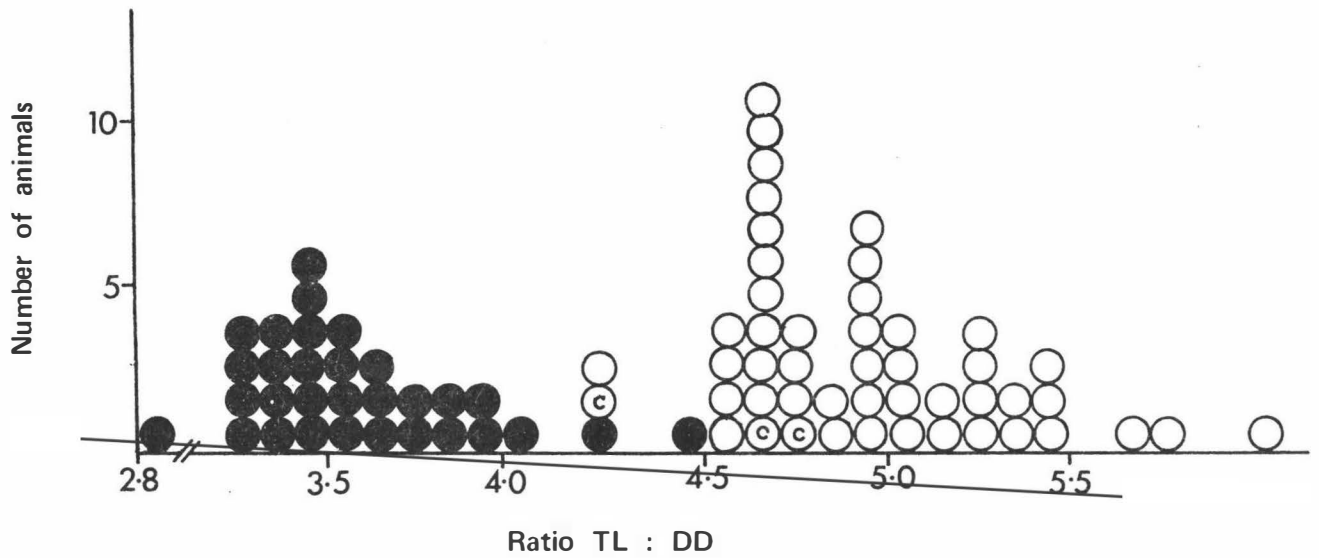


FIGURE 3.3 METACARPAL RATIO VALUE TOTAL LENGTH TO DIAPHYSEAL DIAMETER IN 31 DWARF, 3 CARRIER, AND 44 NORMAL ANIMALS

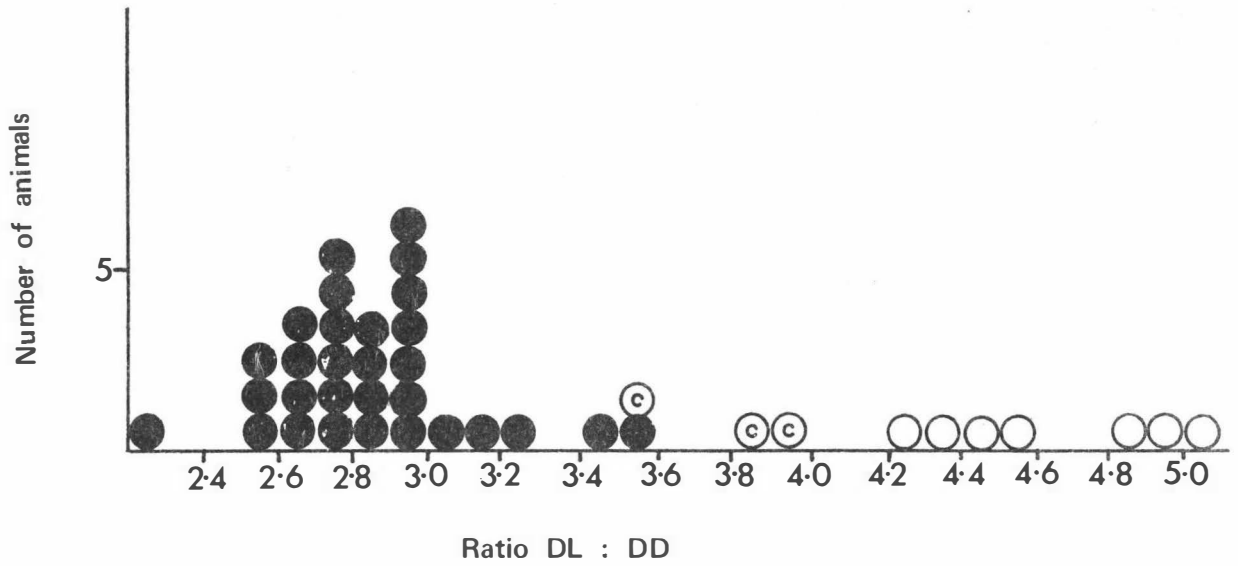


FIGURE 3.4 METACARPAL RATIO VALUE DIAPHYSEAL LENGTH TO DIAPHYSEAL DIAMETER IN 30 DWARF, 3 CARRIER, AND 7 NORMAL ANIMALS

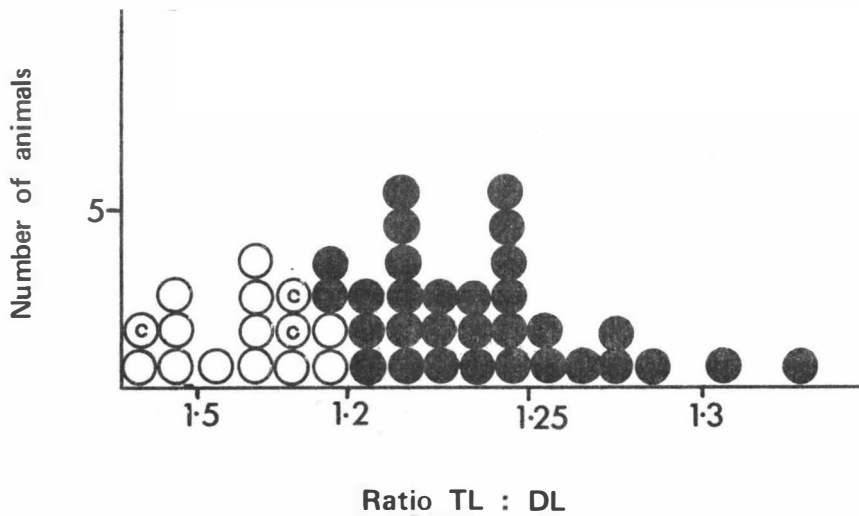


FIGURE 3.5 METACARPAL RATIO VALUE TOTAL LENGTH TO DIAPHYSEAL LENGTH IN 31 DWARF, 3 CARRIER, AND 12 NORMAL ANIMALS

TABLE 3.VIII

Numbers of animals at various ages showing the state of closure of the spheno-occipital synchondrosis

Age	Normal		Dwarf		Uncertain	
	Closed	Open	Closed	Open	Closed	Open
Foetus	-	6	-	5	-	-
Newborn	-	4	-	1	-	-
<10 mths	-	4	4	-	-	3
12-16 mths		2	5, (1 closing)	1	-	-
18-24 mths	-	2	4	-	-	-
>2 years	4	1	10	-	-	-

Animals were classified as dwarf both on phenotypic appearance and on the basis of having metacarpal ratio values within the dwarf range. Included in an uncertain grouping was one Hereford calf of dwarfed appearance which had only one metacarpal ratio value within the dwarf range; one small Angus calf, in which the metacarpal ratio values were all within the normal range; and one other Angus calf with one ratio value in the dwarf range.

This study included two Hereford animals aged 12 months, both of which were of typical brachycephalic dwarf appearance, with all metacarpal ratio values within the dwarf range. In one of these animals the spheno-occipital synchondrosis was completely open, while the other was in the process of closing. In the published literature (Julian et al. 1957) all typical brachycephalic dwarf cattle over the age of 5.5 months had a closed spheno-occipital synchondrosis.

Of the dwarfed skulls examined 82% had projections from the posterior intra-occipital synchondrosis, whereas similar projections were not seen in any of the normal skulls examined. Both dwarfed Angus skulls had very large cartilaginous projections from this synchondrosis. Projections from the wing of the orbito-sphenoid occurred in 61% of dwarf skulls compared with 14% of normals; spicules in various parts of the cranium were present in 75% of dwarf skulls compared with 33% of normals.

Measurements of dwarf and normal skulls are shown in Table 3.IX. It should be noted that whereas measurement of the length of the base of the skull of normal animals was through a horizontal plane, that of the dwarf skulls was over a concave face (Fig.3.6).

The base of the skull was shorter in the foetus and the newborn dwarf in comparison with normal animals, even though the spheno-occipital synchondrosis was still open. This indicates that the shortness of the base of the skull is not due to early closure of this synchondrosis.

Profilometer studies

Following the classification of Gregory et al. (1953) two bulls were found to have 'Roman noses' and were classified as Class I. This type is not able to be classified into heterozygote (dwarf) or normal. Of the others, two were placed in Class II and the remainder in Class III.

TABLE 3.IX

Comparison of various measurements of skull size between
dwarf and normal animals

	Base of Skull (cm)			Cranium Height (cm)			Occipital Condyles (cm)		
	D.	N.	$\frac{D}{N}\%$	D.	N.	$\frac{D}{N}\%$	D.	N.	$\frac{D}{N}\%$
Foetus	5.4 (4)	5.9 (6)	91.5	6.7	6.3	106.4	1.6	1.7	94.1
Newborn	6.5 (1)	7.3 (4)	89	8.0	7.9	101.3	2.0	2.4	83.3
<10 mths	7.9 (4)	9.1 (4)	86.8	11.2	10.6	105.7	2.1	2.8	75
12-16 mths	8.0 (7)	10.7 (2)	74.7	11.4	13.9	82	2.2	3.5	62.9
18-24 mths	8.4 (5)	11.5 (2)	73	13.6	14.5	93.8	2.1	3.4	61.8
>2 years	9.5 (10)	11.3 (5)	84.1	14.0	15.6	89.7	2.4	3.7	64.9

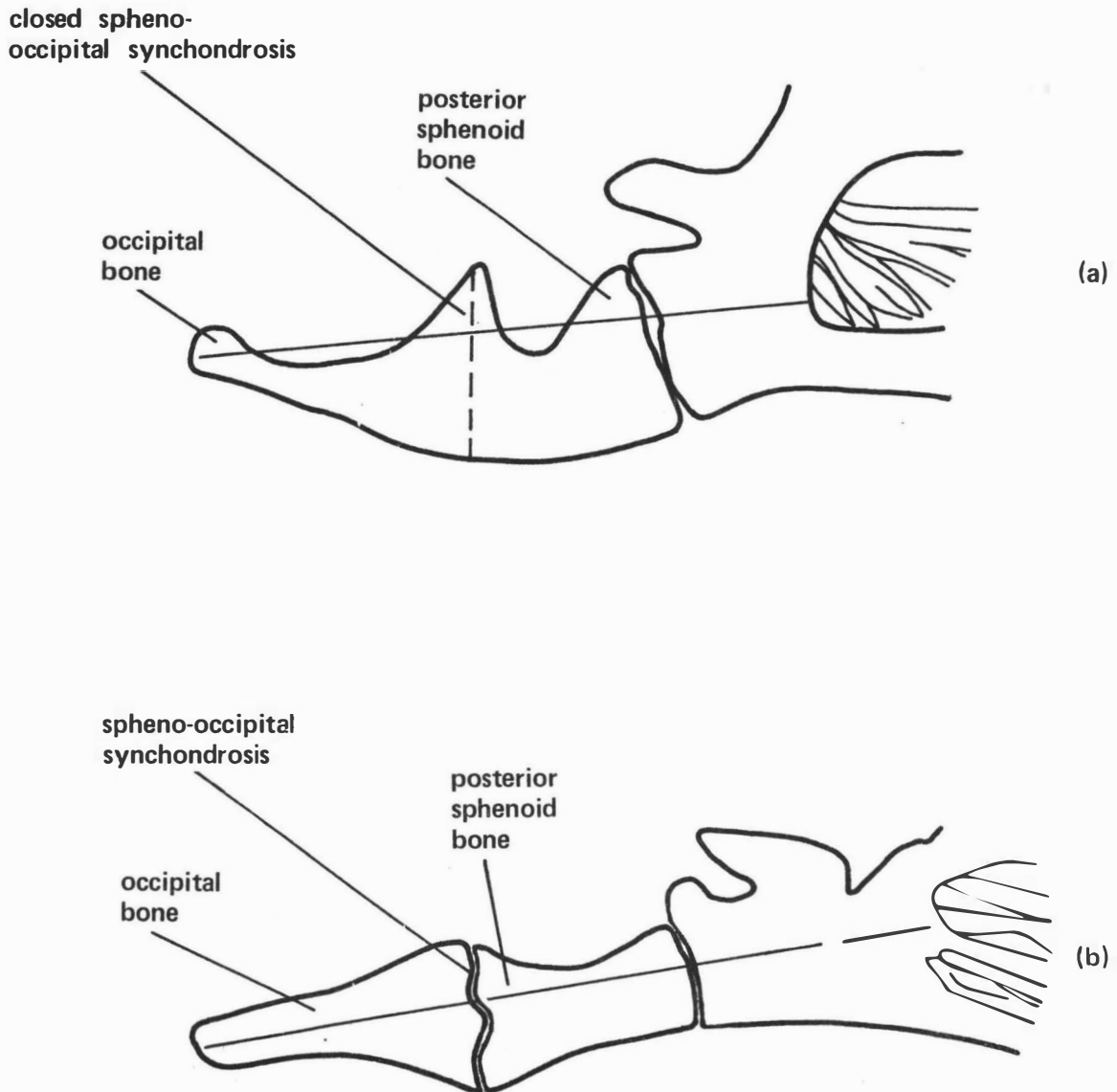


FIGURE 3.6 DIAGRAM OF A MIDLINE SAGITTAL SECTION OF THE BASE OF THE SKULL IN (a) DWARF AND (b) NORMAL ANIMALS COMPARING THE MEASUREMENT OF LENGTH

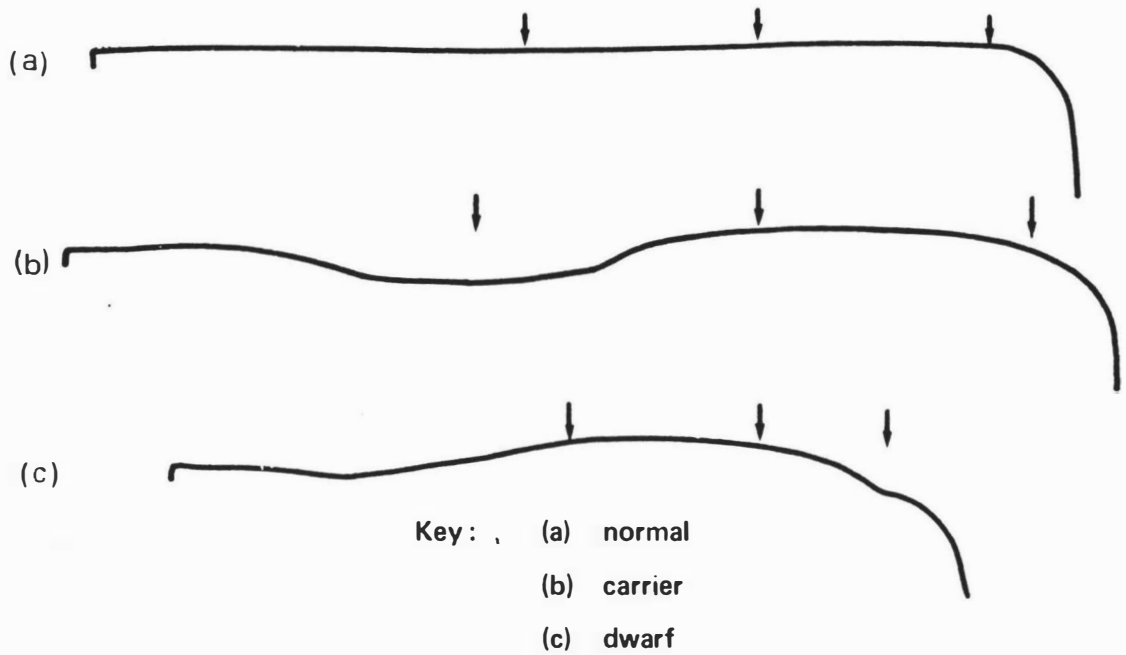
On the basis of classification into sub-groups within Class II and Class III, eight bulls had profiles suggestive of a heterozygote genotype. A recommendation was made to the owner that these bulls should not be used in the following mating season, and no dwarfs resulted from 700 breeding cows mated at this time. Profiles representative of dwarf, carrier and normal animals are shown in Fig.3.7.

Radiography

Lateral radiographs of the lumbar spine from dwarf animals showed the ventral profile of the vertebral body to be flattened with an undulating surface, whilst the dorsal profile of the body showed a concave dip, and the epiphyses frequently 'lipped' under the ventral surface (Fig.3.8). This was in contrast to lateral radiographs from a normal animal (Fig.3.9), in which there was a smooth upward curve of the ventral profile, the dorsal profile was almost flat, and the epiphyses did not lip under the ventral surface.

The dorso-ventral view of the dwarf lumbar spine showed a shortening of the transverse processes with a forward 'hooking' of the ends of the processes (Fig.3.10) when compared with the same view from a normal animal (Fig.3.11).

As the dwarf animals became older the lateral view of the lumbar vertebrae tended to have a more normal appearance, with undulations on the ventral surface being less pronounced, but there was still flattening of this surface and a concavity in the dorsal surface (Fig.3.12).



Arrows indicate the points of measurement for classification of profile type.

FIGURE 3.7 HEAD PROFILES TAKEN WITH A PROFILOMETER, SHOWING THE VARIATION BETWEEN NORMAL, CARRIER AND DWARF PROFILES

Figure 3.8 Lateral radiograph from a 6 month old dwarf calf, showing concavity in dorsal body profile, lipping of epiphyses, irregularity and flattening of ventral vertebral body profile.

Figure 3.9 Lateral radiograph of the lumbar spine from a normal adult cattle beast.

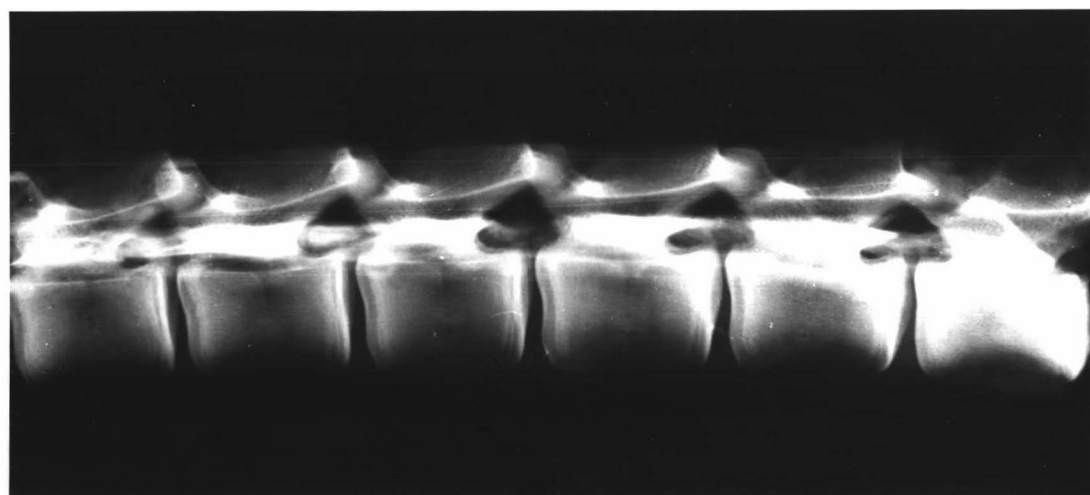
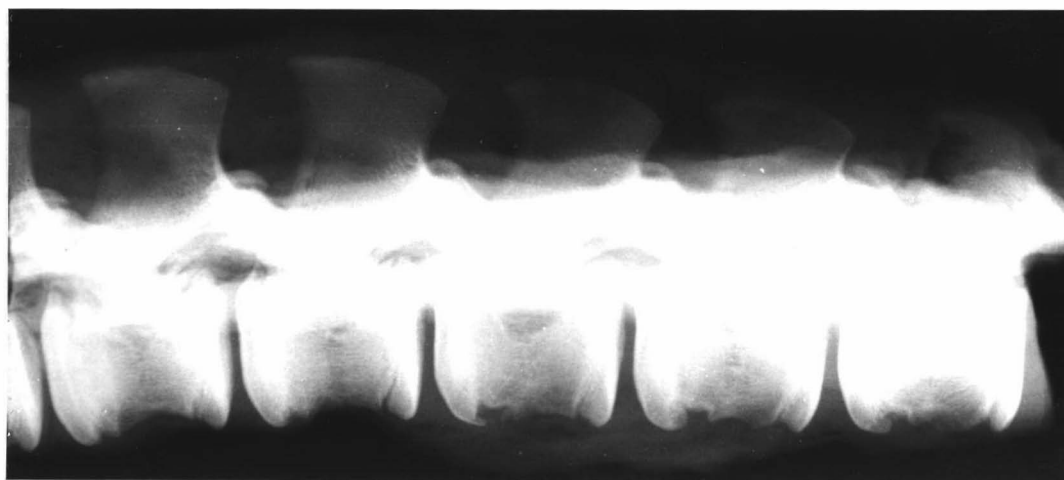
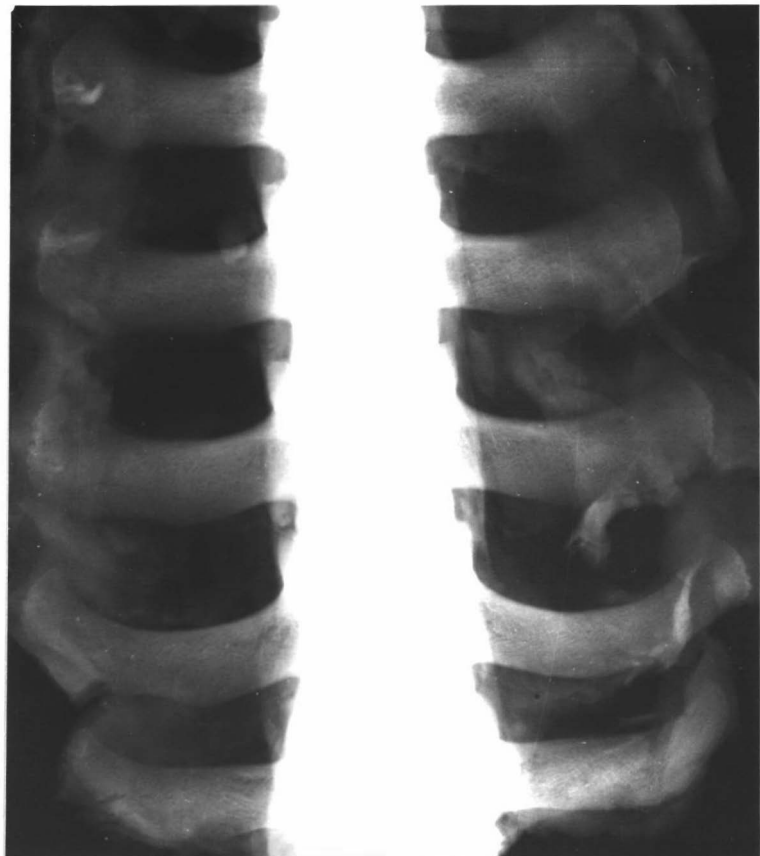
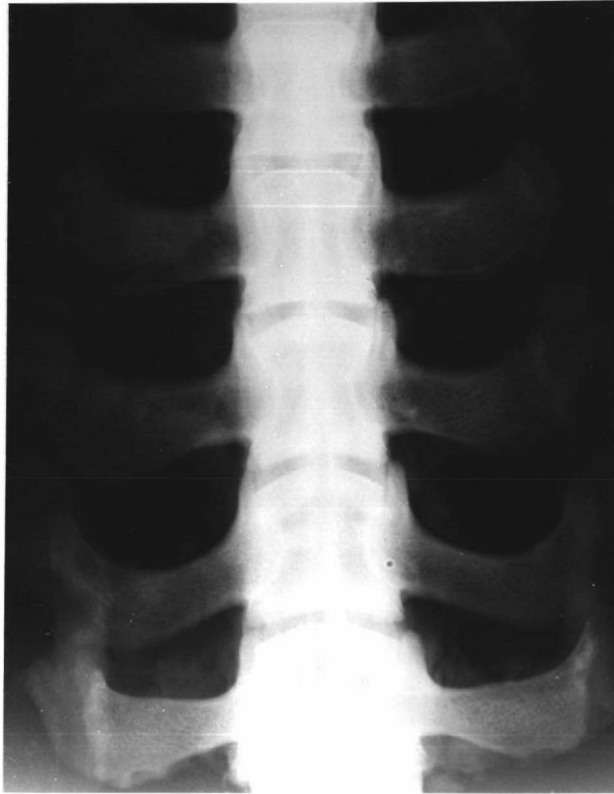
Figure 3.10 Dorso-ventral radiograph of lumbar spine from a dwarf cattle beast, showing shortening of the transverse processes and forward hooking of the ends of the processes.

Figure 3.11 Dorso-ventral radiograph of lumbar spine from a normal cattle beast.



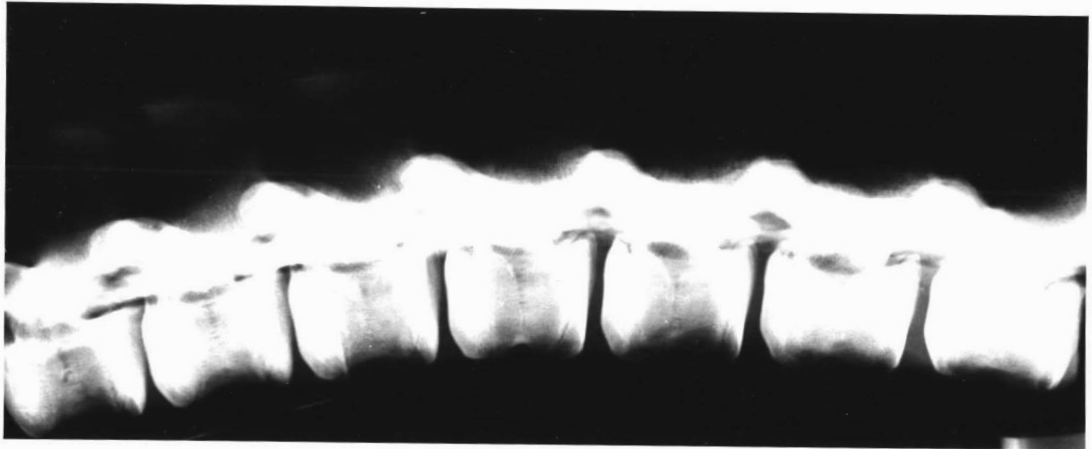


Figure 3.12 Lateral radiograph of the lumbar spine from an adult dwarf cow, showing the features seen in Figure 3.8, but with less pronounced irregularity of the ventral vertebral body surface.

Two calves from cows in the experimental herd were readily identified as dwarfs by radiography of the lumbar spine and the metacarpal bone. The lumbar vertebrae were classified in category 5, and all metacarpal indices were within the dwarf range. Of the radiographs of the remaining 17 calves, two were difficult to interpret, two were classified as representing category 2, and three as representing category 3. The metacarpal ratios from four of these latter five animals while within the normal range, were close to the dwarf values. The remaining animal, which had been classified in category 3, had metacarpal indices in the middle of the normal range. A comparison between the lumbar spines from a young dwarf, normal and possible carrier animal is shown in Fig.3.13.

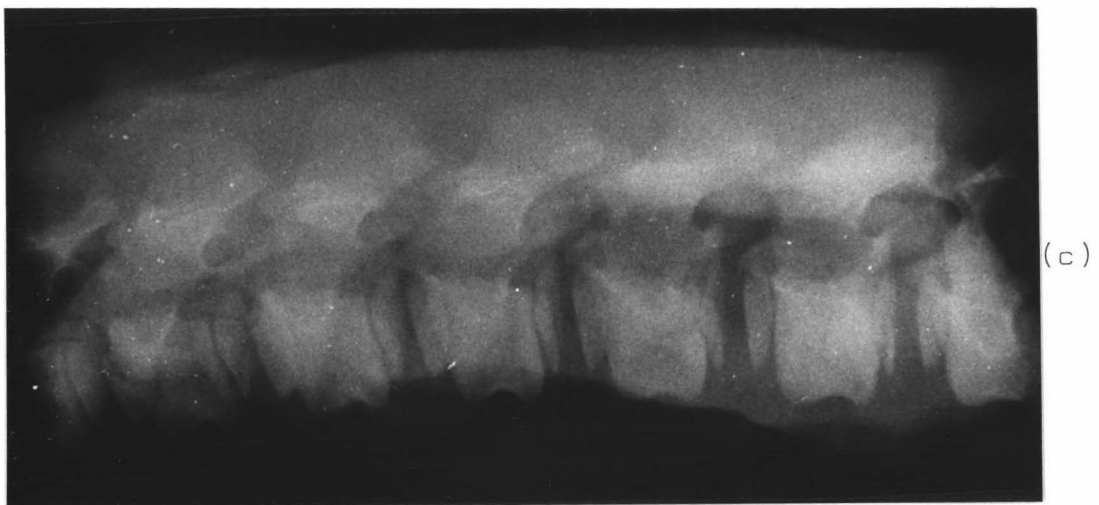
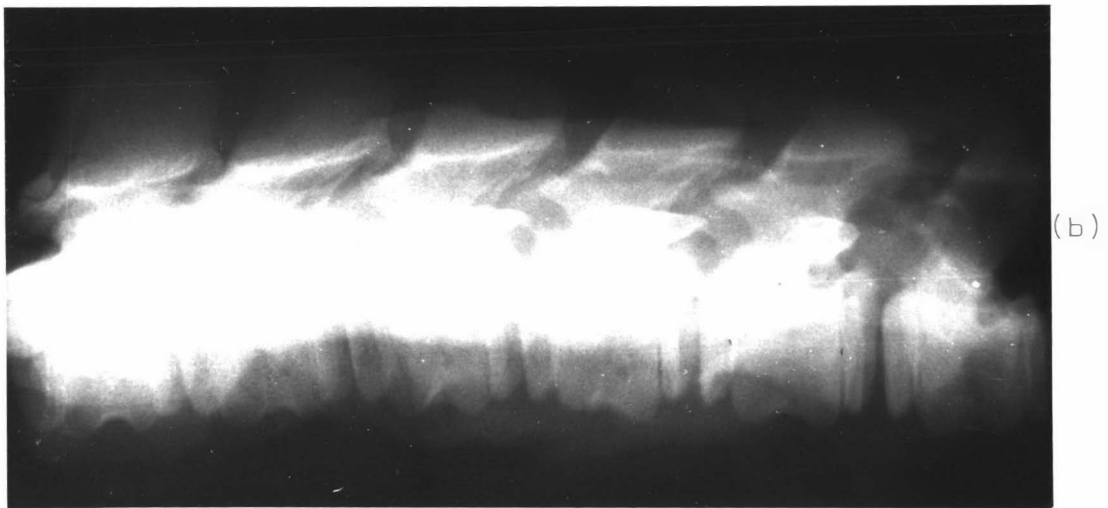
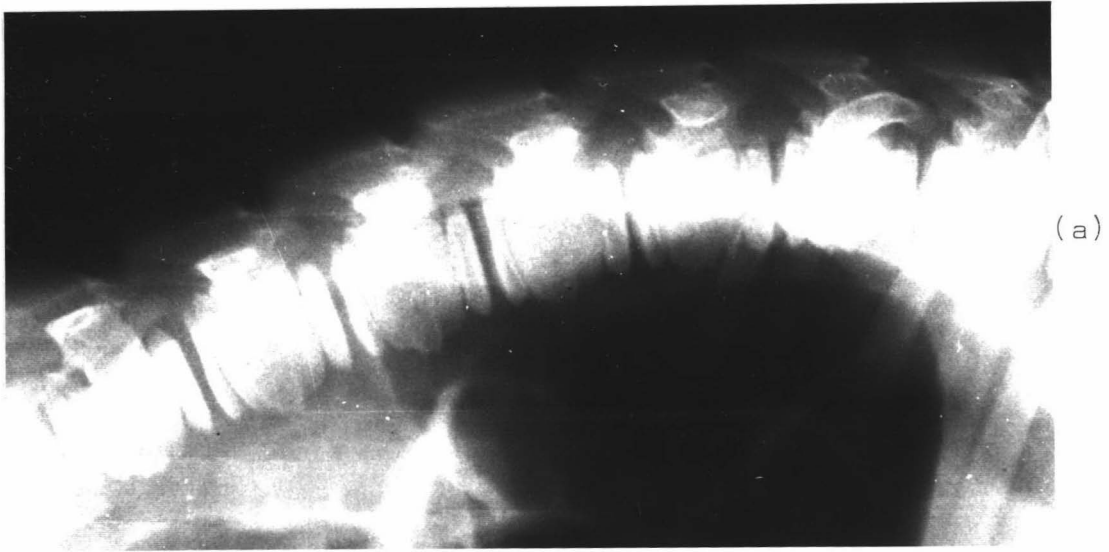
Radiographic examination of the spheno-occipital synchondrosis proved to be too difficult to be of any practical value. On a lateral radiograph the synchondrosis was covered by the mandibular condyle, which made interpretation difficult. In humans, tomography is used which enables an area of the skull at a particular depth to be examined in detail, but facilities for this process were not available.

Foetal studies

Ages of the foetuses examined were estimated as accurately as possible, but with the limited information available (Lindsay, 1969) it was difficult to determine exact ages between 116 and 163 days, and after 238 days. However it was found for all ages that the age calculated from the crown-rump length and that calculated from the loci of

Figure 3.13 Lateral radiographs of lumbar vertebrae from:

- (a) dwarf,
- (b) suspected carrier, and
- (c) normal animal



ossification present, corresponded fairly closely in normal foetuses. In the dwarf foetuses, crown-rump length gave an estimated age 10-15 days younger than that calculated from the loci of ossification present, so the latter was taken as a more accurate estimate. Various measurements taken from the foetuses are shown in Table 3.X. Both sexes were represented.

From inspection of this table it can be seen that the youngest dwarf foetus examined (125-130 days) showed evidence of dwarfing, particularly in the hoof to elbow measurement, and this pattern continued for older age groups. Width of the head was considerably greater than normal in the youngest dwarf foetus, and in all age groups this measurement caused a smaller head length/head width ratio in the dwarfs.

Of the two dwarf foetuses included in group (3), one was from a carrier x carrier mating, while the other was from a dwarf x dwarf mating. Although the dwarf from the carrier x carrier mating was a few days older (as determined by the loci of ossification present) it showed a slightly greater degree of dwarfing in the length measurements recorded than did the foetus from the dwarf x dwarf mating.

Measurements of the metacarpal bones of dwarf and normal foetuses are shown in Table 3.XI and percentages of dwarf to normal values are also included for group (3), where close age matches were possible.

TABLE 3.X

Various anatomical measurements taken from dwarf and normal foetuses
within specified age groups

Length of gestation based on loci of ossification present	Crown-rump (cm)		Hoof-Elbow (cm)		Hoof-Hock (cm)		Hoof-Stifle (cm)	
	D.	N.	D.	N.	D.	N.	D.	N.
(1) 115 days	-	23 (3)	-	7.7	-	5.5	-	9.5
(2) 125 - 130 days	25 (1)	-	7.5	-	6	-	10	-
(3) 190 - 200 days	54 (2)	60 (3)	18	25	16	20	24	32.5
(4) 210 - 220 days	-	72 (2)	-	33.5	-	25.5	-	42
(5) 240+ days	75 (1)	-	30	-	25	-	39.5	-

Length of gestation based on loci of ossification present	Depth Chest (cm)		Head Length (cm)		Head Width (cm)		HL/HW	
	D.	N.	D.	N.	D.	N.	D.	N.
(1) 115 days	-	7.5	-	6.8	-	4.7	-	1.5
(2) 125 - 130 days	7	-	6.8	-	5.5	-	1.2	-
(3) 190 - 200 days	16.5	19.5	13.3	15.1	8.3	8.6	1.6	1.8
(4) 210 - 220 days	-	22	-	17.5	-	9.6	-	1.8
(5) 240+ days	23	-	17.8	-	11.4	-	1.6	-

TABLE 3.XI

Measurements of metacarpal bones from dwarf and normal foetuses
within specified age groups

Length of gestation from loci of ossification present	Total length (cm)			Diaphyseal length (cm)			Diaphyseal diameter (cm)		
	D.	N.	%	D.	N.	%	D.	N.	%
(1) 115 days	-	2.5 (3)	-	-	1.9	-	-	0.5	-
(2) 125 - 130 days	2.2 (1)	-	-	1.6	-	-	0.6	-	-
(3) 190 - 200 days	6.0 (2)	8.8 (3)	68	4.4	7.0	63	1.8	1.5	120
(4) 210 - 220 days	-	11.0 (2)	-	-	9.6	-	-	1.9	-
(5) 240+ days	9.4 (1)	-	-	7.6	-	-	2.3	-	-

Inspection of Table 3.XI shows that a reduction in length of the metacarpus was present from an early age in the foetus, with the 125-130 day foetus having a much shorter metacarpus than normal foetuses 10 days younger. These figures also show that the dwarf metacarpus had a greater diameter than that of normal animals, a trend which was seen to continue in the postnatal animal.

Metacarpal ratio values are shown in Table 3.XII.

TABLE 3.XII

Metacarpal ratio values from dwarf and normal foetuses within specified age groups

Length of gestation from loci of ossification present	TL/DD		TL/DL		DL/DD	
	D.	N.	D.	N.	D.	N.
115 days	-	5.0	-	1.31	-	3.8
125 - 130 days	3.66	-	1.37	-	2.66	-
190 - 200 days	3.33	5.86	1.36	1.25	2.44	4.66
210 - 220 days	-	5.78	-	1.14	-	5.05
240+ days	4.08	-	1.23	-	3.3	-

From inspection of this table it can be seen that the ratio values varied with age for both dwarf and normal foetuses so that some ratio values were outside the range quoted by Tyler et al. (1961) for postnatal animals.

Radiographs of the lumbar spines of foetuses both from the experimental herd and abattoir specimens, allowed classification as before particularly in older foetuses. Of the abattoir foetuses four were classified as category 1 and three as category 2. All dwarf foetuses examined had

markedly abnormal lumbar vertebrae, except for the youngest foetus examined at approximately 125 days, although even at this age the ventral surface appeared flattened compared with a slightly younger normal foetus examined.

DISCUSSION

From the results of the anatomical study of the Hereford dwarf in New Zealand, it was concluded that the dwarf animals examined here were typical of the brachycephalic Hereford dwarf as described from North America. Phenotypic appearance was also very similar when published photographs were compared with the appearance of dwarfs in this country.

The tables recording measurements from live animals (Tables 3.II and 3.III) showed that the dwarf was smaller at birth in all measurements except that of head breadth, but also that the animal increased in size at a slower rate than that of its normal counterpart, so that it was even more severely dwarfed as an adult. Both Johnson et al. (1950) and Gregory et al. (1951) agreed that the differences between dwarf and normal calves became more noticeable with age. The figures published by Tyler et al. (1961) also showed this trend, although he came to the opposite conclusion in his discussion.

Measurements of colligate heterozygote animals in this study although not age, sex, or treatment matched with the dwarf and normal groups, nevertheless tended to be smaller and lighter than normal animals a result which is in accord with that found by previous workers (Edvard and Hazel, 1963;

Marlowe, 1964). While the differences were not sufficiently great to provide a means of diagnosing heterozygosity, Bovard and Hazel considered that heterozygous calves could have been selected early in life for potential breeding animals, as a shorter more stocky phenotype was regarded as desirable in a beef breed. This may have led to an increase in the dwarf gene in the population, and was one of the explanations put forward for the rapid increase in numbers of dwarfs in the late 1940's in the United States of America.

One important aspect of the reduction in size and weight of carrier animals not considered by previous workers, concerns the economic loss from the smaller weight of carcass. While the birth of a dwarf calf will often mean a total loss in terms of carcass value, the unseen presence of carrier animals in the herd means an even greater economic loss. For example it can be estimated on theoretical grounds that if there is a prevalence of 10% carriers in the population, one dwarf would occur in each 400 calves born. If each of the 40 carriers in the herd produced 10% less carcass meat then the economic loss in terms of meat production would be four times that due to the obvious loss of a dwarf animal.

In comparison with human achondroplasia, in which proximal bones are more dwarfed than distal bones, there was more pronounced dwarfing in the distal bones in the dwarf Hereford cattle. In both conditions the diameter of the bones was approximately normal size, although in the Hereford dwarf the metacarpus was wider than normal. Ancon sheep also displayed greater width in the bones than their normal counterparts.

There was also an increase in the degree of dwarfing with age. This is in contrast to some other chondrodystrophies, e.g. the Dachs rabbit and Ancon sheep, in which there was reduction in the limb length in the foetus but growth continued at the same reduced rate, so that the ratio of dwarf/normal remained constant to adult life. Gruneberg (1963) suggested that if the mature chondrocyte was itself abnormal then the abnormality would increase with age, in contrast to a situation in which a cell was only sensitive for a particular phase, so that as older cells moved out of this phase, they were replaced by new cells.

In the present study the metacarpal ratio values fell within the same range as those published by Tyler et al. (1961). Differences were noted in the average values between age groups when normal animals were compared with dwarfs. The value of the total length:diaphyseal length became more divergent between dwarf and normal with increasing age, however that for the total length:diaphyseal diameter tended to become closer with age. A similar trend was apparent in the figures published by Tyler and his colleagues. Perhaps there is some compensatory growth in width of bones by appositional growth.

This study confirmed previous reports of an early closure of the spheno-occipital synchondrosis in the brachycephalic Hereford dwarf. The two 12 month old Hereford animals which had incomplete closure of the spheno-occipital synchondrosis were typical brachycephalic dwarfs in all other criteria. This age was outside the range quoted by Julian et al. (1957) and the reasons for this apparent 'late' closure were not

obvious. The factors which bring about early closure of the spheno-occipital synchondrosis in brachycephalic dwarfs have not been determined. The early closure of the synchondrosis was not however, responsible for the mid frontal prominence, as this latter was already present in foetal skulls in which there was no indication that the synchondrosis was closing. As found by Julian et al., the formation of a synostosis was seen to be starting in the ventral aspect of the joint in the beast in which partial closure had occurred. The early closure of the spheno-occipital synchondrosis was one of the main reasons for the hypothesis that 'achondroplastic processes' were involved in the brachycephalic Hereford dwarf (Julian et al. 1957; Tyler et al. 1957).

The cause of the dwarfed appearance of the two Angus calves examined in which the spheno-occipital synchondrosis was not closed, was not determined. No testing had been carried out for the Mannosidosis status of the calves, which may result in reduced growth. They were not considered to be brachycephalic dwarfs and there is no published evidence that the dwarf gene is present in the Angus breed in New Zealand.

A further Hereford calf examined which was placed in the same uncertain category as the two Angus calves above, also had an open spheno-occipital synchondrosis. In general appearance it did not resemble the brachycephalic dwarfs, having a fairly narrow head and finer bones. While it was possible that this calf represented a different type of genetic dwarfism, it was considered more probable that other hormonal or nutritional factors played a part in the development of its small stature.

The percentage of animals with projections into the cranium in this study compared well with the published percentages of a previous study (Tyler, 1959) more particularly comparing his figures for moderate to severe projections and not including his category of mild projections. In this present study projections were only recorded as positive if they were obviously present.

While no definite conclusions could be drawn from the results of the experiment using a profilometer they were however very encouraging, and it is suggested that this method of possible identification of carriers may be helpful in a herd experiencing problems with dwarfism.

The radiographic findings in dwarf animals examined in New Zealand agreed very well with those published from the United States of America (see Chapter I). A comparison of the radiographic findings in the Hereford brachycephalic dwarf compared with those of achondroplasia in humans shows a number of differences, particularly in the pelvic bones. In achondroplastic humans there are obvious changes from the normal (Chapter I) to the extent that these are used as a means of diagnosis of the disease, whereas apart from a reduction in overall size of the pelvis, there is no anatomical difference between dwarf cattle and normal control animals. Achondroplastic humans also have constriction of the spinal canal which becomes more severe in the lumbar region. Distal narrowing of the spinal canal was not observed in the dwarf cattle.

Emmerson and Hazel (1956) considered that radiography of the lumbar vertebrae revealed sufficient changes in carrier animals for a reasonable estimate of genotype to be made in young calves. High et al. (1959) however, did not recommend radiography as a method to identify individual animals with respect to genotype but did consider it might be used as a progeny test. Radiographs of the progeny from the carrier herd in this present study showed some calves to have slight abnormalities of the vertebrae, but none approached the abnormality seen in the two dwarf animals born from this herd. Radiographs taken in the field of 40 calves from a Hereford stud in which the sire's dwarfism status was in question because of a dwarf carrier in his pedigree, were not conclusive. Seven animals had Grade 2 vertebrae and the radiographs were difficult to read in a further seven. This compares with High's figures of 39% of animals with slight abnormality from a 'clean' herd. No progeny testing of radiographed animals from either this herd, or the experimental herd, has been carried out, and therefore no conclusions were drawn concerning the significance of these abnormalities in respect to the dwarfism gene. However, it would seem a very doubtful method in this country as a means of identifying individual carrier animals, and even as a progeny test it is not considered that much weight could be placed on the diagnosis.

Only one previous study has been made of the effect of the dwarf gene on foetal development (Patton et al. 1966). These authors found that a reduction in length of bones occurred as soon as measurement of length was possible, in

the 90 day foetus. In the present study an estimate of age was made by examining the loci of ossification present and comparing this with published data, with the working assumption that these loci of ossification were appearing at the same age as for normal foetuses. There is however, no proof that this is so; it is possible that a syndrome which interferes with the process of endochondral ossification may also alter the times of appearance of loci of ossification. The youngest dwarf foetus examined in this study, at approximately 125 days gestation, was readily identified as a dwarf. The examination of early foetuses could perhaps provide a means of shortening the period of time required to progeny test a suspected carrier bull by mating him with obligate heterozygote cows or even homozygous dwarf cows.

The foetuses produced by mating dwarf with dwarf appeared no more severely affected than the aborted dwarf foetus produced from the carrier x carrier mating. This also tends to confirm a recessive mode of inheritance, as if the condition was inherited as a dominant as in achondroplasia in man, the affected offspring from a dwarf x dwarf mating would be expected to be more severely affected than the offspring from a mating between carrier animals.

Width of the metacarpus was seen in the postnatal dwarf animal to be as great or greater than that of the normal animal in all except one age group. While this apparent difference could perhaps be explained by chance due to small numbers of animals examined, this same trend was also apparent in the dwarf foetuses. Growth in width of the bone is a

function of the periosteum and would therefore be subject to different controlling factors from growth in length.

The metacarpal ratio values calculated for both dwarf and normal foetuses especially for those under 200 days gestation, cannot be related to the figures for postnatal animals. In the normal foetus up to 200 days, there appeared to be a rapid increase in the diaphyseal length of the metacarpus compared with either the total length or the diaphyseal width. In the dwarf foetus there was a slower increase in the diaphyseal length over this period of development.

CHAPTER IV

HISTOLOGY

INTRODUCTION

Little is reported in the literature concerning histological changes in the Hereford brachycephalic dwarf (Chapter I, page 12), although Tyler et al. (1956) likened the histology they observed in the metacarpal epiphyseal plates to that of hypoplastic achondroplasia of humans. In this chapter, light and electron microscopy findings in the present series of cases are recorded.

MATERIALS AND METHODS

Animals

Tissues were examined from 29 dwarf animals whose morphology conformed to that established for snorter dwarf animals as discussed in Chapter III. They ranged in age from 7 months to 3 years and included entire males, females, and castrated males. In addition five dwarf fetuses were examined; one of these was the result of a heterozygote x heterozygote mating, while the other four were the result of homozygote dwarf x homozygote dwarf mating. As the exact date of mating was not known, these fetuses were aged by radiological examination of the ossification centres present (Lindsay, F.E.F., 1969). Their estimated ages ranged from 125 days to 240 days.

Tissues from nine normal control animals of both sexes were examined. Although most animals were between 18 and 24 months of age, they ranged from the newborn to 3 years. Tissues were also examined from five normal foetuses. One was a dairy breed foetus, estimated age 120 days, one was a Hereford x Angus foetus, estimated age 170 days, and three were beef breed foetuses obtained from the abattoirs, estimated ages 170, 188 and 190+ days.

Most animals were electively killed with intravenous sodium pentobarbitone, with the exception of three dwarf animals which died from ruminal tympany, and one dwarf and three normal animals shot with a captive bolt pistol. At necropsy all animals were confirmed as healthy, except for one dwarf with a severe balanoposthitis, and the three which died of ruminal tympany. The body condition of the animals varied however, and the dwarf animals were generally not in as good condition as the normal cattle.

Tissues

Bones were cut with a band saw to provide longitudinal sections of epiphyseal and other growth plates. Sections were taken from the costochondral junction, distal radius, proximal tibia, distal metacarpus, and the wing of the ilium. In addition, full thickness 4 mm diameter samples were removed with a punch biopsy instrument from the wing of the ilium, from both dwarf and normal animals. These were taken either under local anaesthesia from sedated animals, or immediately after death and provided the majority of material used for electron microscopy studies. Further samples of cartilage

from the proximal tibia were examined by electron microscopy in three animals.

Other tissues selected for light microscopy included liver, spleen, kidney, heart, lung, abomasum, intestine, adrenal gland, thyroid gland, pituitary gland, testis, brain and vagus nerve.

Fixation, embedding and sectioning

(1) Light microscopy: All tissues were fixed in 10% formol saline as soon after death as practical and with the exception of the animals dying from ruminal tympany, this was always within 2 hours of death. Sections containing bone were decalcified in RDO rapid bone decalcifier*. All tissues were then embedded in paraffin and sectioned at 7 μ . Samples of liver and wing of the ilium were taken from one dwarf cow and its foetus, and one normal cow and its foetus. They were then frozen, sectioned with a cryostat, and stained.

(2) Electron microscopy: Samples of cartilage were fixed in a modified Karnovsky's solution prepared the day before as follows:

1.2 g paraformaldehyde was dissolved in 20 ml distilled water by adding 2 drops N NaOH and then heating to 80^oC. When this solution had cooled the following reagents were added:

(a) 15 ml cacodylate buffer prepared from
8.01 g of anhydrous sodium cacodylate

*Du Page Kinetic Laboratories

dissolved in 1.725 ml N HCl and made up to 250 ml with distilled water.

(b) 5 ml glutaraldehyde 25%.

(c) 0.4 ml calcium solution prepared from 0.672 g of calcium chloride dissolved in 10 ml distilled water.

Blocks (maximum size 1 x 1 x 1 mm) were selected from all levels of cartilaginous growth plate in an attempt to include resting cells, proliferating cells, and hypertrophied cells. The tissues were fixed for 2 - 3 hours at 4°C, before being washed three times in sodium cacodylate buffer, pH 7.3, for 10 minutes. Blocks were then postfixed in 2% osmium tetroxide in either cacodylate buffer, or phosphate buffer pH 7.2, for 2 hours. After three buffer washes, blocks were dehydrated in a graded series of acetone, then infiltrated with a mixture of acetone and Spurr's resin*, and finally in 100% Spurr's resin on a mechanical mixer. Polymerisation in Spurr's resin was carried out at 70°C for 12 hours (Spurr, 1969). In order to obtain precipitation of the mucopolysaccharides, toluidine blue was included in the fixation process of cartilage from five dwarfs, two dwarf fetuses, and two normal animals (Shepard and Mitchell, 1976).

Epoxy resin sections for light microscopy were cut on a LKB Ultratome III ultramicrotome, at 1.0µ and approximately 0.25µ with a glass knife. The thicker sections were cut onto a dry knife, but thinner ones

*Taab Laboratories

were sectioned onto a 10% acetone bath and the section picked up with a fine glass rod. All sections were then heat fixed onto a glass slide.

For electron microscopy thin sections of approximately 7,000 nm were cut with a diamond knife and mounted on copper grids.

Staining

All paraffin embedded tissues for light microscopy were routinely stained with haematoxylin and eosin (H & E). In addition, bone sections were stained with Alcian blue/haematoxylin and eosin. Selected bone sections were also stained with Periodic-acid-Schiff (PAS); van Gieson; 1% toluidine blue; and Alcian blue containing magnesium chloride to a molarity of 0.1, 0.4 and 0.9 (Braund, K.G., et al. 1976). Pituitary glands were stained with PAS/Orange G.

Frozen tissues were stained with 1% toluidine blue, Sudan black and oil red O, and in addition the cartilage was stained with PAS/Alcian blue. Thick sections cut from epoxy resin embedded blocks were routinely stained for 15 seconds with toluidine blue on a hot plate at 70°C, and selected sections were stained with safranin, PAS, Sudan black, and Alcian blue stains, the latter with and without magnesium chloride.

Thin sections for electron microscopy were stained in uranyl acetate for 5 minutes, followed, after washing, by lead citrate for a further 5 minutes.

RESULTS

Soft tissues

With the exception of the testis, all soft tissues examined appeared normal. In particular there was no evidence of vacuolated cells as would be expected with a mucopolysaccharide storage disease, nor did examination of frozen sections of liver stained with toluidine blue indicate any increase in metachromasia compared with those from control animals. The proportion of acidophils in the pituitary gland appeared similar in the dwarf and control animals. There was reduced spermatogenesis in the testes examined, although there were spermatazoa present.

Growth plates

The histology of epiphyseal plates from normal control animals as seen in H & E stained paraffin embedded sections, corresponded with other descriptions of the normal histology of the epiphyseal plate (Bloom and Fawcett, 1962; Dellman, 1971) but there was some variation between sections depending on which bone the section was taken from, the plane of sectioning of the plate, and the age of the animal. The proliferating cells formed long even rows, although in some cases nests of cells were seen; the zone of hypertrophied cells varied in size but usually there were greater than six cells per column; capillary ingrowth from the metaphysis was regular, a capillary growing into each space formed by loss of hypertrophied cells. (Fig.4.1) In H & E stained decalcified sections, a small amount of blue staining matrix was present in the middle of most bony trabeculae for a

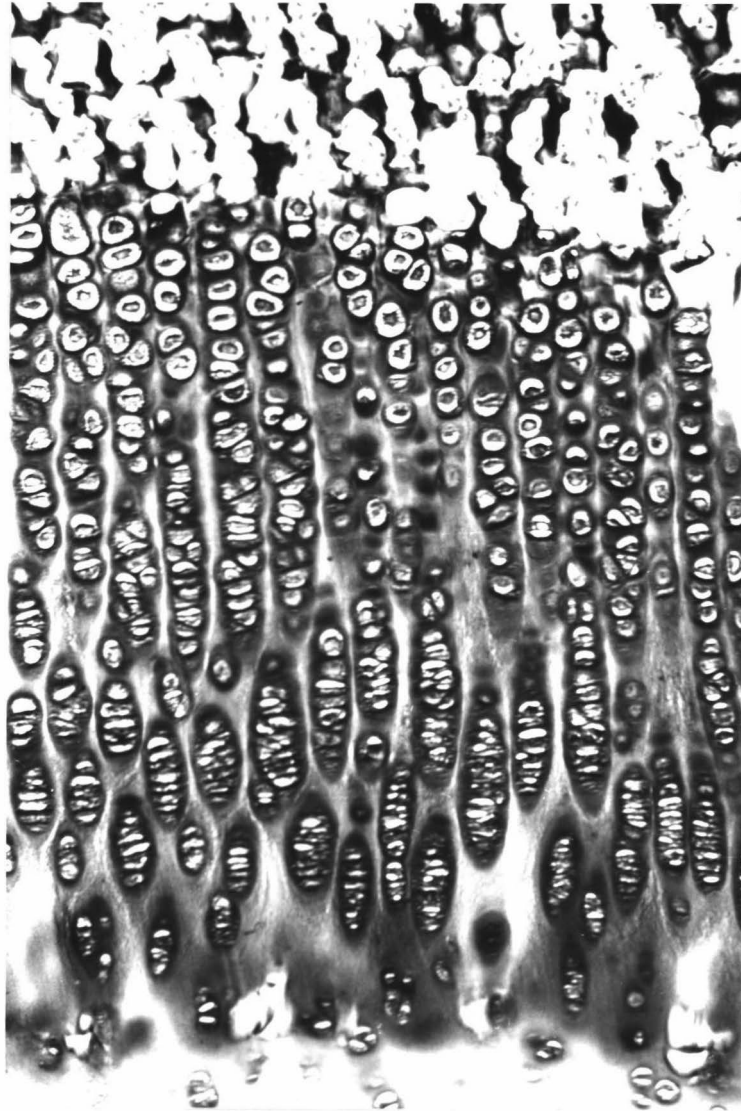


Figure 4.1 Epiphyseal plate from the distal radius of an 18 month old normal control animal. Note the long regular columns of chondrocytes. (Paraffin embedded, HeE, X 125)

short distance in the metaphysis. In the iliac crest from the control animals, the proliferating and hypertrophic zones were shorter in comparison with the epiphyseal plates.

Sections of the epiphyseal plates from dwarf animals were essentially similar to those seen in control animals. A comparison between dwarf and normal control animals of epiphyseal plates from corresponding bones of the body showed however that the proliferating columns of cells tended to be neither as long nor as regular in the dwarf plate, and there was a reduced number of hypertrophied cells. Capillary in-growth was not as regular, so that on occasions the primary trabeculae in the dwarf metaphysis were wider than in the control tissues (Fig.4.2).

Variations in degree of regularity of the growth plates from different bones were seen in both normal control and dwarf animals. The epiphyseal plates from the tibia and the radius were generally more regular and the cells formed longer columns than those from the metacarpus or metatarsus. However this variation was not notably more pronounced in the dwarf sections examined.

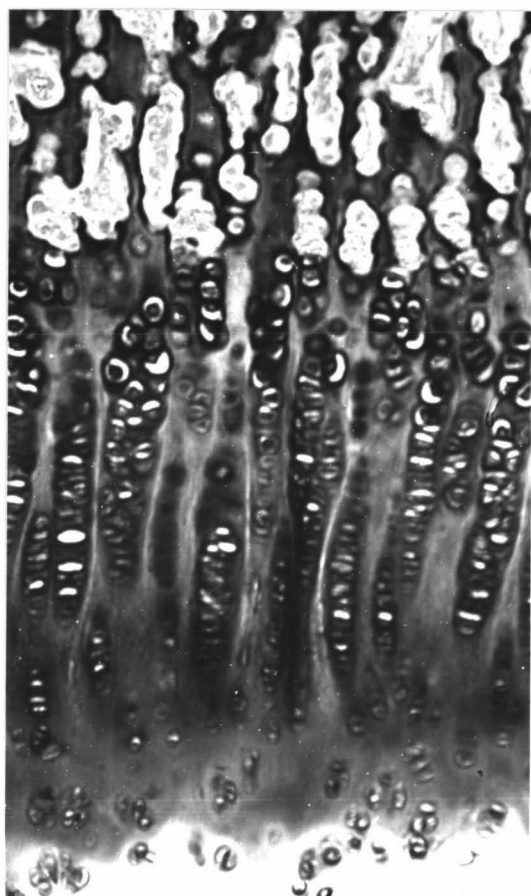
In foetal sections there tended to be a more regular arrangement of the columns compared with older age groups, in both dwarf and control tissues, however in the dwarf foetal tissues examined, there was still a shortness and irregularity of the epiphyseal plate when compared with that from an age matched control (Fig.4.3).

Figure 4.2 Epiphyseal plate from the distal metacarpus of


- (a) nine month old dwarf, and
- (b) eight month old normal control animal.

The length of columns is shorter in the dwarf animal.

(Paraffin embedded, HeE, X 125)



(a)



(b)

Figure 4.3 Epiphyseal plate from the distal metacarpus of

(a) dwarf, and

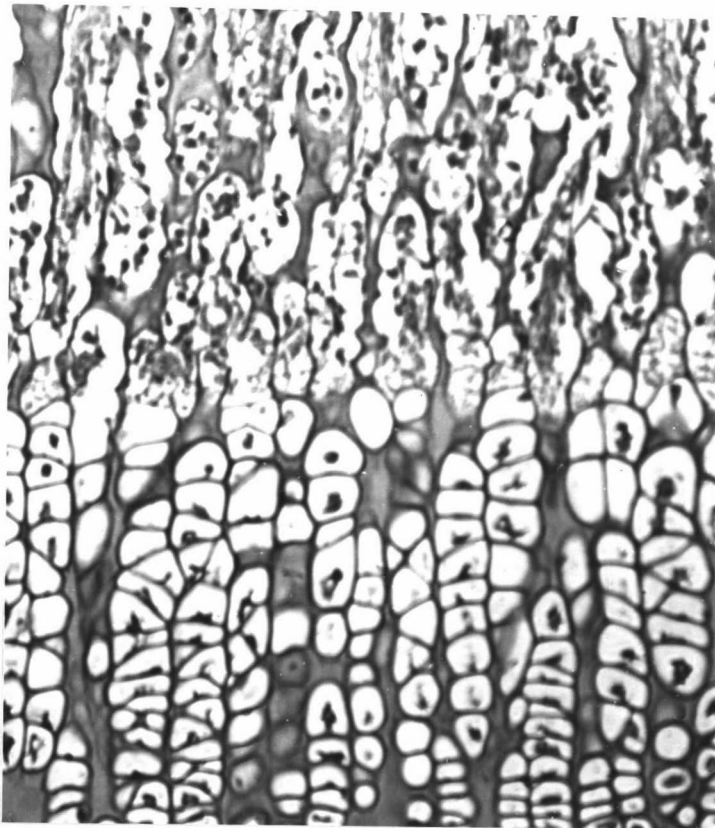

(b) normal control

foetus at estimated 180 days gestation.

Capillary ingrowth is not so regular in the dwarf foetal cartilage; there are fewer hypertrophied cells per column, and the cells appear smaller than in the normal foetal cartilage.

(Paraffin embedded, HeE, X 125)

(a)



(b)

There was less regularity both in the columns of cells and in the capillary ingrowth in older normal control animals, and in sections where the plate was near to closing the columns were very reduced and irregular. This irregularity appeared to start at an earlier age in the dwarf animals examined, and was more pronounced. This variation with age is shown in Figs. 4.4 and 4.5.

In the iliac crest where the proliferating and hypertrophic zones tended to be smaller than these zones in the epiphyseal plates in long bones from normal animals, this appeared even more obvious in the dwarf animal (Fig.4.6).

The spheno-occipital synchondrosis, whilst closing early in the dwarf, showed only the same degree of irregularity as noted in other growth plates from dwarf animals (Fig.4.7).

The number of osteoclasts and osteoblasts present in bone varied with the sample and no consistent difference was noted between dwarf and normal tissues.

Histochemistry of growth plates

- (1) Alcian blue with magnesium chloride: Staining of normal cartilage in Alcian blue with 0.1 M magnesium chloride resulted in an intense blue staining zone immediately surrounding chondrocytes in resting cartilage. This was surrounded by a less intense hue grading to a pale intercellular zone. In the proliferating cell area there were only two zones, an intense blue colour around groups of cells in a column and a less intense colour between columns. Staining with Alcian blue in 0.4 M magnesium chloride


Figure 4.4 Epiphyseal plate from the distal metacarpus of

(a) 18 month old normal control animal compared with that from


(b) 2 year old normal control animal.

The hypertrophied cells are fewer per column in the older animal and the regularity of the columns has been lost.

(Paraffin embedded, HeE, X 125)



(a)



(b)

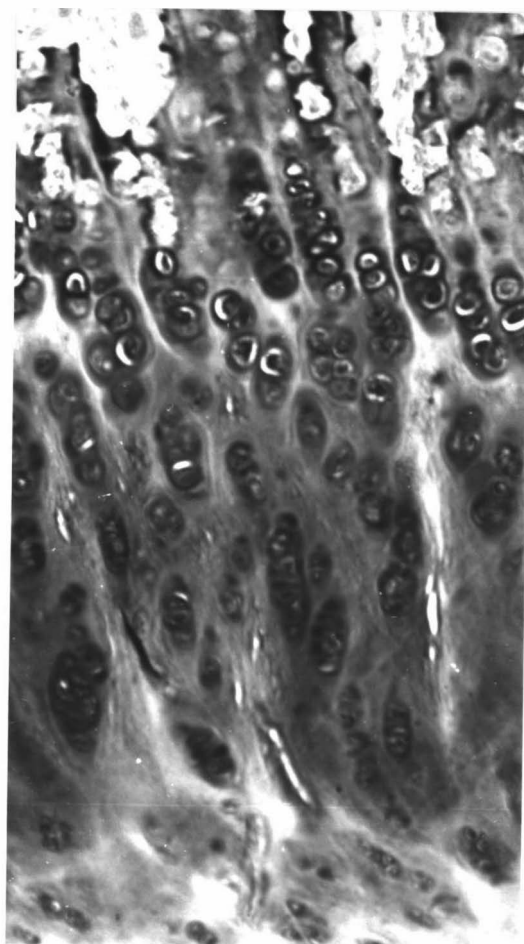
Figure 4.5 Epiphyseal plate from the distal metacarpus of

(a) 18 month old dwarf compared with that from

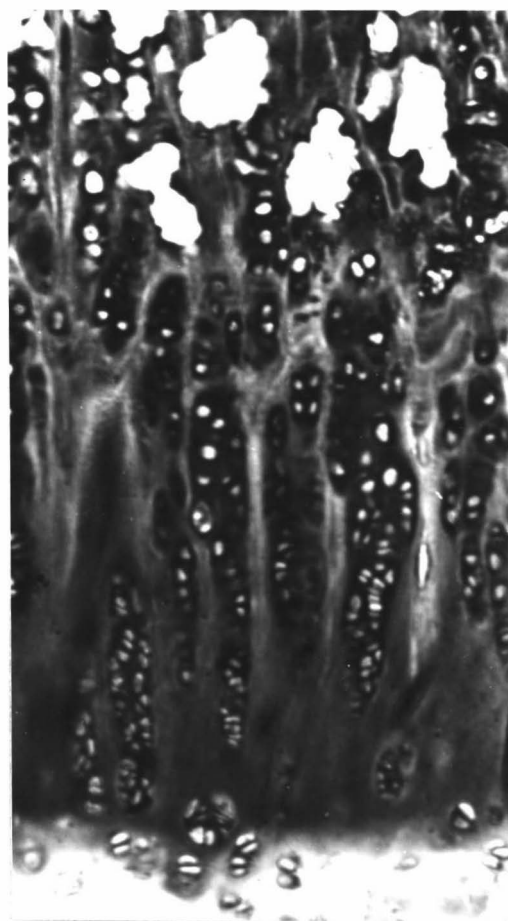
(b) 2 year old dwarf.

Note the irregularity in both sections, with fewer hypertrophied cells in the older animal.

(Paraffin embedded, HeE, X 125)



(a)



(b)

Figure 4.6 Iliac crest from

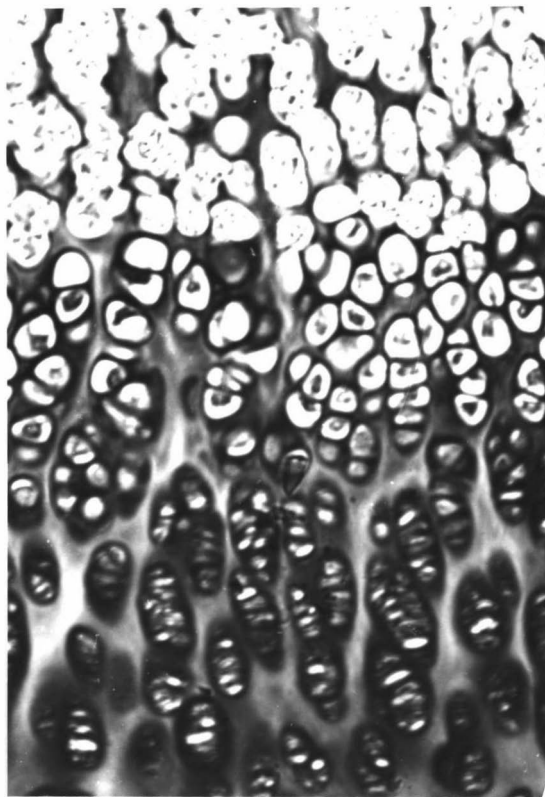
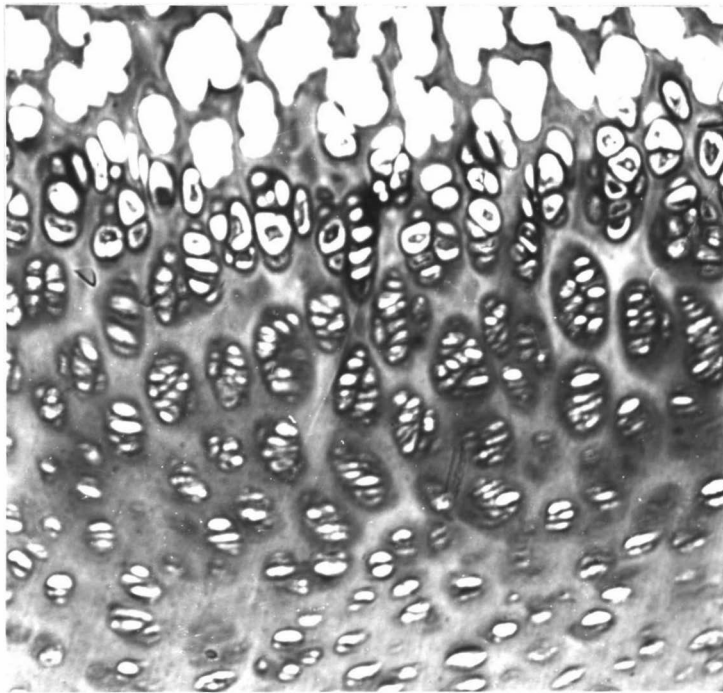
(a) nine month old dwarf compared
with that from

(b) eight month old control animal,

showing the reduced number of hyper-
trophied cells in the cartilage from
the dwarf animal.

(Paraffin embedded, HeE, X 125)

(a)



(b)

Figure 4.7 Spheno-occipital synchondrosis from

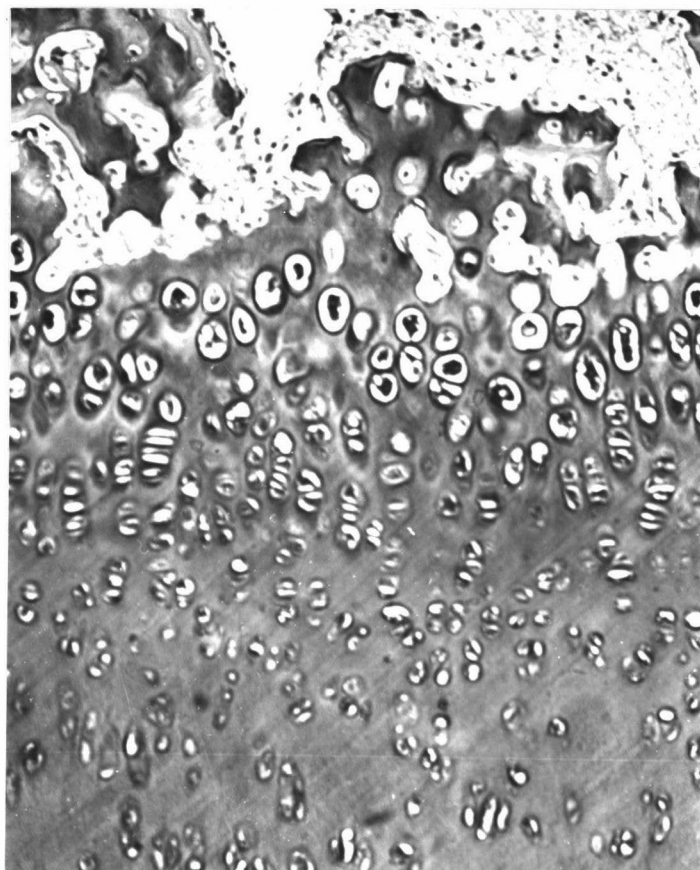
(a) dwarf foetus compared with
that from

(b) normal control foetus

at estimated 180 days gestation.

The dwarf synchondrosis shows fewer
proliferating cells at the base of the
columns, less regular arrangement of
columns, and fewer hypertrophied cells.

(Paraffin embedded, HeE, X 125)



(a)



(b)

resulted in a less intense colouration than above, with less obvious zoning in the resting cartilage. With Alcian blue in 0.9 M magnesium chloride there was very little colouration of matrix at all, but that which occurred was in a zone between the proliferating columns and the resting cartilage.

The dwarf cartilage generally stained in a similar manner, although the stain appeared less intense and the zoning in the resting cartilage was not so obvious, there frequently being a granular appearance to the intercellular matrix.

- (2) PAS: The amount of PAS positive material within cells varied between individuals but no difference was noted between dwarf and normal animals. Treatment with diastase after PAS staining removed the PAS positive material from the chondrocytes, indicating that glycogen in the cell was responsible for the PAS positive reaction.
- (3) Van Gieson: A zoning pattern was also apparent but in contrast to that with Alcian blue, the deeper colouration was in the intercellular zone of the resting cartilage with a pale zone surrounding the cells. The matrix between the columns of the proliferating cells stained more intensely than that immediately around the cells but was not so intense as in the resting cartilage area.
- (4) Toluidine blue: This stain was used specifically to identify mucopolysaccharides, which have a metachromatic staining reaction. In paraffin embedded sections, the cytoplasm of chondrocytes generally stained pale blue,

there was a pale pink-purple zone around the cells and the intermediate zone stained blue.

A more satisfactory examination of the chondrocytes was possible with the resin embedded sections which were subsequently stained with toluidine blue. Chondrocytes from the resting zone of normal cartilage were round to oval in shape with an irregular outline. The matrix immediately surrounding the chondrocytes stained a pale pink/purple colour compared with a more blue staining of the rest of the intercellular matrix. In general, foetal cartilage matrix stained pale blue in young foetuses, but became more metachromatic as the foetal age came closer to term. The nucleus of the cells frequently contained several prominent nucleoli. Most of the cytoplasm stained a uniform blue, although there was often a pale staining area near the nucleus, and occasionally a small amount of purple/red staining stranded material was seen. Many cells contained one or two vacuoles, some of which stained a pale grey/blue indicative of lipid.

Chondrocytes from the proliferating zone were closer together and appeared narrower and more elongated. Their outline was still irregular, but there was a reduced amount of cytoplasm and most cells contained one or two prominent vacuoles.

Chondrocytes from dwarf cartilage appeared very similar to the normal, but in some sections examined, resting chondrocytes contained a much larger amount of the purple/red staining substance than occurred in

chondrocytes from normal cartilage (Fig.4.8). This difference in staining was not always reproducible even in the same block of tissue. and may also have been dependent on the freshness of the toluidine blue stain. Chondrocytes from early foetal sections appeared similar in both normal control and dwarf animals, however as the age of the dwarf foetus approached nearer to term, this purple/red staining in the chondrocytes became apparent, generally in a smaller proportion of cells than in the adult. In foetal tissue up to 25% of the chondrocytes examined might have this staining characteristic, whereas in adult tissue which showed this, as many as half the cells contained some purple/red staining material.

Resin embedded sections with toluidine blue included in the fixing process

This method resulted in the precipitation of the mucopolysaccharides present by the toluidine blue, compared with conventional fixation where a proportion of the mucopolysaccharide was leached out. Thin sections (1μ) cut from these blocks required no further staining. No significant difference could be noted between dwarf and normal cartilage. The method resulted in deeper metachromatic staining around the chondrocytes than of the intercellular matrix. Individual chondrocytes sometimes had an intensely staining ring around them and this was more commonly seen in the proliferating zone (Fig.4.9). In some sections there was a granular appearance around the cell rather than a definite staining zone.

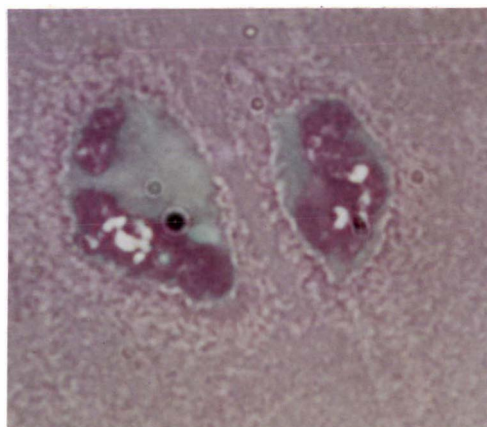
Figure 4.8 Chondrocytes from

(a) dwarf cartilage, and

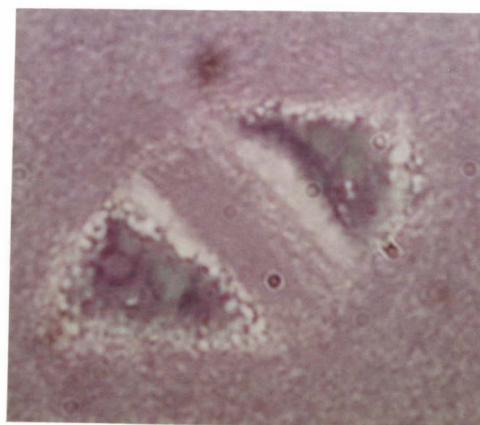(b) normal cartilage,

showing the increased metachromatic staining substance within dwarf chondrocytes.

(Epoxy resin embedded, toluidine blue, X 1250)



(a)



(b)

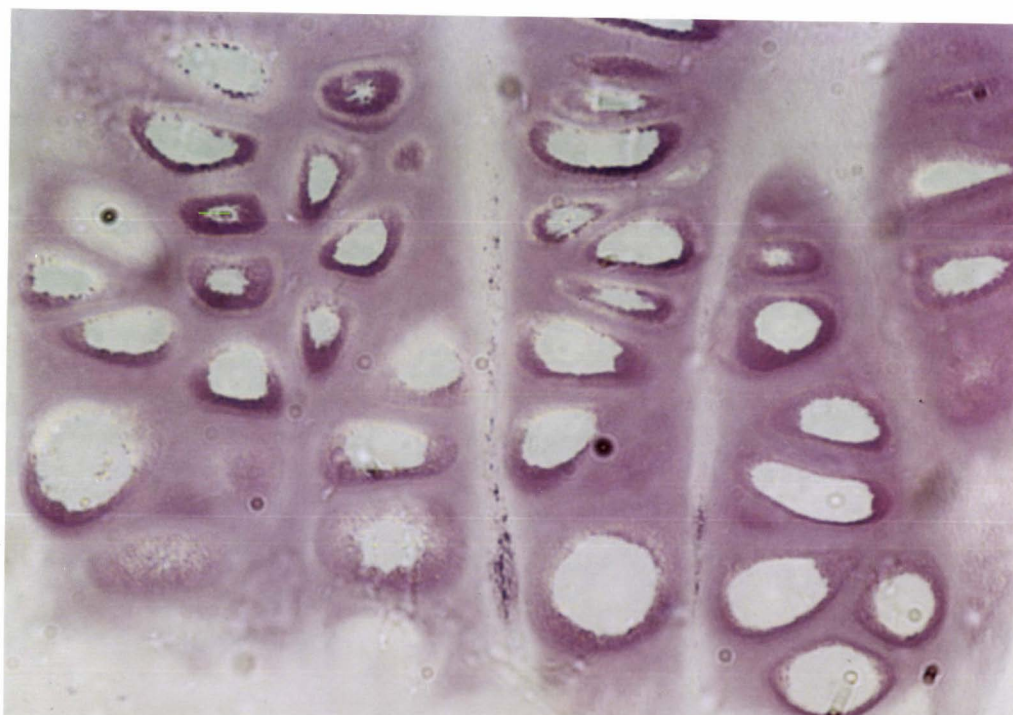


Figure 4.9 Proliferating zone of epiphyseal plate from dwarf cartilage showing metachromatic staining around some chondrocytes.
(Epoxy resin embedded, toluidine blue X 500)

Occasional purple granules were seen in the cytoplasm of the cells, more usually towards the outer membrane.

Histochemistry of frozen sections

- (1) Toluidine blue: There was very little metachromasia seen in either dwarf or normal control liver sections from foetal and adult animals. Cartilage sections showed poor cellular detail. Staining of the zones of the matrix was similar in dwarf and normal control animals, though in some instances the intensity was less in dwarf tissue.
- (2) Sudan black and Oil red O: Neither fat stain showed a significant amount of fat in either liver or cartilage from dwarf or normal control animals.

Electron microscopy

Sectioning with a diamond knife gave more satisfactory results than when a glass knife was used, however there was some variation in the quality of sections presumably due to variations at one or more stages in the fixing process. Experience in using the toluidine blue in the fixation process indicated that the stain (and therefore probably the fixative) did not penetrate very far into the block, even though this was kept to a minimum size. Sections taken too close to the centre of the block would not therefore have been very well fixed.

- (1) Chondrocytes: The ultrastructural appearance of chondrocytes of normal bovine cartilage was similar to published descriptions of this cell type (Godman and Porter, 1960; Goel, 1970; Goel and Jurand, 1972).

Chondrocytes from dwarf cartilage in general showed the same characteristics as chondrocytes from normal control cartilage. Typical cells had an irregular scalloped outline, and contained a large nucleus often with prominent nucleoli (Fig.4.10). A large Golgi complex was situated near the nucleus and consisted of lamellae and vesicles, some of which contained small dense particles (Fig.4.11).

Variations in morphology between cells probably reflected in part the metabolic activity of the cell at the time. In some cells the endoplasmic reticulum had small dilatations, while many cells had large deposits of glycogen. Lipid vacuoles were noted in some cells and vacuoles containing electron dense material were also seen. In other cells, groups of fibrils occurred (Fig.4.12). Similar features were noted in foetal dwarf chondrocytes (Fig.4.13).

In some chondrocytes however, in tissue from all ages, dilatations of the endoplasmic reticulum were larger by subjective assessment than those observed in any chondrocytes from normal cartilage (Figs.4.14, 4.15).

- (2) Matrix: The matrix of normal cartilage was similar to that described in the literature (Matukas et al. 1967; Anderson and Sajdera, 1971; Thyberg, 1977). In both dwarf and normal cartilage it consisted of irregularly arranged collagen fibrils within an amorphous ground substance containing numerous small granules and varying numbers of vesicle type structures (Fig.4.16a and b). There were few collagen fibrils in close

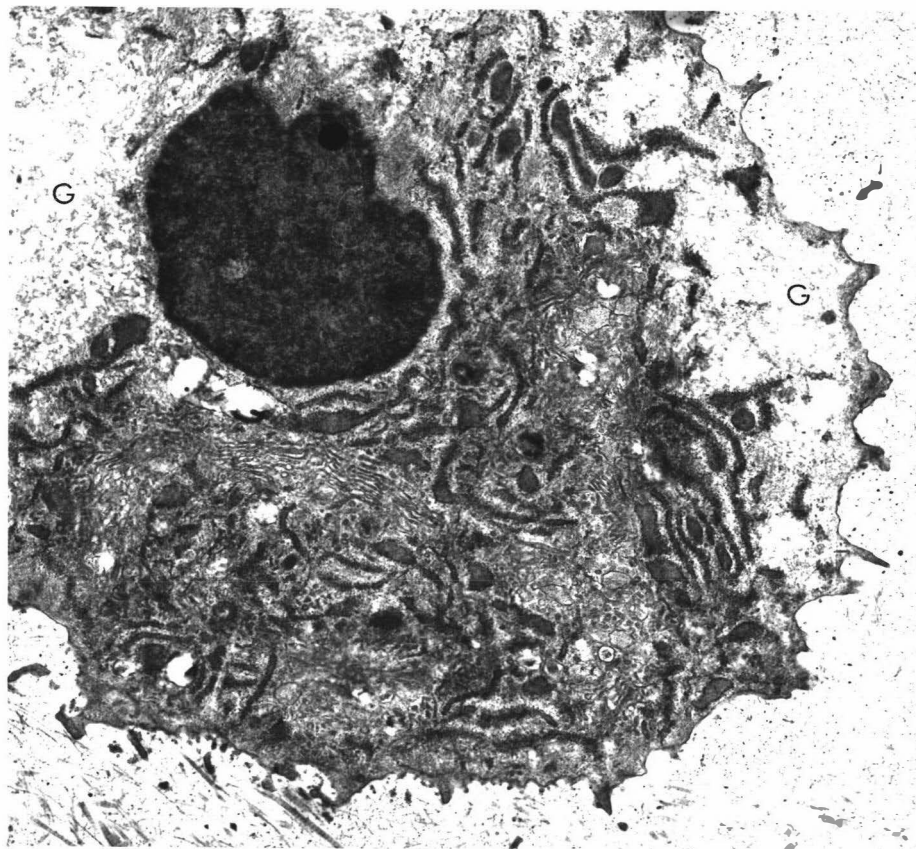


Figure 4.10 Resting chondrocyte in cartilage from an 18month old dwarf animal, showing scalloped outline, large nucleus, vesicles and lamellae of golgi complex, and the endoplasmic reticulum. Glycogen (G) has been leached out during processing.
(E.M. X 12,140)

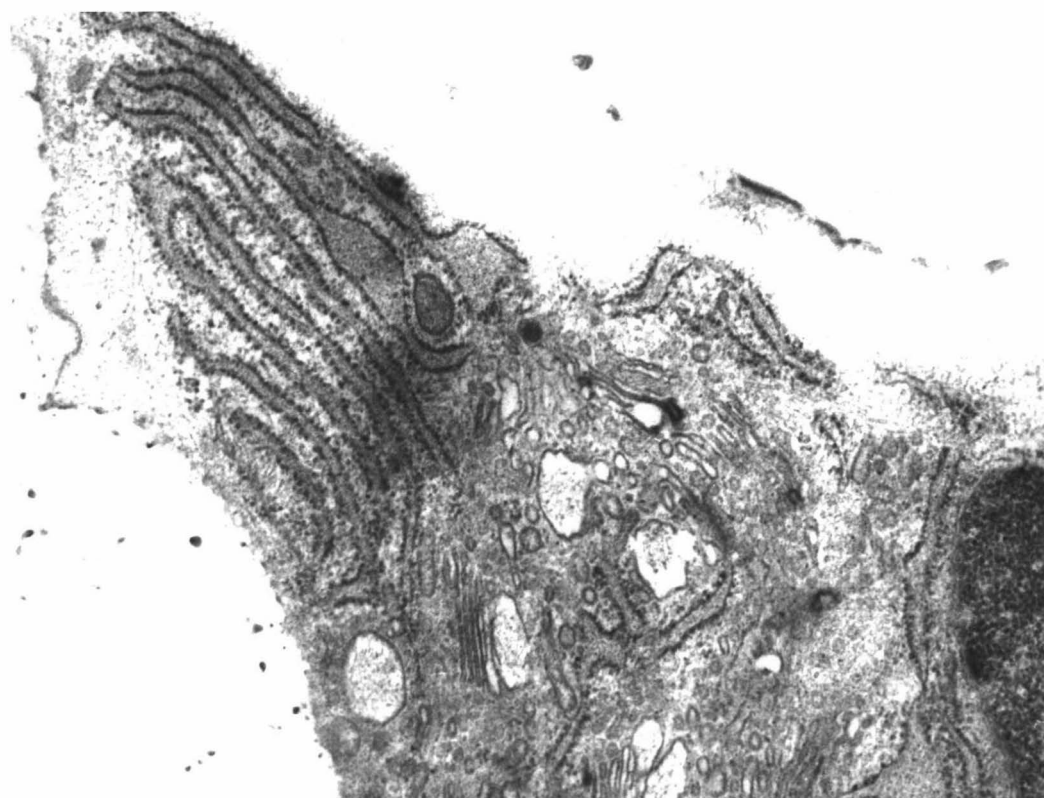
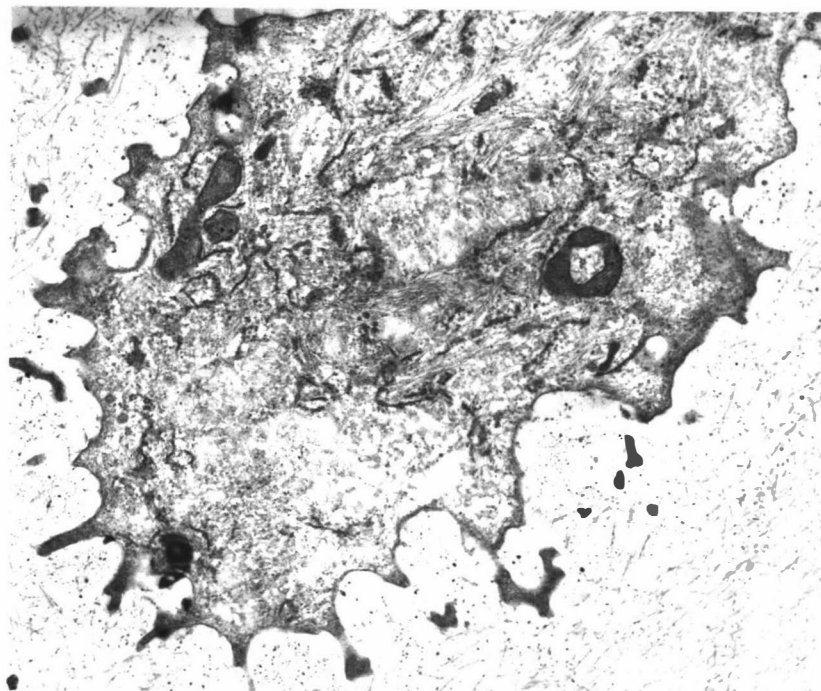


Figure 4.11 Detail of chondrocyte from dwarf cartilage showing vesicles and lamellae of the golgi complex.
E.M. X 30,000.

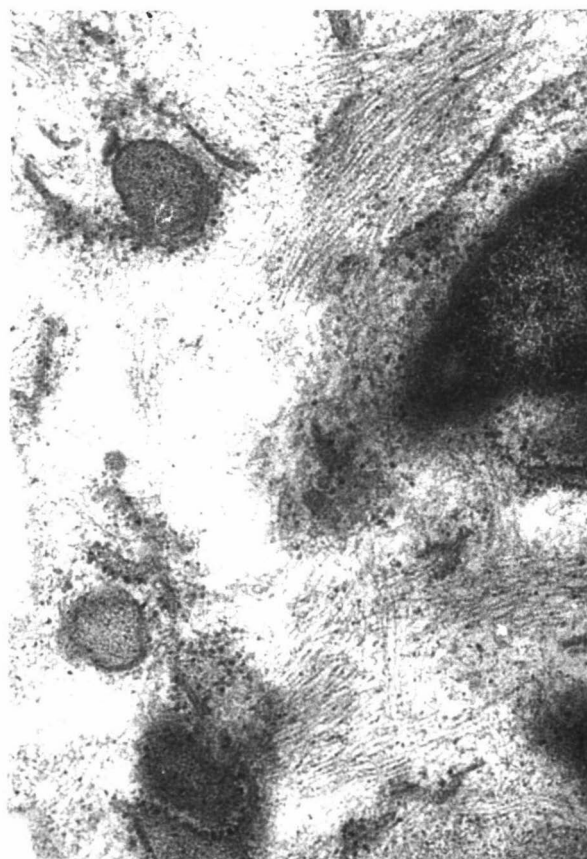
Figure 4.12 Chondrocyte from an 18 month old dwarf.

(a) Note numerous fibrils in cell EM x 15,000.

(b) Detail of fibrils EM x 42,000.



(a)



(b)

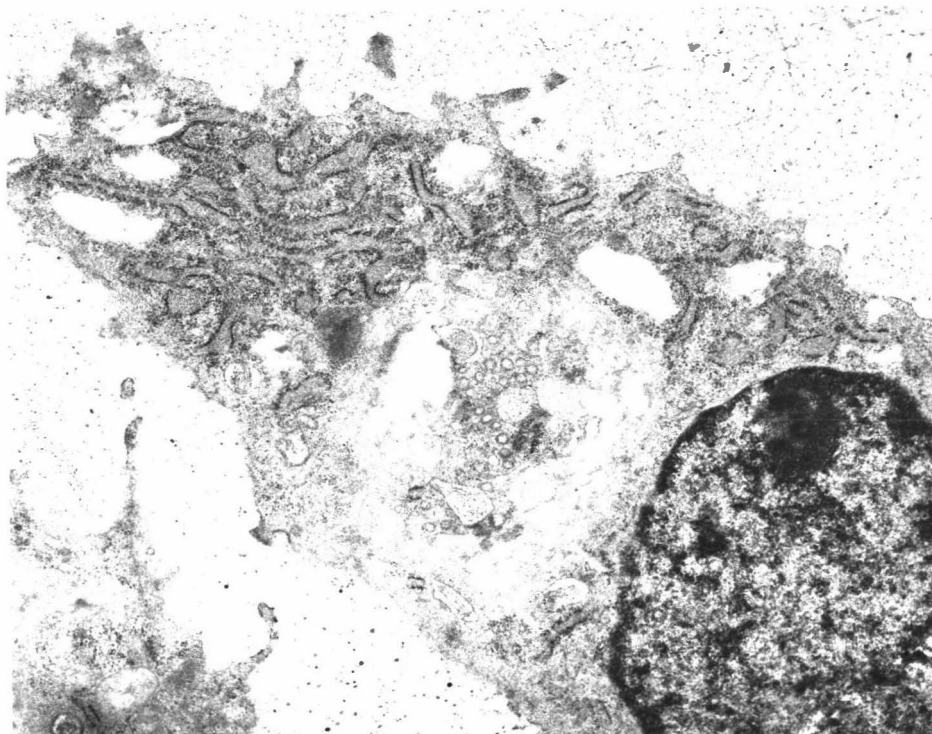


Figure 4.13 Chondrocyte from foetal dwarf cartilage showing essentially normal ultrastructural features. E.M. X 41,400.

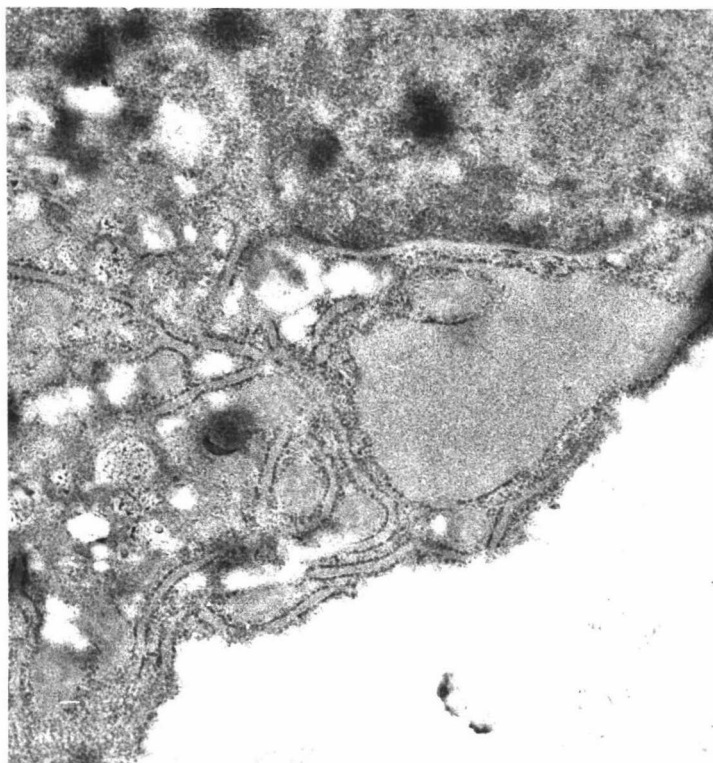


Figure 4.14 Chondrocyte from a 10 month old dwarf animal showing dilatation of the endoplasmic reticulum.
E.M. X 30,700.

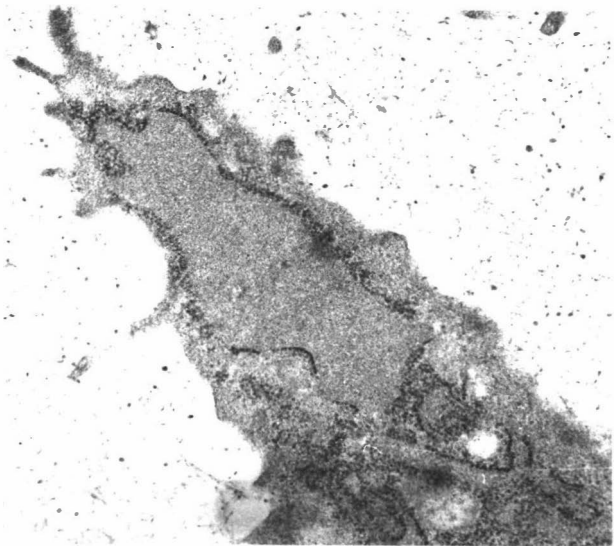
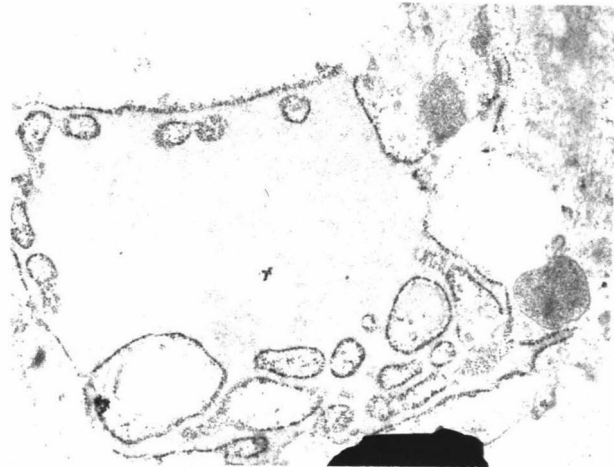


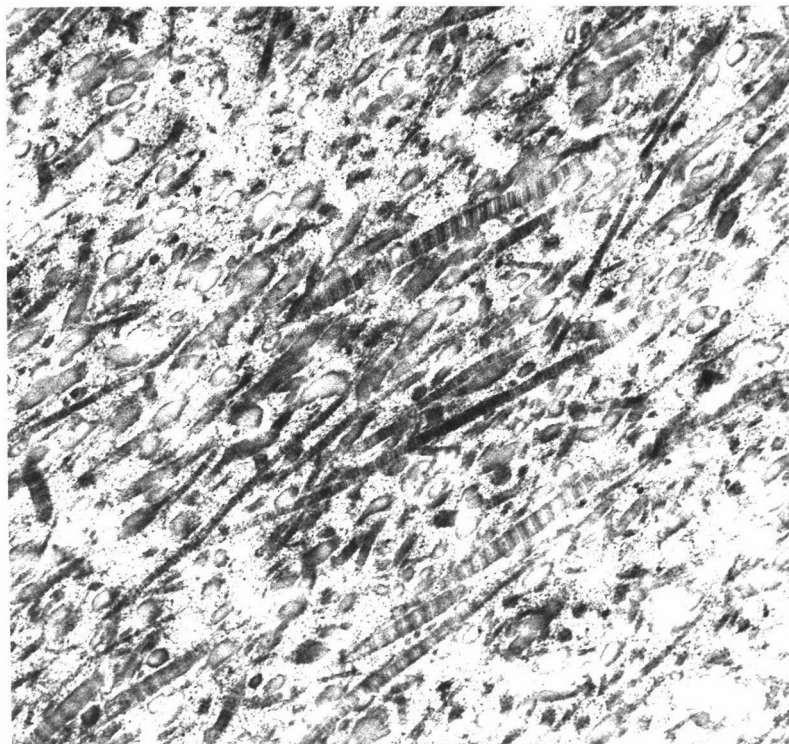
Figure 4.15 Chondrocytes from dwarf foetal cartilage showing dilated endoplasmic reticulum.
E.M. X 22,500.

Figure 4.16 Matrix of cartilage fixed in
Karnovsky's fixative.

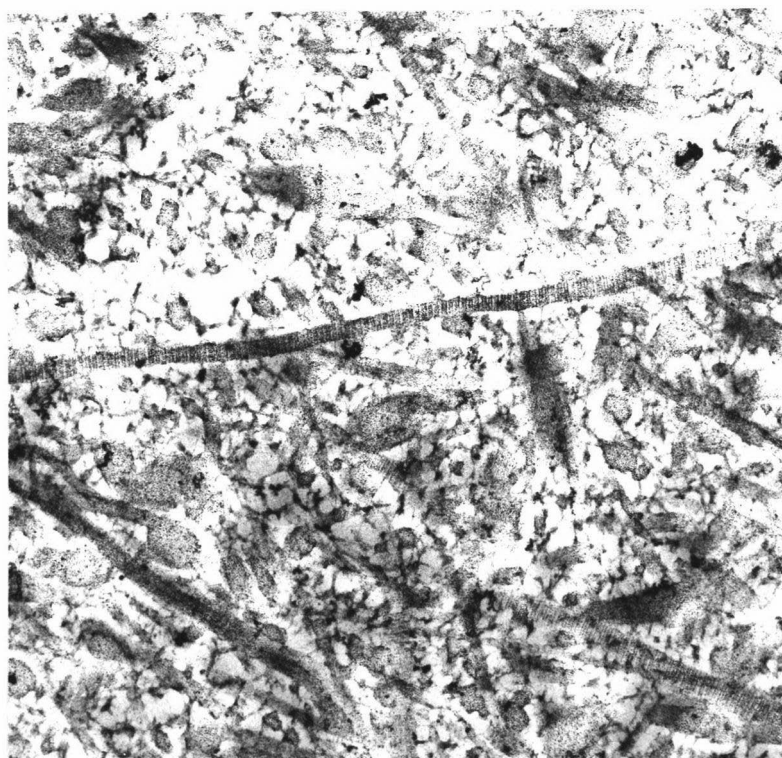
(a) normal animal

(b) dwarf animal

EM x 41,400



(a)



(b)

proximity to chondrocytes. With toluidine blue included in the fixation process, the matrix was seen to be composed of collagen fibrils as before, but the background contained a fine electron dense network extending from the edge of chondrocytes (Fig.4.17a and b). This network represented the mucopolysaccharide which was precipitated by the toluidine blue in the fixing process. No difference between dwarf and normal matrix was observed.

DISCUSSION

In previous reports concerning light microscopy of tissues from the Hereford brachycephalic dwarf few abnormalities were recorded (Chapter I, p.12). This present study likewise found most soft tissues examined to be normal. Although there was reduced spermatogenesis in the testis, at least one of the dwarf bulls used in this study was fertile, as all the dwarf cows running with them became pregnant (Chapter II, p.48). Only one other report in the literature mentioned the histology of growth plates in dwarf animals (Tyler et al, 1956) and few details were given.

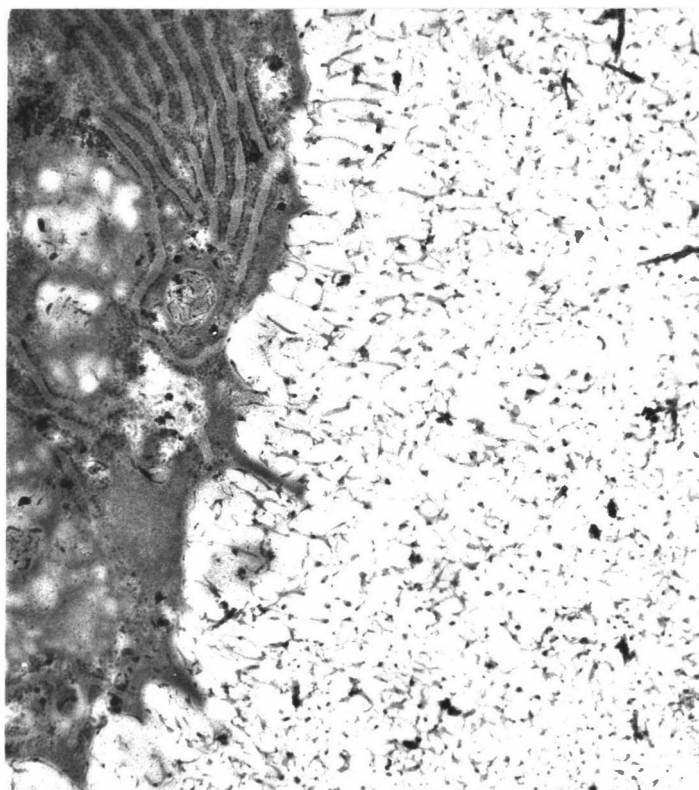
Careful control of environmental variables such as age, sex, plane of nutrition, climatic factors etc., which very probably have an effect on the normal histology of the epiphyseal plates in a growing animal, were not as easily regulated as has been achieved in studies with dwarf laboratory animals. Despite this, the histology of dwarf growth plates was consistently more irregular than that seen in normal animals

Figure 4.17 Matrix of cartilage, fixed in Karnovsky's fixative but including toluidine blue in the fixing process. Note electron dense network extending from the edge of the chondrocyte. No collagen fibres are visible.

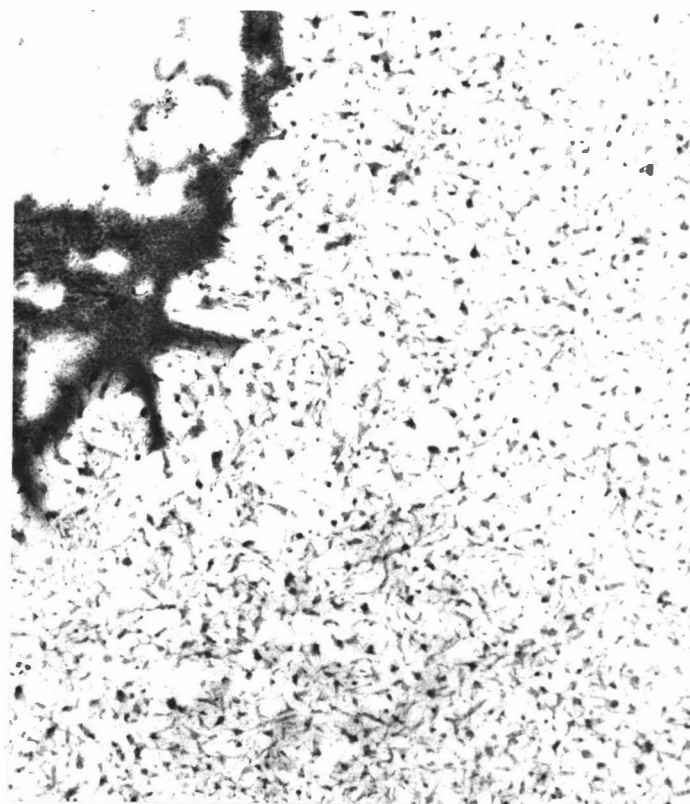
(a) normal animal

(b) dwarf animal

EM x 22,500.



(a)



(b)

of a comparable age. Tyler and his colleagues likened the changes they observed to that seen in hypochondroplasia in humans. However, Rimoin (1975) stated that histology of the rib and iliac crest revealed regular, well organised endochondral ossification in hypochondroplasia. This was also the case in achondroplasia in humans, but the two could be distinguished histologically by the increased periosteal ossification seen in achondroplasia. This change was not observed in the sections from the Hereford dwarfs, neither was cupping observed radiographically at the rib ends or other growth plates. Primary trabeculae were sometimes observed to be slightly wider in the dwarfs compared with those of normal controls, a feature also recorded in human achondroplasia.

The irregularity in the epiphyseal plate became more marked with age in the dwarf sections examined. This irregularity was also seen in growth plates from the older normal control animals, and so would appear to be part of the normal ageing process. It was noted by Ponseti (1970) when examining growth plates from achondroplastic children, that the epiphyseal plate from the head of the fibula was more irregular than that from the iliac crest which appeared essentially normal. As was recorded in the results, variations in regularity between epiphyseal plates from different bones of the body were seen, but a similar trend was seen in both normal control and dwarf animals.

Characteristic changes were seen by light microscopy of cartilage from cases of mucopolysaccharidoses by Rimoin (1974) who described a loose, lacey type of connective tissue

scattered throughout the cartilage. No such changes were observed in the cartilage from the Hereford dwarfs.

In this study the histochemical investigations of paraffin embedded dwarf cartilage sections showed few changes from those of the normal control tissues. Possible differences in the mucopolysaccharide component of the matrix shown by slight variations in intensity of staining with Alcian blue between dwarf and normal tissue were not confirmed by the toluidine blue stain in paraffin or epoxy resin embedded dwarf cartilage.

Staining with toluidine blue of epoxy resin embedded sections examined by light microscopy did show some variation from normal, in that a red staining material was seen both in greater amounts and more frequently within chondrocytes from dwarf cartilage than in those from normal control cartilage. Toluidine blue was used by Godman and Lane (1964) to observe intracellular and pericellular sites of gamma (red) metachromasia in cartilage. They stated that a violaceous metachromasia given by the ribonucleo-proteins in the cytoplasm could be distinguished from the reddish metachromasia of sulphated mucopolysaccharides. They observed this red metachromasia within cells only occasionally, and it was normally distributed as a series of granules at the cell periphery, although it was occasionally seen in the golgi area. In this present study it was not definitely established whether the red staining would be attributed to the ribonucleo-proteins, or to sulphated mucopolysaccharides. A comparison of toluidine blue fixed cells with those using conventional fixation revealed that there was metachromasia around the periphery of the cell in

the former, with a few granules in the cell, whereas the cell from conventionally fixed tissue and stained with toluidine blue contained metachromatic material within the cell. As the mucopolysaccharides were more likely to have been leached out of the cells where conventional fixation was used, this would seem to indicate that the metachromasia was not due to these substances.

Ultrastructural examination revealed dilated endoplasmic reticulum in dwarf chondrocytes to a greater degree than that seen in those from normal controls. Rimoin (1976) found dilated cisterns of rough endoplasmic reticulum in the Kniest syndrome, metaphyseal chondrodysplasia, and some cases of spondyloepiphyseal dysplasias. He considered that such dilations were non-specific and the result of a variety of different alterations in protein synthesis or secretion. Perhaps these dilations of endoplasmic reticulum could be related to the increased amounts of metachromatic staining substance seen in dwarf chondrocytes with toluidine blue staining of epoxy resin embedded sections. However, serial sections with identification of a particular cell by both light and electron microscopy was not achieved.

Light microscopy did not indicate any significant change in staining properties of the dwarf matrix when compared with matrix from cartilage of normal control animals. Electron microscopic studies likewise showed no difference in the matrix between the two groups.

Although some variations from normal were noted in the regularity of the epiphyseal plates and some staining reactions, these changes were not sufficient to allow specific histological

diagnosis of dwarfism. Morphometrical studies of epiphyseal plates from age, sex, and environment controlled dwarf and normal Hereford cattle would allow a more accurate assessment of the extent of the variation from normal seen in dwarf cartilage.

CHAPTER VBIOCHEMISTRY: ANALYSIS OF MUCOPOLYSACCHARIDES EXCRETED
BY THE HEREFORD SNORTER DWARF

INTRODUCTION

Higher levels of mucopolysaccharides were found in the urine of Hereford dwarf cattle than in the urine of normal cattle in the United States of America by Lorincz (1960), and in the same material reworked by Hurst et al. (1975). McIlwain and Eveleth (1962) also reported higher levels of mucopolysaccharide in the urine of dwarf cattle they examined. However these results were refuted by others (Tyler et al. 1962; Mayes et al. 1964).

In this chapter urinary mucopolysaccharides of New Zealand dwarf Hereford cattle are compared with those of carefully matched controls.

MATERIALS AND METHODS

Animals

Three castrated male Hereford dwarf cattle 9 months of age, and three normal Hereford animals of the same age and sex were accustomed to hay and meal for two weeks. They were then housed in individual stalls where the same diet was fed, with water available at all times. One week later urine collection commenced by means of vinyl funnels strapped around each animal's abdomen, leading into a plastic container placed below stall level. Samples were collected twice daily, filtered, measured, refrigerated and then 24 hour samples were bulked. From this 24 hour sample, 2 x 100 ml

aliquots were frozen at -12°C until required. At the completion of urine collection, the cattle were weighed and at a later date autopsied.

Biochemical analyses

1. The CPC citrate turbidity test (Pennock, 1976)

Reagents:

- (a) Citrate buffer pH 4.8: 9.68 g of citric acid and 15.88 g of trisodium citrate were dissolved in 1.0 l of deionised water.
- (b) CPC reagent: 1.0 g of cetylpyridinium chloride was dissolved in 1.0 l of the citrate buffer.
- (c) Standards were prepared containing 10.0 mg/l of chondroitin sulphate, Type A*.

Method:

All samples were assayed in duplicate at room temperature and the mean results recorded.

- (a) 2.0 ml of sample was mixed with 2.0 ml of citrate buffer as a blank.
- (b) 2.0 ml of sample was mixed with 2.0 ml of CPC reagent for the test.
- (c) 2.0 ml of standard was mixed with 2.0 ml of CPC reagent.
- (d) These solutions were allowed to stand for 30 minutes, and the absorbance (OD) at 680 nm recorded.

*Sigma chemical company

(e) CPC units/l were calculated from the following:

$$\frac{\text{OD Test} - \text{OD Blank}}{\text{OD Standard}} \times \frac{\text{Concentration of standard (mg/l)}}{10} = \text{CPC units/l}$$

(Where 1 CPC unit = absorbance given by a solution containing 10 mg/l chondroitin sulphate)

2. Urinary creatinine (Bauer et al. 1968)

Reagents:

(a) Saturated picric acid solution.

(b) 0.75 M Sodium hydroxide.

(c) Creatinine standards:

(i) Stock standard - 150 mg creatinine and 1.0 ml concentrated hydrochloric acid was dissolved in water to make 100 ml, to give a solution containing 1.5 mg/ml.

(ii) Working standard - 1.0 ml of the stock standard was diluted with water to 100 ml, to give a solution containing 0.015 mg/ml.

Method:

(a) The urine sample was diluted 1:100 with water. To 3.0 ml of this diluted urine, 1.0 ml picric acid and 1.0 ml NaOH solution were added. A water blank and a working standard were set up in the same way. Two other standards were prepared, containing 1.0 ml of working standard plus 2.0 ml water, and 2.0 ml of working standard plus 1.0 ml of water, with other reagents added as before. The tubes were mixed and allowed to stand at room temperature for 20 minutes. The absorbance at 520 nm was recorded

and creatinine in the urine calculated as follows:

$$\text{mg/ml creatinine} = \frac{\text{OD Sample}}{\text{OD Standard}} \times \frac{1}{3} \times S \times 100$$

(where S = amount of creatinine added to the standard i.e. 0.015, 0.03 or 0.045 mg).

3. Quantitative estimation of urinary mucopolysaccharides by the measurement of total hexuronic acid (Pennock, 1976)

Reagents:

- (a) CPC reagent: 100 g of cetylpyridinium chloride was dissolved in 1.0 l of deionised water and stored at room temperature.
- (b) Potassium acetate in ethanol : 10 g of potassium acetate was dissolved in 1.0 l of absolute ethanol.
- (c) Borate-sulphuric acid reagent : 9.5 g of sodium tetraborate decahydrate (AR) was dissolved in 1.0 l of concentrated sulphuric acid (AR).
- (d) Carbazole reagent : 0.125 g of carbazole was dissolved in 100 ml of 95% ethanol (AR).
- (e) Hexuronic acid standards : glucuronolactone was dissolved in a solution containing 3.0 g of benzoic acid per 100 ml to give final concentrations of 100, 60, 40 and 20 mg/l.

Method:

- (i) Isolation of mucopolysaccharides
 - (a) 5.0 ml of sample was mixed with 0.2 ml of CPC reagent and allowed to stand for 24 hours at 4°C.

- (b) The sample was centrifuged for 15 minutes at 3,000 rev/min and the supernatant discarded.
 - (c) 5.0 ml of potassium acetate in ethanol was added to the precipitate, mixed well and allowed to stand for 24 hours at 4^oC.
 - (d) The sample was centrifuged at 3,000 rev/min for 15 minutes, the supernatant discarded and the tube inverted onto filter paper to drain.
 - (e) 1.0 ml of deionised water was added to dissolve the precipitate and the sample mixed well. After centrifuging the supernatant was used for hexuronic acid assay.
- (ii) Hexuronic acid assay
- (a) 0.4 ml of sample was placed in a heat resistant test tube.
 - (b) 0.4 ml of carbazole reagent was added.
 - (c) 4.0 ml of cold borate-sulphuric acid reagent was added.
 - (d) The samples were mixed for 15 seconds using a vortex mixer and each test tube was covered with foil.
 - (e) Water blanks and standards were prepared in the same way.
 - (f) The tubes were transferred to a vigorously boiling water bath (containing deionised water) for 7 - 10 minutes.

- (g) After removal from the water bath, samples were cooled to room temperature and absorbance at 530 nm recorded.
- (h) The concentration of hexuronic acid/l was calculated from the prepared standard curve.

4. Patterns of excretion of the macromolecular and micro-molecular urinary mucopolysaccharides (from Hurst et al. 1976)

Reagents:

- (a) Sephadex G-25 medium was used to pack a Pharmacia column, 2.6 cm x 35 cm (volume 186 ml).
- (b) Sodium chloride : 1.0 gm of sodium chloride (AR) was dissolved in 1.0 l of distilled water.
- (c) Hexuronic acid assay reagents as before.

Method:

- (a) 2.0 ml from a centrifuged sample of urine was diluted to 4.0 ml with distilled water, and applied to the gel bed.
- (b) The column was eluted with 1 M NaCl by gravity flow and 110 aliquots containing 32 drops in each were collected.
- (c) The column was washed after each sample with 200 ml 1 M NaCl, and after every fourth sample with 200 ml distilled water to dislodge pigments which had collected.
- (d) Hexuronic acid analysis as previously described was performed on every second aliquot between tube numbers 20-110.

RESULTS

The weight, and volume of urine collected from each animal is recorded in Table 5.I.

TABLE 5.I

Cattle weight and volume of urine collected
for biochemical analyses

Animal	Weight (kg)	Urine volume		
		Day 1 (ml)	Day 2 (ml)	
Dwarf	D25	145	3,000	3,350
	D26	149	2,050	2,240
	D27	139	2,900	3,050
Normal	N12	237	3,400	4,050
	N13	225	3,790	4,890
	N14	199	3,780	5,050

1. The CPC citrate turbidity test

The CPC units, representing precipitated glycosaminoglycans, excreted in the urine from each animal are recorded in Table 5.II.

They are expressed in terms of the volume of urine excreted, the amount of creatinine excreted in the urine, the bodyweight of the animal, and also as a total for each day.

TABLE 5.II

Excretion of CPC units, representing precipitated glycosaminoglycans
excreted by dwarf and normal animals

Animal	Day	E 680 nm	CPC units/l	g/l Cr.*	CPC units/g Cr.	CPC units/day	CPC units/kg B.Wt.**/day
D25	(1)	1.21	67.2	0.9	78.2	201.7	1.4
	(2)	0.845	46.9	0.9	55.2	157.3	1.1
D26	(1)	1.38	76.7	0.9	90.2	171.7	1.2
	(2)	1.09	60.6	1.5	39.3	124.1	0.8
D27	(1)	1.28	71.1	0.7	103.1	216.9	1.6
	(2)	1.29	71.7	0.8	90.7	207.8	1.5
Mean			65.7	0.95	76.1	180.1	1.3
N12	(1)	1.28	75.6	1.4	52.3	241.8	1.0
	(2)	1.055	52.8	1.1	53.8	237.4	1.0
N13	(1)	1.195	66.4	0.9	70.6	251.6	1.1
	(2)	1.235	68.6	0.9	75.4	335.5	1.5
N14	(1)	1.36	71.1	0.9	86.8	285.6	1.4
	(2)	0.95	58.6	0.4	122.7	266.5	1.3
Mean			65.5	0.93	76.9	269.9	1.2

*Cr. : Creatinine

**B.wt. : Body weight

There was no difference between dwarf and normal animals in the average values obtained for the CPC units/1 of urine; CPC units/day/kg/B.wt.; or CPC units/g Cr./1. In terms of total CPC units/day excreted, the dwarf value was 67% that recorded for control animals.

2. Urinary mucopolysaccharides measured as hexuronic acid

The amount of hexuronic acid excreted in the urine and expressed in terms of the volume of urine excreted, the amount of creatinine excreted in the urine, the body-weight of the animal, and as a total for the day, is recorded in Table 5.III.

The mean total hexuronic acid excreted/day by the dwarf animals as determined by this method was only half that excreted by normal animals. When corrections were made for body weight and the volume of urine excreted, the dwarf animals still excreted only 70% - 75% of the total hexuronic acid compared with normal animals.

3. Patterns of excretion of urinary mucopolysaccharides

The hexuronic acid in each alliquot assayed for the six animals is shown as a profile in Fig. 5.1. There was no essential difference between the profiles of the normal animals and those of the dwarfs. High molecular weight mucopolysaccharides were represented by a number of small peaks up to tube No.54, whilst lower molecular weight mucopolysaccharides occurred from this tube on, with a major peak occurring constantly around tube No.68, and smaller peaks between tubes No.84-94.

TABLE 5.III

Total hexuronic acid excretion in the urine
from dwarf and normal animals

Animal	Day	Average E 530	mg Hex.* ac./1	mg Hex. ac. /g Cr.	mg Hex. ac. /day	mg Hex. ac./day /kg B.Wt.
D25	(1)	0.21	21	23.3	63	0.43
	(2)	0.14	14.5	16.1	48.6	0.33
D26	(1)	0.36	34	37.8	69.7	0.47
	(2)	0.27	35.3	16.9	56.7	0.38
D27	(1)	0.36	34	48.6	98.6	0.71
	(2)	0.39	37	46.3	112.9	0.81
Mean			27.6	31.5	74.9	0.52
N12	(1)	0.4	38	27.1	129.2	0.55
	(2)	0.35	33	30.0	133.7	0.56
N13	(1)	0.46	42.5	47.2	161.1	0.72
	(2)	0.52	48	53.3	234.7	1.04
N14	(1)	0.34	32	35.6	121.0	0.61
	(2)	0.32	30	75.0	151.5	0.76
Mean			37.3	44.7	155.2	0.71

*Hex. ac. : Hexuronic acid

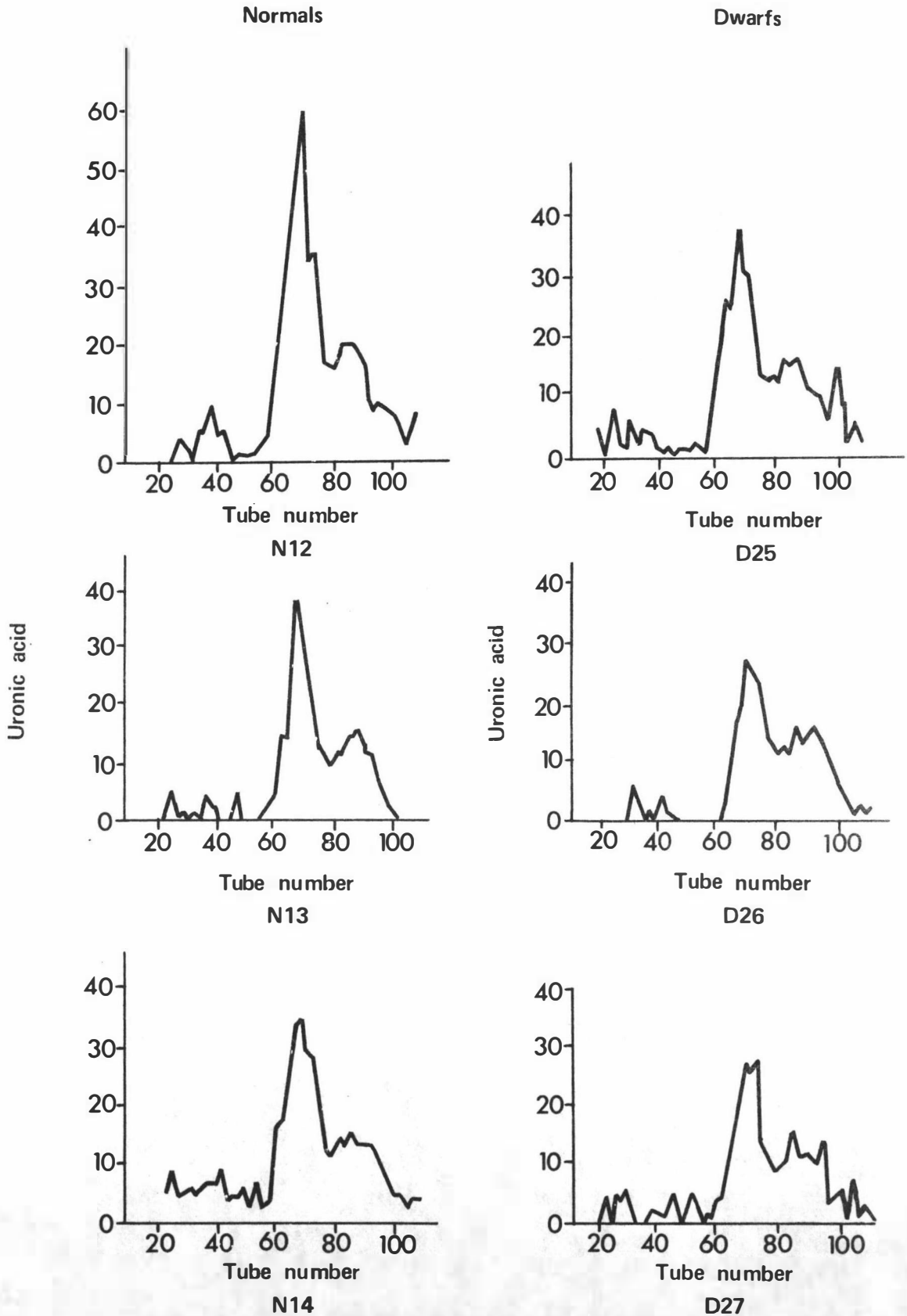


FIGURE 5.1 PROFILES OF MUCOPOLYSACCHARIDES EXCRETED IN THE URINE OF 3 NORMAL AND 3 DWARF CATTLE

DISCUSSION

The difference in mucopolysaccharide excretion levels found between dwarf and normal cattle by Lorincz could perhaps be explained by age differences. The age of the cattle used in his experiments was not clearly stated and they may not have been closely matched. In humans, excretion rates of newborn infants are high even in the normal child, but these drop over the first year of life, and a similar decrease in levels has been shown in cattle (Mayes et al. 1964). For this reason the cattle used in this present project were matched for age and sex, and also diet.

The results from this experiment showed that the Hereford dwarf in New Zealand did not excrete larger amounts of mucopolysaccharide than normal cattle. In fact estimation of hexuronic acid after precipitation by cetylpyridinium chloride was found to be lower in the dwarf cattle than in the controls. The reason for this is not certain, although Hurst et al. (1976) state that precipitation of mucopolysaccharides by CPC decreases where the creatinine concentration is greater than 0.8 mg/ml. Creatinine levels in most of the urine samples analysed were in fact higher than this, and perhaps this may account for the discrepancy.

It has been suggested (Rimoin, 1975) that in achondroplasia in humans the defect is a change in the rate of growth of cells. If the cells are sluggish, a decreased output of mucopolysaccharide levels in the urine could perhaps be expected. Mucopolysaccharide excretion levels in human achondroplasia have been found to be normal (Ponseti, 1970).

The CPC citrate turbidity test when related to urine volume, creatinine in the urine, or bodyweight of the animal showed very similar results between dwarf and normal animals. Only in terms of the total amount excreted/day was there a difference, and in this case the dwarf animals excreted less than normal animals. This result would be expected in view of the smaller volume of urine excreted/day by the dwarfs.

The fact that the disease of brachycephalic dwarfism as seen in Hereford cattle in New Zealand does not represent a mucopolysaccharidosis is further confirmed by the profile patterns of excretion of urinary mucopolysaccharides which are essentially the same for both dwarf and normal animals. Gel filtration provides a means of complete separation of low from high molecular weight compounds, and the uronic acid determination on the fractions collected gives a measure of the total glycosaminoglycans present. This third test is thus probably the most accurate of all the tests used. In cases of human mucopolysaccharidoses the uronic acid determined in the macromolecular fractions is approximately 10 times that for normal urine (Hurst et al. 1976). In this present study there were variations in the number of peaks within both fractions but there was no evidence of an obvious increase in the macromolecular fraction in the dwarf cattle. This variation in peak number may have been due in part to trouble experienced with a blue green colouration which occurred in some samples (both dwarf and normal) particularly if the tubes were not securely capped. This occurred even though deionised water was used in the water bath, and could perhaps have been due to impurities in the air.

These results are thus in accord with the light and electron microscopic studies (Chapter IV) in which no lesions typical of a mucopolysaccharide storage disease were found.

CHAPTER VI

GENERAL DISCUSSION

Dwarfism in Hereford cattle is an inherited defect characterised by a shortening of most skeletal measurements of length relative to width, a bulging forehead, brachycephalic head, and reduced viability. It results in economic loss through reduced reproductive potential and reduced or nil carcass return. Perhaps more important than this direct loss from affected calves, is the reduced carcass value of carrier animals. They are much more numerous than dwarfs and may be up to ten percent smaller than normal animals.

While this disease of cattle has been likened to achondroplasia in humans it is clear it is different inasmuch as the mode of inheritance differs. The results from matings carried out in this project confirm earlier reports that it is inherited as an autosomal recessive, and examination of foetuses from dwarf x dwarf matings compared with that from a carrier x carrier mating, also indicate that a recessive gene is responsible for the disease. In humans, achondroplasia results from a dominant gene, the majority of cases being new mutations, and dwarf x dwarf matings result in an offspring which is more severely dwarfed than a heterozygous individual.

The anatomical measurements of dwarf cattle made in this present study are very similar to those reported from the United States of America. As it is believed that the dwarfism gene came into New Zealand with four sires which were imported in the 1950s, the dwarfs which occur in the Hereford breed here in New Zealand probably represent the same

mutation as the most common form of dwarfism in the United States of America. While there was some variability in the expression of the disease between cattle, such a variation in phenotype is not uncommon with inherited diseases because of the possibility of a gene having a pleiotropic effect.

The histological appearance of the epiphyseal plate corresponded well with descriptions published of the epiphyseal plate in achondroplasia in humans. There was generally a shortening in length of columns of proliferating cells, with fewer hypertrophied cells in the dwarf tissue. The cells appeared smaller than normal and capillary ingrowth was less regular than in normal tissue. However, the changes are not so marked that the disease can be immediately recognised from examination of a histological section. Apart from the dilated endoplasmic reticulum, whose significance is uncertain, electron microscopy of dwarf cartilage appeared normal. The increase in material within the endoplasmic reticulum may suggest some slowing down of the cell's processes, either in utilising the material synthesised, or in processing it further. This increased material within the endoplasmic reticulum may be correlated with the increased red-purple staining material noted within some dwarf chondrocytes in the epoxy resin sections stained with toluidine blue.

The underlying molecular pathology of dwarfism in Hereford cattle is yet to be established. While no hormone assays were conducted in this present study, reports in the literature indicate that the aetiology of the disease is not

related to any variations from normal in hormone levels. Cytogenetic studies have not revealed any chromosome abnormalities, nor would any be expected with a simple autosomal recessive disease. Any chromosomal change discernible by light microscopy is unlikely to affect just a single gene, and therefore a defect such as this is probably not the cause of this disease. From the biochemical analyses and histopathology of this form of dwarfism there is no evidence that this disease is an example of a mucopolysaccharide storage disease, as has been previously suggested.

Examination of collagen fibres by electron microscopy showed a normal appearance. However, technology for biochemical analysis of collagen is continually being developed, and it is quite possible that there may be a biochemical abnormality of collagen which may be demonstrated as an enzymopathy or an altered gene product.

This project has achieved the definition of the Hereford dwarf as it occurs in New Zealand, and the histopathology of the disease has been more completely described than previously. Although the underlying pathogenesis has not been defined biochemically so that no simple test for heterozygosity has been developed, limited experience during the course of this work confirms that use of the profilometer may be of help in detecting bulls most likely to be heterozygous in problem herds. The ability to recognise a dwarf foetus as early as 3 to 4 months, coupled with the present ability to abort cattle at this stage with prostaglandins has shortened the time required for progeny testing a bull

and made this a more useful procedure. Detection of possible carrier cattle by radiographic analysis of lumbar vertebrae does not appear to be worthwhile.

REFERENCES

- Anderson, H.C.; Sajdera, S.W.; (1971); The fine structure of bovine nasal cartilage. J. Cell Biol. 49: 650-663.
- Andresen, E.; Willeberg, P.; Rasmussen, P.G.; (1974): Pituitary dwarfism in German Shepherd dogs: genetic investigations. Nord. VetMed. 26: 692-701.
- Andrews, F.N.; Fransen, J.M.; (1958): Effects of endocrine therapy on the growth of dwarf beef cattle: Am.J.vet.Res. 19: 822-824.
- Arthaud, R.L.; Koch, R.M.; Arthaud, V.H.; (1957): Anatomical measurements as related to the snorter dwarf gene in Hereford calves. J.Anim.Sci. 16: 1028 (Abstr.).
- Baker, M.L.; Blunn, C.T.; Oulafa, M.M.; (1950): Stumpy, a recessive achondroplasia in Shorthorn cattle. J.Hered. 41: 243-245.
- Baker, M.L.; Blunn, C.T.; Plum, M.; (1951): Dwarfism in Aberdeen Angus cattle. J.Hered. 42: 141-143.
- Bauer, J.D.; Ackerman, P.G.; Toro, G.; (1968): Clinical chemistry. p.314-316. In: Bray's clinical laboratory methods. 7th ed. The C.V. Mosby Company.
- Bloom, W.; Fawcett, D.W.; (1962): Bone. p.153-186. In: A Textbook of Histology. W.B. Saunders Company, Philadelphia, London.
- Bolin, F.M.; Buchanan, M.S.; Shumard, R.F.; Eveleth, D.F.; (1957): Abortion of foetuses exhibiting evidence of dwarfism. Vet.Med. 52: 327-328.
- Bone, J.F.; (1963): Dwarfism in cattle. Mod.vet.Pract. 44: 37-40.
- Bonucci, E.; Del Marco, A.; Nicoletti, B.; Petrinelli, P.; Pozzi, L.; (1976): Histological and histochemical investigations of achondroplastic mice: a possible model of human achondroplasia. Growth 40: 241-251.
- Bonucci, E.; Gherardi, G.; Del Marco, A.; Nicoletti, B.; Petrinelli, P.; (1977): An electron microscope investigation of cartilage and bone in achondroplastic (cn/cn) mice. J.Submic.Cytol. 9: 299-306.

- Bornstein, P.; (1974): Disorders of connective tissues. P.881-984. In: Duncan's Diseases of Metabolism. 7th ed. W.B. Saunders Company.
- Bovard, K.P.; Hazel, L.N.; (1963): Growth patterns in snorter dwarf and normal Hereford calves. J.Anim.Sci. 22: 188-196.
- Bowden, D.M.; (1970): Achondroplasia in Holstein-Friesian cattle. J.Hered. 61: 163-164.
- Braund, K.G.; Ghosh, P.; Taylor, T.K.F.; Larsen, L.H.; (1975): Morphological studies of the canine intervertebral disc. The assignment of the beagle to the achondroplastic classification. Res.vet.Sci. 19: 167-172.
- Braund, K.G.; Ghosh, P.; Taylor, T.K.F.; Larsen, L.H.; (1976): The qualitative assessment of glycosaminoglycans in the canine intervertebral disc using a critical electrolyte concentration staining technique. Res.vet.Sci. 21: 314-317.
- Brown, R.G.; Hoag, G.N.; Smart, M.E.; Boechner, G.; Subden, R.E.; (1977a): Alaskan Malamute chondrodysplasia IV. Concentrations of zinc, copper, and iron in various tissues. Growth 41: 215-220.
- Brown, R.G.; Hoag, G.N.; Subden, R.E.; Smart, M.E.; (1977b): Alaskan Malamute chondrodysplasia III. Connective tissue of bone. Growth 41: 207-214.
- Bruere, A.N.; (1969): Dwarfism in beef cattle: Diagnosis and control. N.Z.vet.J. 17: 205-209.
- Burris, M.J.; Priode, B.M.; (1956): Crossbred dwarfs in beef cattle. J.Hered. 47: 245-247.
- Caffey, J.; (1958): Achondroplasia of pelvis and lumbo-sacral spine. Am.J.Roentg.Radium Ther.Nucl.Med. 80: 449-457.
- Carroll, F.D.; Gregory, P.W.; Rollins, W.C.; (1951): Thyrotropic hormone deficiency in homozygous dwarf beef cattle. J.Anim.Sci. 10: 916-921.
- Chang, T.K.; (1949a): Morphological study on the skeleton of Ancon sheep. Growth 13: 269-297.
- Chang, T.K.; (1949b): Skeletal growth in Ancon sheep. Growth 13: 221-267.

- Collipp, P.J.; Sharma, R.K.; Thomas, J.; Maddaiah, V.T.; Chen, S.Y.; (1972): Abnormal glucose tolerance in children with achondroplasia. Am.J.Dis.Child. 124: 682-685.
- Cooper, R.R.; Ponseti, I.V.; Maynard, J.A.; (1973a): Pseudoachondroplastic dwarfism. A rough surfaced endoplasmic reticulum storage disorder. J.Bone Jt Surg. 55-A: 475-484.
- Cooper, R.R.; Pedrini-Mille, A.; Ponseti, I.V.; (1973b): Metaphyseal dysostosis. A rough surfaced endoplasmic reticulum storage defect. Lab.Invest. 28: 119-125.
- Cornelius, C.E.; Tyler, W.S.; Gregory, P.W.; (1956): Chemical and haematological studies on blood of bovine dwarfs. Proc.Soc.exp.Biol.Med. 92: 522-524.
- Cowell, K.R.; Jezyk, P.F.; Haskins, M.E.; Patterson, D.F.; (1976): Mucopolysaccharidosis in a cat. J.Am.vet.med.Ass. 169: 334-339.
- Crew, F.A.E.; (1924): The bull-dog calf: A contribution to the study of achondroplasia. Proc.R.Soc.Med. 17: 39.
- Dellman, H.D.; (1971): Connective and supporting tissues. p.33-53. In: Veterinary Histology. Lea and Febiger, Philadelphia.
- Deyoe, C.W.; Shrode, M.C.; Banks, W.C.; Kunkel, H.O.; (1957): Quantitative chemical and granulocytic changes in insulin induced stress in mature dwarf bovine and heterozygote females. J.Anim.Sci. 16: 1029(Abstr.).
- Di Ferrante, N.; Rich, C.; (1956): The determination of acid aminopolysaccharide in urine. J.Lab.clin.Med. 48: 491-494.
- Dinkel, C.A.; Minyard, J.A.; Jones, W.C.; (1960): Radiographic and electrocardiographic studies of the bovine heart in relation to dwarfism. J.Anim.Sci. 19: 948-955.
- Dollahon, J.C.; Koger, M.; Hentges, J.F.; Warnick, A.C.; (1957): The expression of various forms of dwarfism in certain crosses and heterogeneous genetic backgrounds in beef cattle, J.Anim.Sci. 16: 1029(Abstr.).

- Dollahon, J.C. Owens, K.G.; Koger, M.; Kentges, J.F.;
Warnick, A.C.; (1959): Cerebrospinal fluid pressures
of snorter dwarf carrier and non-carrier cattle.
J.Am.vet.med.Ass. 135: 109-111.
- Dorfman, A.; Matalon, R.; (1976): The mucopolysaccharidoses
(A review). Proc.natn.Acad.Sci.U.S.A. 73: 630-637.
- Duffel, S.J.; (1977): Chondrodystrophy in lambs. Vet.Rec.
100: 319.
- Emmerson, M.A.; Hazel, L.N.; (1956): Radiographic demonstration
of dwarf gene-carrier beef animals. J.Am.vet.med.Ass.
128: 381-390.
- Evans, H.E.; Sack, W.O.; (1973): Prenatal development of
domestic and laboratory mammals. Anat.Histol.Embryol. 2:
11-45.
- Eveleth, D.F.; Bolin, F.M.; Buchanan, M.L.; (1956): Abnormal
shape of the heart of dwarf cattle. Vet.Med. 51: 495.
- Felson, B.; (1973): Dwarfs and other little people.
Seminars in Roentgenology B: No.2.
- Fletch, S.M.; Pinkerton, P.H.; (1972): An inherited anaemia
associated with hereditary chondrodysplasia in the
Alaskan Malamute. Can.vet.J. 13: 270-271.
- Fletch, S.M.; Smart, M.E.; Pennock, P.W.; Subden, R.E.; (1973):
Clinical and pathologic features of chondrodysplasia
(dwarfism) in the Alaskan Malamute. J.Am.vet.med.Ass.
162: 357-361.
- Foley, C.W.; Massey, J.W.; Lasley, J.F.; (1956): Variations
in the physiological response to stress in dwarf and
normal beef cattle. J.Anim.Sci. 15: 1217(Abstr.).
- Foley, C.W.; Lasley, J.F.; (1959): The effect of the dwarf
gene on carbohydrate metabolism in beef cattle.
J.Anim.Sci. 18: 1460(Abstr.).
- Fox, R.R.; Crary, D.D.; (1975): Hereditary chondrodystrophy
in the rabbit. J.Hered. 66: 271-276.
- Fransen, J.M.; Andrews, F.N.; (1954): The physiology of
dwarfism in beef cattle. J.Anim.Sci. 13: 1020.
- Fransen, J.M.; Andrews, F.N.; (1958): Blood plasma cholesterol
levels in normal and dwarf beef cattle. Am.J.vet.Res.
19: 332-335.

- Fransen, J.M.; Andrews, F.N.; (1958a): Blood plasma cholesterol levels in normal and dwarf beef cattle. Am.J.vet.Res. 19: 332-335.
- Fransen, J.M.; Andrews, F.N.; (1958b): Cerebrospinal fluid pressure in dwarf and normal cattle. Am.J.vet.Res. 19: 336-337.
- Gardner, D.L.; (1959): Familial canine chondrodystrophia foetalis (Achondroplasia). J.Path.Bact. 77: 243-247.
- Gardner, R.J.M.; (1977): A new estimate of the achondroplasia mutation rate. Clin.Genet. 11: 31-38.
- Gething, M.A.; (1972): Suspected Ehlers-Danlos syndrome in the dog. Vet.Rec. 90: 347.
- Gluhovschi, N.; Bistriceanu, M.; Palicica, R.; Codreanu, N.; Marschang, F.; Bratu, M.; (1972): A contribution to the clinical and cytogenetic study of bovine dwarfism. Vet.Med.Rev. No.2: 107-115.
- Godman, G.C.; Porter, K.R.; (1960): Chondrogenesis, studied with the electron microscope. J.biophys.biochem.Cytol. 8: 719-759.
- Godman, G.C.; Lane, N.; (1964): On the site of sulphation in the chondrocyte. J.Cell Biol. 21: 353-366.
- Goel, S.C.; (1970): Electron microscopic studies on developing cartilage I. The membrane system related to the synthesis and secretion of extracellular materials. J.Embryol.exp.Morph. 23: 169-184.
- Goel, S.C.; Jurand, A.; (1972): Electron microscopic studies on developing cartilage II. Demonstration and distribution of glycogen in chick and mouse epiphyseal cartilage. J.Embryol.exp.Morph. 28: 153-162.
- Gregory, P.W.; Mead, S.W.; Regan, W.M.; (1942): A new type of recessive achondroplasia in cattle. J.Hered. 33: 317-322.
- Gregory, P.W.; Rollins, W.C.; Pattengale, P.S.; Carroll, F.D.; (1951): A phenotypic expression of homozygous dwarfism in beef cattle. J.Anim.Sci. 10: 922-933.
- Gregory, P.W.; Brown, B.B.; (1952): A profilometer for studying head form of the bovine. J.Anim.Sci. 11: 700-704.

- Gregory, P.W.; Roubicek, C.B.; Carroll, F.D.; Stratton, P.O.; Hilston, N.W.; (1953): Inheritance of bovine dwarfism and the detection of heterozygotes. Hilgardia 22: 407-450.
- Gregory, P.W.; (1955): The genetic relationships of phenotypically different bovine dwarfs. J.Anim.Sci. 14: 1182-1183(Abstr.).
- Gregory, P.W.; (1956): Phenotypic forms and genetic relationships of the bovine dwarf complex. J.Anim.Sci. 15: 1207(Abstr.).
- Gregory, P.W.; Carroll, F.D.; (1956): Evidence for the same dwarf gene in Hereford, Aberdeen Angus and certain other breeds of cattle. J.Hered. 47: 106-111.
- Gregory, P.W.; Julian, L.M.; Tyler, W.S.; (1957): The validity of dwarf-carrier cows as testers for the major dwarf conditioning gene. J.Anim.Sci. 16: 1028(Abstr.).
- Gregory, P.W.; Julian, L.M.; Tyler, W.S.; (1964): Bovine achondroplasia; the progeny test. Growth 28: 191-212.
- Gregory, P.W.; Tyler, W.S.; Julian, L.M.; (1966): Bovine achondroplasia: the reconstitution of the Dexter components from non Dexter stocks. Growth 30: 393-418.
- Gregory, P.W.; Julian, L.M.; Tyler, W.S.; (1967): Bovine achondroplasia: possible reconstitution of the Telemark lethal. J.Hered. 58: 220-224.
- Gruneberg, H.; (1963): Systemic disorders of the cartilaginous skeleton. In: The Pathology of Development. p52-73.
- Hafez, E.S.E.; Ensminger, M.E.; Ham, W.E.; (1959): Morphological and physio-chemical studies on dwarf Herefords. J.Agr.Sci. 53: 339-346.
- Hafez, E.S.; Rupnow, E.H.; (1960): Proportionality of organ development in osteodystrophic dwarf beef cattle. J.Agric.Sci. 55: 351-358.
- Hazel, L.N.; Emerson, M.A.; Bovard, K.P.; (1956): Radiographic examination of lumbar vertebrae as a method of detecting carriers of the snorter dwarf gene. J.Anim.Sci. 15: 1213(Abstr.).

- Hegreberg, G.A.; Norby, D.E.; Hamilton, M.J.; (1974):
Lysosomal enzyme changes in an inherited dwarfism of
cats. Fed.Proc. 33: 2189.
- Hegreberg, G.A.; (1975): Animal model of human disease
Ehlers-Danlos syndrome. Am.J.Path. 79: 383-386.
- High, J.W.; Smith, H.J.; Kincaid, C.M.; Hobbs C.S.; (1959):
Evaluation of the X-ray method of detecting animals
heterozygous for snorter dwarfism. J.Anim.Sci. 18:
1438-1447.
- Hoag, G.N.; Brown, R.G.; Smart, M.E.; Subden, R.E.; (1976a):
Alaskan Malamute chondrodysplasia I. Bone composition
studies. Growth 40: 3-11.
- Hoag, G.N.; Brown, R.G.; Smart, M.E.; Subden, R.E.; (1976b):
Alaskan Malamute chondrodysplasia II. Urinary excretion
of hydroxyproline, uronic acid and acid mucopolysaccharides.
Growth 40: 13-18.
- Hurst, R.E.; Cezayirli, R.C.; Lorincz, A.E.; (1975): Nature
of the glycosaminoglycanuria (mucopolysacchariduria) in
brachycephalic 'snorter' dwarf cattle. J.Comp.Path. 85:
481-486.
- Hurst, R.E.; Settine, J.M.; Lorincz, A.E.; (1976): A method
for the quantitative determination of urinary glycos-
aminoglycans. Clin.chim.Acta 70: 427-432.
- Jezyk, P.F.; Haskins, M.E.; Patterson, D.F.; Mellman, W.J.;
Greenstein, M.; (1977): Mucopolysaccharidosis in a cat
with arylsulfatase B deficiency: a model of Maroteaux-
Lamy syndrome. Science: 198: 834-836.
- Johansson, I.; (1953): A new type of achondroplasia in
cattle. Hereditas 39: 75-87.
- Johnson, L.E.; Harshfield, G.S.; McCone, W.; (1950): Dwarfism:
An hereditary defect in beef cattle. J.Hered. 41: 177-181.
- Johnson, D.R.; Wise, J.M.; (1971): Cartilage anomaly (can);
a new mutant gene in the mouse. J.Embryol.exp.Morph. 25:
21-31.
- Johnson, D.R.; (1977): Ultrastructural observations on stumpy
(stm), a new chondrodystrophic mutant in the mouse.
J.Embryol.exp.Morph. 39: 279-284.

- Jubb, K.V.; McEntee, K.; (1955): Observations on the bovine pituitary gland. Cornell Vet. 45: 593-641.
- Julian, L.M.; Tyler, W.S.; Gregory, P.W.; (1956): Systematic studies on the anatomical expression of bovine dwarfism. J.Anim.Sci. 15: 1208(Abstr.).
- Julian, L.M.; Tyler, W.S.; Hage, T.J.; Gregory, P.W.; (1957): Premature closure of the spheno-occipital synchondrosis in the horned Hereford dwarf of the 'short-headed' variety. Am.J.Anat. 100: 269-287.
- Kivirikko, K.I.; Risteli, L.; (1976): Biosynthesis of collagen and its alterations in pathological states. Med.Biol. 54: 159-186.
- Koger, M.; Dollahon, J.C.; Warnick, A.C.; Kirk, W.G.; Hentges, J.F.; Palmer, A.Z.; (1955): Forms of dwarfism in English and Brahman breeds of beef cattle. J.Anim.Sci. 14: 1186(Abstr.).
- Langer, L.O.; Baumann, P.A.; Gorlin, R.J.; (1967): Achondroplasia. Am.J.Roentg. 100: 12-26.
- Leuchtenberger, C.; Schrader, F.; Hughes-Schrader, S.; Gregory, P.W.; (1956): Certain cytochemical and cytological aspects of dwarfism in cattle. J.Morph. 99: 481-512.
- Lindley, C.E.; (1951): Observations on midgets in beef cattle. J.Hered. 42: 273-275.
- Lindsay, F.E.F.; (1969): Observations on the loci of ossification in the prenatal and neonatal bovine skeleton. 1. The appendicular skeleton. Br.vet.J. 125: 101-110.
- Lorincz, A.E. (1960): 'Snorter' dwarf cattle: a naturally occurring heritable disorder of acid mucopolysaccharide metabolism which resembles the Hurler syndrome. Am.J.Dis.Child. 100: 488-489.
- Lorincz, A.E.; (1961): Heritable disorders of acid mucopolysaccharide metabolism in humans and in snorter dwarf cattle. Ann.N.Y.Acad.Sci. 91: 644-658.
- Lorincz, A.E.; (1964): Hurler's syndrome in man and snorter dwarfism in cattle. Clin.Orthop. 33: 104-118.

- McCann, L.P.; (1974): The battle of bull runts. Columbus, Ohio. 176p.
- McIlwain, P.; Eveleth, D.F.; (1962): Urinary mucopolysaccharides of dwarf cattle. Vet.Med. 57: 508.
- Marlowe, T.J.; Chambers, D.; (1954): Some endocrine aspects of dwarfism in beef cattle. J.Anim.Sci. 13: 961(Abstr.).
- Marlowe, T.J.; (1960): A comparison of the growth hormone content of the pituitary glands from dwarf and normal beef calves. J.Anim.Sci. 19: 811-819.
- Marlowe, T.J.; (1964): Evidence of selection for the snorter dwarf gene in cattle. J.Anim.Sci. 23: 454-460.
- Matukas, V.J.; Panner, B.J.; Orbison, J.L.; (1967): Studies on ultrastructural identification and distribution of protein-polysaccharide in cartilage matrix. J.Cell Biol. 32: 365-377.
- Mayes, J.S.; Hansen, R.G.; Gregory, P.W.; Tyler, W.S.; (1964): Mucopolysaccharide excretion in dwarf and normal cattle. J.Anim.Sci. 23: 833-837.
- Mead, S.W.; Gregory, P.W.; Regan, W.M.; (1942): Proportionate dwarfism in Jersey cows. J.Hered. 33: 411-416.
- Miller, W.A.; Flynn-Miller, K.L.; (1976): Achondroplastic, brachymorphic and stubby chondrodystrophies in mice. J.Comp.Path. 86: 349-363.
- Mohr, O.L. (1926) "Über letalfaktoren, mit berücksichtigung ihres verhaltens bei haustierne and beim menschen." Z.indukt.Abstamm.-u. VererbLehre. 41. (Cited by Gregory et al, 1967).
- Neufeld, E.F.; Lim, T.W.; Shapiro, L.J.; (1975): Inherited disorders of lysosomal metabolism. Ann.Res.Bioch. 44: 357-434.
- O'Hara, P.J.; Read, W.K.; Romane, W.M.; Bridges, C.H.; (1970): A collagenous tissue dysplasia of calves. Lab.Invest. 23: 307-314.
- Orkin, R.W.; Pratt, R.M.; Martin, G.R.; (1976): Undersulphated chondroitin sulphate in the cartilage matrix of brachymorphic mice: Devl.Biol. 50: 82-94.
- Orkin, R.W.; Williams, B.R.; Cranley, R.E.; Poppke, D.C.; Brown, K.S.; (1977): Defects in the cartilaginous growth plates of brachymorphic mice. J.Cell Biol. 73: 287-299.

- Pahnish, O.F.; Stanley, E.B.; Safley, C.E.; (1955): The inheritance of a dwarf anomaly in beef cattle. J.Anim.Sci. 14: 200-207.
- Patton, J.D.; Crockett, J.R.; Gavan, J.A.; (1966): Prenatal skeletal development in the bovine. J.Anim.Sci. 25: 251(Abstr.).
- Pennock, C.A.; (1976): A review and selection of simple laboratory methods used for the study of glycosaminoglycan excretion and the diagnosis of the mucopolysaccharidoses. J.Clin.Path. 29: 111-123.
- Ponseti, I.V.; (1970): Skeletal growth in achondroplasia. J.Bone Jt Surg. 52-A: 701-716.
- Pope, F.M.; Martin, G.R.; Lichtenstein, J.R.; Penttinen, R.; Gerson, B.; Rowe, D.W.; McKusick, V.A.; (1975): Patients with Ehlers-Danlos syndrome type IV lack type III collagen. Proc.natn.Acad.Sci.U.S.A. 72: 1314-1316.
- Rankin, B.J.; Turman, E.J.; Watkins, B.J.; Chambers, D.; Stephens, D.F.; (1959): An evaluation of the X-ray method for identifying carriers of the snorter dwarf gene in beef cattle. J.Anim.Sci. 18: 1461(Abstr.).
- Rimoin, D.L.; (1974): Histopathology and ultrastructure of cartilage in the chondrodystrophies. p.1-18. In: Skeletal Dysplasias. Birth Defects: Original Article Series 10.
- Rimoin, D.L.; (1975): The chondrodystrophies. p.1-118. In: Advances in human genetics, Vol.5. Ed. Harris, H. and Hirschhorn, K.
- Rimoin, D.L.; Silberberg, R.; Hollister, D.W.; (1976): Chondro-osseous pathology in the chondrodystrophies. Clin.Orthop. No.114: 137-152.
- Rubin, P.; (1963): Achondroplasia versus pseudoachondroplasia. Radiol.Clin.N.A. 1: 621-637.
- Saldino, R.M.; (1973): Radiographic diagnosis of neonatal short-limbed dwarfism. Med.Radiogr.Photoqr. 49: 61-95.
- Sawin, P.B.; Raule M.; Crary, D.D.; (1959): Morphogenetic studies of the rabbit XXV. The spheno-occipital synchondrosis of the Dachs (chondrodystrophy) rabbit. Am.J.Anat. 105: 257-280.

- Scott, D.V.; (1974): Cutaneous asthenia in a cat, resembling Ehlers-Danlos syndrome in man. Vet.Med./S.A.C. 69: 1256-1258.
- Seegmiller, R.; Fraser, F.C.; Sheldon, H.; (1971): A new chondrodystrophic mutant in mice: electron microscopy of normal and abnormal chondrogenesis. J.Cell Biol. 48:
- Shepard, N.; Mitchell, N.; (1976): Simultaneous localisation of proteoglycan by light and electron microscopy using toluidine blue o. A study of epiphyseal cartilage. J.Histochem.Cytochem. 24: 621-629.
- Shepard, T.H.; Fry, L.R.; Moffett, B.C.; (1969): Microscopic studies of achondroplastic rabbit cartilage. Teratology 2: 13-22.
- Shepard, T.H.; (1971): Organ-culture studies of achondroplastic rabbit cartilage: evidence for a metabolic defect in glucose utilization. J.Embryol.exp.Morph. 25: 347-363.
- Siggers, D.C.; Rimoin, D.L.; Dorst, J.P.; Doty, S.B.; Williams, B.R.; Hollister, D.W.; Silberberg, R.; Cranley, R.E.; Kaufman, R.L.; McKusick V.A.; (1974): The Kniest syndrome. p.193-208. In: Skeletal Dysplasias. Birth Defects: Original Article Series 10.
- Silberberg, R.; Hasler, M.; Lesker, P.; (1976): Ultrastructure of articular cartilage of achondroplastic mice. Acta.Anat. 96: 162-175.
- Silberberg, R.; Lesker, P.; (1977): Defective endochondral ossification in brachymorphic mice. J.Comp.Path. 87: 319-323.
- Silverman, F.N.; (1968): A differential diagnosis of achondroplasia. Radiol.Clin.N.A. 6: 223-237.
- Sly, W.S.; Quinton, B.A.; McAlister, W.H.; Rimoin, D.L.; (1973): Beta glucuronidase deficiency: report of clinical, radiologic, and biochemical features of a new mucopolysaccharidosis. J.Pediat. 82: 249-257.
- Spurr, A.R.; (1969): A low-viscosity epoxy resin embedding medium for electron microscopy. Ultrastruct.Res. 26: 31-43.

- Stephens, T.D.; Seegmiller, R.E.; (1976): Normal production of cartilage glycosaminoglycan in mice homozygous for the chondrodysplasia gene. Teratology 13: 317-325.
- Stonaker, H.; Tom, R.C.; (1944): 'Compact' Shorthorns. J.Hered. 35: 247-250.
- Taylor, R.E.; Turman, E.J.; (1959): Some carbohydrate metabolism studies with dwarf and non-dwarf cattle. J.Anim.Sci. 18: 1460(Abstr.).
- Temple, R.S.; Hazel, L.N.; (1961): Use of haematological techniques in study of 'Snorter' dwarfism. J.Anim.Sci. 20: 459-463.
- Thompson, J.N.; Palmer, C.G.; Christian, J.C.; (1969): The absence of metachromasia in brachycephalic bovine dwarf cell culture. Birth Defects: Original Article Series 5: 214-215.
- Thyberg, J.; (1977): Electron microscopy of cartilage proteoglycans. Histochem.J. 9: 259-266.
- Tyler, W.S.; Julian, L.M.; Gregory, P.W.; (1956): Identification of the process responsible for the short-headed Hereford dwarf based on anatomical studies. J.Anim.Sci. 15: 1207(Abstr.).
- Tyler, W.S.; Julian, L.M.; Gregory, P.W.; (1957): The nature of the process responsible for the short-headed Hereford dwarf as revealed by gross examination of the appendicular skeleton. Am.J.Anat. 101: 477-496.
- Tyler, W.S.; Julian, L.M.; McFarland, L.S.; Evans, H.E.; Gregory, P.W.; (1959): Two projections into the cranial cavity associated with achondroplastic dwarfism in cattle. Am.J.vet.Res. 20: 702-707.
- Tyler, W.S.; Julian, L.M.; Gregory, P.W.; (1961): Bovine achondroplastic brachycephalic dwarfs and controls. Am.J.vet.Res. 22: 693-697.
- Tyler, W.S.; Gregory, P.W.; Meyer, K.; (1962): Sulphated mucopolysaccharides of urine from brachycephalic bovine dwarfs. Am.J.vet.Res. 23: 1109-1110.

Willeberg, P.; Kastrup, K.W.; Andresen, E.; (1975):

Pituitary dwarfism in German Shepherd dogs: studies on somatomedin activity. Nord.VetMed. 27: 448-454.

Xallahan, W.P.; Lorincz, A.E.; (1967): Hepatic ultrastructure in foetal snorter dwarf cattle. Anat.Rec. 157: 352-353.