



Bone sequestrum in a yearling red deer (*Cervus elaphus*) hind in New Zealand

KE Lawrence, C Balcomb, KJ Flay & L Whitfield

To cite this article: KE Lawrence, C Balcomb, KJ Flay & L Whitfield (2022) Bone sequestrum in a yearling red deer (*Cervus elaphus*) hind in New Zealand, *New Zealand Veterinary Journal*, 70:5, 297-299, DOI: [10.1080/00480169.2022.2073919](https://doi.org/10.1080/00480169.2022.2073919)

To link to this article: <https://doi.org/10.1080/00480169.2022.2073919>



Published online: 19 May 2022.



Submit your article to this journal [↗](#)



Article views: 80



View related articles [↗](#)



View Crossmark data [↗](#)

Bone sequestrum in a yearling red deer (*Cervus elaphus*) hind in New Zealand

Osseous sequestration is a common orthopaedic condition of horses and cattle (Firth 1987), and is frequently associated with trauma that results in cortical ischemia and bacterial invasion (Huber 2011). Although deer were introduced into New Zealand in the nineteenth century (Husheer *et al.* 2003), commercial deer farming itself only became legal in New Zealand in 1969 following the introduction of the New Zealand government's Noxious Animals Amendment Act 1967 and the Deer Farming Regulations 1969 (Challies 1991). Interest in deer farming increased rapidly in the early 1970s (Pollard and Wilson 2002), with exports of venison, antler, and by-products now worth around NZD\$240 million for the year ended September 2020 (B+LNZ 2021). Most of the deer farmed in New Zealand are *Cervus elaphus*, including the European red deer, North American wapiti, and their hybrids, with a smaller number of fallow deer (*Dama dama*) also farmed (Mason 1994).

There have been a small number of reports of musculoskeletal problems in New Zealand deer including fractures (Wilson 1981; Audigé *et al.* 2001), osteochondrosis secondary to copper deficiency (Thompson *et al.* 1994; Audigé *et al.* 1995), angular limb deformities (Beatson *et al.* 2011), epiphysitis and osteomyelitis (Badger 1982), foot abscesses (Wilson 1981), polydactyly in red and sika deer (Daniel 1967; Davidson 1971) and outbreaks of lameness associated with *Bacteroides nodosus* (Skerman 1983) and *Fusobacterium necrophorum* (Ingram and Gill 2010). However, there have been no reports of bone sequestra in deer in New Zealand, and a literature search conducted using the search terms "deer AND sequestrum AND lameness" in Web of Science on 12 January 2022, found no further results from overseas.

On 13 August 2021 a rising 1-year-old (R1) red deer hind weighing 86 kg with a body condition score (BCS) of 2.5/5 presented with severe lameness of the right rear leg. The hind was part of a group of 55 weaned R1 deer, grazing at pasture. Examination of the leg identified a soft, painful swelling on the medial aspect of the metatarsal bone, mid-way between the hock and fetlock. The swelling was not freely movable and seemed adherent to the underlying bone, no crepitus or mobility was noticed on palpation or manipulation of the metatarsus. Differential diagnoses included osteomyelitis with or without bone sequestration, incomplete fracture, and neoplasia although this was less likely due to the patient's signalment. Radiographic imaging of the leg was sought to confirm the diagnosis. However, the SARS-CoV-2 lockdown response mandated by the New Zealand Government (<https://www.health.govt.nz/>) meant this had to be postponed until after restrictions were lifted. The

deer was treated with 20 mg/kg S/C oxytetracycline (Bivatop 200 Injection, Boehringer Ingelheim (NZ) Ltd., Auckland, NZ).

One month later, lockdown restrictions eased, and imaging could be conducted. Two views of the right metatarsus were obtained while the hind was standing and minimally restrained, including mediolateral and plantarodorsal views centred at the mid-diaphyseal region. In addition, there was now a discharging fistula present (Figure 1A). The firm swelling and pain response had increased markedly since first examination, consistent with the periosteal reaction. The results of the radiograph confirmed the presence of an osseous sequestrum, and osteomyelitis (Figure 1B) and arrangements were made to perform a sequestrectomy. The hind was treated again with 20 mg/kg S/C oxytetracycline and this was repeated 3 days later.

One week after the radiograph was taken, the hind was sedated with 0.8 mg/kg 5% xylazine (Phoenix Xylazine 5% injection; Phoenix Pharm Distributors Ltd.), Auckland, New Zealand) given by I/M injection into the neck. Once recumbent a tourniquet was placed just below the hock, and the leg clipped. The tourniquet remained in position throughout the surgery. Intravenous regional anaesthesia using 5 mL 2% lignocaine (Nopaine 2%, Phoenix Pharm Distributors Ltd.), diluted to 20 mL with sterile water, was injected under pressure into a superficial vein identified on the anterior lateral aspect of the metatarsus, using a 19-gauge butterfly needle. A total of 15 mL of diluted lignocaine was injected. The site was surgically scrubbed and prepared whilst the I/V regional anaesthesia took effect.

An elliptical skin incision was made longitudinally around the fistula using a number 15 scalpel blade. Blunt dissection was then used to extend the incision to the periosteum, using the fibrous tissue surrounding the fistula as a guide to locate the sequestrum. The skin edges were retracted using a small Gelpi retractor. A mallet and 6-mm osteotome were then used to remove sufficient periosteal new bone from the cloaca (the cavity in the bone surrounding the sequestrum) to allow removal of the sequestrum using haemostats (Figure 1C). The bone sequestrum measured 30.0 mm × 11.2 mm × 4.9 mm (Figure 1D). The operation site was then flushed with sterile normal saline (Baxter Sodium Chloride for Irrigation; Baxter Healthcare Ltd, Auckland, NZ) and the edges of the wound loosely opposed using Glycolide & eCaprolactone (SilverGlide Pty Ltd, Castle Hill, NSW, Australia) gauge 1–0 suture material. A Robert Jones pressure bandage was then placed over the surgery site, encompassing the whole lower limb, including the foot, and removed 4 days later. At completion of

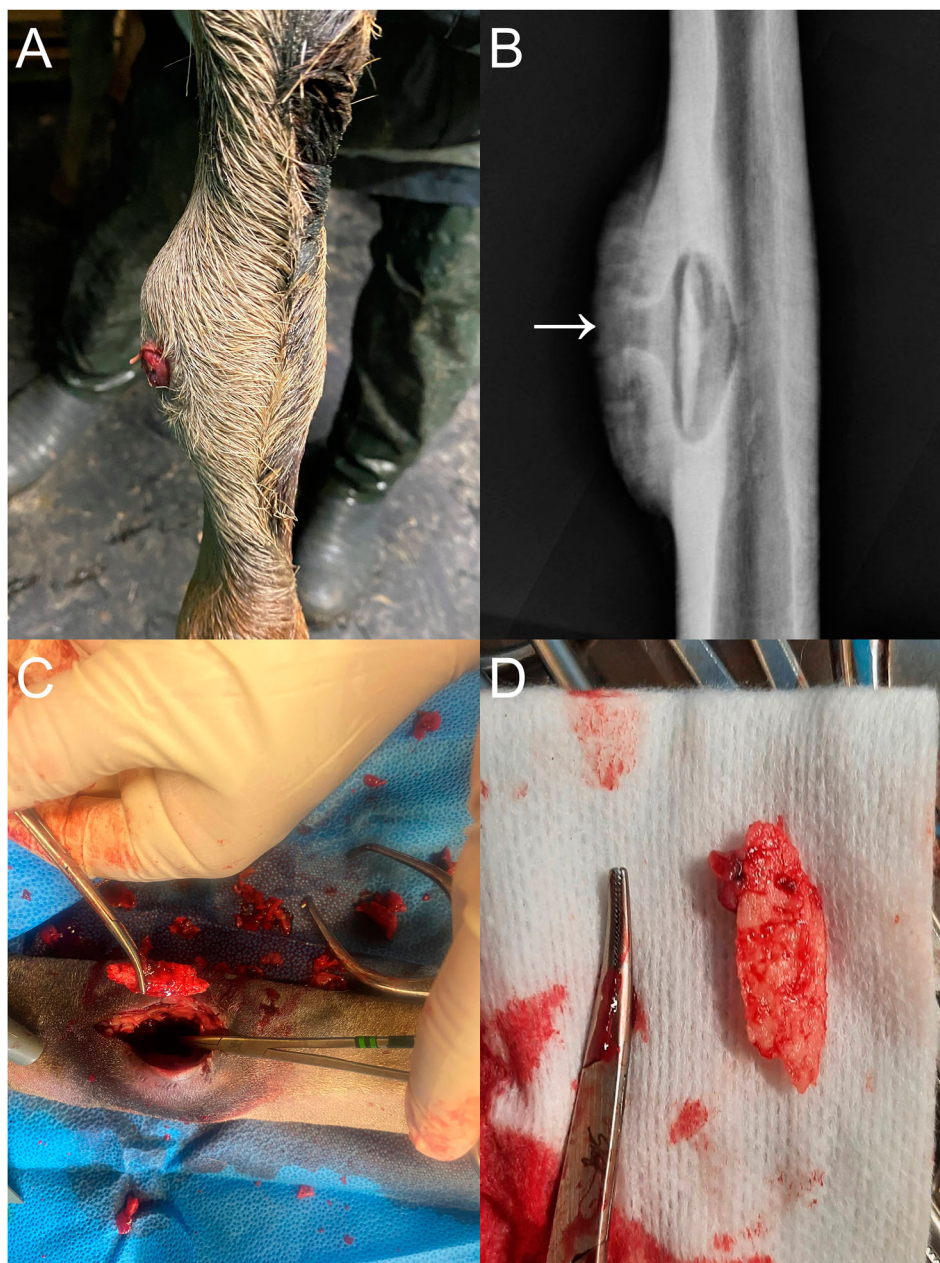


Figure 1. Images of a rising 1-year-old red deer (*Cervus elaphus*) hind that presented for severe lameness, taken 1 month after initial presentation, showing (A) lesion on the medial aspect of the right hindlimb and (B) mediolateral radiographic view of the right hind leg revealing fistula (white arrow) and the bone sequestrum, within a cloaca, surrounded by substantial periosteal new bone formation. Photographs showing (C) surgical removal of the bony sequestrum after debridement of the periosteal bone reaction 1 week later and (D) the bony sequestrum positioned on a 10 × 10 cm surgical swab for scale.

the surgery, the hind was treated with 20 mg/kg S/C oxytetracycline and 0.5 mg/kg S/C meloxicam (Metacam; Boehringer Ingelheim (NZ) Limited, Auckland, NZ), which was repeated when the bandage was removed. The xylazine sedation was reversed using 0.2 mg/kg yohimbine (Reveral Injection; Phoenix Pharm Distributors Ltd.) administered I/V, and once standing, the deer was returned to the paddock. The surgery took approximately 30 minutes from sedation to reversal. In the follow-up period, until the end of October, the hind was placed in a smaller herd of 25, mostly male, R1 deer, before joining a herd of 33 replacement R1 hinds.

The sutures were removed 3 weeks after surgery, but the wound was not quite closed, with a small 1-cm² granulation bed protruding through the incision. The hind

now weighed 94.5 kg (BCS 3/5). There was no heat or pain elicited on palpation and the deer was observed to be walking and running sound. Given the excellent improvement, repeat radiography was considered unnecessary. There was, however, still marked swelling of the limb, which was attributed to the formation of new periosteal bone. Two months after surgery the skin was closed, and the hind weighed 103 kg, but a large amount of new bone was still palpable. No victimisation by other deer of the hind whilst wearing the bandage or afterwards was observed.

The site of this sequestrum, the metatarsus, is also the most common site for sequestra in cattle and horses (Firth 1987; Clem *et al.* 1988; Valentino *et al.* 2000). The metatarsal bones have minimal soft tissue coverage which means

that local periosteal vascular stasis is more likely to develop after trauma (Clem *et al.* 1988). At the time of the initial lameness examination, there was no evidence of physical trauma. This is not unusual with physical trauma only observed in about 55% of cattle cases (Valentino *et al.* 2000), indicating that blunt trauma may have been the likely cause of the injury in this hind. The ideal time for surgical removal of a sequestrum is 3–4 weeks after the injury (Firth 1987), as at this point the sequestrum should be loose from the underlying bone but not engulfed by the periosteal reaction. In this case, we cannot be certain when the initial injury occurred, but the delay caused by the SARS-CoV-2 lockdown could have allowed time for additional formation of new bone making more debridement necessary than if it had been possible to operate earlier.

Bacterial culture was not carried out in this case, but when done, mixed infections, often including *Trueperella pyogenes*, are commonly reported in cattle (Valentino *et al.* 2000). However, since it is the removal of the nidus of infection that is the object of the treatment, it is likely that antibiotics play only a minor role in resolving the problem (Booth 1998).

The surgery in this case was successful – the hind made a full recovery and was retained for breeding. This was not unexpected, as sequestrectomy reportedly has a good success rate in other species, with 78% of affected cattle making a full recovery after surgery (Valentino *et al.* 2000). The straightforward nature of the surgery, combined with the generally good prognosis following sequestrectomy, mean that surgical treatment should be considered as a routine option for general practitioners presented with similar cases.

Acknowledgements

The authors would like to acknowledge the help of Geoff Purchas in the management of this case.

References

- Audigé L, Wilson P, Morris R, Davidson G.** Osteochondrosis, skeletal abnormalities and enzootic ataxia associated with copper deficiency in a farmed red deer (*Cervus elaphus*) herd. *New Zealand Veterinary Journal* 43, 70–6, 1995
- Audigé L, Wilson P, Morris R.** Disease and mortality on red deer farms in New Zealand. *Veterinary Record* 148, 334–40, 2001
- Badger S.** Infectious epiphysitis and valvular endocarditis in a red deer (*Cervus elaphus*). *New Zealand Veterinary Journal* 30, 17–8, 1982
- *Beatson N, Thompson K, Dittmer K.** Angular limb deformities in growing farmed deer in Canterbury. *Proceedings of the Deer Branch of the New Zealand Veterinary Association*. Pp 109–10, 2011
- Booth L.** Superficial septic osteitis and sequestrum formation in the horse. *Equine Veterinary Education* 10, 233–7, 1998
- *B+LNZ.** *Compendium of New Zealand Farm Facts 2021*. [https://beeflambnz.com/sites/default/files/data/files/Compendium%](https://beeflambnz.com/sites/default/files/data/files/Compendium%202021_digital.pdf)

[202021_digital.pdf](https://beeflambnz.com/sites/default/files/data/files/Compendium%202021_digital.pdf) (accessed 12 January 2022). Beef + Lamb New Zealand, Wellington, NZ, 2021

- Challies CN.** Status and future management of the wild animal recovery industry. *New Zealand Forestry* 36, 10–17, 1991
- Clem M, DeBowes R, Yovich J, Douglass J, Bennett S.** Osseous sequestration in the horse a review of 68 cases. *Veterinary Surgery* 17, 2–5, 1988
- Daniel M.** Polydactyly in red deer, *Cervus elaphus* Linne, 1758. *New Zealand. Säugetierkundl Mitt* 15, 149–55, 1967
- Davidson MM.** A case of polydactylism in sika deer in New Zealand. *Journal of Wildlife Diseases* 7, 109–10, 1971
- Firth E.** Bone sequestration in horses and cattle. *Australian Veterinary Journal* 64, 65–9, 1987
- *Huber MJ.** Bone sequestration of the appendicular skeleton in camelids. *Proceedings. American College of Veterinary Surgeons Veterinary Symposium*. Pp 660–2, 2011
- Husheer SW, Coomes DA, Robertson AW.** Long-term influences of introduced deer on the composition and structure of New Zealand *Nothofagus* forests. *Forest Ecology and Management* 181, 99–117, 2003
- *Ingram L, Gill G.** Lameness outbreak in a group of weaner deer. *Proceedings of the Deer Branch of the New Zealand Veterinary Association*. Pp 99–100, 2010
- Mason P.** Parasites of deer in New Zealand. *New Zealand Journal of Zoology* 21, 39–47, 1994
- Pollard J, Wilson P.** Welfare of farmed deer in New Zealand. 1. Management practices. *New Zealand Veterinary Journal* 50, 214–20, 2002
- Skerman T.** Isolation of *Bacteroides nodosus* from hoof lesions in a farmed red deer (*Cervus elaphus*). *New Zealand Veterinary Journal* 31, 102–3, 1983
- Thompson K, Audigé L, Arthur D, Julian A, Orr M, McSparran K, Wilson P.** Osteochondrosis associated with copper deficiency in young farmed red deer and wapiti x red deer hybrids. *New Zealand Veterinary Journal* 42, 137–43, 1994
- Valentino LW, St. Jean G, Anderson DE, Desroches A, Kersting K, Lopez MJ, Adams SB, Huhn J, Mueller PE, Cohen ND.** Osseous sequestration in cattle: 110 cases (1987–1997). *Journal of the American Veterinary Medical Association* 217, 376–83, 2000
- *Wilson P.** Foot problems and lameness of deer. *A Deer Seminar for Veterinarians – New Zealand Veterinary Association Deer Advisory Panel*. *New Zealand Veterinary Association*. Pp 157–8, 1981

KE Lawrence

School of Veterinary Sciences, Massey University,
Palmerston North, New Zealand

✉ k.lawrence@massey.ac.nz  <http://orcid.org/0000-0002-2453-1485>

C Balcomb

School of Veterinary Sciences, Massey University,
Palmerston North, New Zealand

KJ Flay

Department of Veterinary Clinical Sciences, City University of
Hong Kong, Kowloon, Hong Kong SAR, People's Republic of
China

 <http://orcid.org/0000-0003-3770-3765>

L Whitfield

Farm Vet Services, Palmerston North, New Zealand

 <http://orcid.org/0000-0002-4368-7792>