

## CASE REPORT

# Hydrocortisone therapy in a cat with vasopressor-refractory septic shock and suspected critical illness-related corticosteroid insufficiency

Simone R. R. Pisano<sup>1</sup>, Judith Howard<sup>1</sup>, Horst Posthaus<sup>2</sup>, Alan Kovacevic<sup>1</sup> & Ivayla D. Yozova<sup>3</sup> 

<sup>1</sup>Department of Clinical Veterinary Medicine, Vetsuisse Faculty, University of Bern, Bern, Switzerland

<sup>2</sup>Department of Infectious Diseases and Pathobiology, Vetsuisse Faculty, University of Bern, Bern, Switzerland

<sup>3</sup>Institute of Veterinary, Animal and Biomedical Sciences, Massey University, Palmerston North, New Zealand

### Correspondence

Ivayla D. Yozova, Institute of Veterinary, Animal and Biomedical Sciences, Massey University, Private Bag 11-222, Palmerston North 4412, New Zealand.  
Tel: +6463505329; Fax: +6463505616;  
E-mail: i.yozova@massey.ac.nz

### Funding Information

No sources of funding were declared for this study.

Received: 23 December 2016; Revised: 5 April 2017; Accepted: 1 May 2017

doi: 10.1002/ccr3.1018

This case report was presented as an abstract (poster) at the 15th European Veterinary Emergency and Critical Care Congress in Ljubljana, Slovenia, June 2016.

## Introduction

The syndrome of critical illness-related corticosteroid insufficiency (CIRCI), previously known as *relative adrenal insufficiency*, is defined as an endocrinological dysfunction in critically ill patients, resulting in inadequate cortisol activity for the existing severity of illness and leading to fluid- and vasopressor-refractory shock [1–3]. It may result from alterations in one or more levels of the hypothalamic–pituitary–adrenal (HPA) axis and glucocorticoid metabolism pathways or from decreased glucocorticoid receptor sensitivity and tissue response to corticosteroids [4–8]. However, its multifactorial pathophysiology is only partially understood, and there is no absolute consensus regarding criteria for the diagnosis of

### Key Clinical Message

A 27-month-old female cat was presented with septic peritonitis secondary to a ruptured pyometra and subsequent pyothorax. Vasopressor-refractory septic shock led to a suspicion of critical illness-related corticosteroid insufficiency, successfully treated with intravenous hydrocortisone. Previous megestrol acetate administration may have played a role in the development of adrenocortical dysfunction.

### Keywords

Feline, pyometra, pyothorax, relative adrenal insufficiency, sepsis.

CIRCI in either human or veterinary medicine. The Surviving Sepsis Campaign recommends considering a patient to be affected by CIRCI if vasopressor-resistant shock is responsive to supplementation with hydrocortisone [9].

This study is the first case describing suspected CIRCI in a cat with septic shock and its successful treatment with hydrocortisone constant rate infusion (CRI).

## Case Presentation

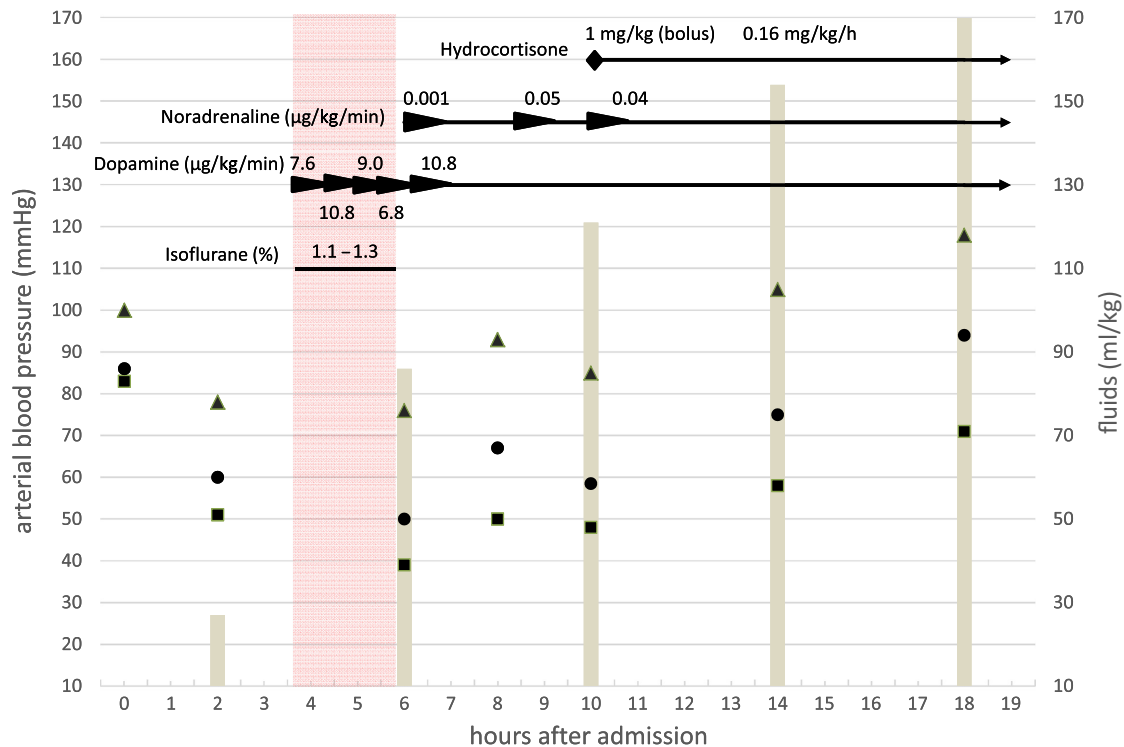
A 27-month-old, nulliparous Maine Coon queen was presented to the Emergency Service of the Small Animal Hospital of the Vetsuisse Faculty of the University of Bern, Switzerland with a two-week history of progressive

anorexia, lethargy, and weight loss. Heat cycle control with megestrol acetate (MA, 5 mg/cat PO every other week, in irregular intervals) was last administered 2 months earlier. The cat was presented in lateral recumbency, unable to stand with a heart rate of 180 beats/min, weak peripheral pulses, pale mucous membranes, capillary refill time of 2 sec, and a rectal temperature of 104°F (40°C). Severe dehydration, a poor body condition score of 2/9 and a positive fluid sign on abdominal palpation were noted. The oscillometric mean arterial blood pressure (oMAP) was 85 mmHg (Fig. 1).

Venous blood gas analysis revealed a mixed acid-base disorder with pH 7.43 (reference interval [RI], 7.28–7.41), metabolic acidosis (bicarbonate, 14.1 mmol/L; RI, 18.0–23.2 mmol/L) respiratory alkalosis (pCO<sub>2</sub>, 21.8 mmHg; RI, 32.7–44.7 mmHg), and hyperlactatemia (50.5 mg/dL [5.6 mmol/L]; RI, 0–18.0 mg/dL [0–2.0 mmol/L]). A CBC revealed leukopenia (1.52 × 10<sup>3</sup>/μL; RI, 6.5–15.4 × 10<sup>3</sup>/μL), neutropenia (0.33 × 10<sup>3</sup>/μL; RI, 2.5–12.5 × 10<sup>3</sup>/μL) with a left shift (0.91 × 10<sup>3</sup>/μL; RI, 0–0.3 × 10<sup>3</sup>/μL) and lymphopenia (0.24 × 10<sup>3</sup>/μL; RI, 1.5–7.0 × 10<sup>3</sup>/μL). A biochemistry profile revealed hyponatremia (132 mmol/L; RI, 144–159 mmol/L), hypokalemia (2.94 mmol/L; RI,

3.11–4.93 mmol/L), hypoglycemia (41.4 mg/dL [2.3 mmol/L]; RI, 57.1–102.8 mg/dL [3.17–5.71 mmol/L]), hyperglobulinemia (4.2 g/dL [42.2 g/L]; RI, 2.7–3.6 g/dL [27.4–35.5 g/L]), and hypoalbuminemia (1.0 g/dL [10.1 g/L]; RI, 3.0–4.1 g/dL [30.3–40.5 g/L]). Feline leukemia and feline immunodeficiency virus serologic tests were negative. An abdominal focused assessment with sonography for trauma scan revealed a moderate amount of echogenic fluid with small suspended particles, diagnosed as a septic exudate on cytology and later confirmed with bacteriologic culture to contain *E. coli*.

Initial medical management included two boli at 1.4 mL/kg of 25% dextrose, IV isotonic crystalloids (Plasma-Lyte A, Baxter AG, Volketswil, Switzerland) given as a 15 mL/kg bolus, followed by 10–15 mL/kg/h constant rate infusion (CRI) supplemented with 4.5% dextrose and 40 mmol/L KCl, two boli of methadone (0.2 mg/kg IV), ampicillin–sulbactam (30 mg/kg q8 h IV), metronidazole (12.5 mg/kg q12 h IV), marbofloxacin (4 mg/kg q24 h IV), and 20% human serum albumin (27 mL/kg IV over 2.5 h). Two hours after initiating fluid therapy, the heart rate was 180 beats/min with weak peripheral pulses, and mucous membranes were pale pink with a capillary refill



**Figure 1.** Time-related changes in arterial blood pressure in association with intravenous fluid therapy and administration of vasopressors and hydrocortisone in a cat with suspected CIRCI. Systolic oscillometric arterial pressures are shown as black triangles, mean oscillometric arterial pressures as black circles and diastolic oscillometric arterial pressures as black squares. Doppler arterial pressure is shown as white diamonds. Total volumes of intravenous fluids are shown as gray bars. Vasopressors and hydrocortisone are shown as black arrows. The hydrocortisone bolus is shown as a black diamond. The red area represents the duration of the general anesthesia.

time of 2 sec. The oMAP decreased to 60 mmHg (Fig. 1). The hematocrit was 24%, total solids—55 g/L and blood glucose—220 mg/dL (12.2 mmol/L). A full abdominal exploratory laparotomy revealed approximately 200 mL of fluid, a ruptured pyometra, and generalized peritonitis. An ovariohysterectomy was performed, the abdomen was copiously lavaged, and Jackson Pratt drains were placed prior to abdominal closure. The anesthetic protocol consisted of premedication with methadone (0.1 mg/kg IV) and midazolam (0.2 mg/kg IV), and induction with alfaxalone (1 mg/kg IV). Following endotracheal intubation, anesthesia was maintained using isoflurane (1.1–1.3%) in 100% oxygen. Intraoperative analgesia was provided with fentanyl (5–10  $\mu$ g/kg/h IV).

Persistent intra-operative hypotension (median Doppler systolic arterial pressure, 50 mmHg; range, 35–60 mmHg) was observed despite fluid resuscitation (55 mL/kg over 3 h) and dopamine CRI (6–10  $\mu$ g/kg/min, Fig. 1). Hypoglycemia (60 mg/dL [3.3 mmol/L]) despite supplementation and hyperlactatemia (36 mg/dL [4 mmol/L]) recurred. Hypotension continued in the postoperative period (oMAP, 58.5 mmHg; range, 45–89 mmHg) despite continued dopamine CRI. Supplementation with titrating CRI doses of noradrenaline (0.001–0.5  $\mu$ g/kg/min) resulted in minimal transient improvement (Fig. 1). Immediately following surgery, the hematocrit was 26%, total solids—58 g/L, blood glucose—80 mg/dL (4.4 mmol/L), and blood lactate—42.3 mg/dL (4.7 mmol/L). Critical illness-related corticosteroid insufficiency (CIRCI) was suspected based on persistent hypotension unresponsive to fluid therapy (total fluid volume, 130 mL/kg over 10 h) and to vasopressors (Fig. 1) despite high basal cortisol concentrations at presentation (10.4  $\mu$ g/dL; RI, 0.5–8.80  $\mu$ g/dL). Hydrocortisone was administered IV (initial bolus of 1 mg/kg followed by 0.16 mg/kg/h CRI). Normotension (oMAP, 86 mmHg; range, 70–94 mmHg), correction of hypoglycemia and an improvement in the general condition of the cat were observed within 3 h and maintained throughout the hospitalization (Fig. 1). Intravenous supplementation with dextrose and vasopressor therapy was tapered and discontinued over 3 and 16 h, respectively. Hydrocortisone therapy was reduced by 50% every 48 h and discontinued over 5 days.

One day after surgery, the cat developed mild dyspnea. A thoracic ultrasound revealed minimal pleural and pericardial effusions. Echocardiography revealed mild inhomogeneity of the ventricular wall, suggestive of possible myocarditis, and minimal pericardial effusion. Pleural fluid real-time PCR for feline Corona virus was negative. Cytology revealed a septic exudate, confirmed to be hemolytic *E. coli* on bacterial culture. Blood cultures were negative. The pyothorax was treated with

intermittent thoracocentesis followed by placement of bilateral chest drains and intermittent lavage during 4 days. Bacterial culture and sensitivity revealed that *E. coli* cultured from both body cavities was sensitive to marbofloxacin but *E. coli* cultured from the peritoneal cavity was resistant to ampicillin and rifampicin, and *E. coli* cultured from the pleural cavity was resistant to all penicillins and 1st- and 3rd-generation cephalosporins. Monotherapy with marbofloxacin was, therefore, continued.

## Outcome and Follow-up

The cat was discharged 14 days after presentation in good general condition with a good appetite and a body condition score of 3/9 with instructions to continue administration of oral marbofloxacin (4 mg/kg q24 h) for a further 10 days. On follow-up examination 1 month later, the cat had a body condition score of 4/9, and no clinical abnormalities were noted. Echocardiography revealed persistence of myocardial changes but no functional abnormalities.

Three months later, the cat was presented because of acute lethargy in lateral recumbency with a rectal temperature of 91.4°F (33.1°C) and dehydration. Emergency blood work revealed a high packed cell volume (58%; RI, 27–47%) and total solids (11.6 g/dL [116 g/L]; RI, 5.5–7.6 g/dL [55–76 g/L]), elevated plasma creatinine (3.3 mg/dL [287  $\mu$ mol/L]; RI, 0.8–2.4 mg/dL [71–212  $\mu$ mol/L]), and hypoglycemia (55.8 mg/dL [3.1 mmol/L]). Venous blood gas analysis revealed acidemia (pH, 7.13), metabolic acidosis (bicarbonate, 12.8 mmol/L), and hyperlactatemia (68.5 mg/dL [7.6 mmol/L]). The cat was treated with IV crystalloids supplemented with dextrose but suffered cardiopulmonary arrest within a few hours of presentation. Cardiopulmonary resuscitation was not attempted as the owner had requested a do not resuscitate order.

Necropsy, performed with the owner's consent, revealed mild myocardial arteriosclerosis, and bilateral diffuse adrenocortical hyperplasia and hypertrophy with moderate cytoplasmic vacuolization, but no lesions explaining the cause of death were identified.

## Discussion

Reports of CIRCI in veterinary literature are limited to rare case reports and evaluation of the HPA axis in small groups of critically ill animals. In most veterinary publications, evaluation of HPA-axis impairment was based on delta cortisol values (the difference in cortisol concentrations before and after administration of adrenocorticotrophic hormone [ACTH]) [10]. Lower delta cortisol

values and higher free cortisol fractions were reported in six dogs with septic shock compared to healthy controls [11]. In one study, dogs with severe trauma, sepsis or gastric dilation-volvulus were found to have decreased delta cortisol values compared to controls. Furthermore, dogs with lower delta cortisol values were more likely to receive vasopressors [12]. In another report, both hypotension and decreased survivals were found to be associated with lower delta cortisol values in septic dogs [13]. Decreased delta cortisol levels were additionally reported in a small population of critically ill cats [14]. Despite such reports in the veterinary literature, current recommendations in human medicine do not support use of the ACTH-stimulation test to identify patients with CIRCI requiring corticosteroid treatment [4, 9, 15]. Instead, CIRCI is suspected when fluid therapy and vasopressor-resistant shock (usually failure to maintain SAP > 90 mmHg or MAP > 65 mmHg) are responsive to hydrocortisone administration [4, 15, 16]. Likewise, the diagnosis of suspected CIRCI in the cat in the present report was based on clinical findings and response to therapy.

Previous reports of treatment of suspected CIRCI in veterinary medicine include a dog with hydrocortisone-responsive septic shock [17] and a cat with polytrauma-related hypotension responsive to intravenous dexamethasone [18]. Additionally, one abstract reports a prospective blinded placebo-controlled study in eight dogs treated with either hydrocortisone or an equivalent volume of saline, but results were inconclusive due to the small number of dogs enrolled [19]. While intermittent and CRI administration of hydrocortisone appear to be equally effective in people with CIRCI, dexamethasone is not recommended due to its prolonged suppression of the HPA axis [4]. Although different hydrocortisone treatment regimens have been reported in both veterinary and human medicine [3, 4, 9, 10, 20], the ultimate goal of therapy is to provide doses of hydrocortisone adequate for the needs of the patient. The cat in the present report was treated with a dose suggested in both human [4] and veterinary literature [21], as evidence-based therapeutic guidelines for cats are lacking.

Basal cortisol levels in the cat in the present report were above reference ranges, similar to previous reports in critically ill dogs and cats [11, 14] but in contrast to the normal levels found in the previously reported polytraumatized cat with suspected CIRCI [18]. However, as CIRCI may result from different aspects of HPA axis impairment, including tissue resistance or decreased receptor sensitivity, basal cortisol levels may be above or below reference ranges and be insufficient to meet the needs of the patient [2, 4, 11].

Although CIRCI has mostly been associated with septic shock, other causes including traumatic brain injury and cancer have been reported in people [22–24]. Similarly, the previously reported case of feline CIRCI was a cat with polytrauma [18]. In addition, evidence of CIRCI based on ACTH-stimulation testing was found in critically ill cats with neoplasia [25]. Septic shock was likely the main cause of CIRCI in the cat reported here, but predisposing factors, including drug exposure should be considered [26, 27]. Megestrol acetate administration has been associated with metropathies [28–30], and likely played a role in the development of pyometra in this cat. Moreover, MA administration may lead to reversible and potentially fatal HPA axis suppression in both humans and cats [31–34], thereby implicating it in the development of CIRCI itself. However, adrenocortical recovery after MA administration (2.5 mg/cat q24 h or 5 mg/cat q48 h for 2 weeks) was found to only require 2–4 weeks [34–36]. The cat in the present report received a similar dose and the last dose reported by the owner was 8 weeks prior presentation. Even if the owner was mistaken about the timing of the last dose of MA, basal cortisol would be expected to be <1 µg/mL in MA-induced HPA axis suppression [34], but basal cortisol measured in this cat was elevated. Moreover, hydrocortisone therapy is considered necessary in people with CIRCI regardless of cause, and treatment response in this cat is evidence of CIRCI responding to hydrocortisone whether or not MA played a role in its development [33].

The use of alfaxalone, a synthetic allopregnanolone analog as an anesthesia induction agent, might have interfered with the HPA axis in this patient. Indeed, allopregnanolone may increase production of endogenous opioids, which downregulate corticotropin-releasing hormone production by presynaptic inhibition of norepinephrine release [37, 38]. Nevertheless, alfaxalone failed to induce HPA suppression in ovario-hysterectomized sows as opposed to endogenous allopregnanolone in pregnant sows [39]. Furthermore, alfaxalone was reported to increase cortisol levels in anesthetized rabbits [40], and an alfaxalone/alfadolone mixture has been reported to increase cortisol levels in rats and people [41, 42]. To the authors' knowledge, the effects of alfaxalone on the HPA axis in cats have not been investigated. Moreover, as hypotension was observed prior to anesthesia, alfaxalone administration is unlikely to have caused CIRCI in the cat described in this report.

Although reports on histopathologic findings in CIRCI patients are rare, severe adrenal hemorrhage secondary to bacterial infection (Waterhouse–Friderichsen syndrome), most commonly to meningococcal sepsis, is described in humans and has been associated with the development of CIRCI [43, 44]. In the case described herein, necropsy

revealed bilateral diffuse adrenocortical hyperplasia and hypertrophy, which has previously been associated with chronic stress [45], pituitary hyperadrenocorticism [46, 47], hyperaldosteronism [48], and congenital adrenal hyperplasia [49]. Although ACTH-stimulation testing is not considered useful during initial shock management, a convalescent ACTH-stimulation test may, therefore, have been of benefit to investigate adrenal function in this case. The failure to perform an ACTH-stimulation test when the cat presented for follow-up examination is, therefore, a limitation of this report. Necropsy also revealed adrenocortical cytoplasmic vacuolization, which has been described in association with toxicosis [50] and MA administration [34]. However, reversible adrenocortical atrophy rather than hyperplasia would be expected if vacuolization was due to MA or hydrocortisone administration [34]. Whether the observed histopathologic changes were secondary to CIRCI or an underlying disease predisposing to CIRCI in this case remains unclear. Furthermore, as necropsy was performed 2 months after initial presentation, the observed histopathologic findings may be unrelated to the presenting sepsis, shock, or CIRCI. Indeed, no macroscopic adrenal changes were observed during laparotomy, although abdominal exploration may have been limited due to hypotension and the desire to curtail the duration of anesthesia. To the authors' knowledge, necropsy findings of adrenal glands of animals with suspected CIRCI have not been previously reported.

In conclusion, this is the first report of suspected CIRCI in a cat with septic shock treated successfully with hydrocortisone. Critical illness-related corticosteroid insufficiency should be recognized as a potential cause of fluid- and vasopressor-refractory septic shock in cats, and treatment with hydrocortisone considered in such cases. Although unclear in this case, prior exposure to MA and other drugs that may affect the HPA axis could potentially contribute to the development of CIRCI.

## Acknowledgments

The authors would like to thank Dr. med.vet. Ulrich Rytz, Dipl. ECVS for his valuable clinical input.

## Authorship

SP: performed the literature review and wrote the manuscript. JH: corrected and revised the manuscript. HP: wrote and revised parts of the manuscript. AK: wrote and revised parts the manuscript. IDY: performed the literature review, guided the author in writing the manuscript, revised and approved final version of the manuscript.

## Conflict of Interest

The authors declare no conflict of interest.

## References

- Annane, D., E. Bellissant, V. Sebille, O. Lesieur, B. Mathieu, J. C. Raphael, et al. 1998. Impaired pressor sensitivity to noradrenaline in septic shock patients with and without impaired adrenal function reserve. *Br. J. Clin. Pharmacol.* 46:589–597.
- Creedon, J. M. 2015. Controversies surrounding critical illness-related corticosteroid insufficiency in animals. *J. Vet. Emerg. Crit. Care* 25:107–112.
- Martin, L. G. 2011. Critical illness-related corticosteroid insufficiency in small animals. *Vet. Clin. North Am. Small Anim. Pract.* 41:767–782, vi.
- Marik, P. E., S. M. Pastores, D. Annane, G. U. Meduri, C. L. Sprung, W. Arlt, et al. 2008. Recommendations for the diagnosis and management of corticosteroid insufficiency in critically ill adult patients: consensus statements from an international task force by the American College of Critical Care Medicine. *Crit. Care Med.* 36:1937–1949.
- Kanczkowski, W., M. Sue, K. Zacharowski, M. Reincke, and S. R. Bornstein. 2015. The role of adrenal gland microenvironment in the HPA axis function and dysfunction during sepsis. *Mol. Cell. Endocrinol.* 408:241–248.
- Schroeder, S., M. Wichers, D. Klingmuller, M. Hofer, L. E. Lehmann, T. von Spiegel, et al. 2001. The hypothalamic-pituitary-adrenal axis of patients with severe sepsis: altered response to corticotropin-releasing hormone. *Crit. Care Med.* 29:310–316.
- de Jong, M. F., N. Molenaar, A. Beishuizen, and A. B. Groeneveld. 2015. Diminished adrenal sensitivity to endogenous and exogenous adrenocorticotrophic hormone in critical illness: a prospective cohort study. *Crit. Care* 19:1.
- Peeters, B., E. Boonen, L. Langouche, and G. Van den Berghe. 2015. The HPA axis response to critical illness: new study results with diagnostic and therapeutic implications. *Mol. Cell. Endocrinol.* 408:235–240.
- Dellinger, R. P., M. M. Levy, A. Rhodes, D. Annane, H. Gerlach, S. M. Opal, et al. 2013. Surviving Sepsis Campaign: international guidelines for management of severe sepsis and septic shock, 2012. *Intensive Care Med.* 39:165–228.
- Burkitt Creedon, J. M. 2015. Critical illness-related corticosteroid insufficiency. Pp. 376–379 in D. C. Silverstein and K. Hopper, eds. *Small animal critical care medicine*, 2nd ed. Elsevier Saunders, Missouri, USA.
- Goy-Thollot, I., C. Pouzot-Nevolet, A. Barthelemy, J.-M. Bonnet, M. Pugeat, H. Dechaud, et al. 2011. Biologically active cortisol in dogs with septic shock. *J. Vet. Emerg. Crit. Care* 21(S1):S11.



12. Martin, L. G., R. P. Groman, D. J. Fletcher, E. N. Behrend, R. J. Kemppainen, V. R. Moser, et al. 2008. Pituitary-adrenal function in dogs with acute critical illness. *J. Am. Vet. Med. Assoc.* 233:87–95.
13. Burkitt, J. M., S. C. Haskins, R. W. Nelson, and P. H. Kass. 2007. Relative adrenal insufficiency in dogs with sepsis. *J. Vet. Intern. Med.* 21:226–231.
14. Prittie, J., L. Barton, M. Peterson, R. Kemppainen, P. Bergman, and P. Fox. 2003. Hypothalamo-pituitary-adrenal (HPA) axis function in critically ill cats. *J. Vet. Emerg. Crit. Care* 13:159–177.
15. Rhodes, A., L. E. Evans, W. Alhazzani, M. M. Levy, M. Antonelli, R. Ferrer, et al. 2017. Surviving sepsis campaign: international guidelines for management of sepsis and septic shock: 2016. *Intensive Care Med.* 43:304–377.
16. Annane, D., E. Bellissant, P. E. Bollaert, J. Briegel, D. Keh, and Y. Kupfer. 2015. Corticosteroids for treating sepsis. *Cochrane Database Syst. Rev.* 3:CD002243.
17. Peyton, J. L., and J. M. Burkitt. 2009. Critical illness-related corticosteroid insufficiency in a dog with septic shock. *J. Vet. Emerg. Crit. Care* 19:262–268.
18. Durkan, S., A. de Laforcade, E. Rozanski, and J. E. Rush. 2007. Suspected relative adrenal insufficiency in a critically ill cat. *J. Vet. Emerg. Crit. Care* 17:197–201.
19. Burkitt Creedon, J., and K. Hooper. 2011. Low-dose hydrocortisone in dogs with septic shock. *J. Vet. Emerg. Crit. Care.* 21(S1): S11.
20. Martin, L. G. 2014. Approach to critical illness-related corticosteroid insufficiency. Pp. 174–178 *in* J. D. Bonagura and D. C. Twedt, eds. *Kirk's current veterinary therapy XV*. Elsevier Sanders, Missouri, USA.
21. Boller, M., and D. J. Fletcher. 2015. Post-cardiac arrest care. Pp. 20, 17–25 *in* D. C. Silverstein and K. Hopper, eds. *Small animal critical care medicine*, 2nd ed. Elsevier Saunders, Missouri, USA.
22. Dimopoulou, I., S. Tsagarakis, A. T. Kouyialis, P. Roussou, G. Assithianakis, M. Christoforaki, et al. 2004. Hypothalamic-pituitary-adrenal axis dysfunction in critically ill patients with traumatic brain injury: incidence, pathophysiology, and relationship to vasopressor dependence and peripheral interleukin-6 levels. *Crit. Care Med.* 32:404–408.
23. Yang, Y., L. Liu, D. Jiang, J. Wang, Z. Ye, J. Ye, et al. 2014. Critical illness-related corticosteroid insufficiency after multiple traumas: a multicenter, prospective cohort study. *J. Trauma Acute Care Surg.* 76:1390–1396.
24. Hebbar, K. B., T. Petrillo, and J. D. Fortenberry. 2012. Adrenal insufficiency and response to corticosteroids in hypotensive critically ill children with cancer. *J. Crit. Care* 27:480–487.
25. Farrelly, J., A. Hohenhaus, and M. Peterson. 1999. Evaluation of pituitary-adrenal function in cats with lymphoma. 19th Annual Veterinary Cancer Society Conference; Wood's Hole.
26. Peeters, B., F. Guiza, E. Boonen, P. Meersseman, L. Langouche, and G. Van den Berghe. 2016. Drug-induced HPA axis alterations during acute critical illness: a multivariable association study. *Clin. Endocrinol.* 86:26–36.
27. Bornstein, S. R. 2009. Predisposing factors for adrenal insufficiency. *N. Engl. J. Med.* 360:2328–2339.
28. Norsworthy, G. D. 2016. Use of megestrol in cats. *J. Feline Med. Surg.* 18:248–249.
29. Romagnoli, S. 2015. Progestins to control feline reproduction: historical abuse of high doses and potentially safe use of low doses. *J. Feline Med. Surg.* 17:743–752.
30. Greenberg, M., D. Lawler, S. Zawistowski, and W. Jochle. 2013. Low-dose megestrol acetate revisited: a viable adjunct to surgical sterilization in free roaming cats? *Vet. J.* 196:304–308.
31. Nanjappa, S., C. Thai, S. Shah, and M. Snyder. 2016. Pharmacy report: megestrol acetate-induced adrenal insufficiency. *Cancer Control* 23:167–169.
32. Chidakel, A. R., S. B. Zweig, J. R. Schlosser, P. Homel, J. W. Schappert, and A. M. Fleckman. 2006. High prevalence of adrenal suppression during acute illness in hospitalized patients receiving megestrol acetate. *J. Endocrinol. Invest.* 29:136–140.
33. Delitala, A. P., G. Fanciulli, M. Maioli, G. Piga, and G. Delitala. 2013. Primary symptomatic adrenal insufficiency induced by megestrol acetate. *Neth. J. Med.* 71:17–21.
34. Chastain, C. B., C. L. Graham, and C. E. Nichols. 1981. Adrenocortical suppression in cats given megestrol acetate. *Am. J. Vet. Res.* 42:2029–2035.
35. Church, D. B., A. D. Watson, D. R. Emslie, D. J. Middleton, K. Tan, and D. Wong. 1994. Effects of proligestone and megestrol on plasma adrenocorticotrophic hormone, insulin and insulin-like growth factor-1 concentrations in cats. *Res. Vet. Sci.* 56:175–178.
36. Middleton, D. J., A. D. Watson, C. J. Howe, and I. D. Catterson. 1987. Suppression of cortisol responses to exogenous adrenocorticotrophic hormone, and the occurrence of side effects attributable to glucocorticoid excess, in cats during therapy with megestrol acetate and prednisolone. *Can. J. Vet. Res.* 51:60–65.
37. Frye, C. A., J. J. Hirst, P. J. Brunton, and J. A. Russell. 2011. Neurosteroids for a successful pregnancy. *Stress* 14:1–5.
38. Brunton, P. J., and J. A. Russell. 2011. Allopregnanolone and suppressed hypothalamo-pituitary-adrenal axis stress responses in late pregnancy in the rat. *Stress* 14:6–12.
39. Rault, J. L., K. Plush, T. Yawno, and P. Langendijk. 2015. Allopregnanolone and social stress: regulation of the stress response in early pregnancy in pigs. *Stress* 18:569–577.

40. Gil, A. G., G. Silvan, A. Villa, and J. C. Illera. 2012. Heart and respiratory rates and adrenal response to propofol or alfaxalone in rabbits. *Vet. Rec.* 170:444.
41. Dunn, J. D., and D. Doray. 1984. The effect of althesin on plasma corticosterone levels. *Life Sci.* 35:1585–1591.
42. Sabato, A. F., F. Beccia, and U. Petrozzi. 1980. Effects of CT 1341 (althesin) anesthesia on human adrenal cortical function. *Minerva Anesthesiol.* 46:121–128.
43. Tormos, L. M., and C. A. Schandl. 2013. The significance of adrenal hemorrhage: undiagnosed Waterhouse-Friderichsen syndrome, a case series. *J. Forensic Sci.* 58:1071–1074.
44. Harris, P., and A. Bennett. 2001. Waterhouse-Friderichsen syndrome. *New Engl. J. Med.* 345:841.
45. Ulrich-Lai, Y. M., H. F. Figueiredo, M. M. Ostrander, D. C. Choi, W. C. Engeland, and J. P. Herman. 2006. Chronic stress induces adrenal hyperplasia and hypertrophy in a subregion-specific manner. *Am. J. Physiol. Endocrinol. Metab.* 291:E965–E973.
46. Kimitsuki, K., H. Boonsriroj, D. Kojima, and C. H. Park. 2014. A case report of feline pituitary carcinoma with hypercortisolism. *J. Vet. Med. Sci.* 76:133–138.
47. Nelson, R. W., E. C. Feldman, and M. C. Smith. 1988. Hyperadrenocorticism in cats: seven cases (1978–1987). *J. Am. Vet. Med. Assoc.* 193:245–250.
48. Djajadiningrat-Laanen, S., S. Galac, and H. Kooistra. 2011. Primary hyperaldosteronism: expanding the diagnostic net. *J. Feline Med. Surg.* 13:641–650.
49. Owens, S. L., M. E. Downey, B. M. Pressler, A. J. Birkenheuer, D. W. Chandler, and J. C. Scott-Moncrieff. 2012. Congenital adrenal hyperplasia associated with mutation in an 11beta-hydroxylase-like gene in a cat. *J. Vet. Intern. Med.* 26:1221–1226.
50. Rosol, T. J., J. T. Yarrington, J. Latendresse, and C. C. Capen. 2001. Adrenal gland: structure, function, and mechanisms of toxicity. *Toxicol. Pathol.* 29:41–48.